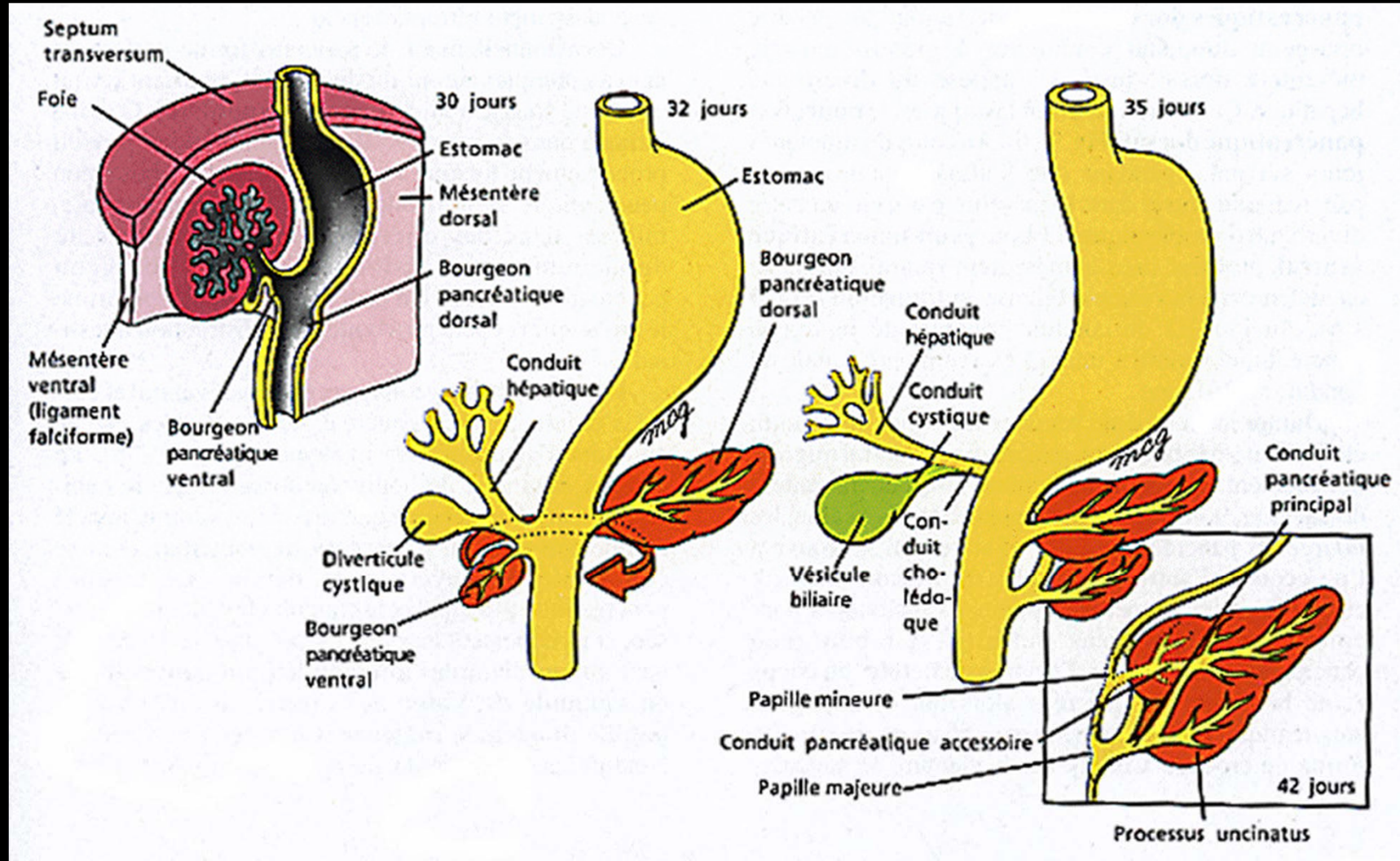
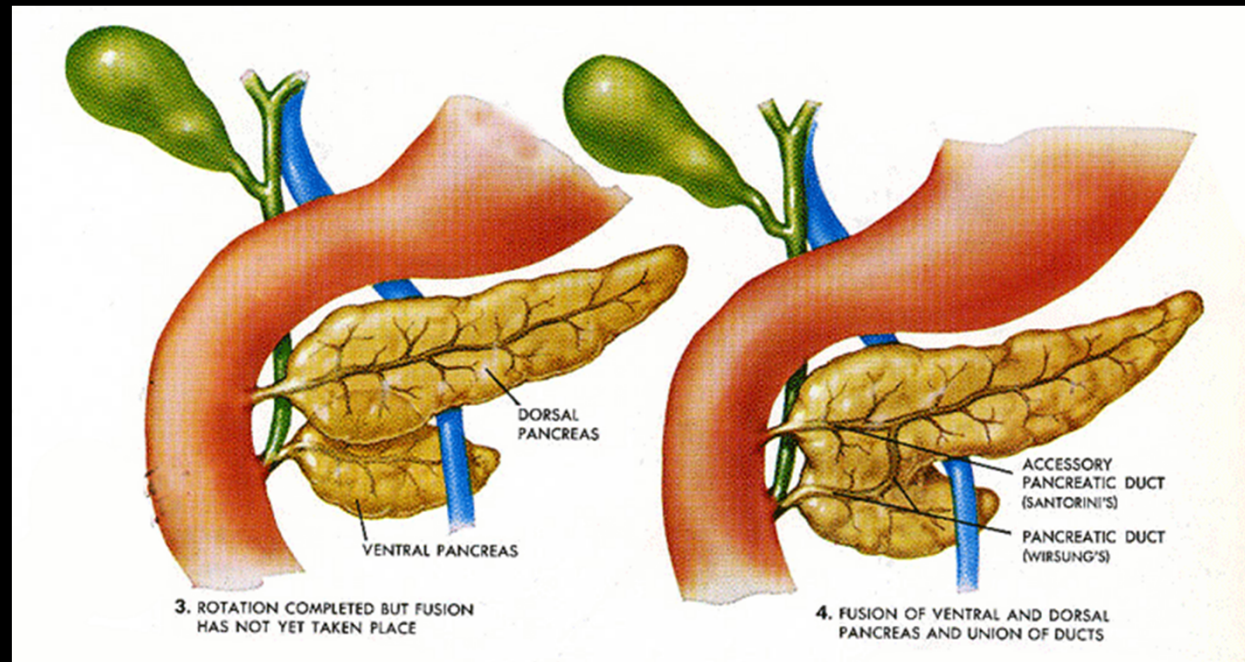
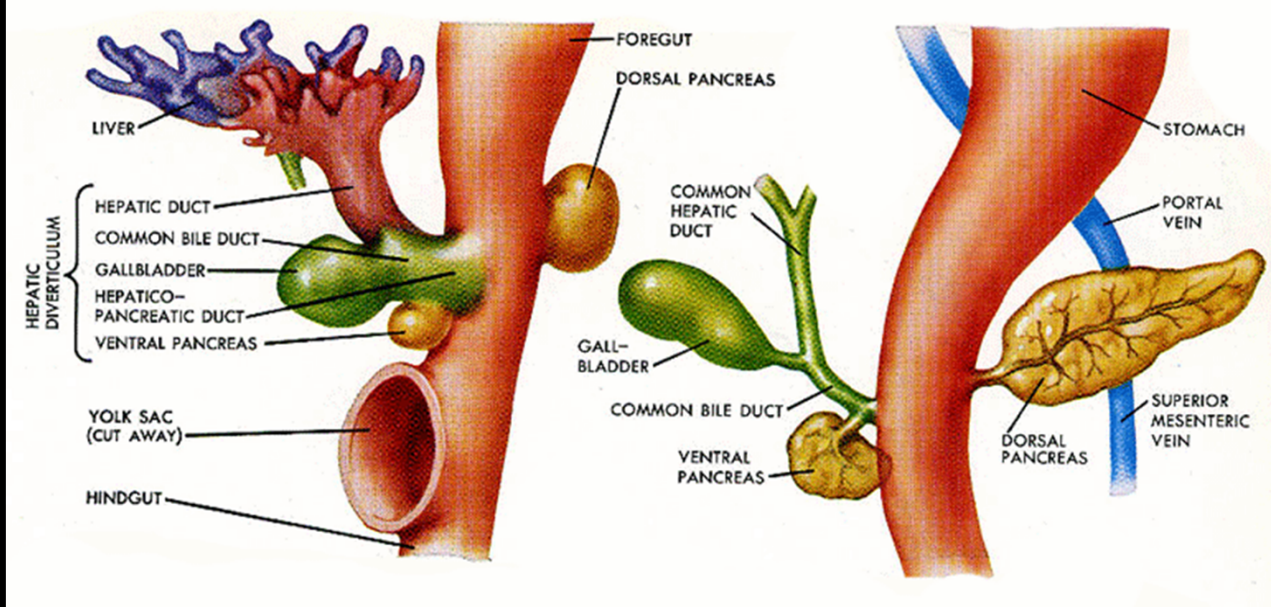
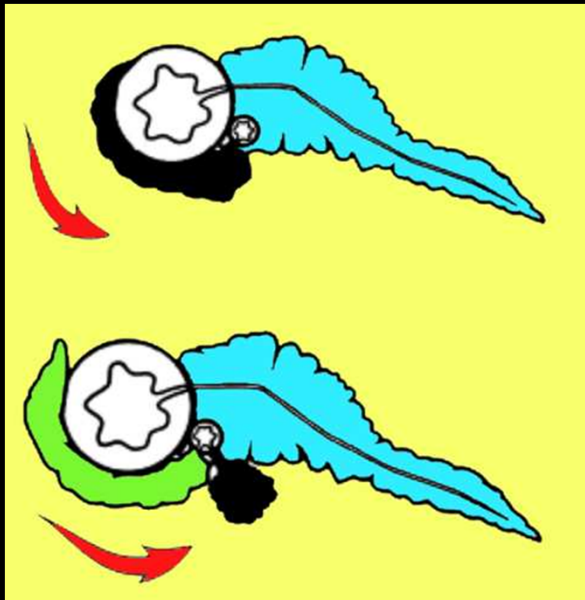


embryologie

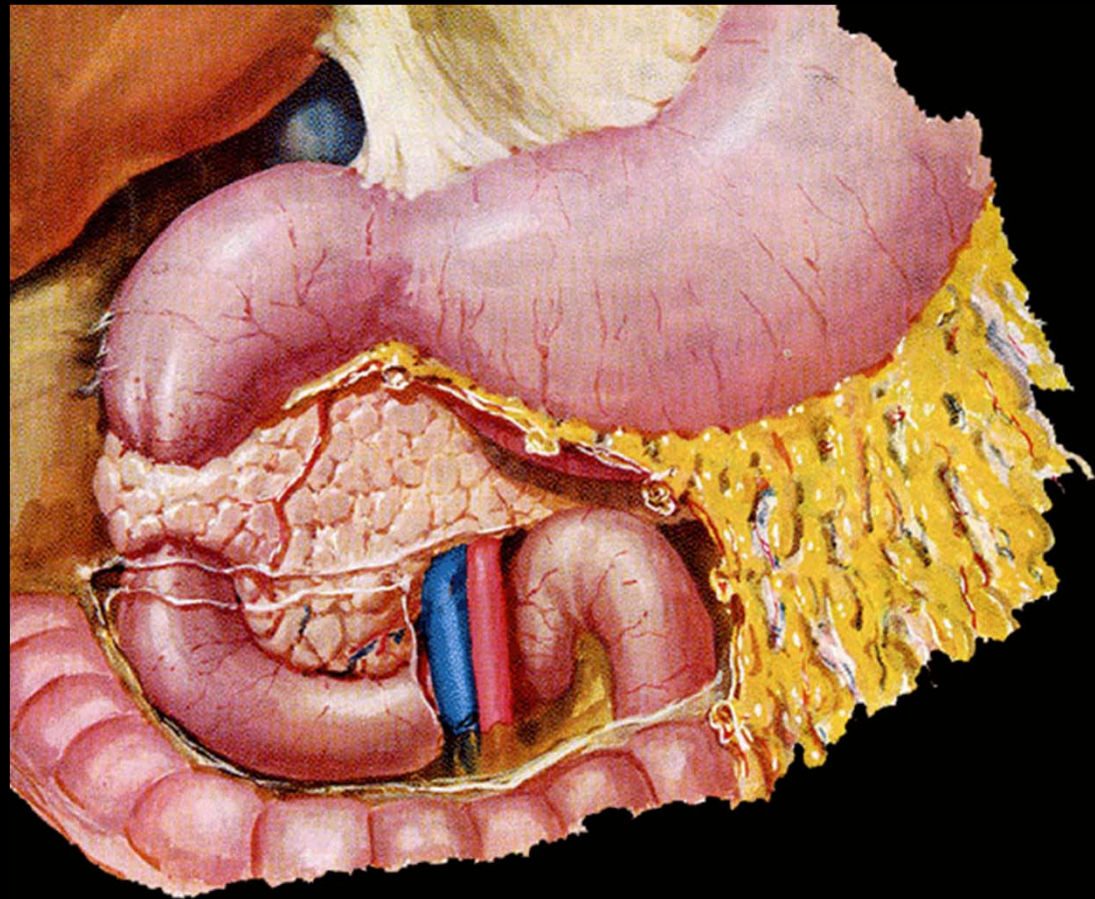


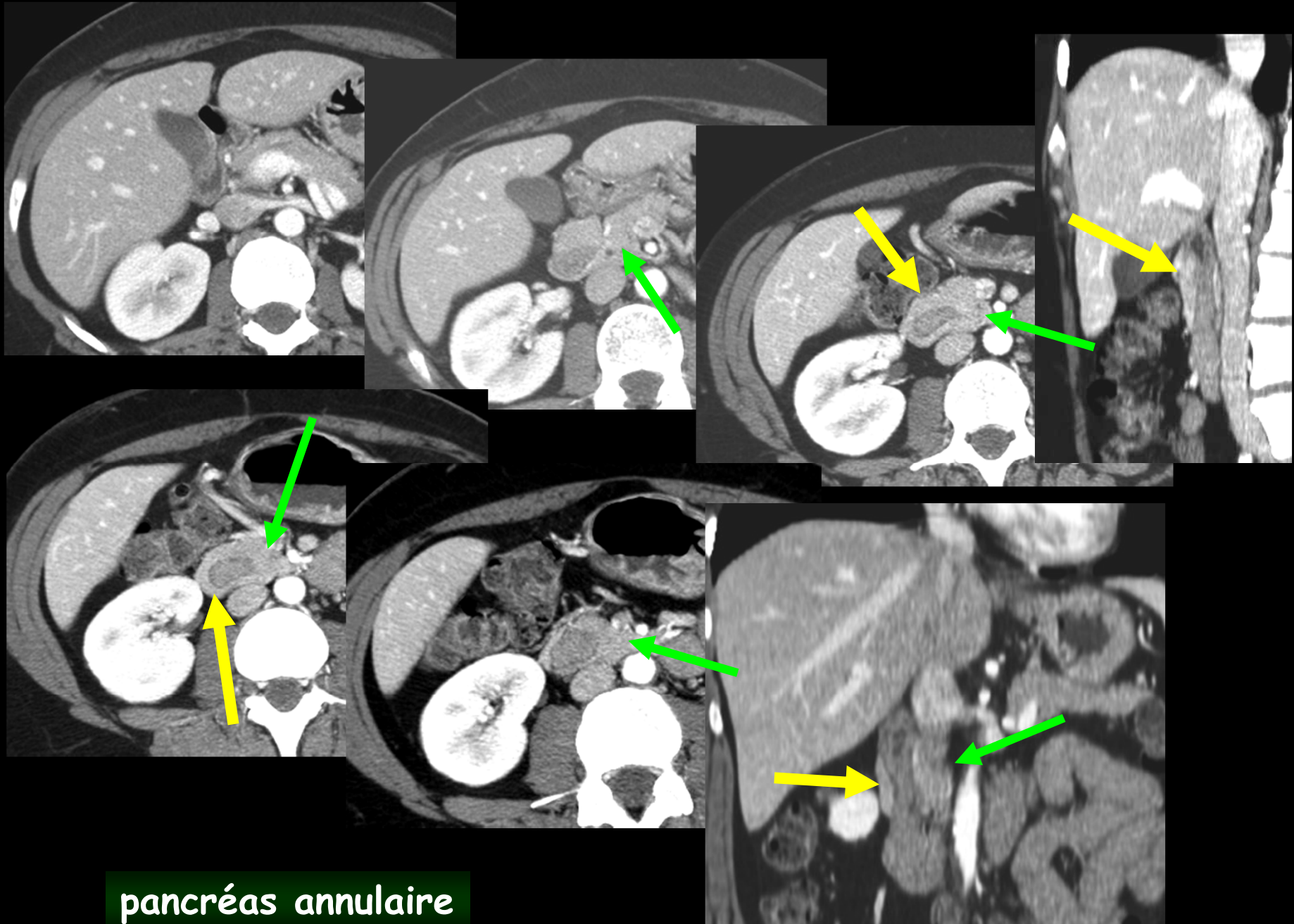
embryologie



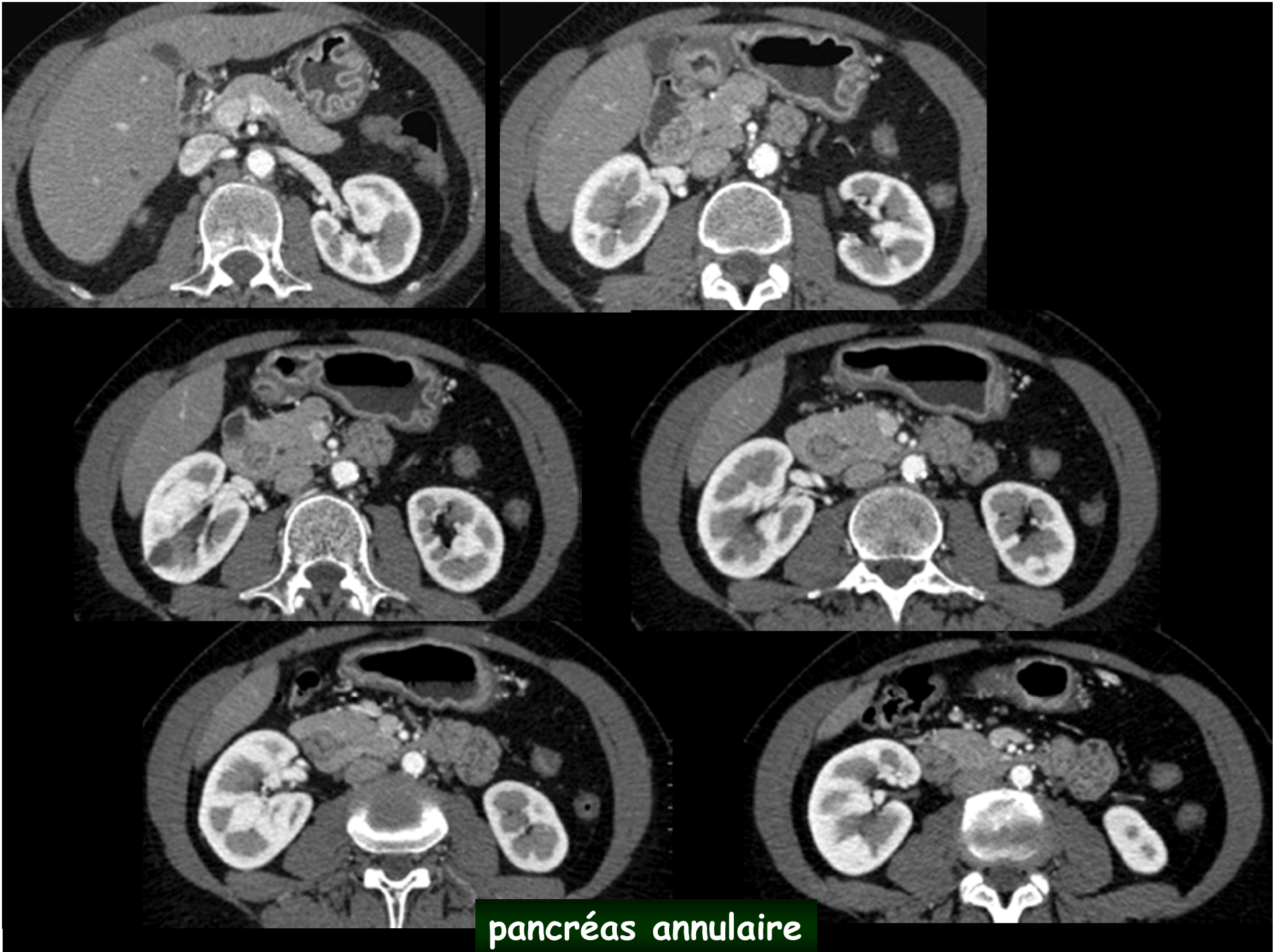


le pancréas annulaire se développe à partir de l'ébauche ventrale qui comporte elle-même 2 bourgeons ,antérieur et postérieur

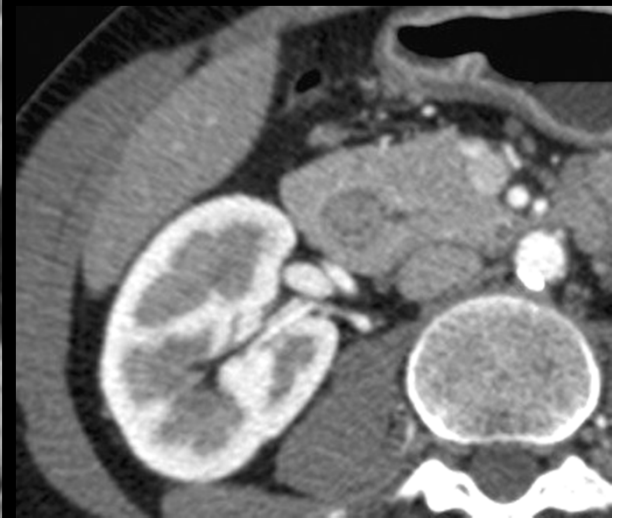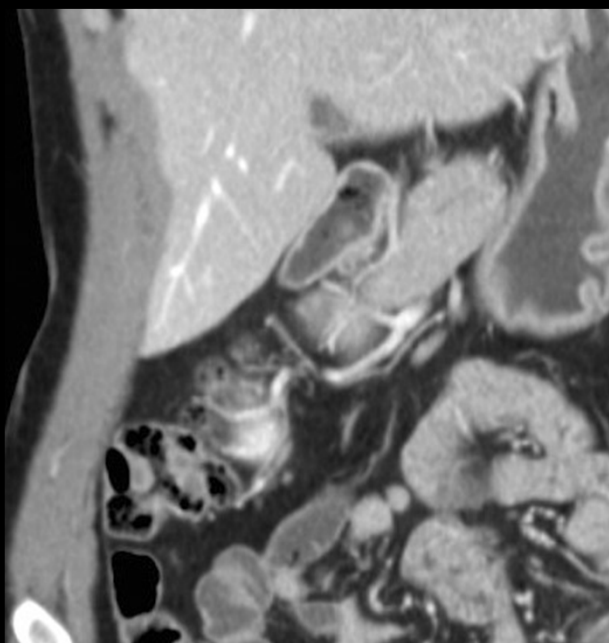
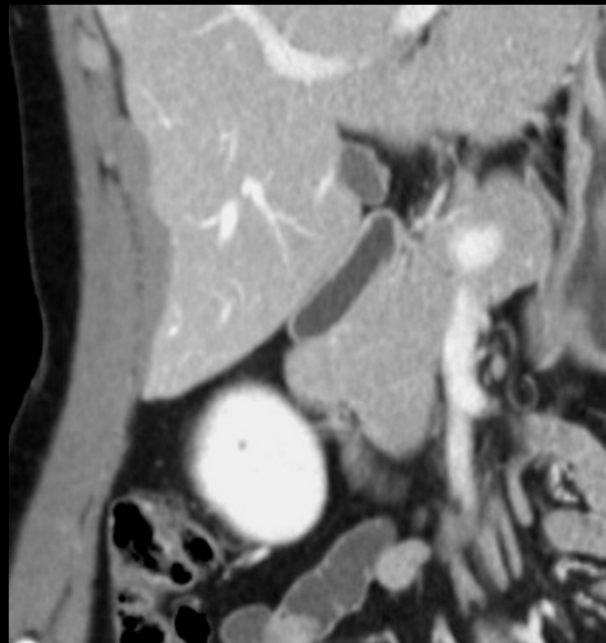
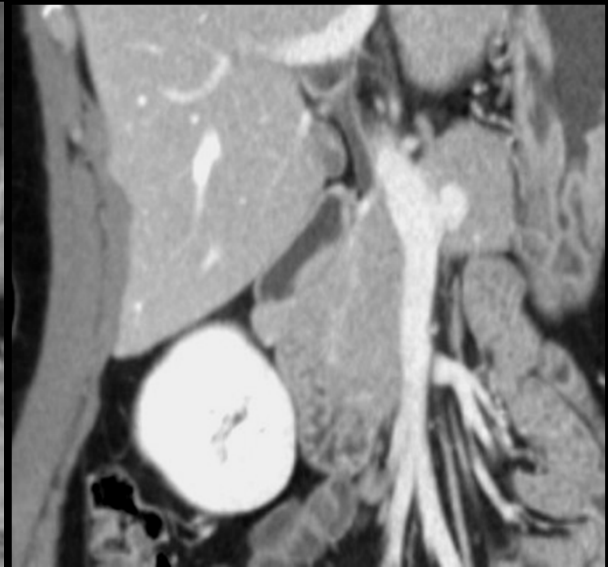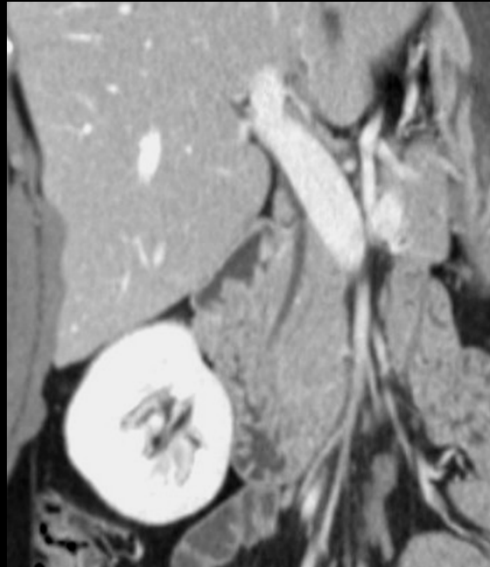
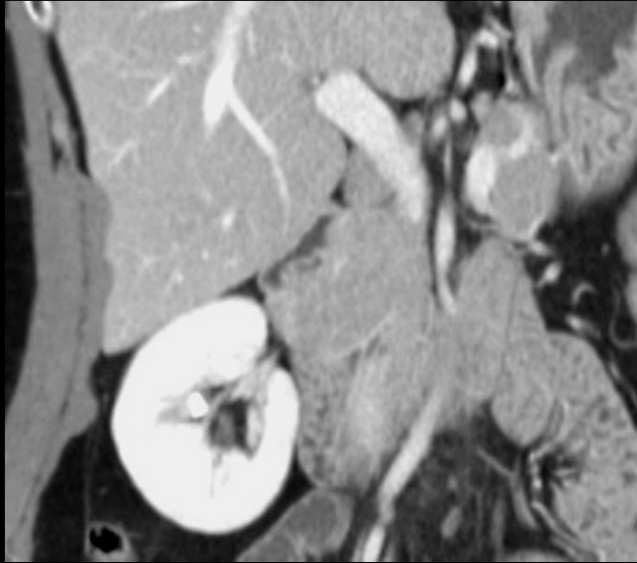




pancréas annulaire

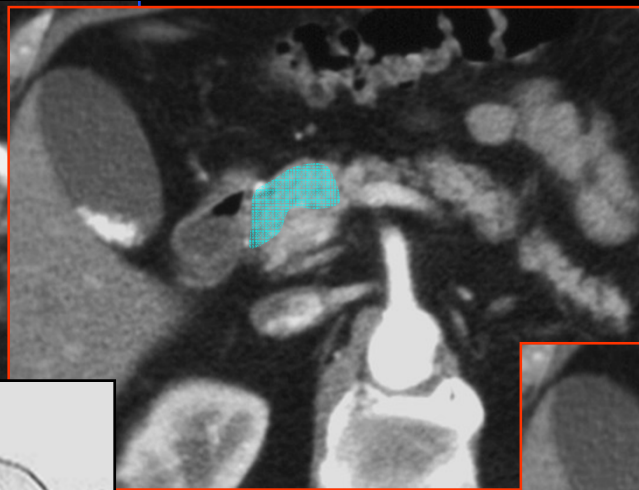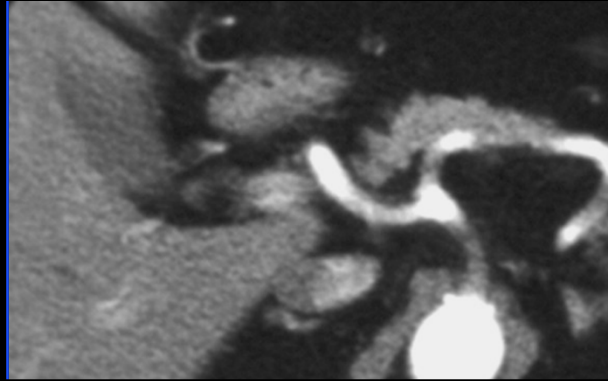


pancréas annulaire

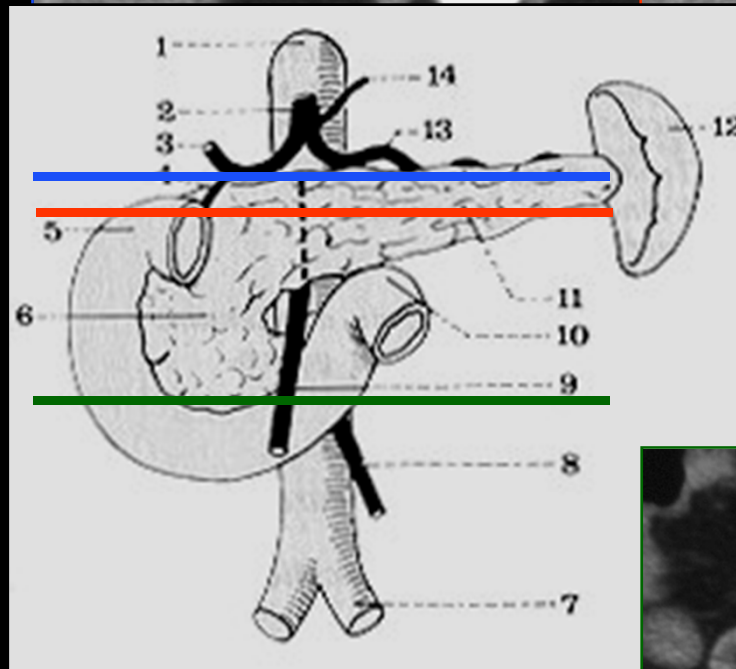


pancréas annulaire

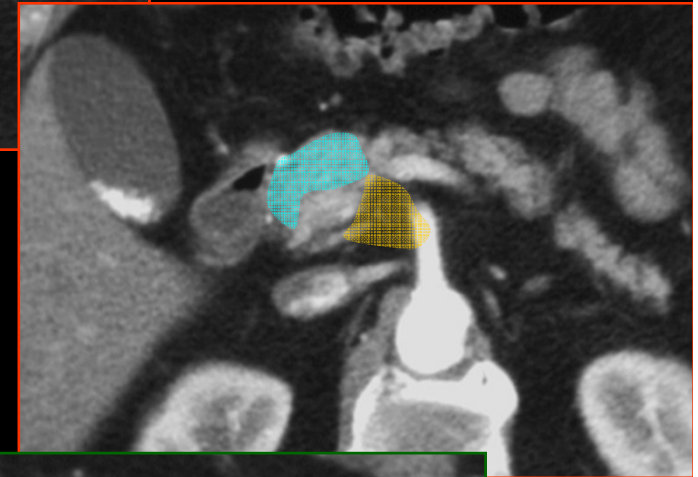
anatomie normale imagerie en coupes axiales



les 2
constituants
embryologiques
du pancréas
céphalique

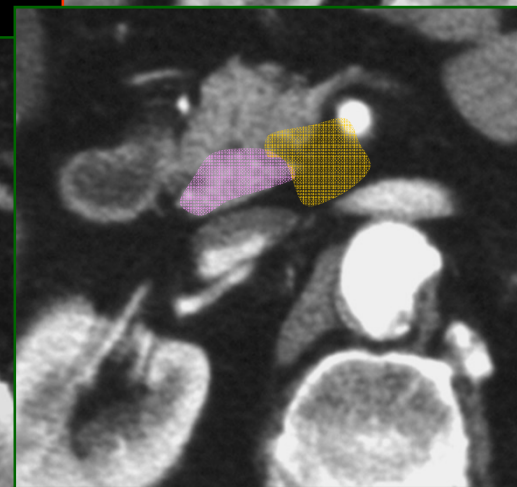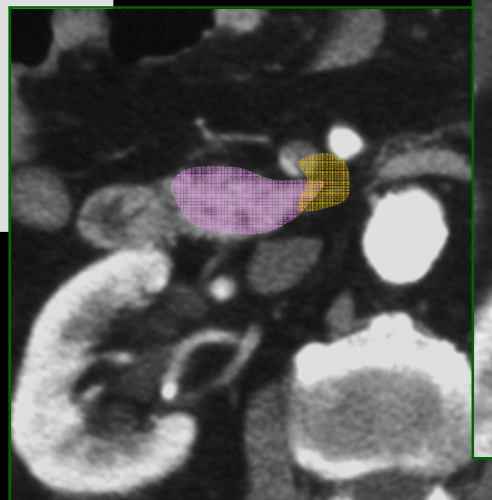


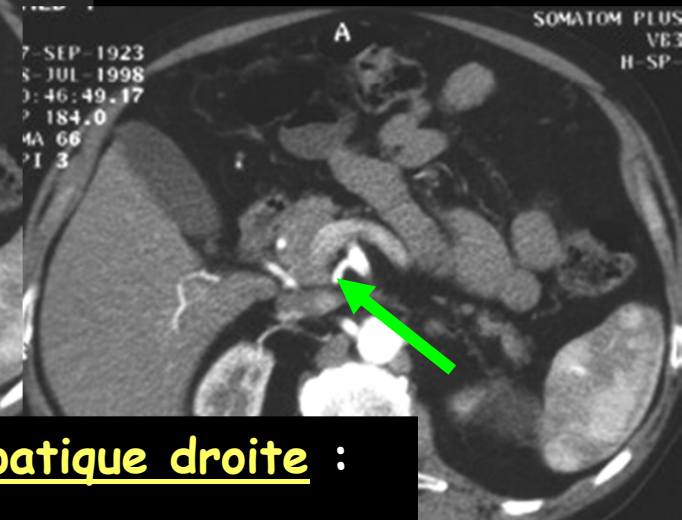
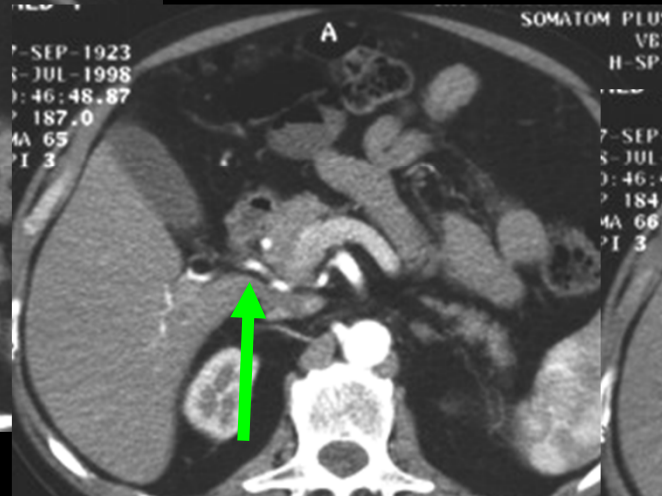
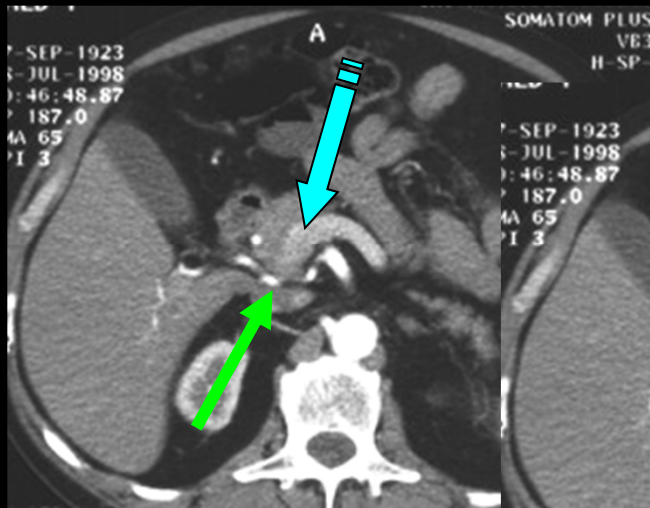
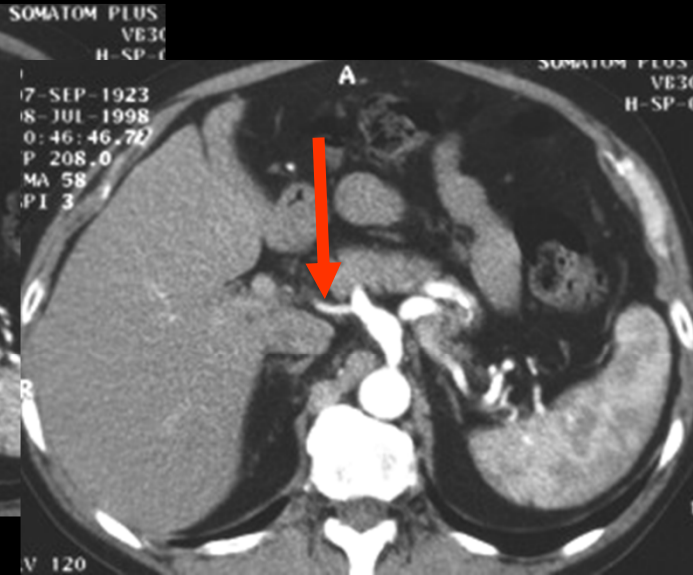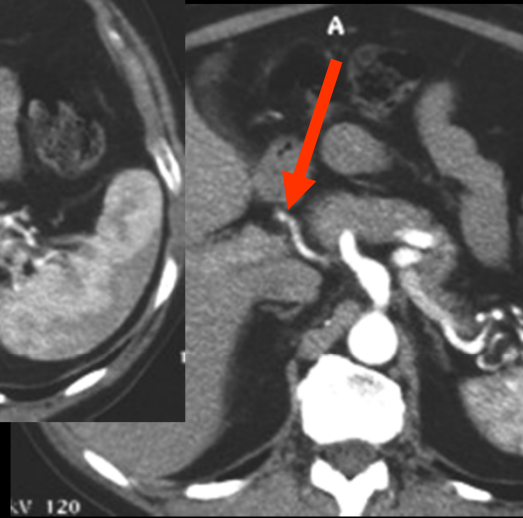
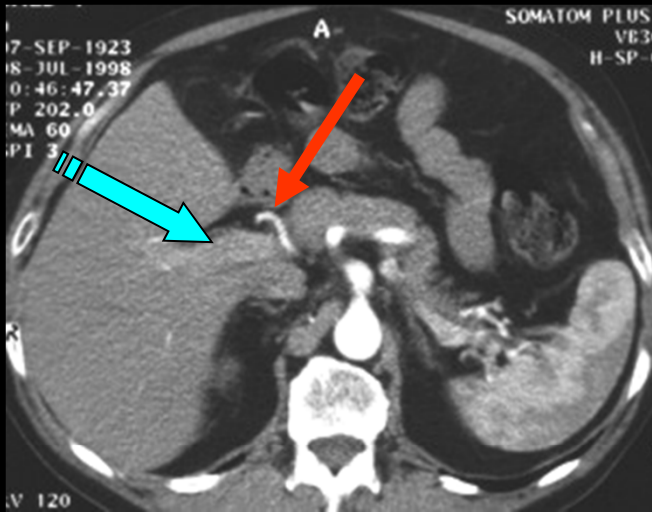
ébauche
dorsale



lame rétro-portale

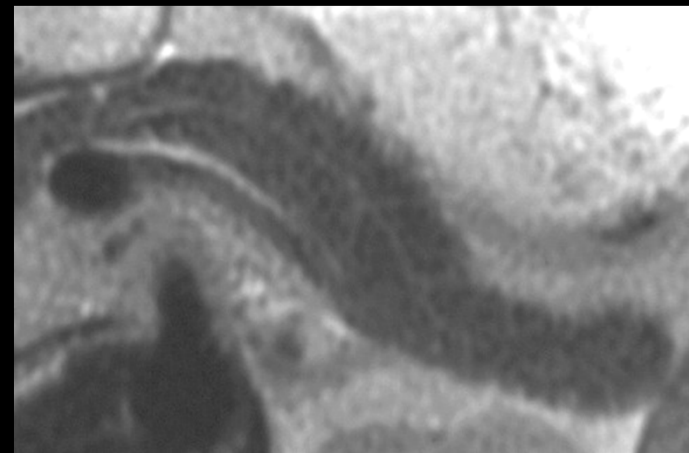
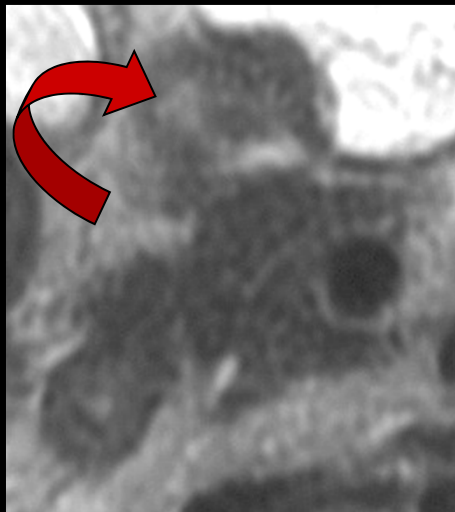
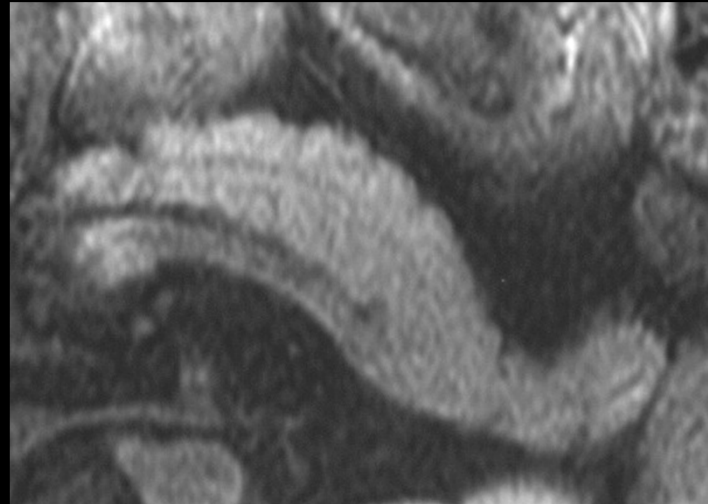
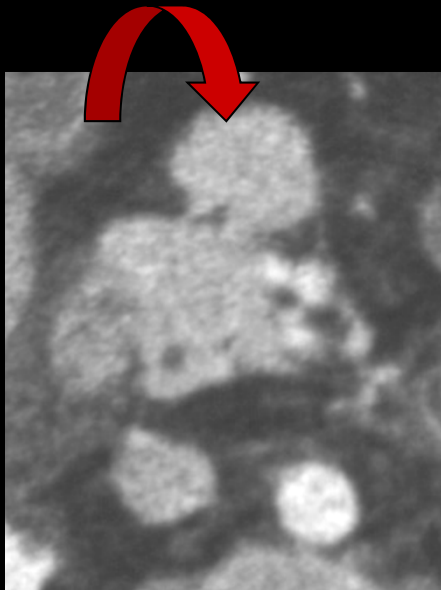
ébauche ventrale
processus unciné



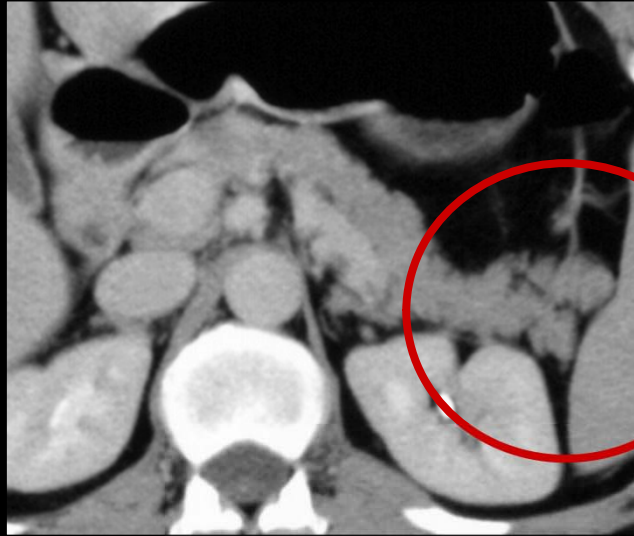

rechercher systématiquement une artère hépatique droite :
branche artérielle rétro portale dans le hiatus de Winslow

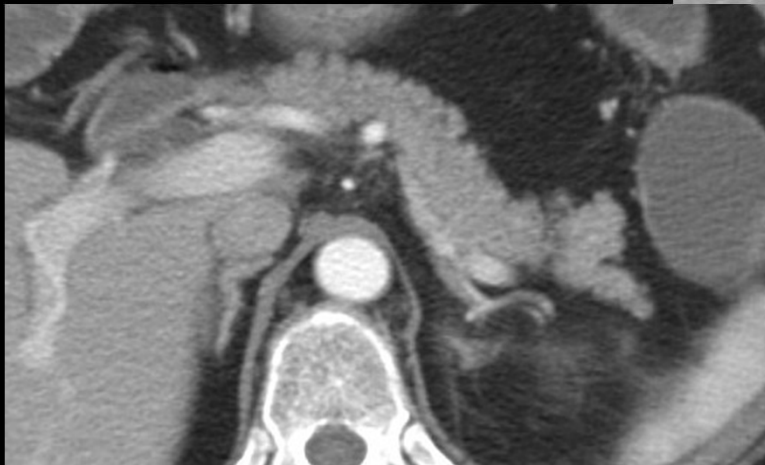
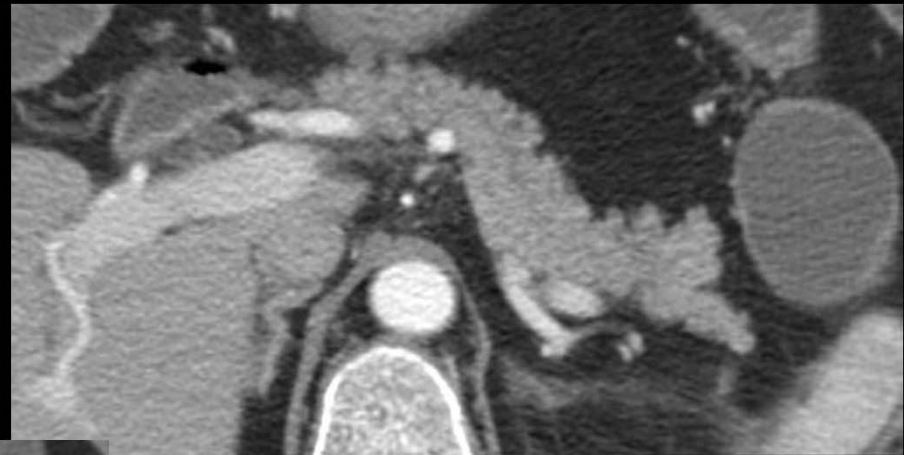
variantes morphologiques du pancréas



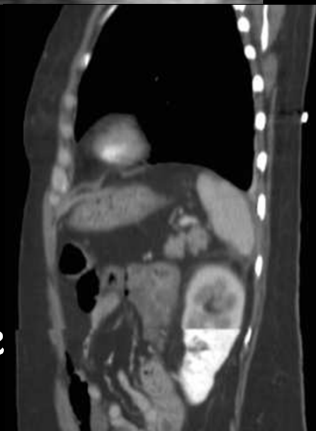tubercule omental du pancréas



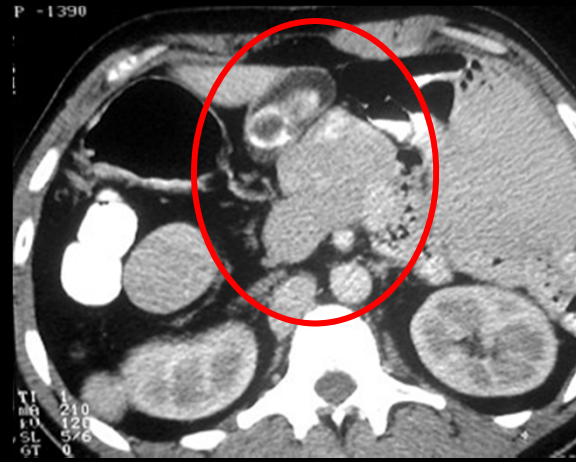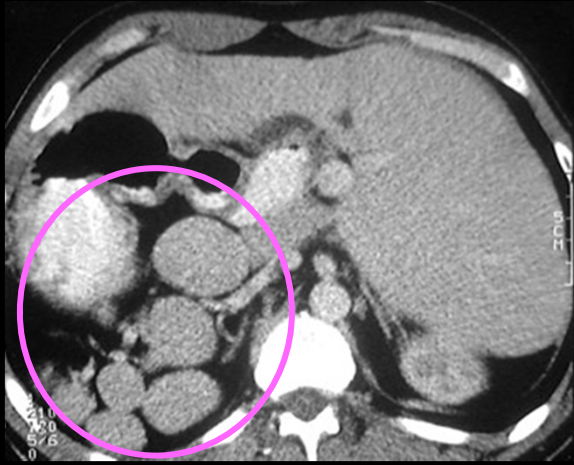
pancréas caudal bifide



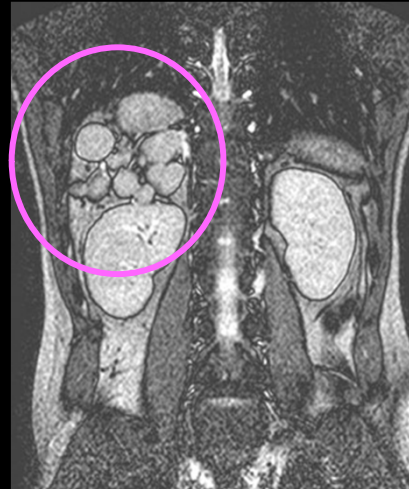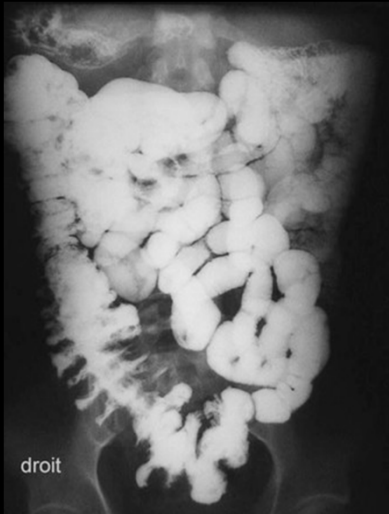
pancréas caudal bifide



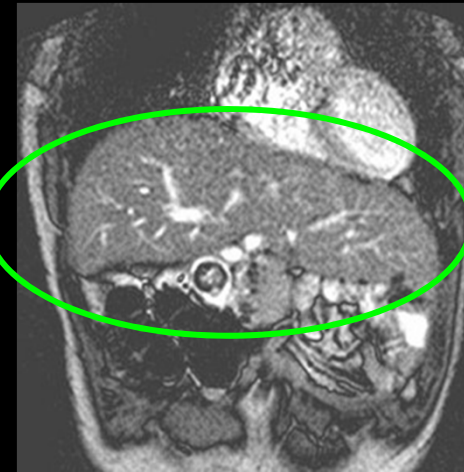
CT
sans
inj.



CT 50"



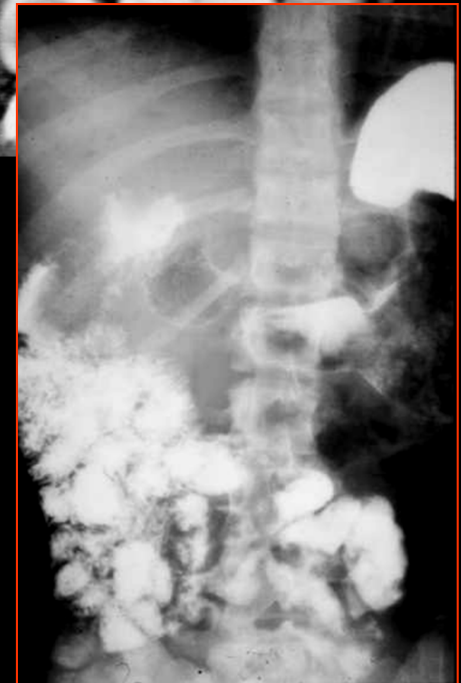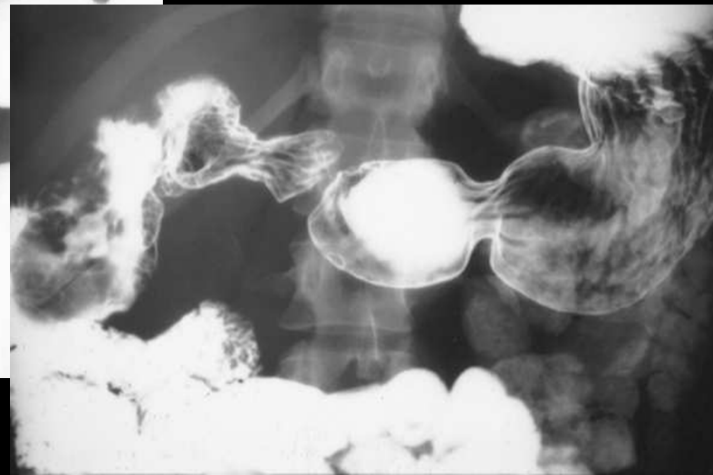
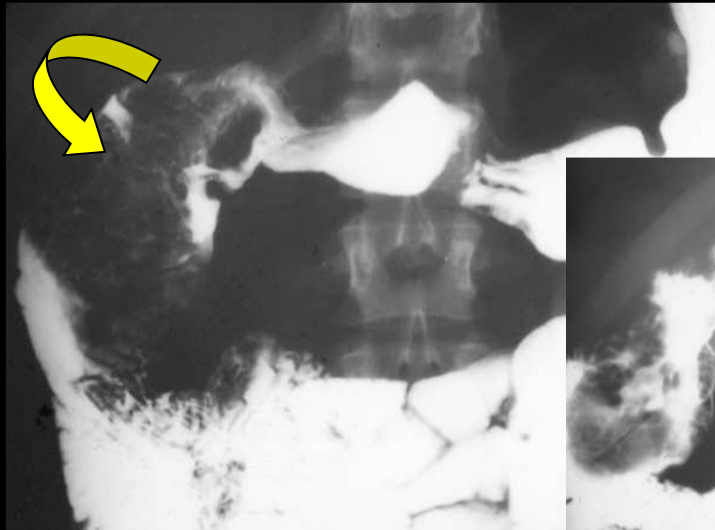
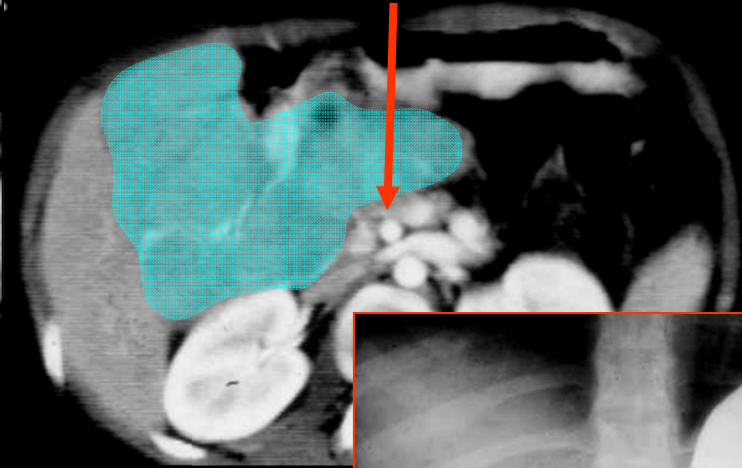
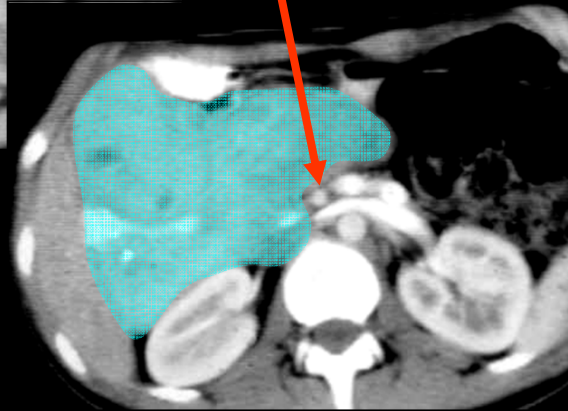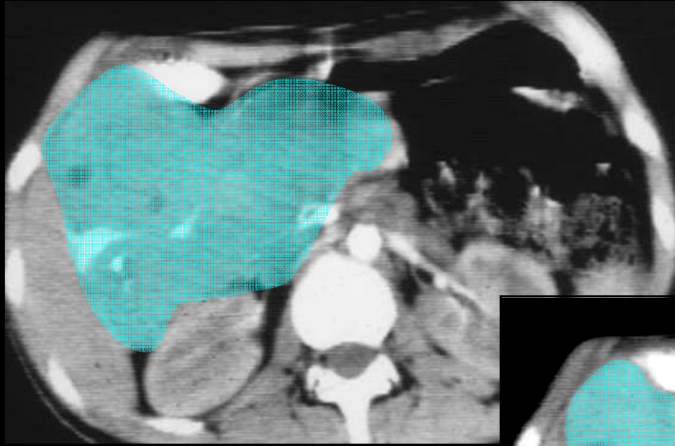
T2

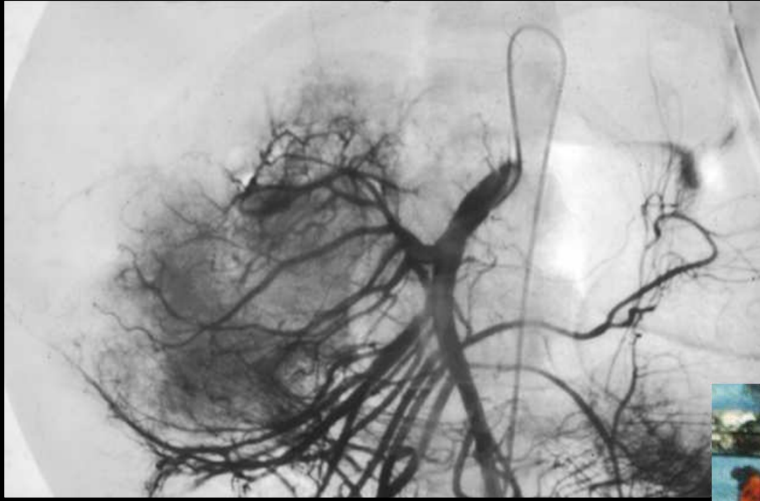

T2

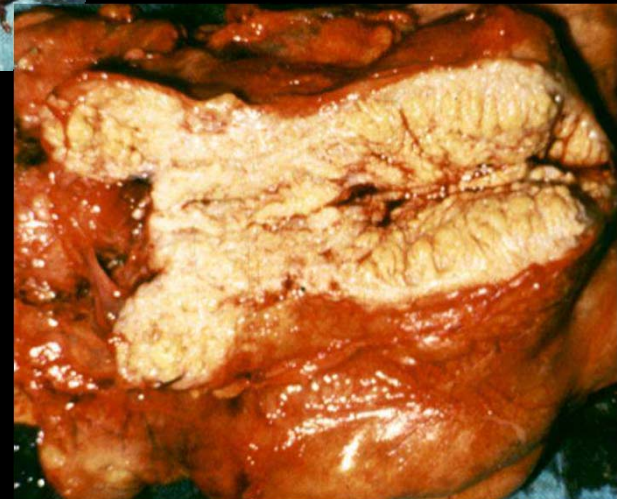
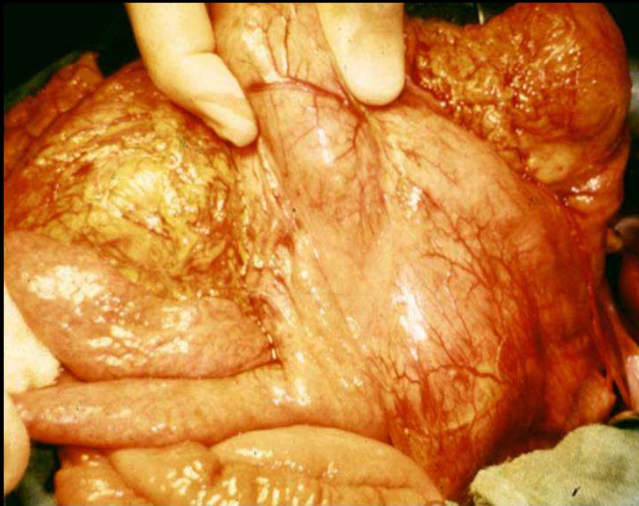
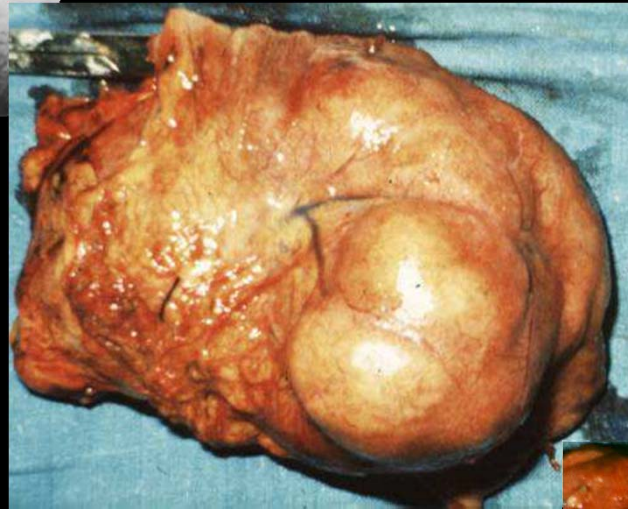
Le **syndrome de polysplénie** (**hétérotaxie** ou défaut de latéralisation) associe un isomérisme pulmonaire et hépatique , un **mésentère commun** , un **situs inversus** et un **pancréas court** , une agénésie du segment rétro hépatique avec continuation azygos de la VCI ...

jeune fille 22 ans
douleurs épigastriques
hémorragies digestives
ulcération bulbaire à l'endoscopie



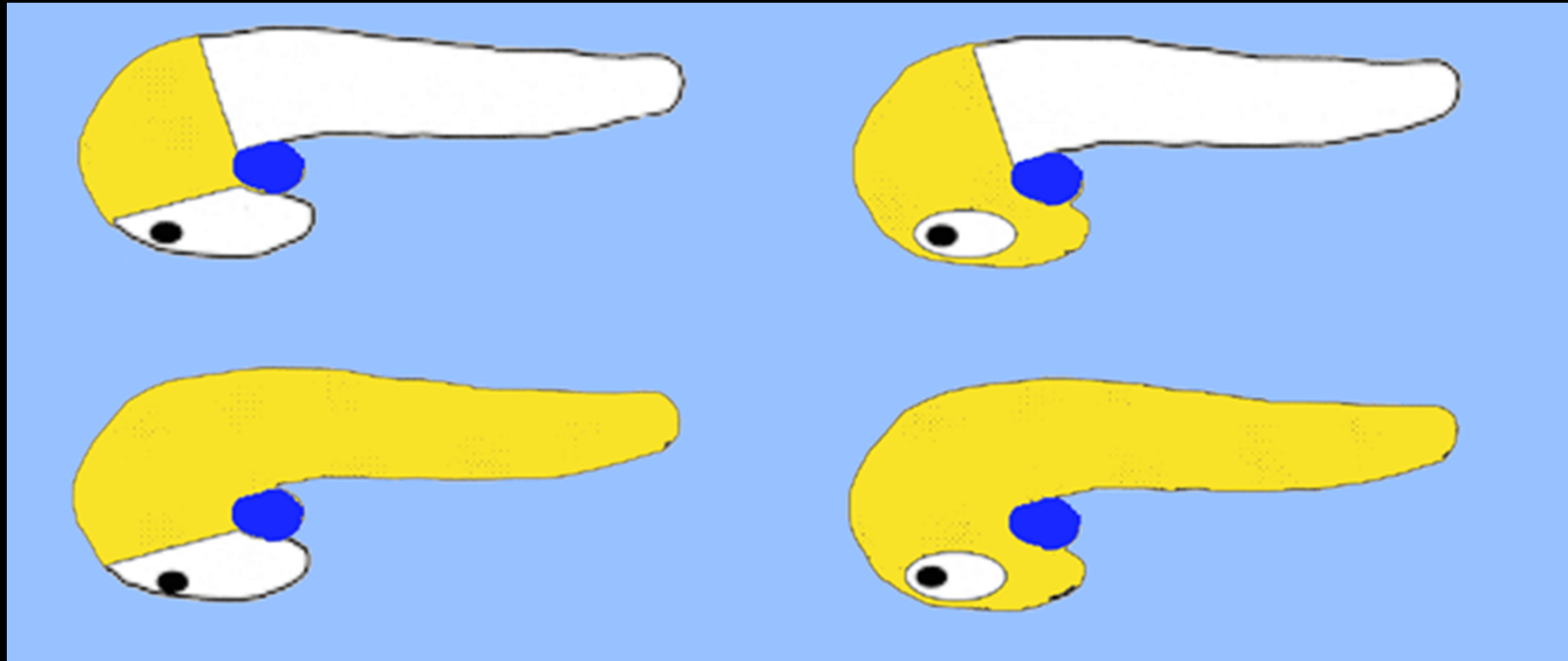


diagnostic pré (et per)- opératoire : tumeur
conjonctive (léiomyosarcome) de D2,
associée à une malrotation de l'anse
intestinale primitive de type mésentère
commun



exérèse complète de la lésion
ana-path : pancréas normal !!! ...court et
sphérique

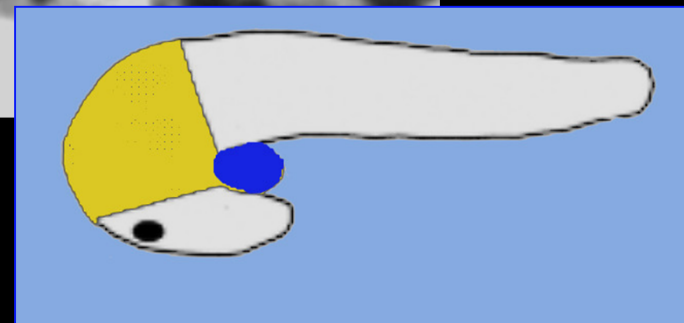
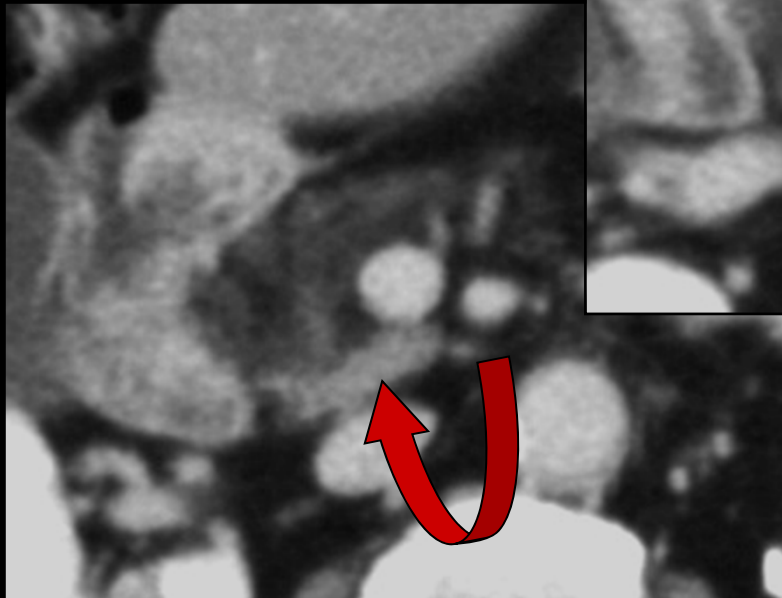
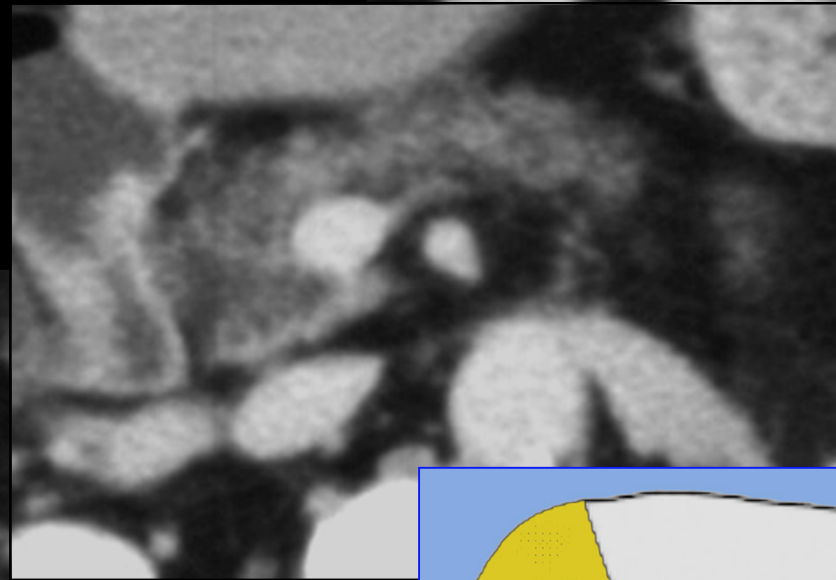
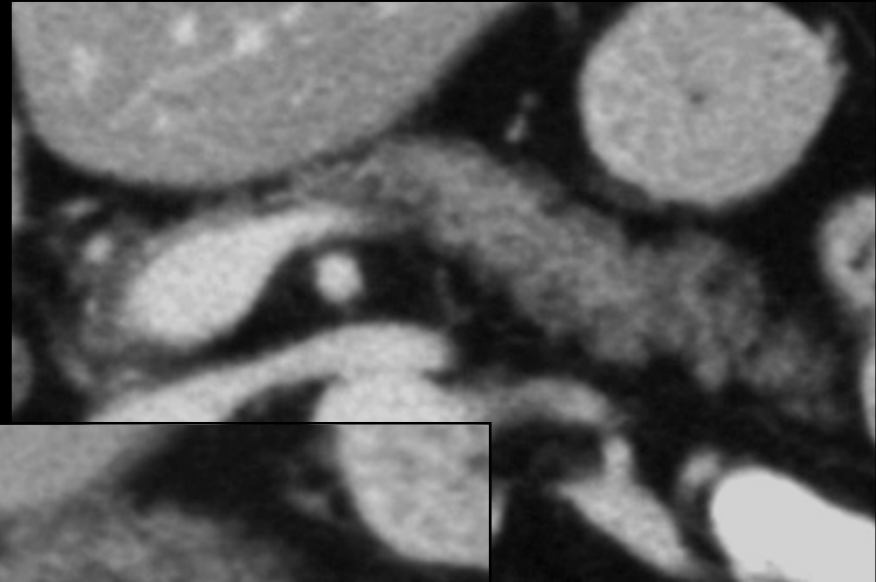
involution graisseuse (uneven lipomatosis) du pancréas

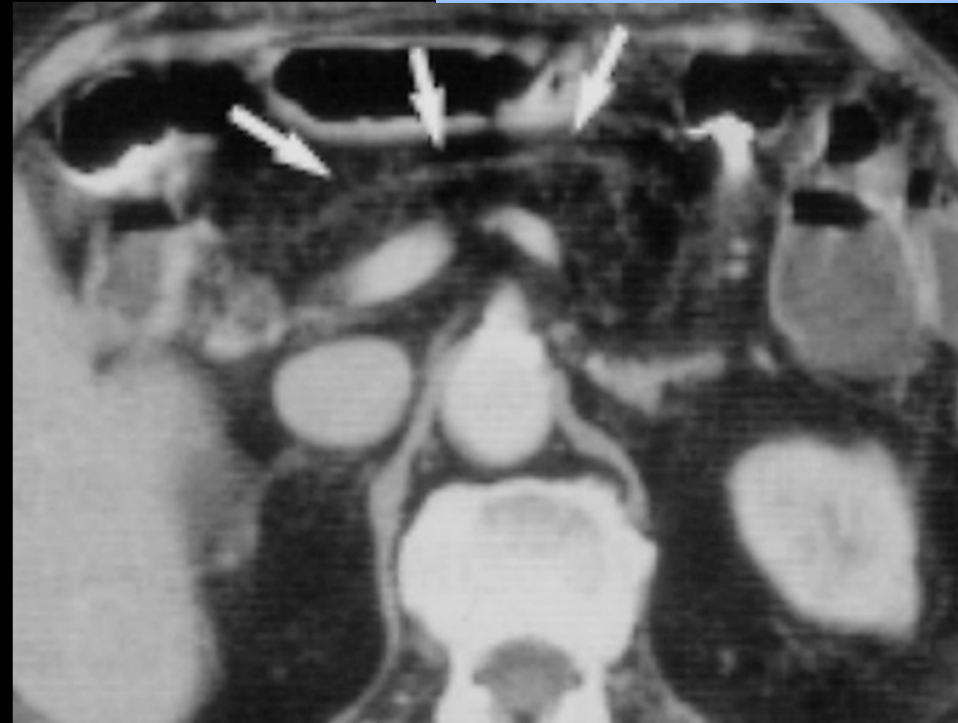
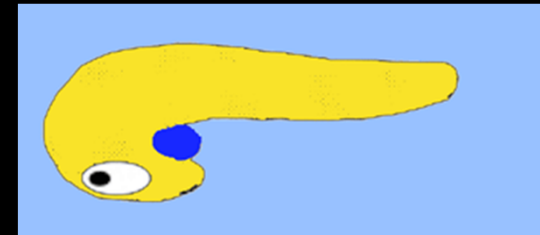
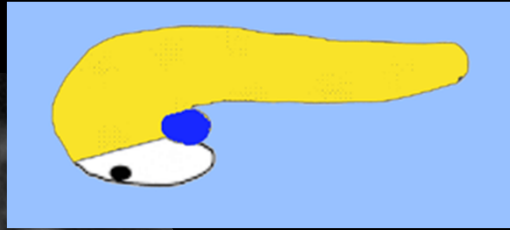
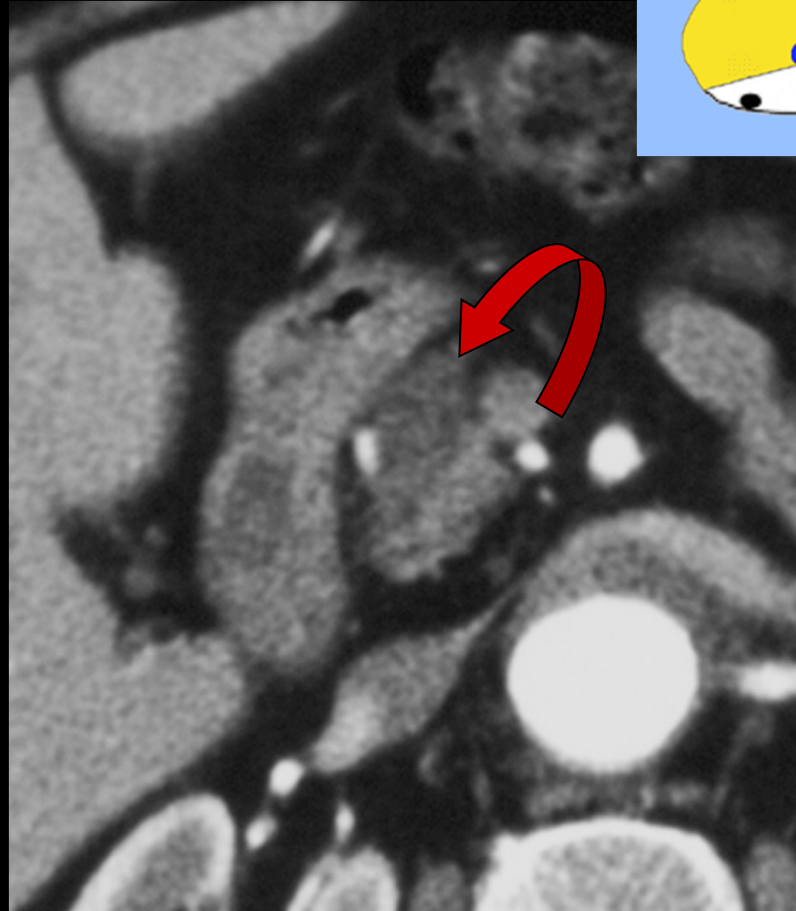


type 1

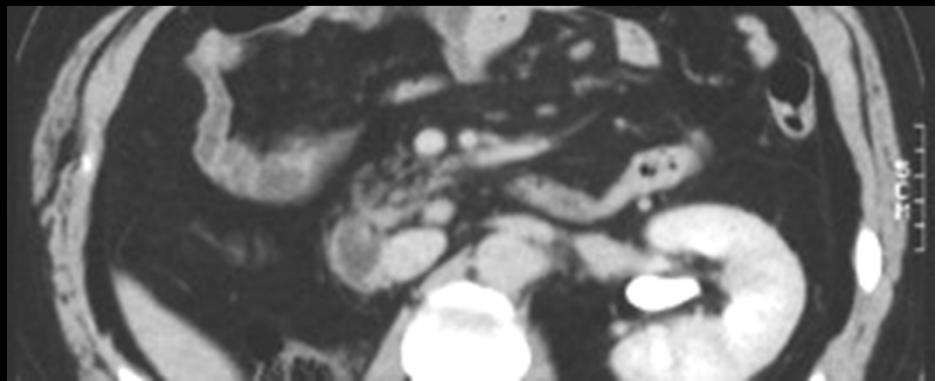
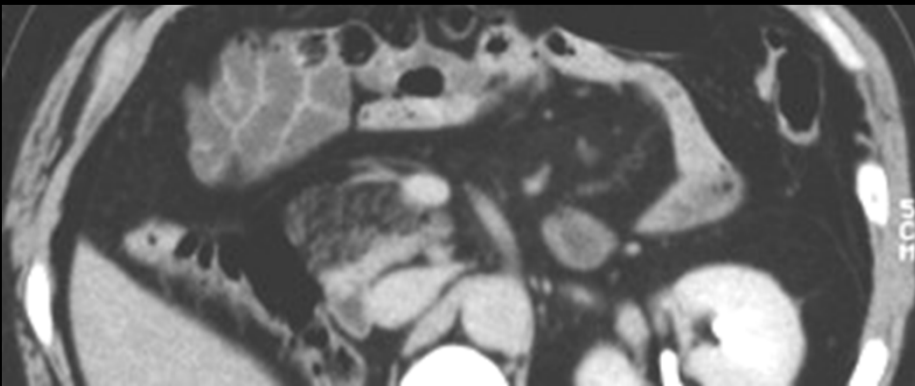
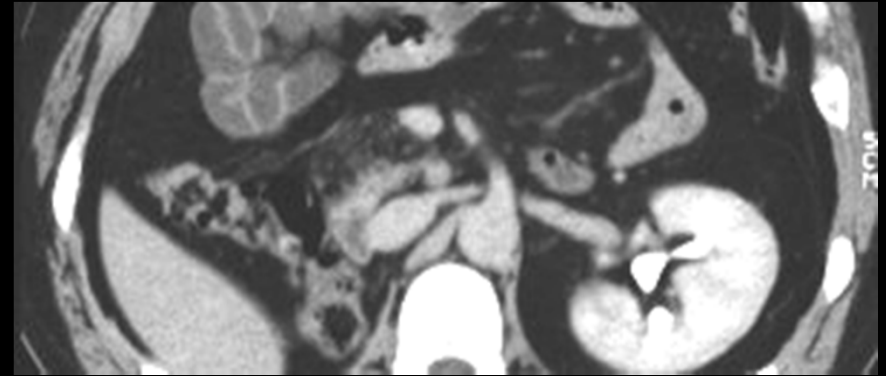
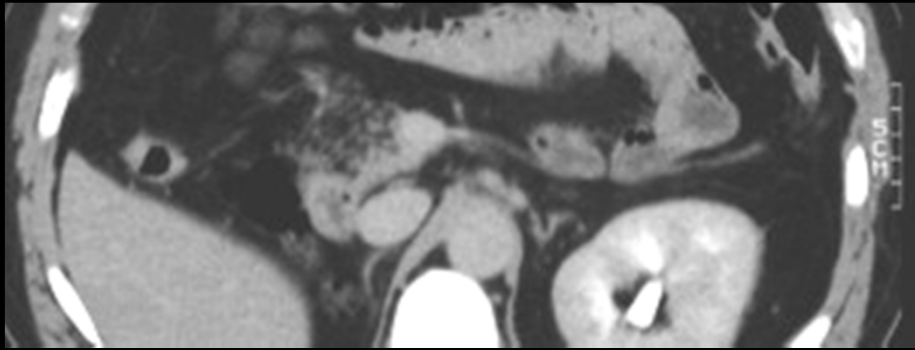
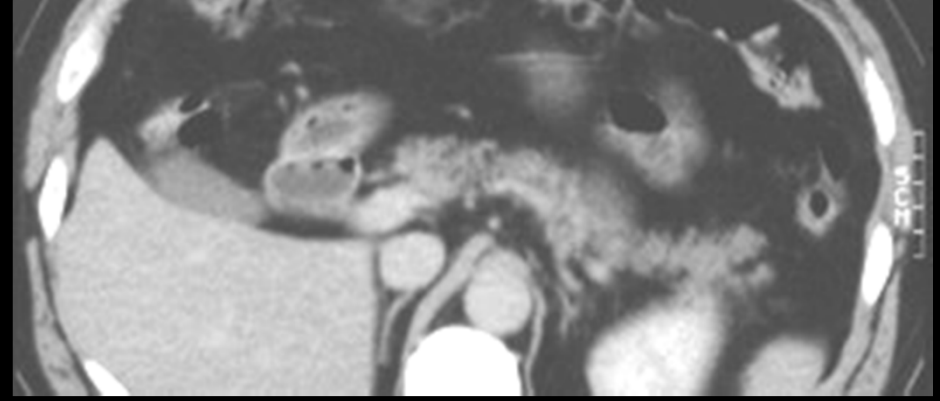
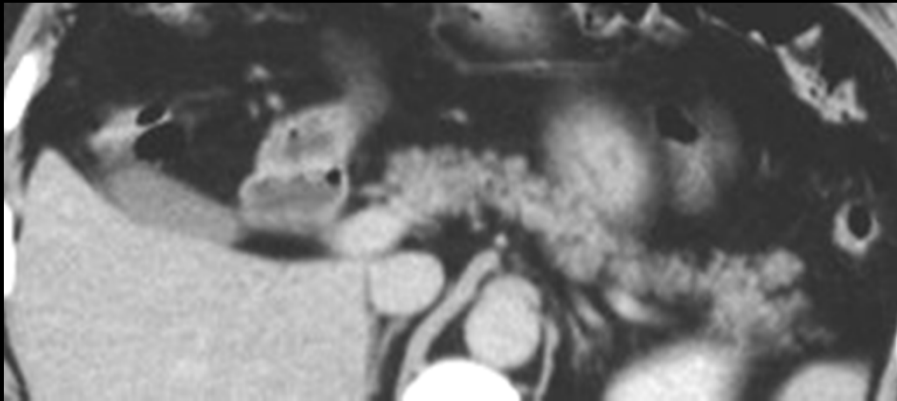
type 2

lipomatose Ia

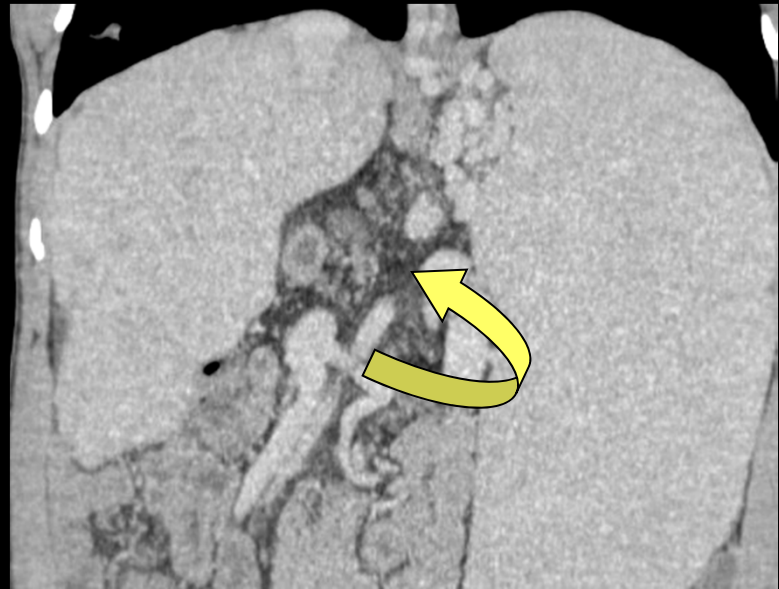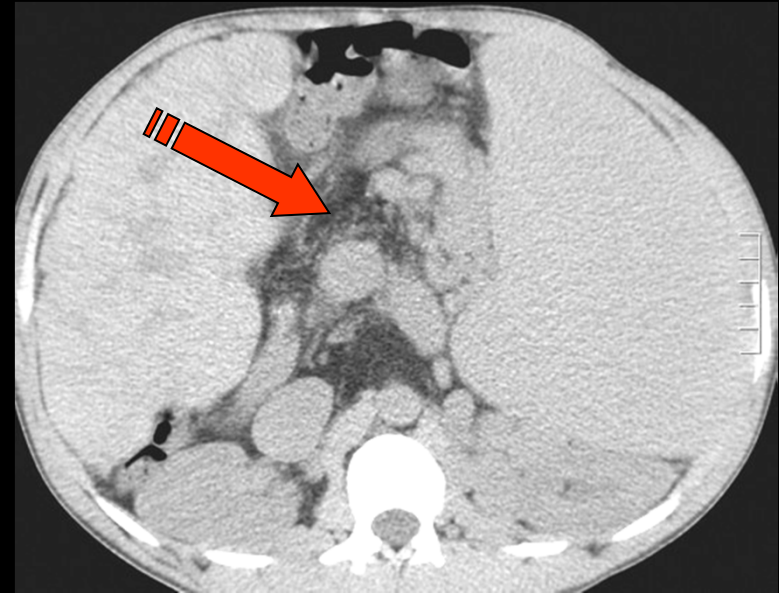
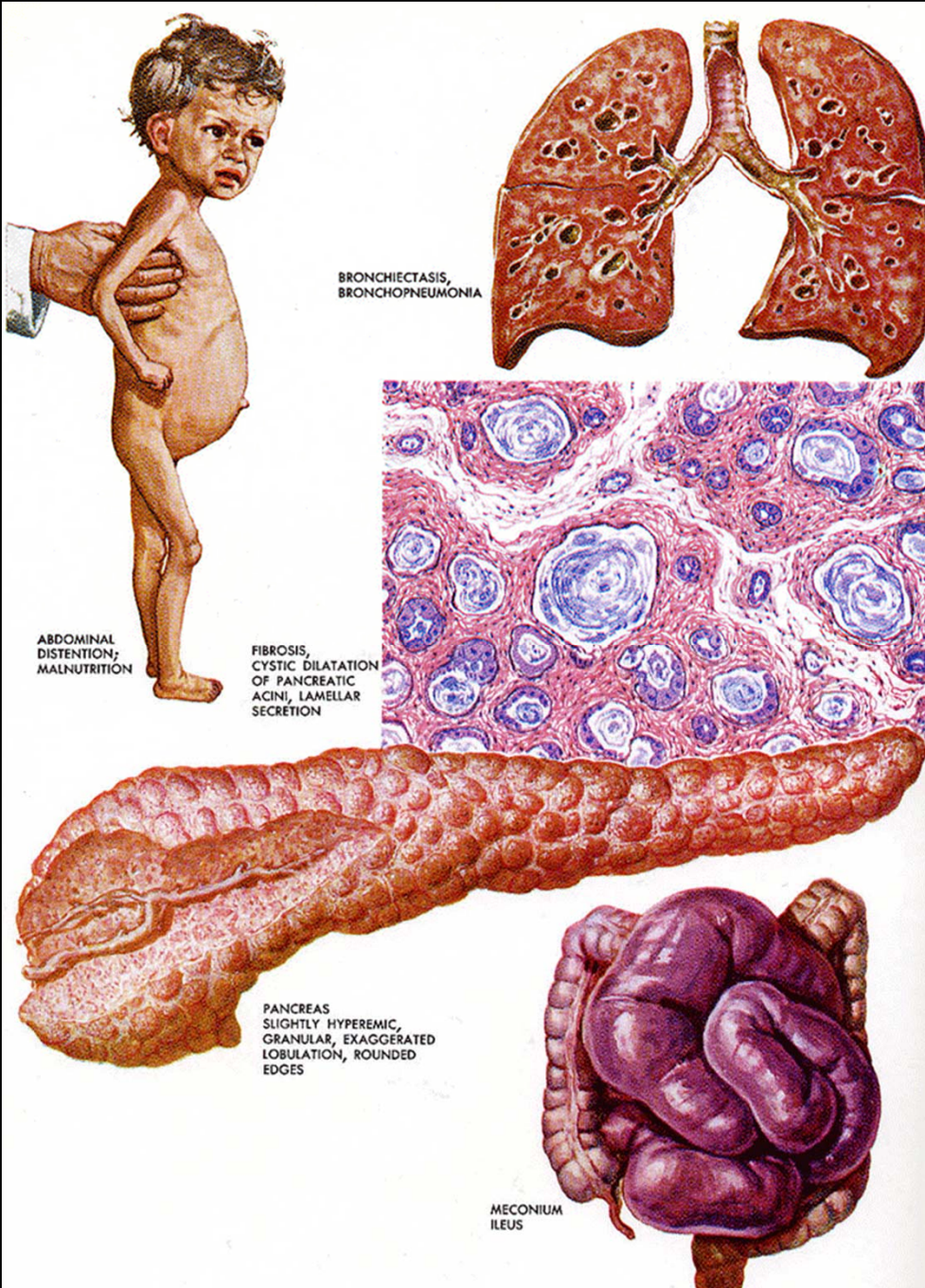




lipomatoses



uneven lipomatosis type 2



mucoviscidose ; 22 ans

la mucoviscidose (cystic fibrosis) ,la plus fréquente des maladies héréditaires autosomiques récessives léthales dans la race blanche (fibrose kystique du pancréas décrite en 1938 , à l'origine de la dénomination anglaise ..)

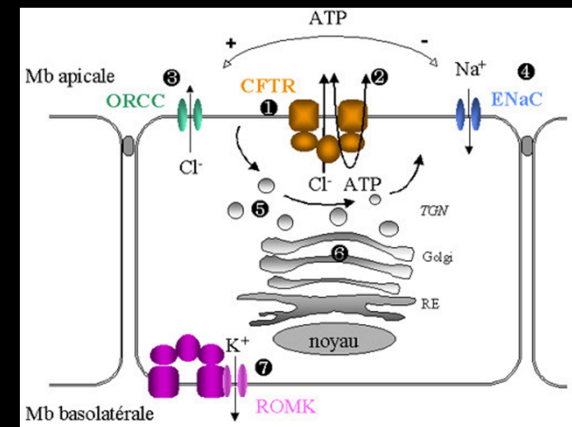
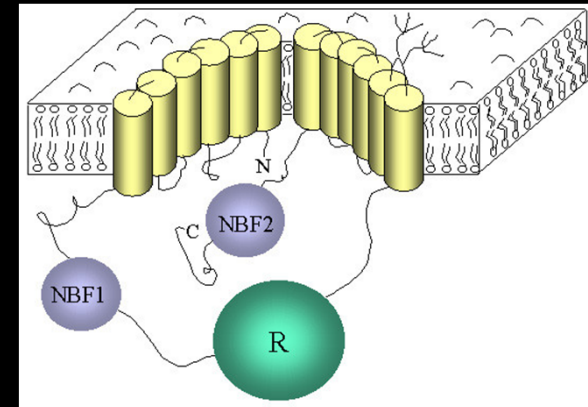
1/2500 naissances, 6 groupes de mutations des gènes régulateurs des transporteurs membranaires des ions (CFTR)

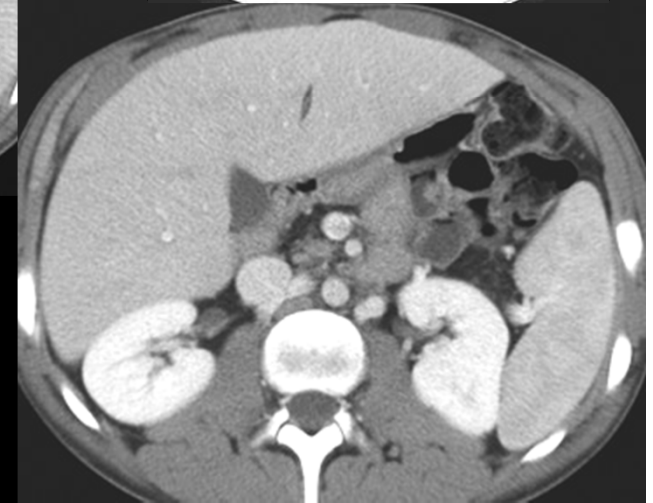
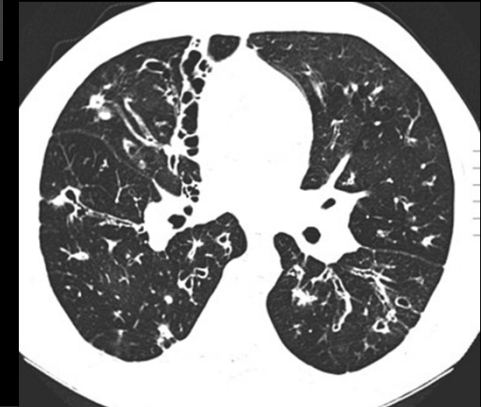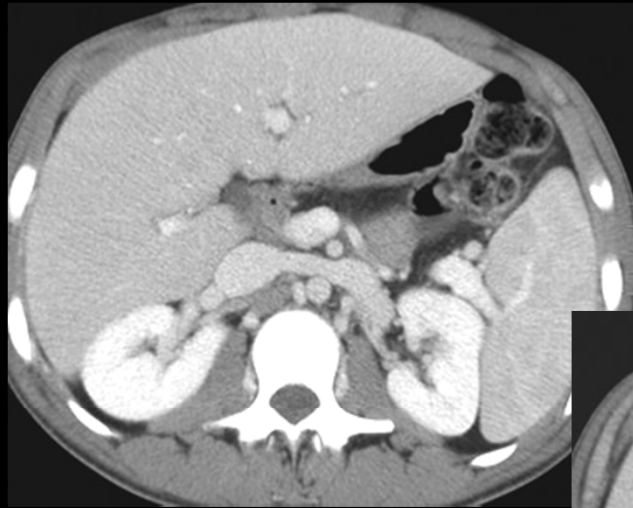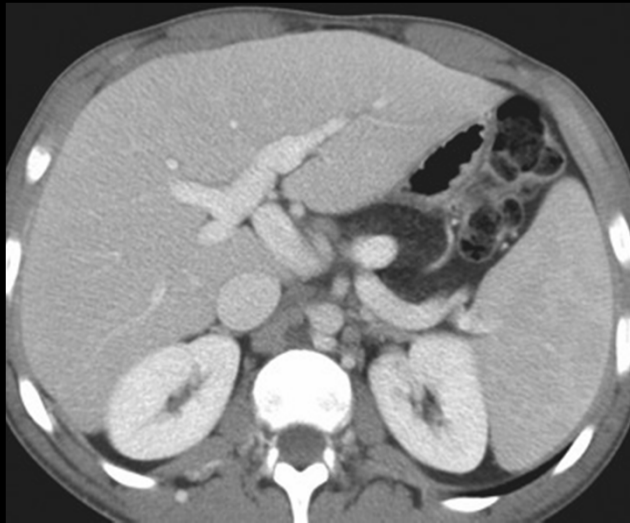
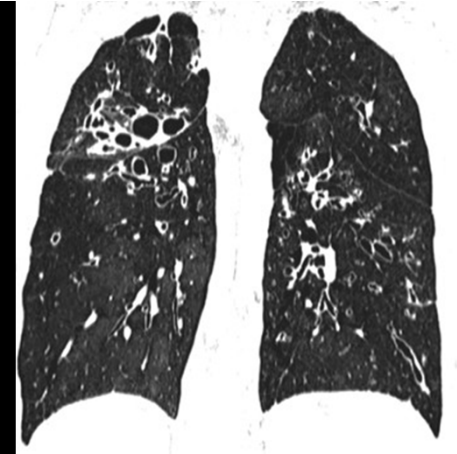
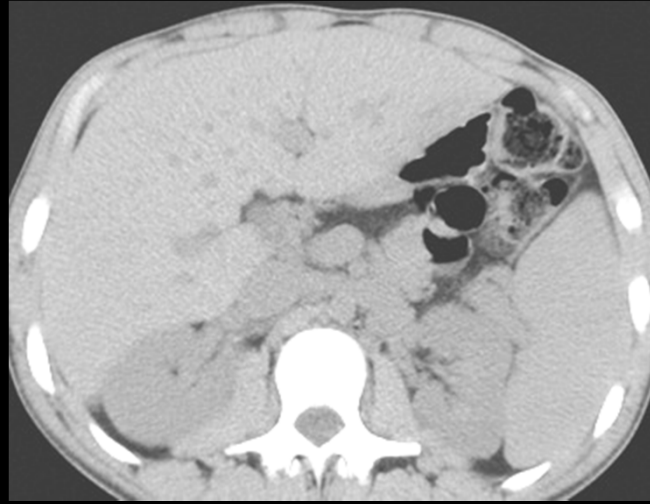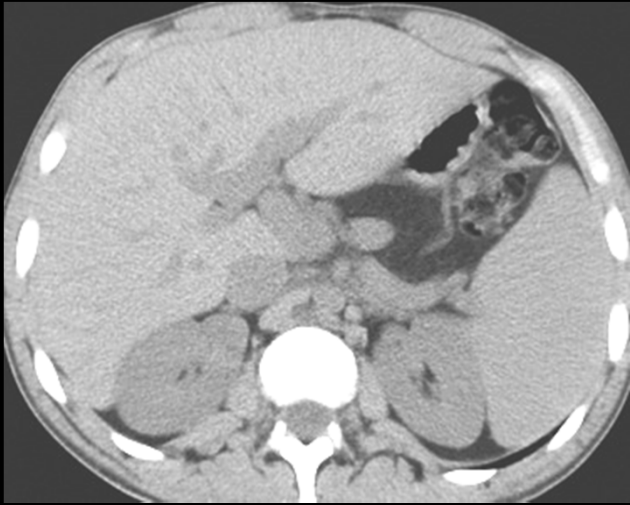
mécanismes

- défaut du transport ionique (chlore+++)
- hyperconcentration du mucus
- précipitation des protéines à l'intérieur des acini et des canaux, toxicité directe sur parenchyme
- atrophie et fibrose

- kystes : quand poursuite de la sécrétion malgré l'obstruction des canaux excréteurs

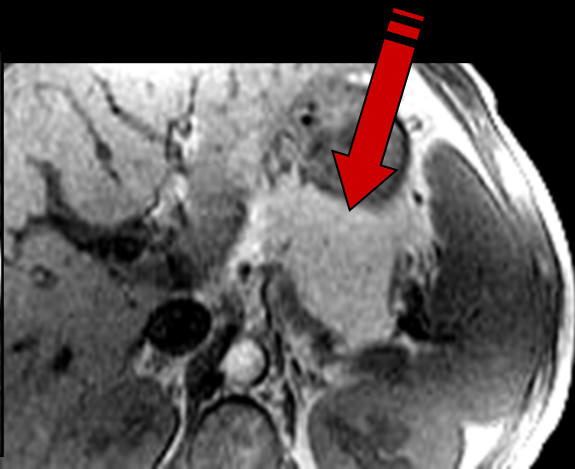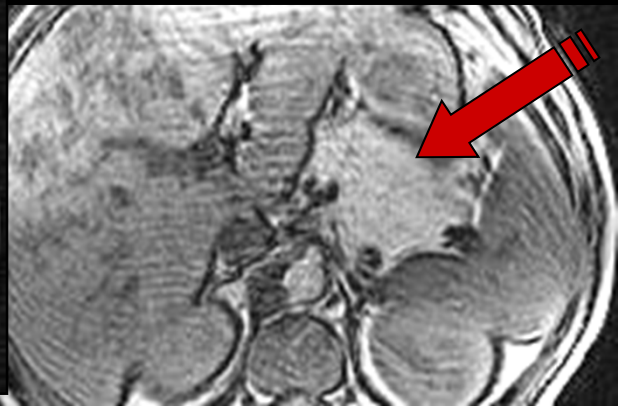
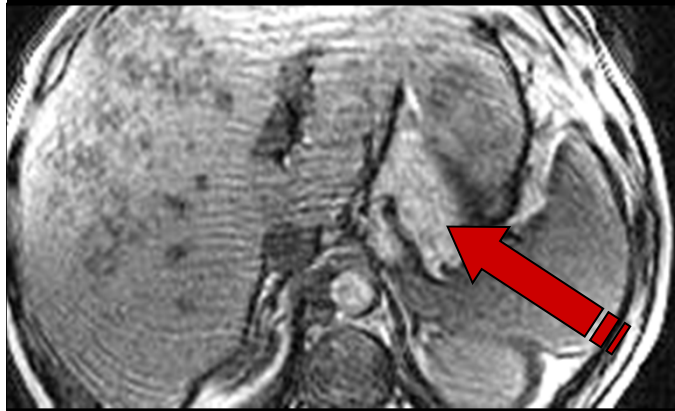
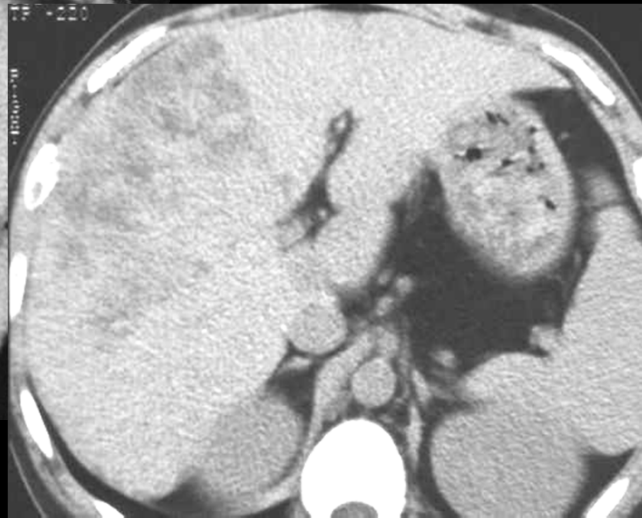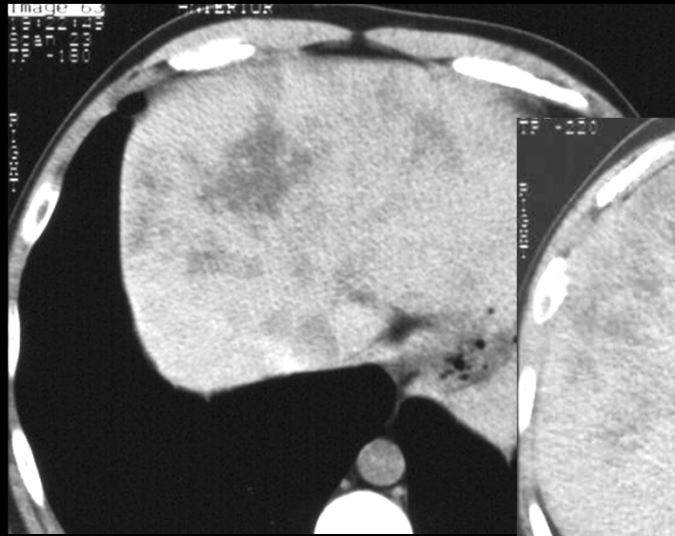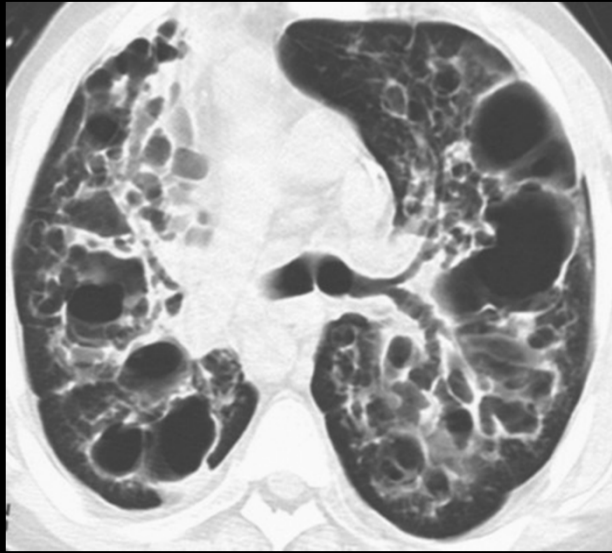
la sévérité de l'atteinte pancréatique dépendent de la durée et de l'intensité de la maladie mais pas du type de déficit génétique



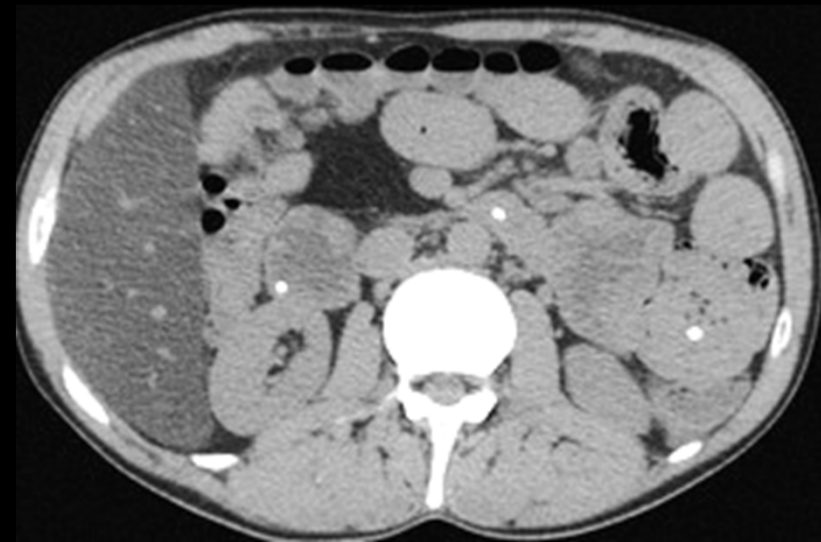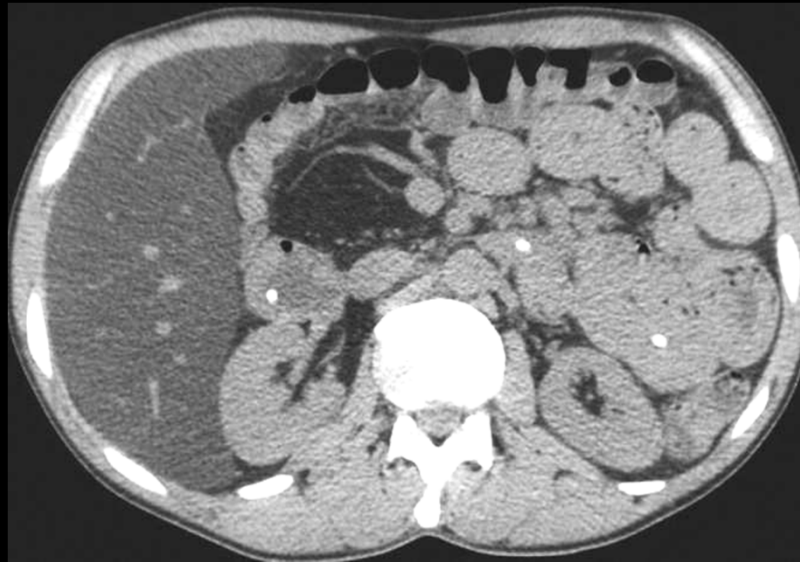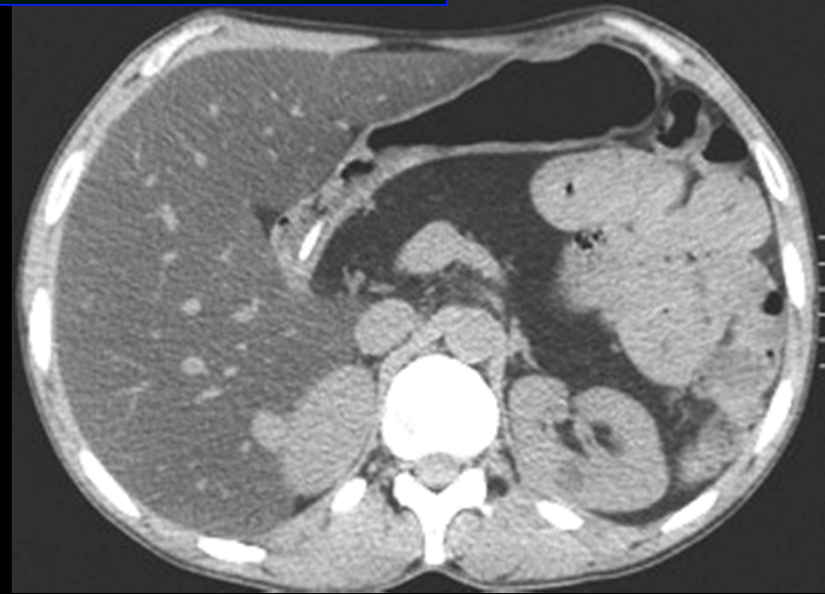
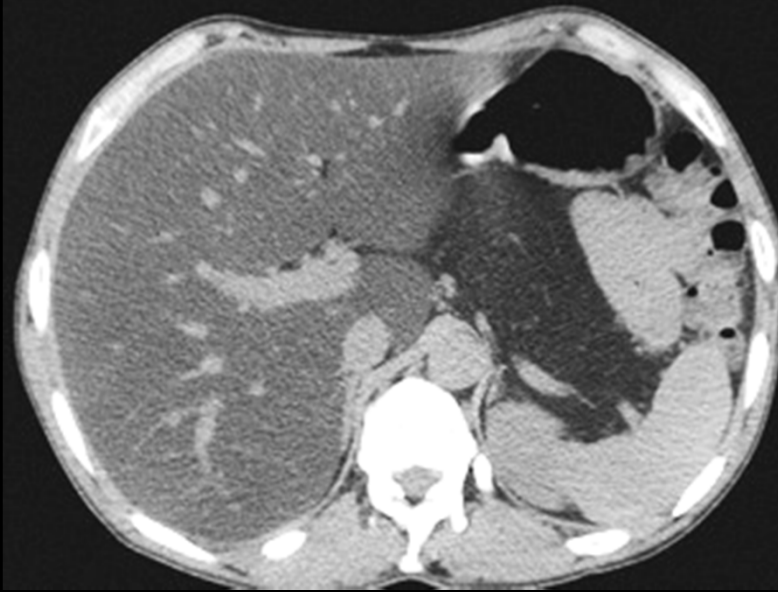


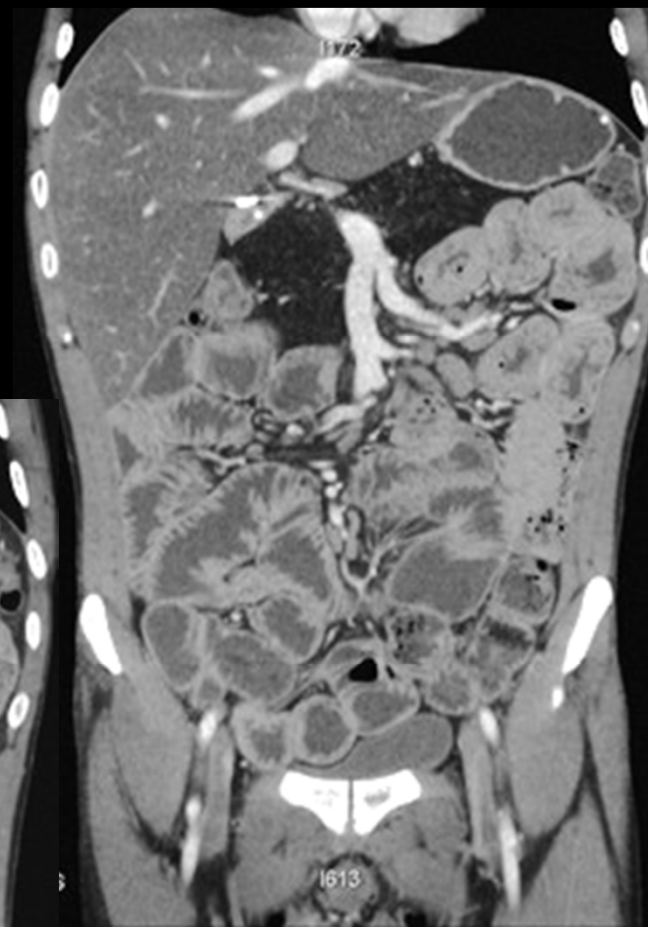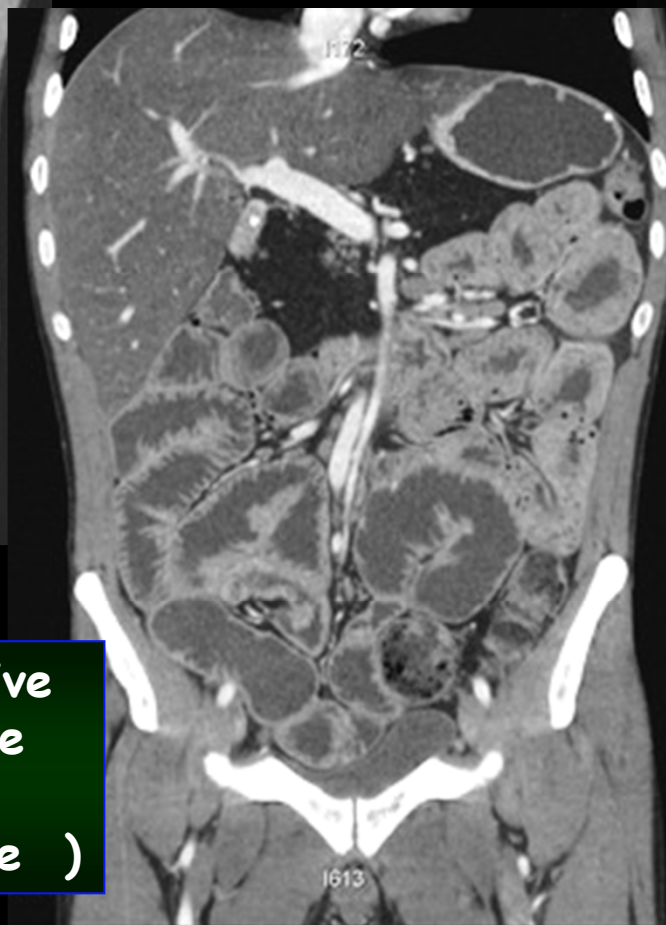
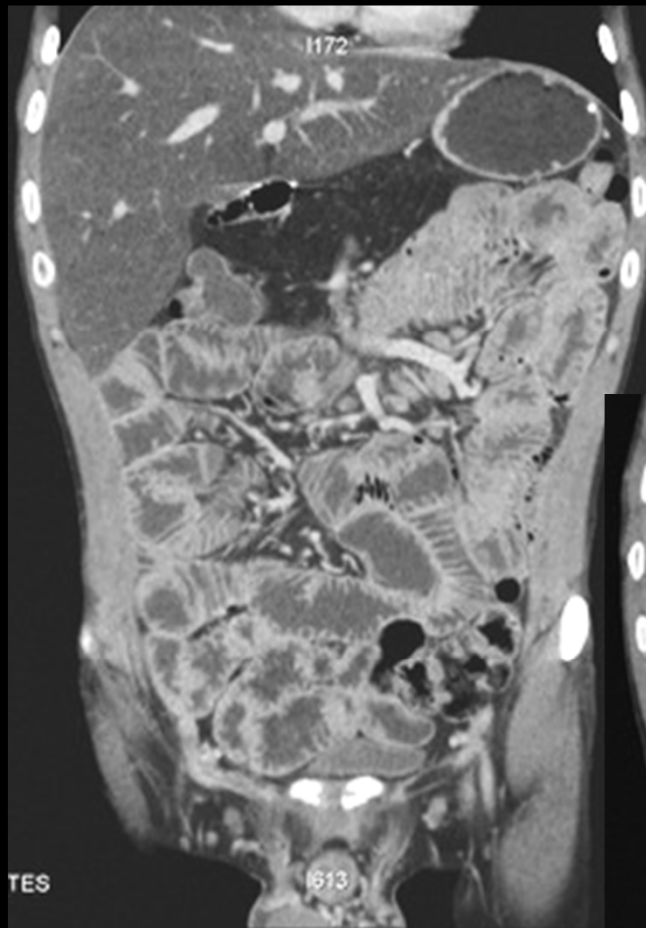
involution graisseuse
massive du pancréas au
cours d'une
mucoviscidose

involution graisseuse massive du pancréas au cours d'une mucoviscidose (et stéatose hétérogène hépatique)

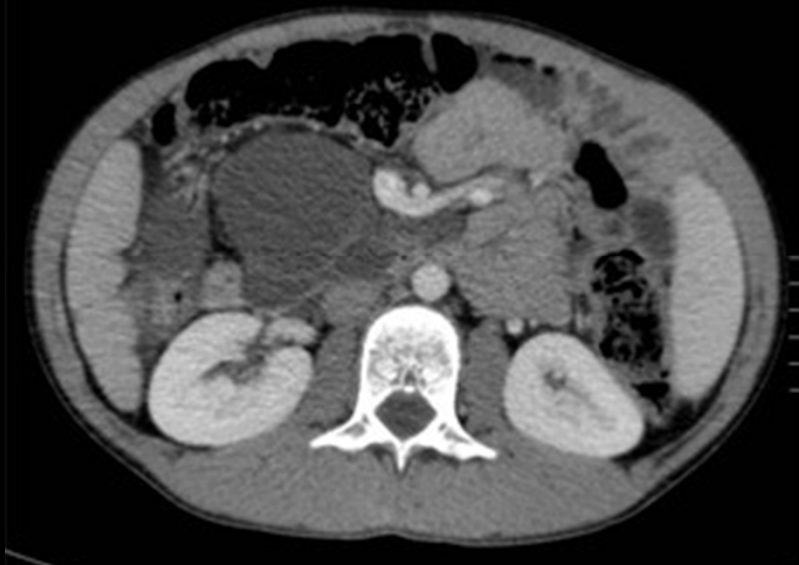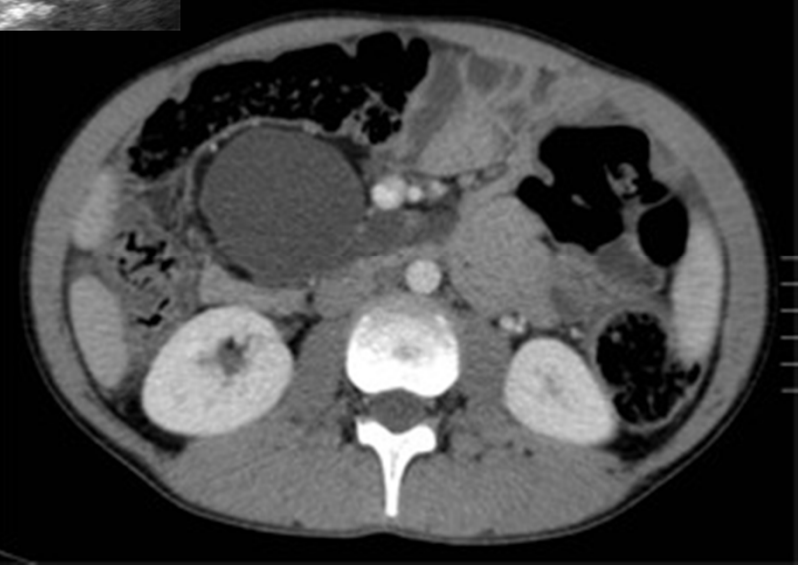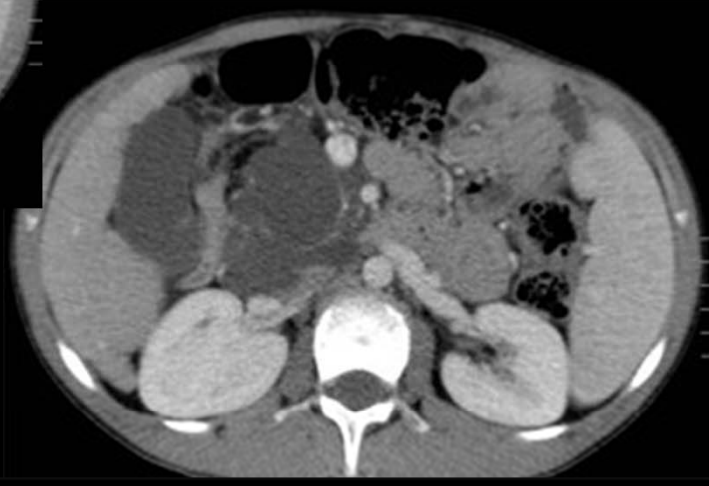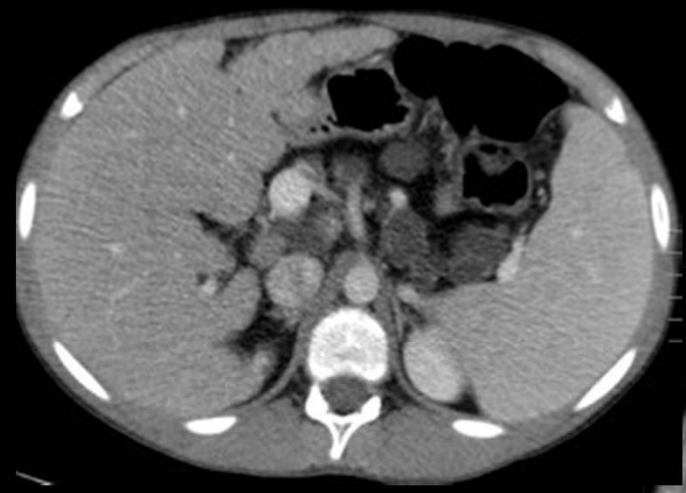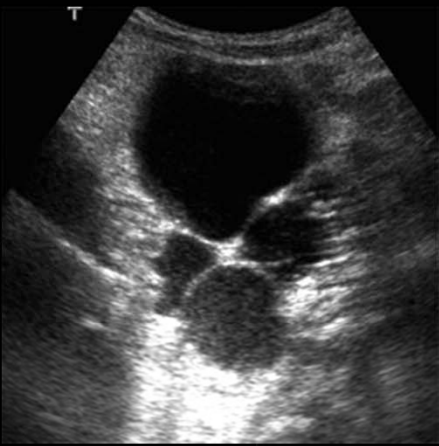
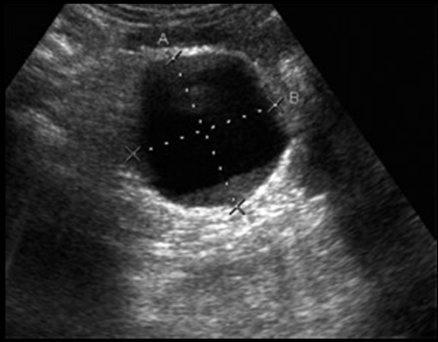


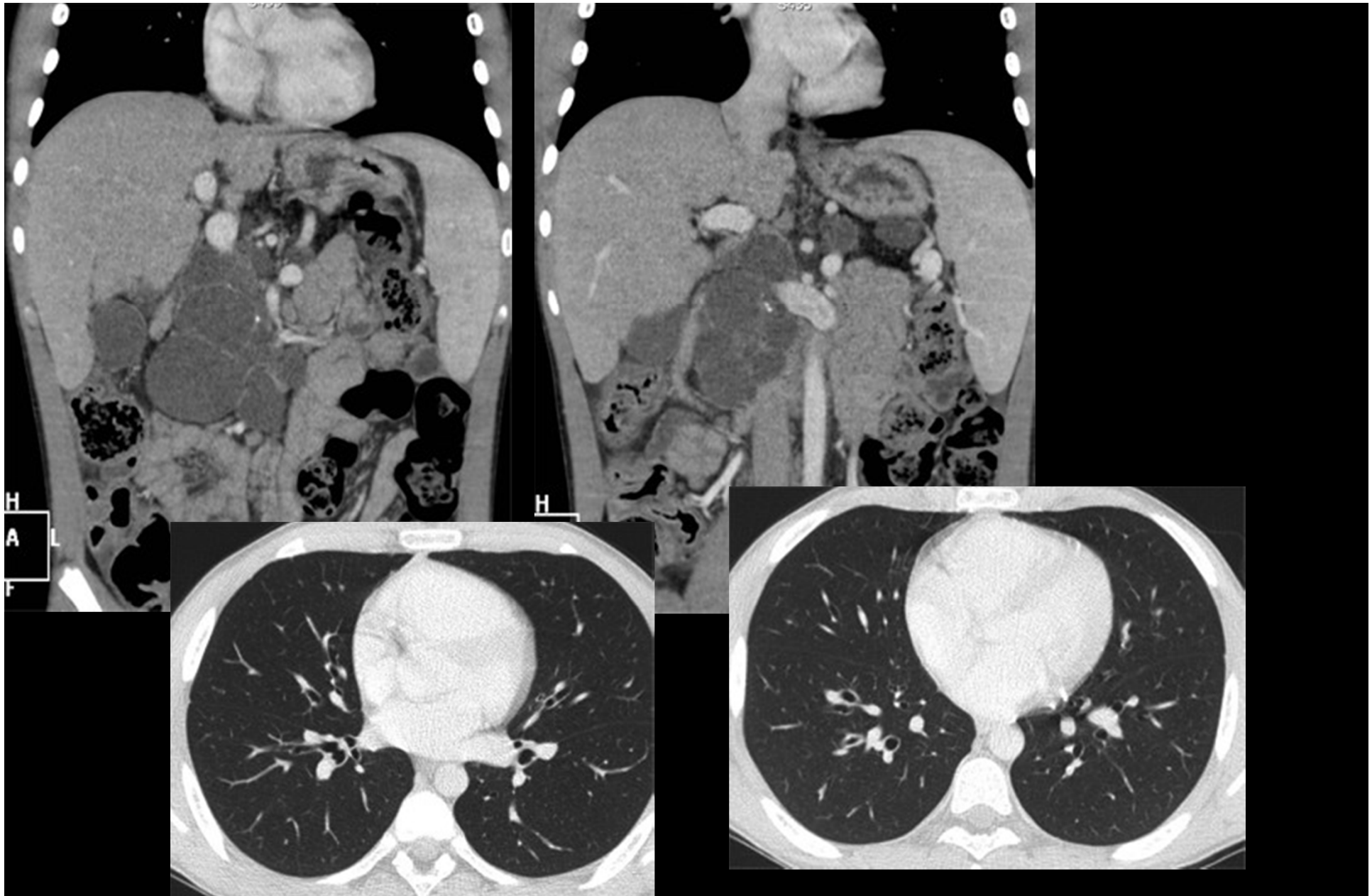
involution graisseuse massive du pancréas au cours d'une maladie coeliaque (et stéatose hépatique massive)



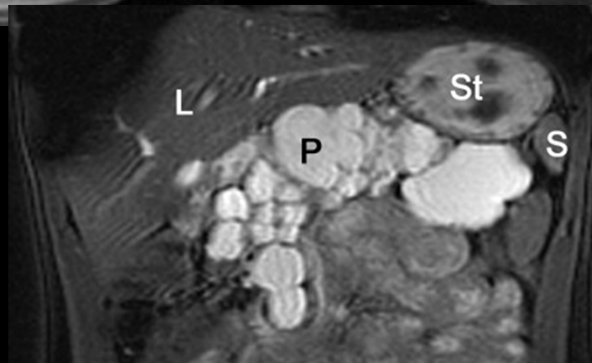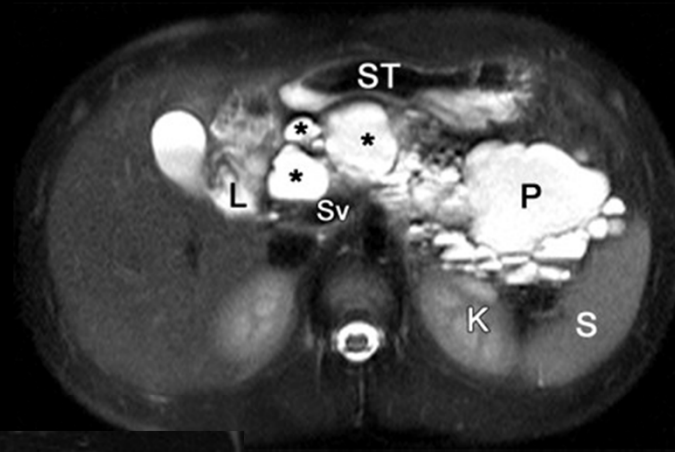
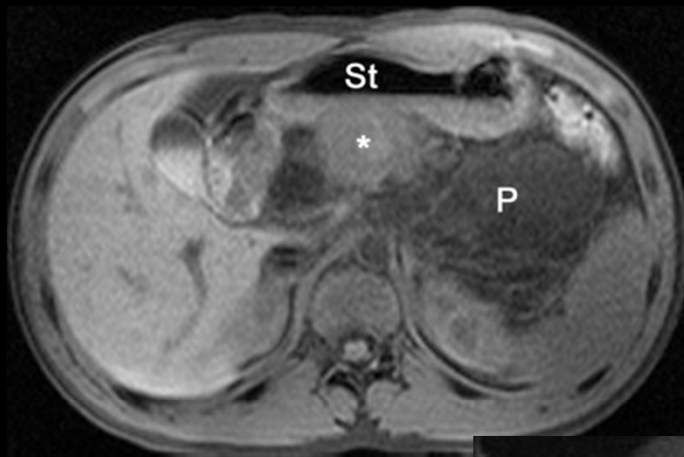
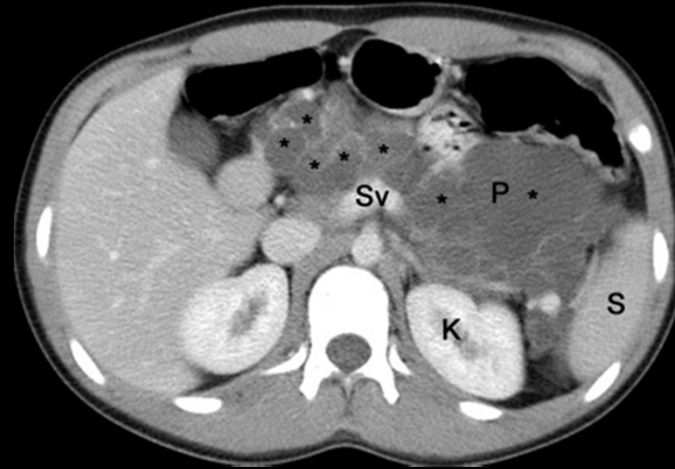
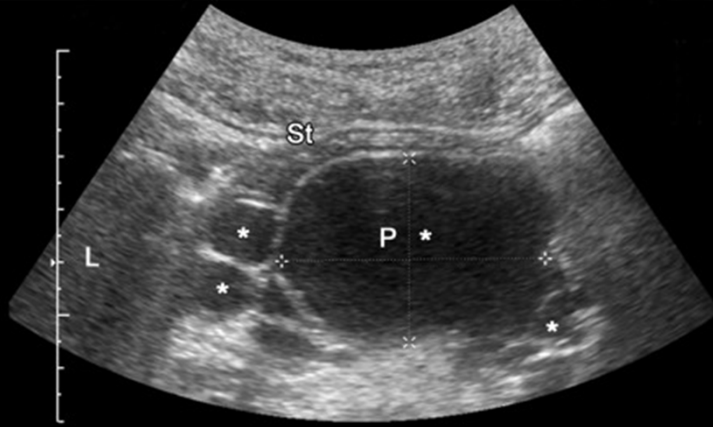


involution graisseuse massive
du pancréas au cours d'une
maladie coeliaque (et
stéatose hépatique massive)





pancreatic cystosis (hydropancreatose) évolution d'une mucoviscidose ;
persistance d'une sécrétion malgré l'obstruction des canaux excréteurs



Van Rijn RR, Schilte PP,
Wiarda BM, Taminau JA,
Stoker J.
Case 113: pancreatic
cystosis.
Radiology. 2007
May;243(2):598-602.

**cystoses pancréatique au
cours de mucoviscidoses**