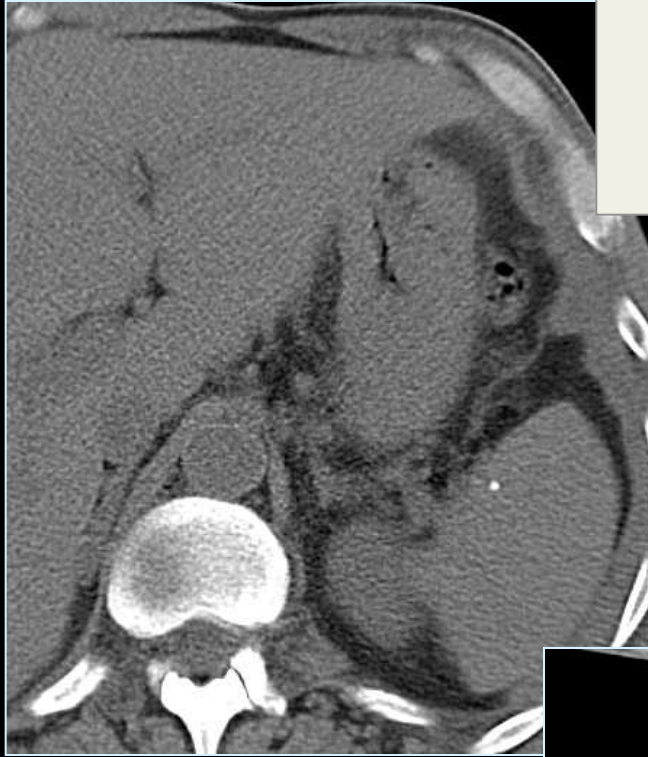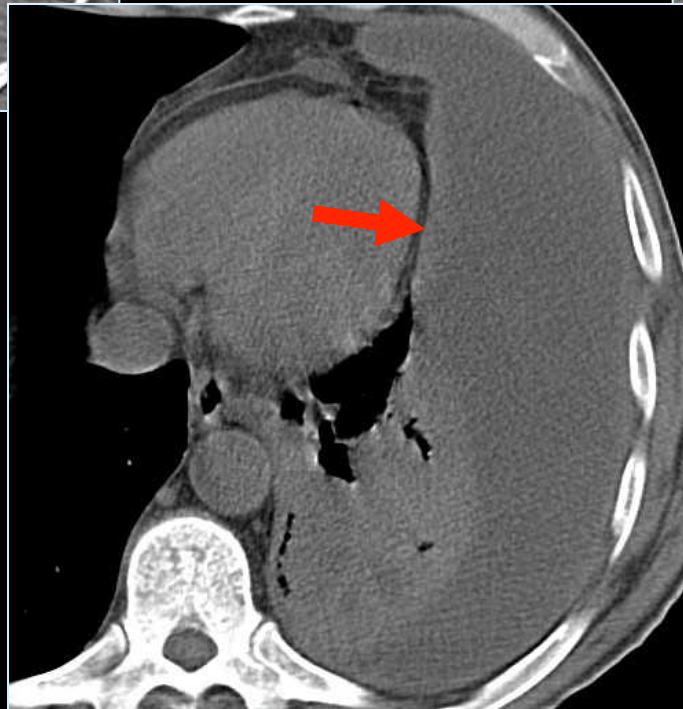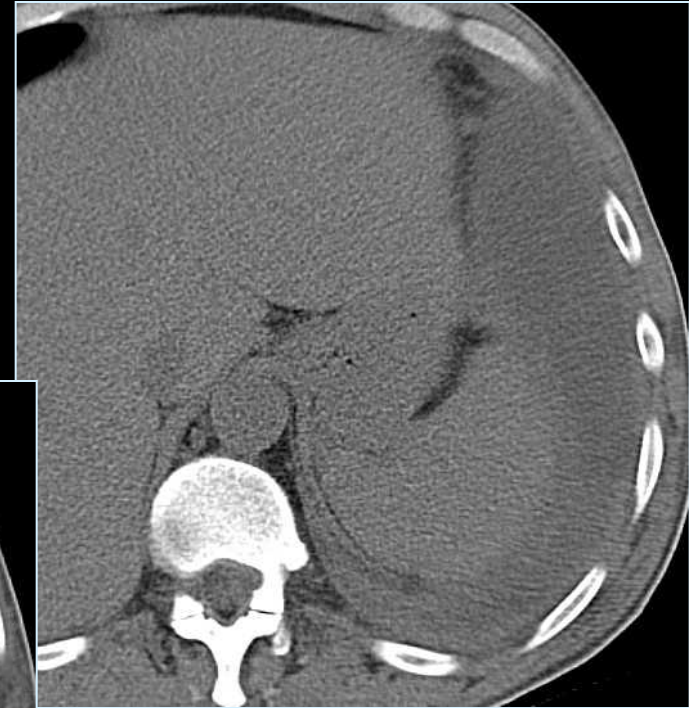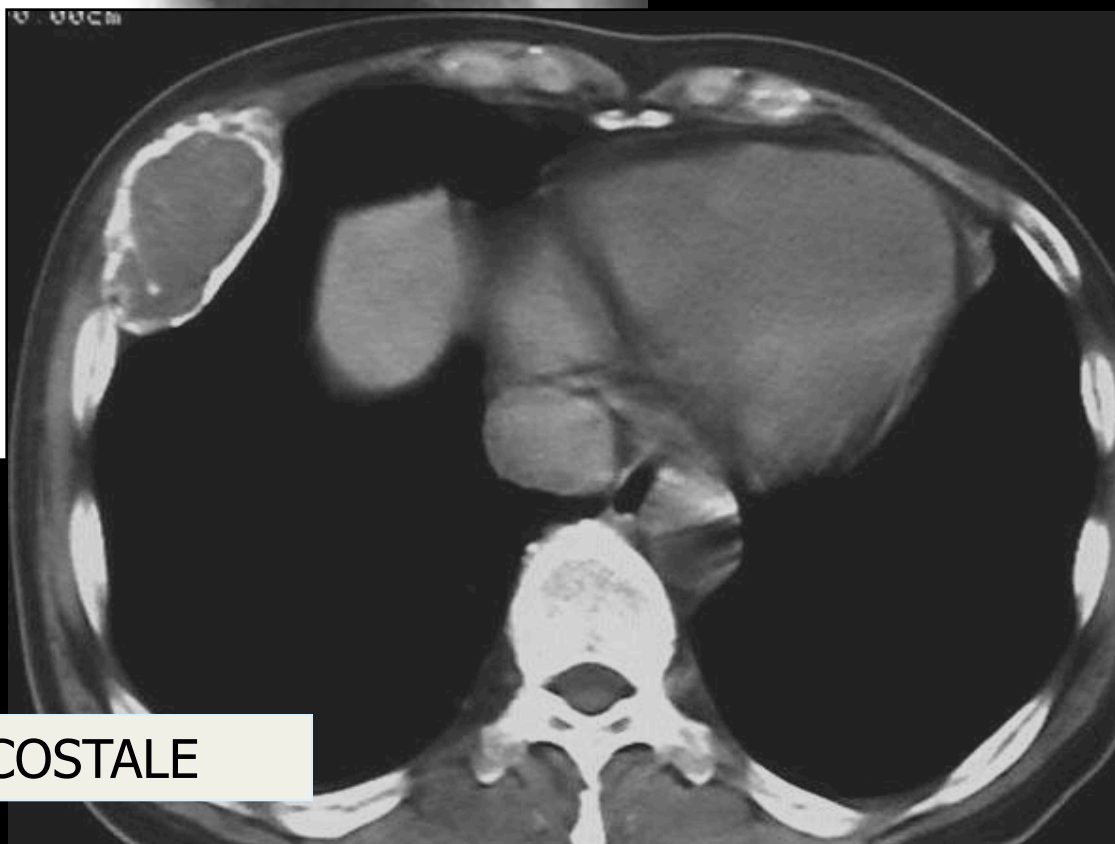
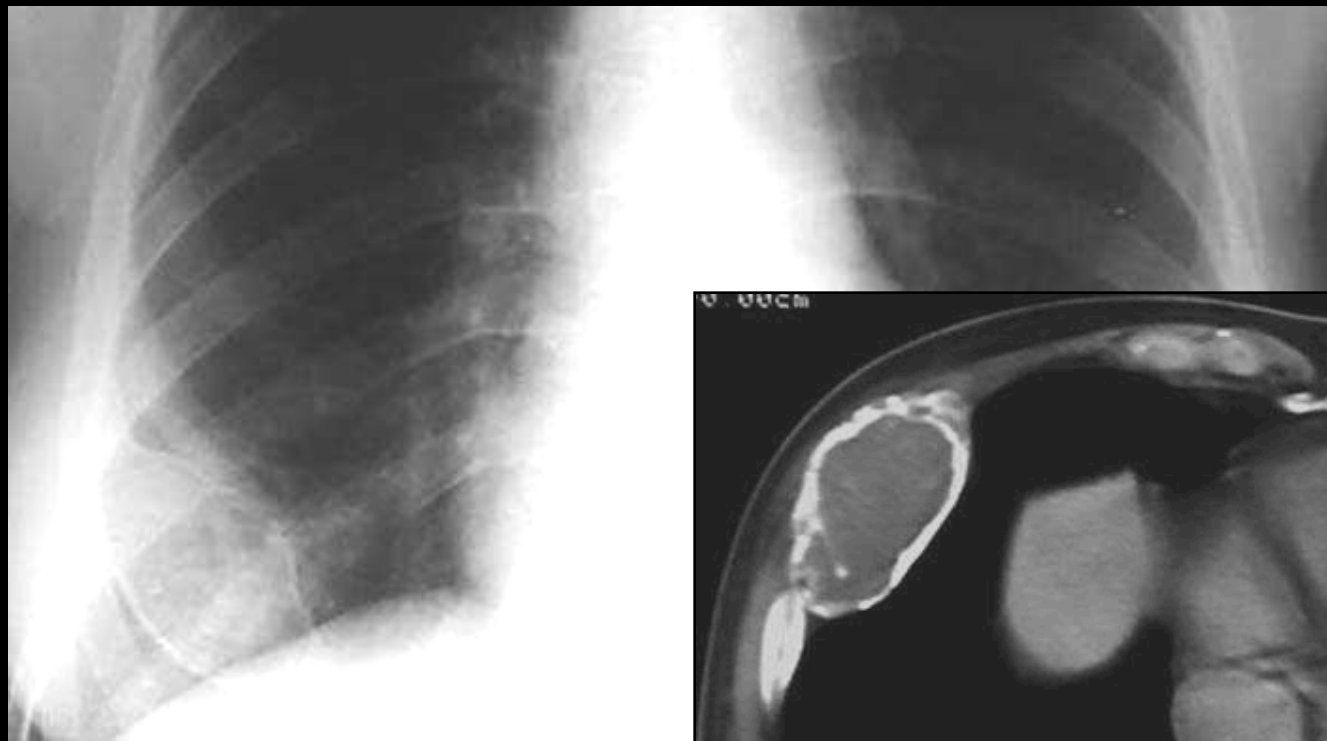


Patient de 50 ans / Fièvre élevée Sd inflammatoire
Douleurs latéro-thoraciques G / Toux et
expectorations purulentes

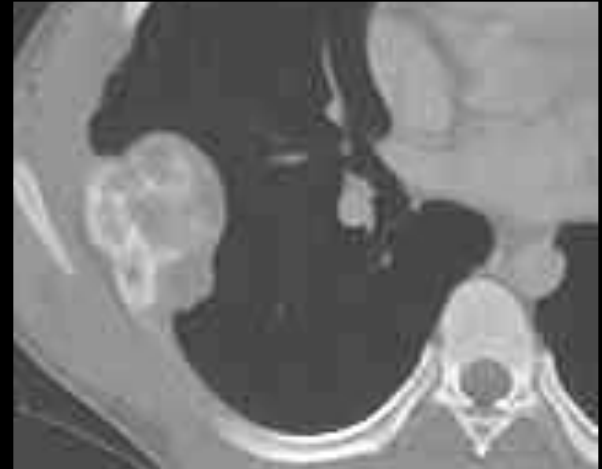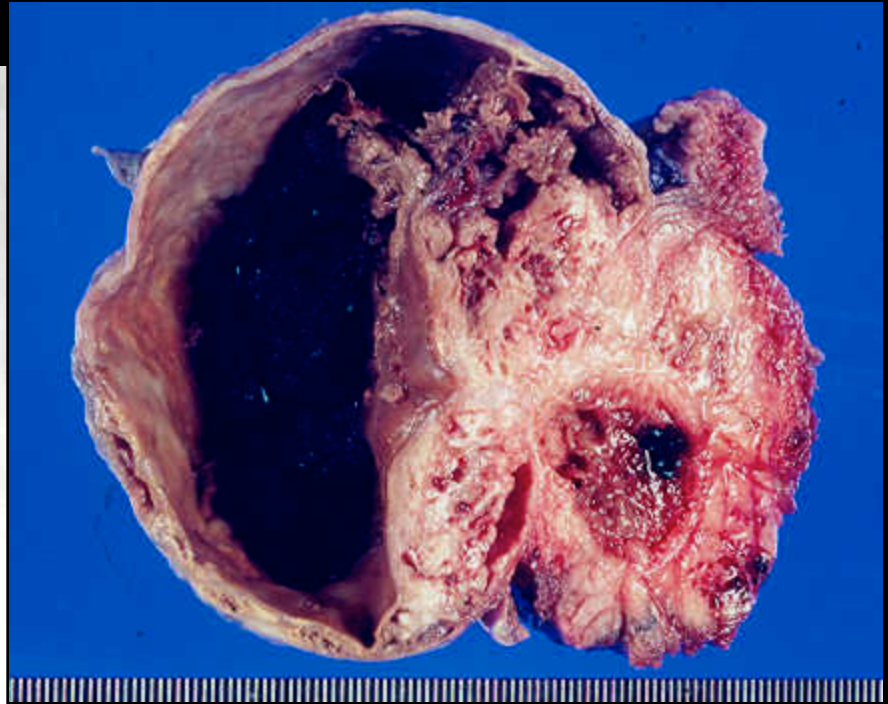
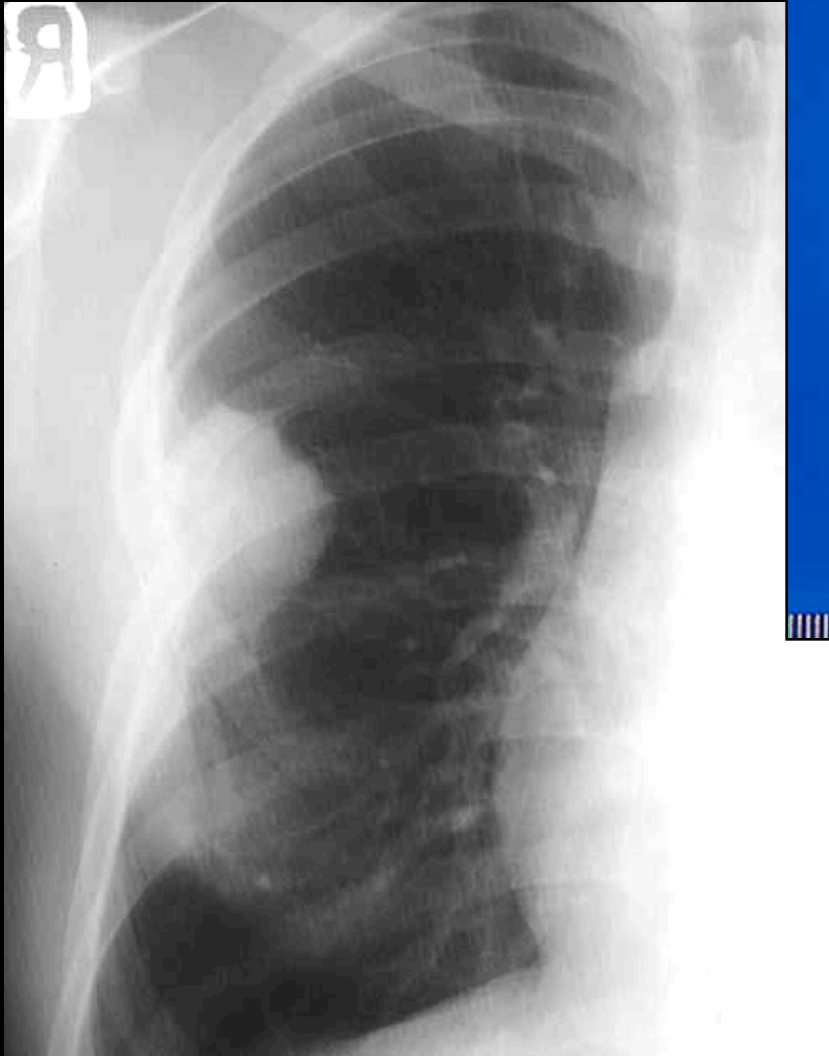


N°1

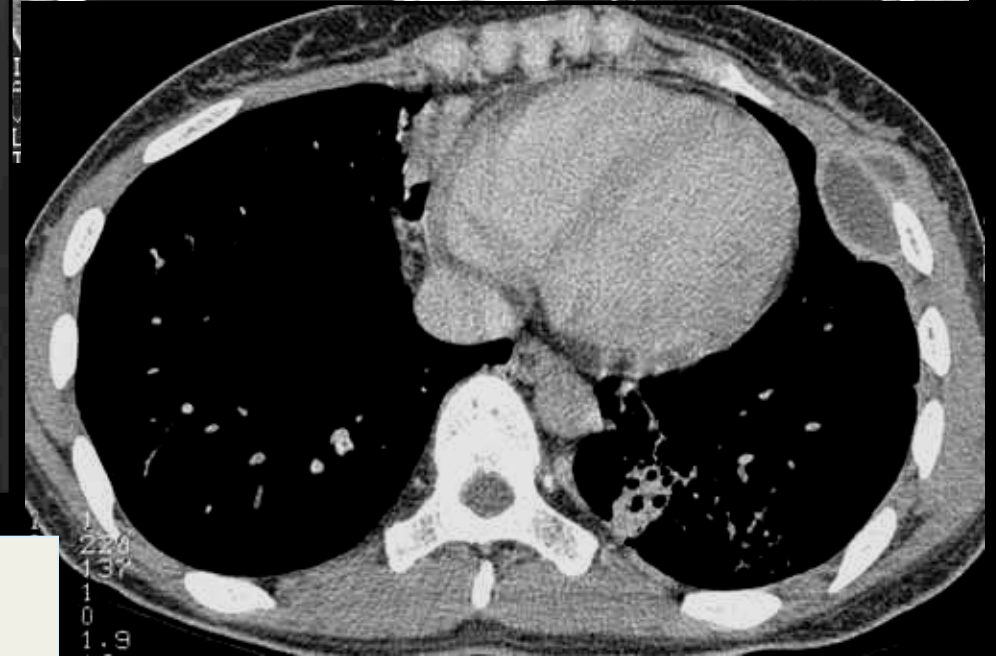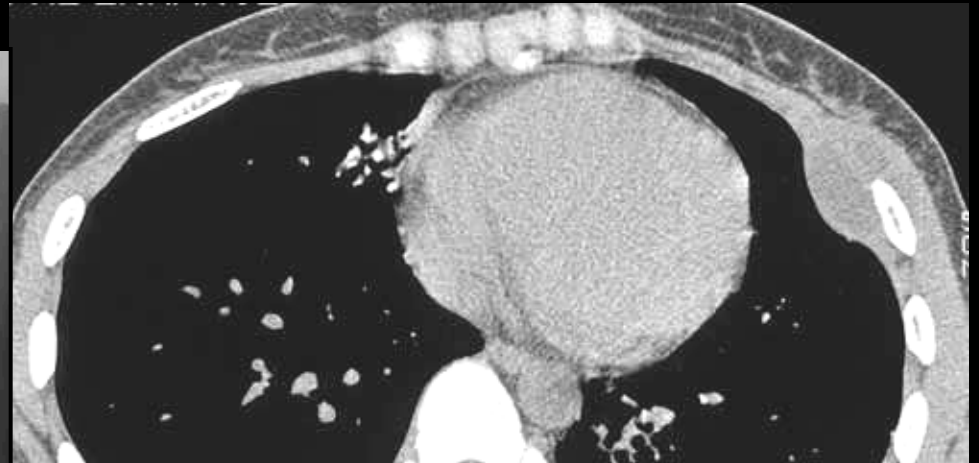
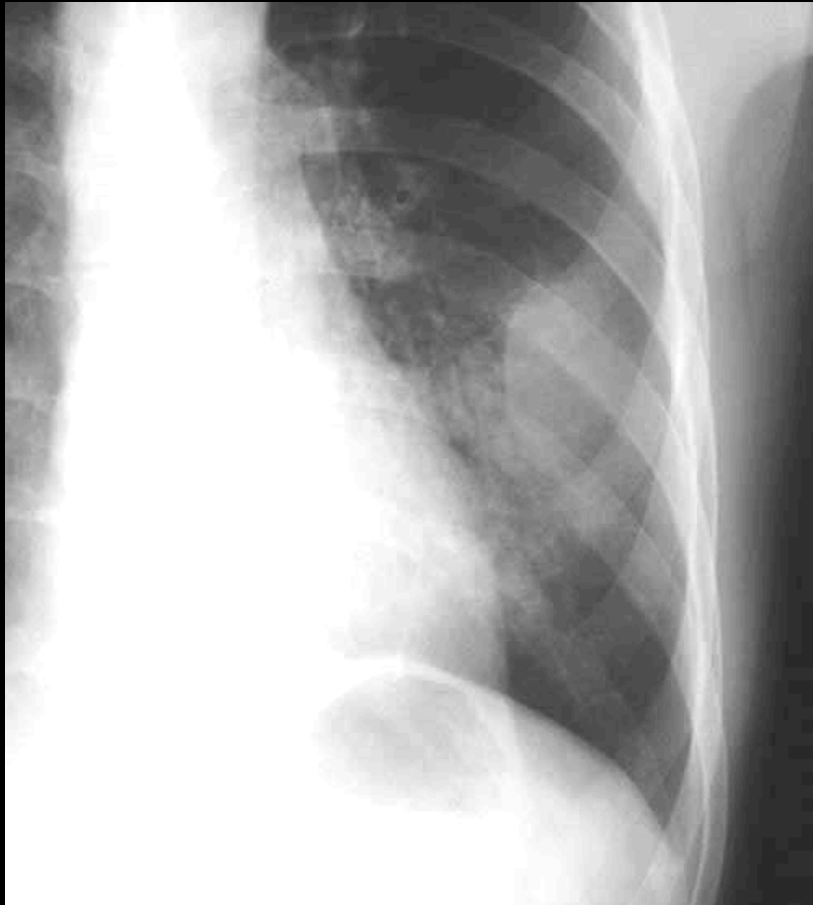




DYSPLASIE FIBREUSE COSTALE

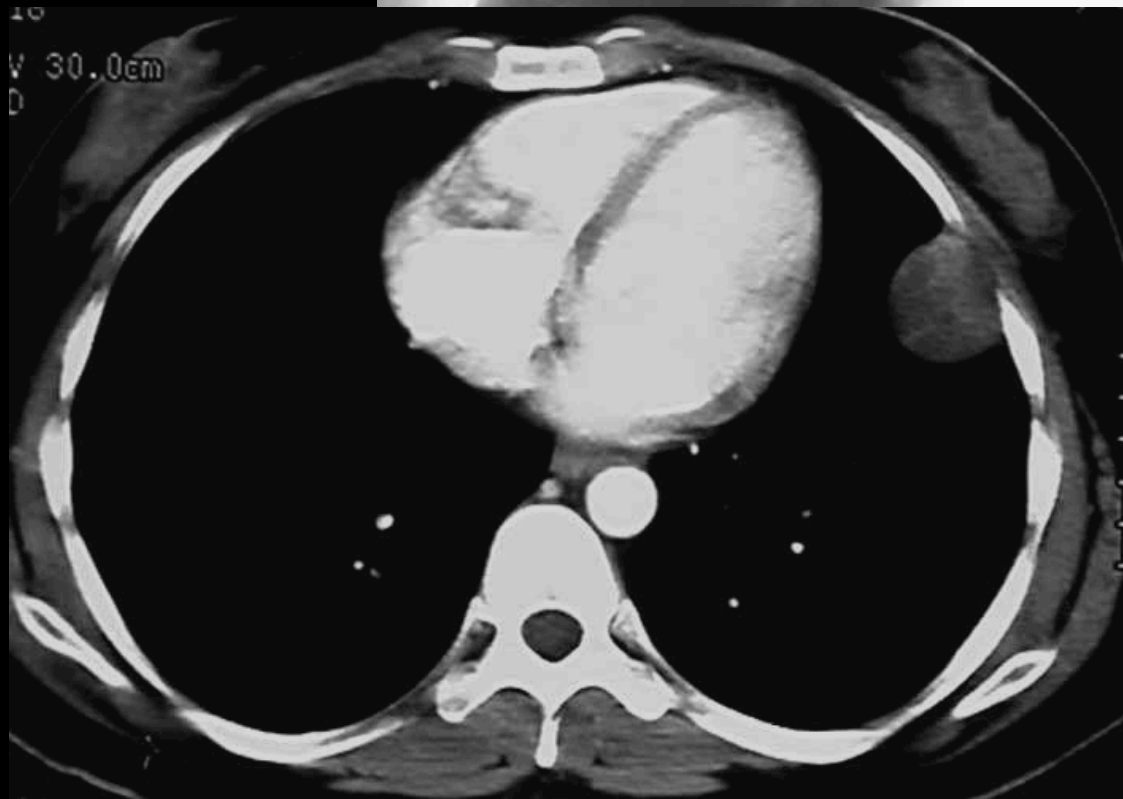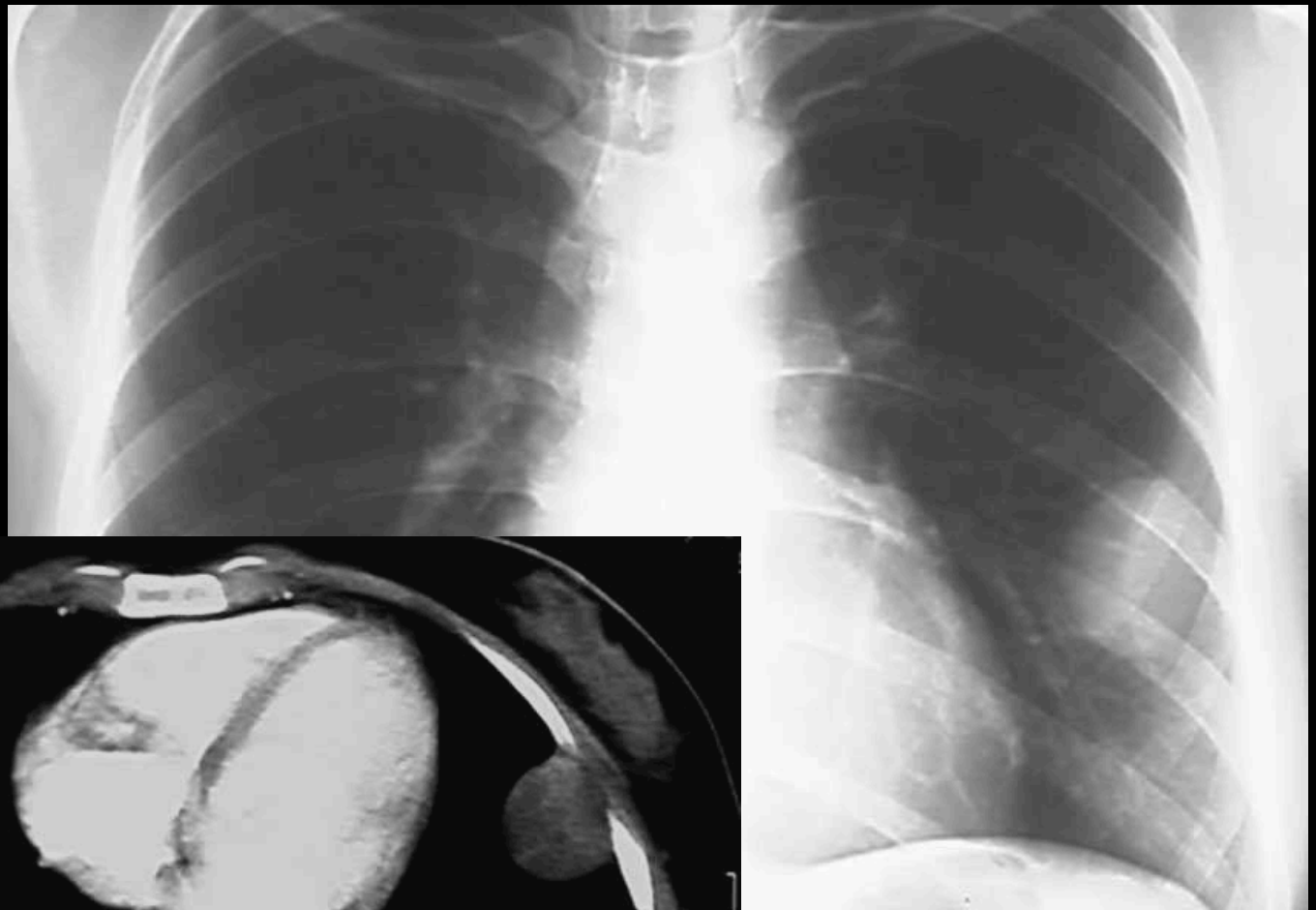


Ostéosarcome costal



Empyème chronique tuberculeux
Empyème de nécessité
(empyema necessitatis)

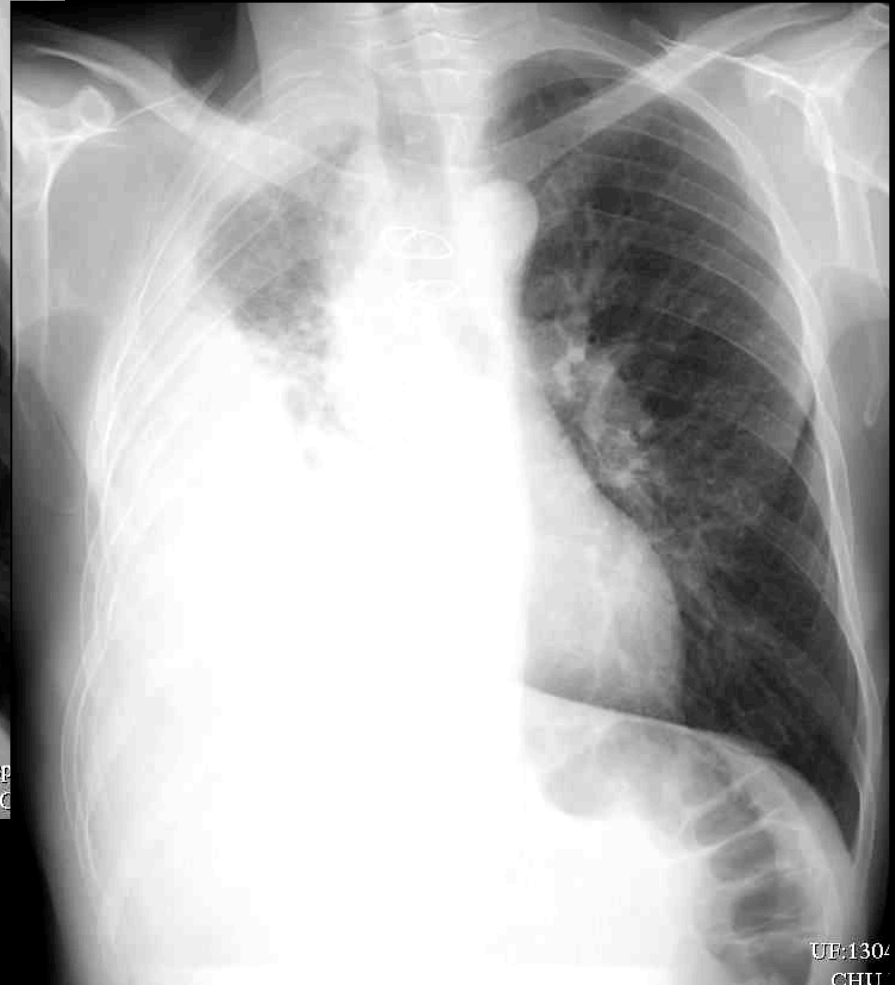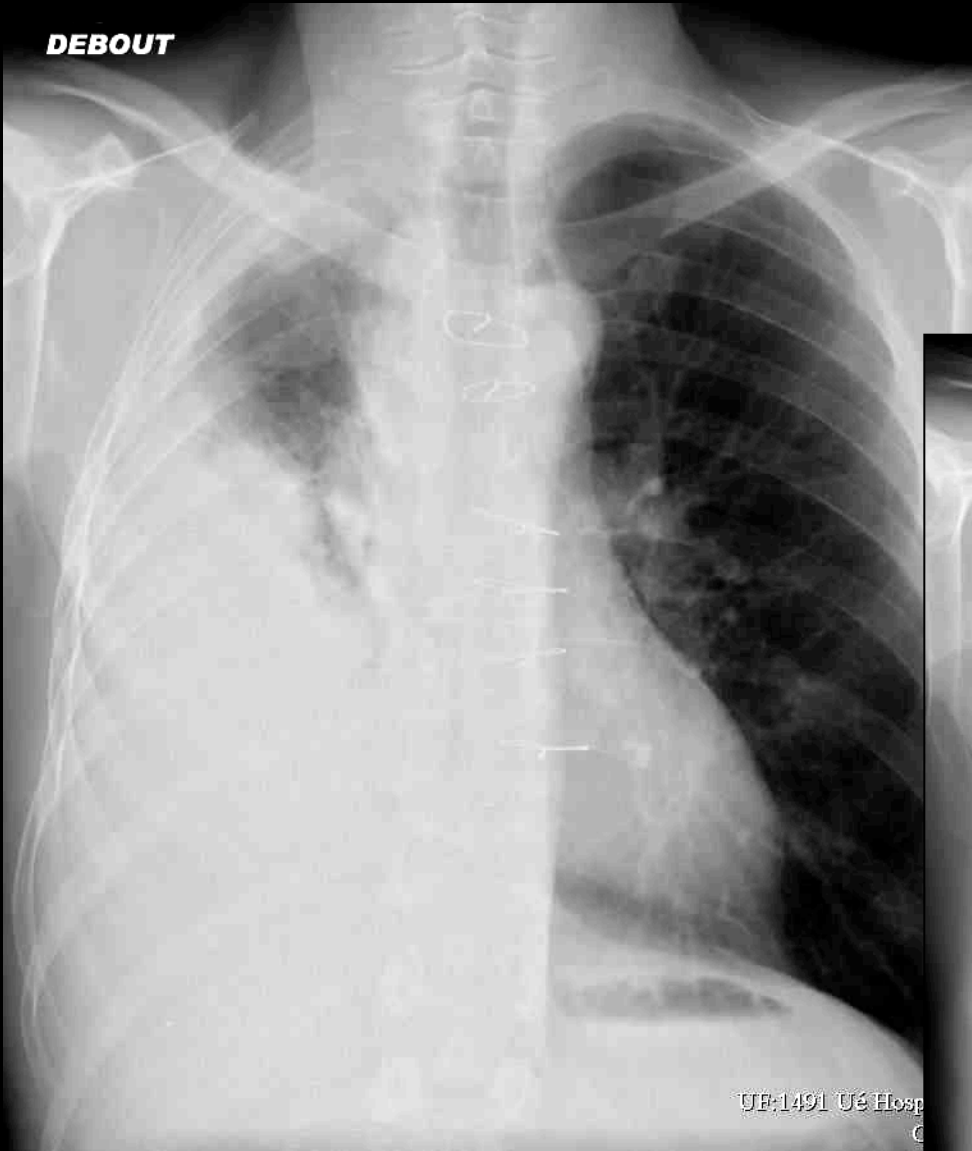
N°13

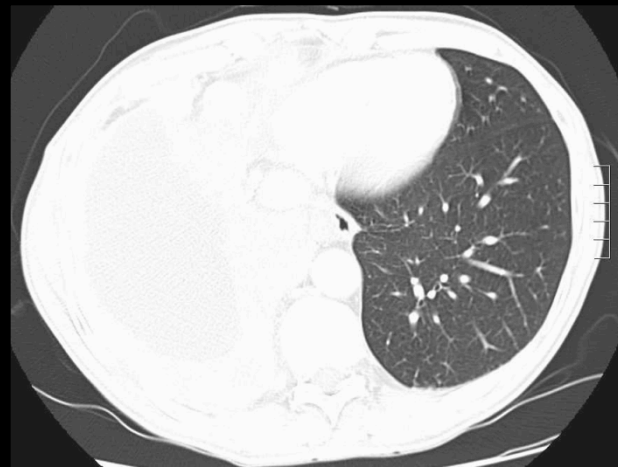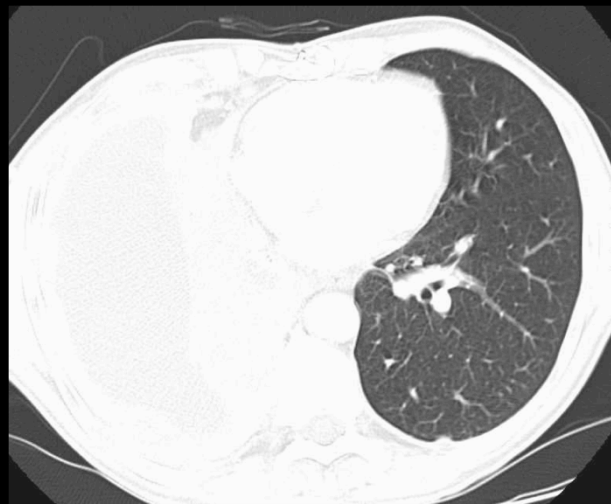
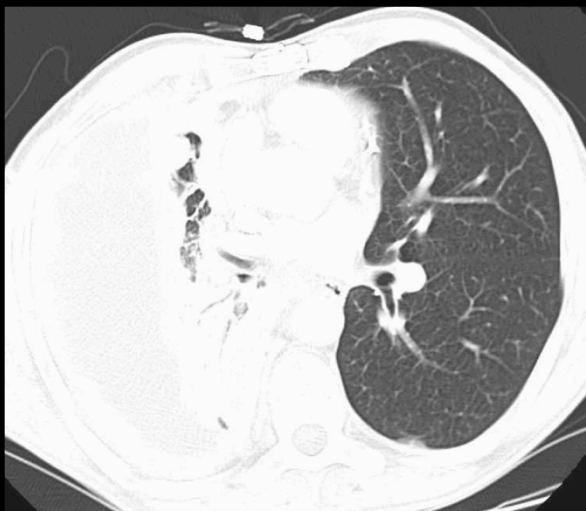
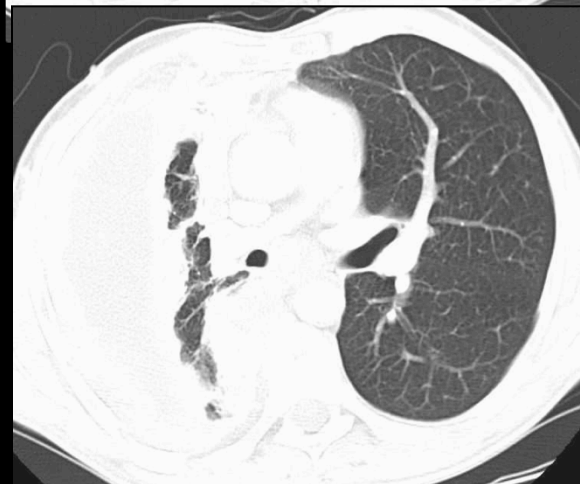
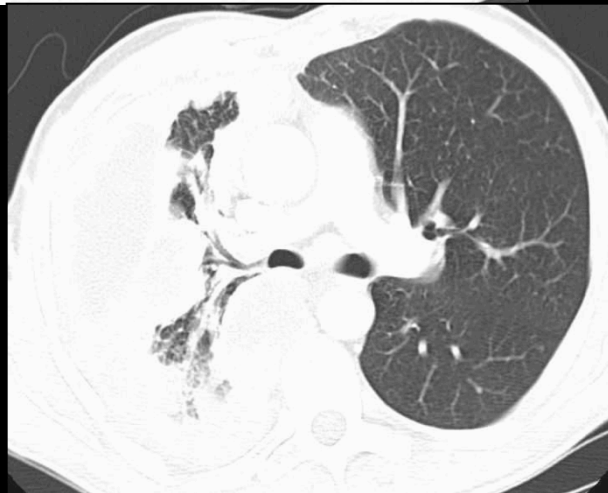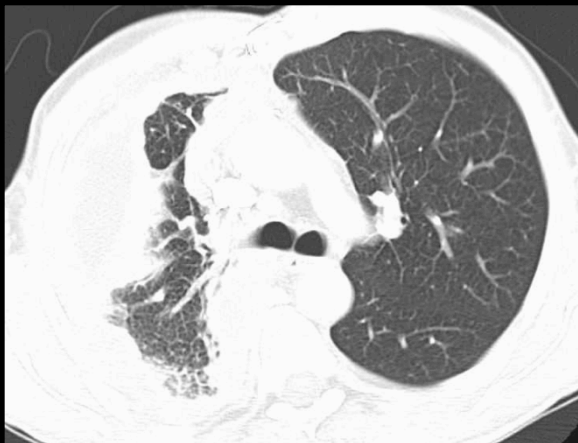
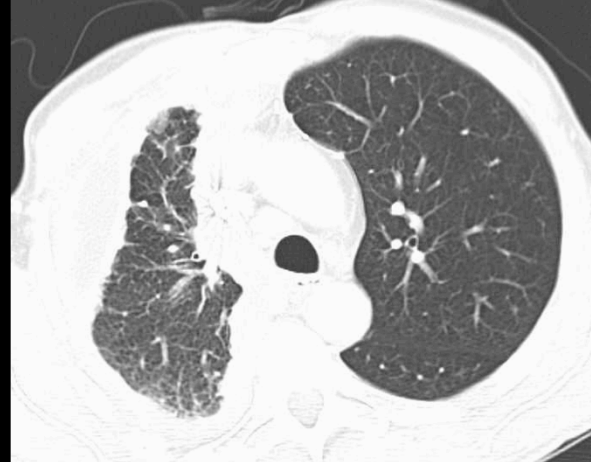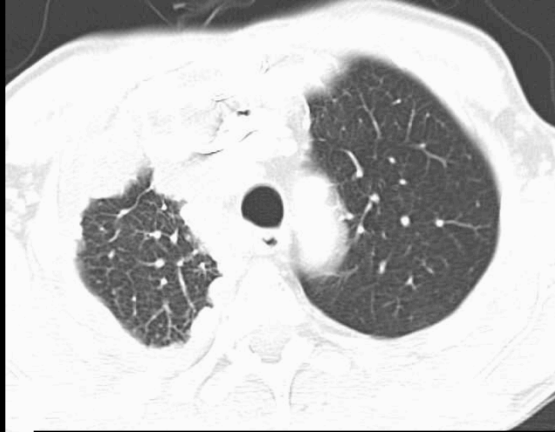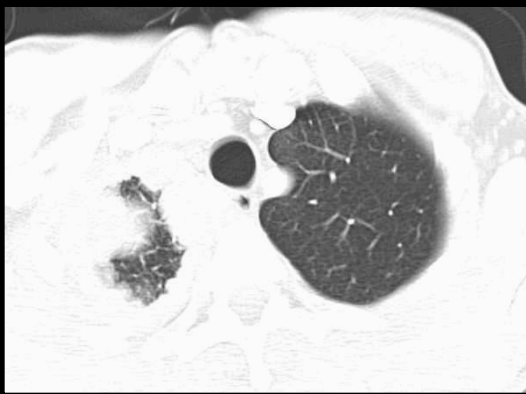


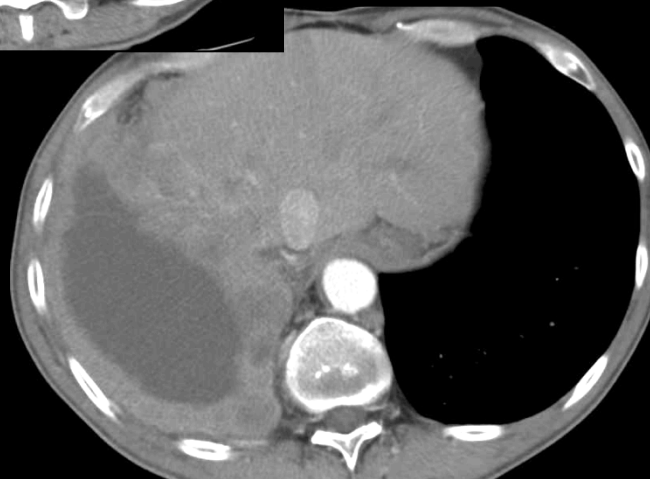
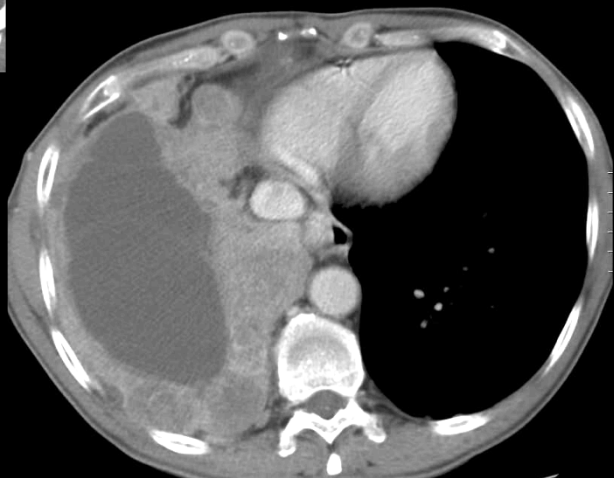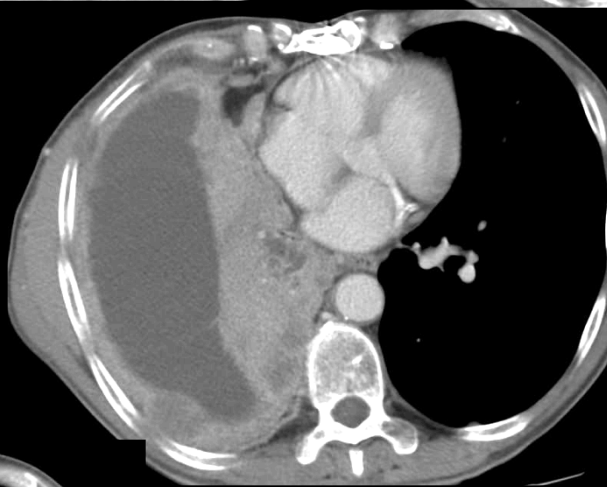
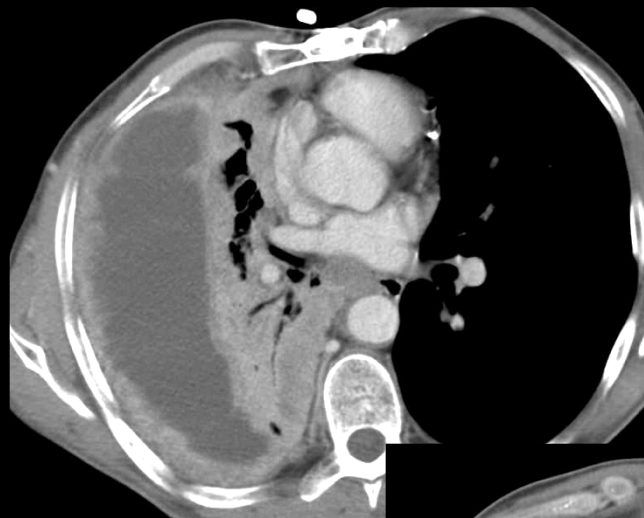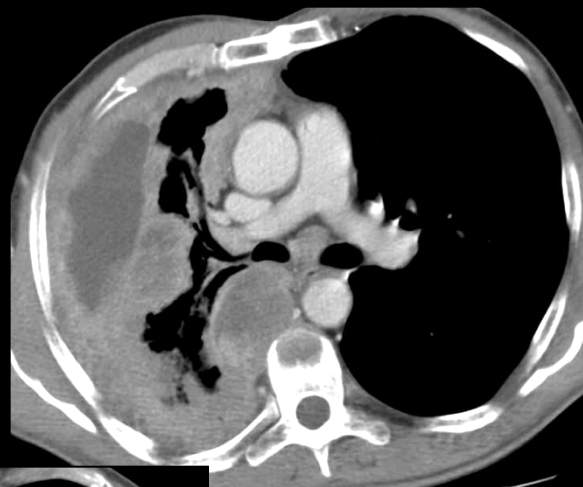
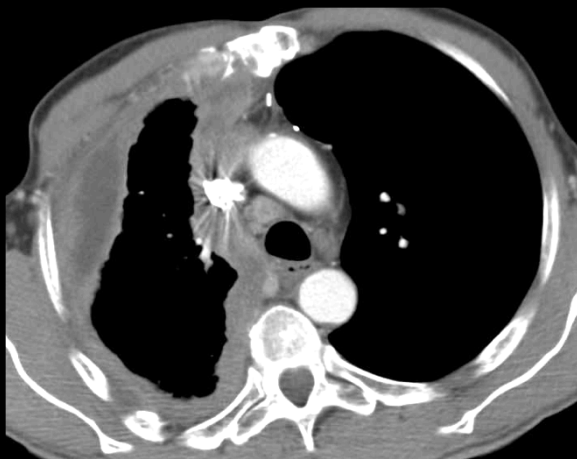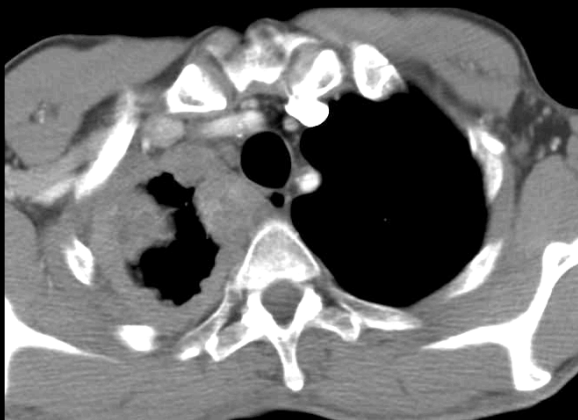Tumeur intercostale
neurogénique

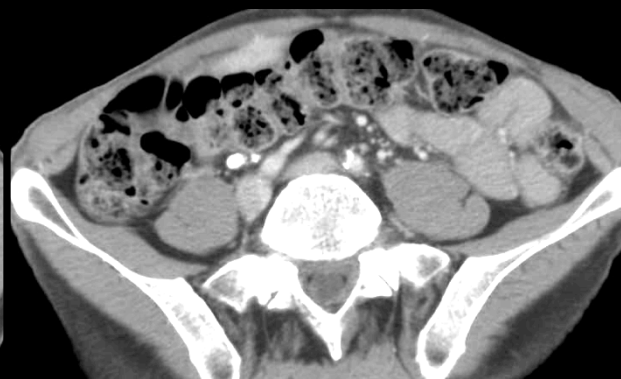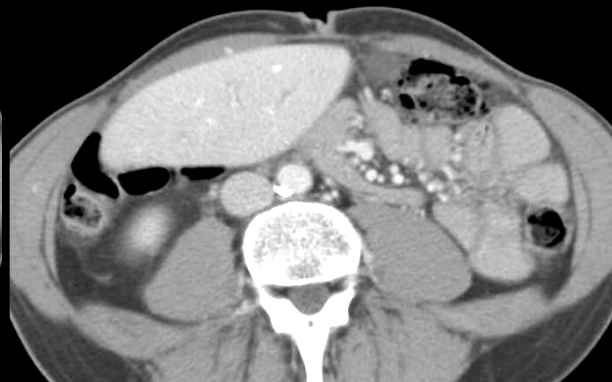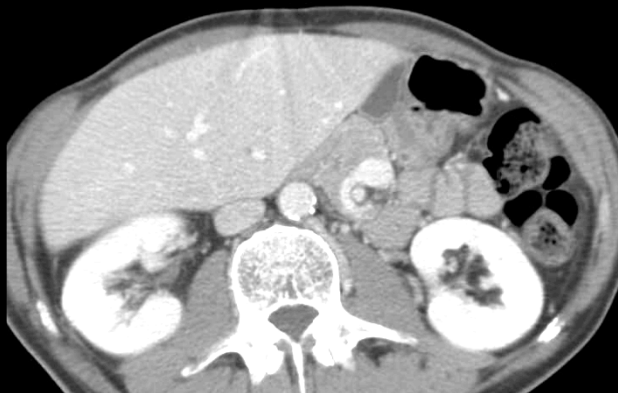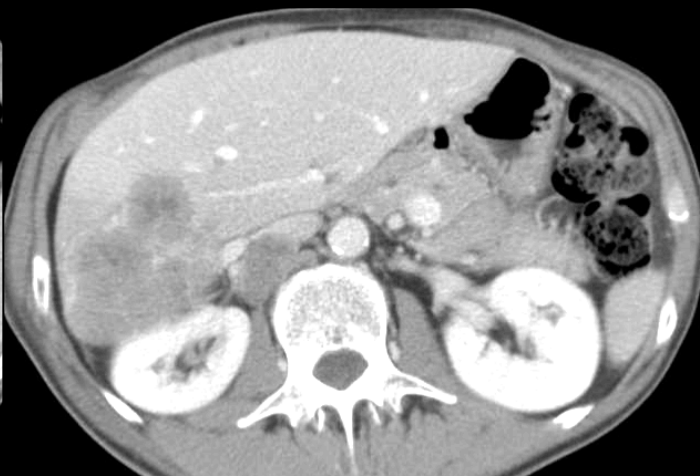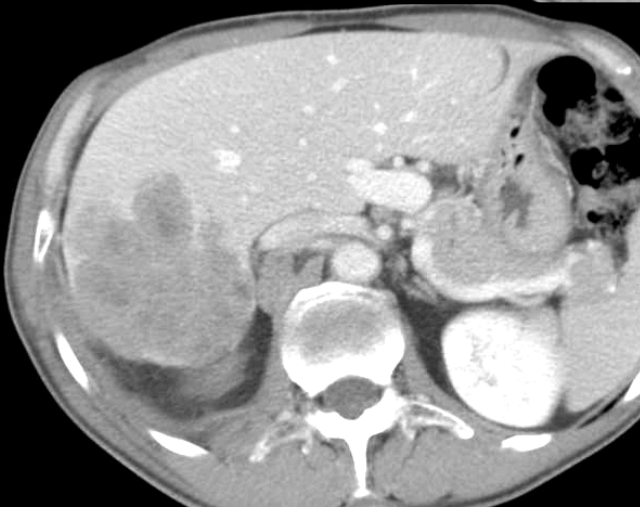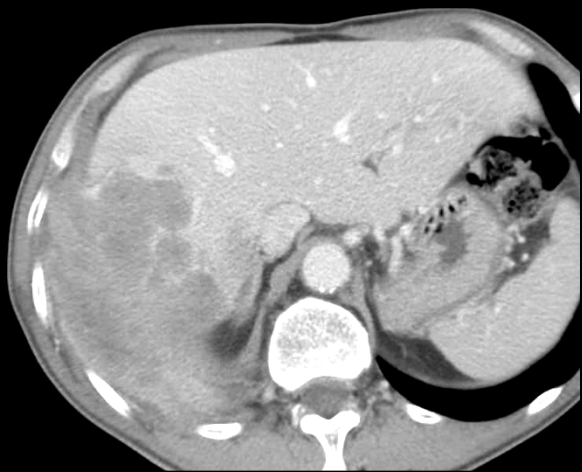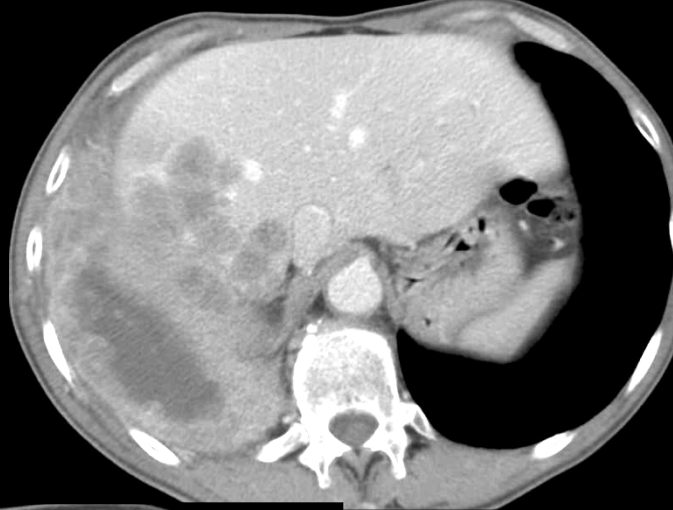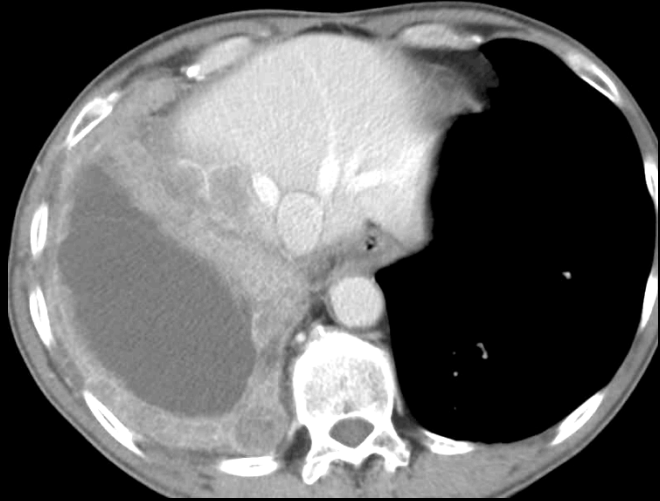DEBOUT

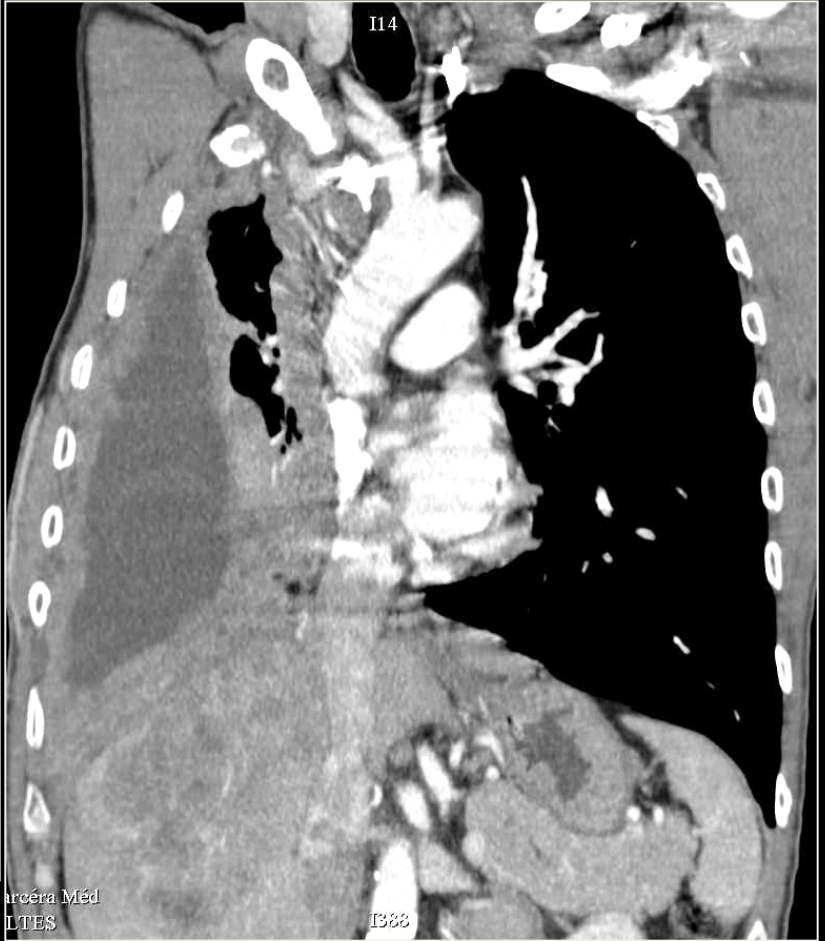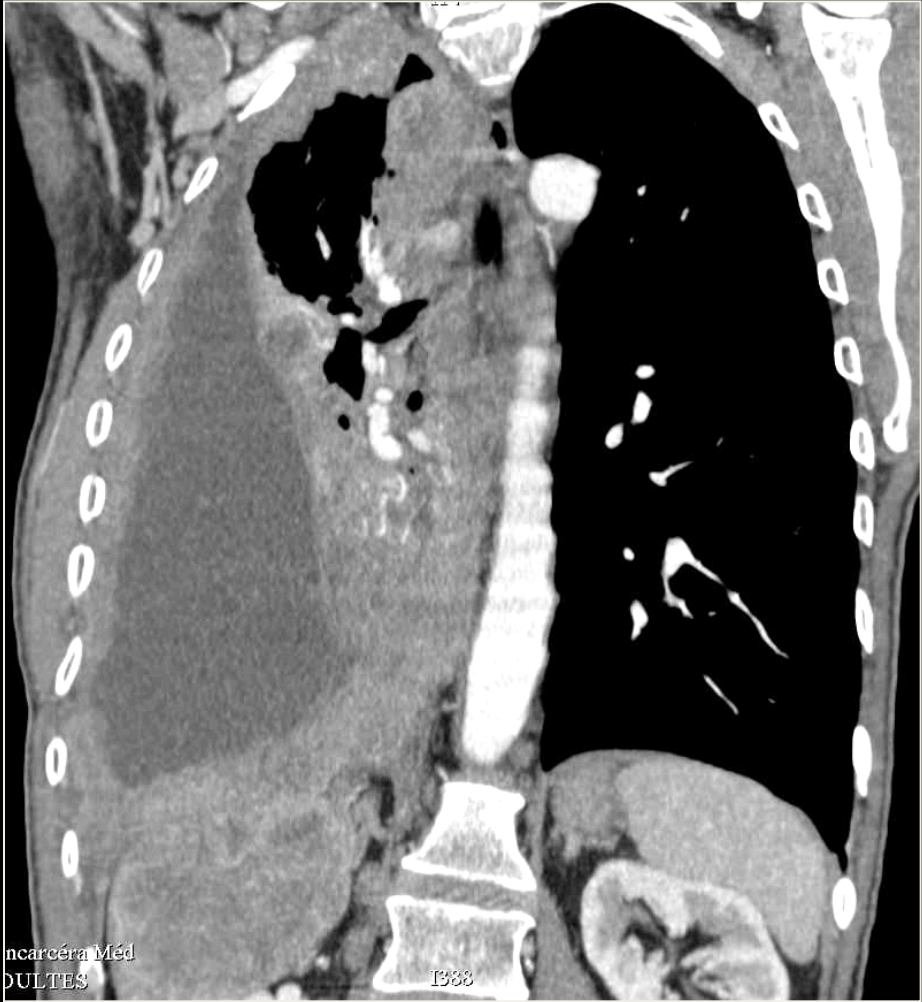N°14

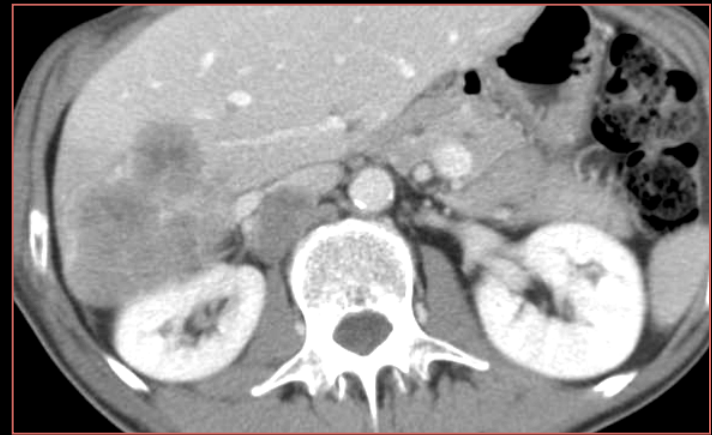
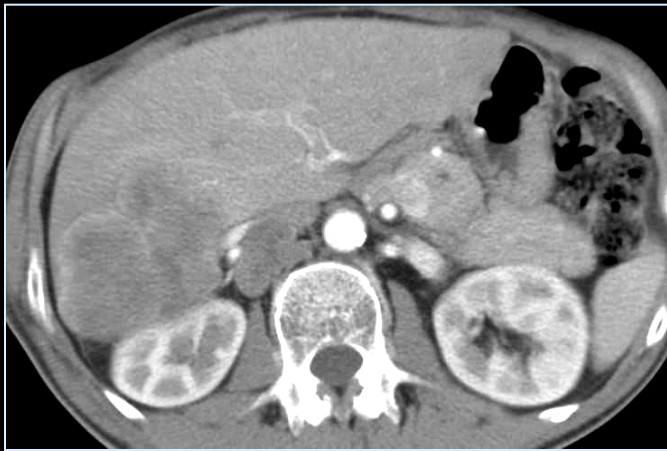
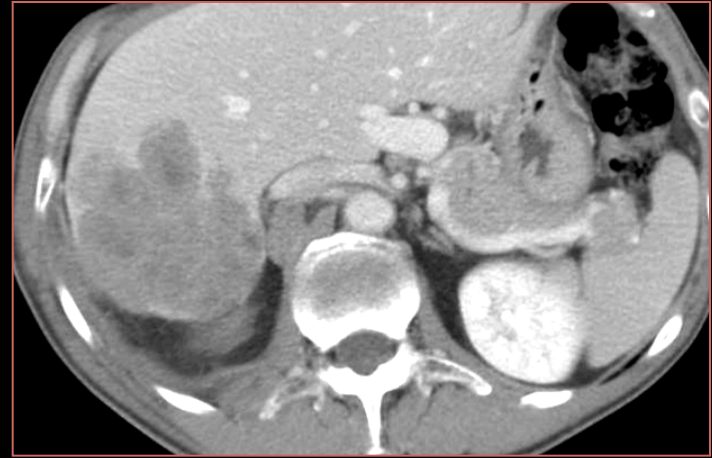
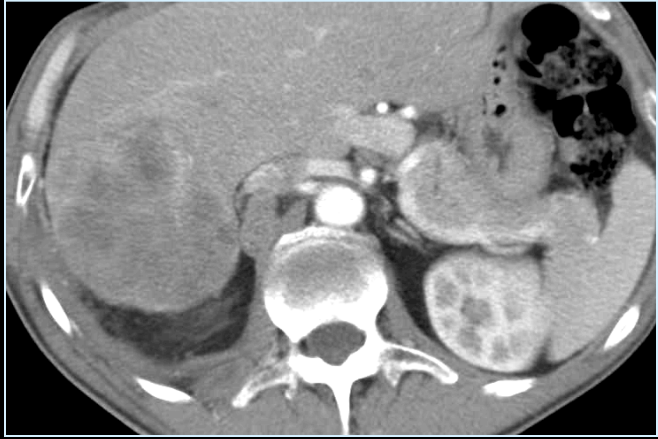




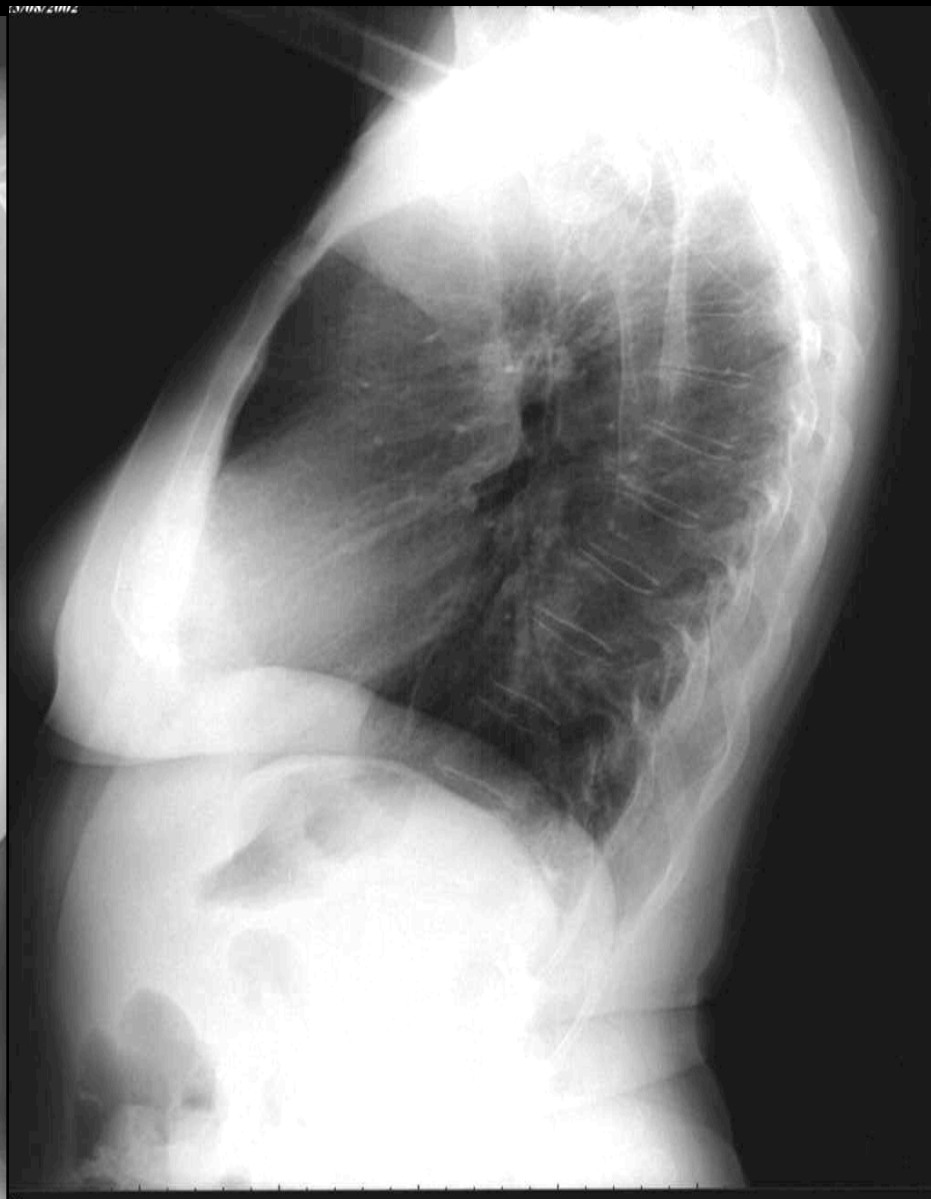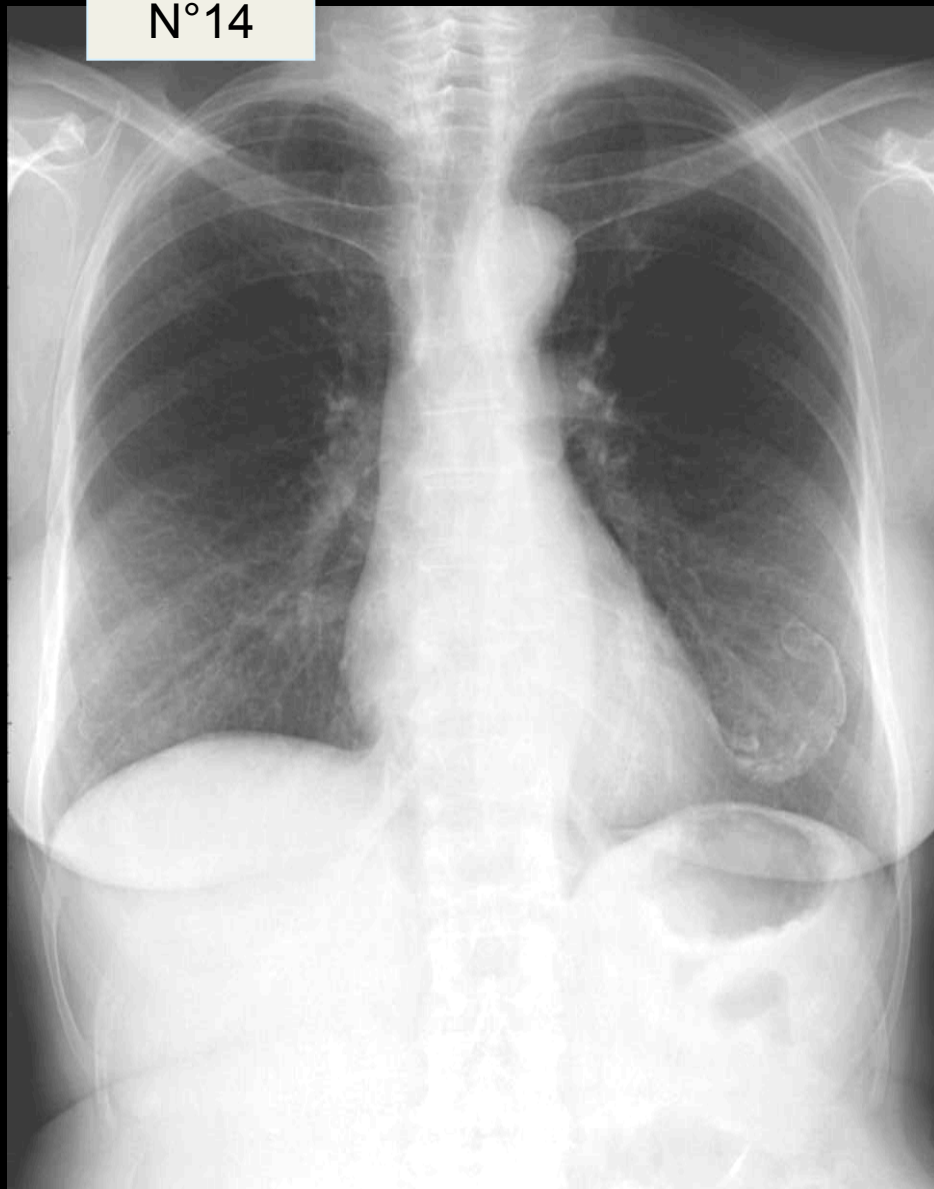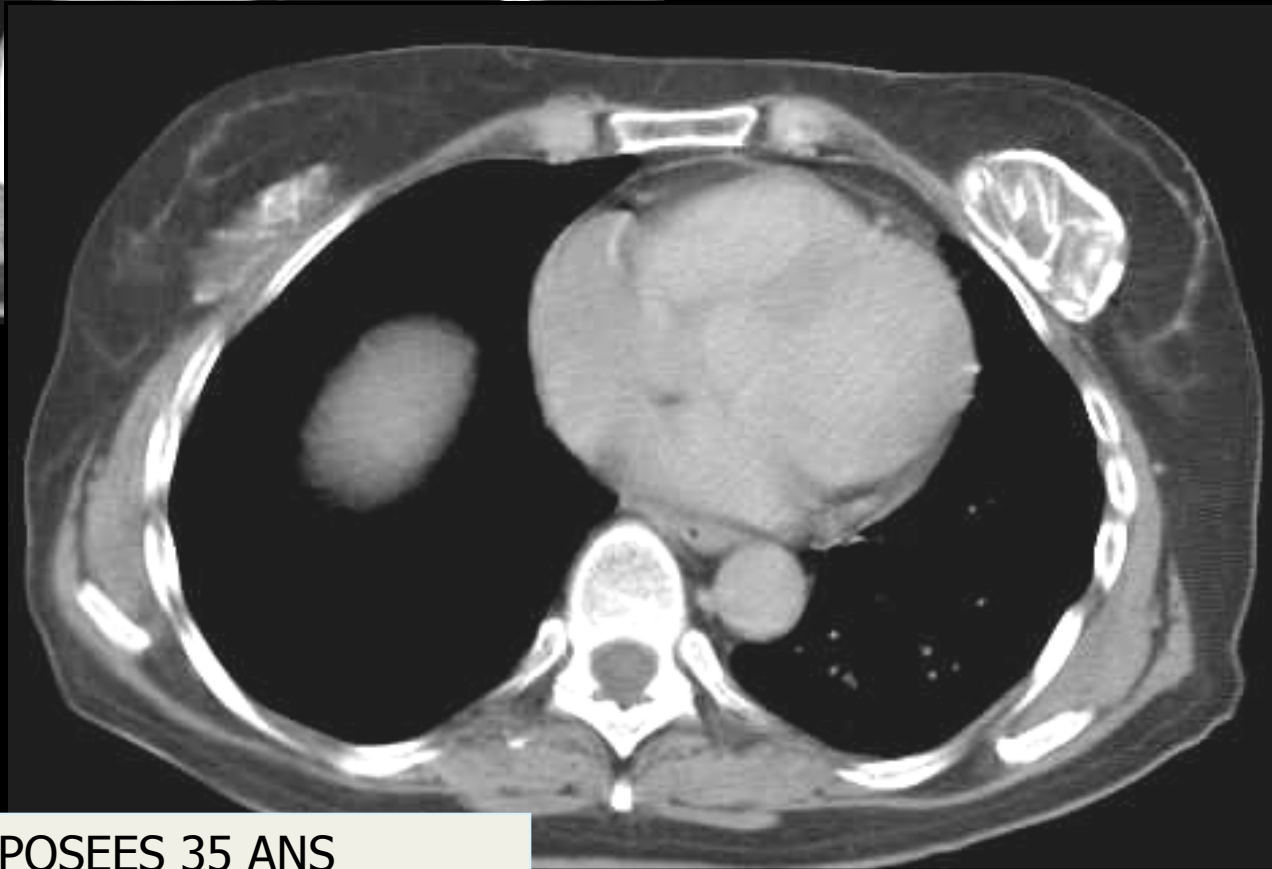
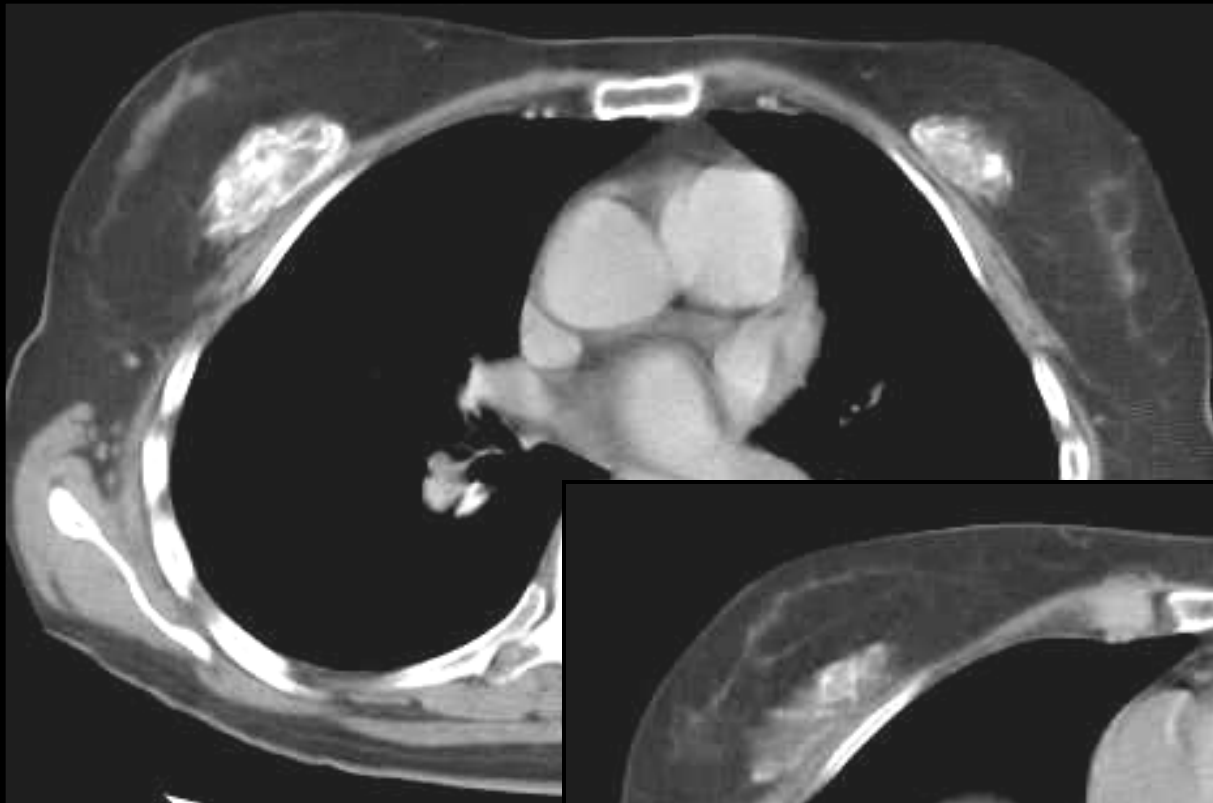




Aspect très évocateur de mésothéliome ;
biopsie : adénocarcinome

N°14

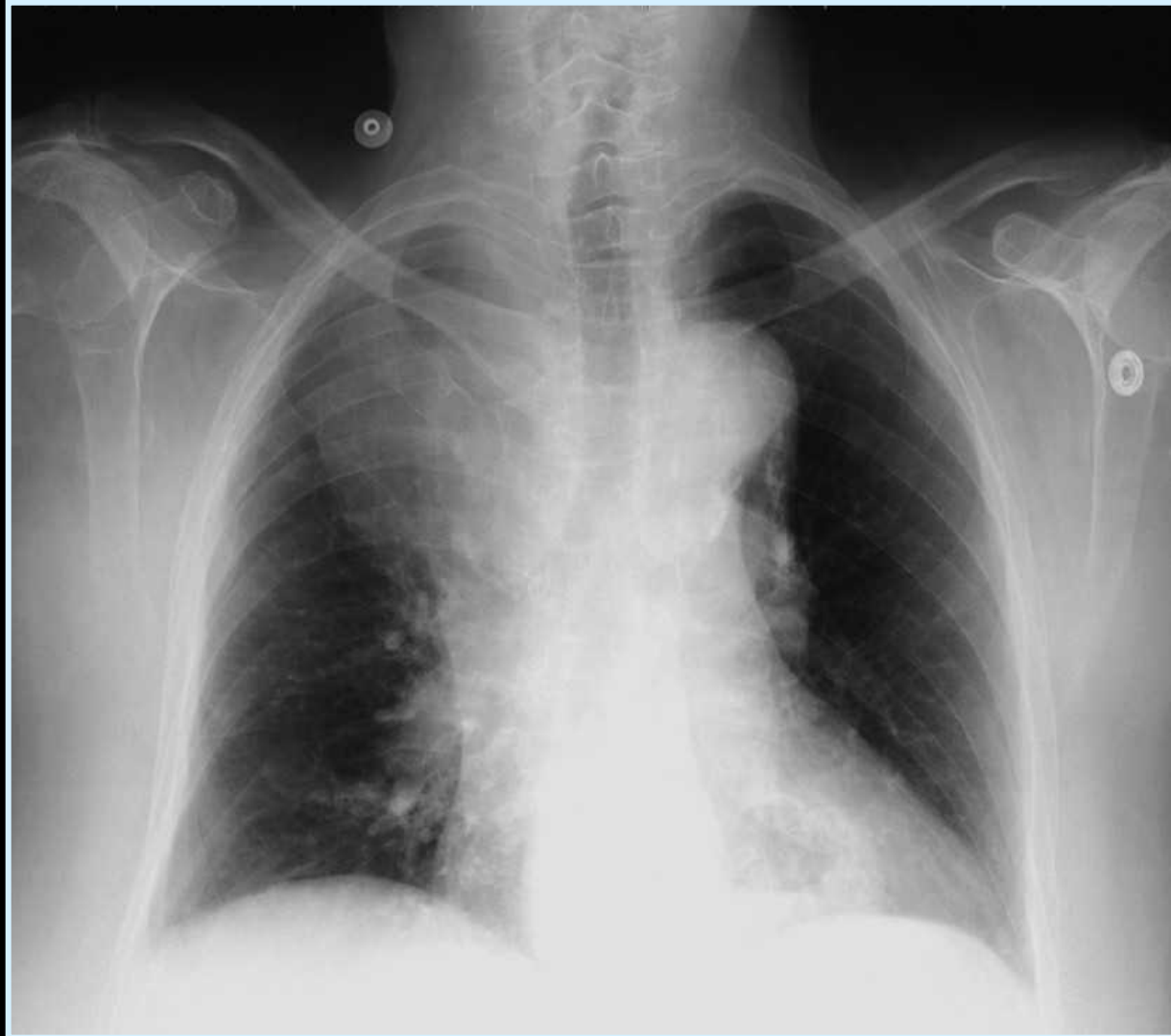

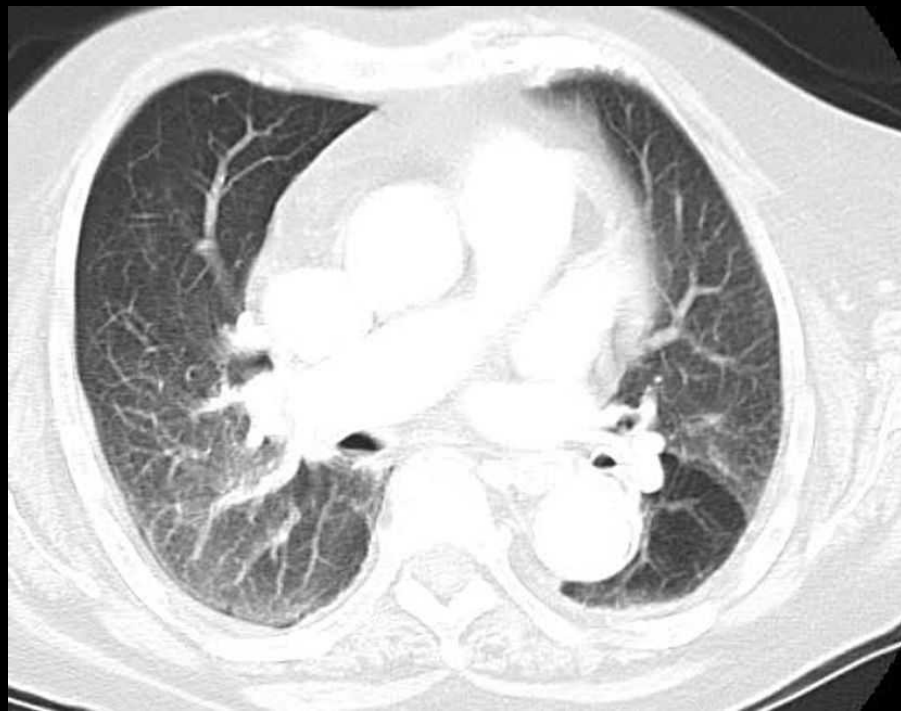
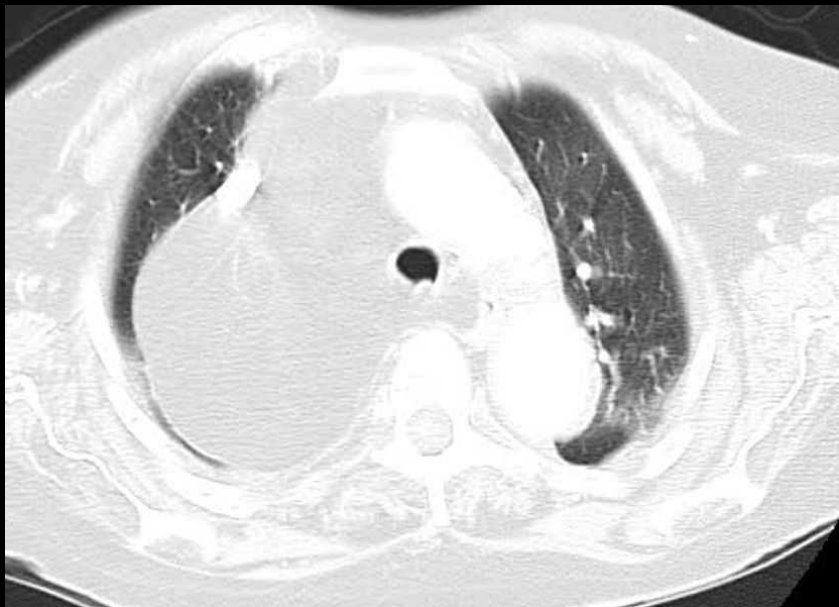

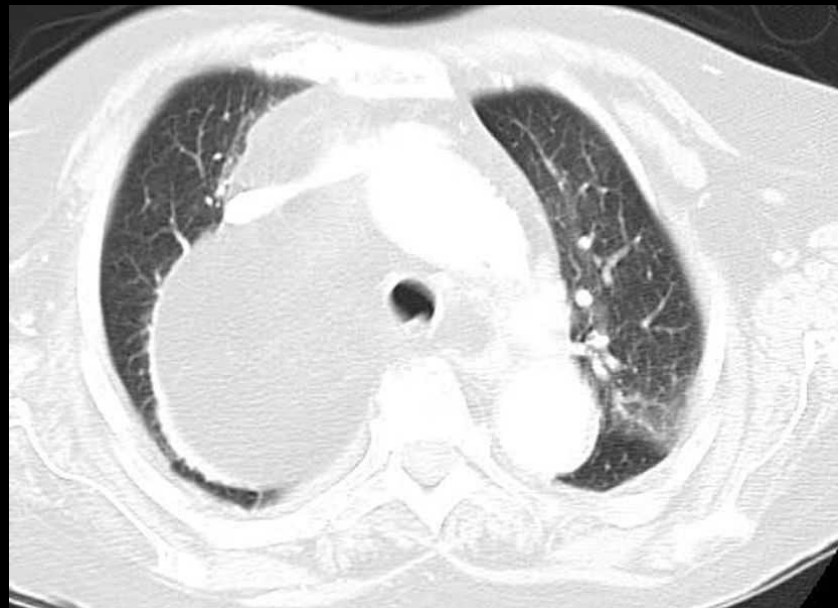
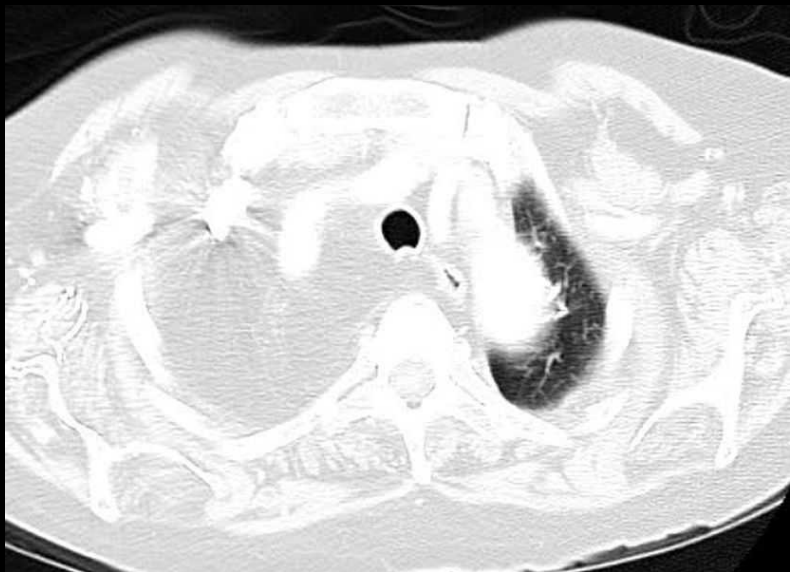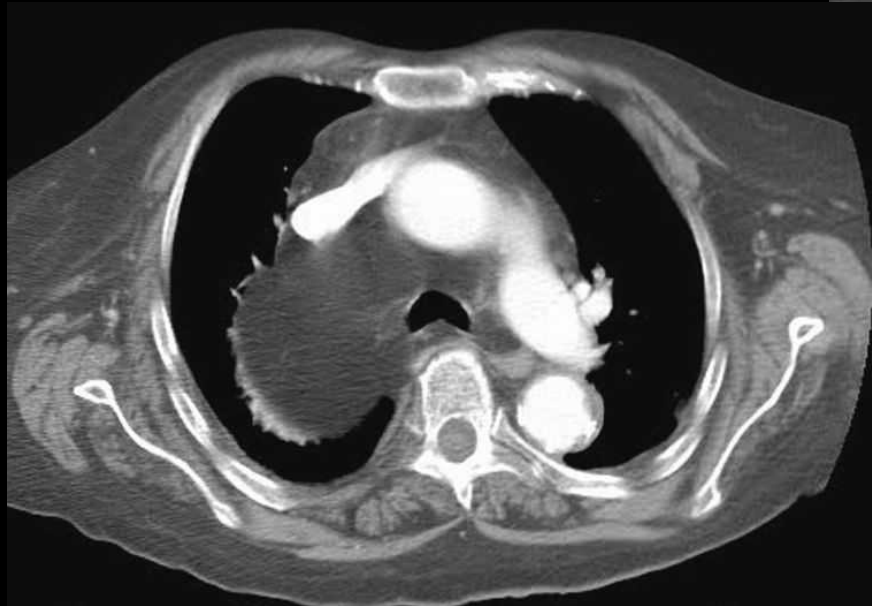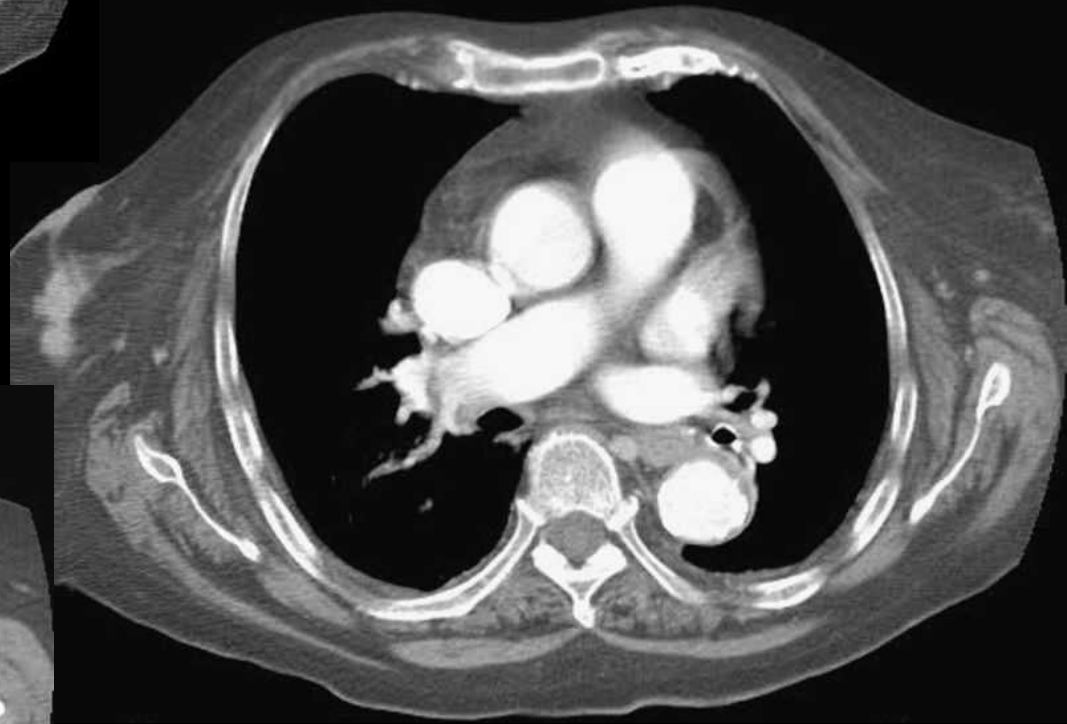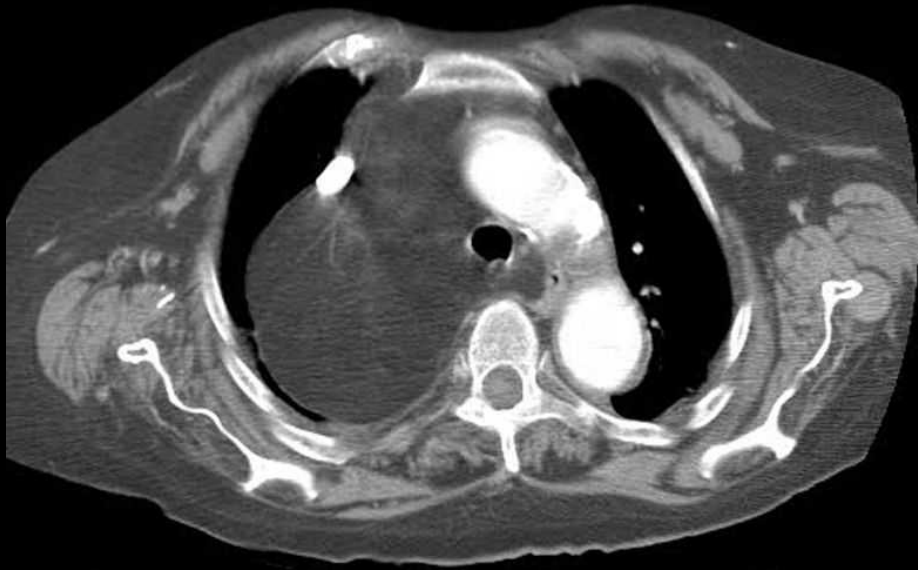PROTHESES MAMMAIRES POSEES 35 ANS

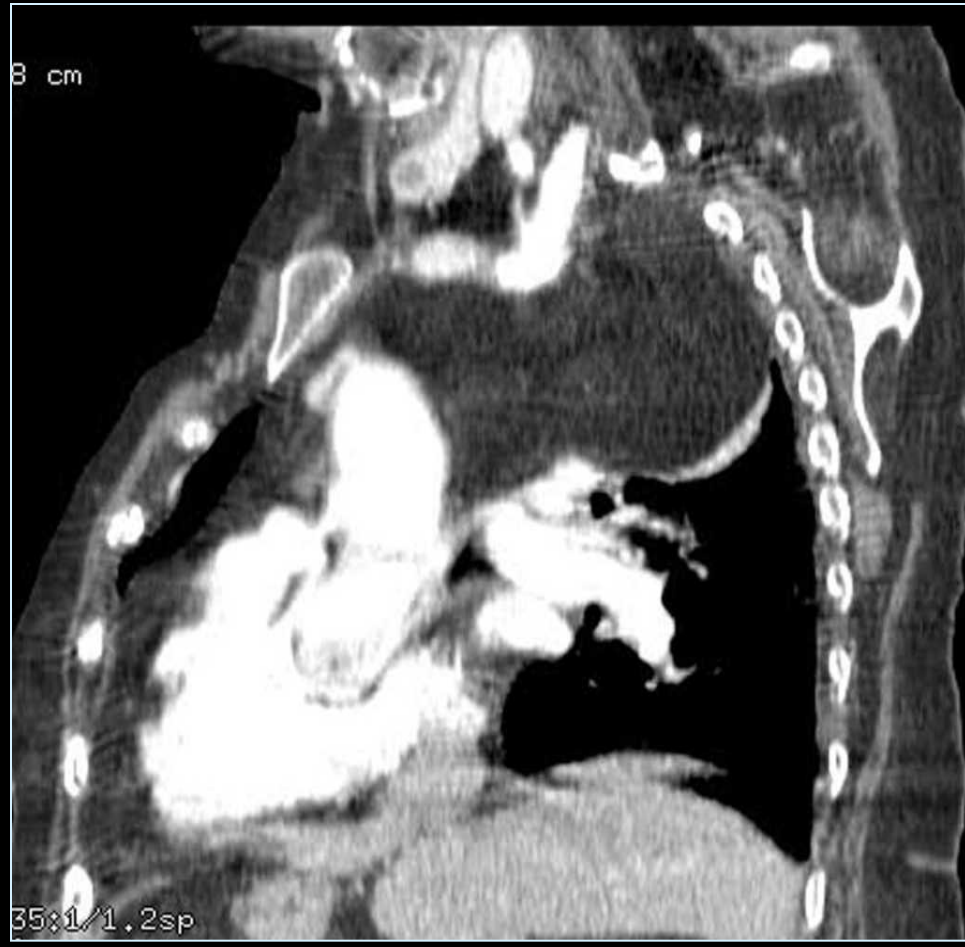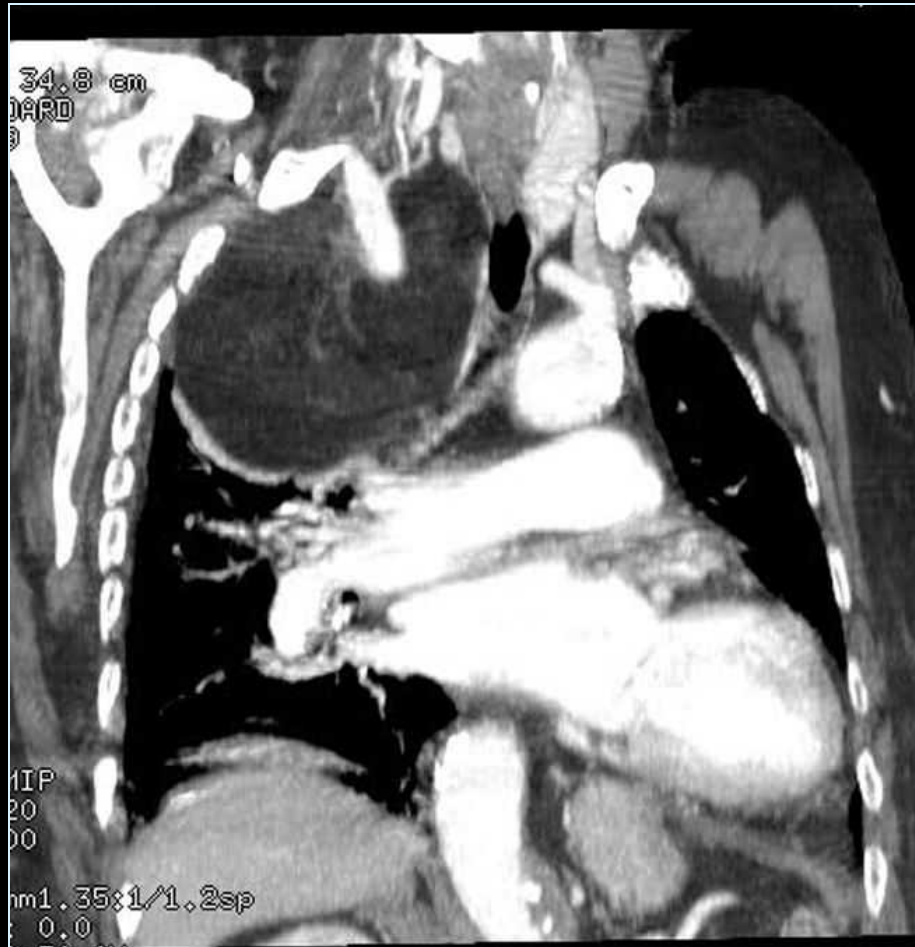
Patiente de 90 ans altération de l'état général

N°15

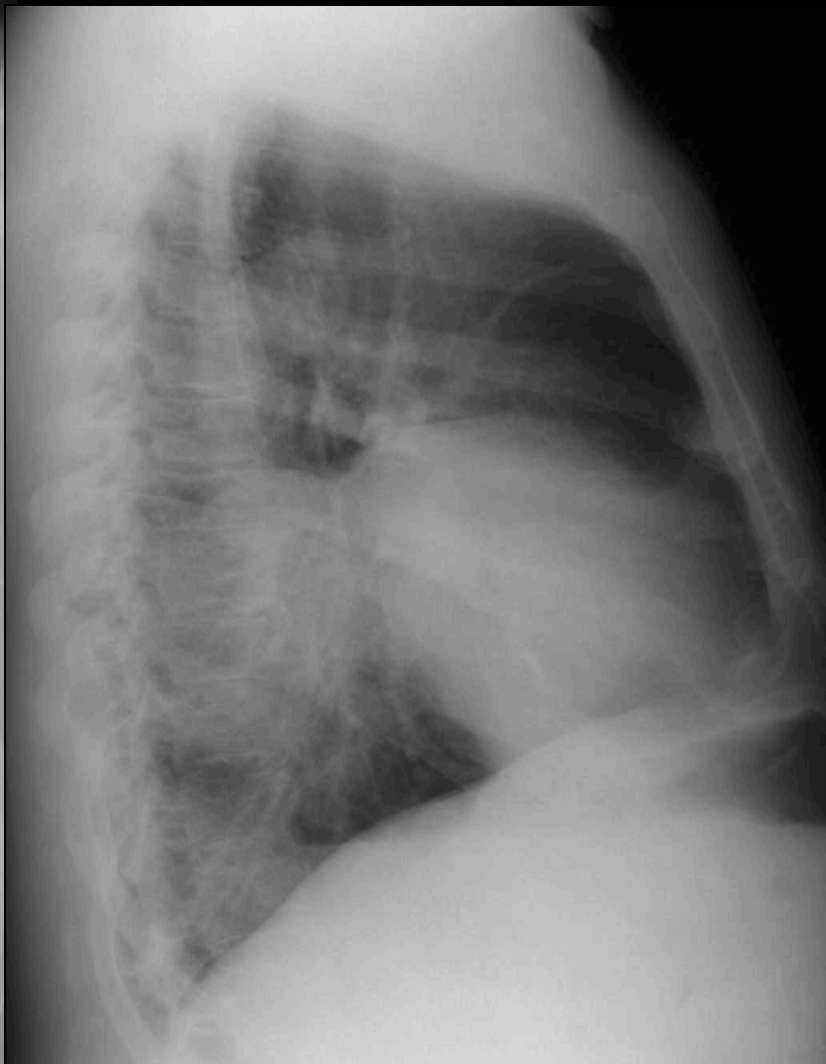
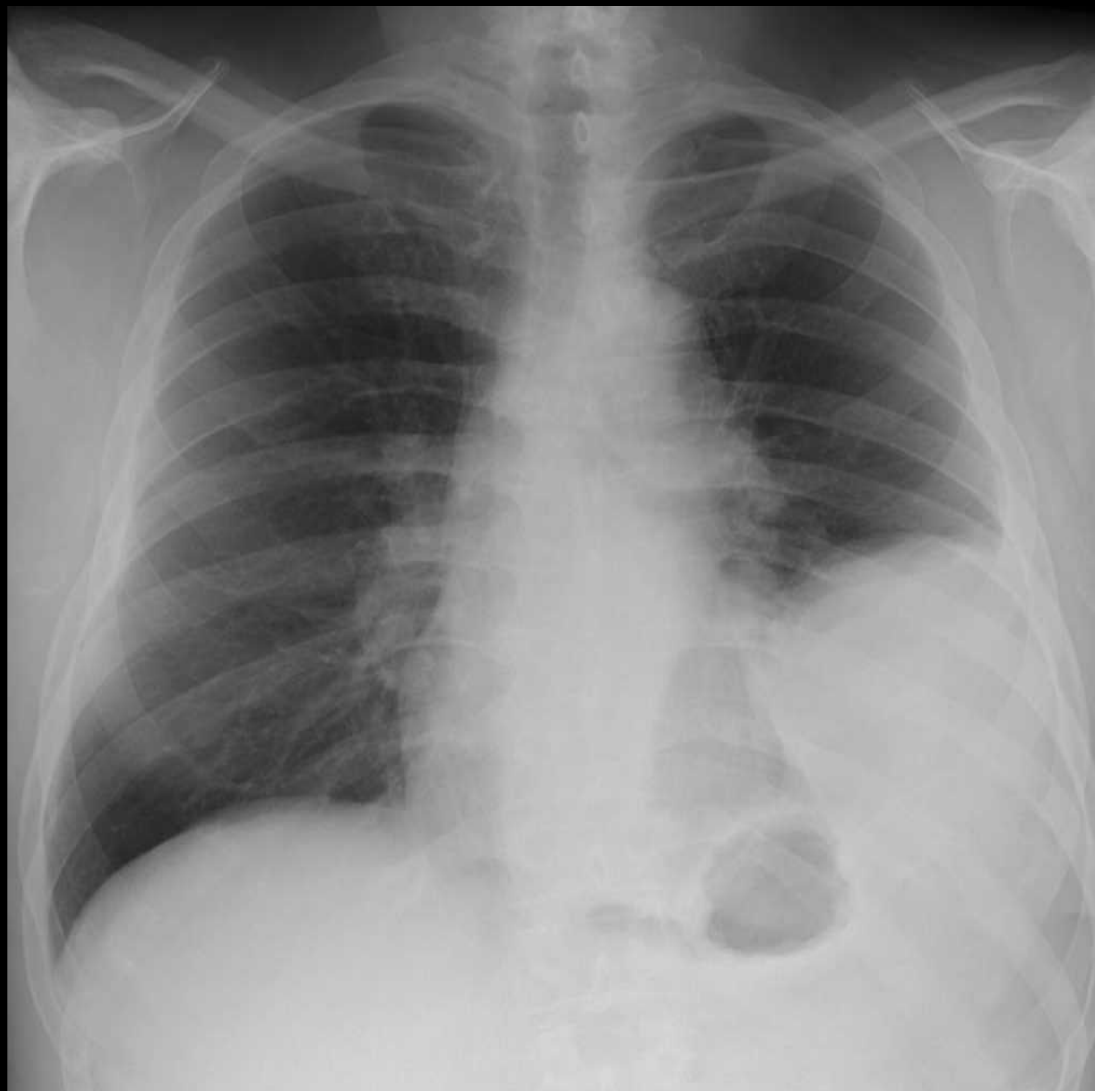


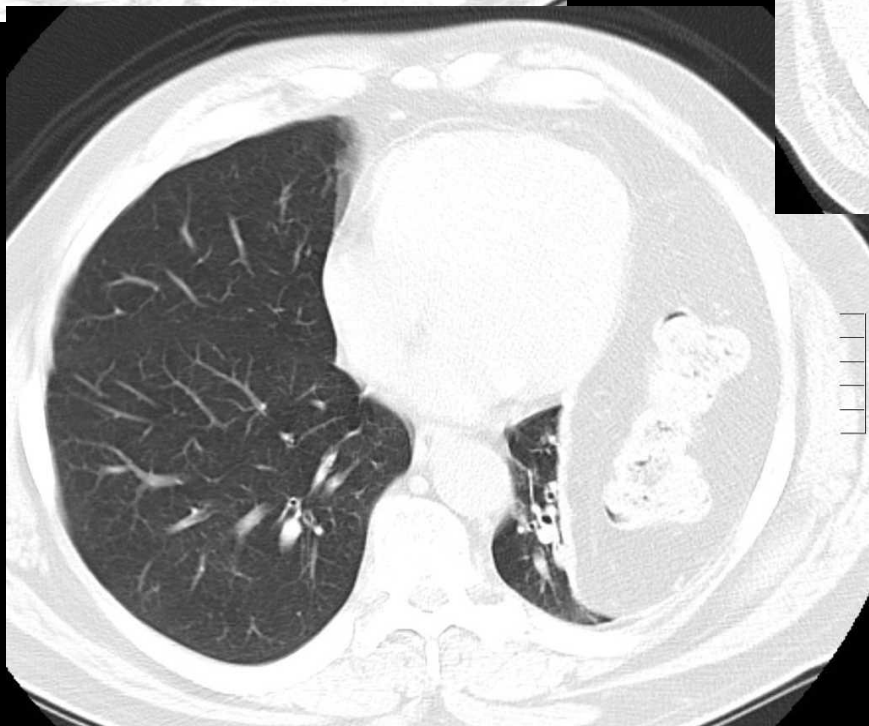
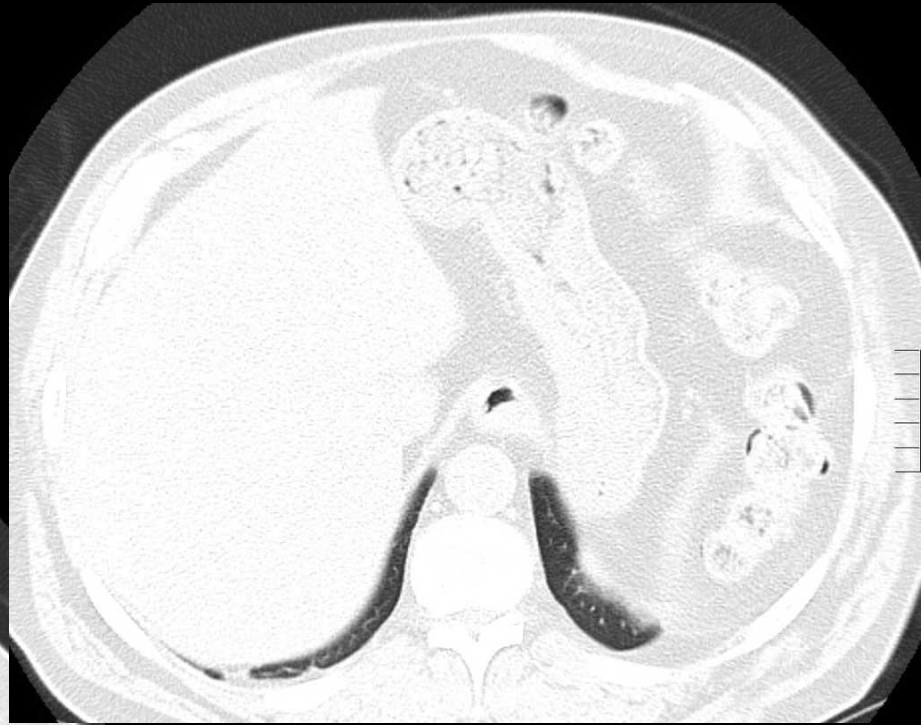
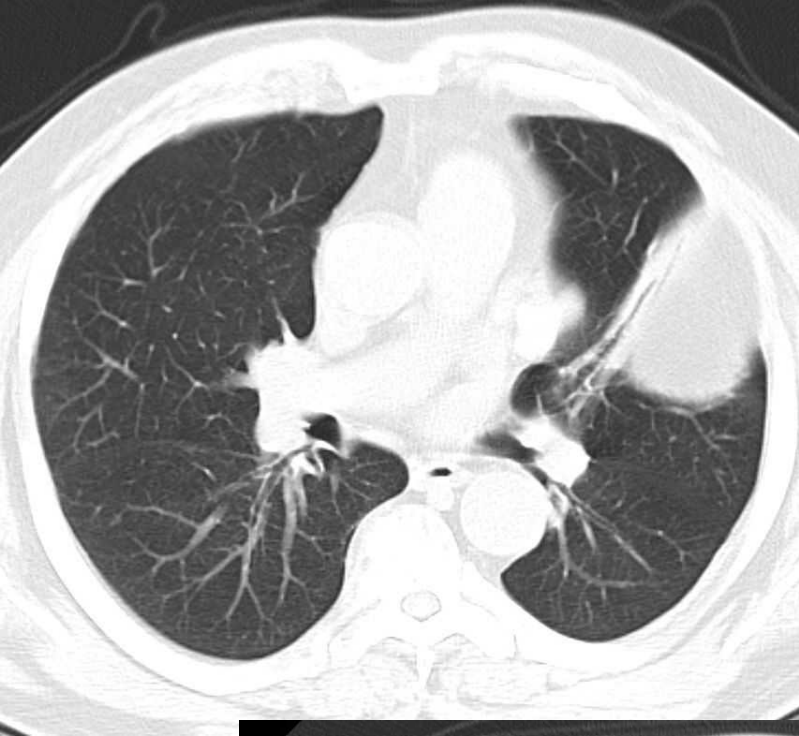
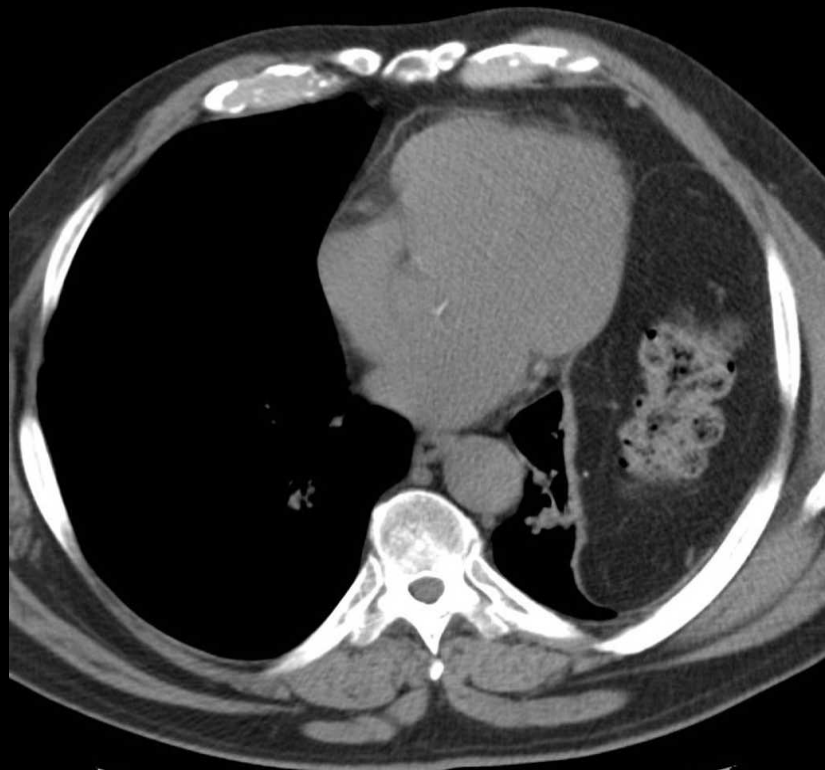
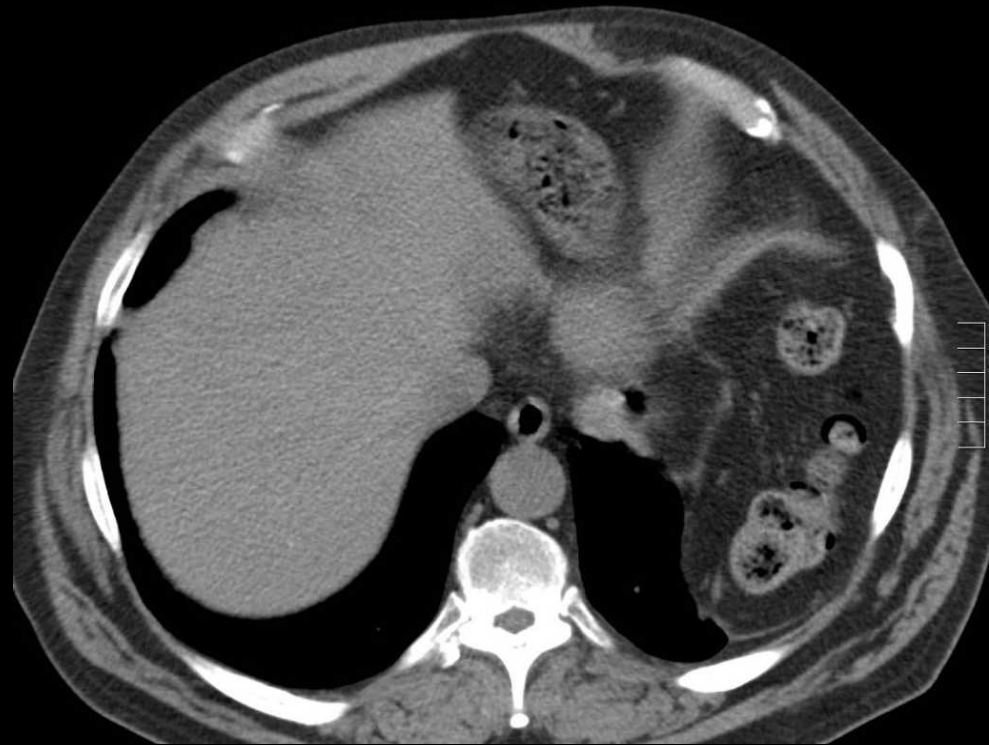
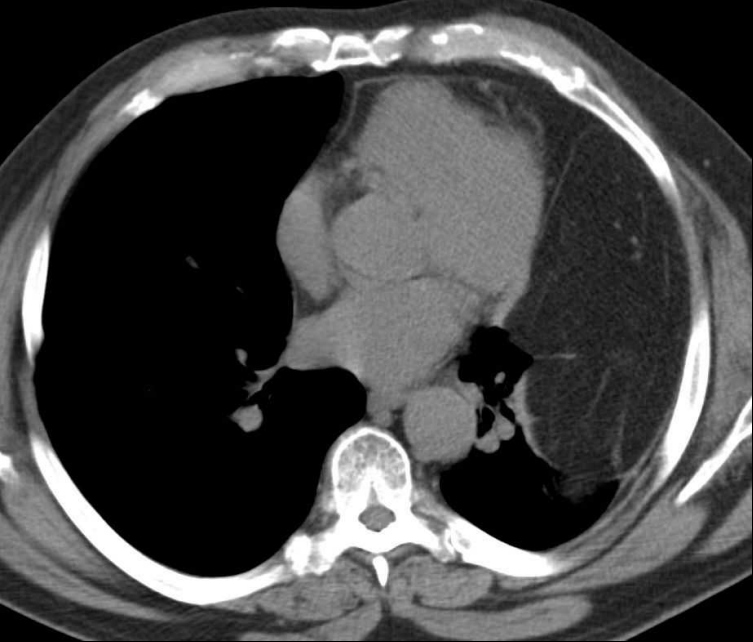


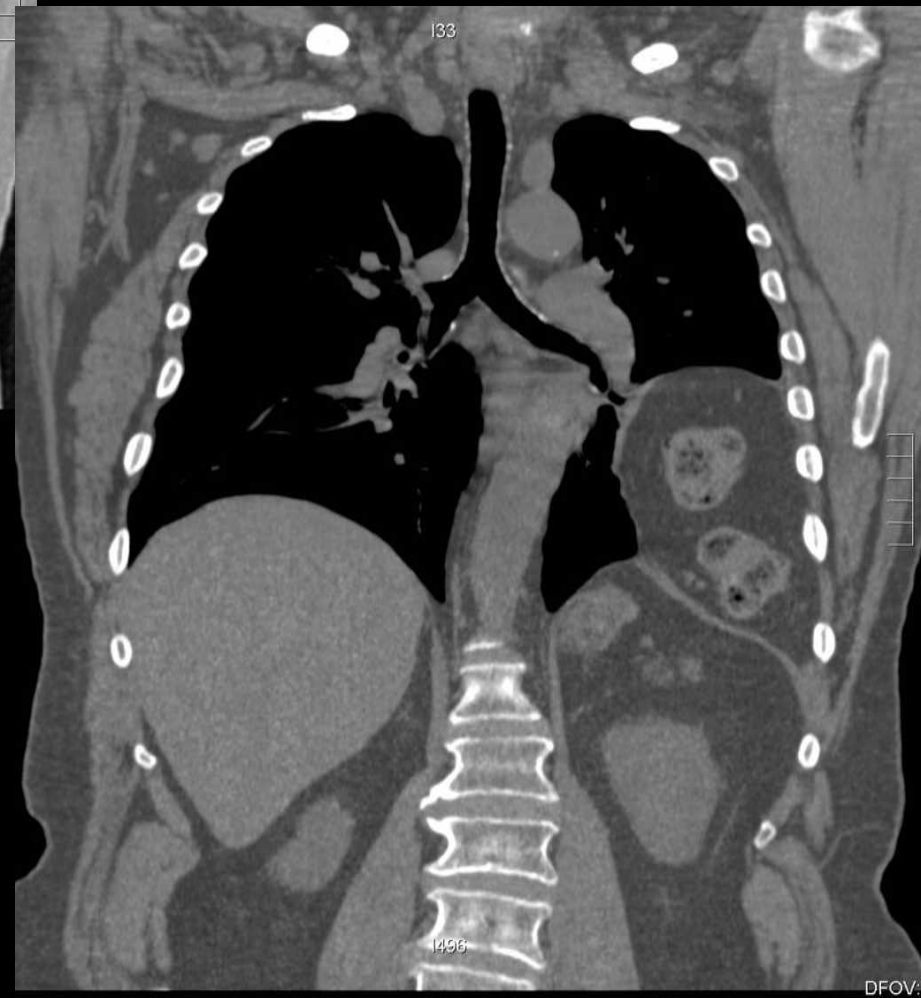
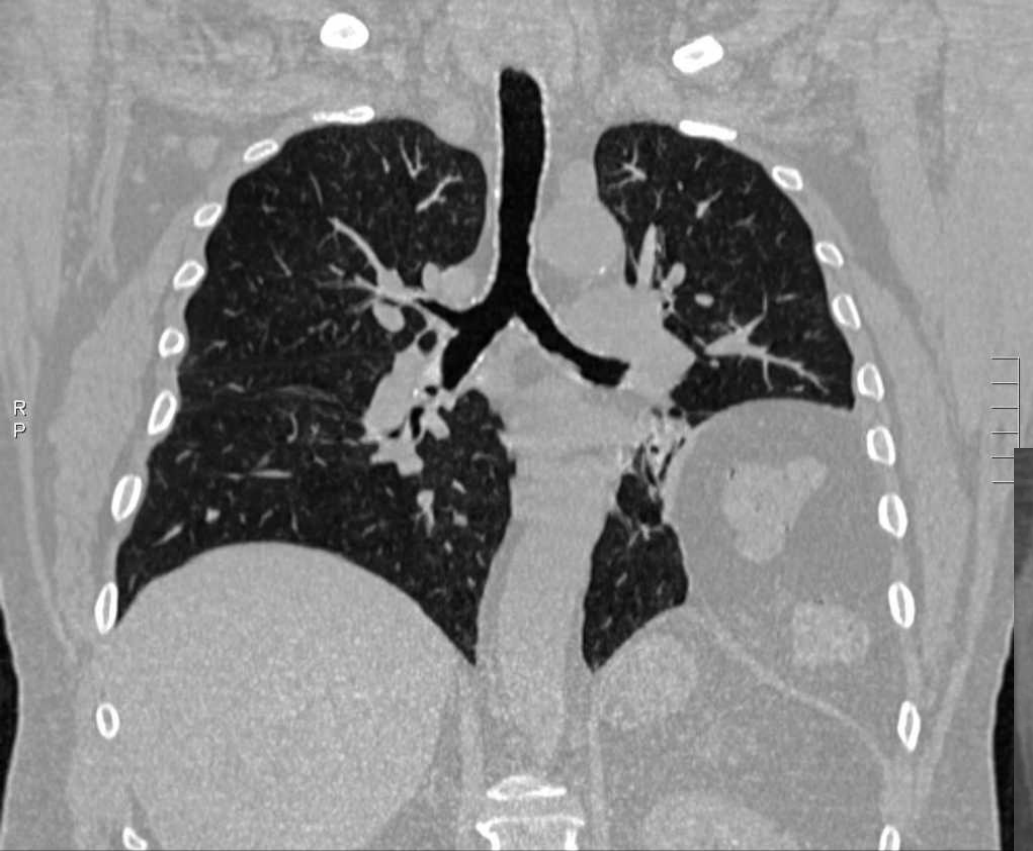


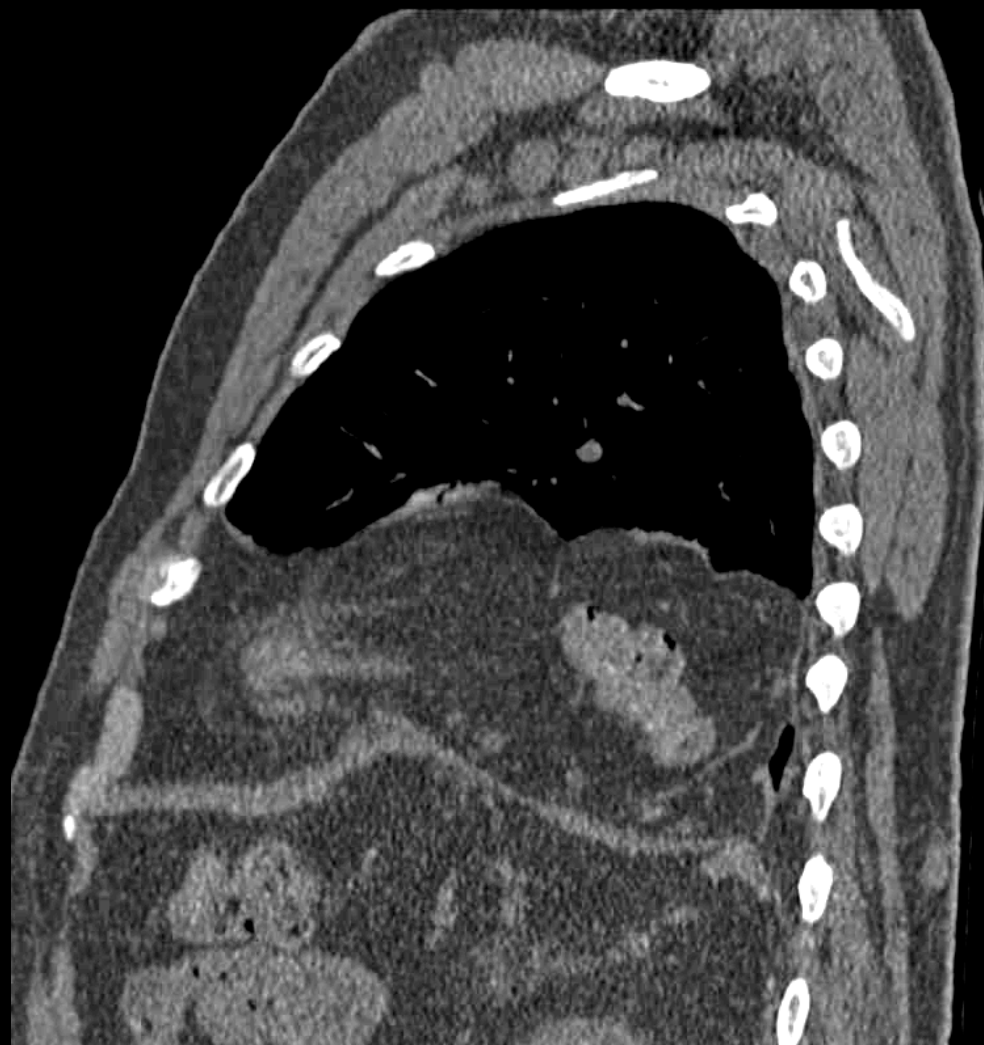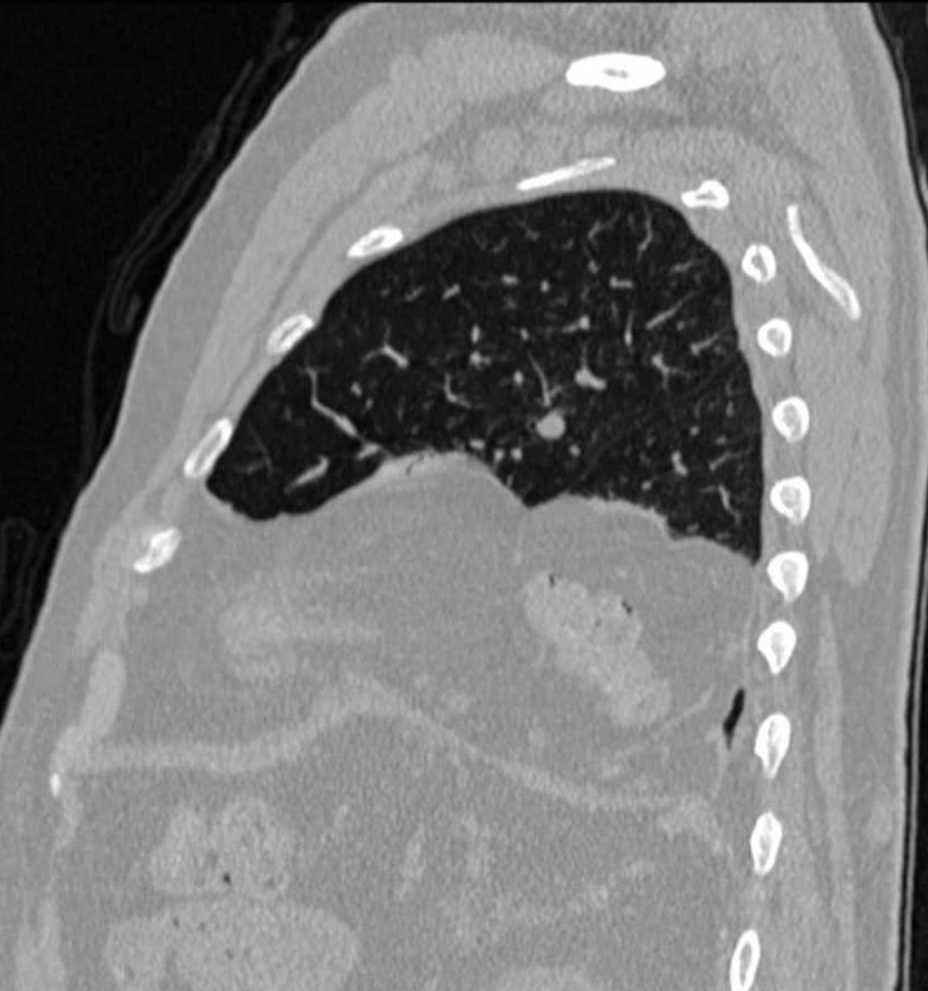N°16

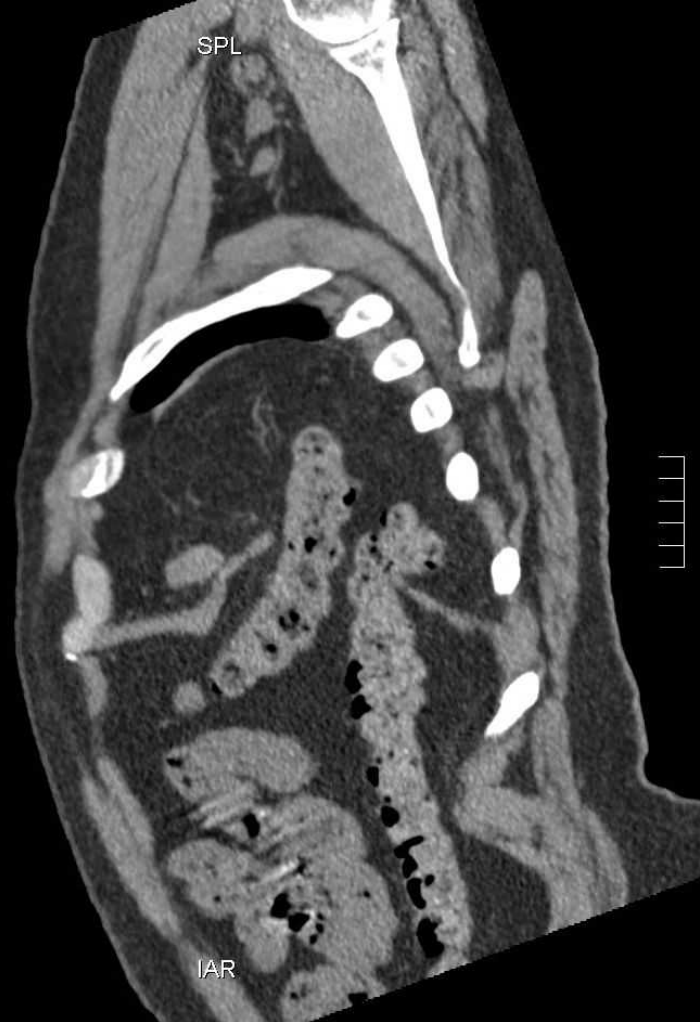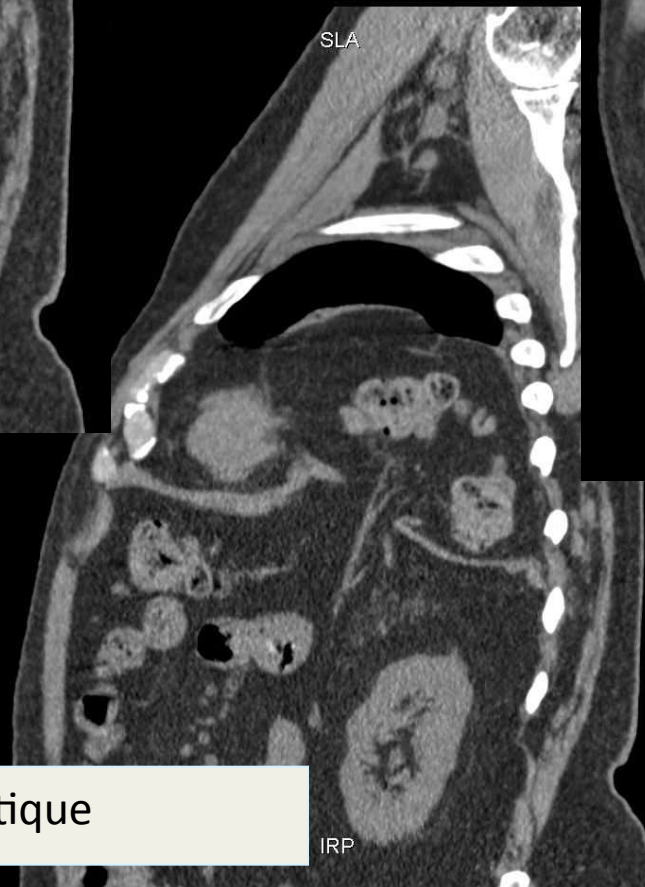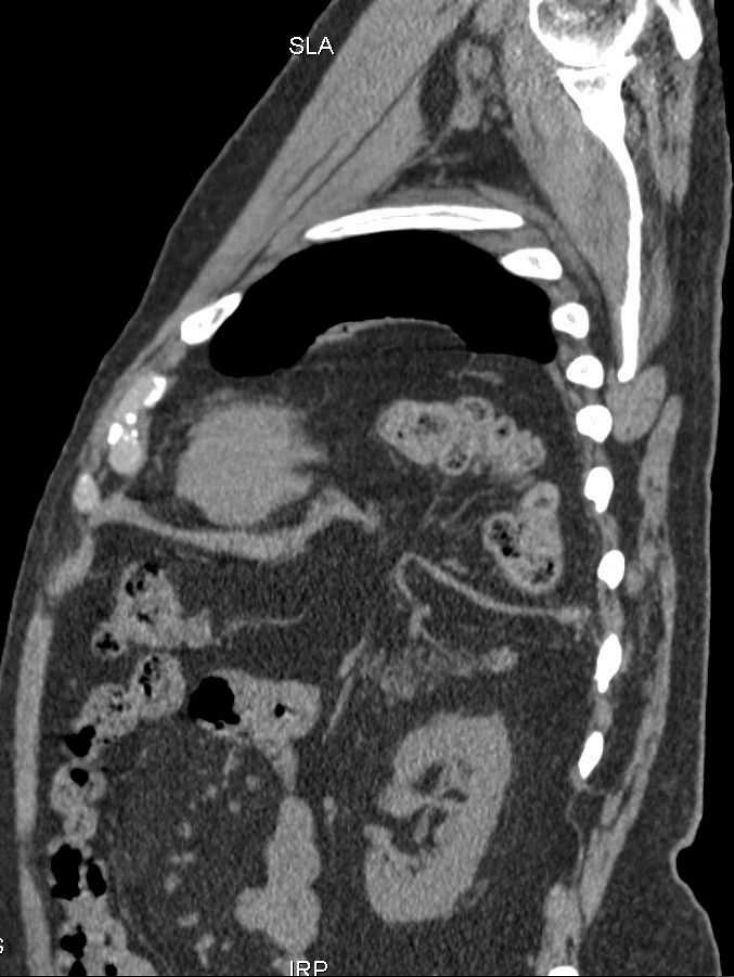










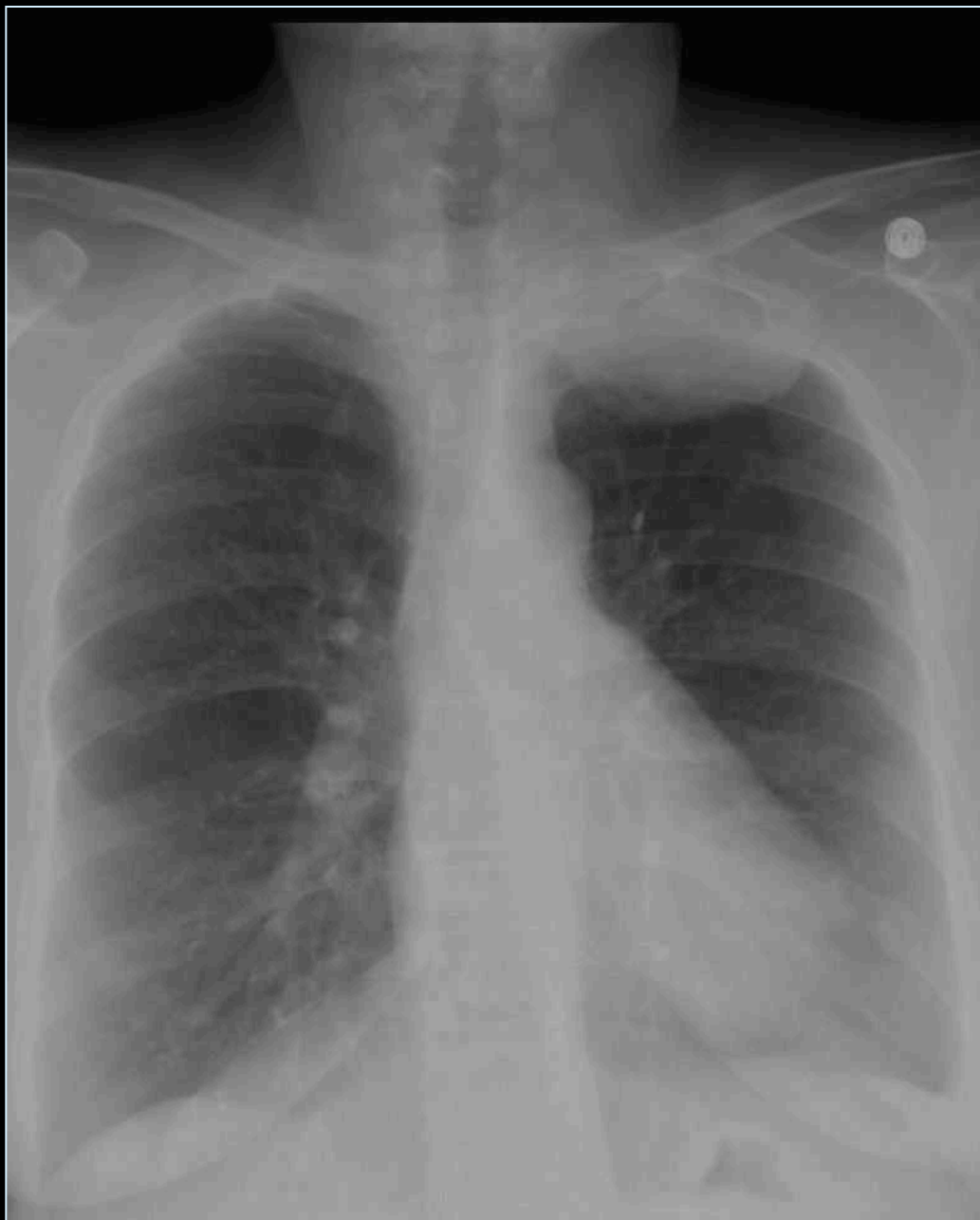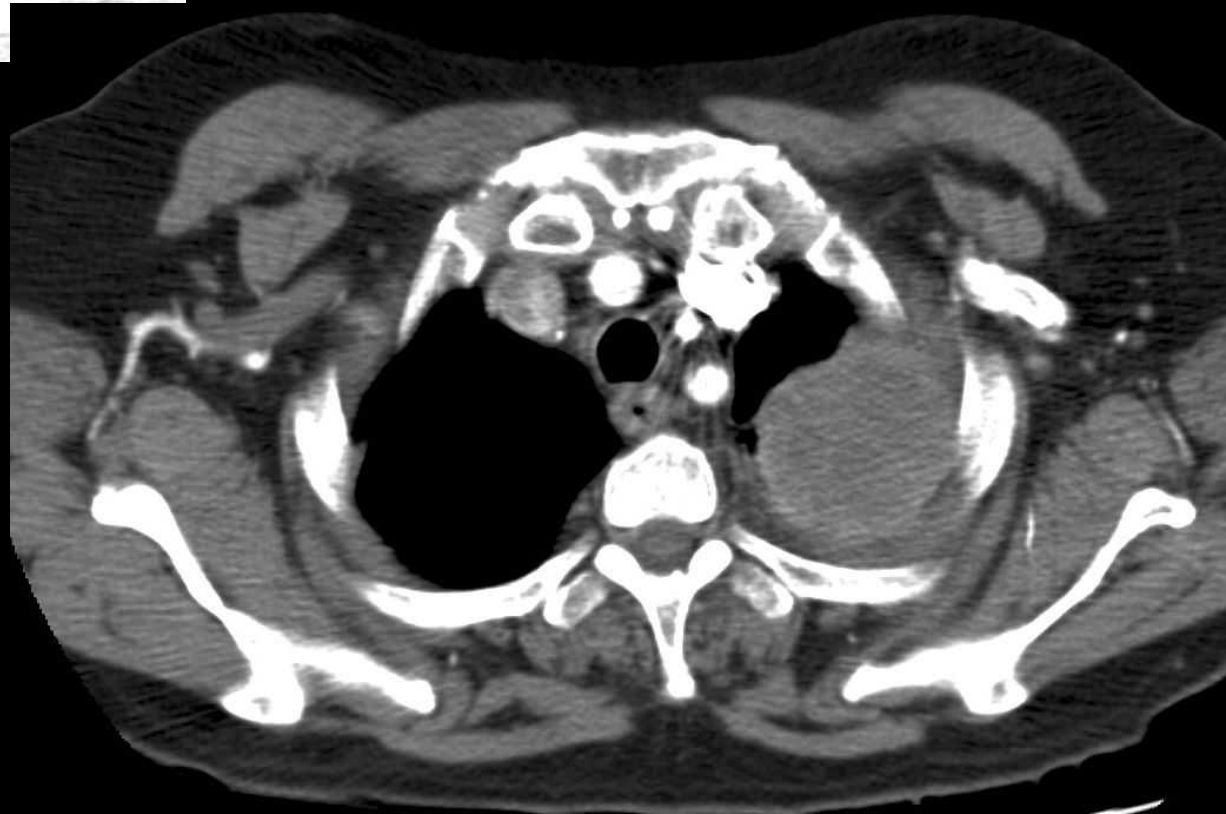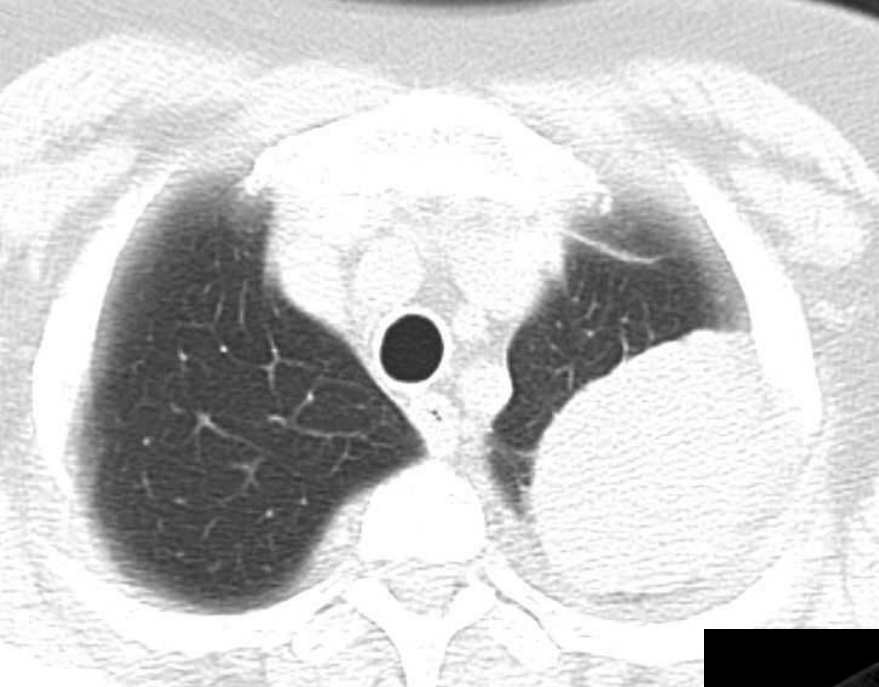


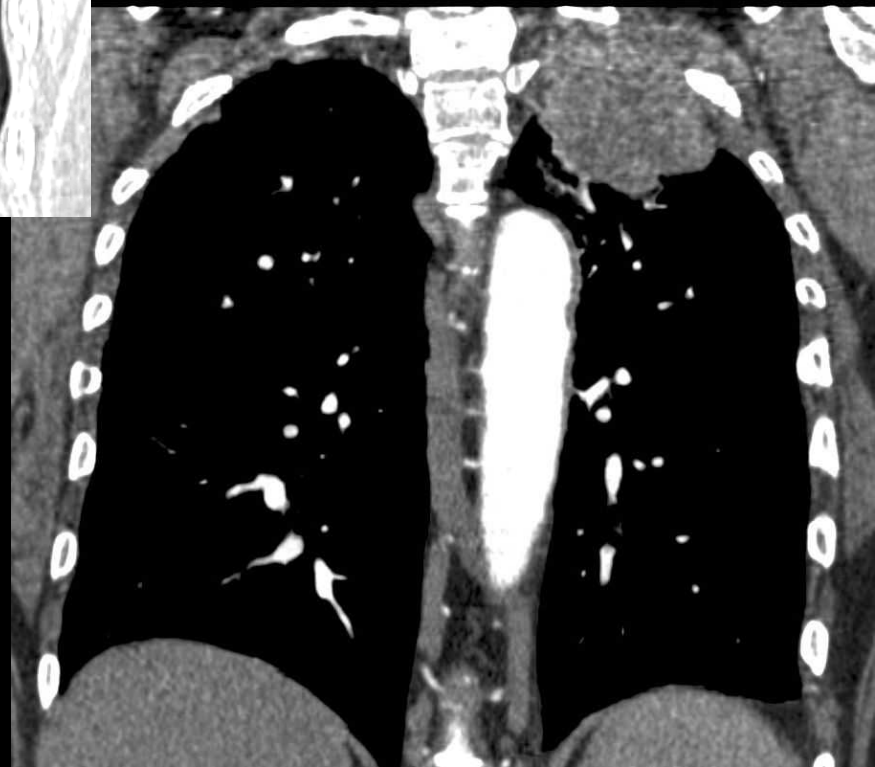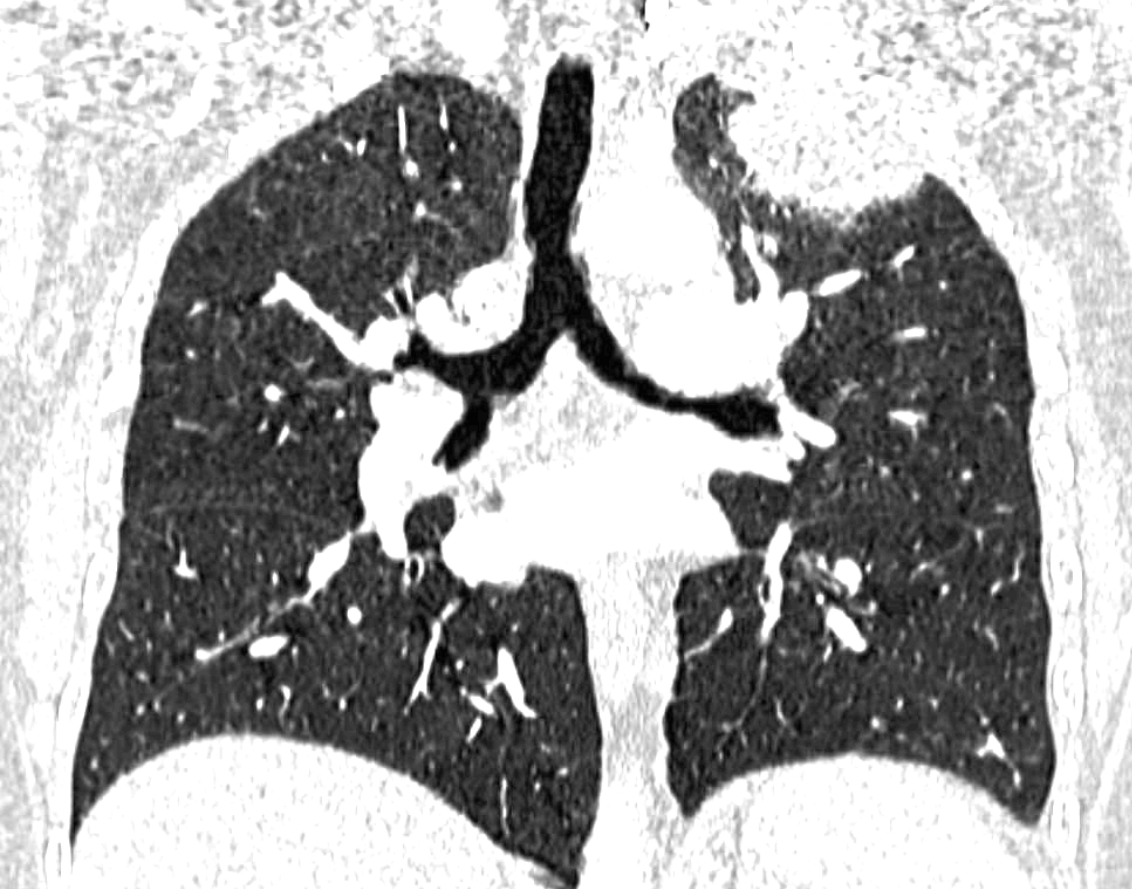Hernie diaphragmatique

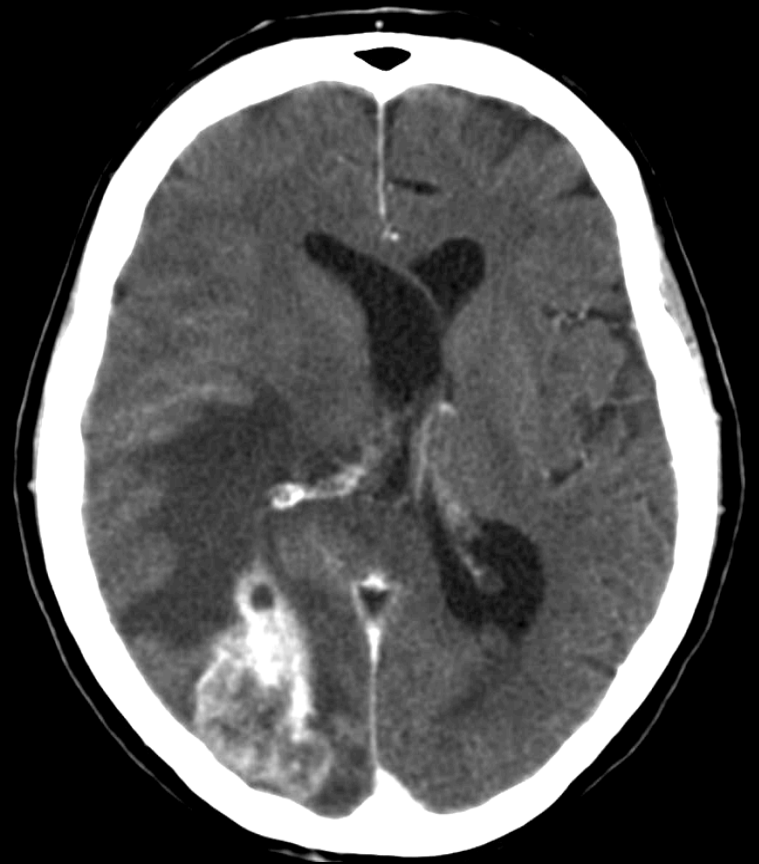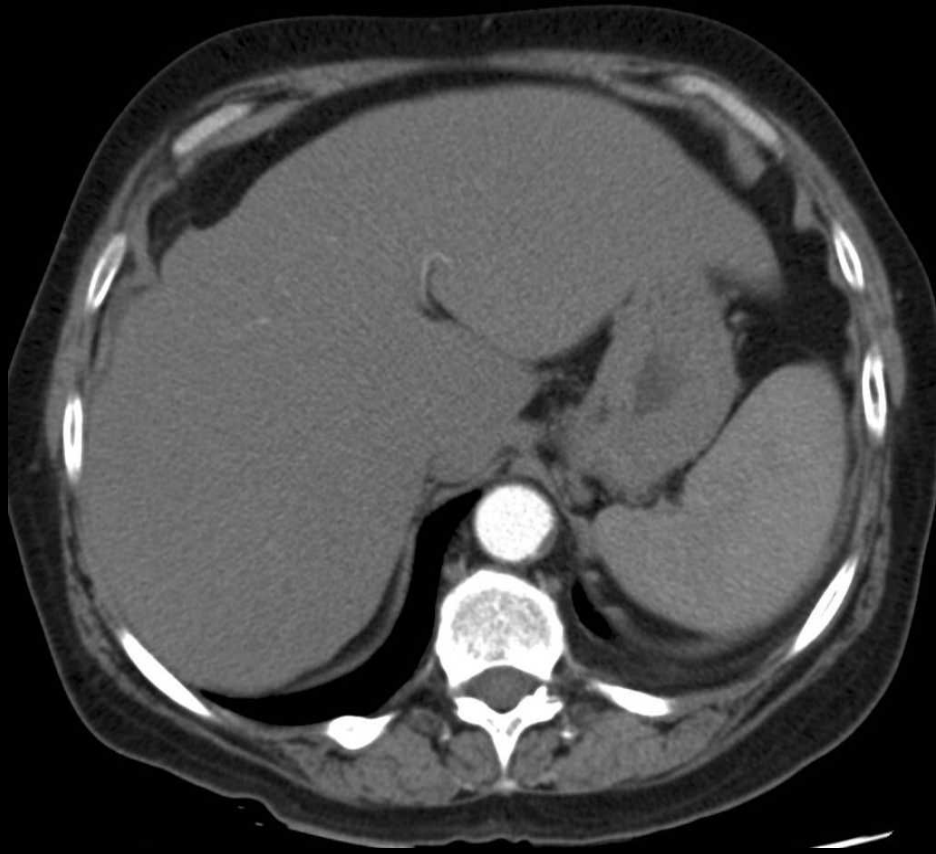
IRP

N°17

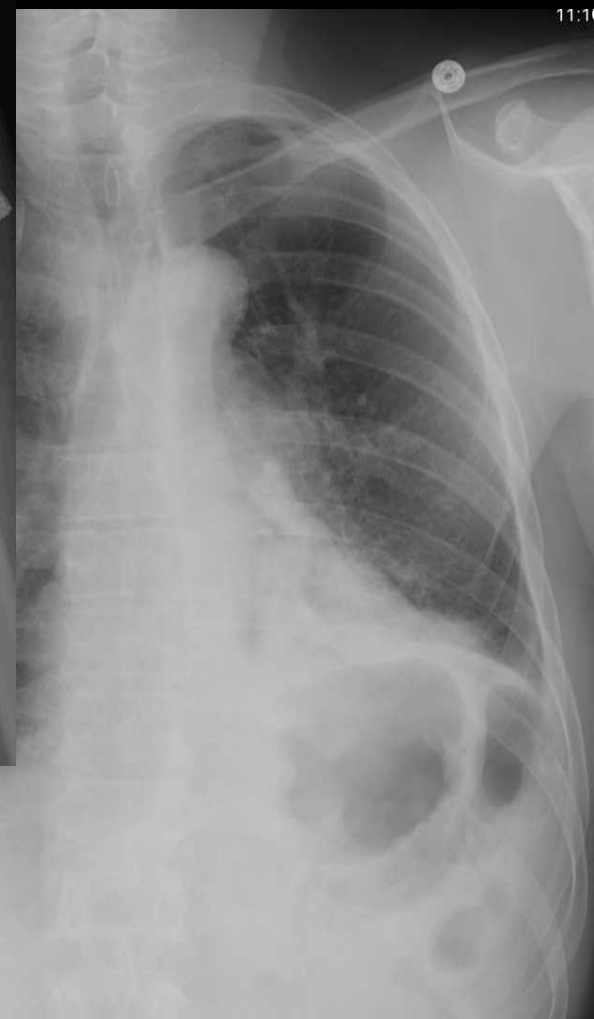
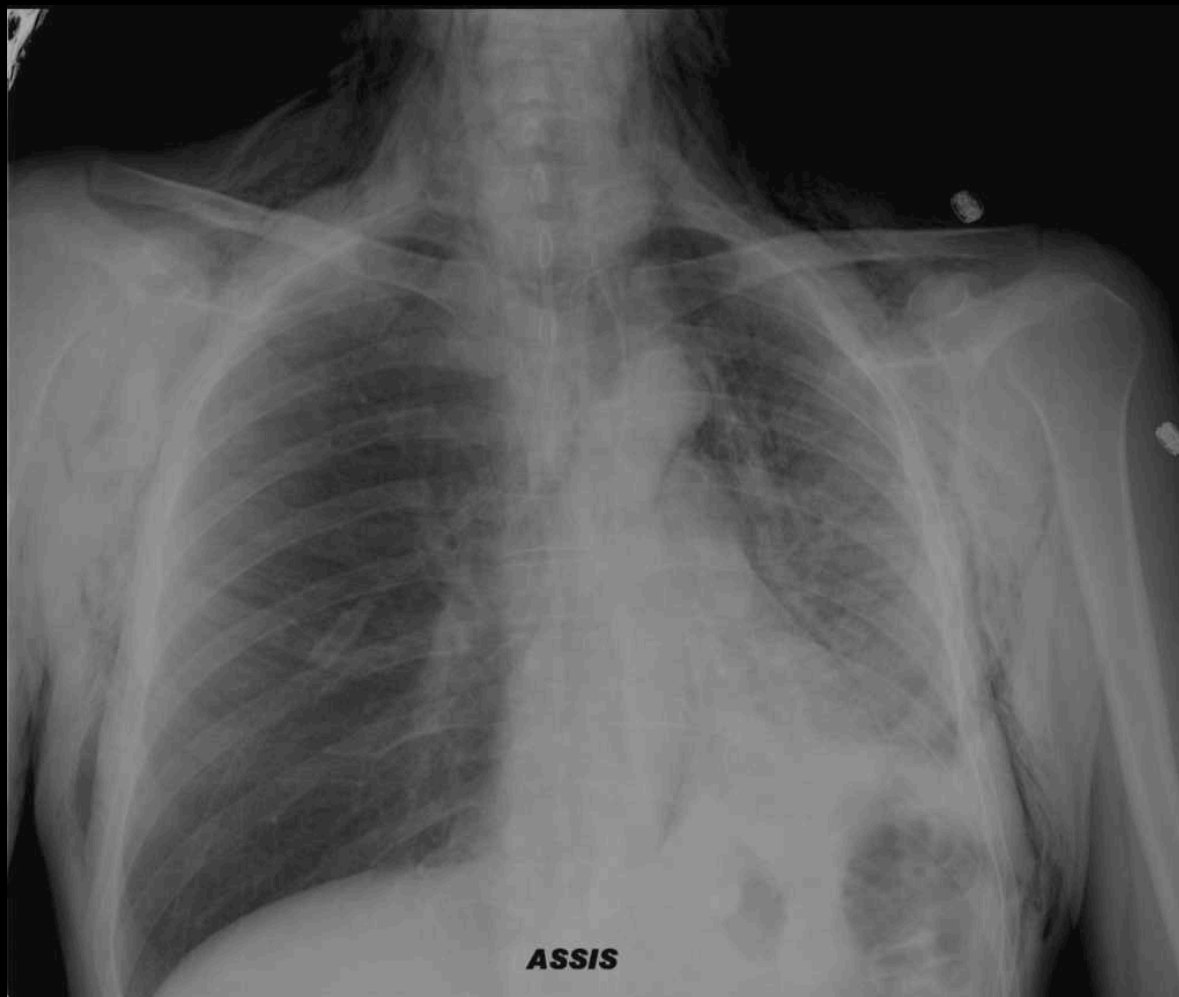




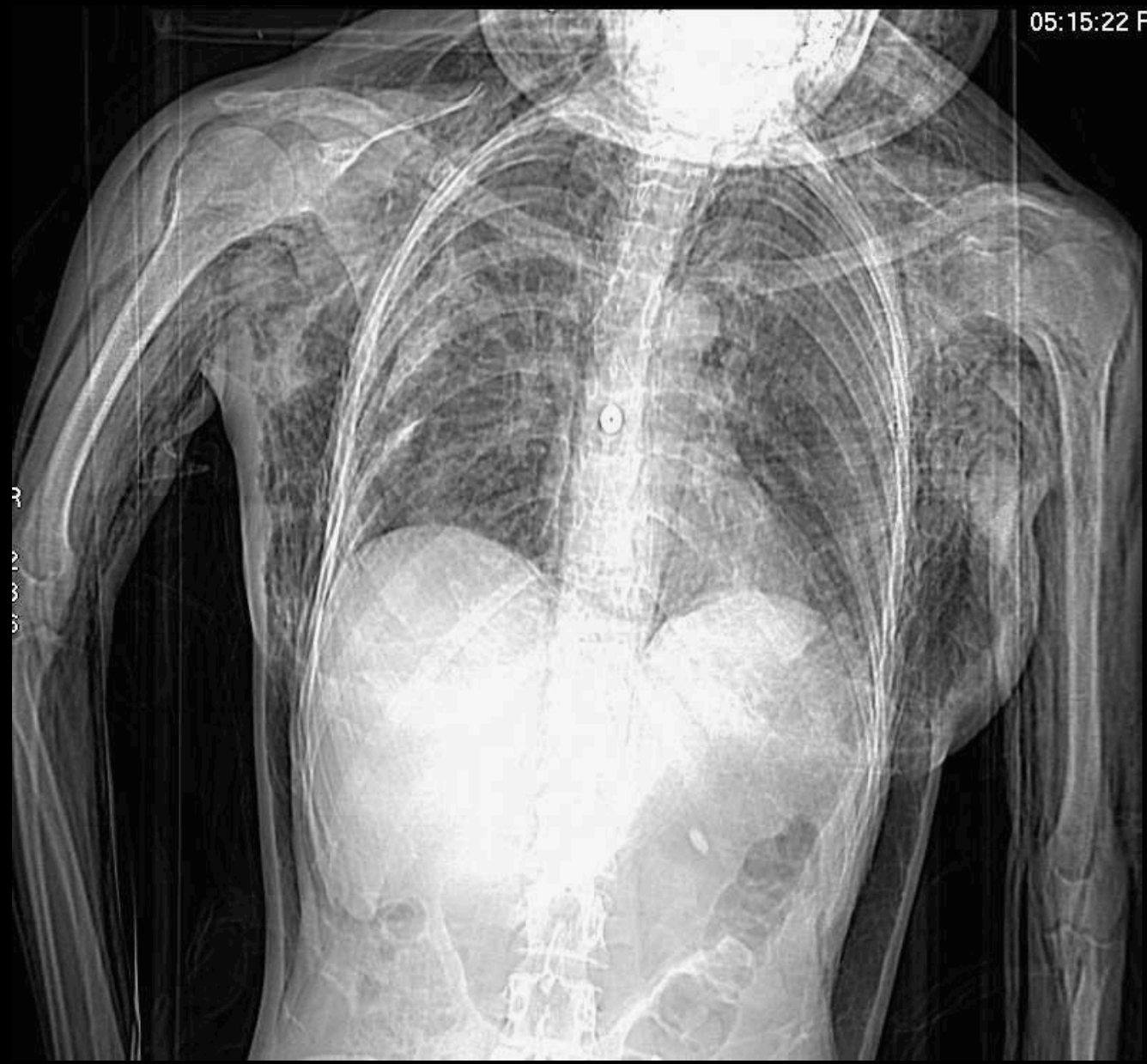

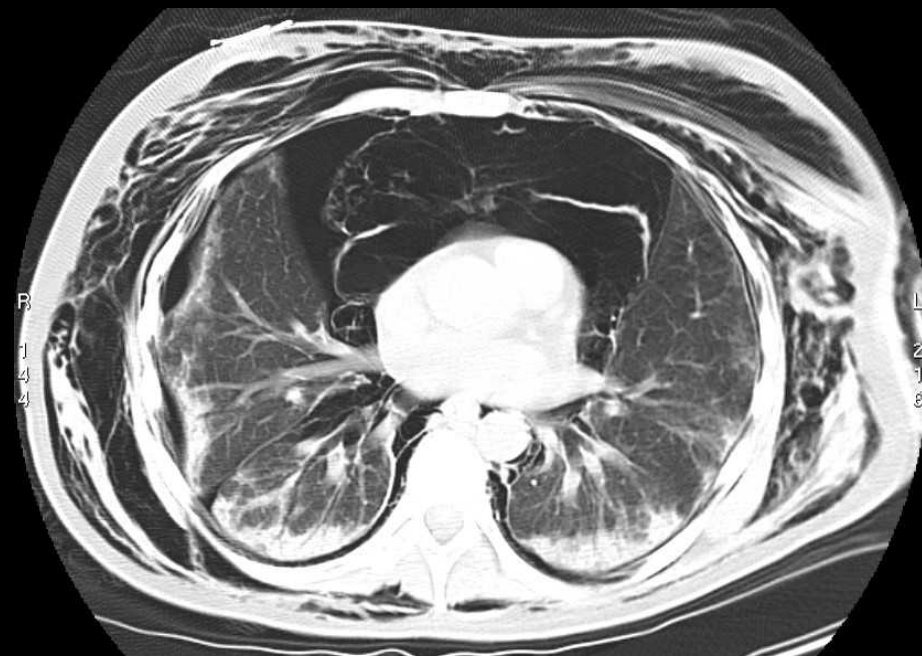
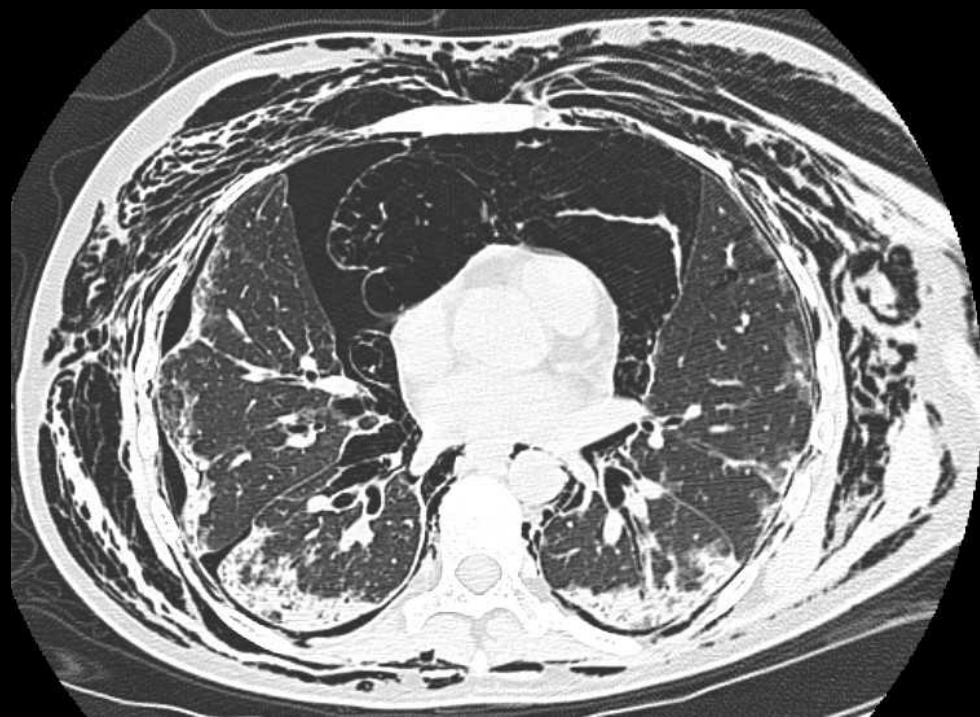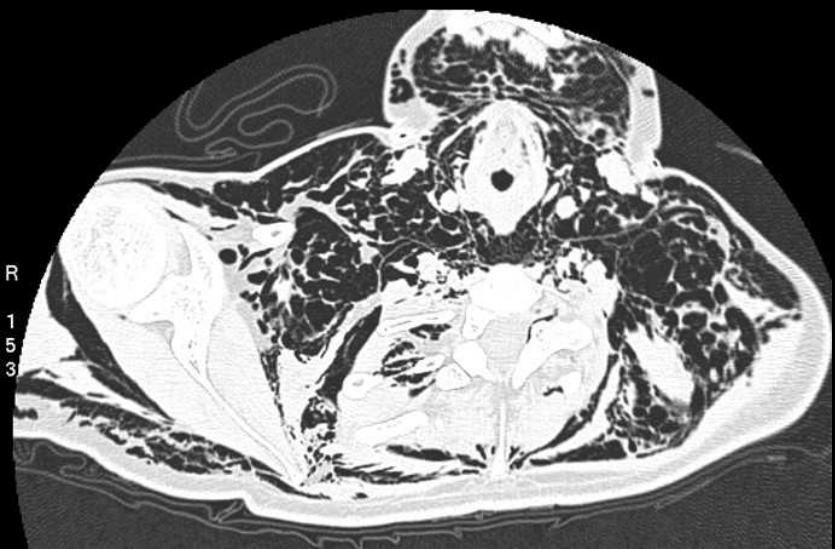
N°18



05:15:22 PM

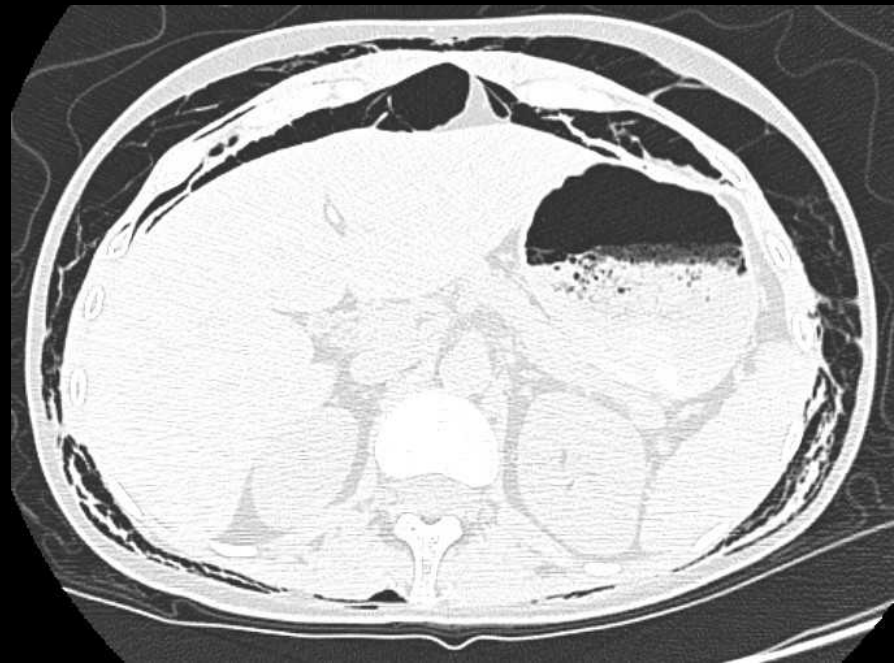

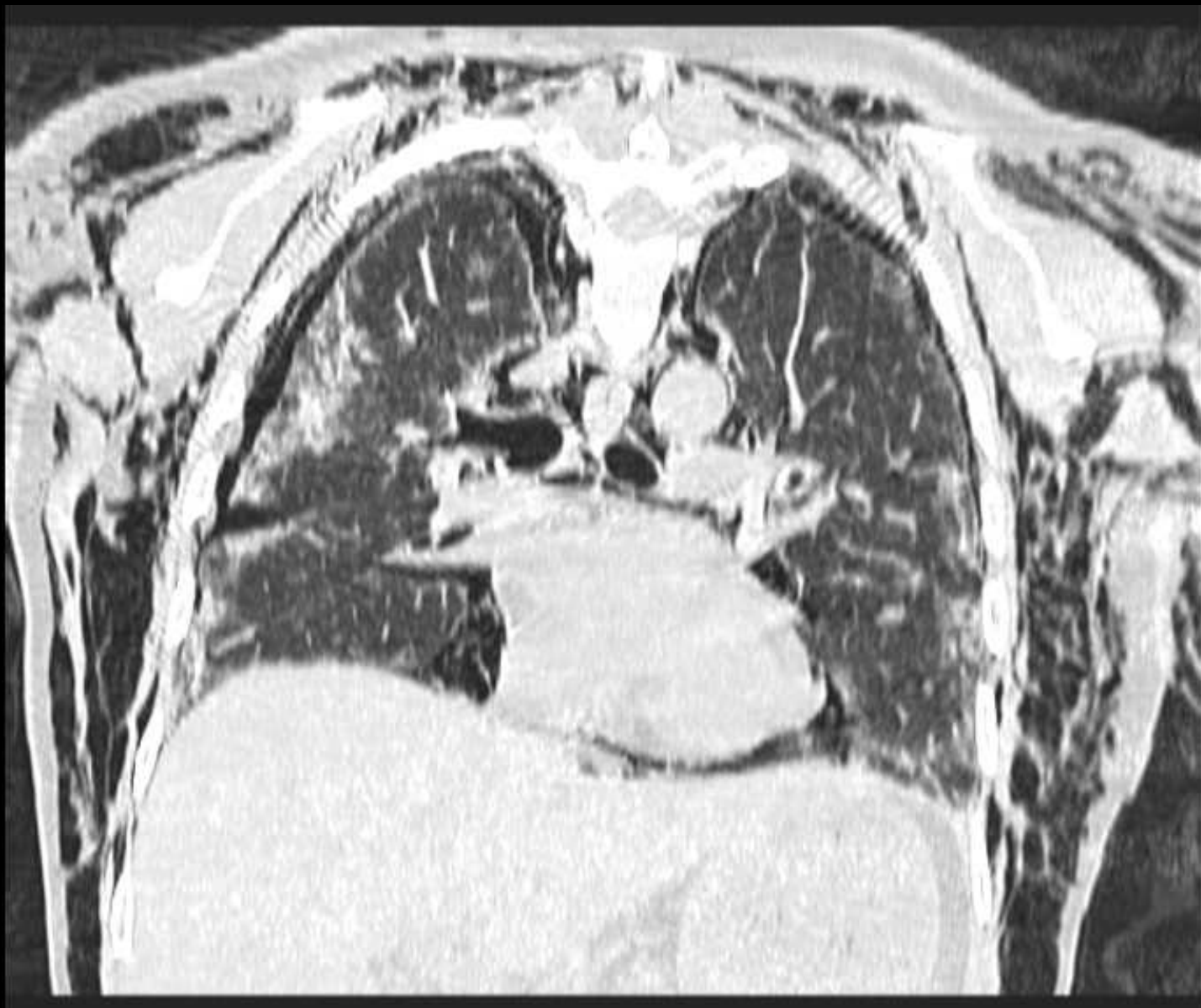
R
1
5
3



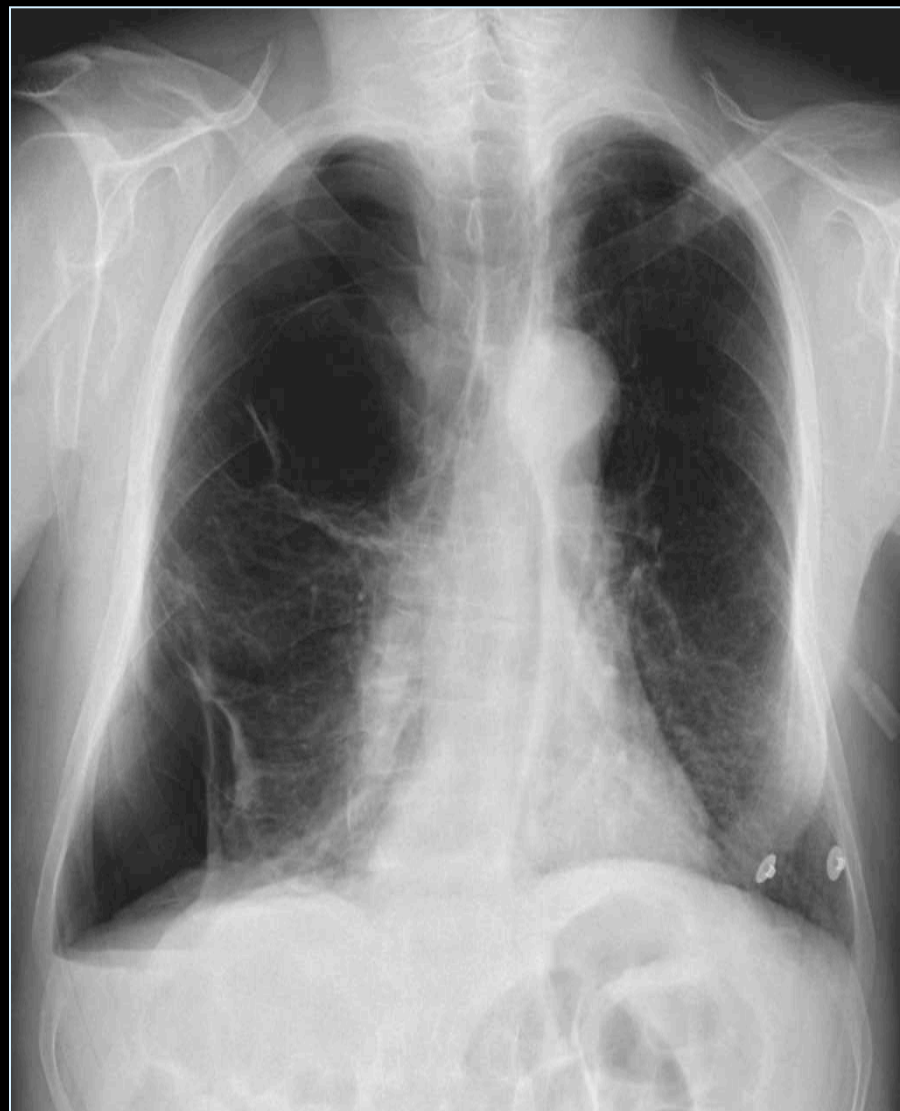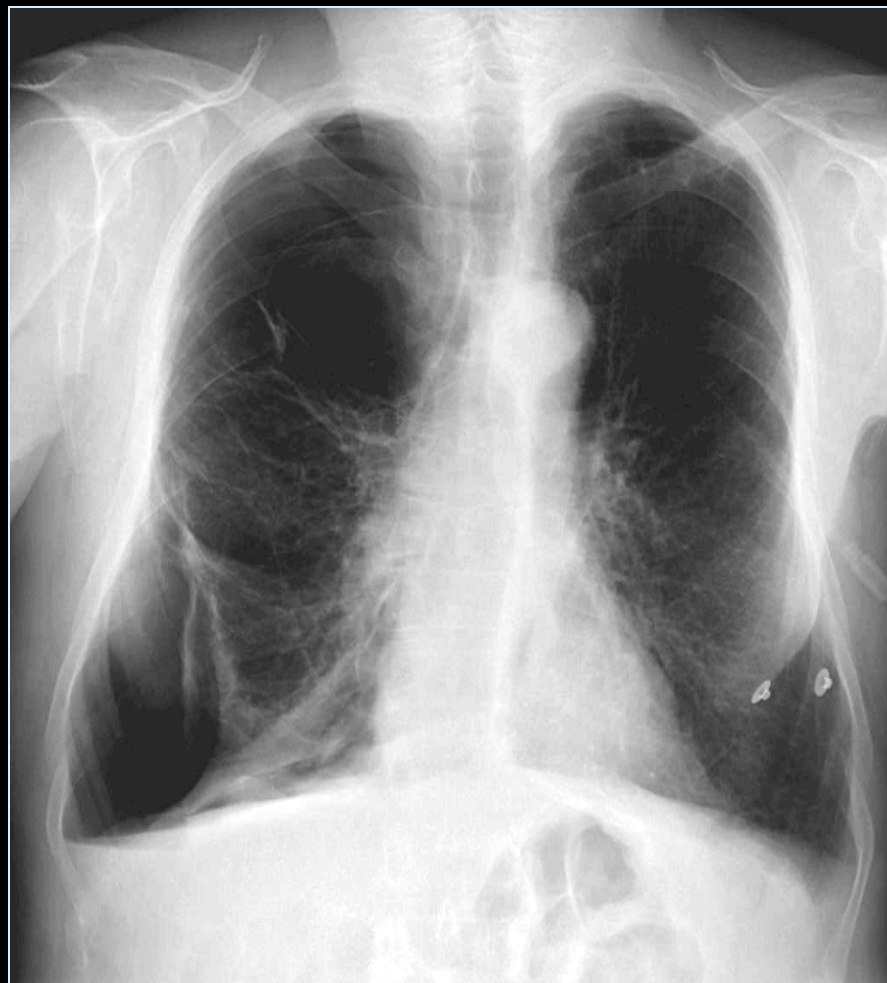R
1
4
4

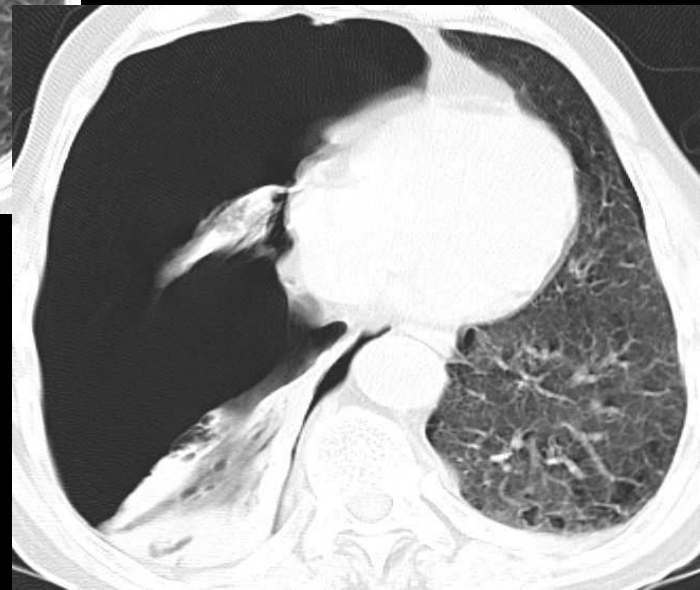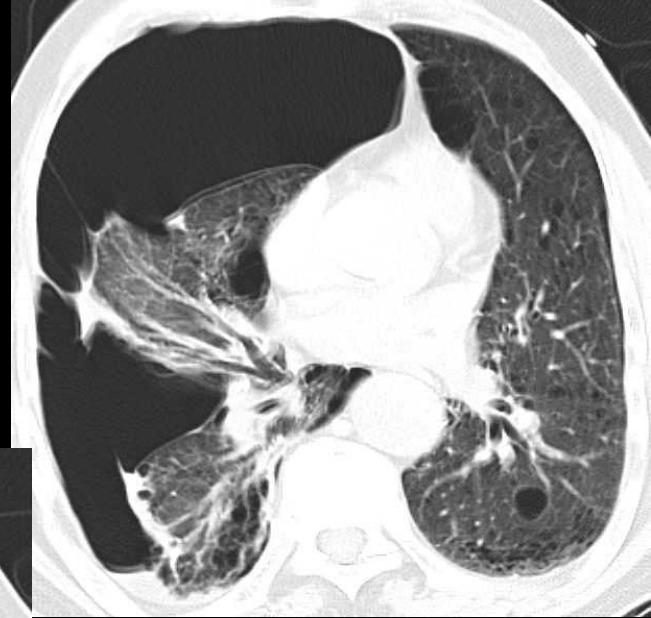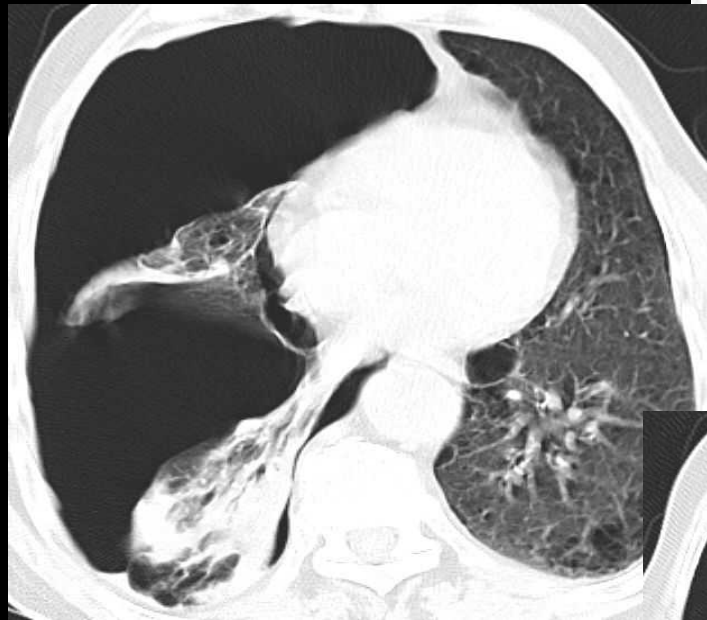
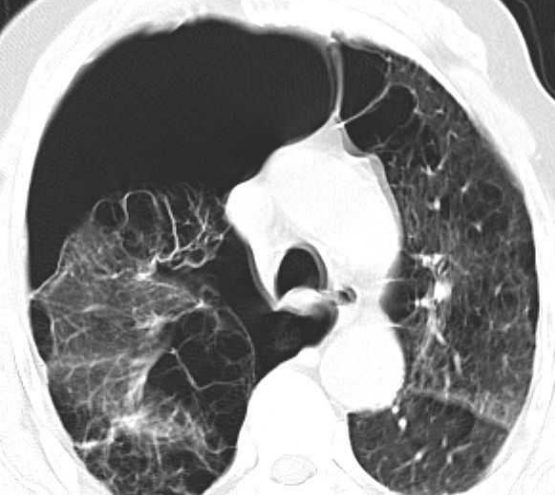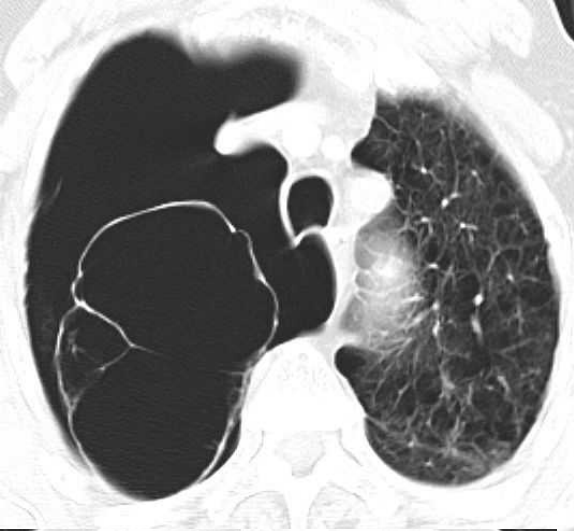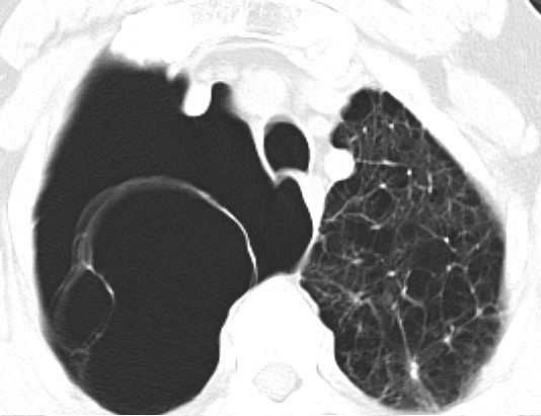
L
2
1
8





N°19



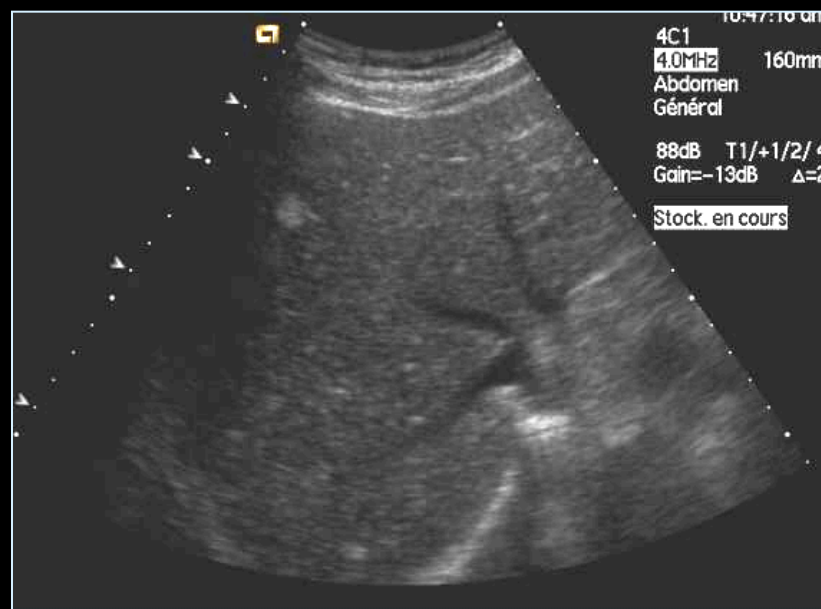
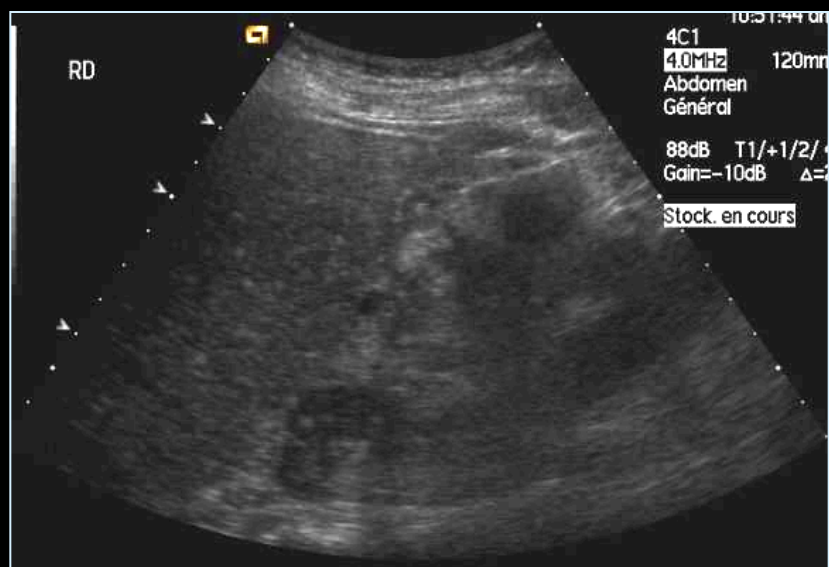
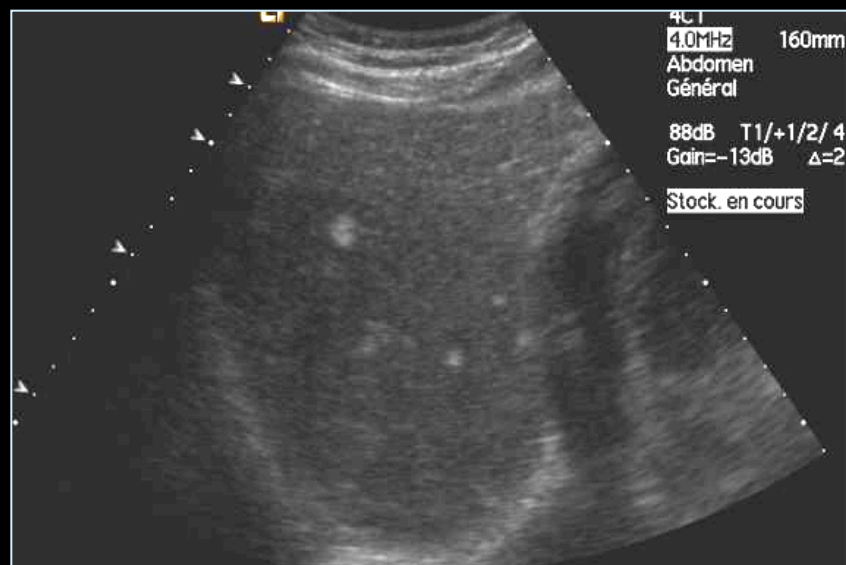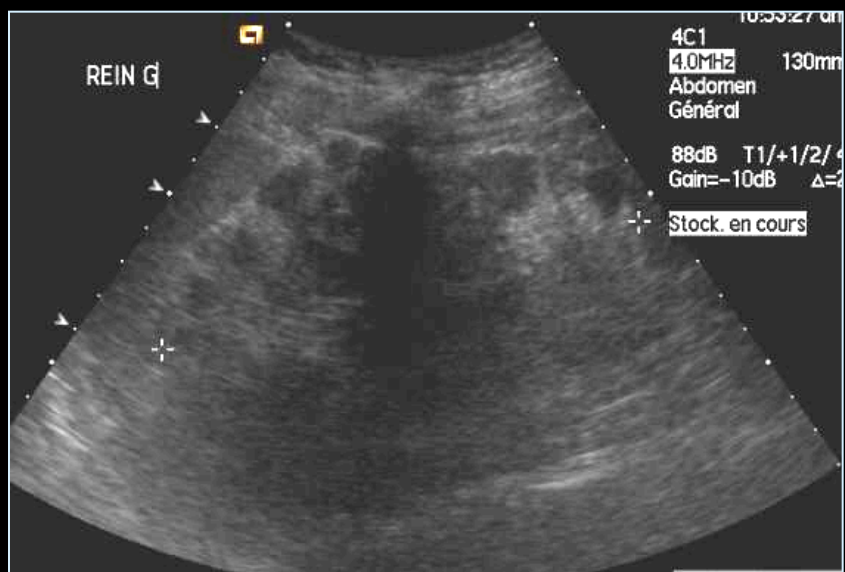Femme de 40 ans

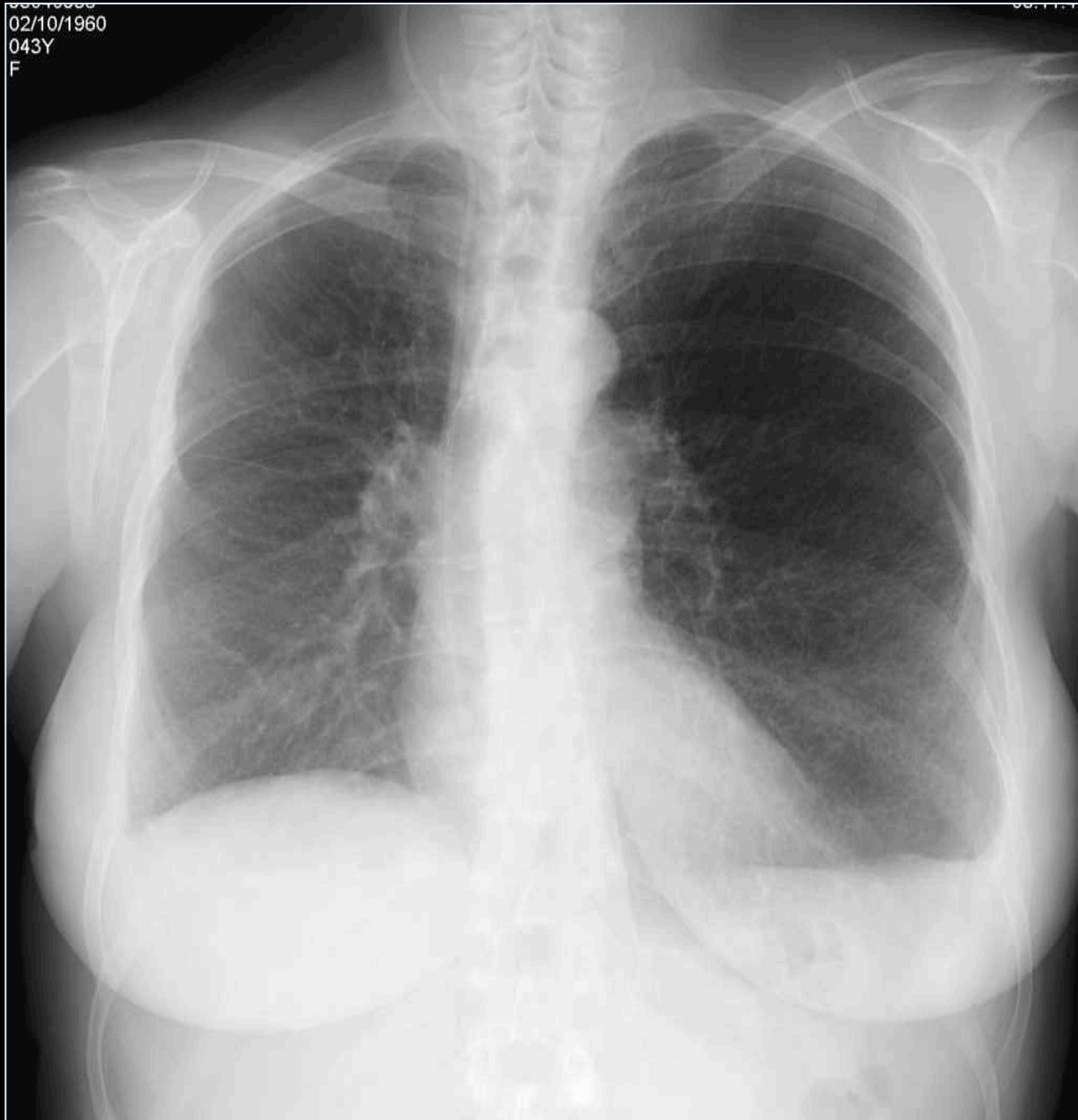
Surveillance après greffe pulmonaire D en 1998

Pas de symptomatologie clinique

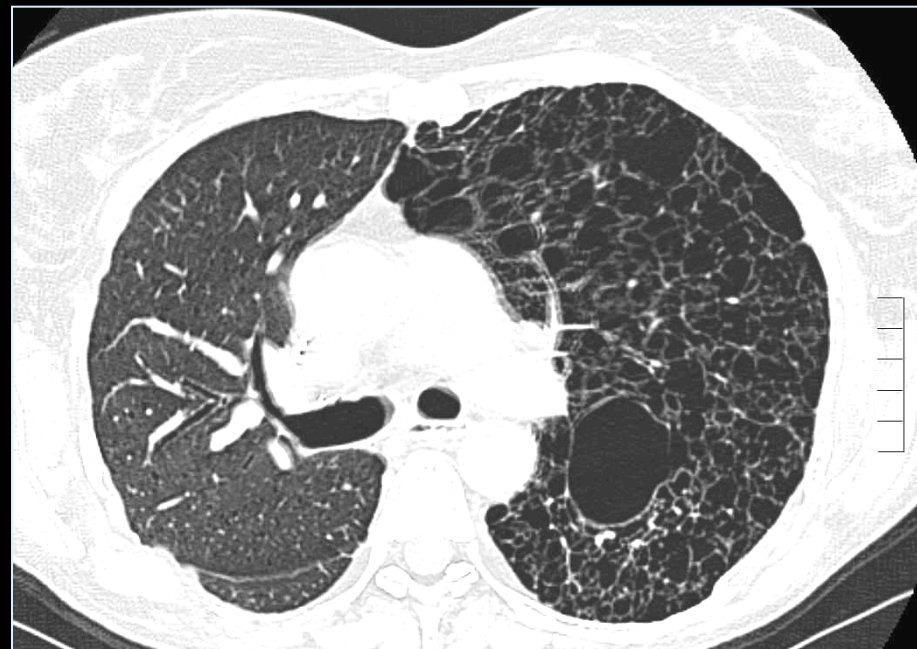
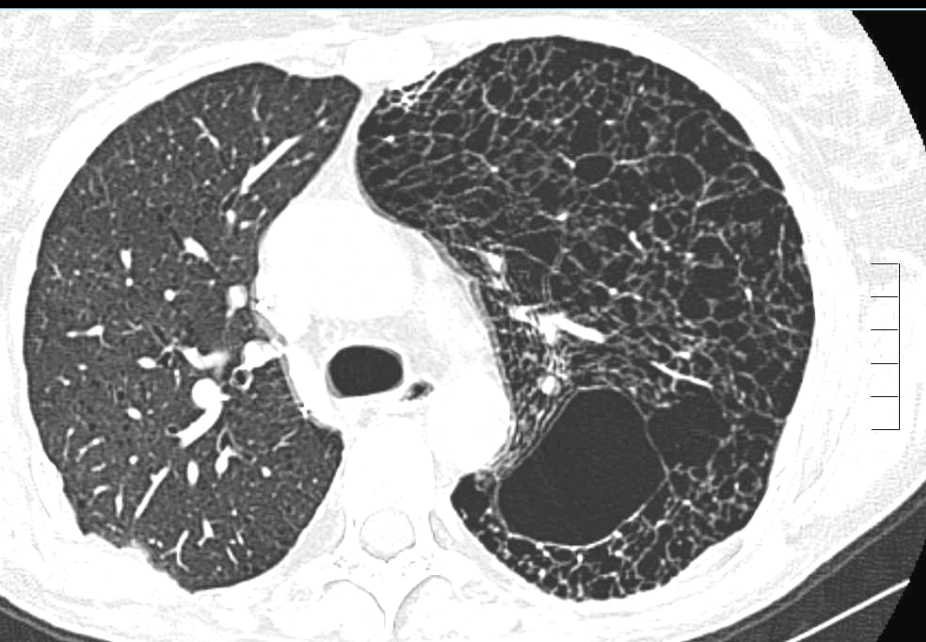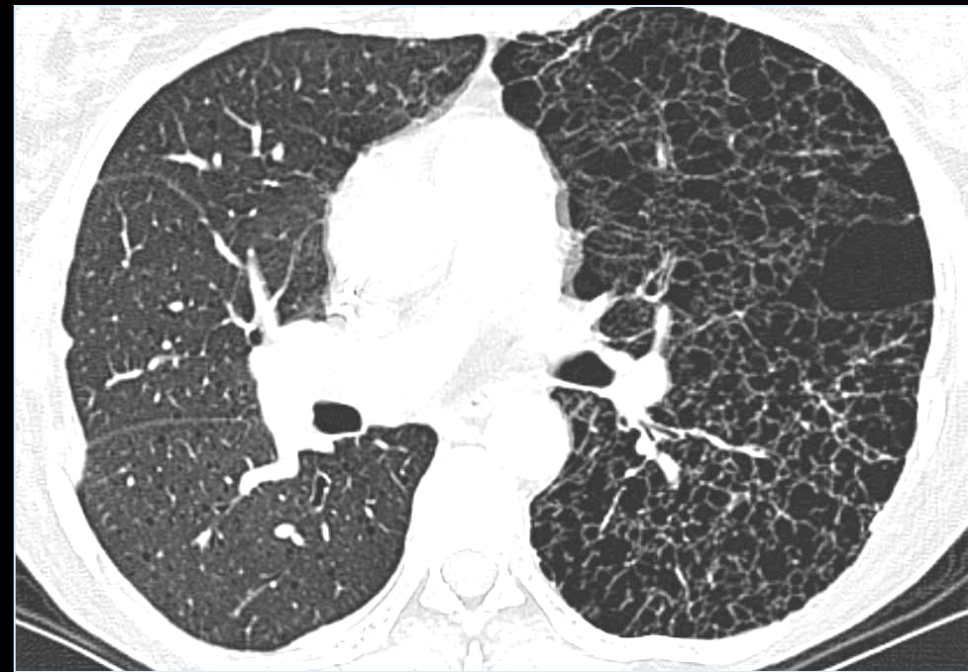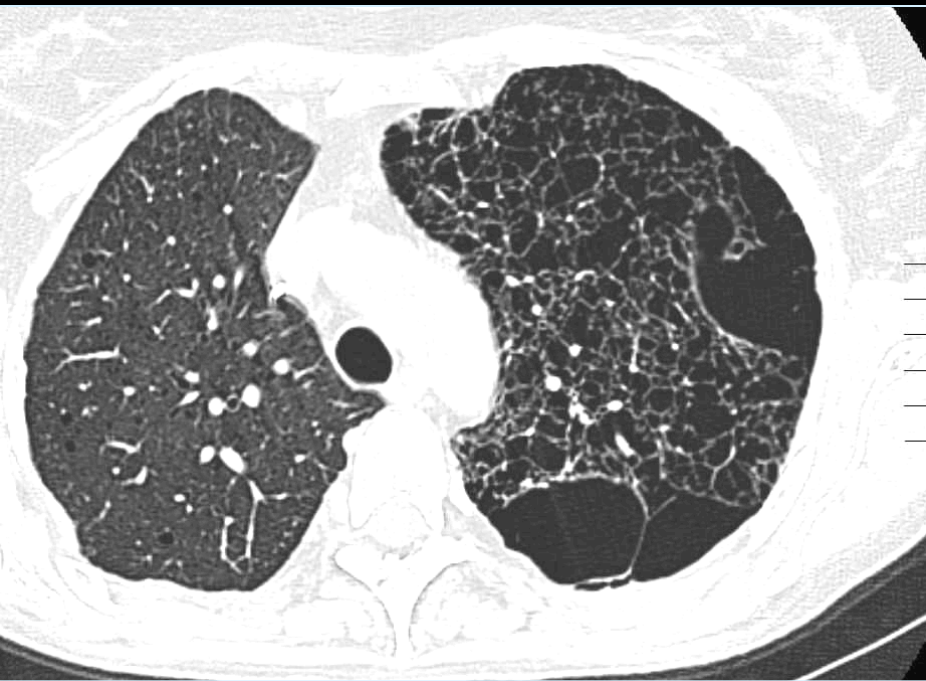
Échographie abdominale



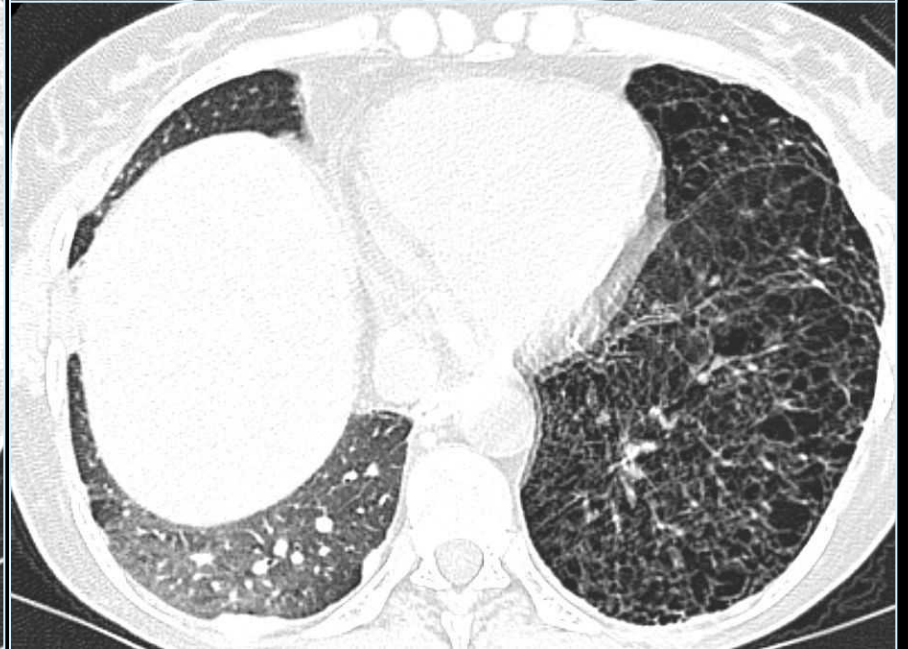
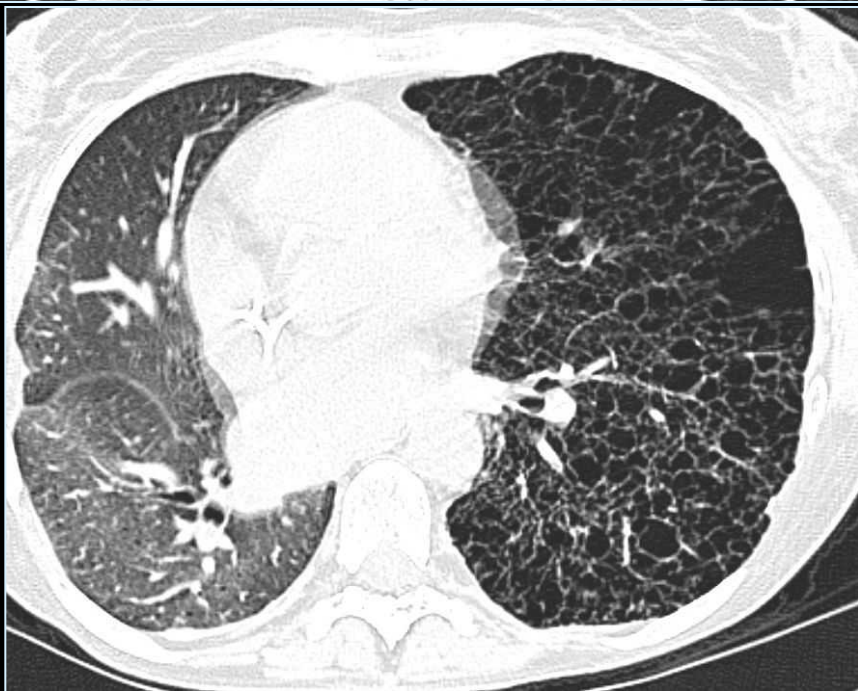
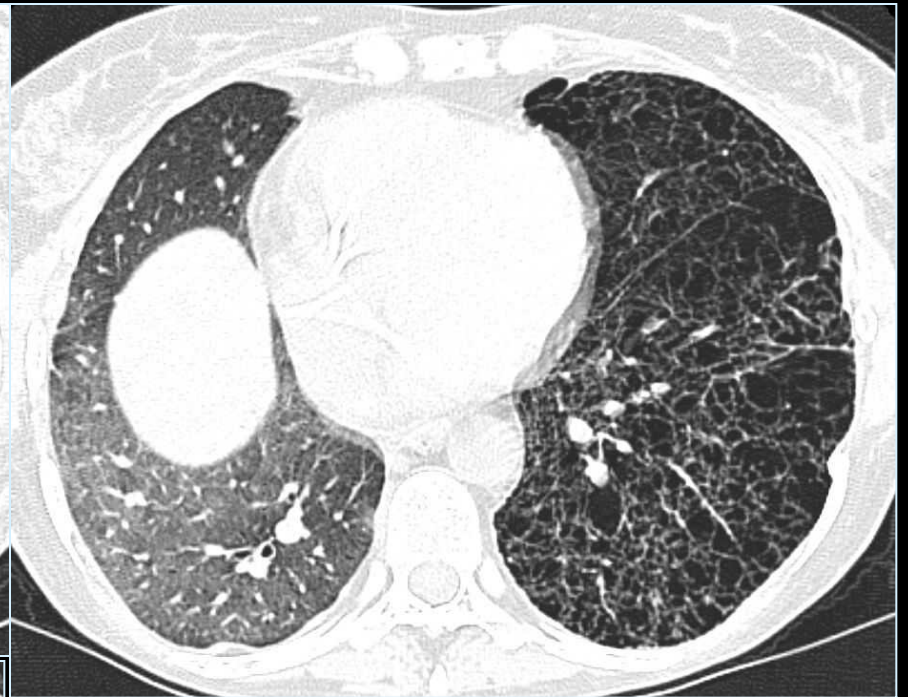
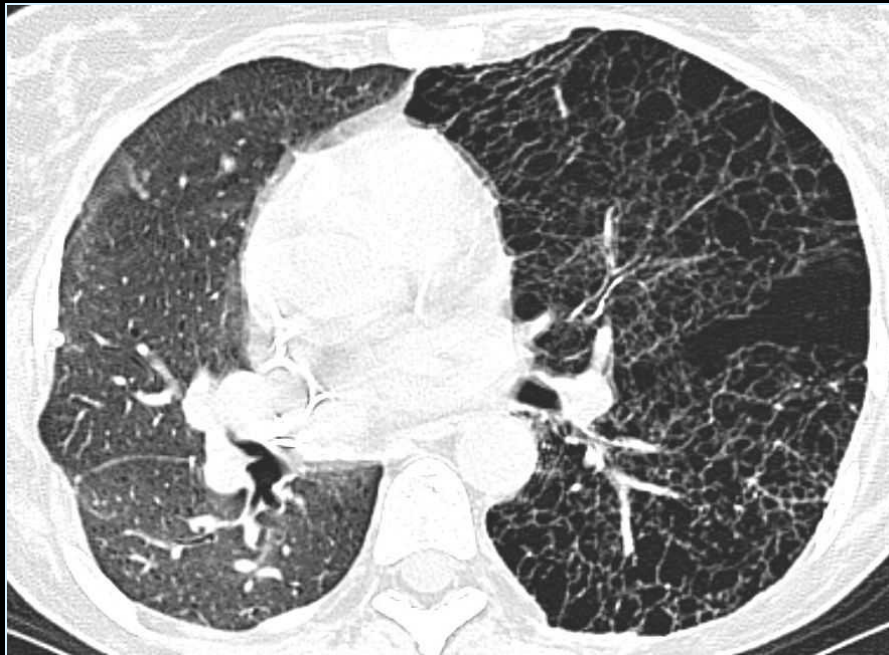
Surveillance après greffe pulmonaire D en 1998
Pas de symptomatologie clinique



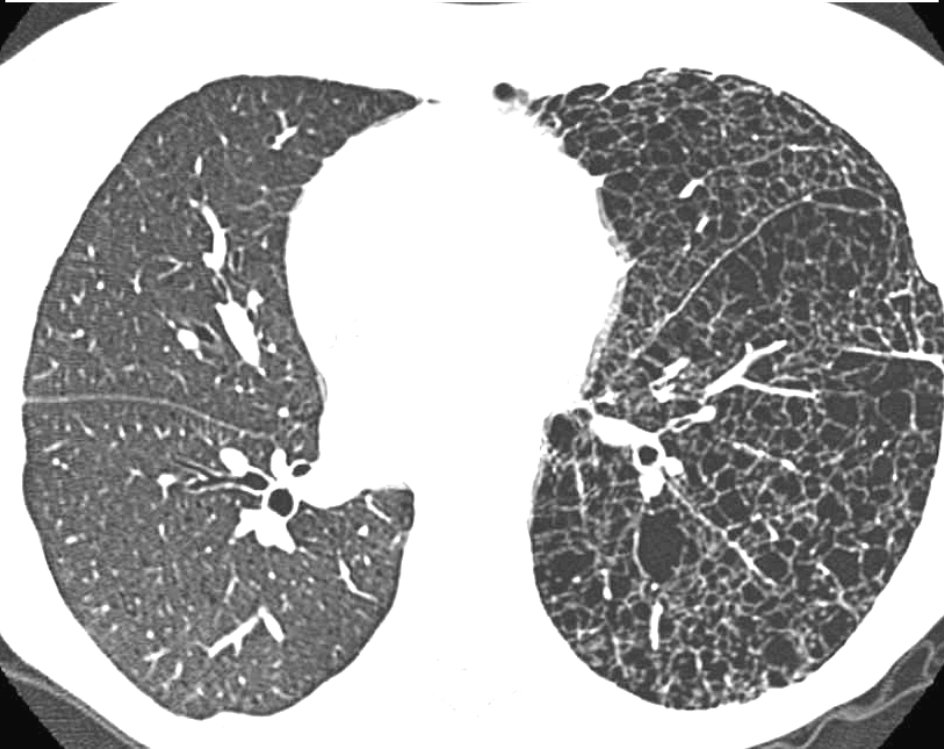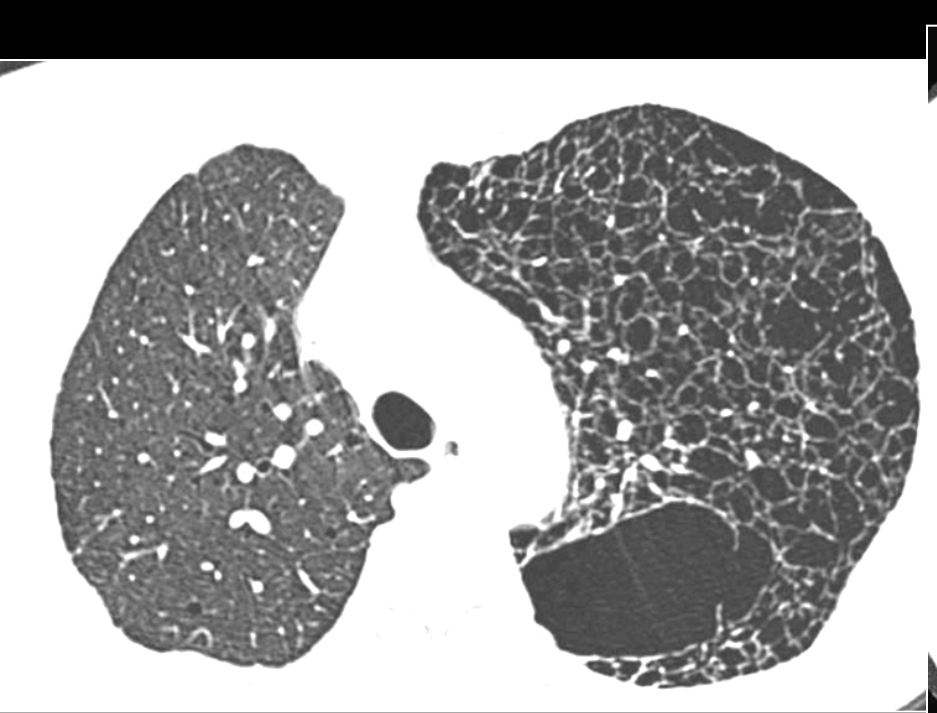
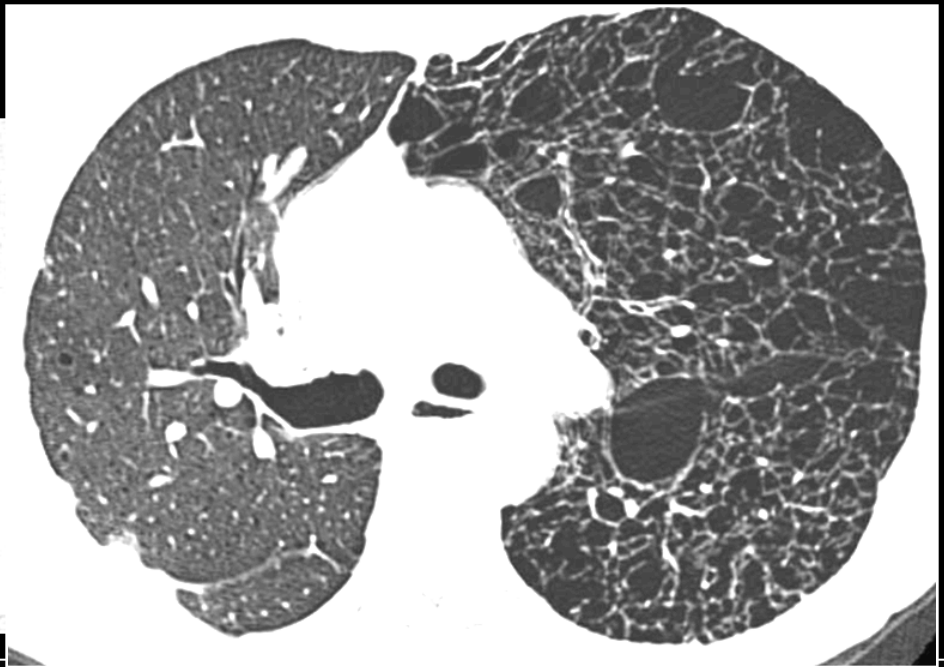
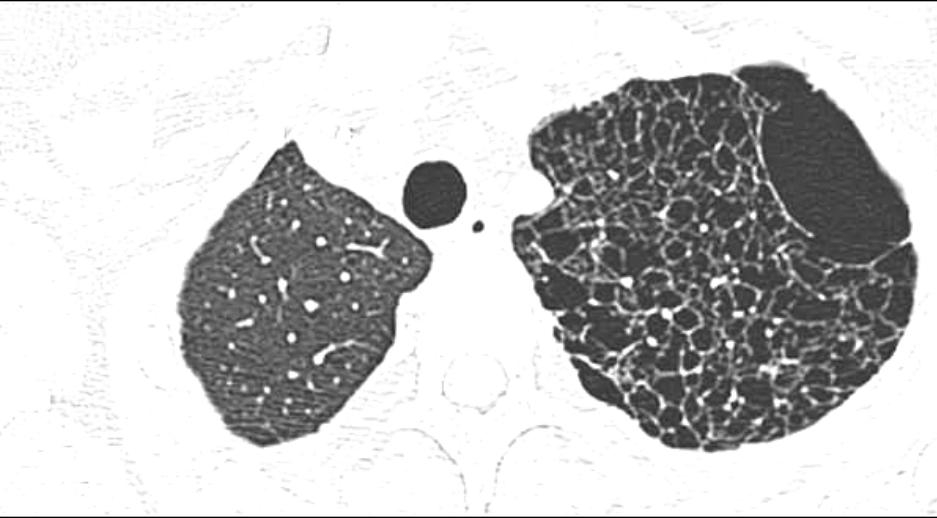
TDM INSPIRATION

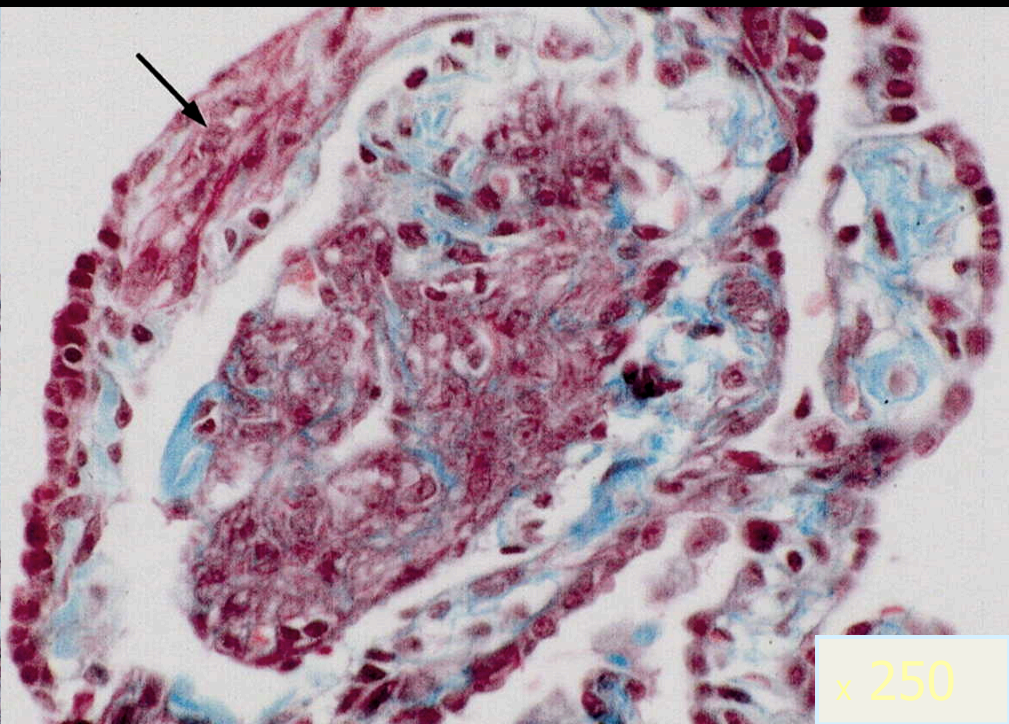
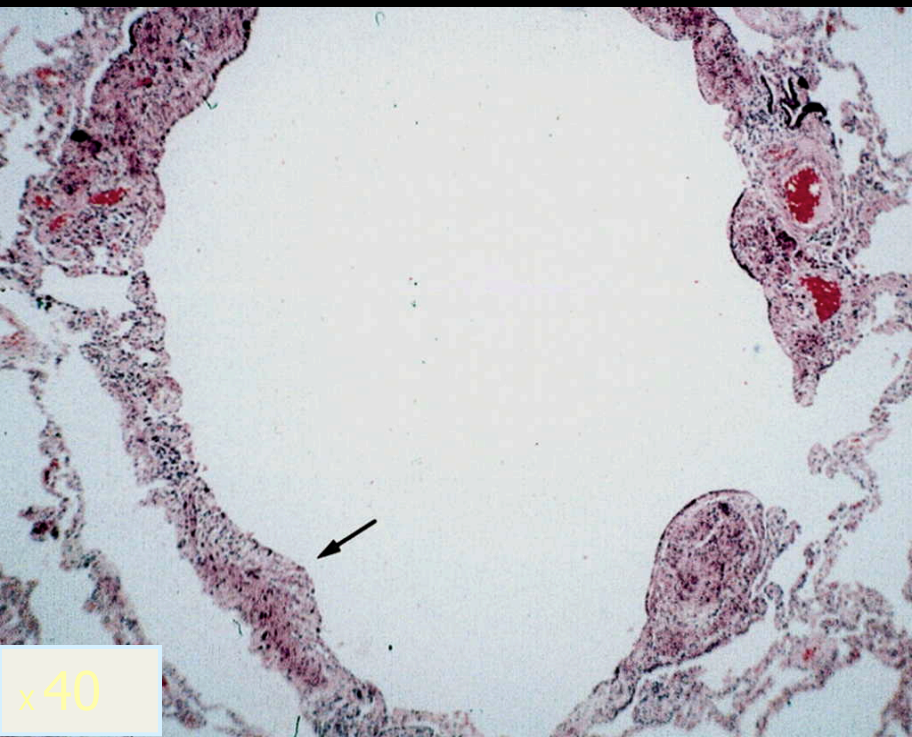


TDM EXPIRATION




TDM il y a 6 mois

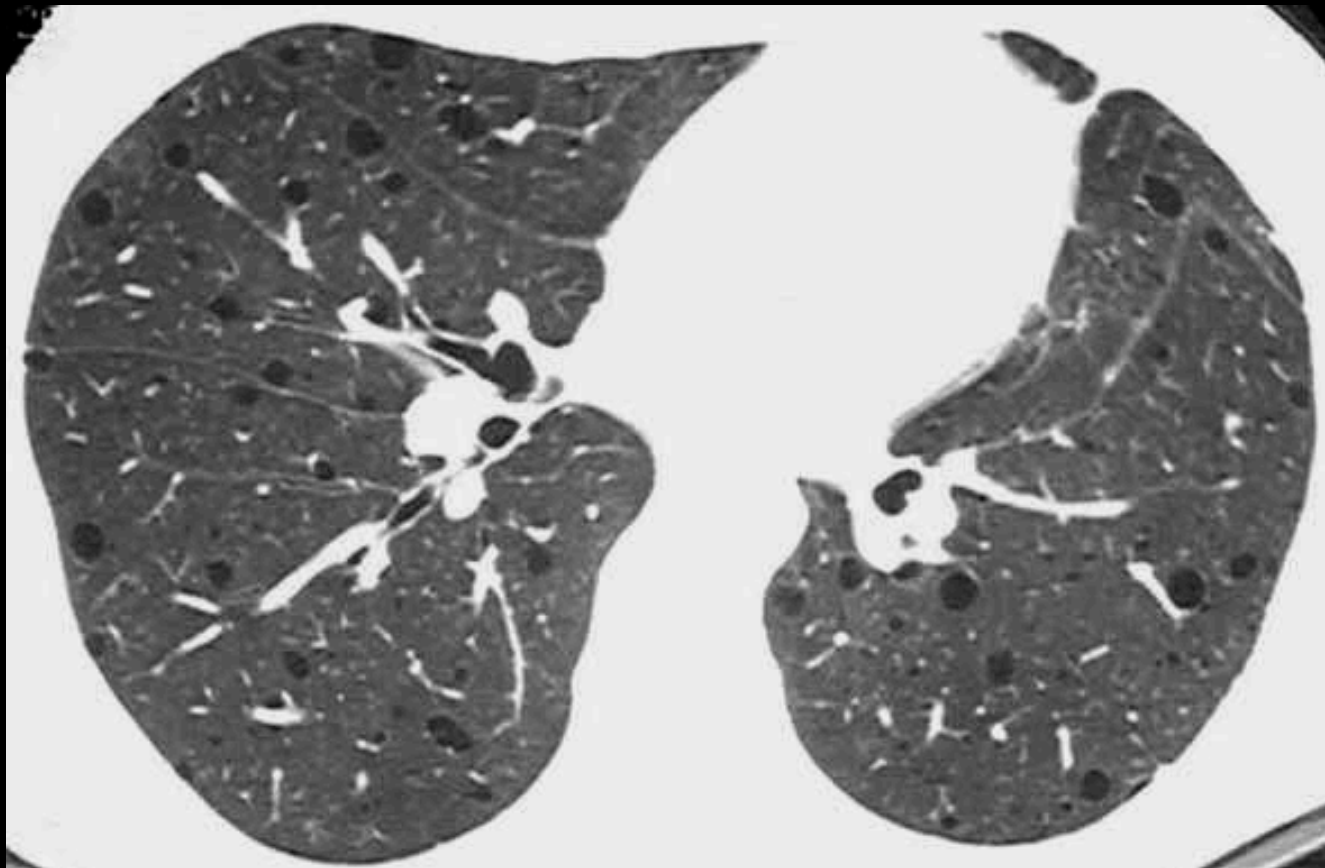




- Elargissement des espaces aériens alvéoles - bronchioles
- Épaississement des parois infiltrations par des cellules musculaires lisses anormales le long des canaux lymphatiques



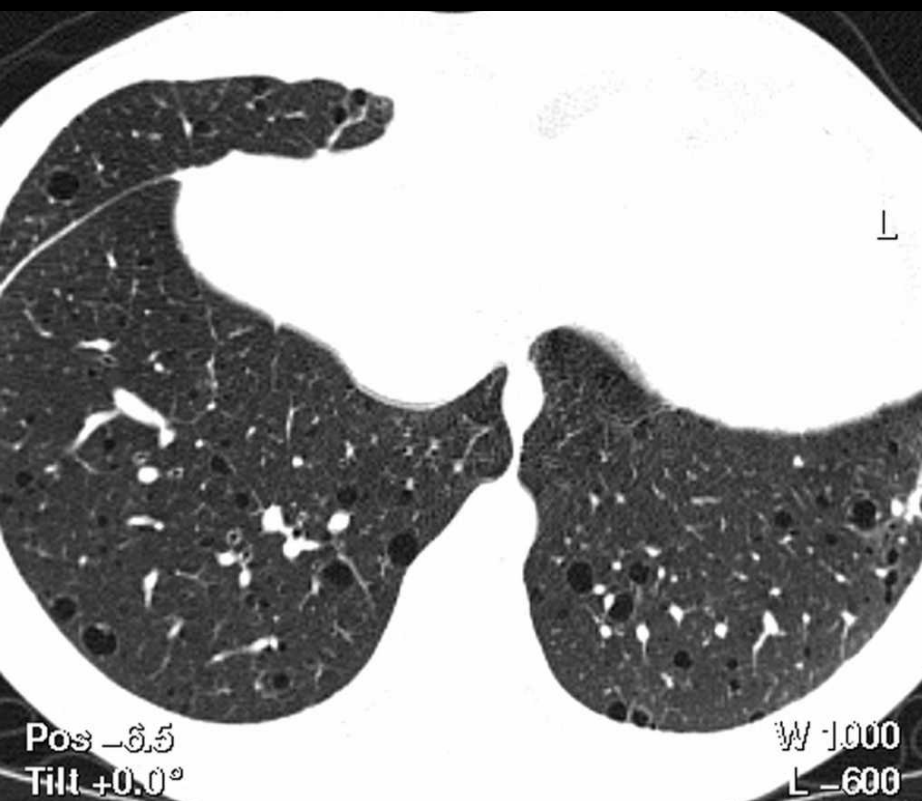obstruction bronchiolaire et formations de kystes



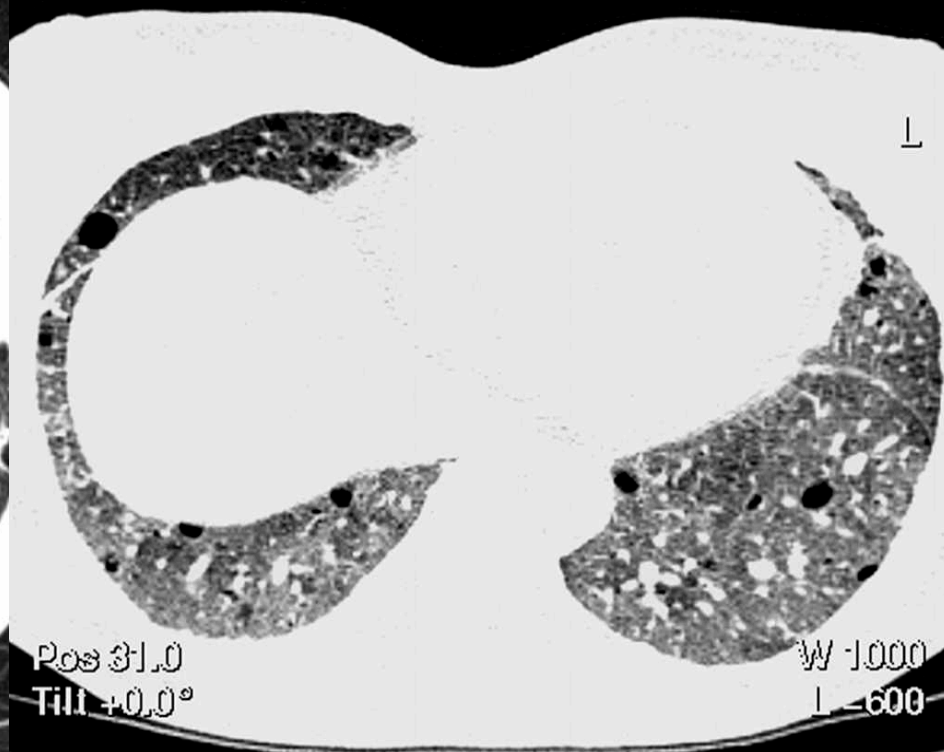
Kystes à parois fines réguliers et diffus

Parenchyme adjacent normal

inspiration



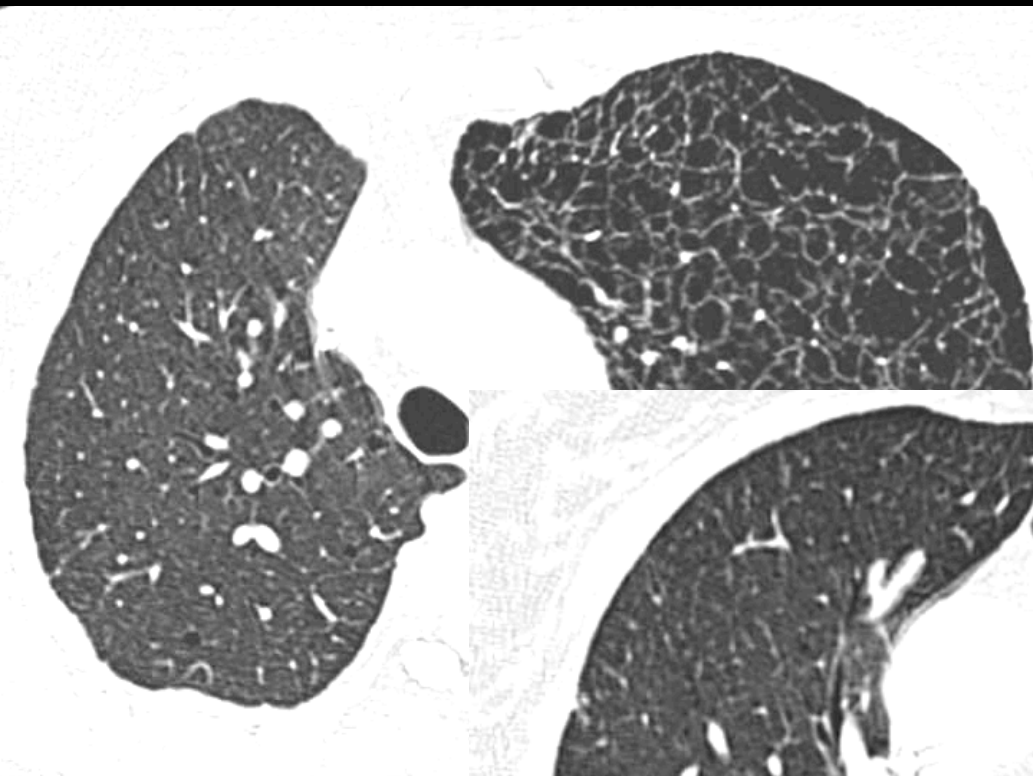
expiration



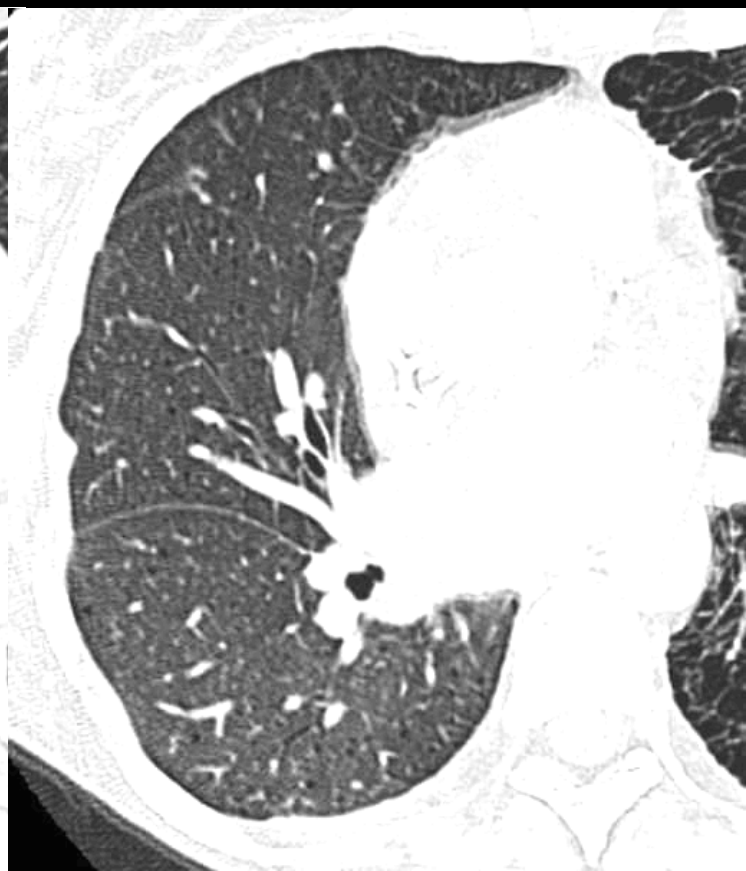
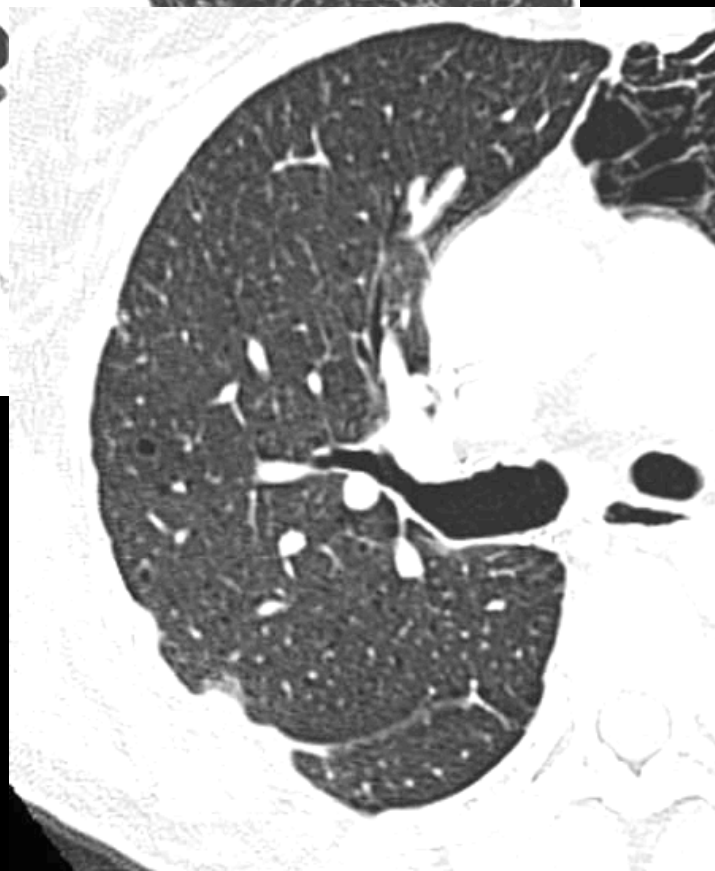
Kystes se vident peu

Le parenchyme restant est normal

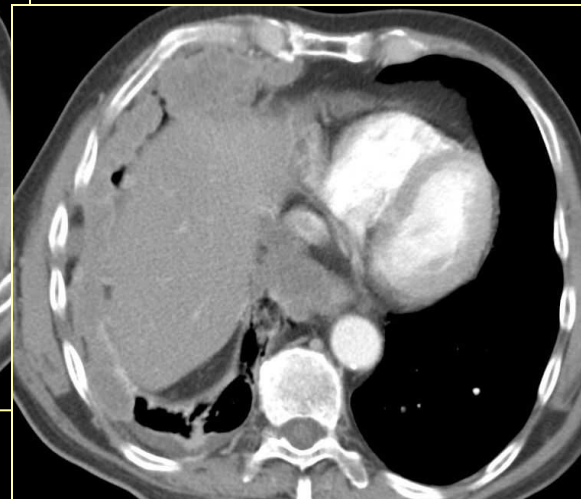
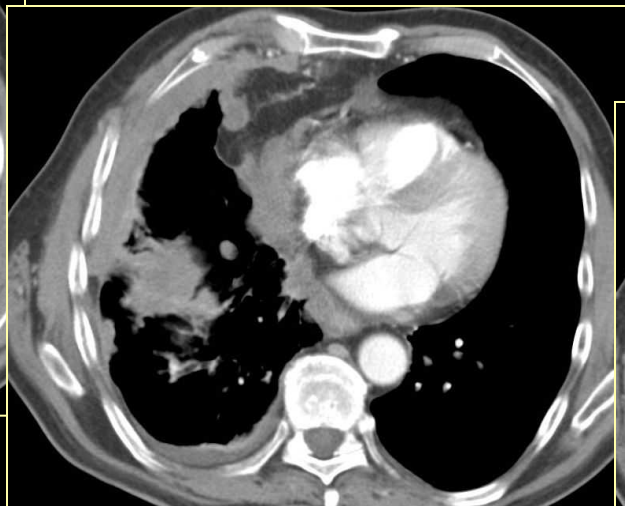
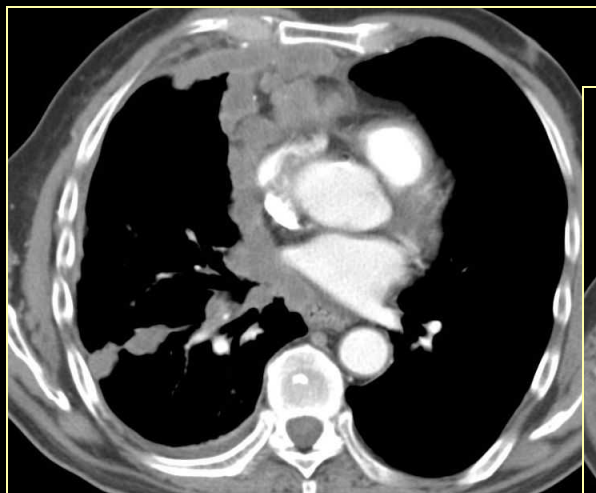
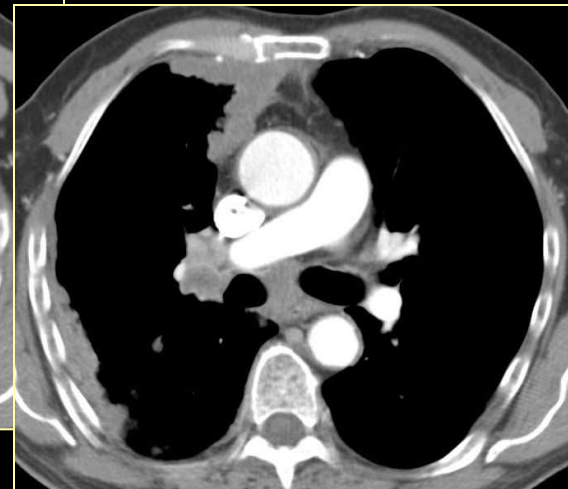
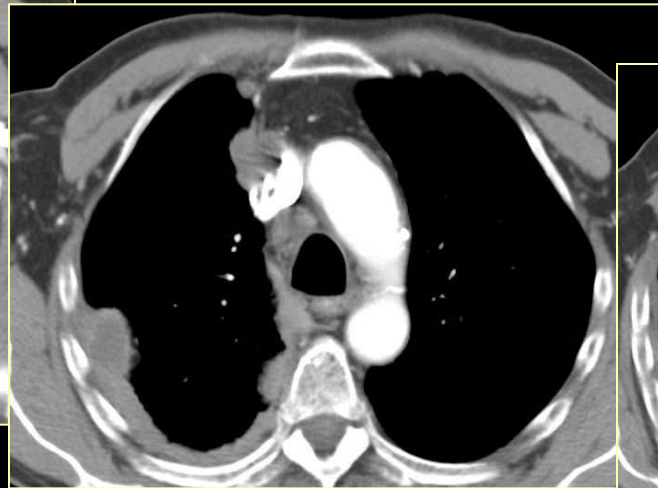
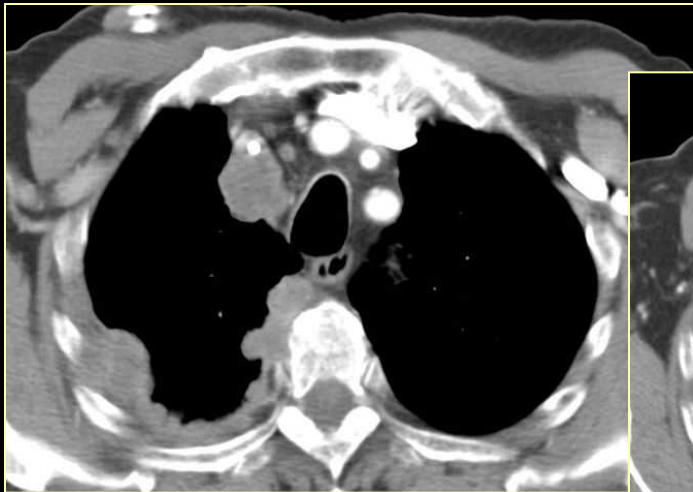Ttt hormonaux ou greffe pulmonaire si maladie reste évolutive

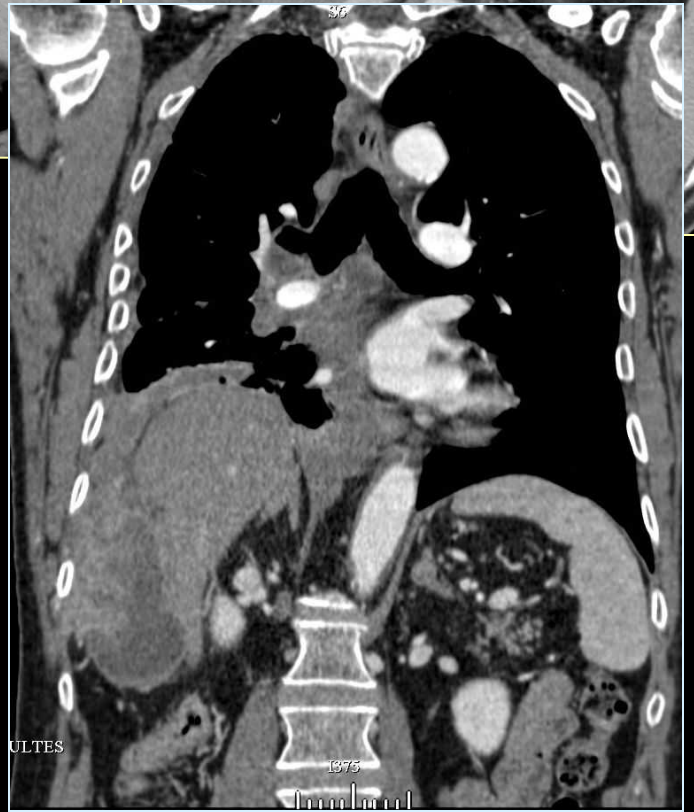
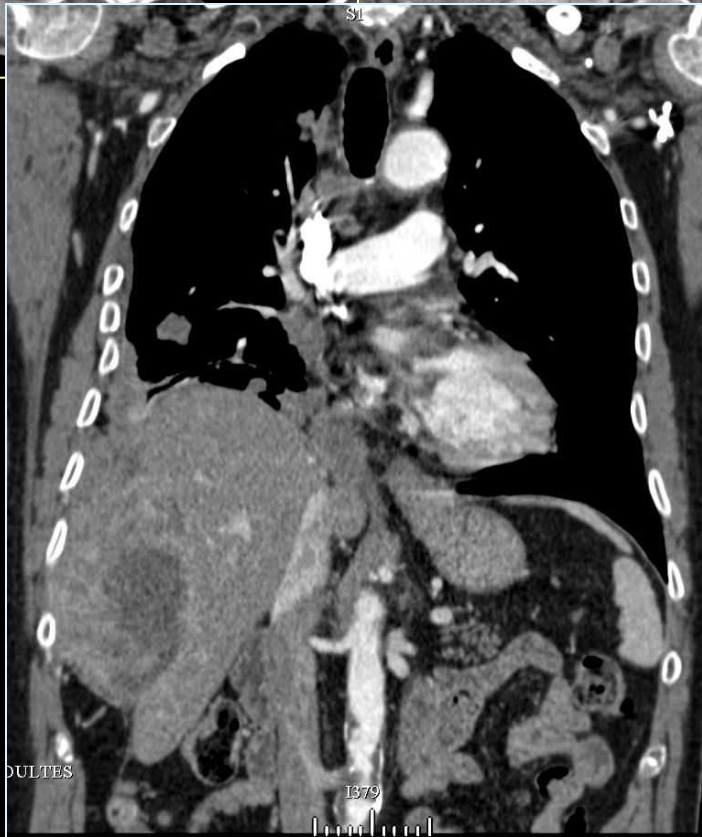
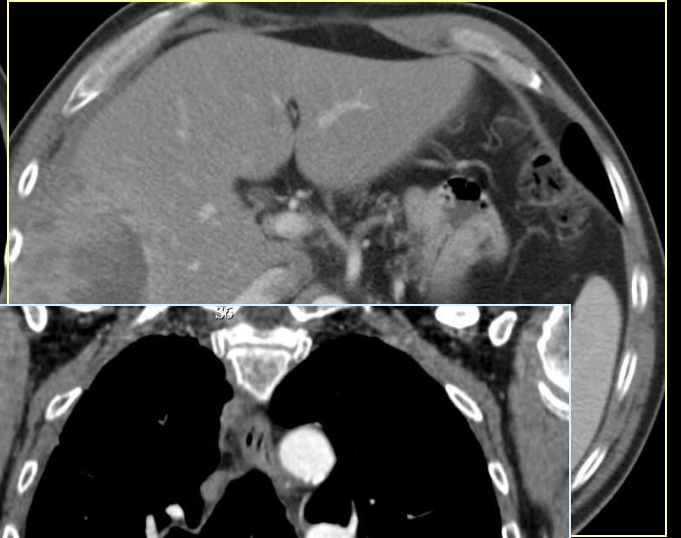
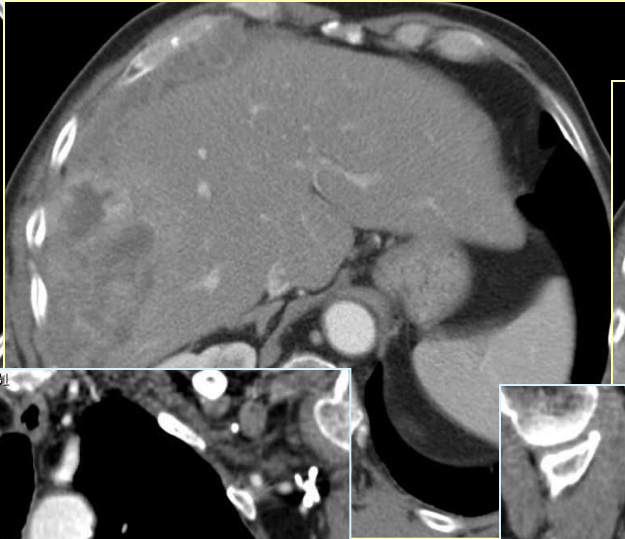
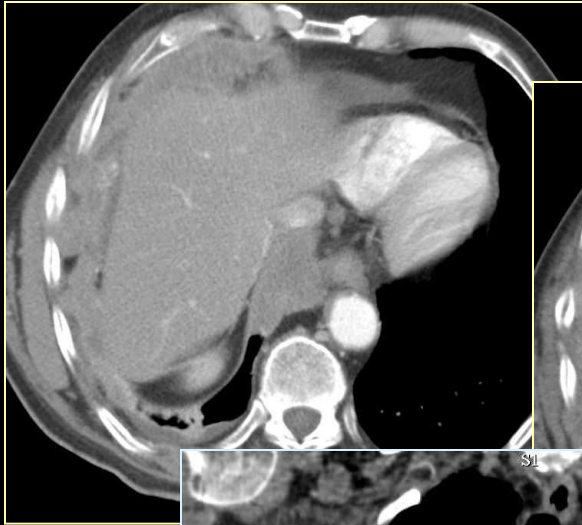


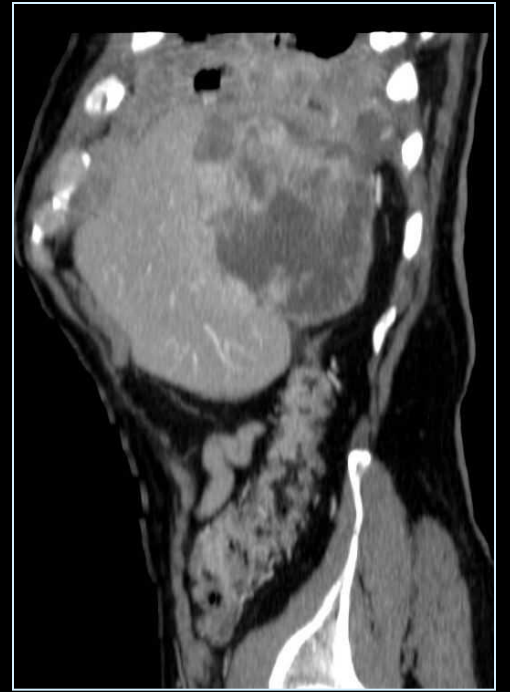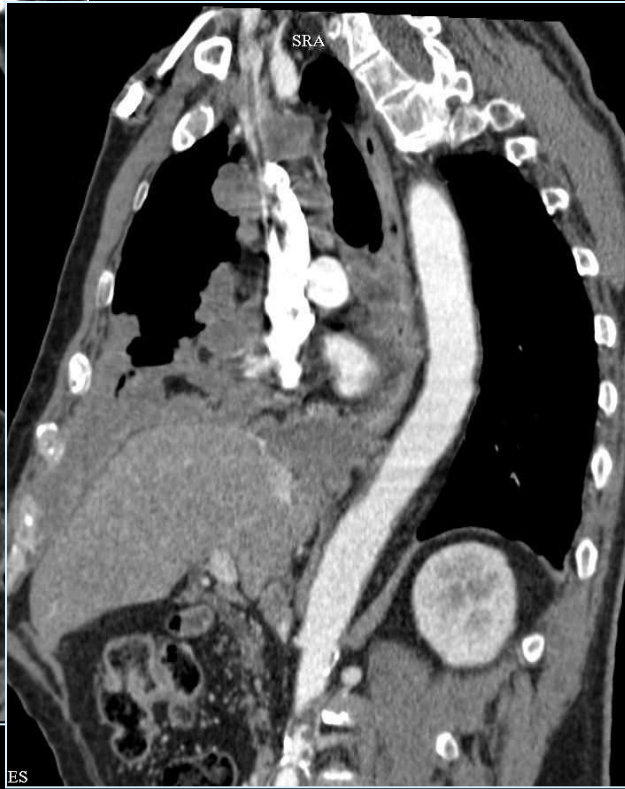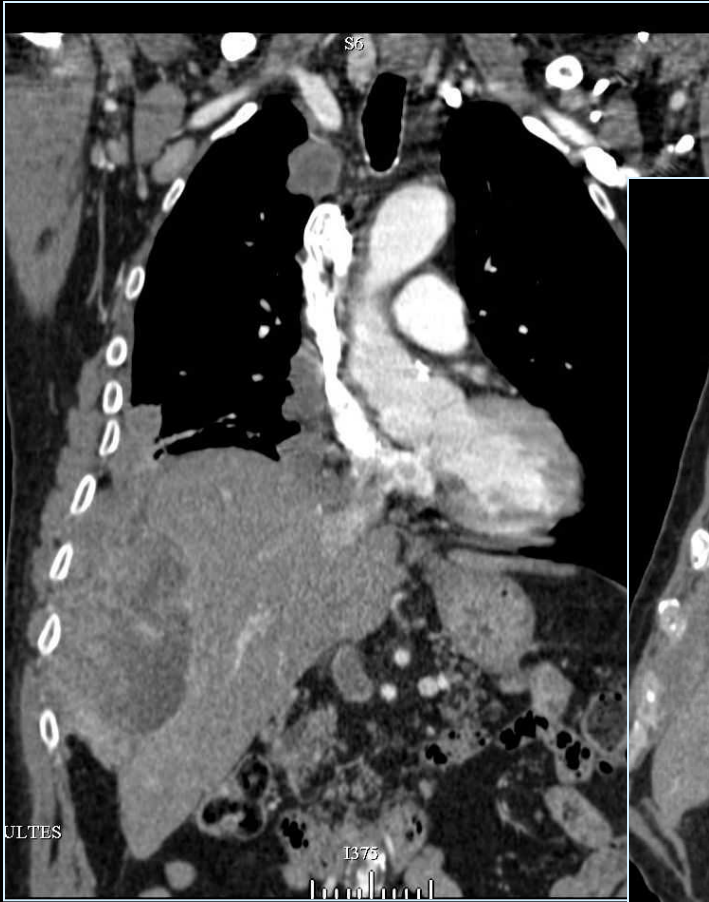
Récidive de la maladie sur greffon
10 % cas

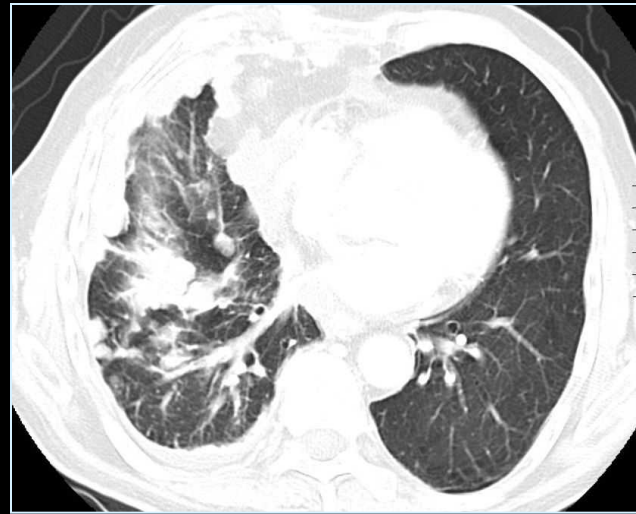
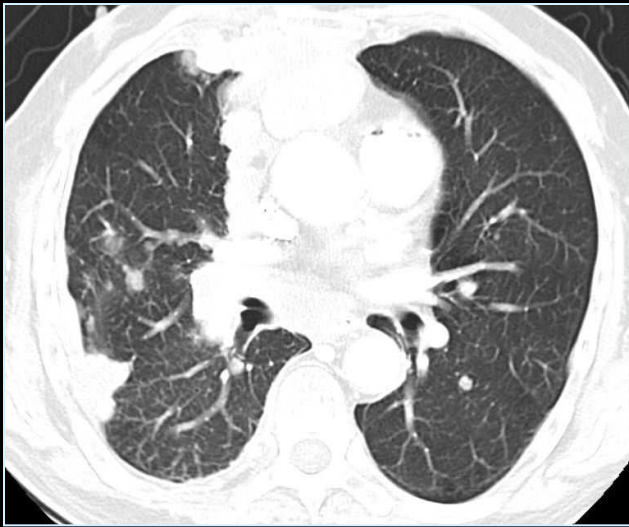
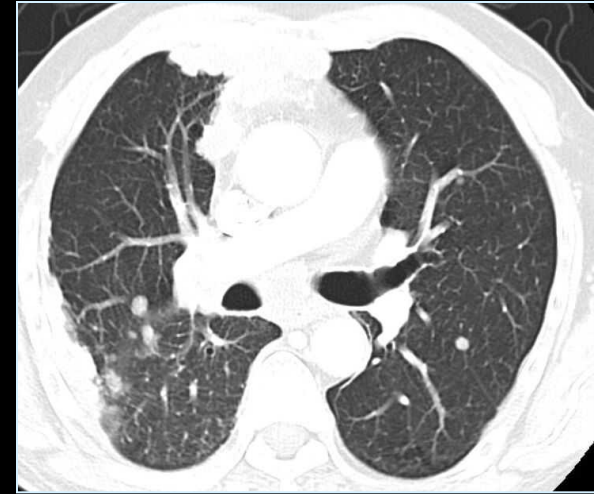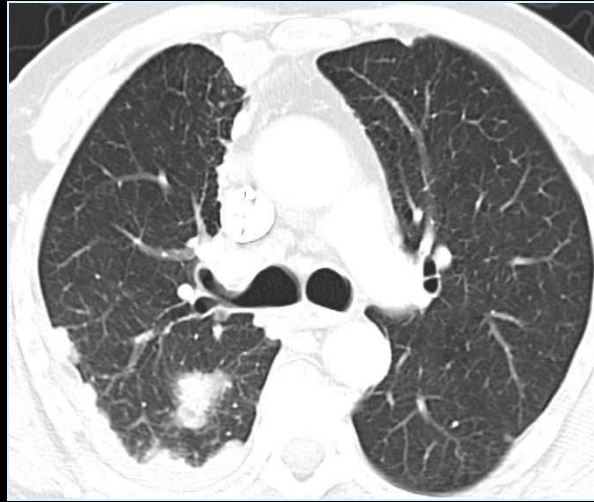
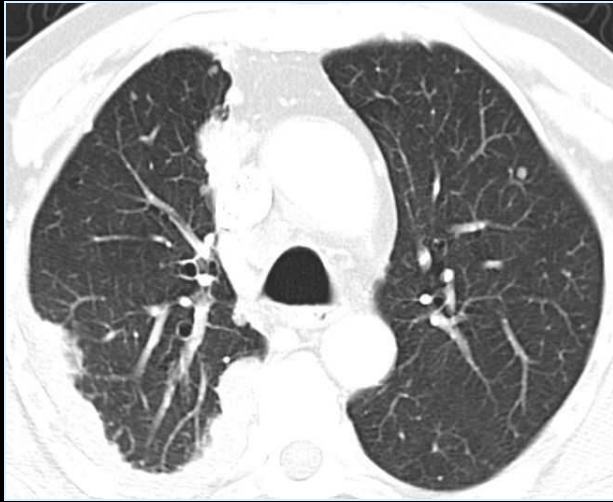


N°21









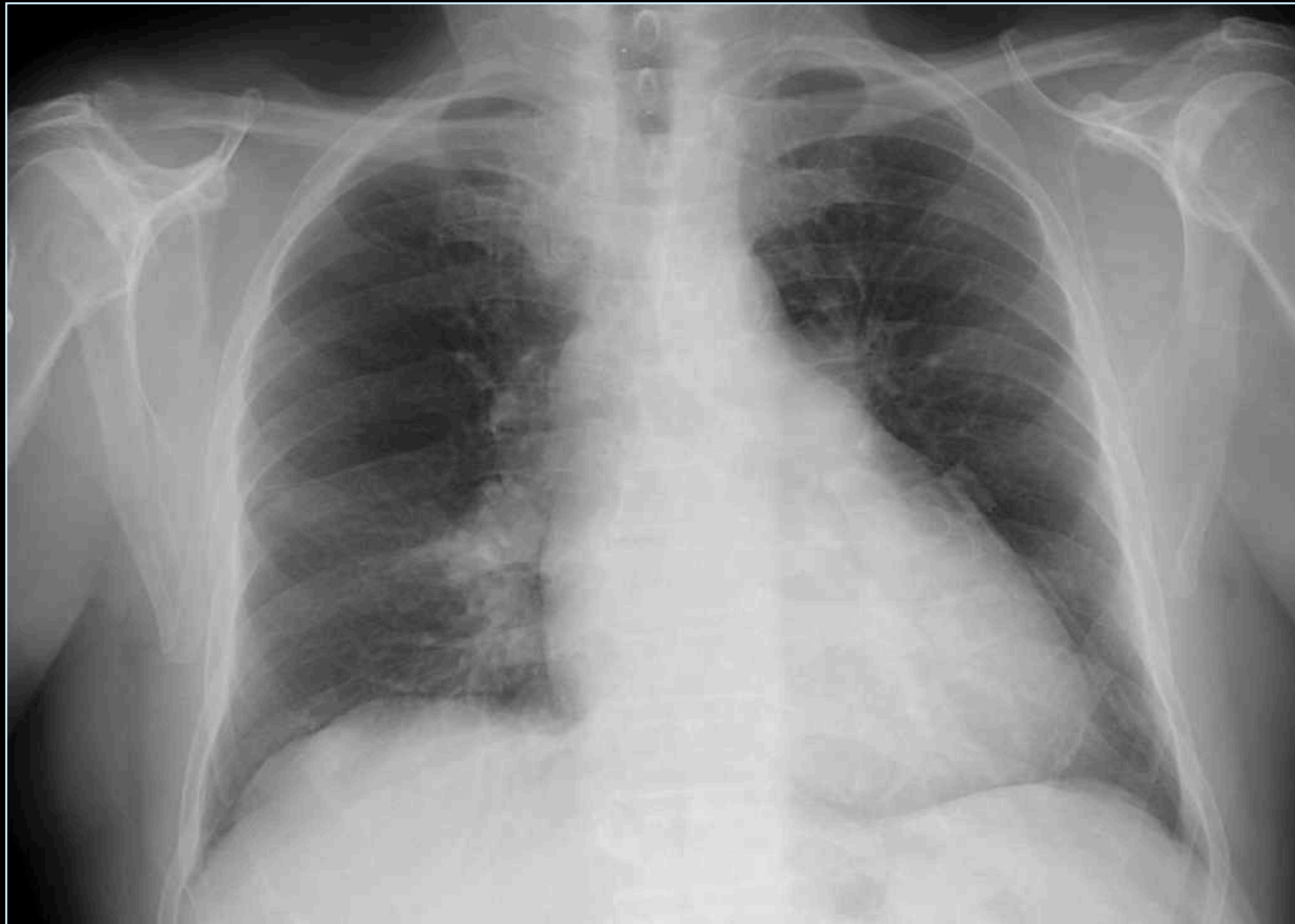Mésothéliome

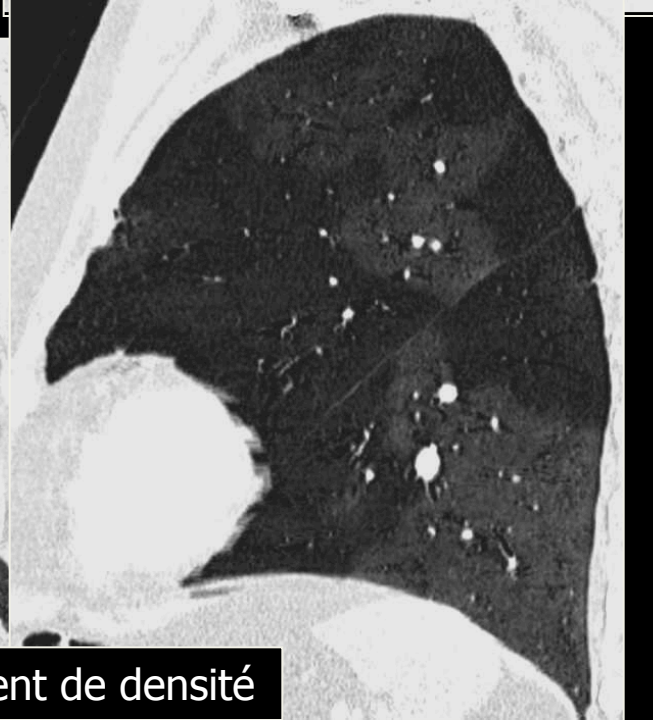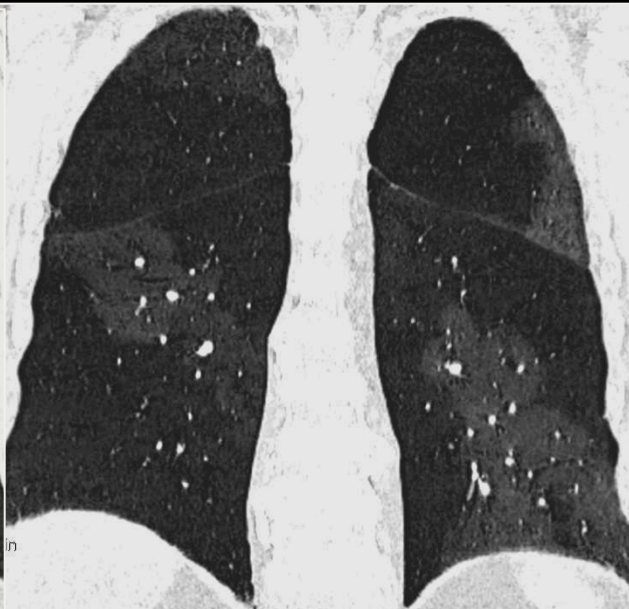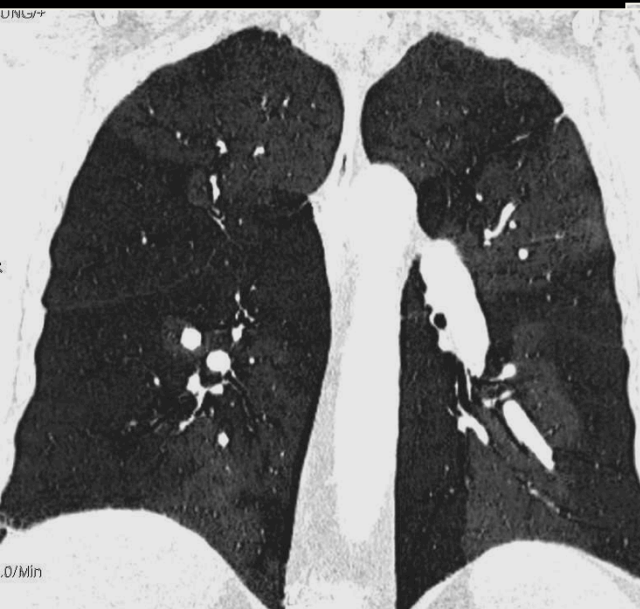
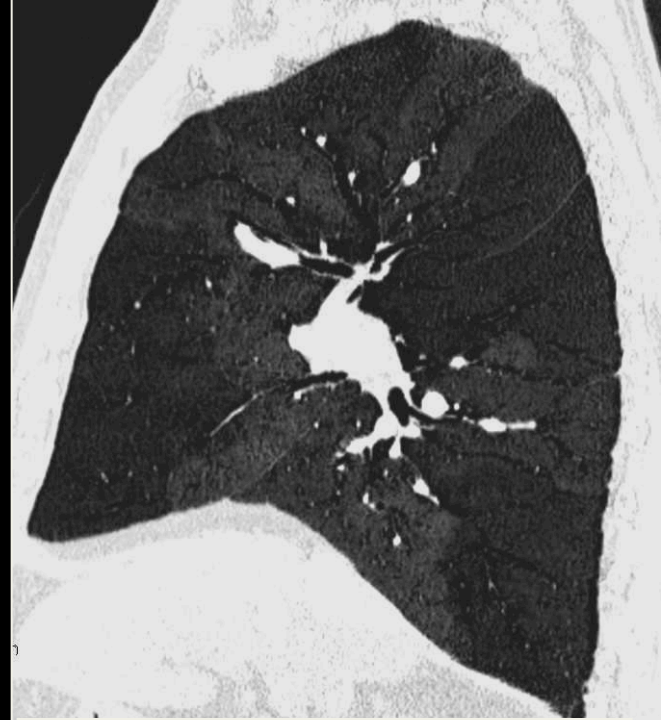
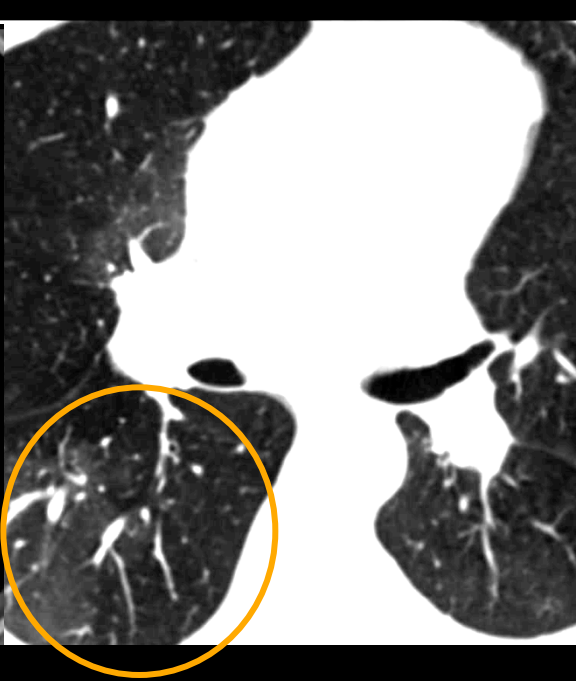
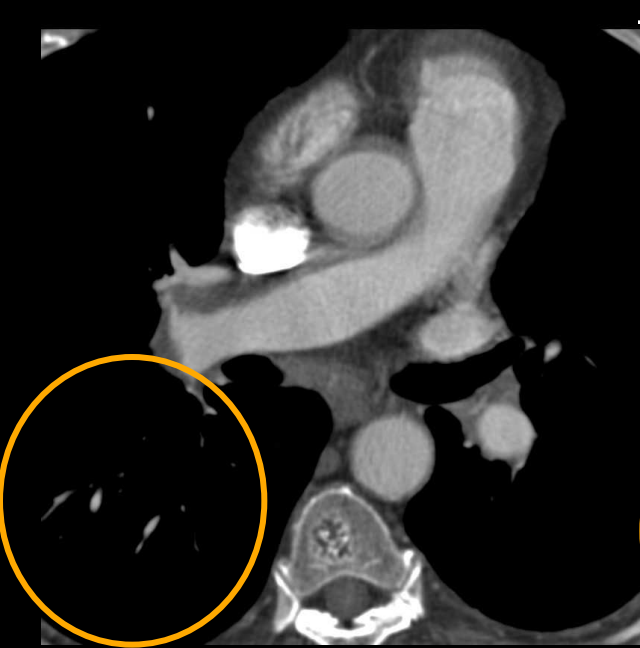Homme 75 ans hypoxémie HTAP

N°22

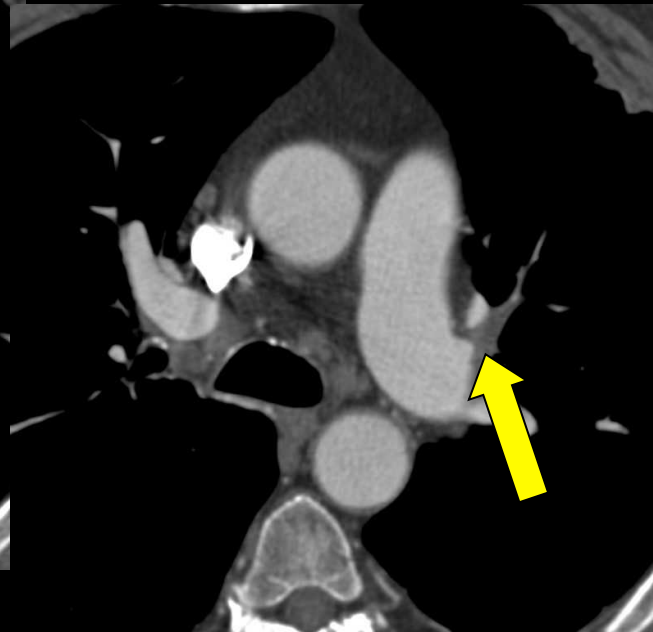
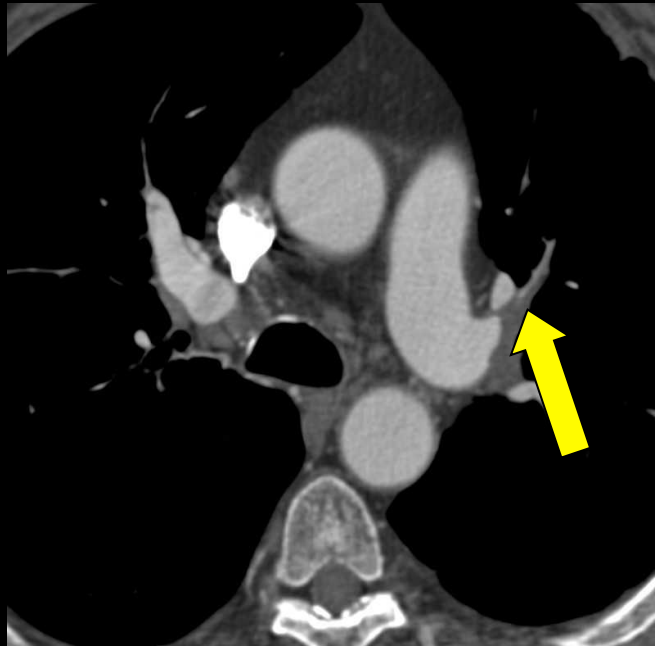
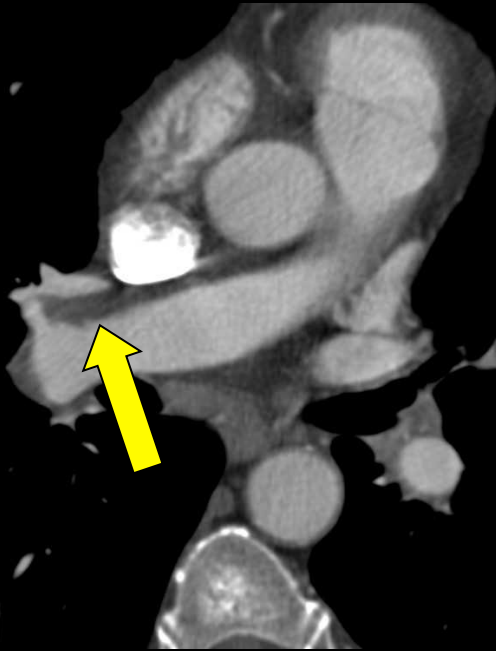
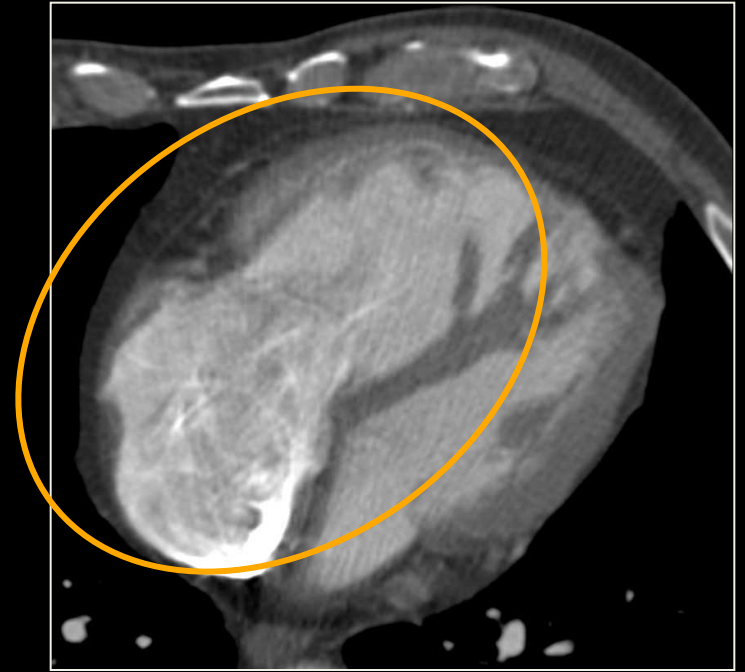
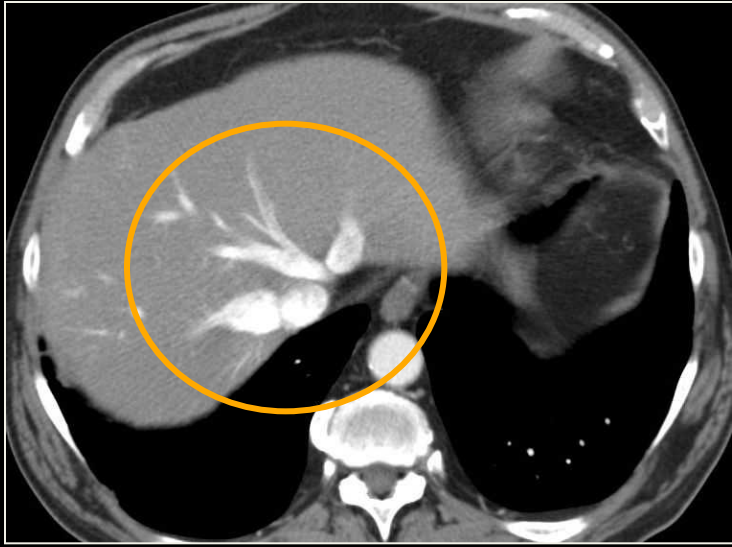
Découverte récente d'un cancer colique droit

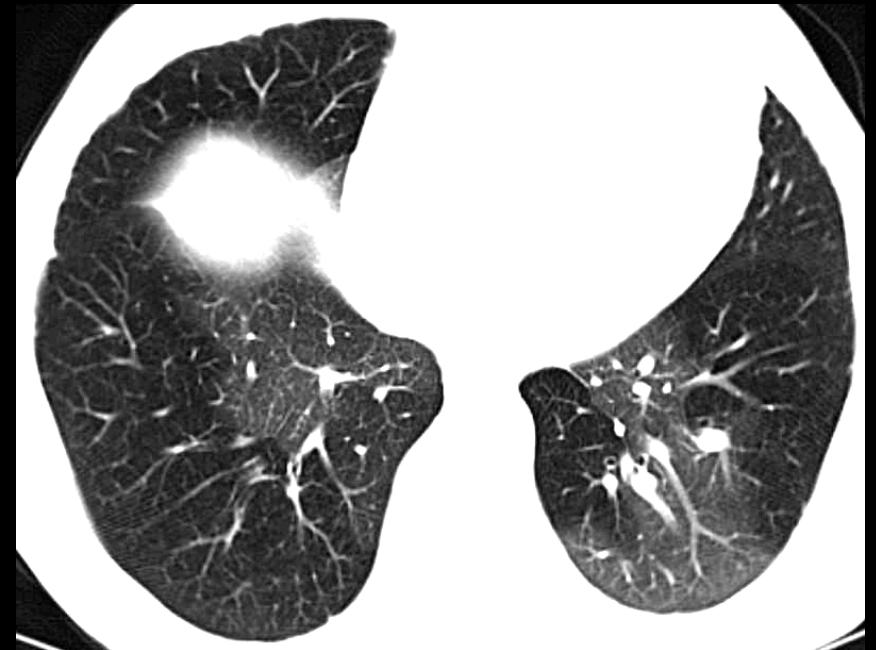
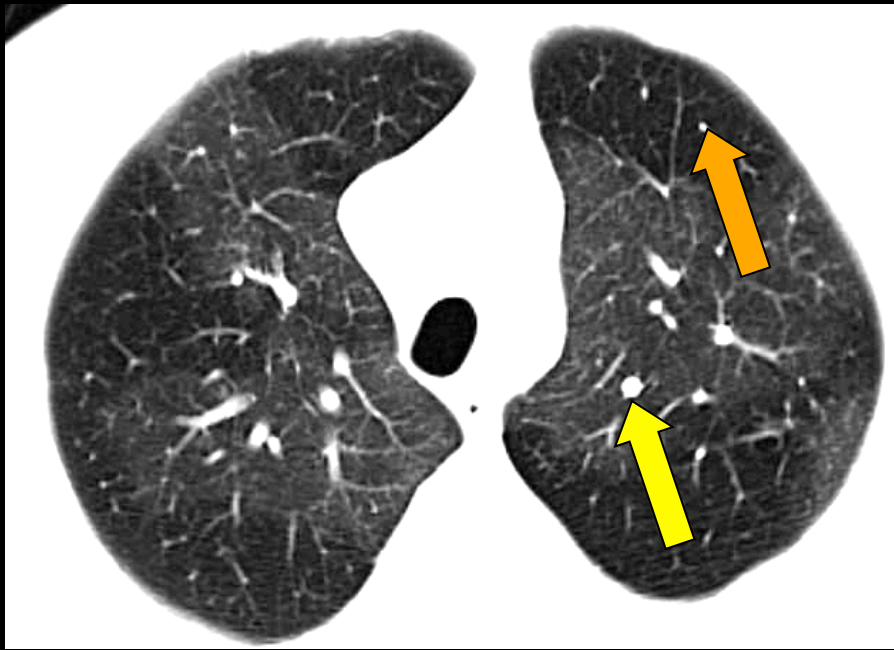
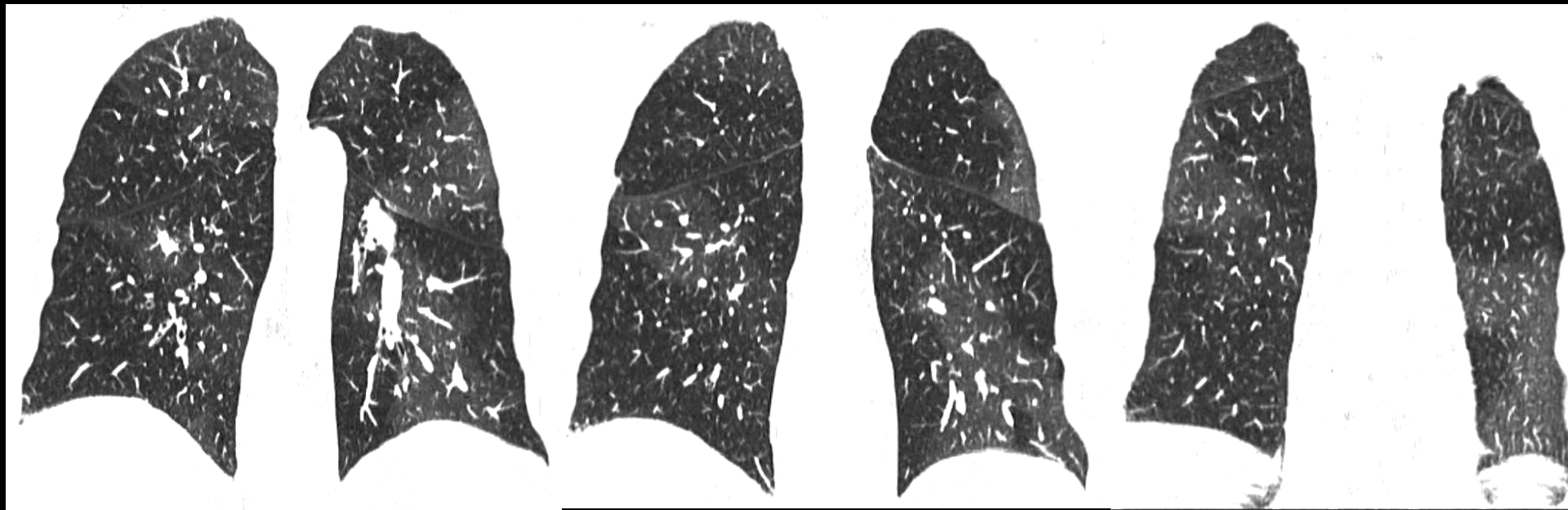
tabagisme sévère





Post traitement des images en MinMIP pour accentuer le gradient de densité





Cœur pulmonaire post embolique