

Ateliers d'IRM viscérale et vasculaire en pathologie abdomino-thoracique

ED

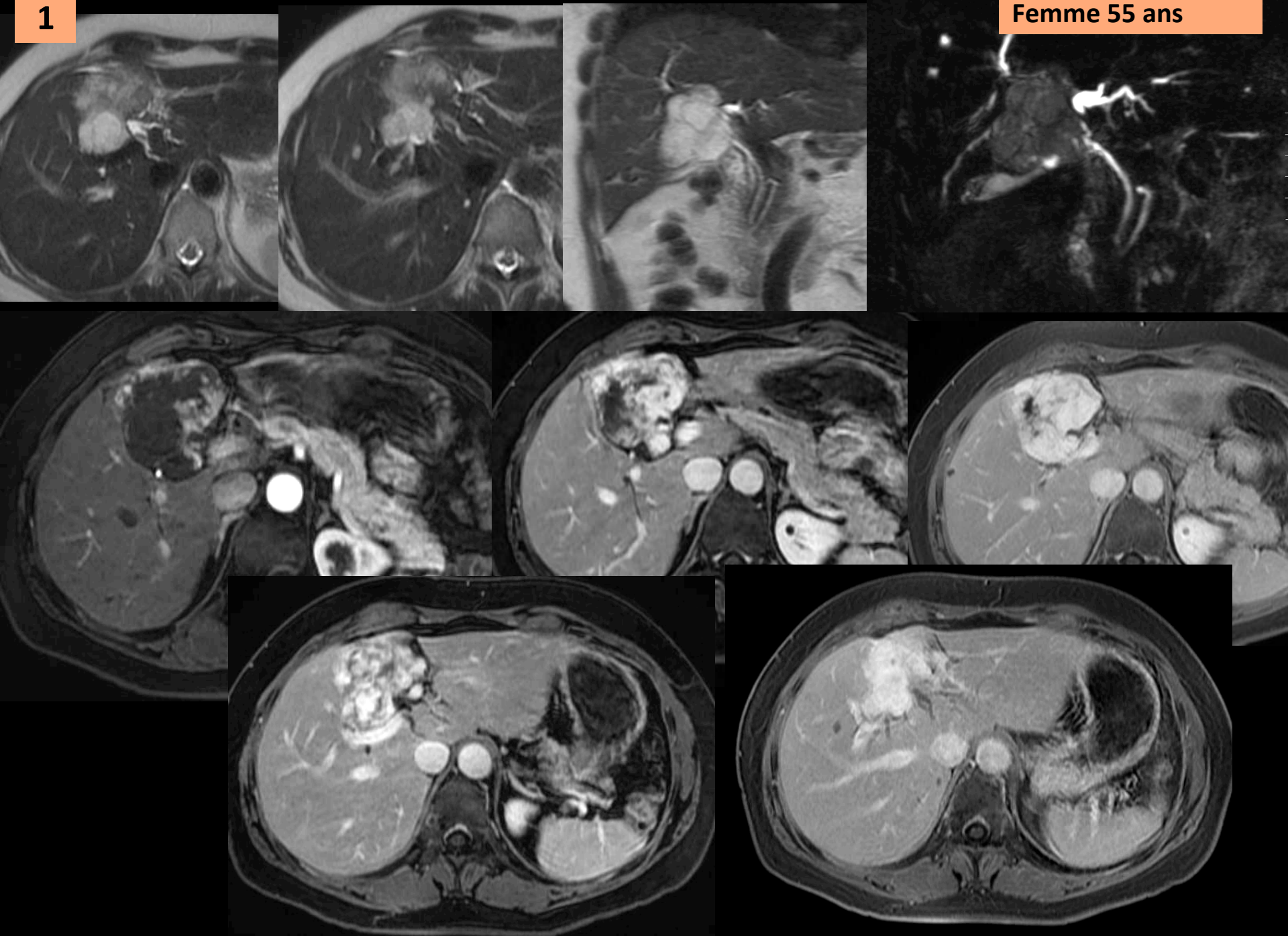Parenchyme hépatique

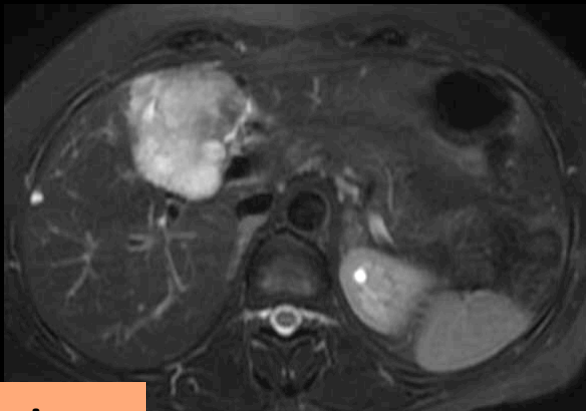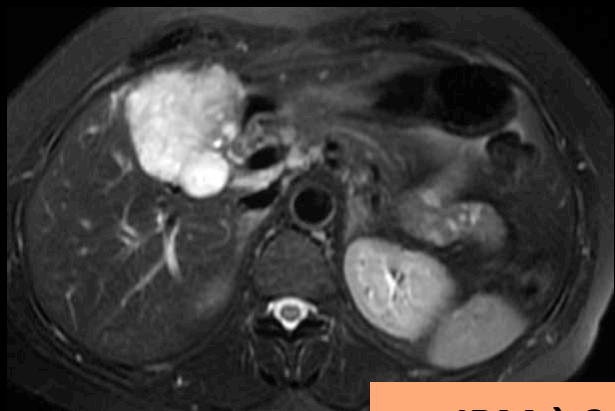
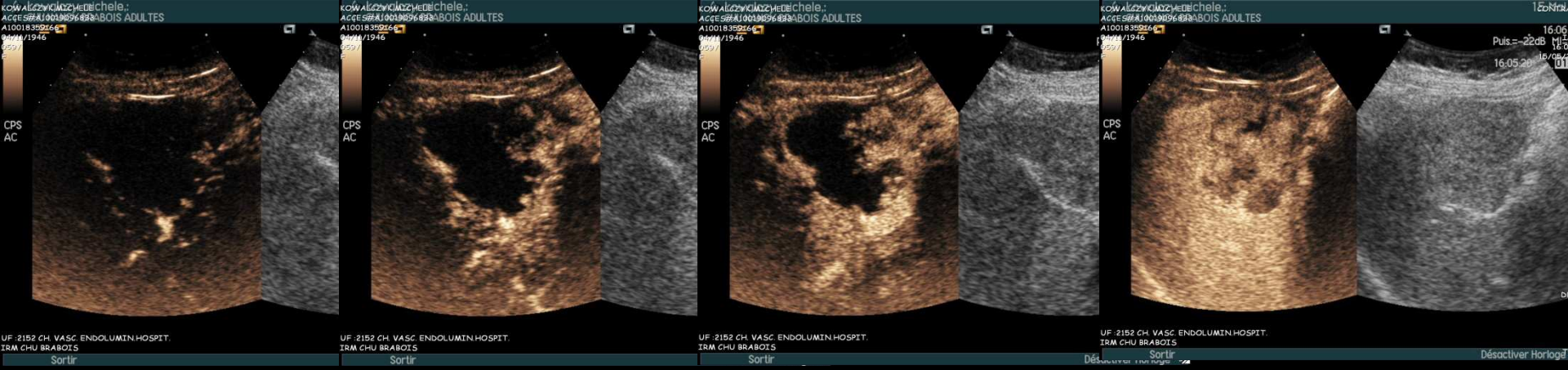Alexandre OLIVER

ACC Brabois Adultes

1

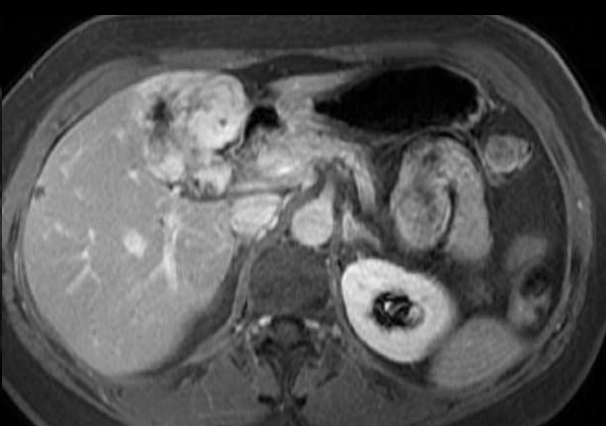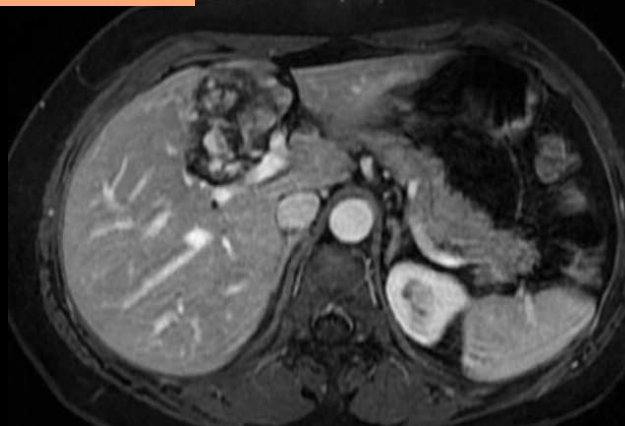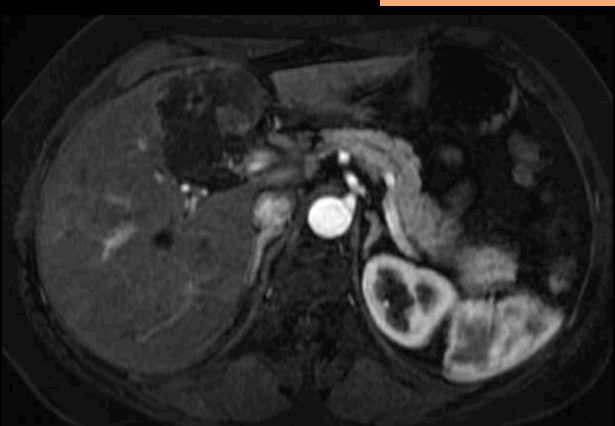
Femme 55 ans





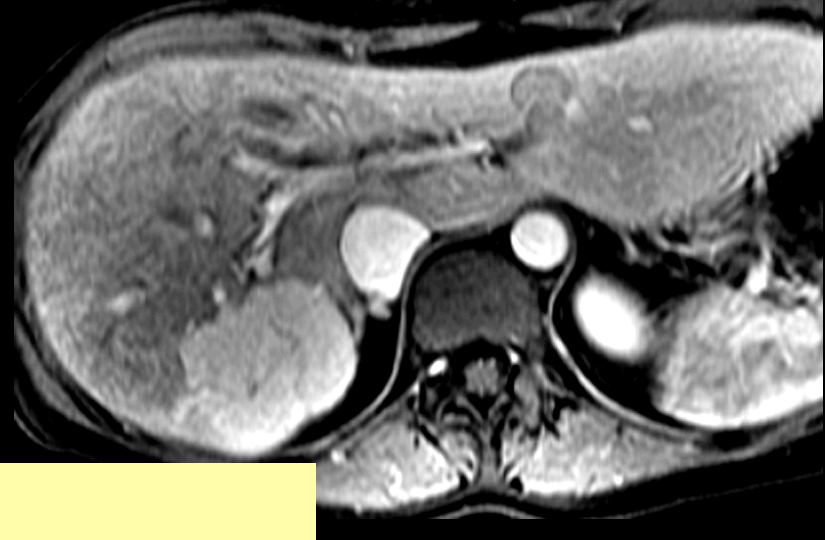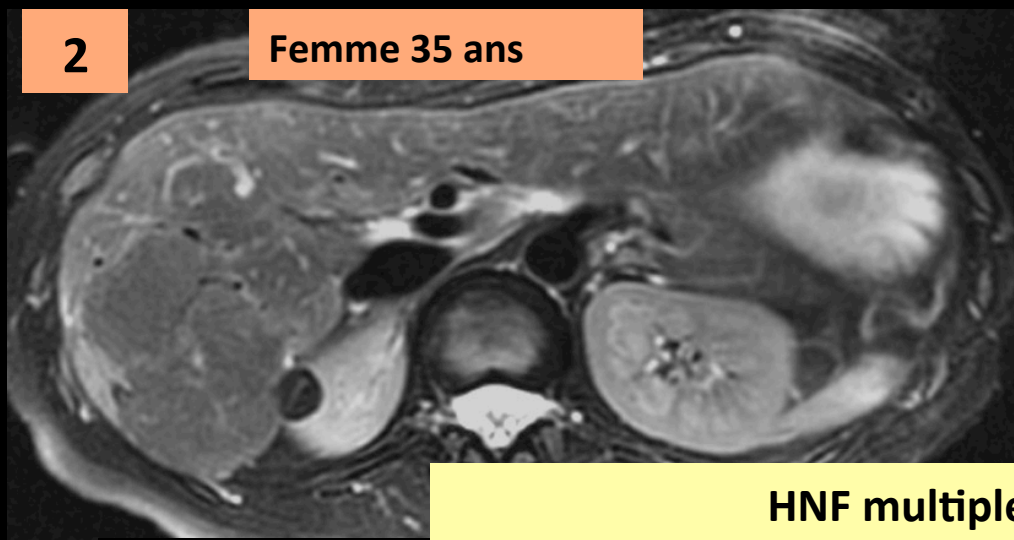
IRM à 3 mois

hémangiome

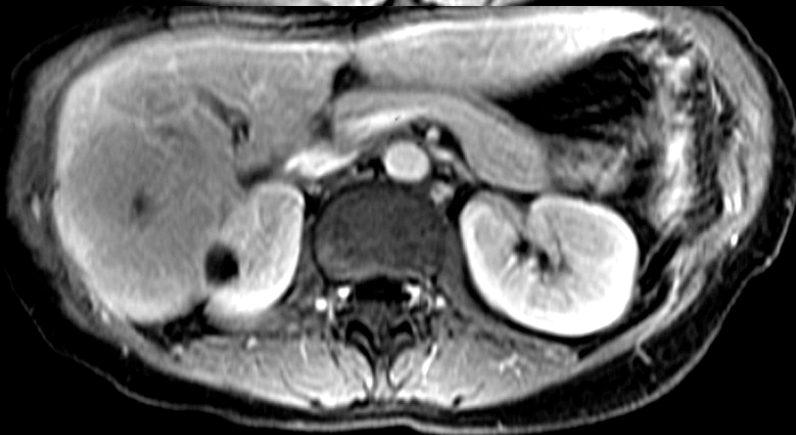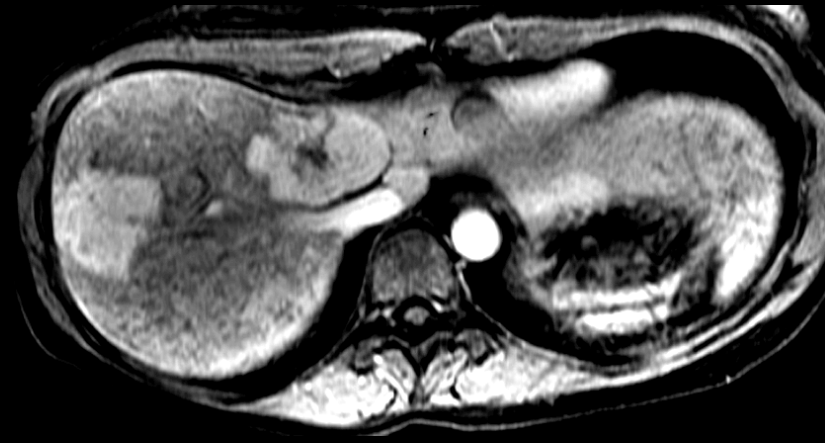

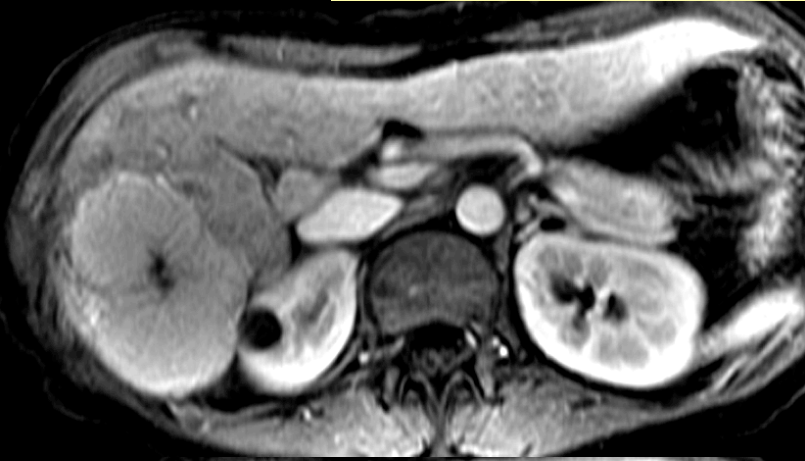
2

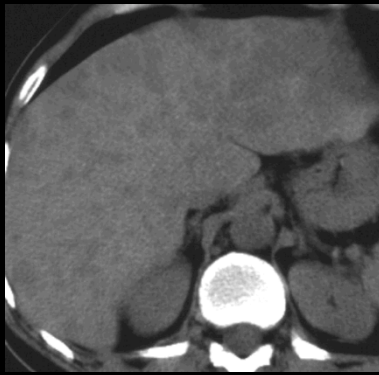
Femme 35 ans



HNF multiples



3

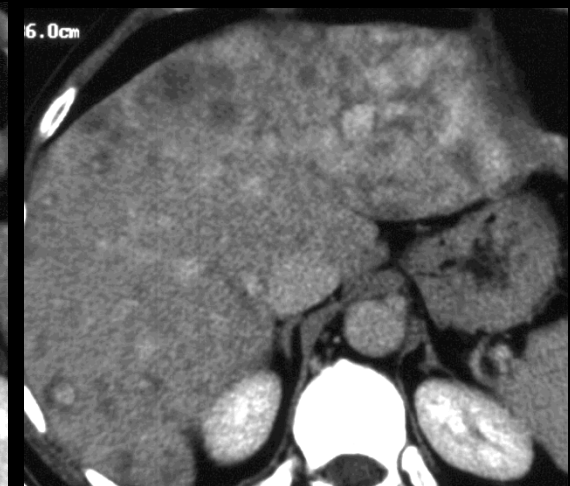
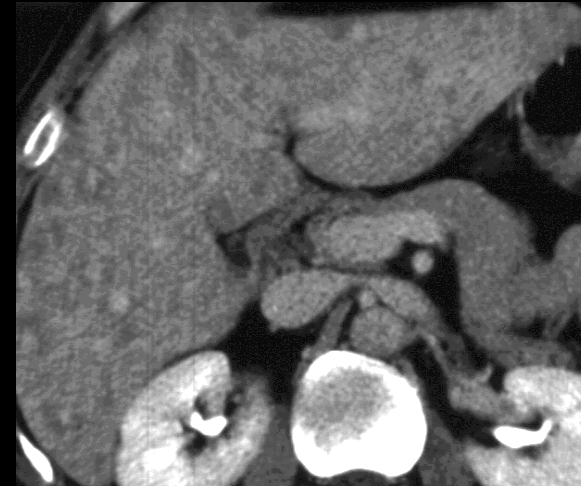
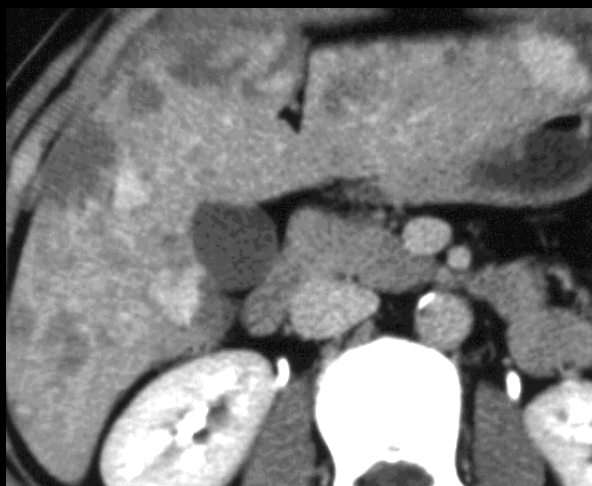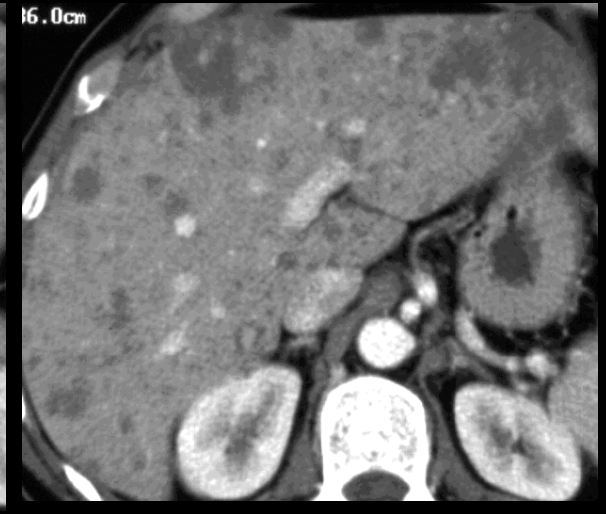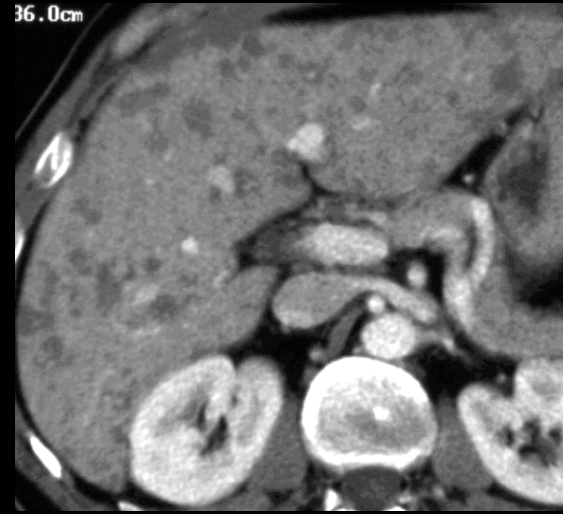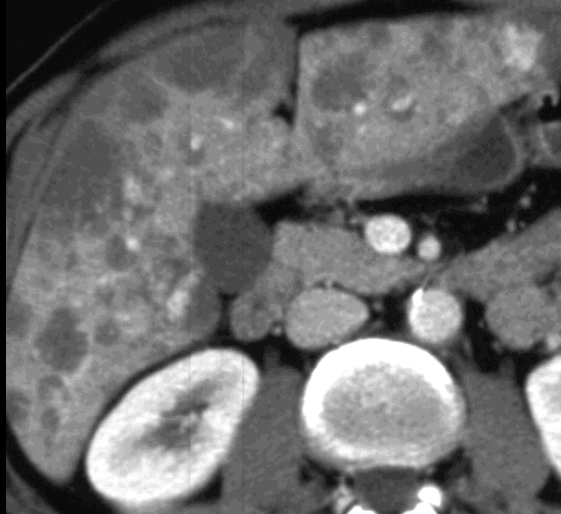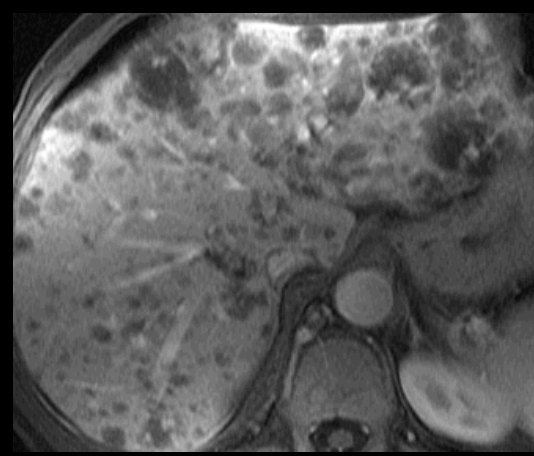
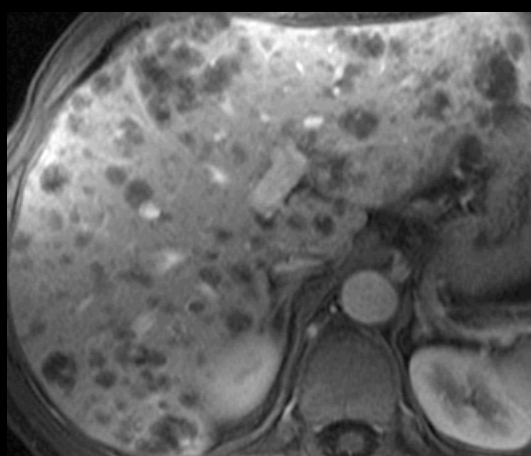
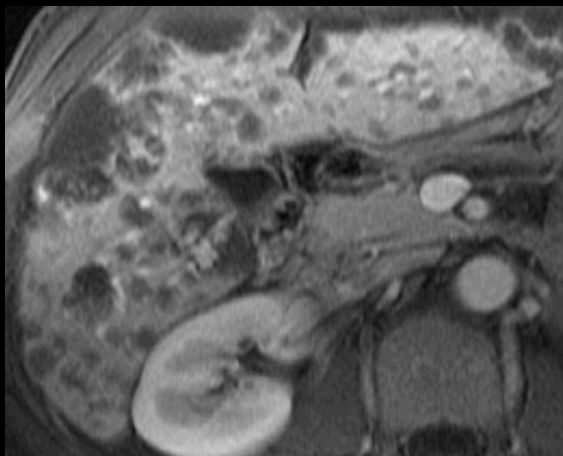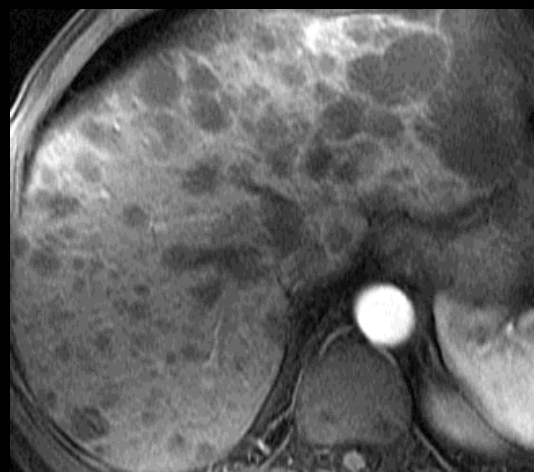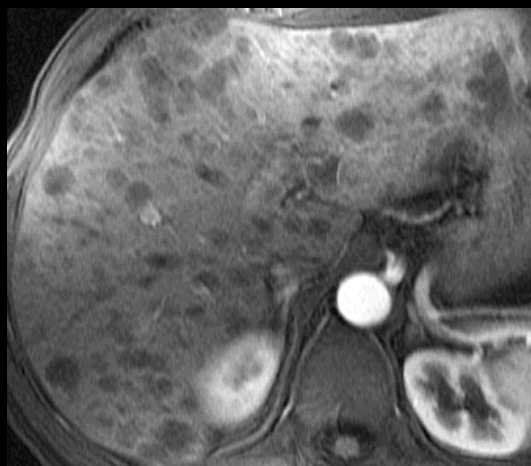
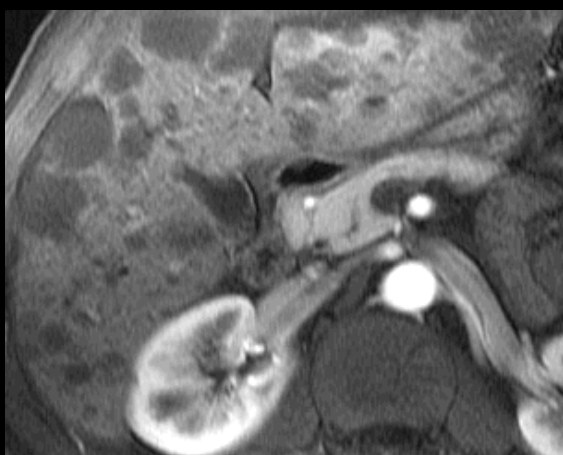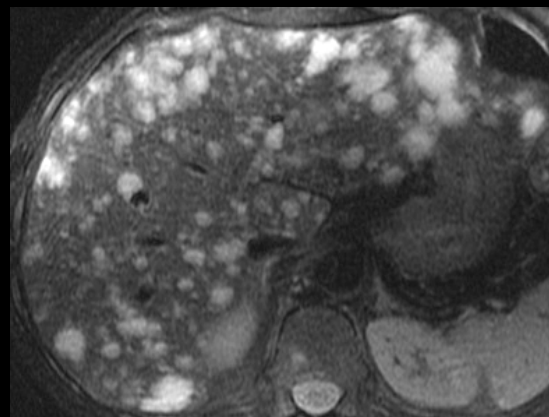
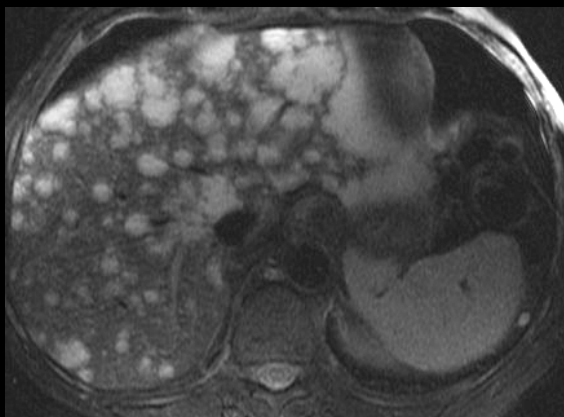
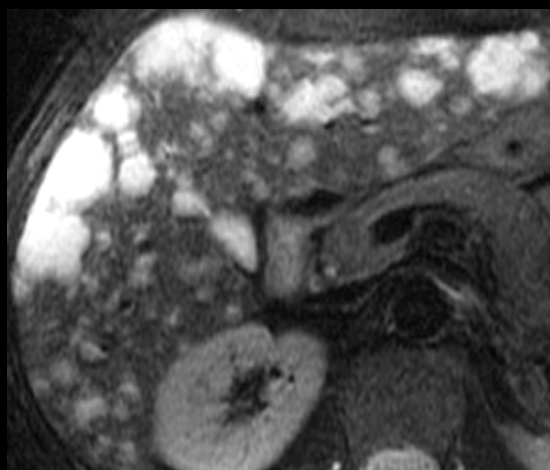
Homme, 50 ans

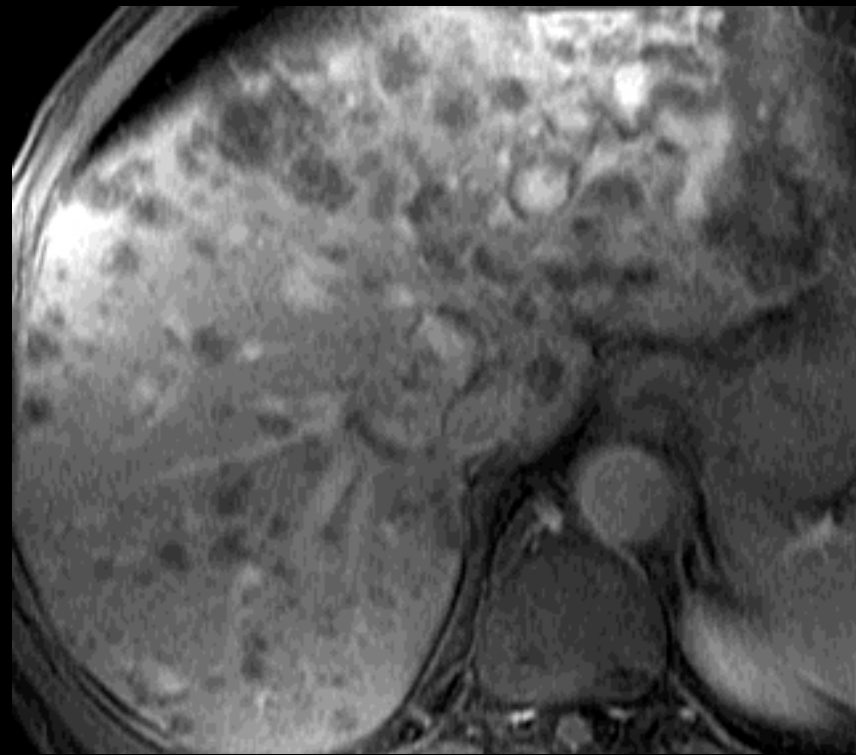
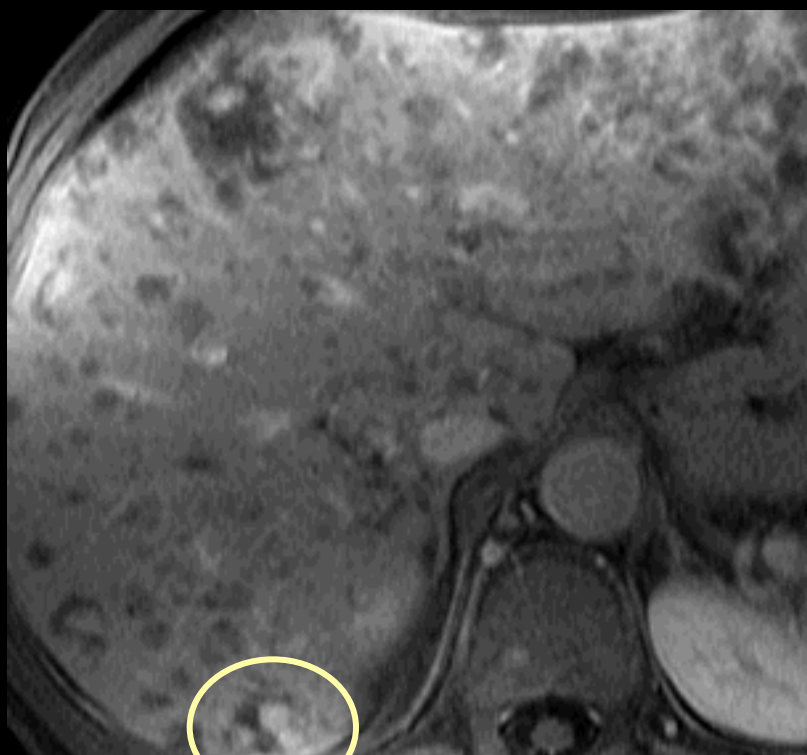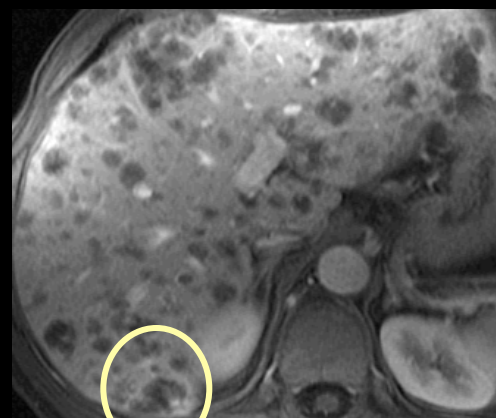
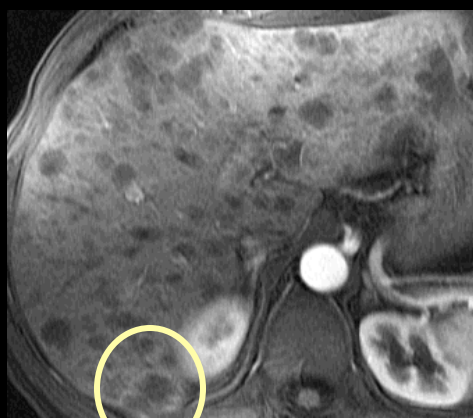
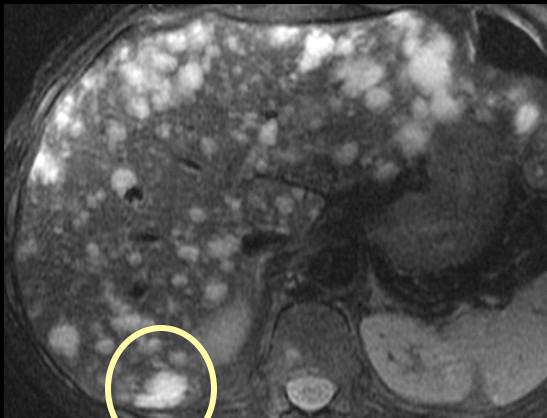
- Douleurs épigastriques

- Pas d'antécédent

- Echo. Abdo : découverte de nodules disséminés







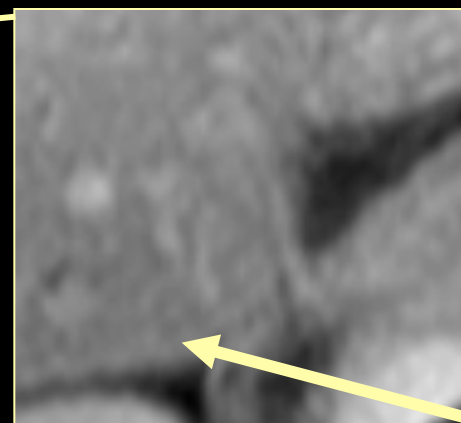
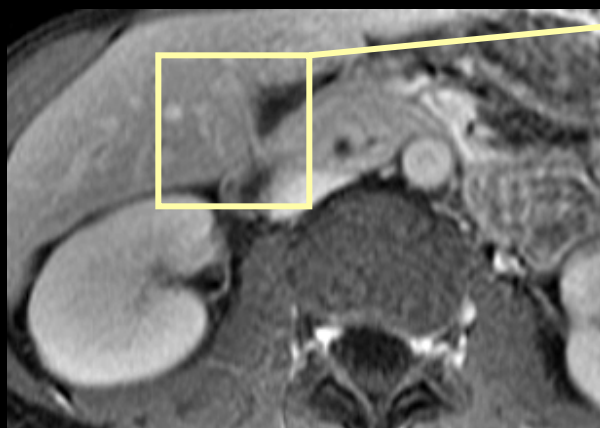
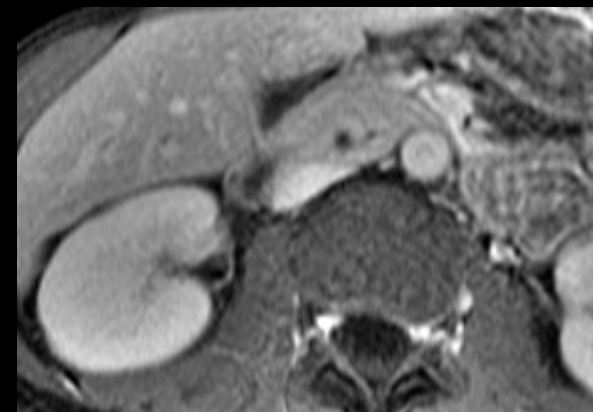
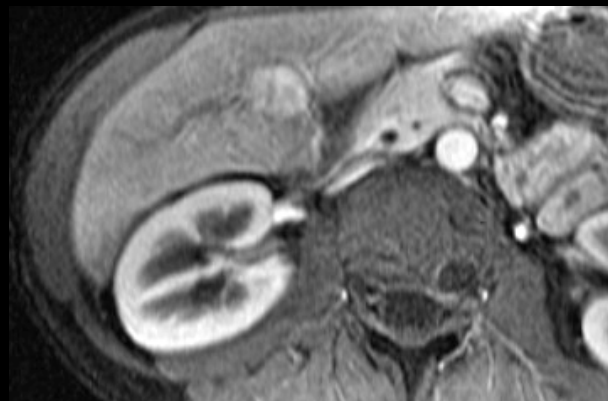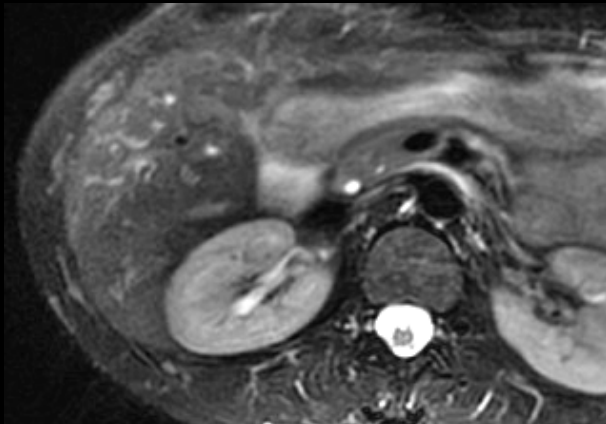
Ax T1 gado tardives

Hémangiomatose

4

Femme, 40 ans

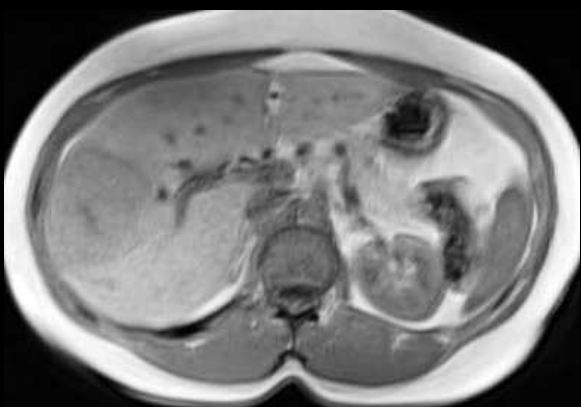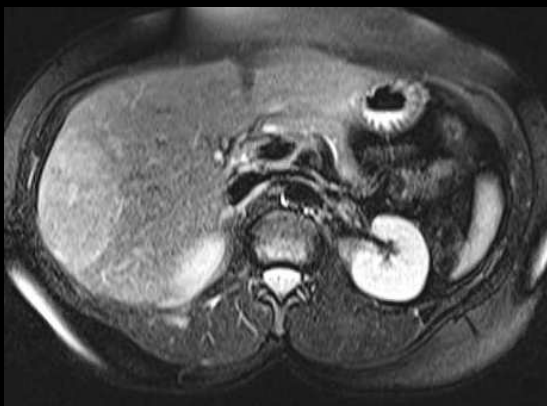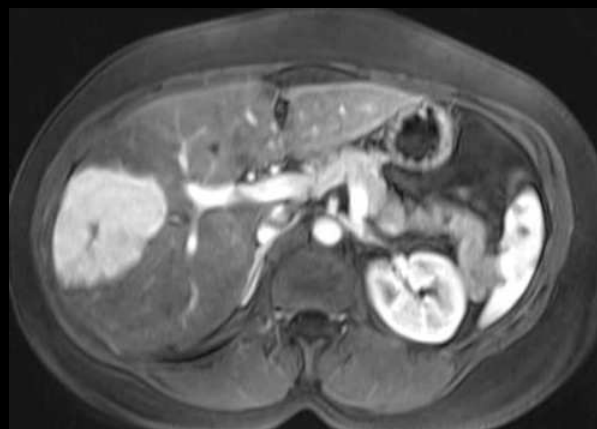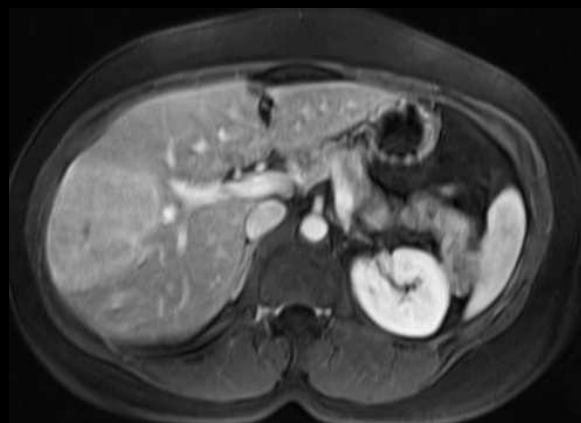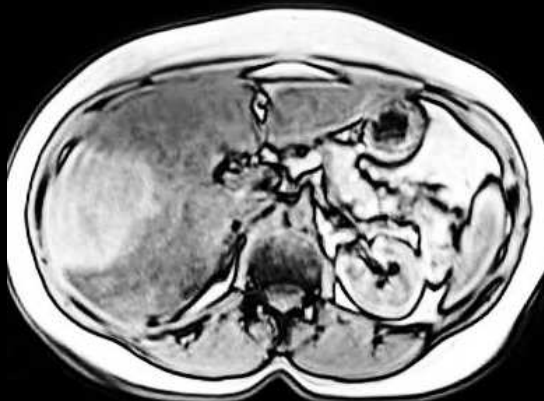
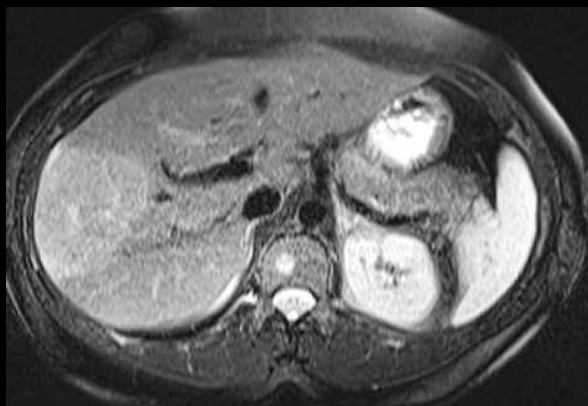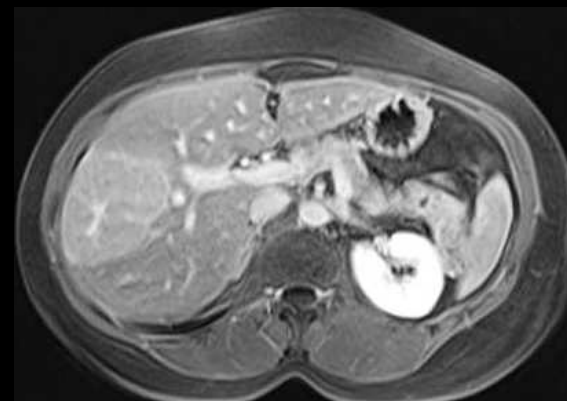
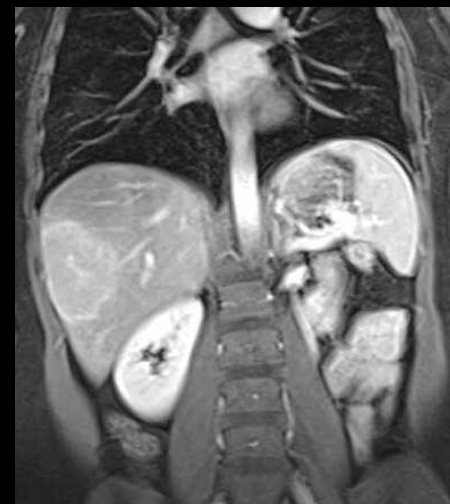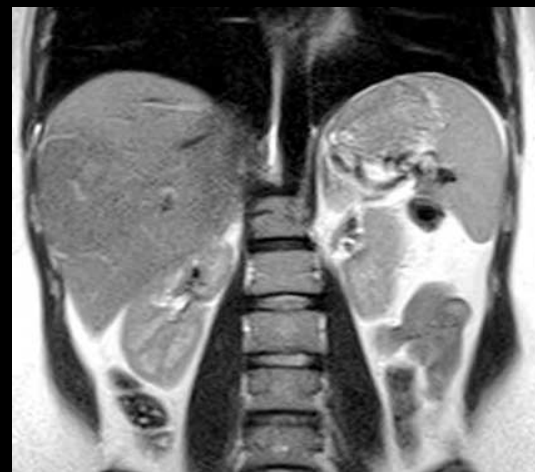
HNF



5

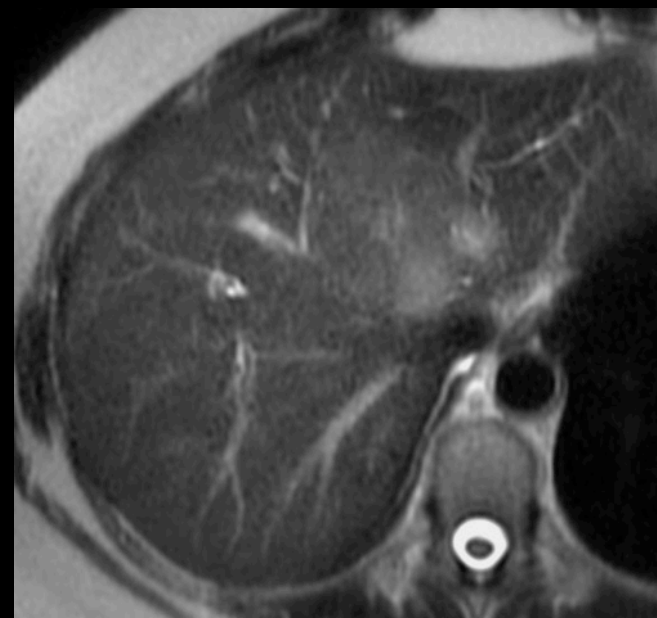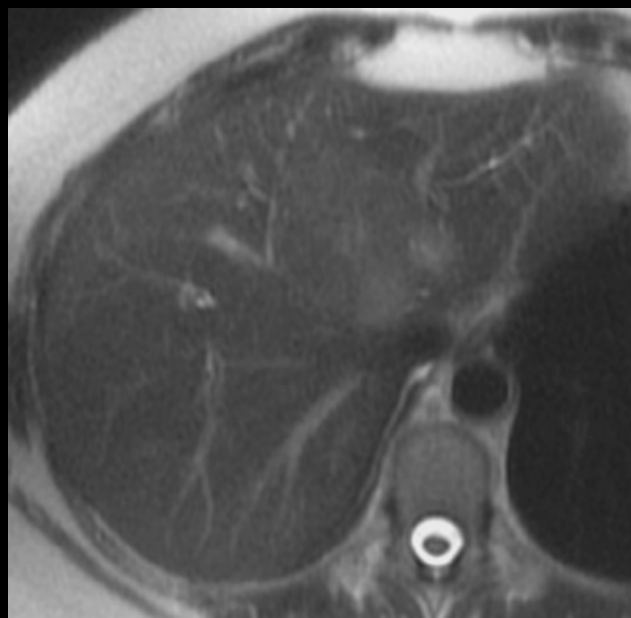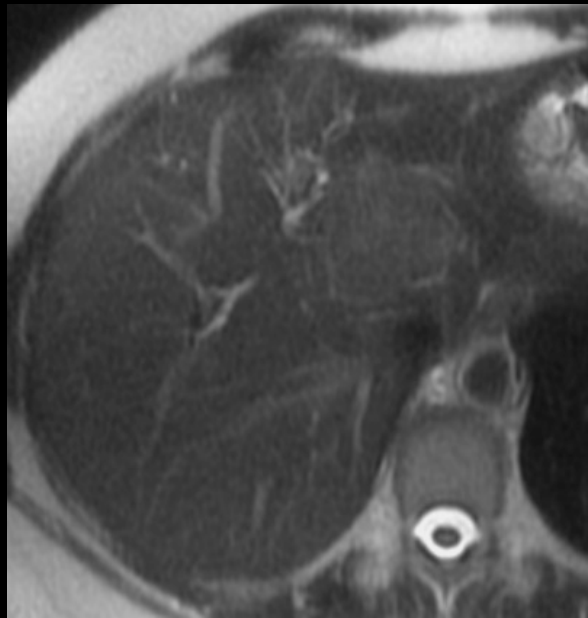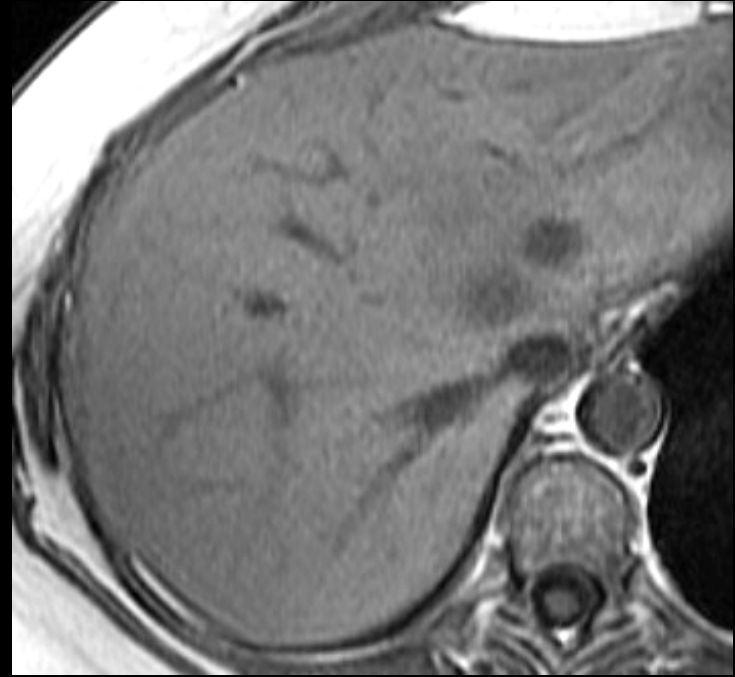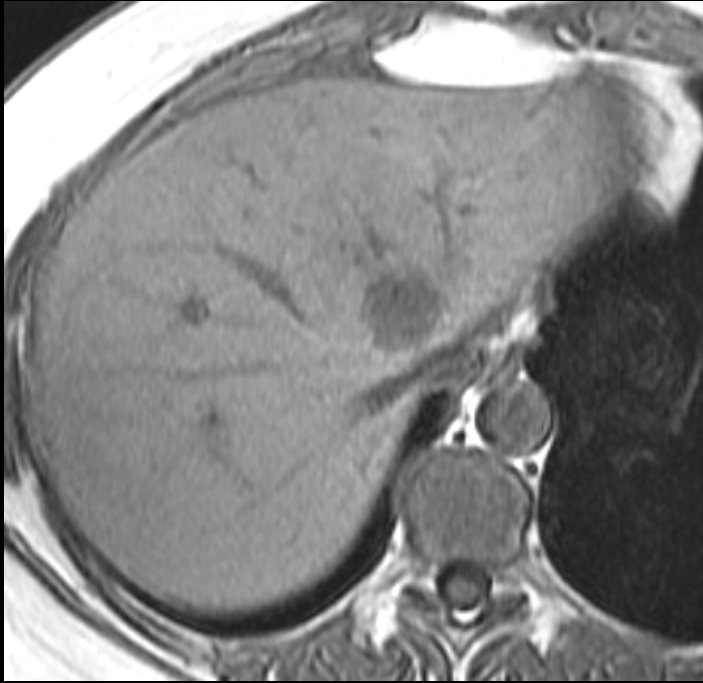
femme, 30 ans

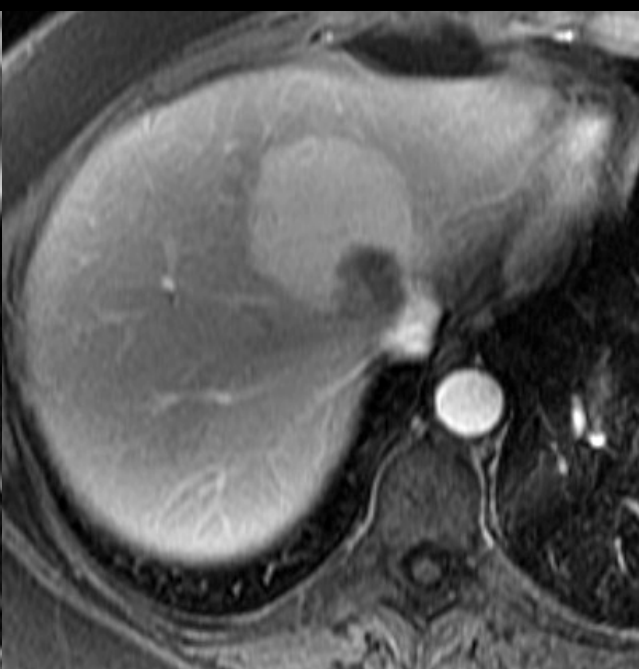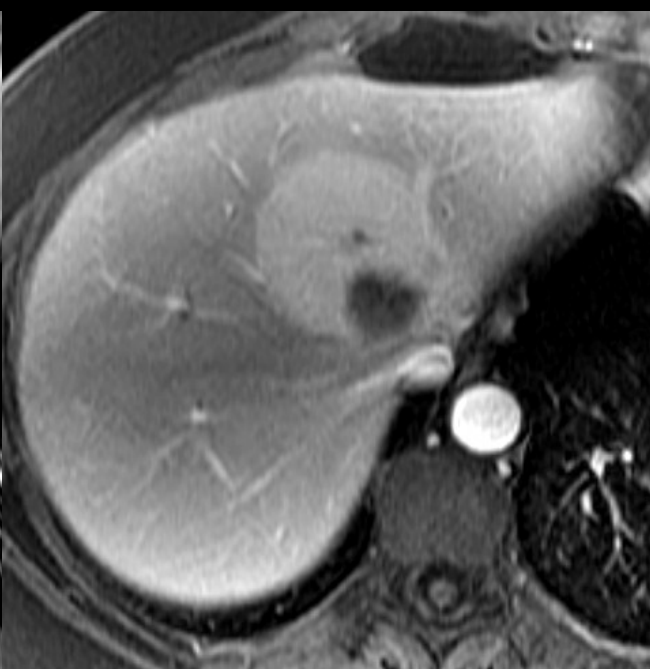
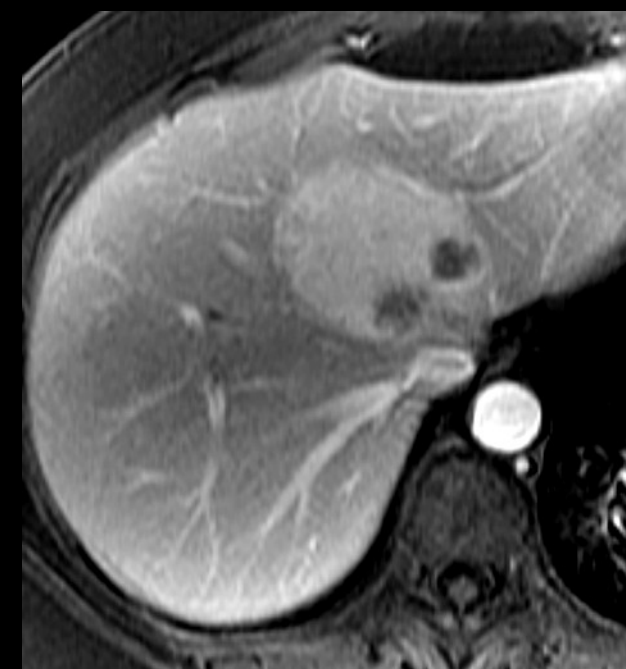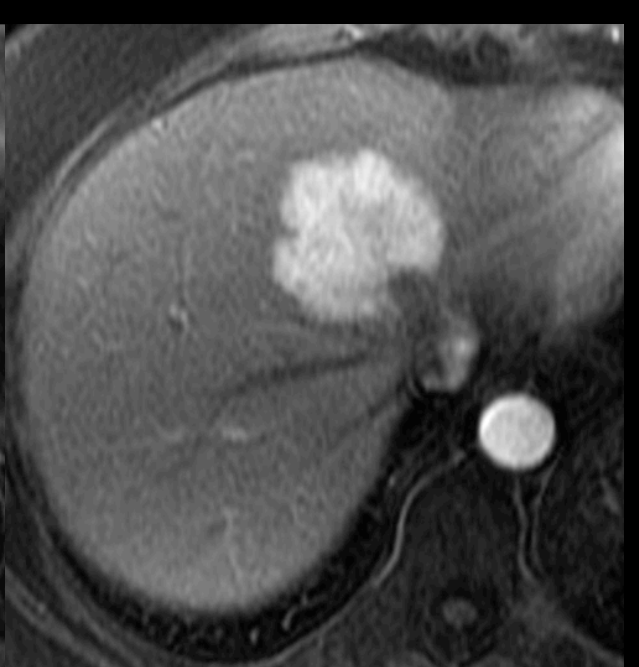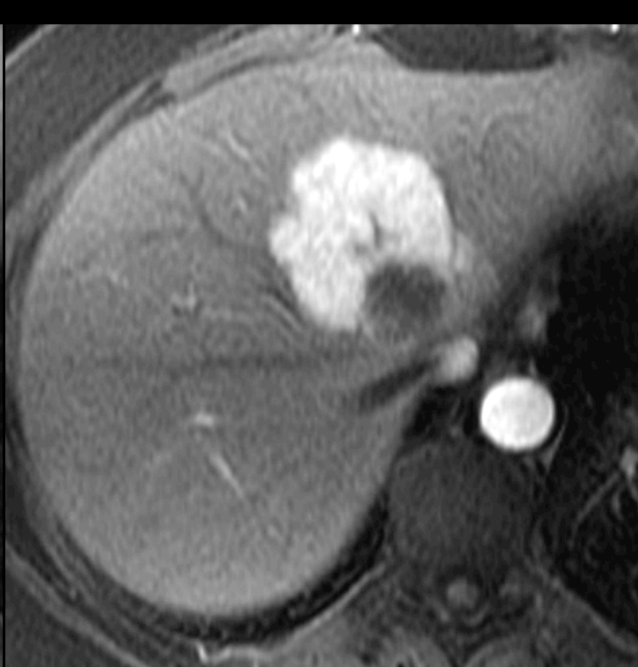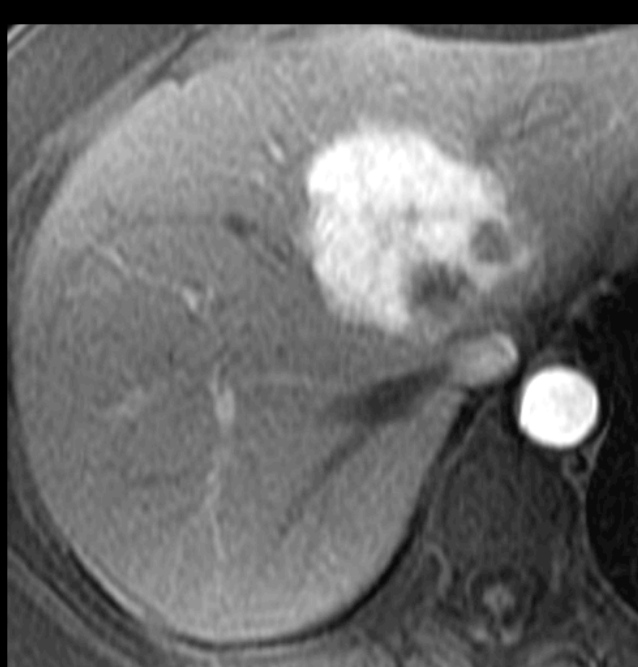HNF

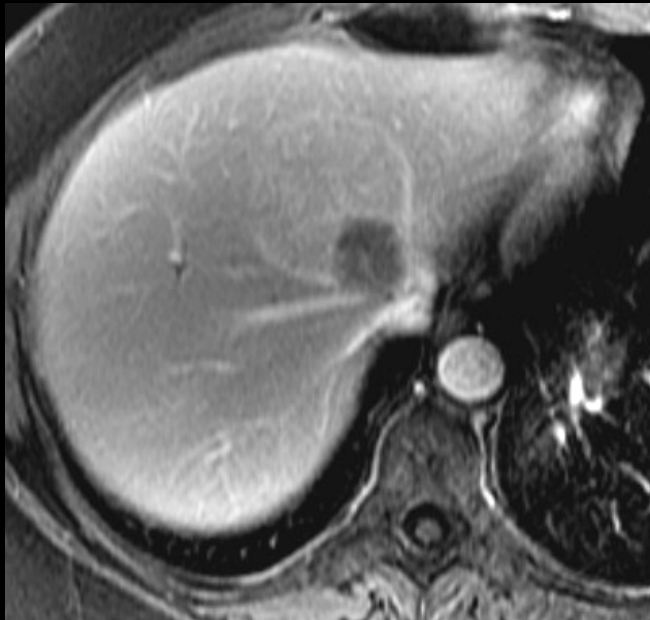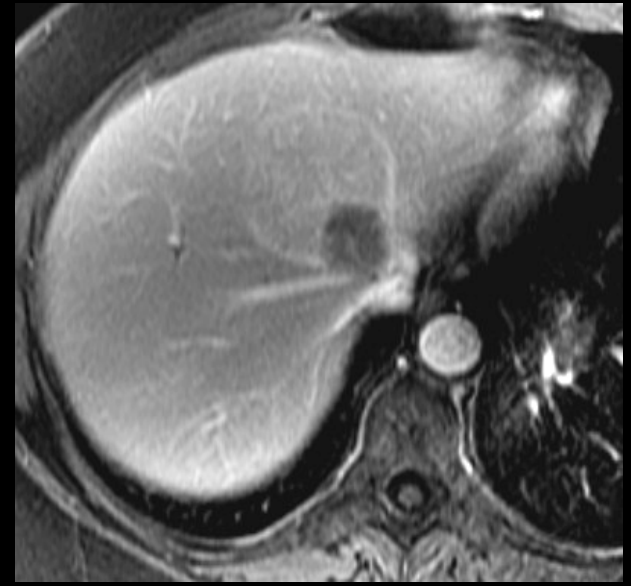
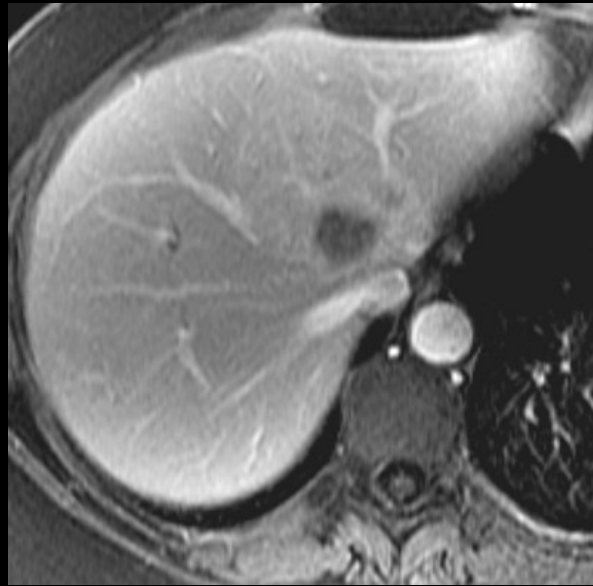

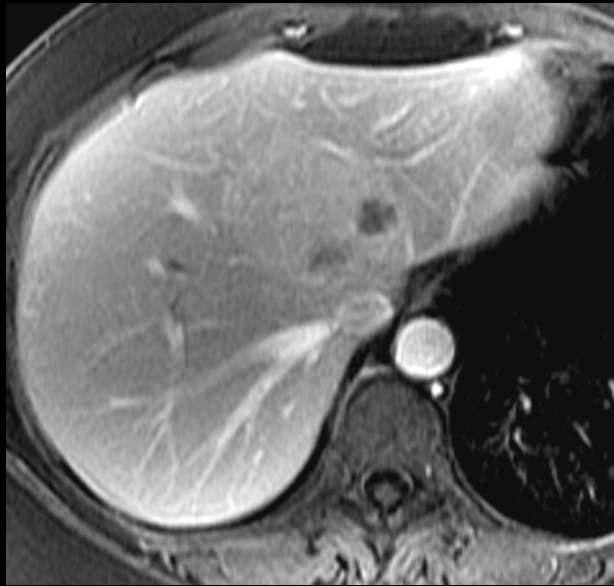
6

femme, 65 ans







Patiente fumeuse

**Radio thorax : opacité
suspecte apicale**

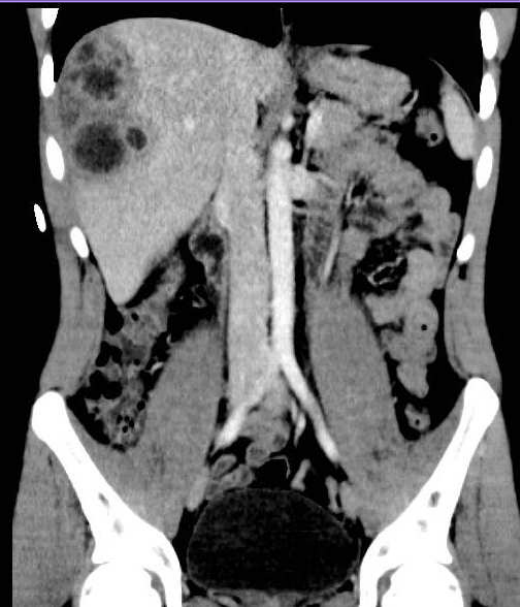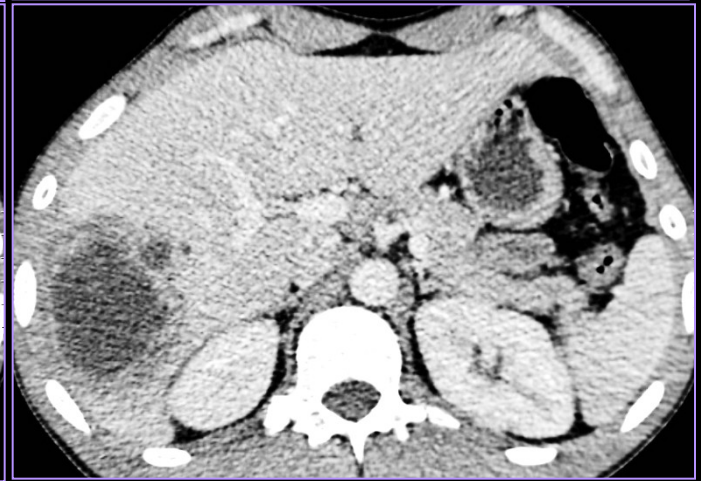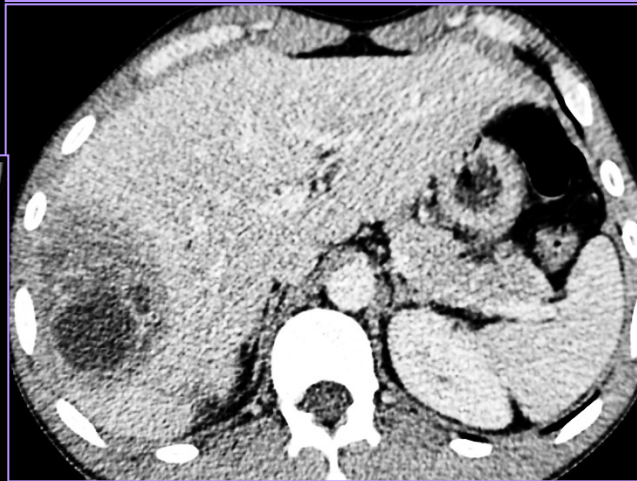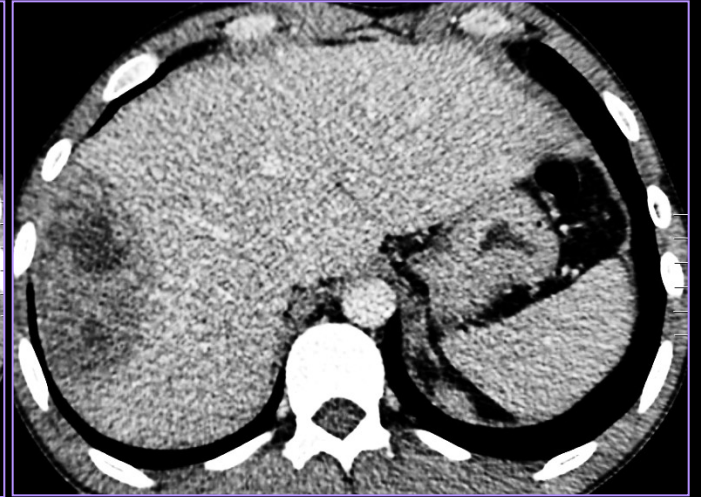
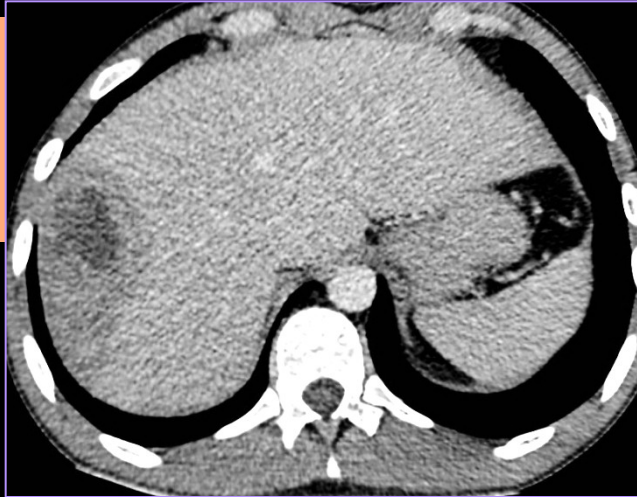
HNF

Et

métastases

Homme, 35 ans, origine marocaine (séjour récent).
Douleur de l'hypochondre, fièvre, ictère.

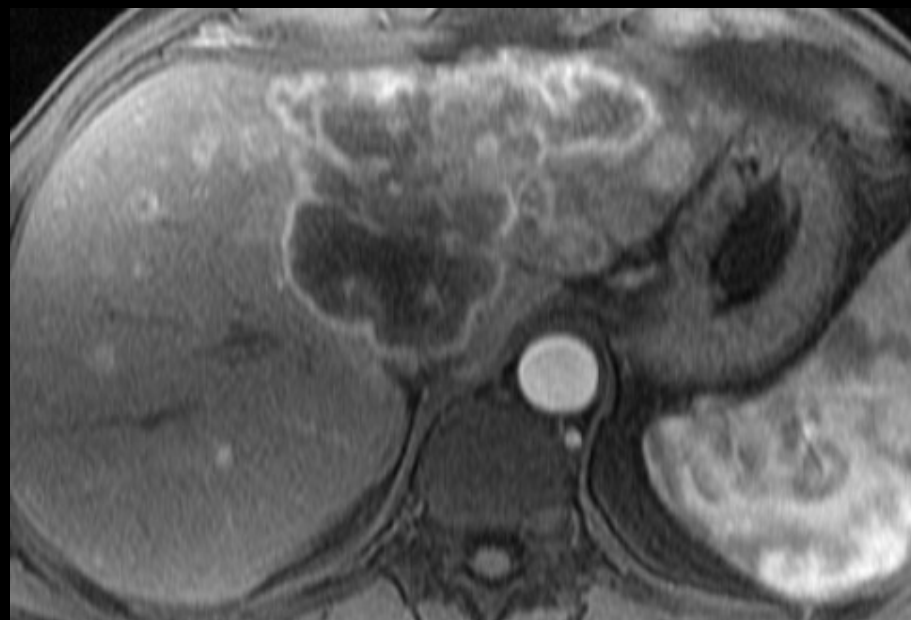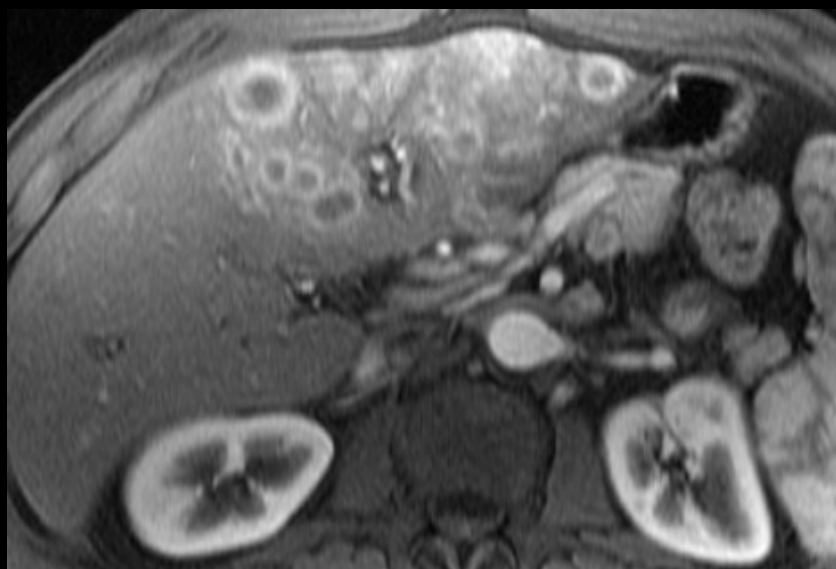
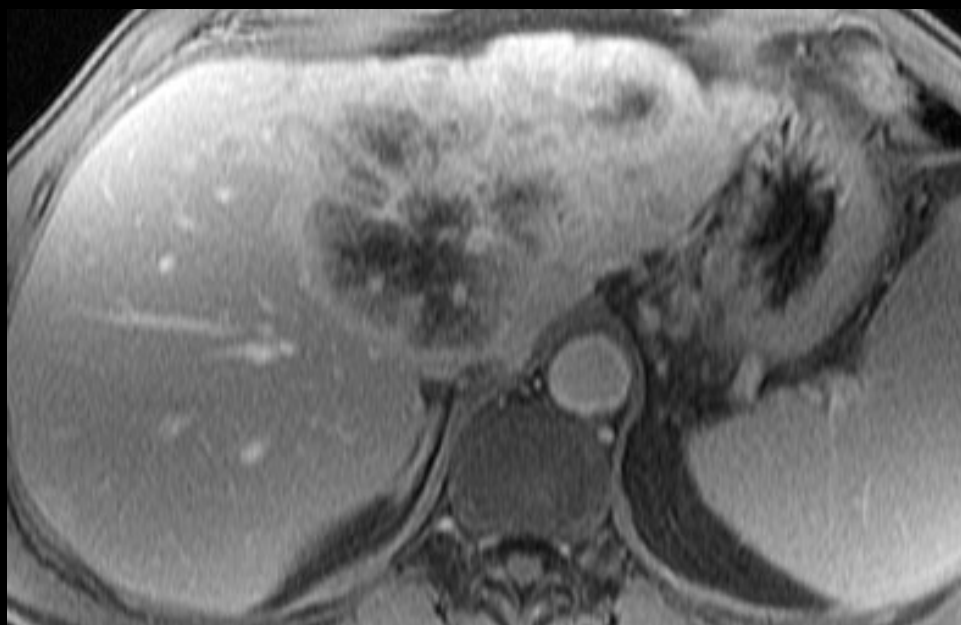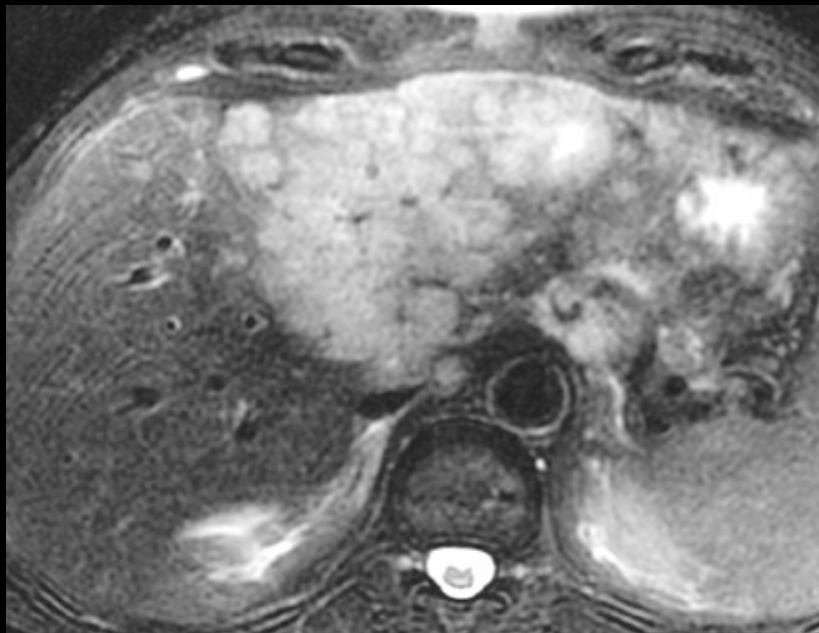
Abcès à pyogènes
(ici *Prevotella*
Buccae)



8

femme, 65 ans

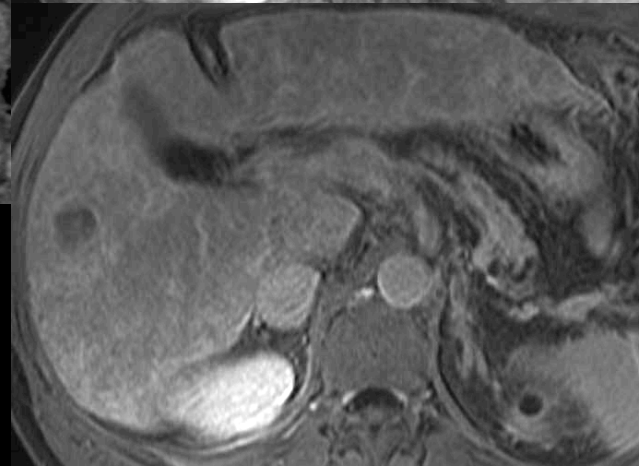
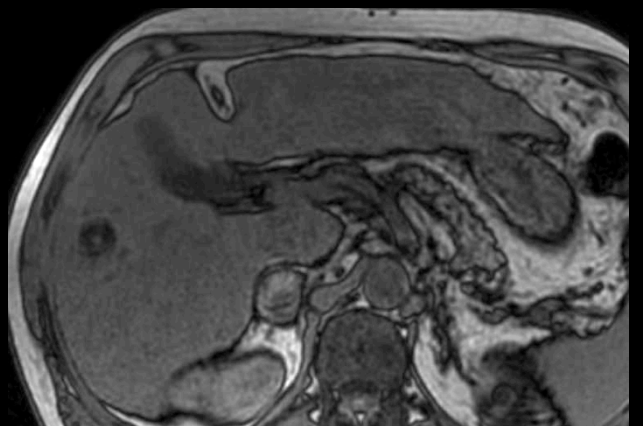
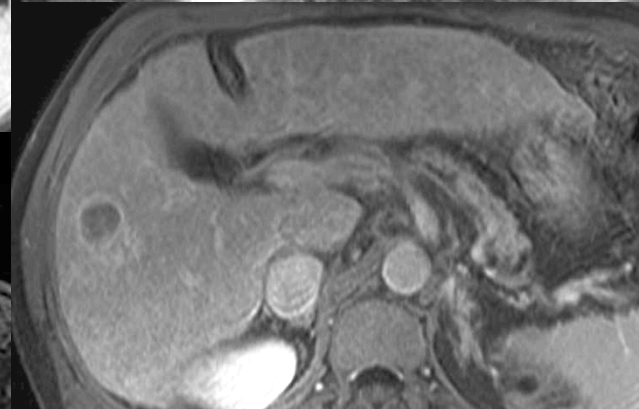
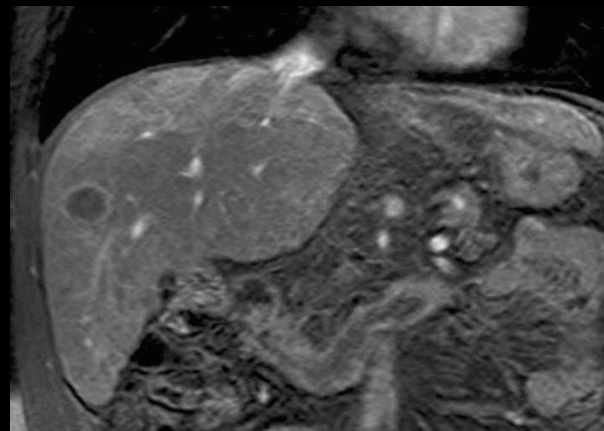
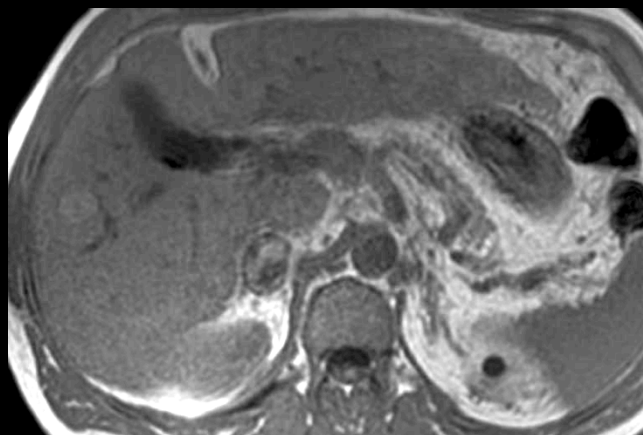
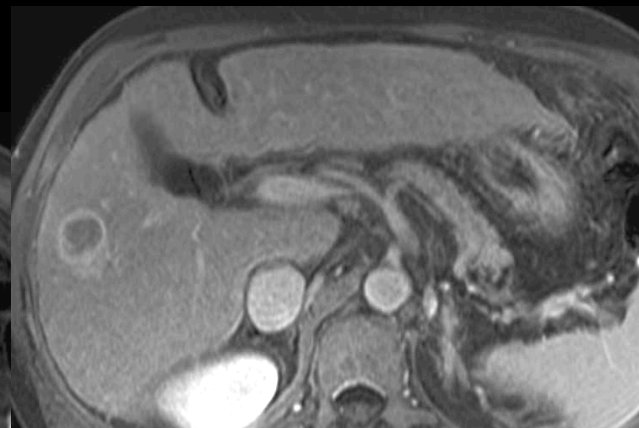
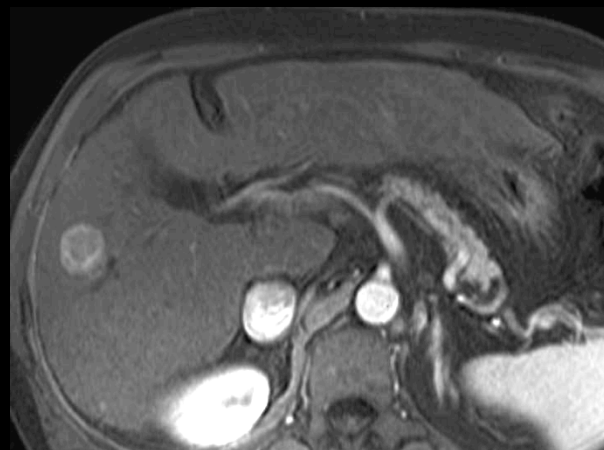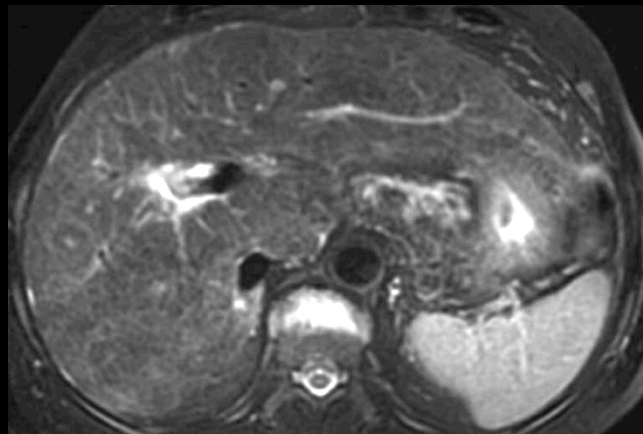
Cholangiocarcinome intra hépatique



9

Homme, 60 ans

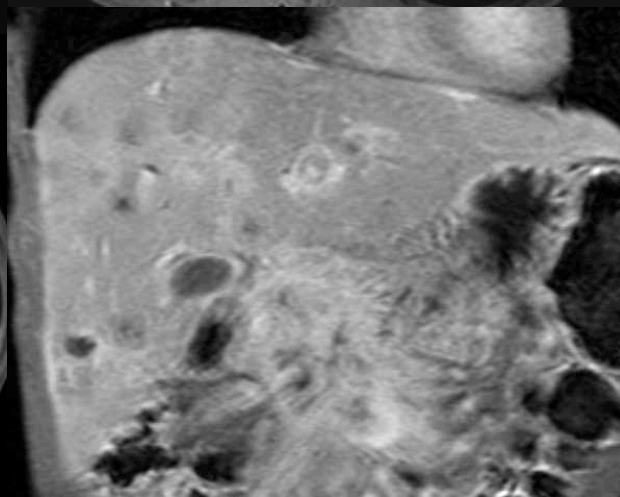
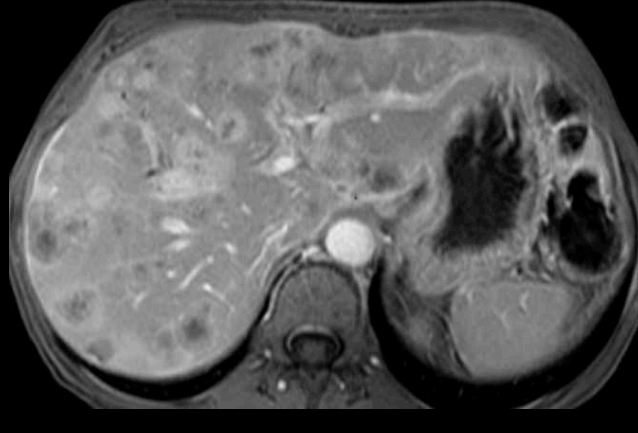
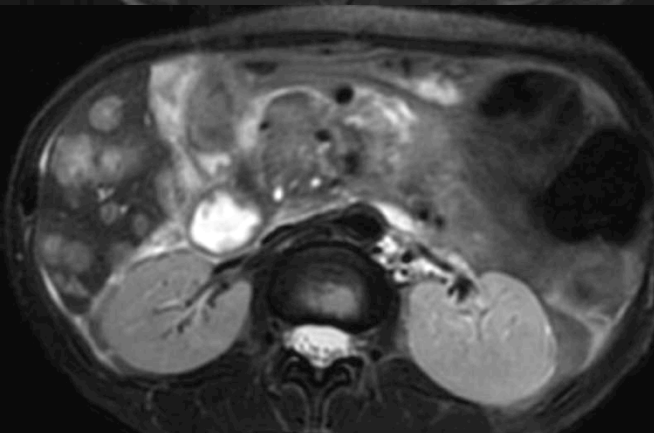
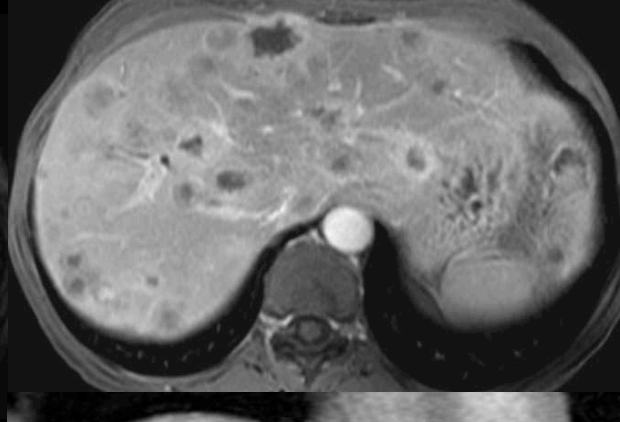
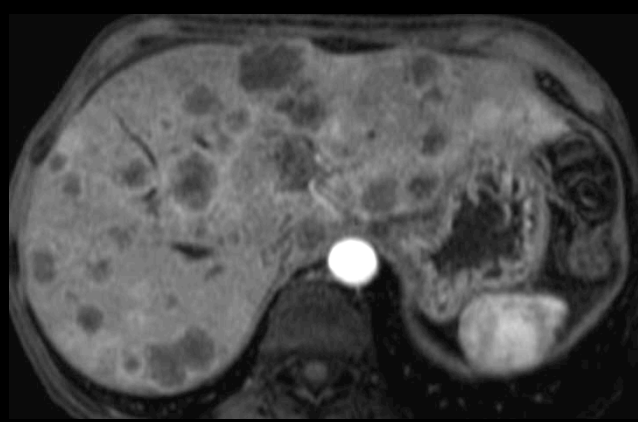
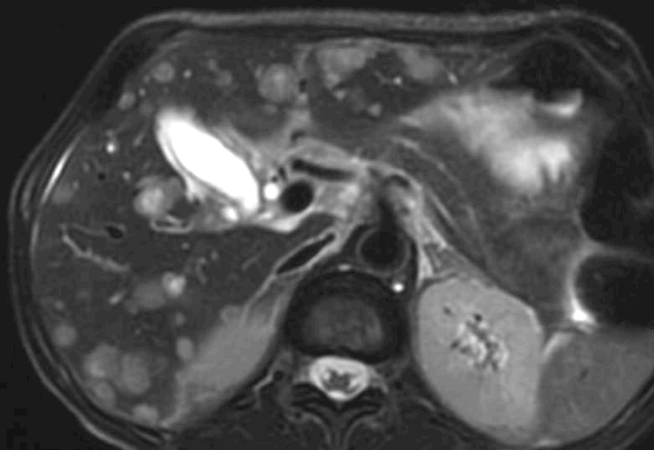
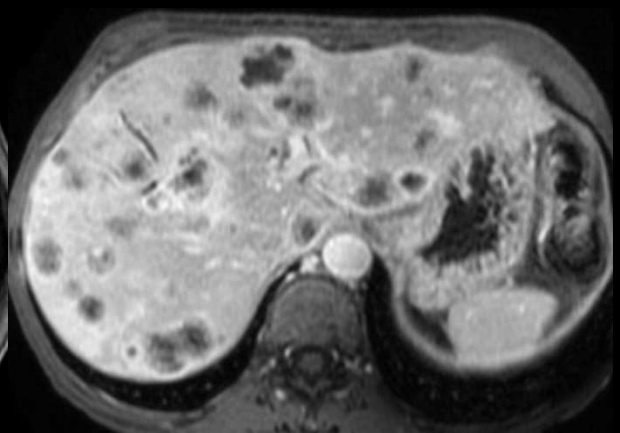
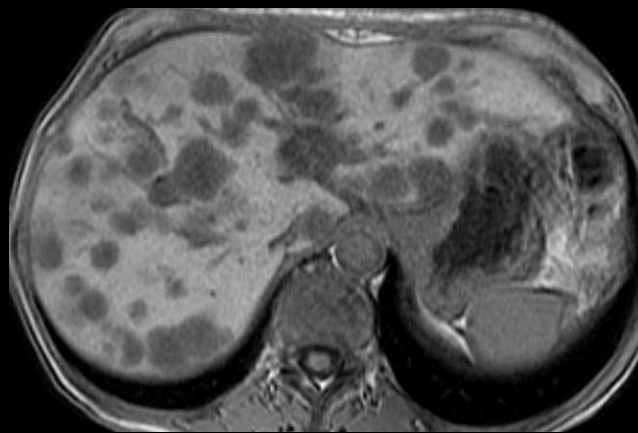
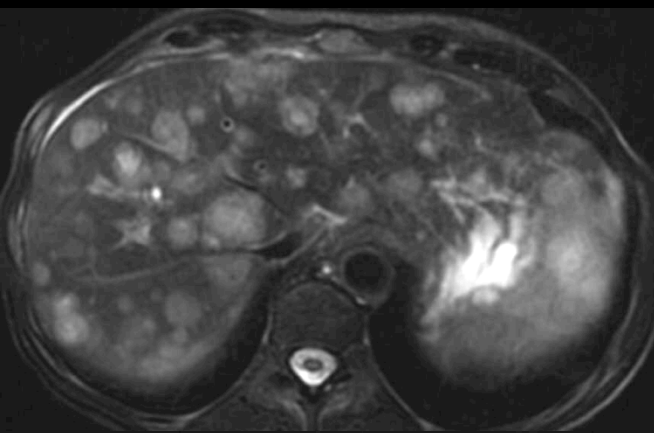
CHC bien différencié



10

femme, 45 ans

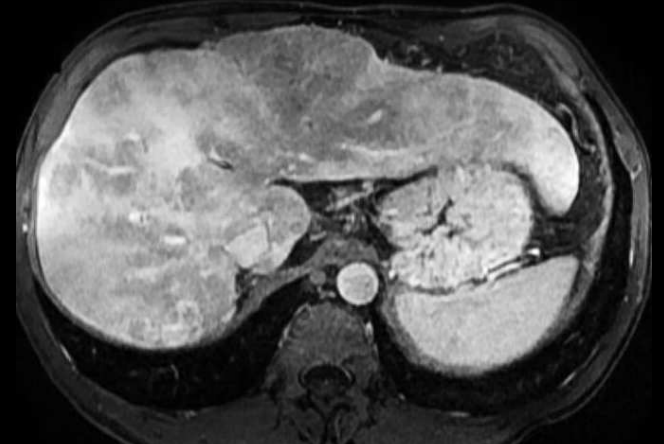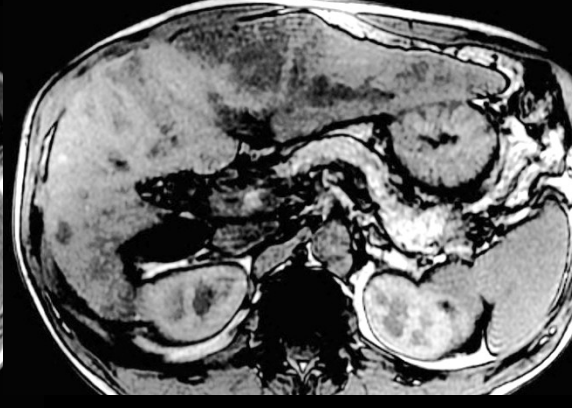
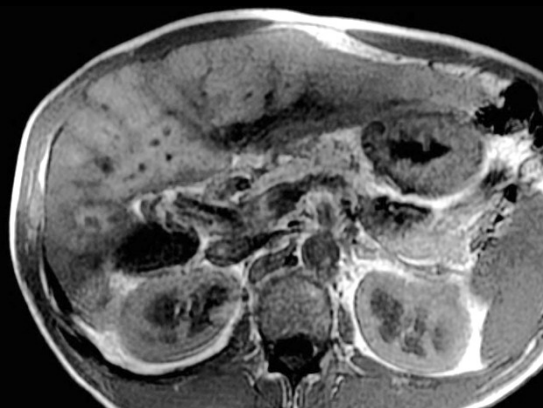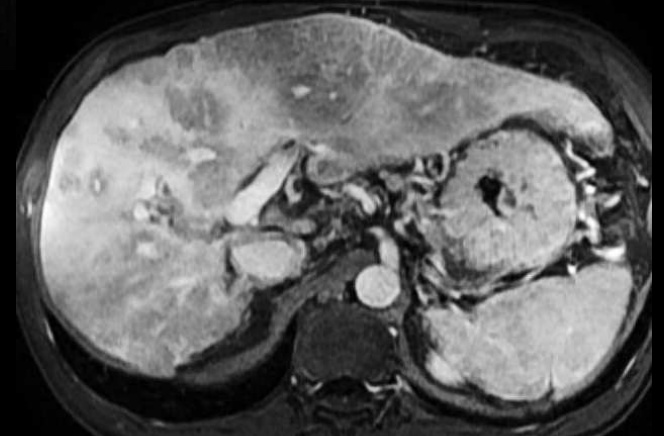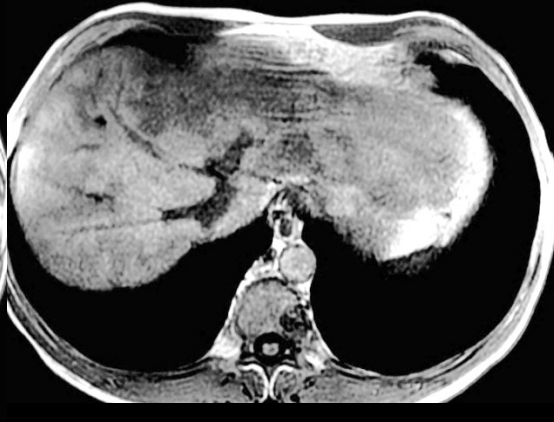
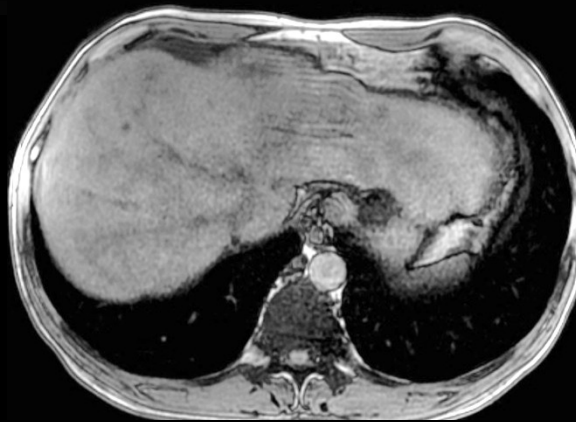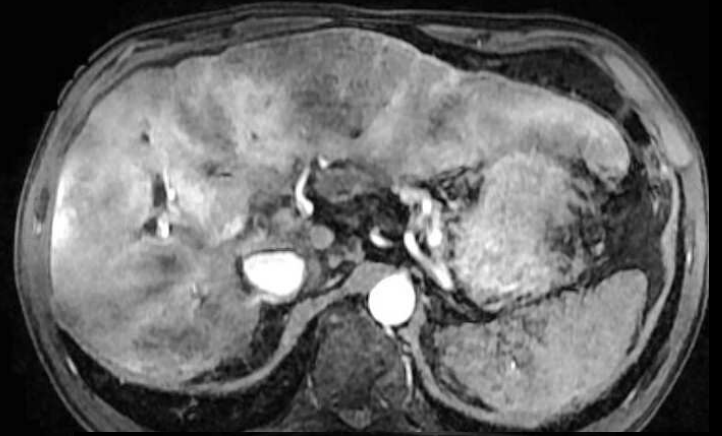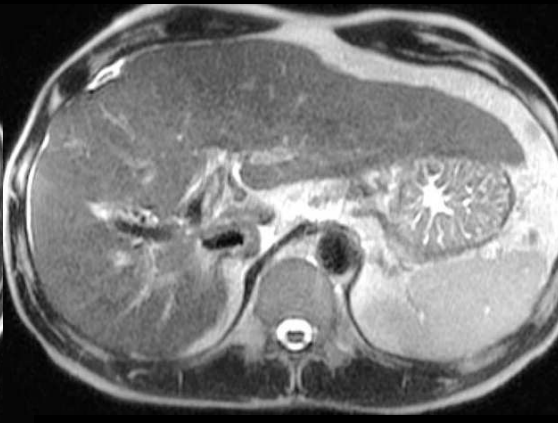
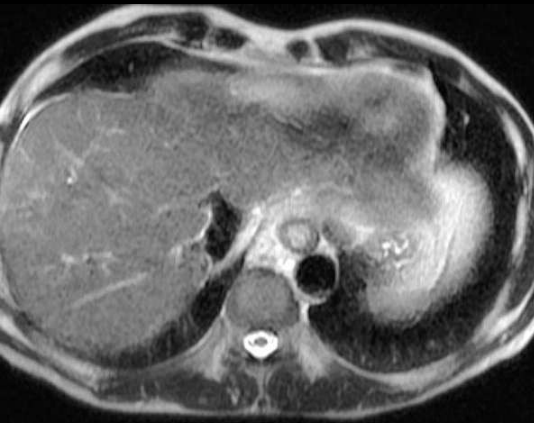
Métastases de tumeur du pancréas



11

Homme, 50 ans

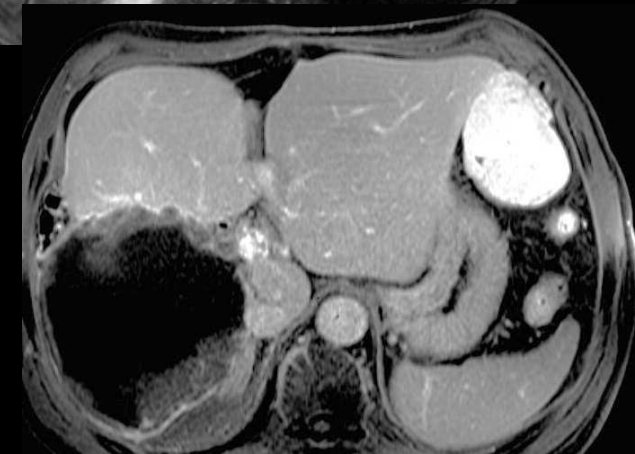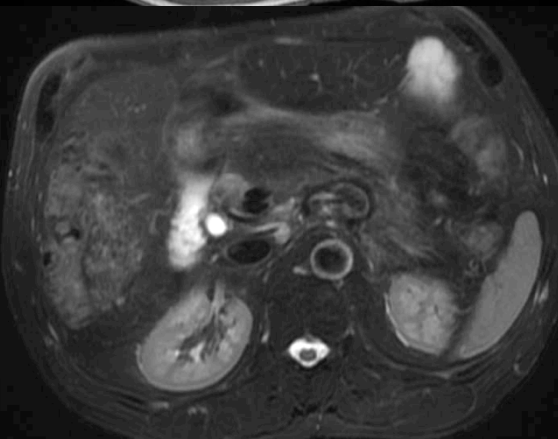
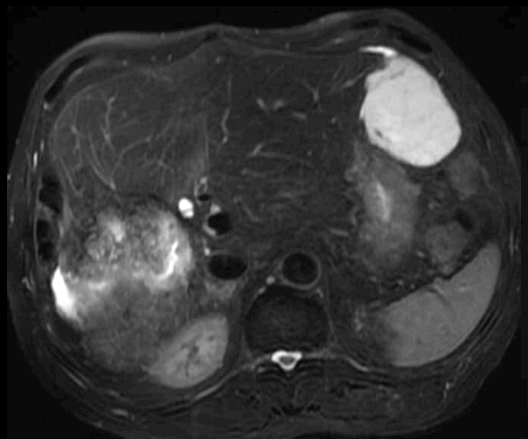
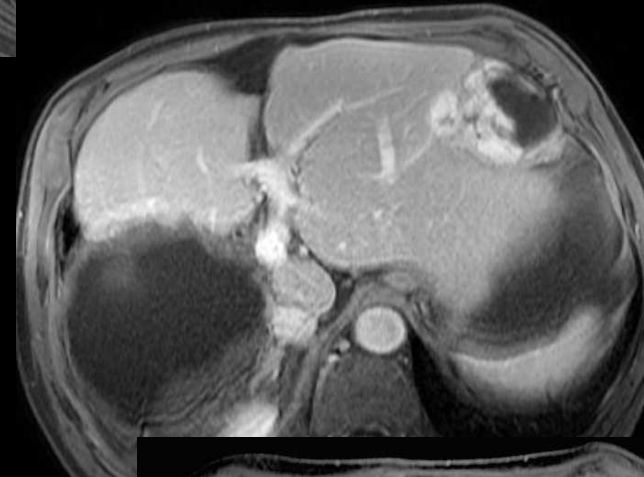
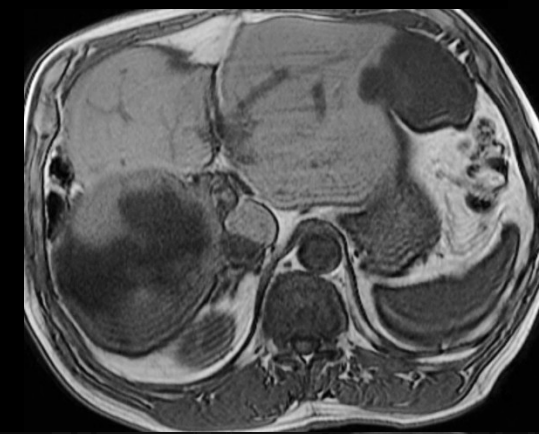
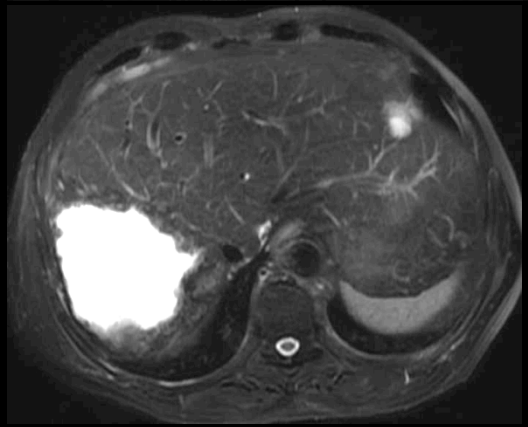
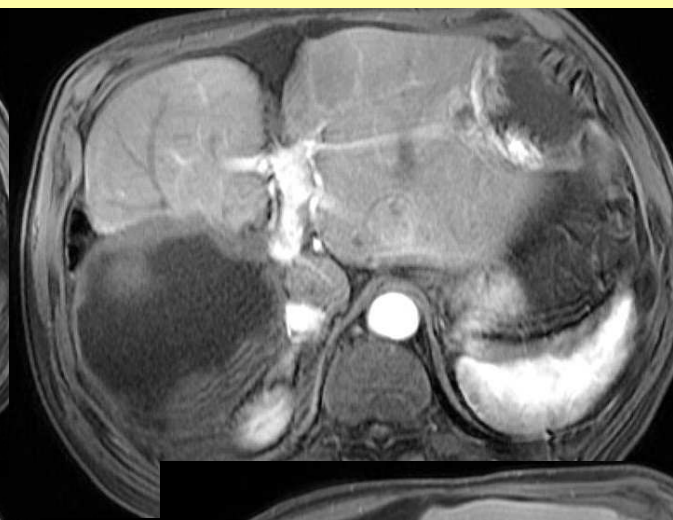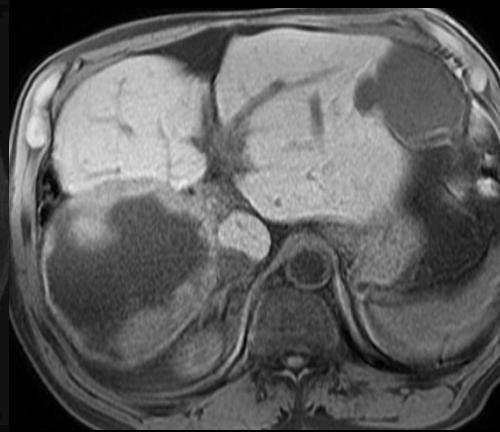
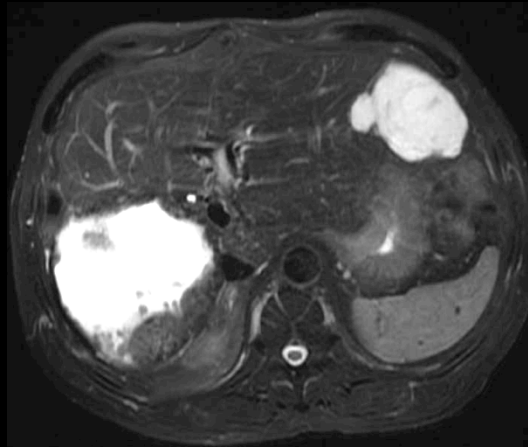
Cirrhose et stéatose périvasculaire



12

homme, 70 ans

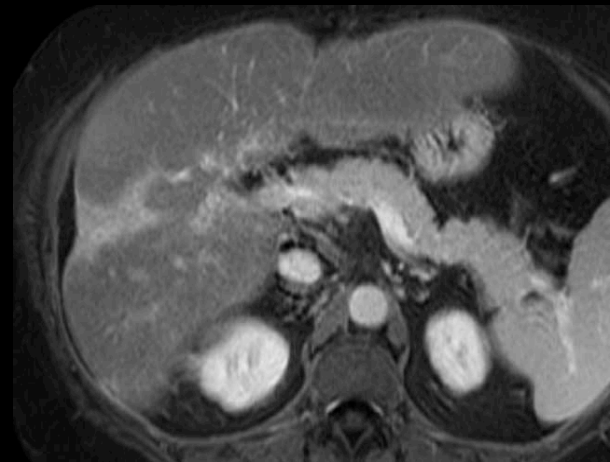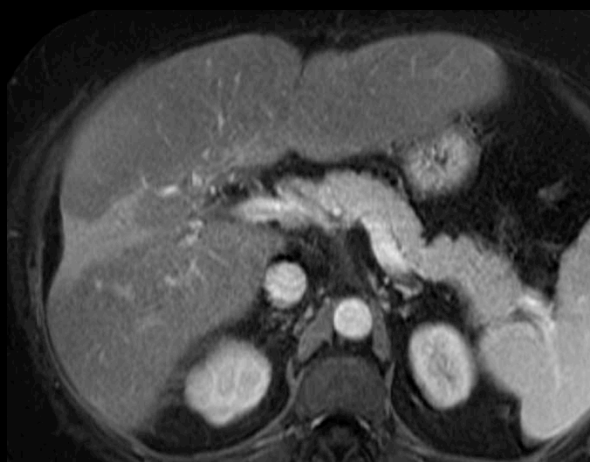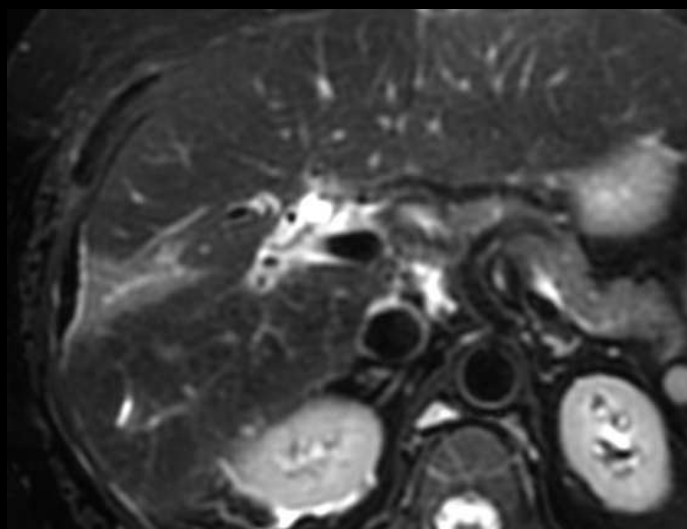
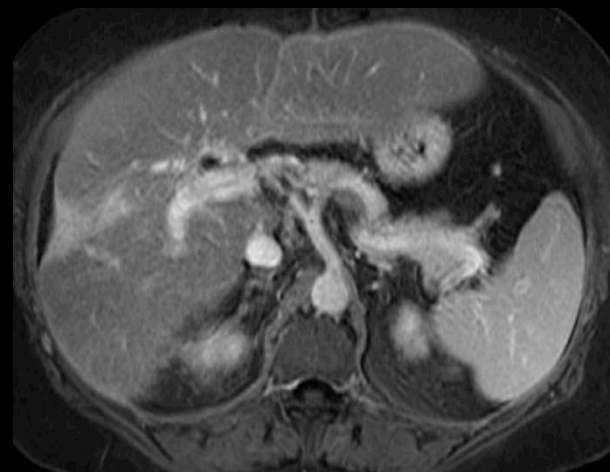
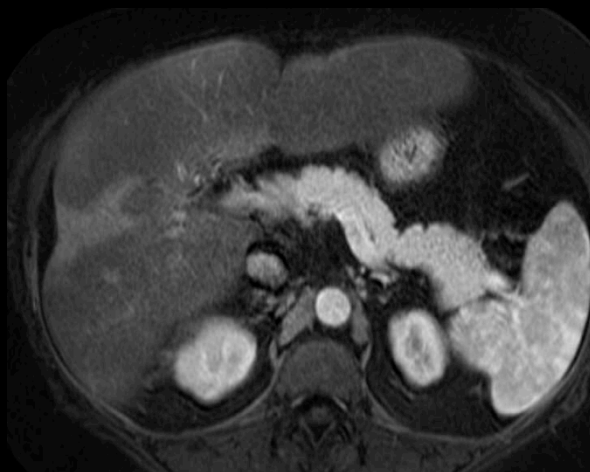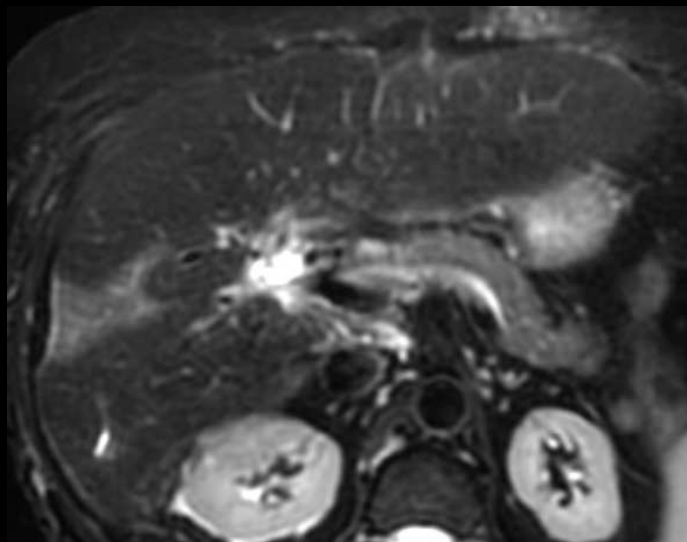
Echinococcose et angiome



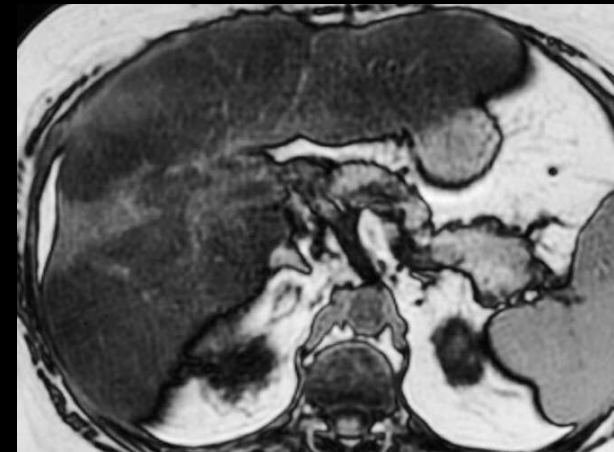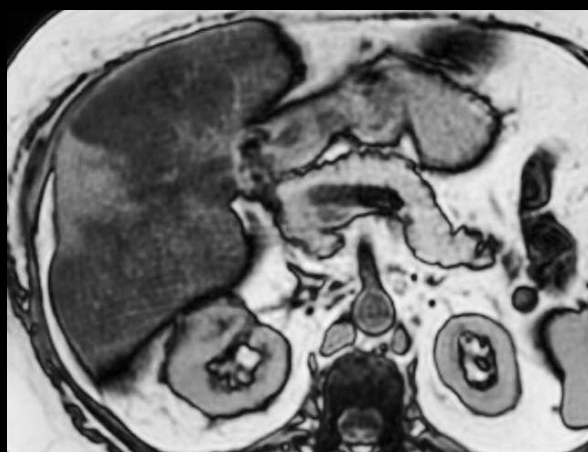
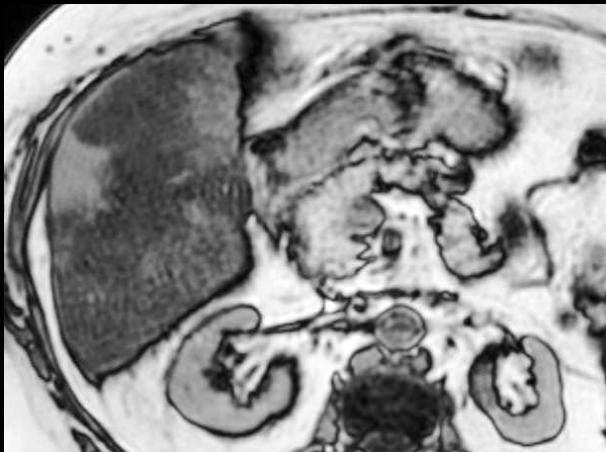
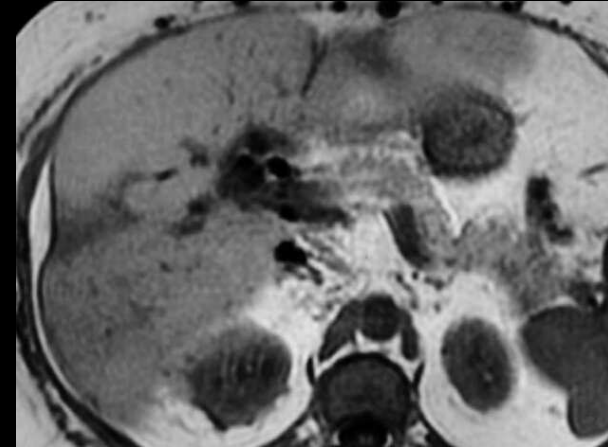
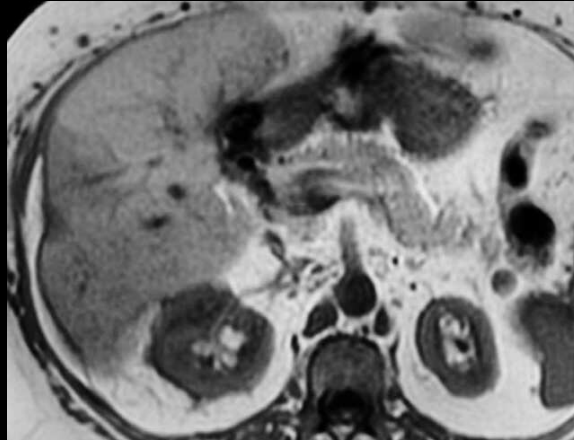
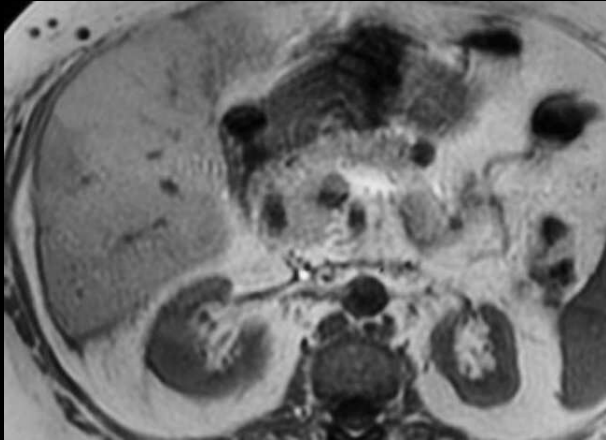
13

homme, 55 ans

Séquence clé ?



IP/OP

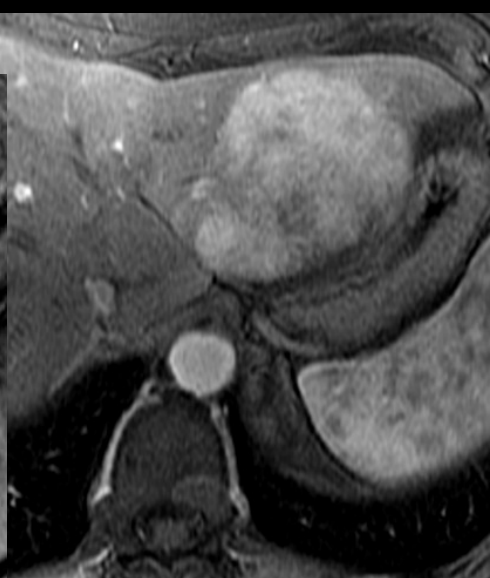
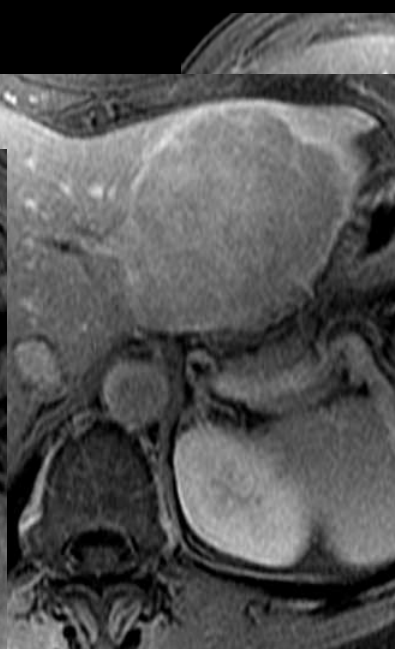
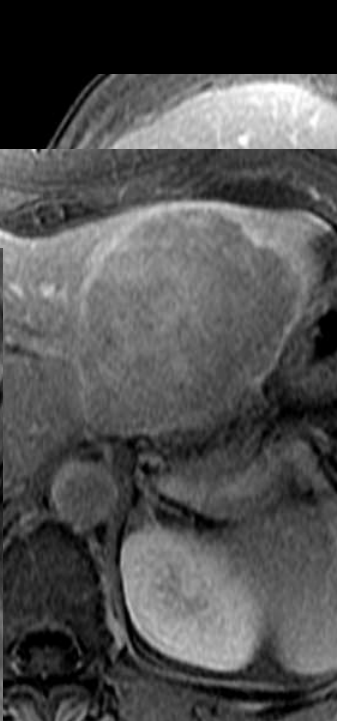
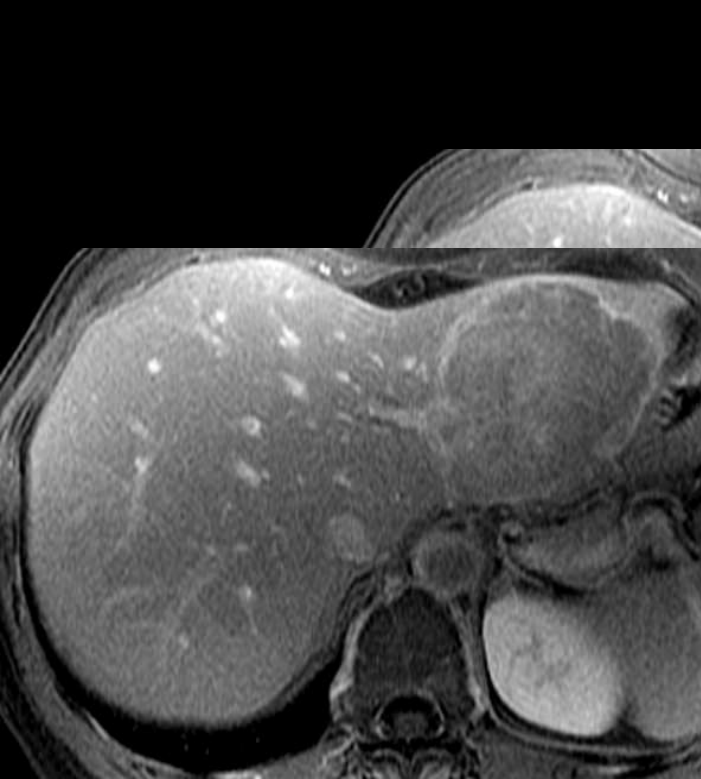
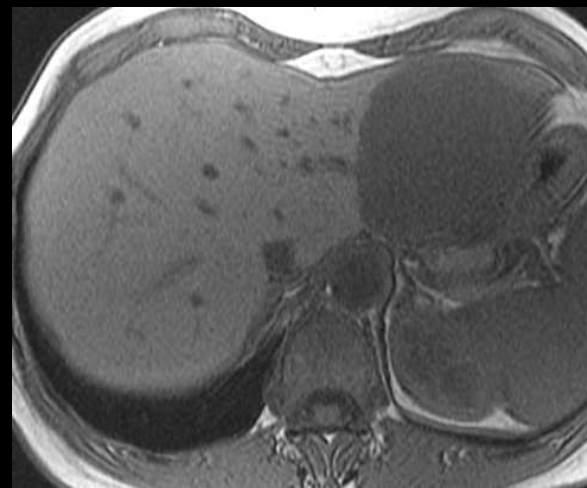
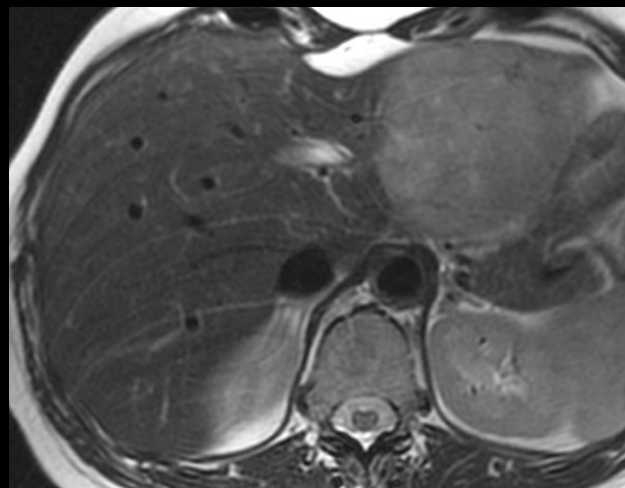
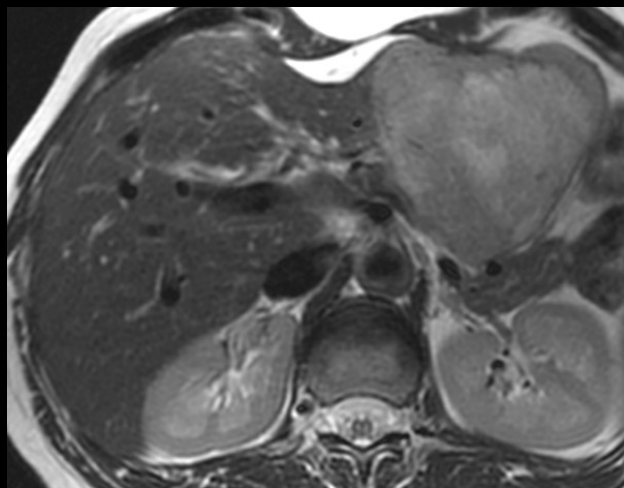


Plaque de fibrose et foie stéatosique

14

femme, 50 ans

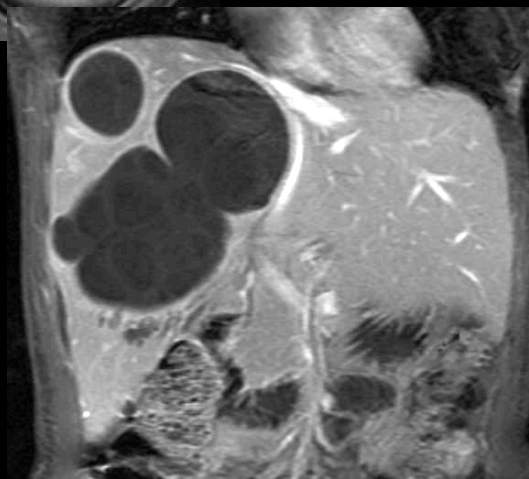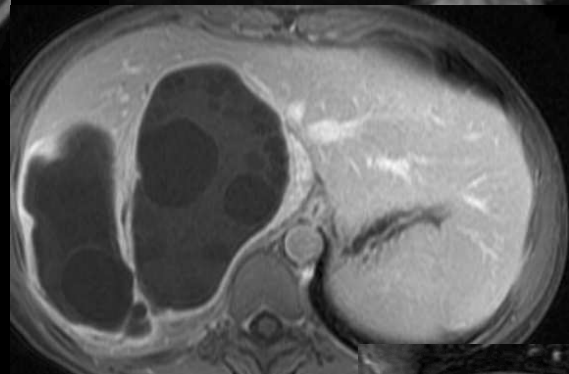
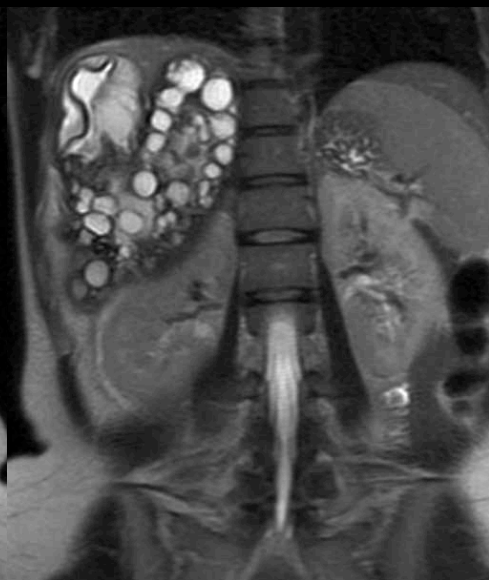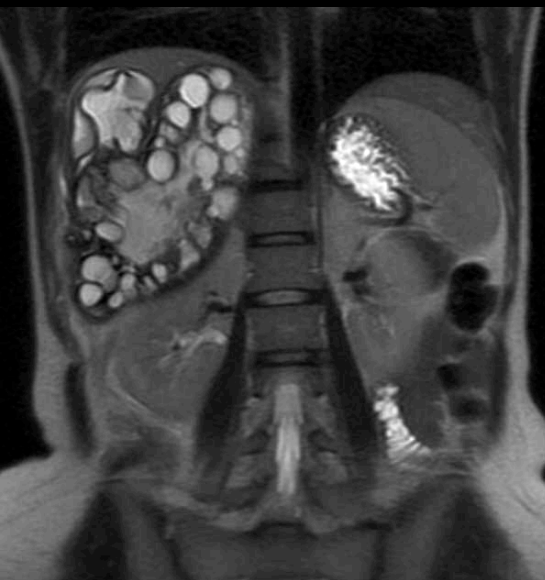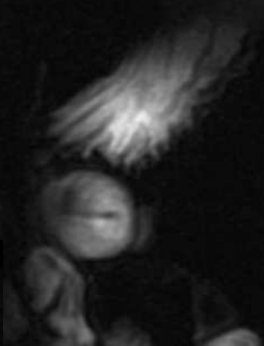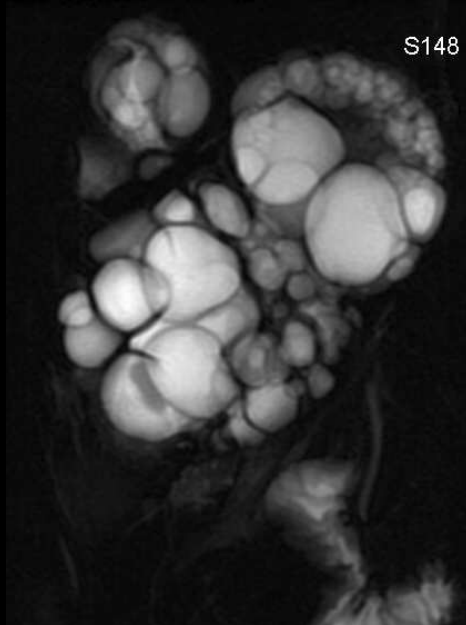
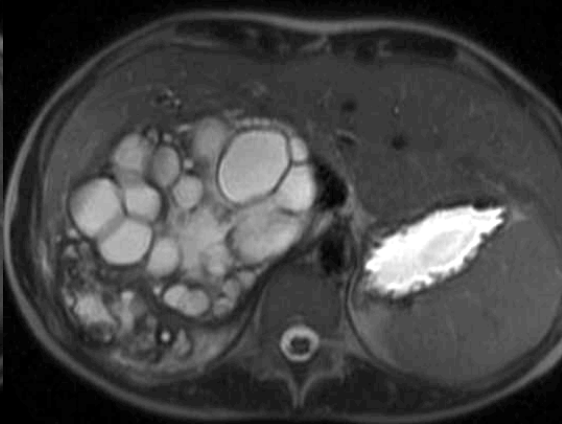
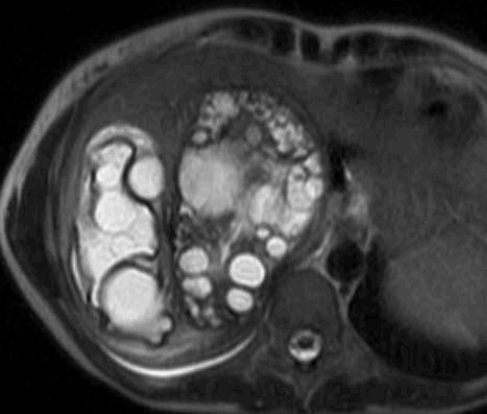
Carcinome hépatocellulaire sur foie sain



15

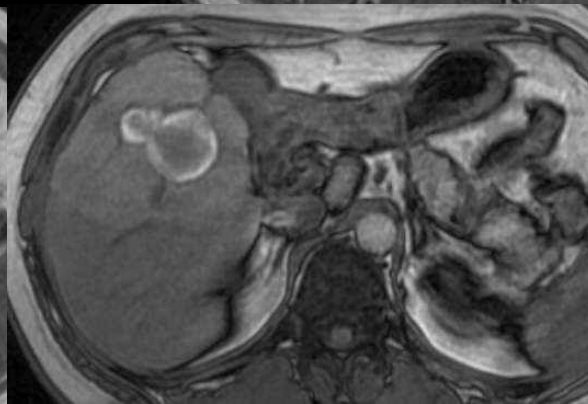
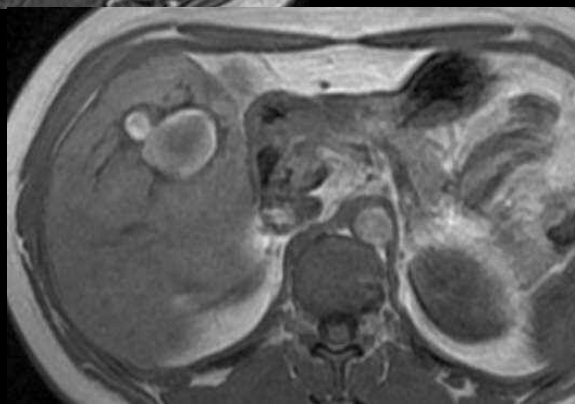
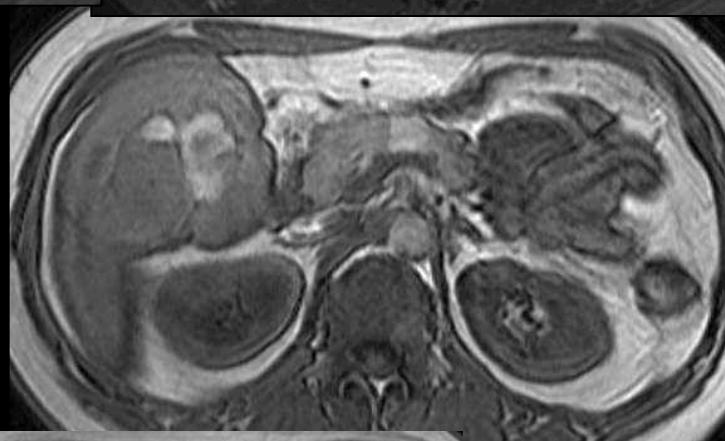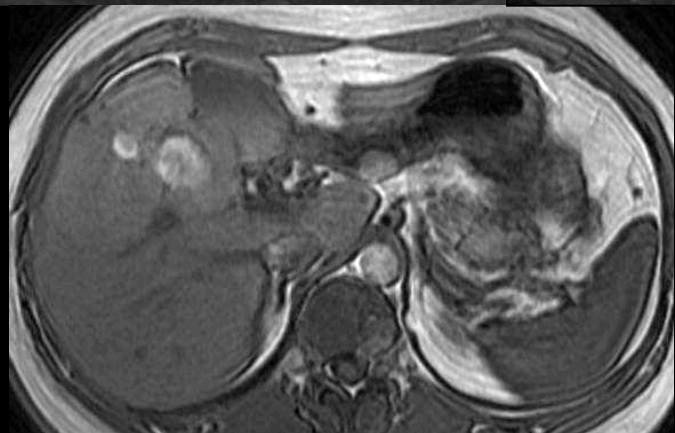
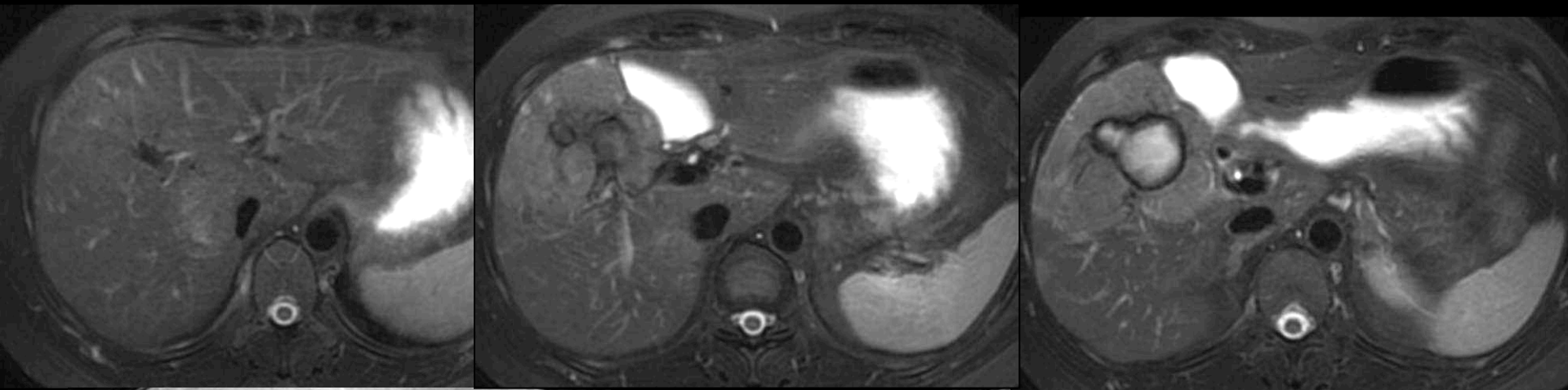femme, 30 ans

Kyste hydatique

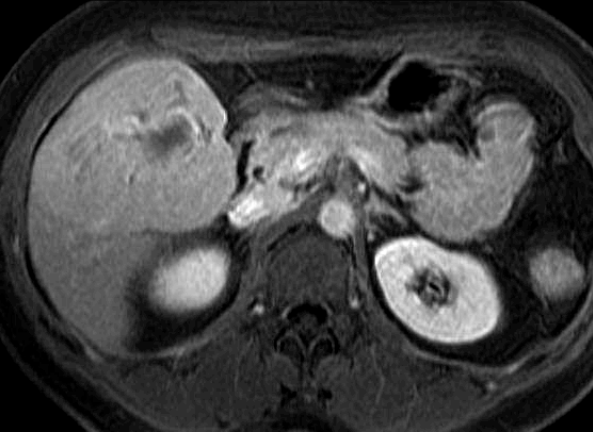
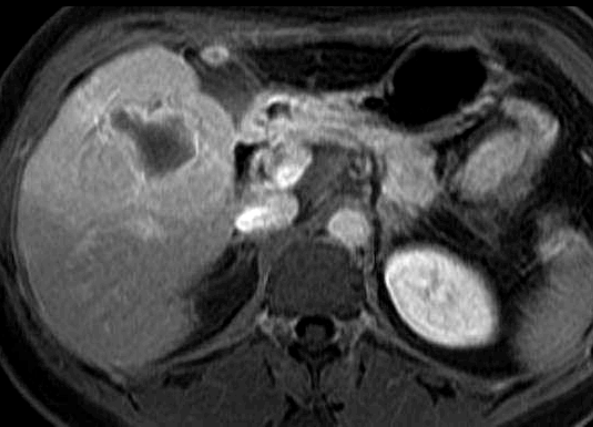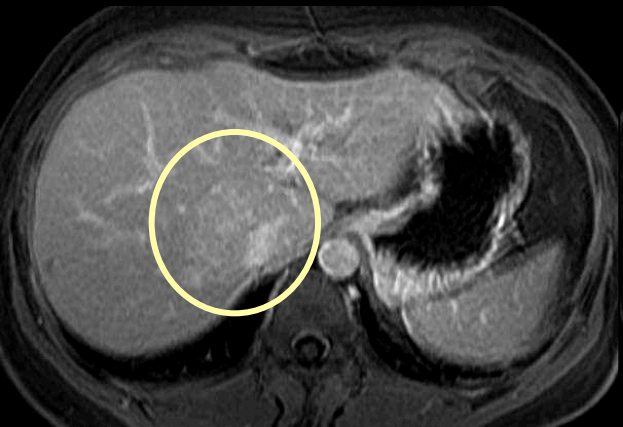
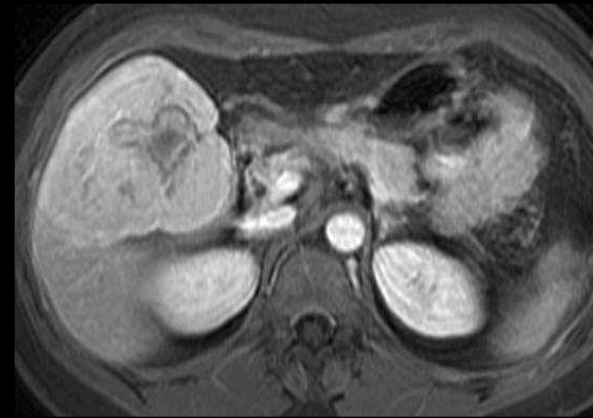
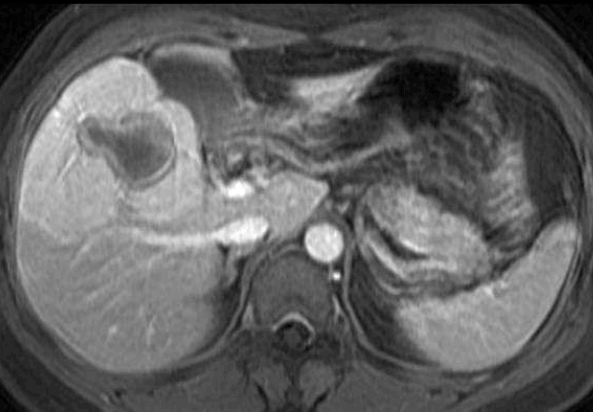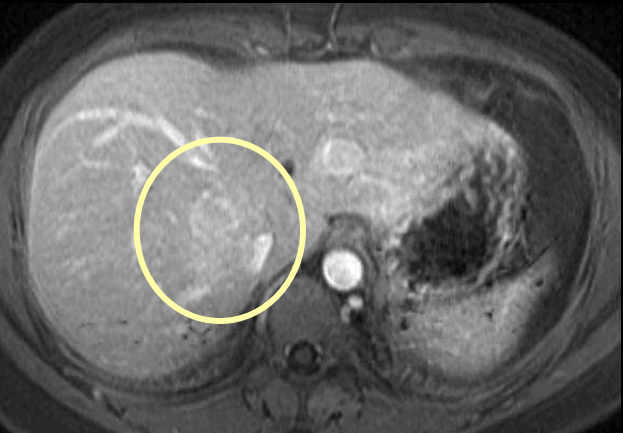


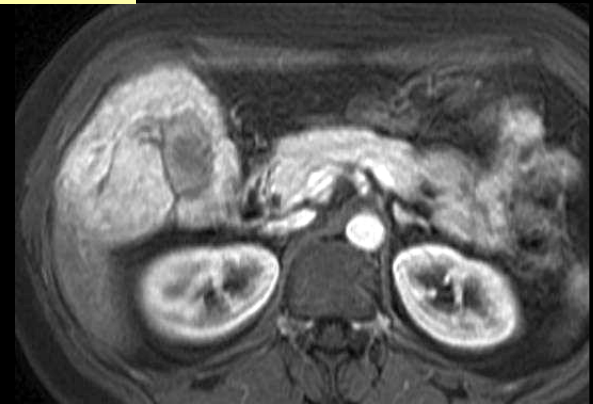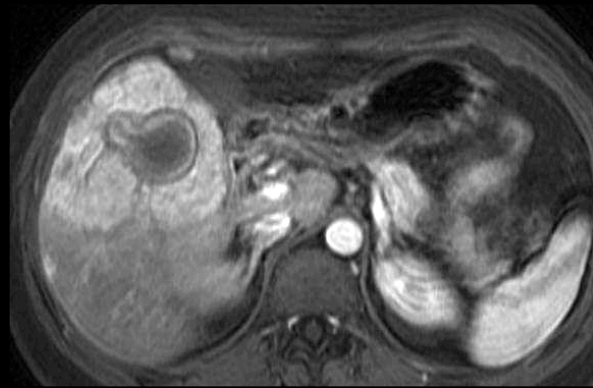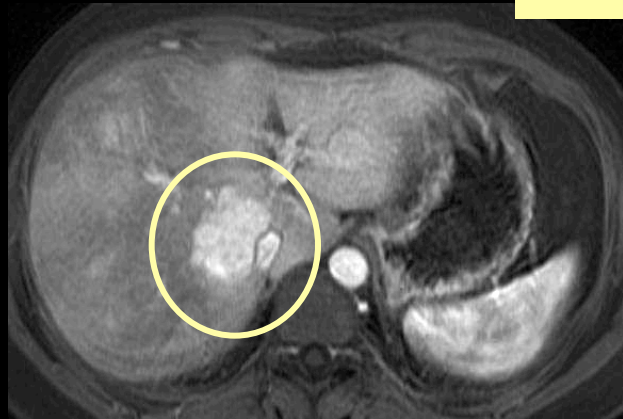16

femme, 40 ans



Adénome hémorragique et HNF



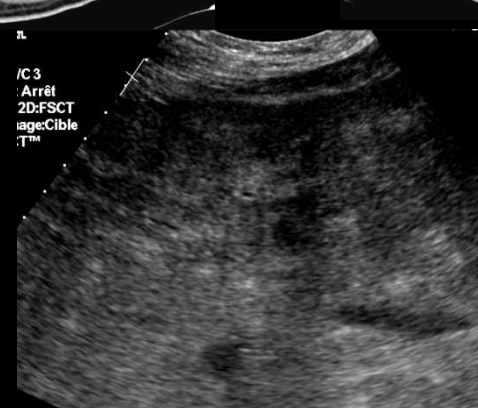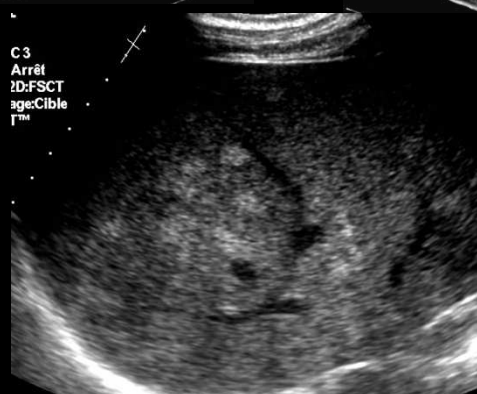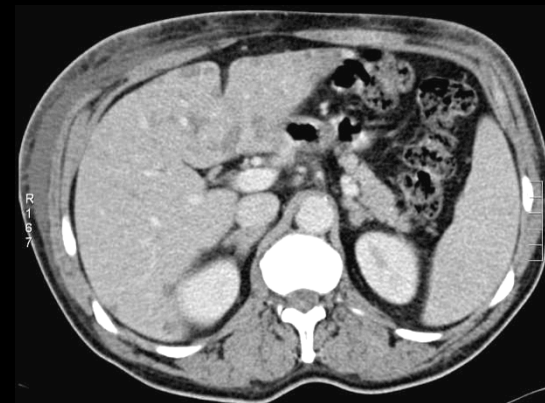
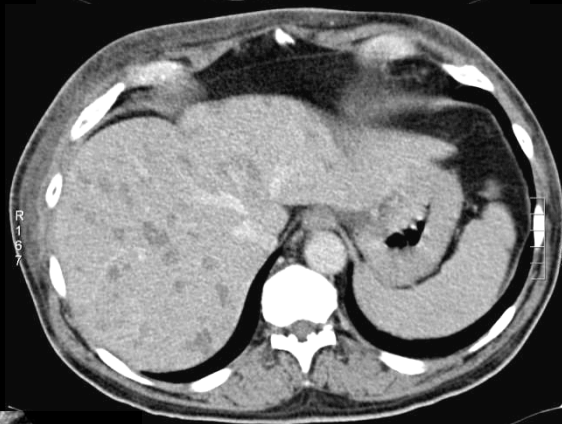
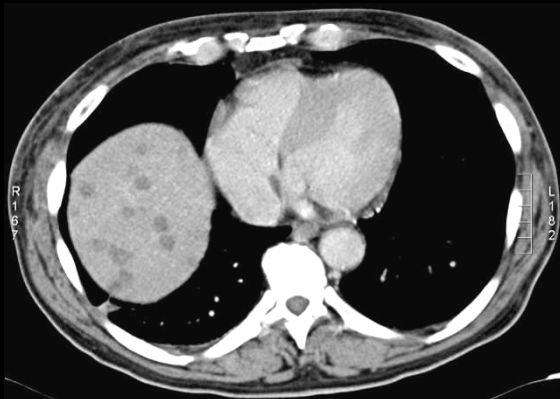
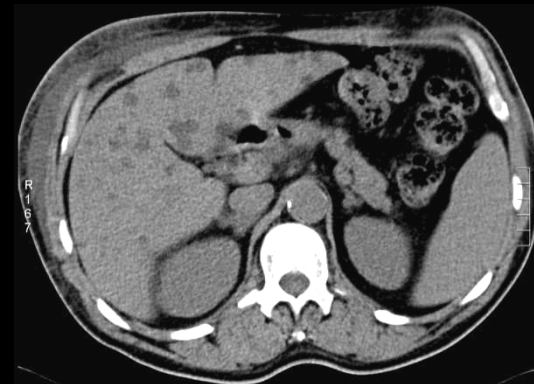
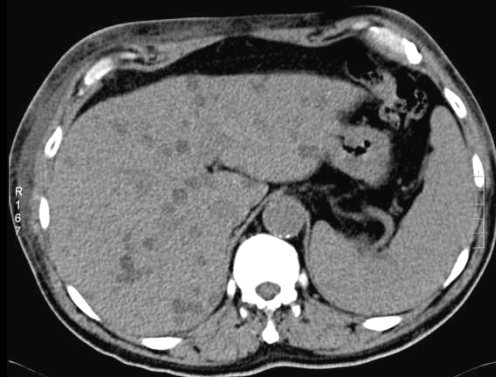
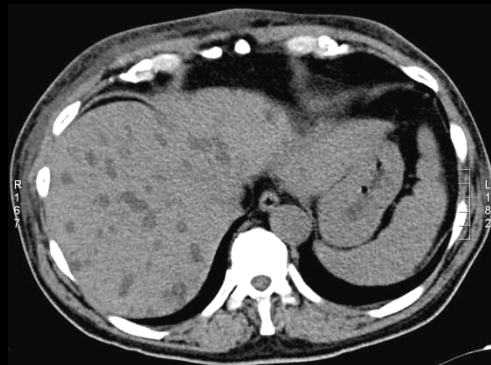17

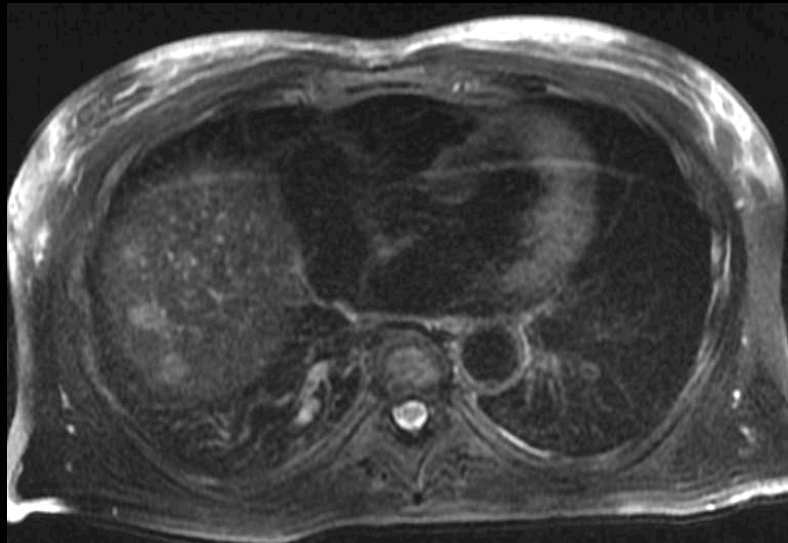
Homme 59 ans

Antécédent d' hépatite C traitée par interféron et Ribavirine pendant 8 mois

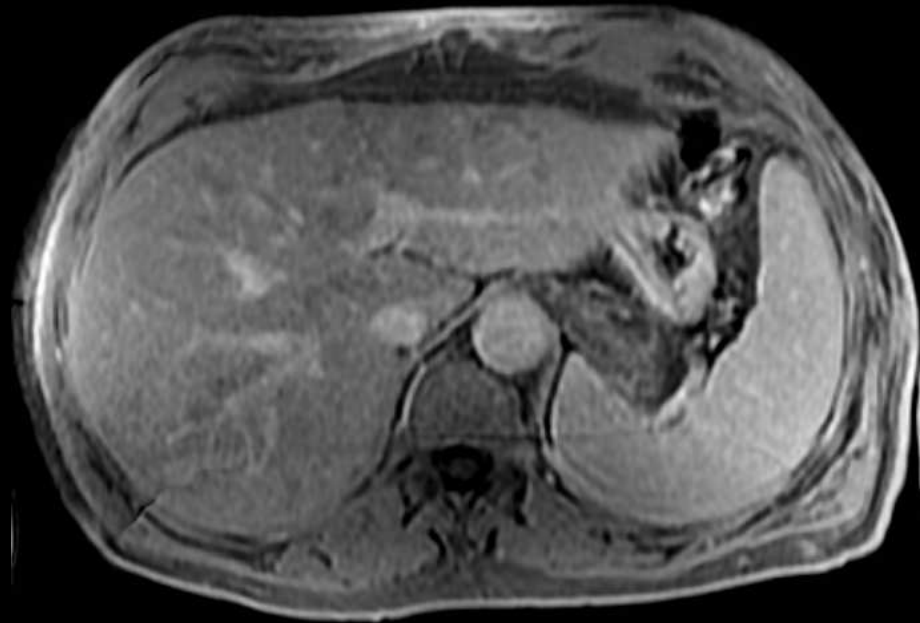Fièvre

Bilan infectieux négatif

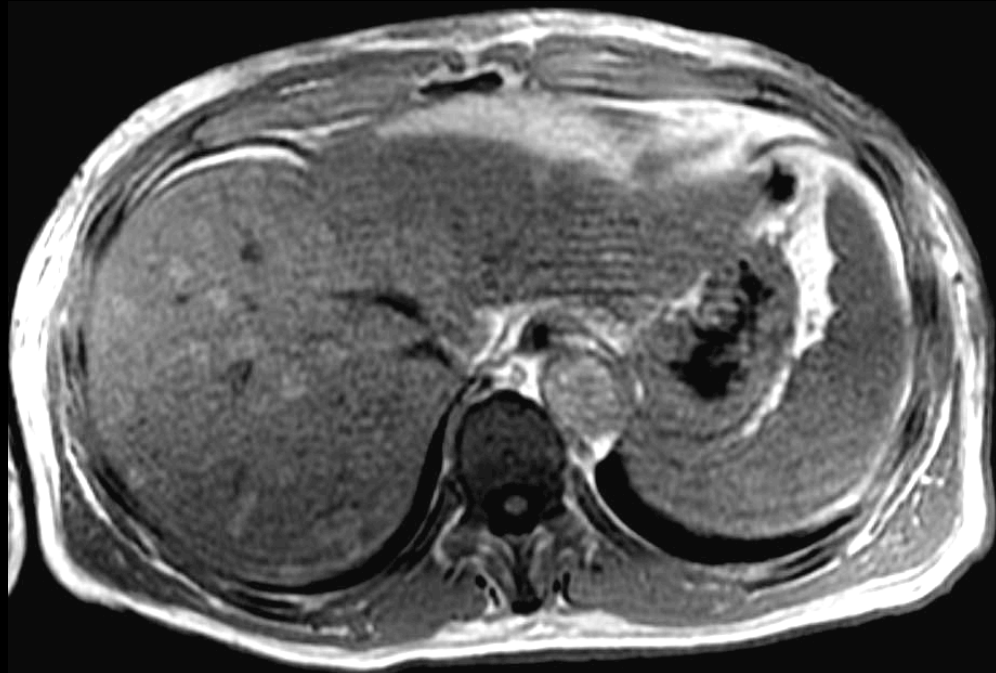




Ax T2 FS

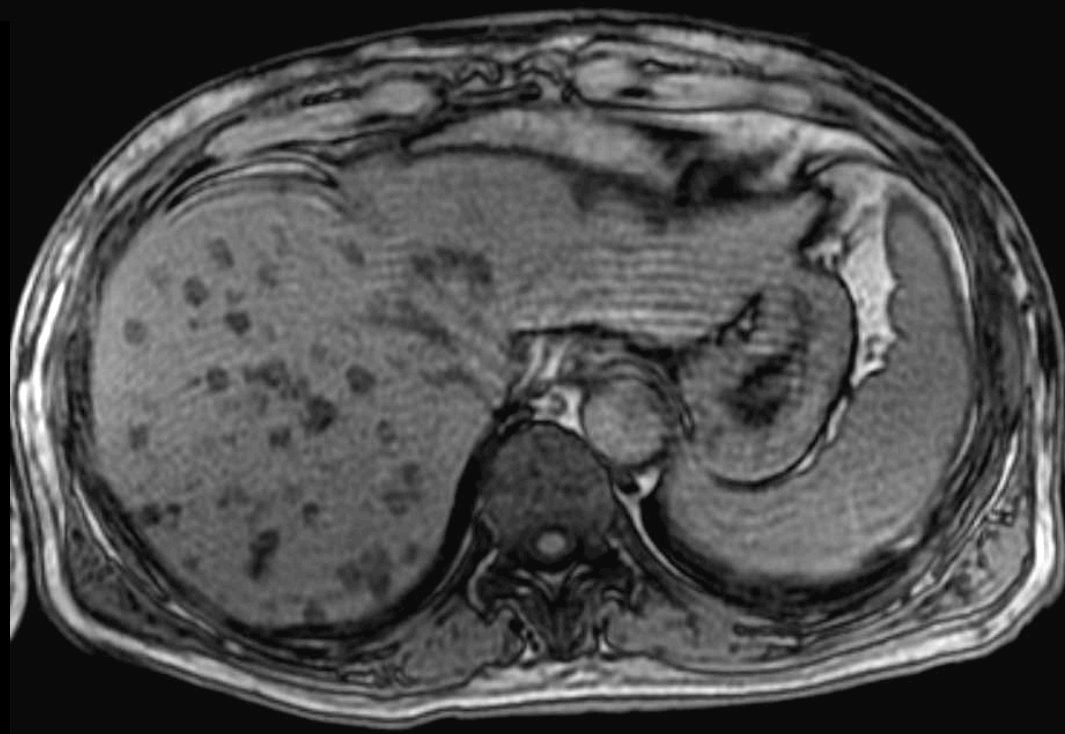


Ax T1 Gd FS



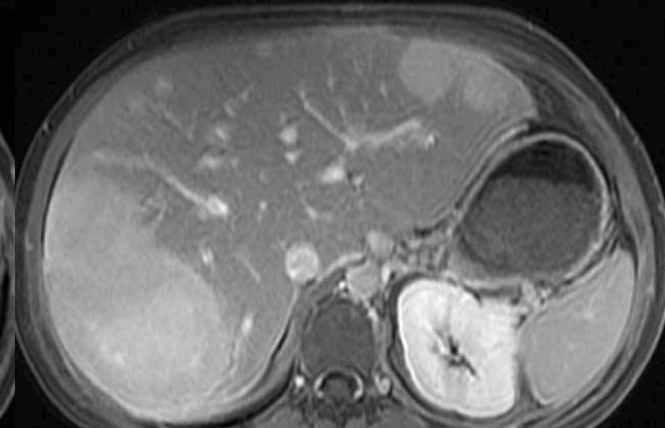
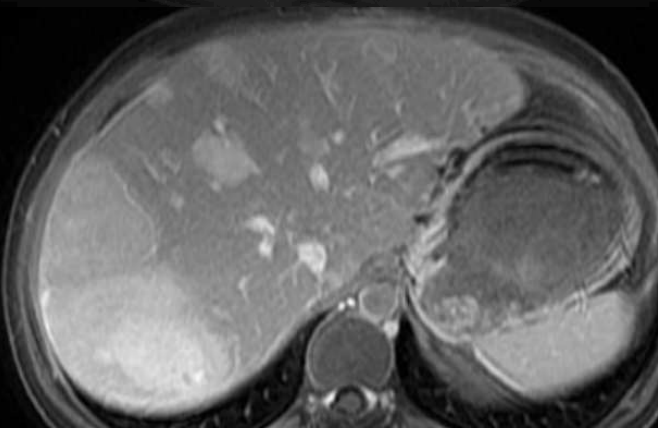
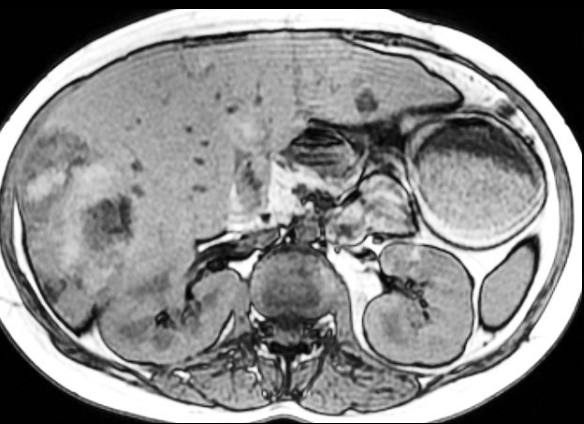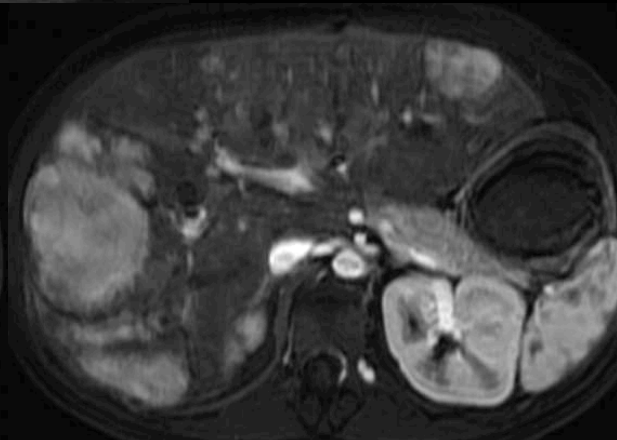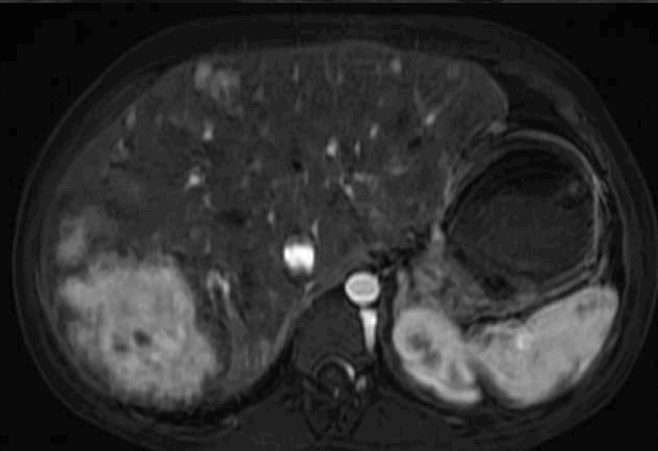
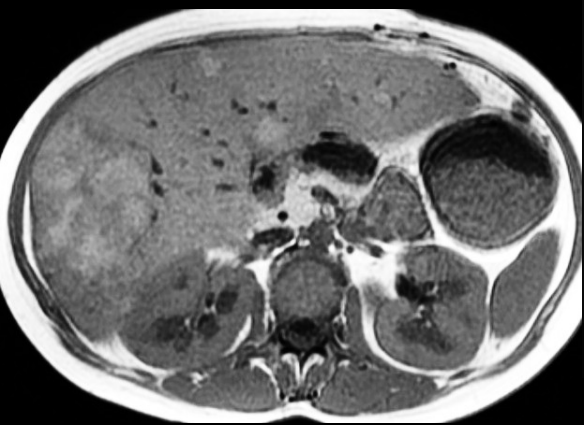
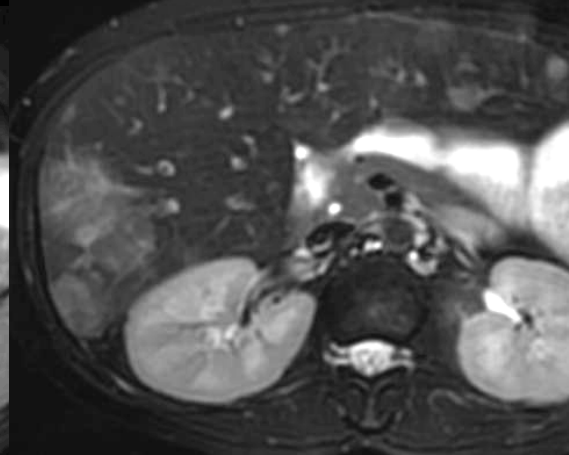
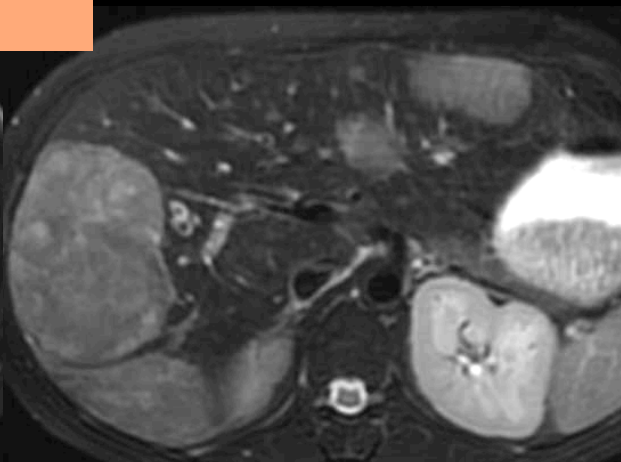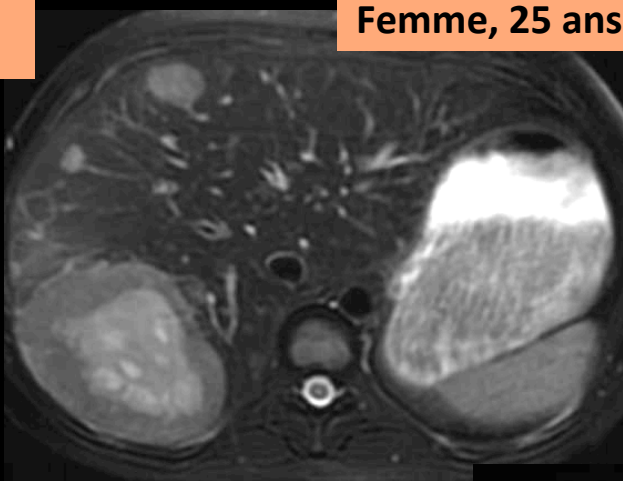
Ax IP/OP

**Stéatose
nodulaire
multifocale**



18

Femme, 25 ans



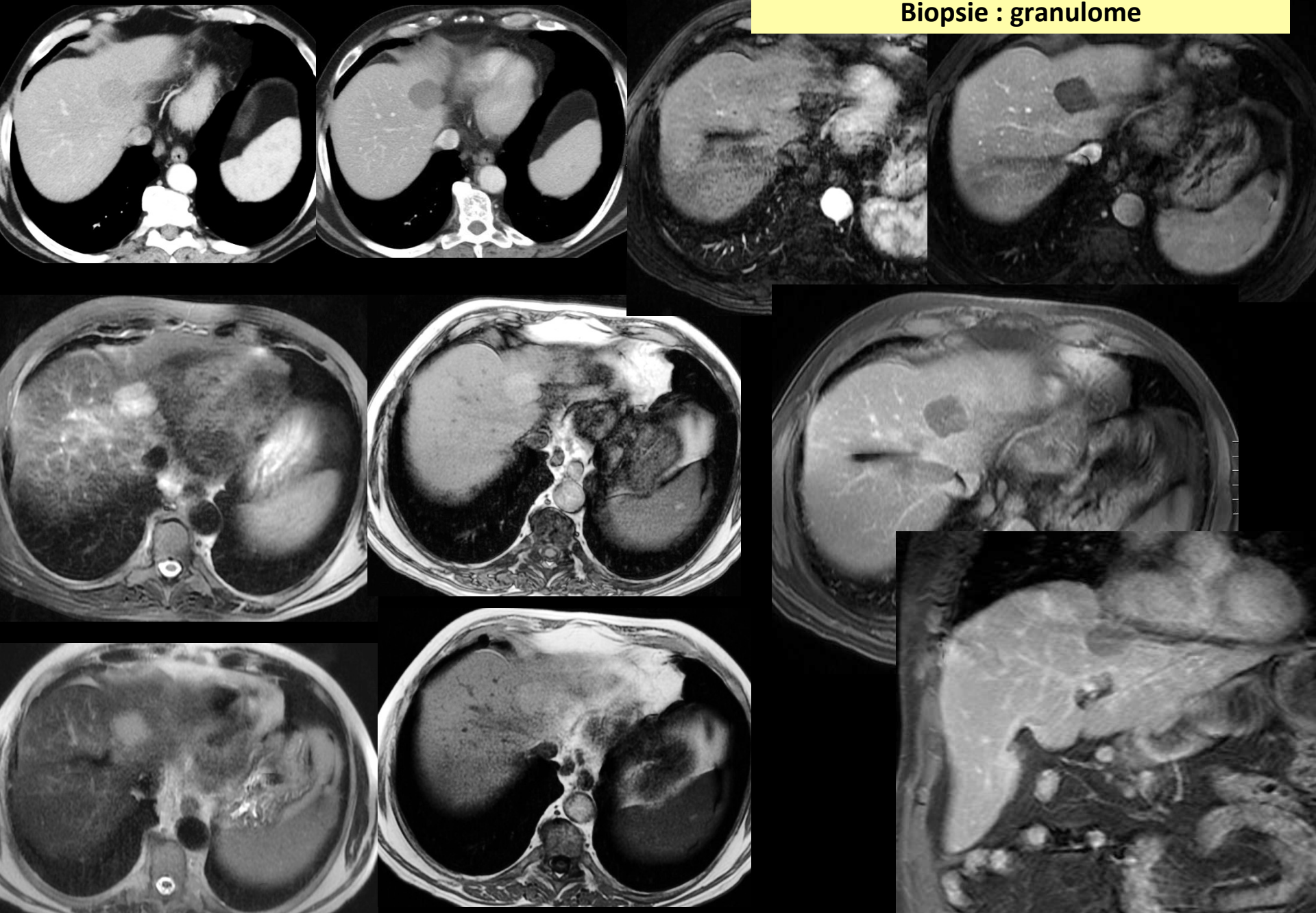
Polyadénomatosse dans un contexte de glycogénose de type I

19

homme, cirrhose , 55 ans

Lésion amorphe / atcd sarcoïdose

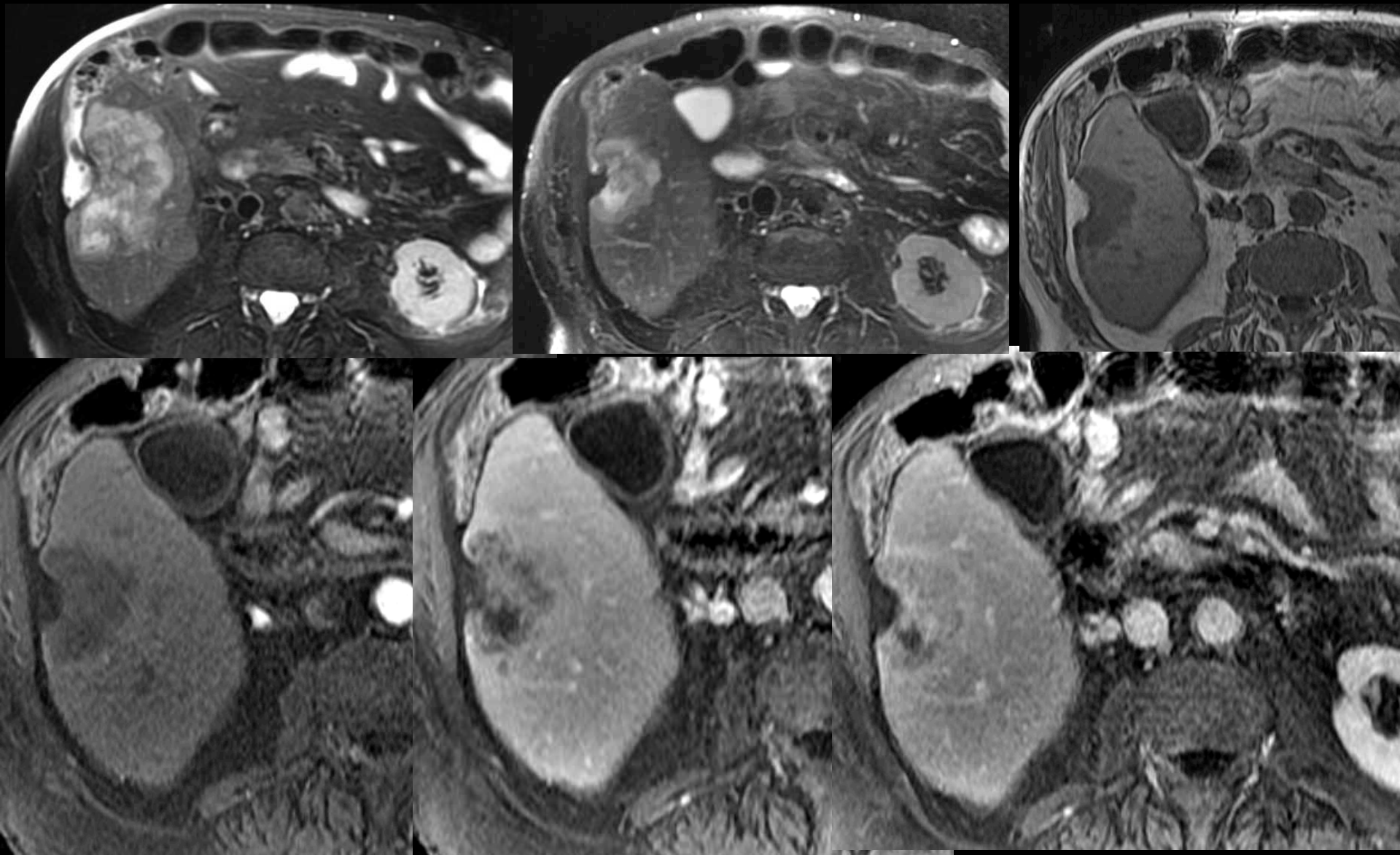
Biopsie : granulome



20

homme, 85 ans

Cholangiocarcinome intra hépatique

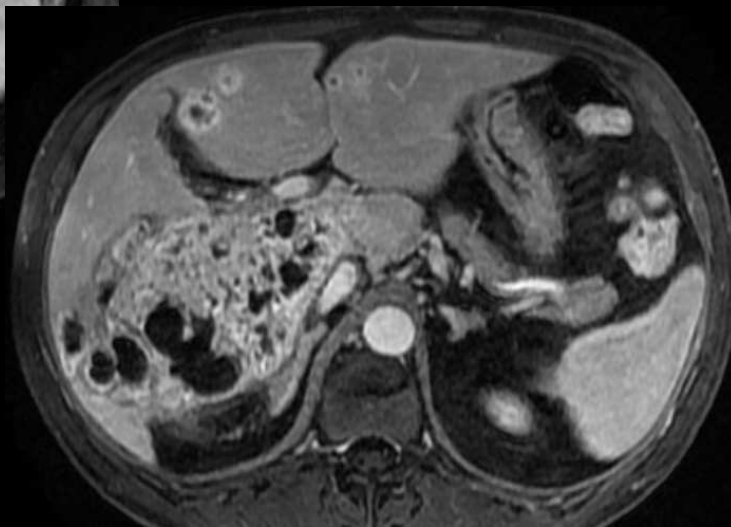
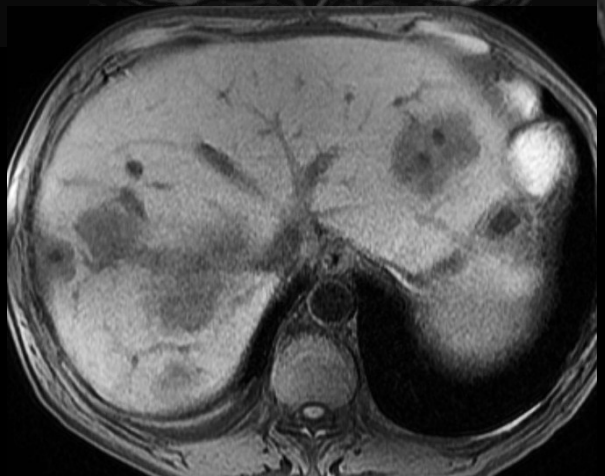
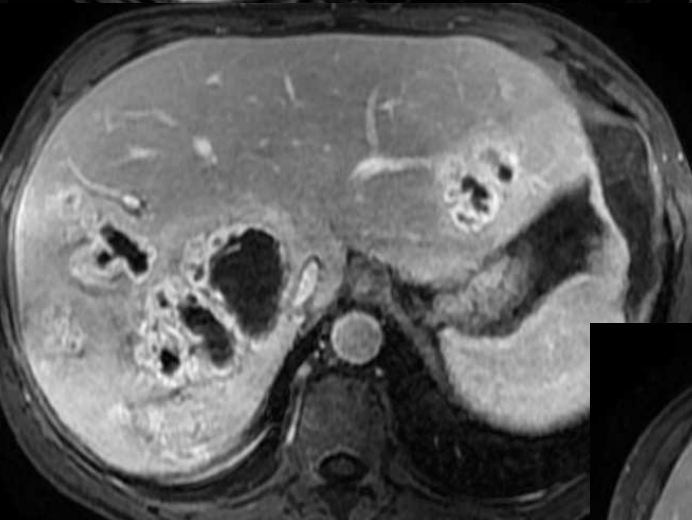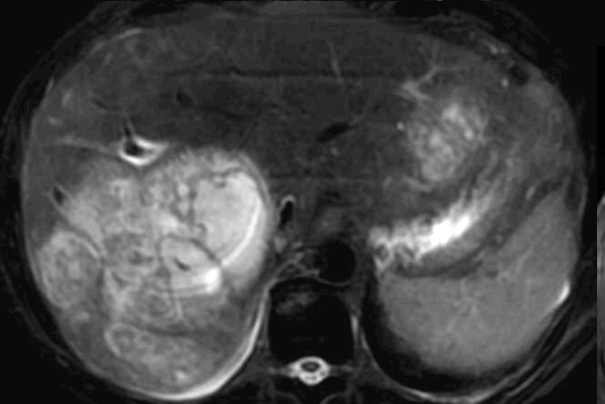
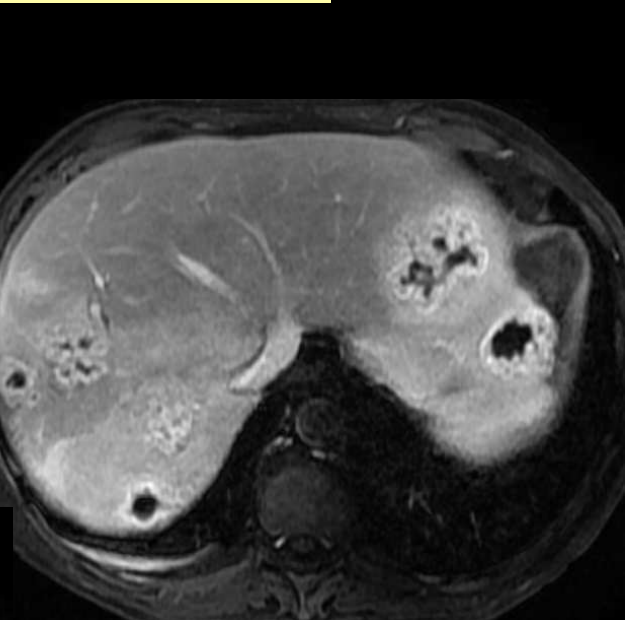
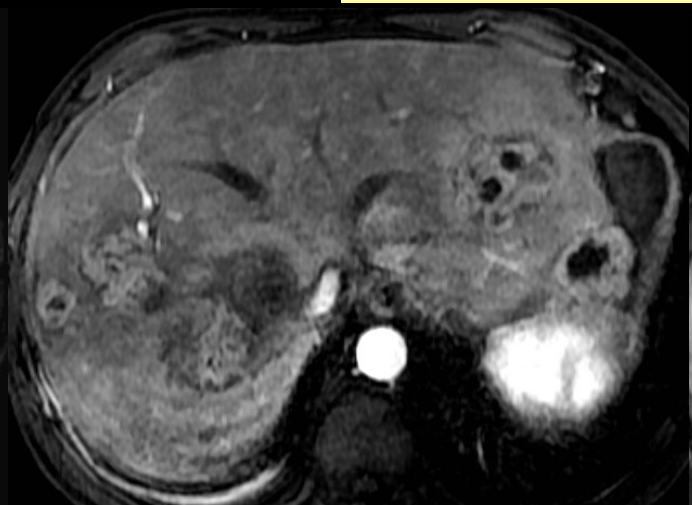
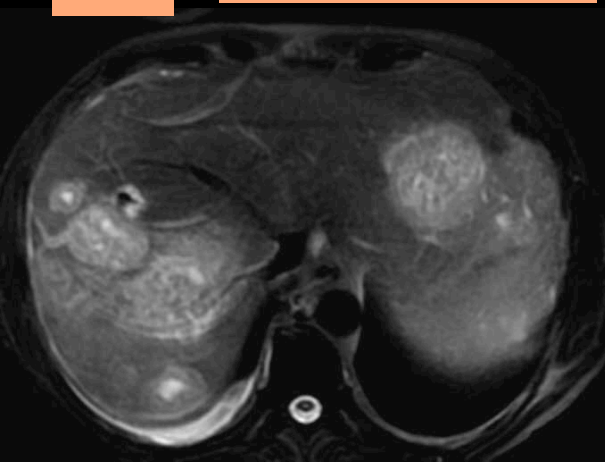


Rétraction capsulaire hépatique: THPM (HEE, CK, CHC FL), THPB (angiome scléreux), métastases, fibrose hépatique + lésions traitées

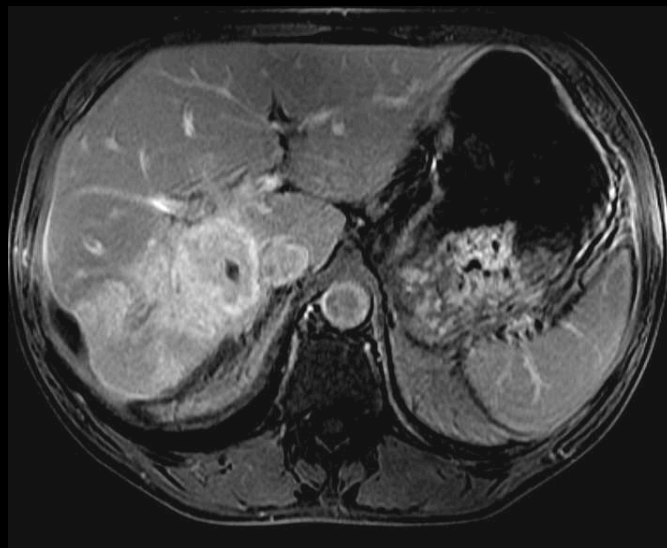
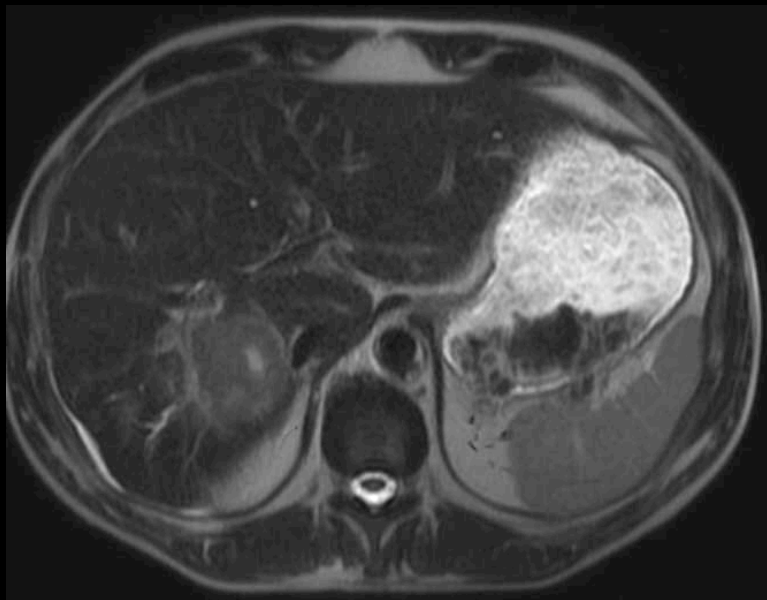
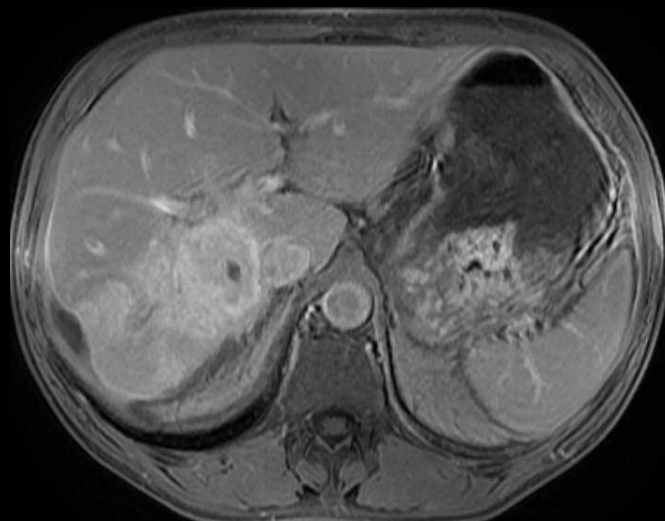
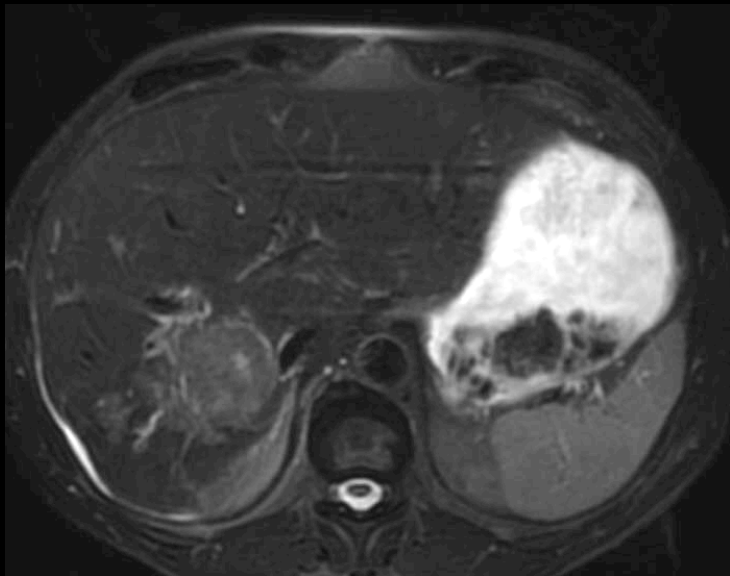
21

homme, 45 ans

Abcès à pyogènes



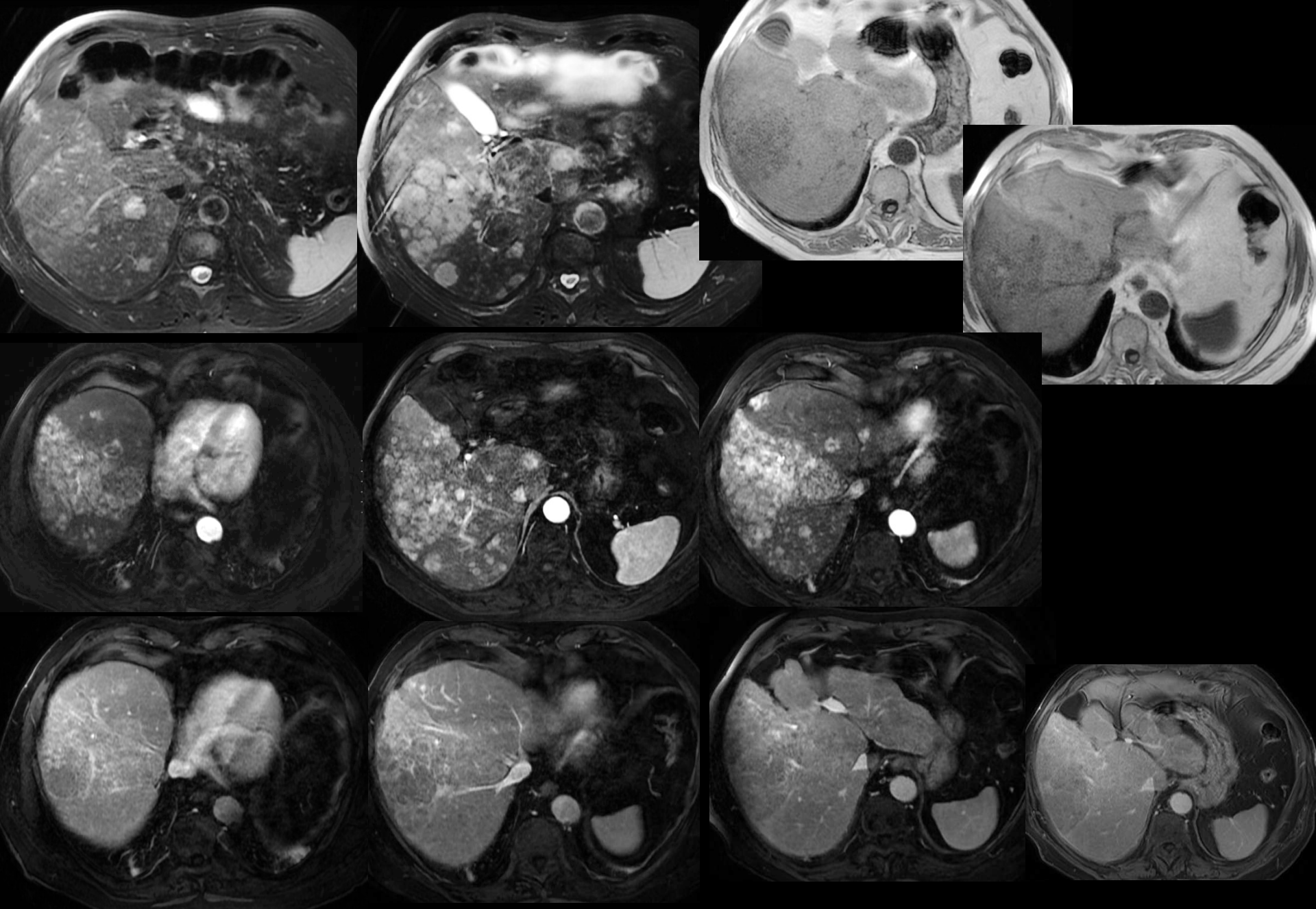
Contrôle à 2 mois



22

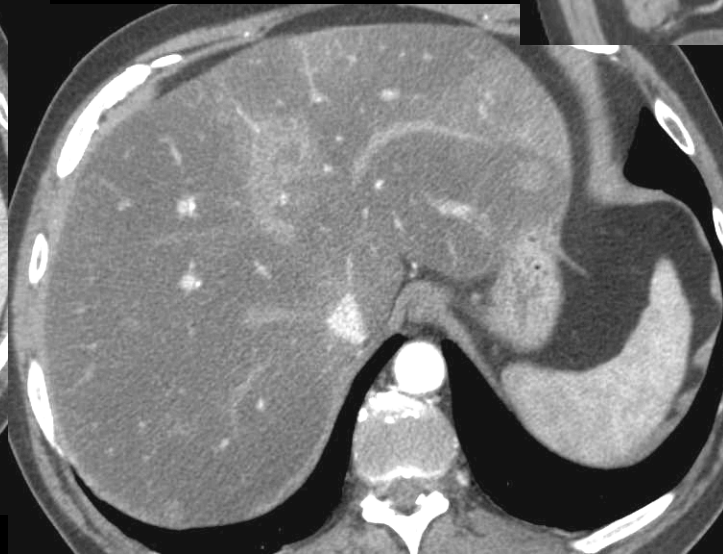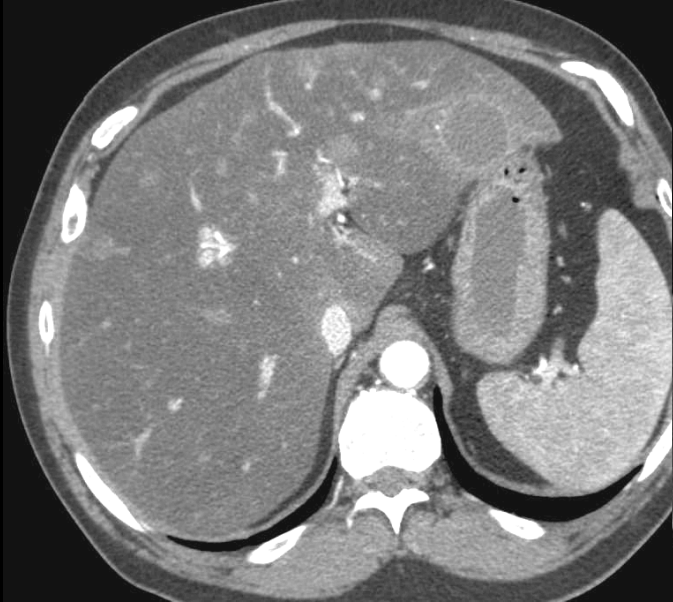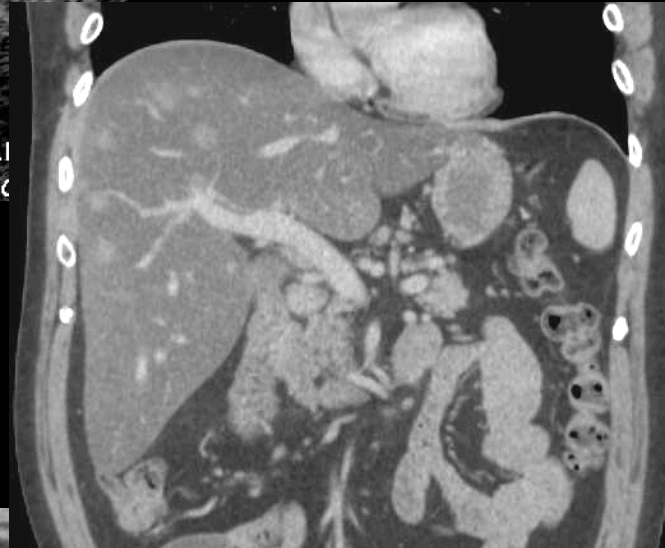
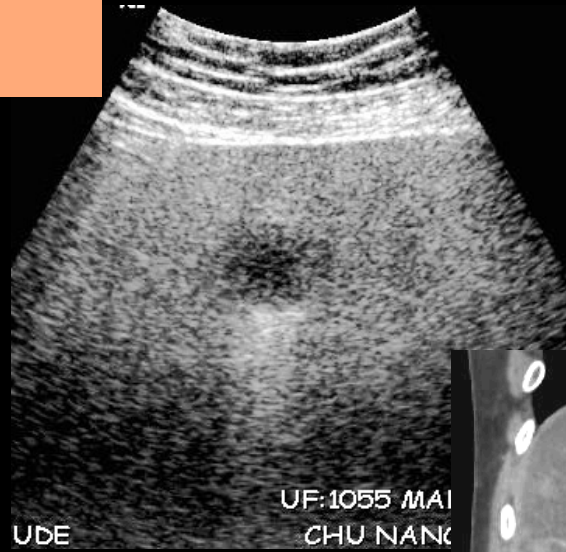
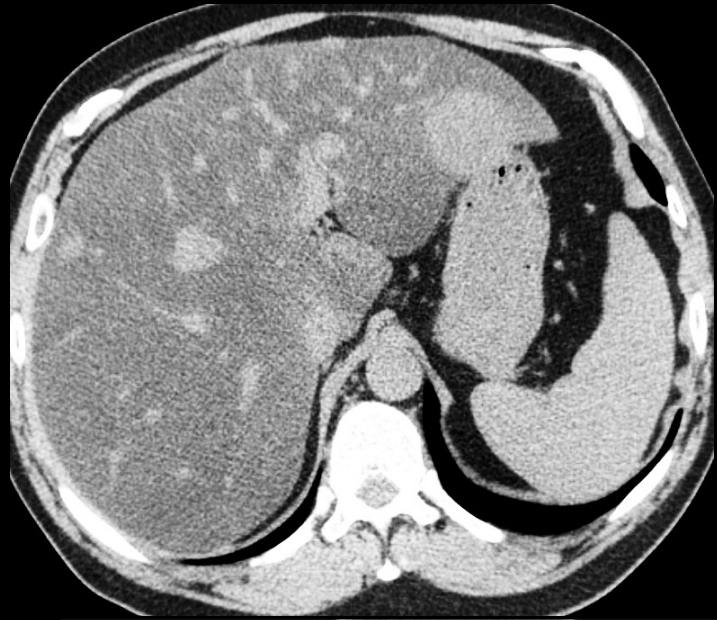homme, 70 ans

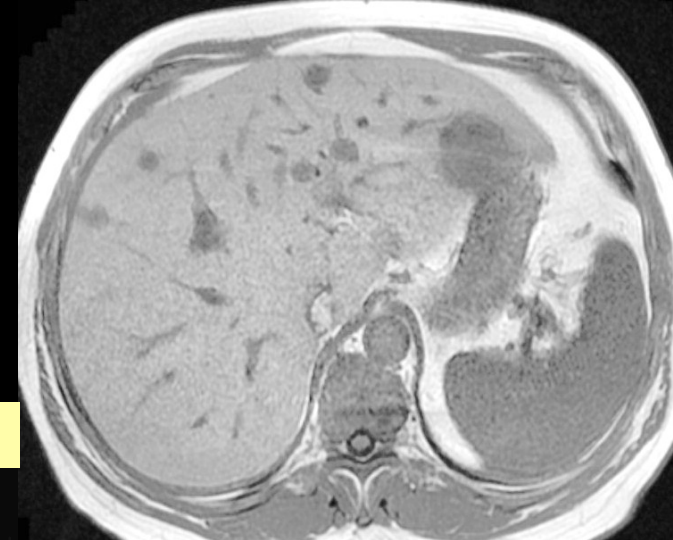
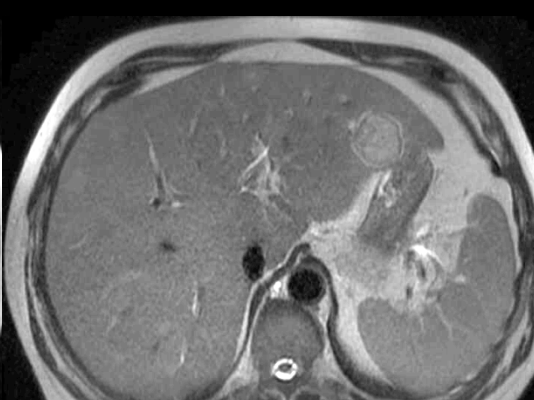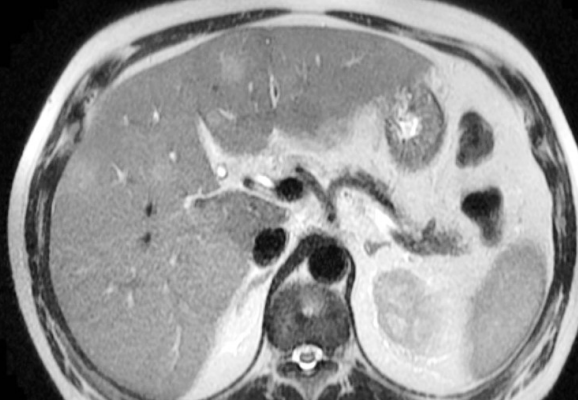CHC multifocal



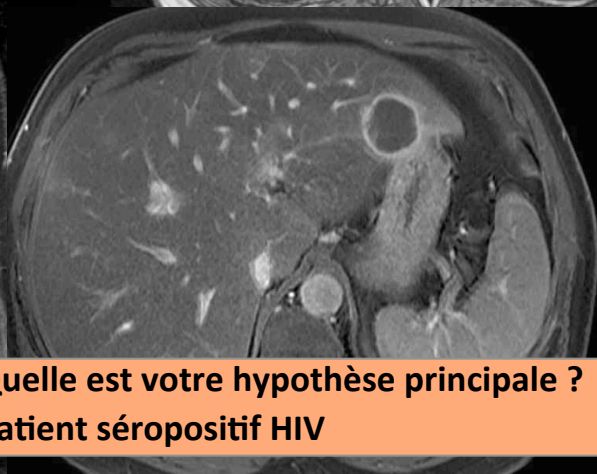
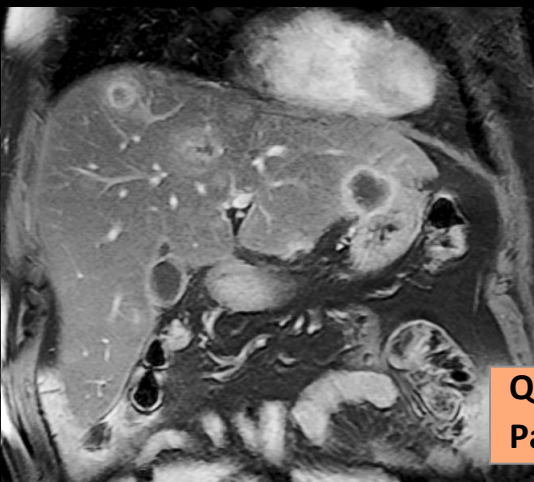
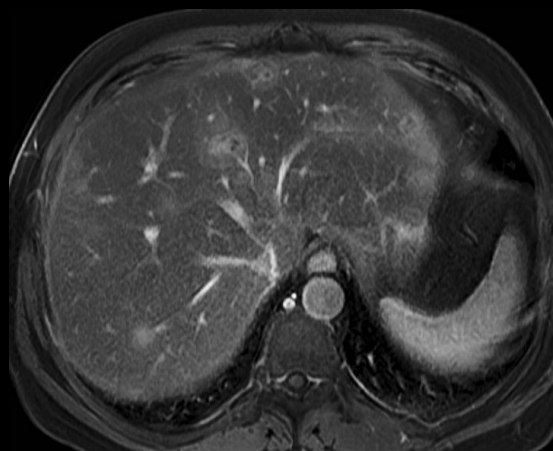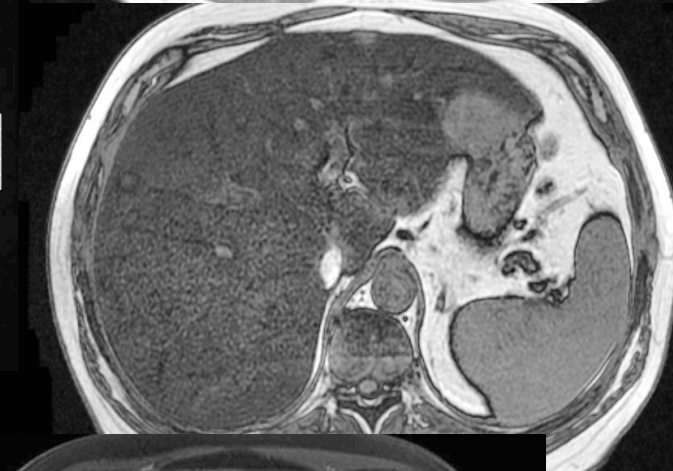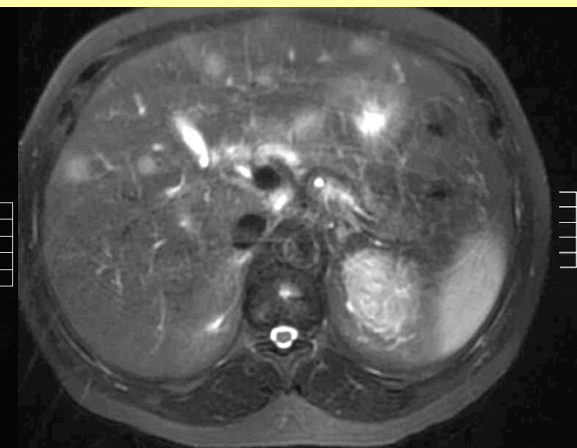
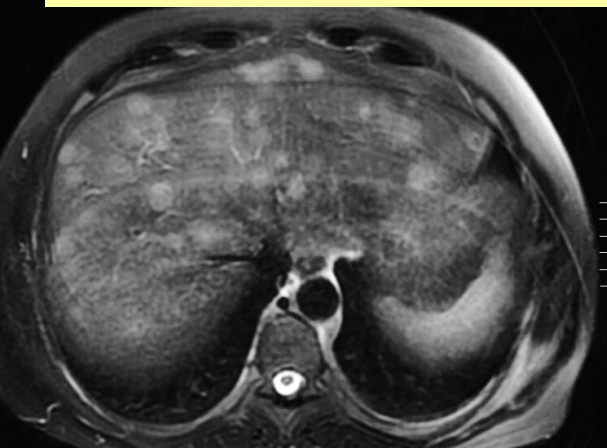
23

Homme 45 ans fièvre et perte de poids
Ancien toxicomane





Biopsies: lymphome malin B diffus à grandes cellules

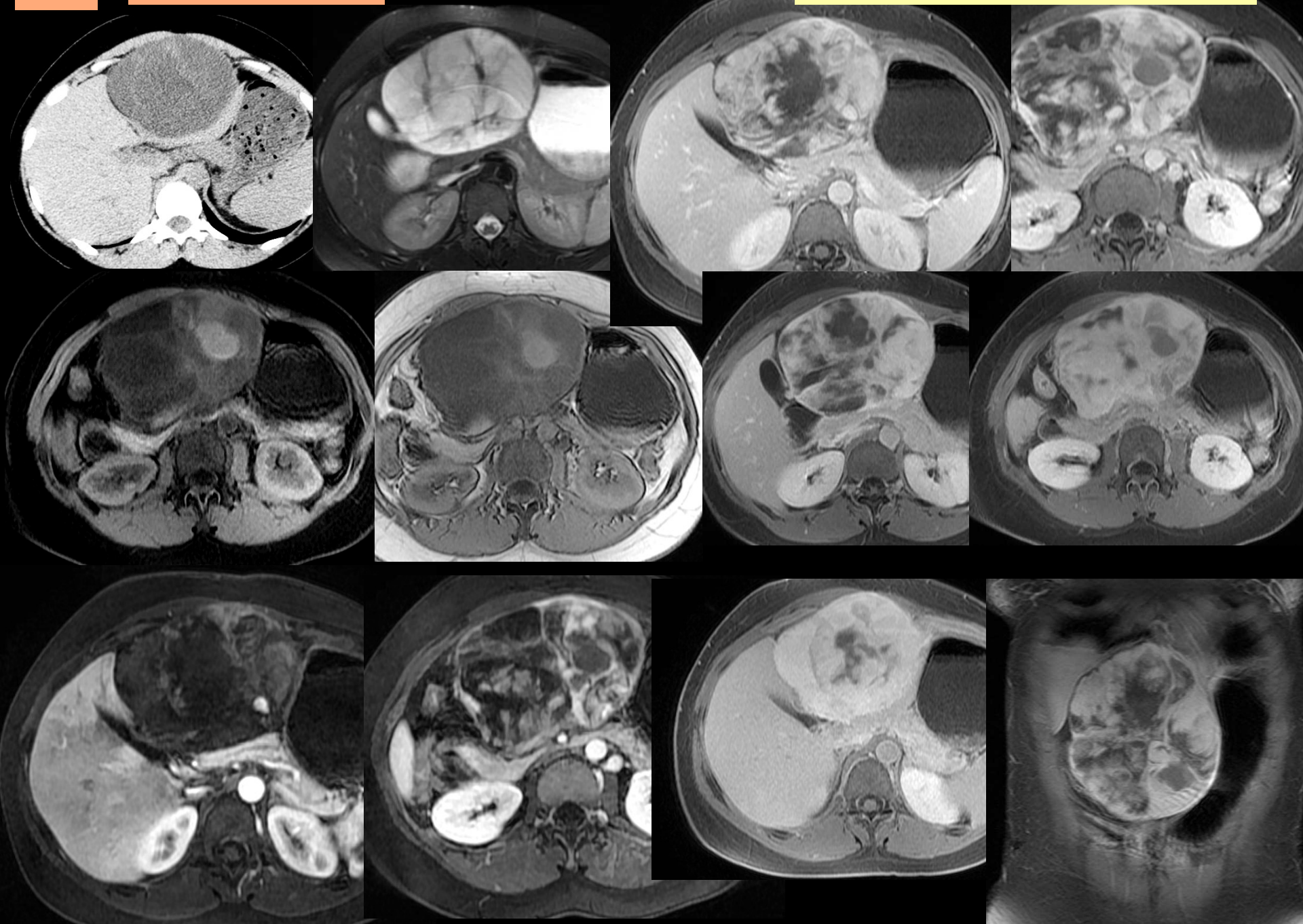


**Quelle est votre hypothèse principale ?
Patient séropositif HIV**

24

Femme, 25 ans

Sarcome myxoïde du lig rond

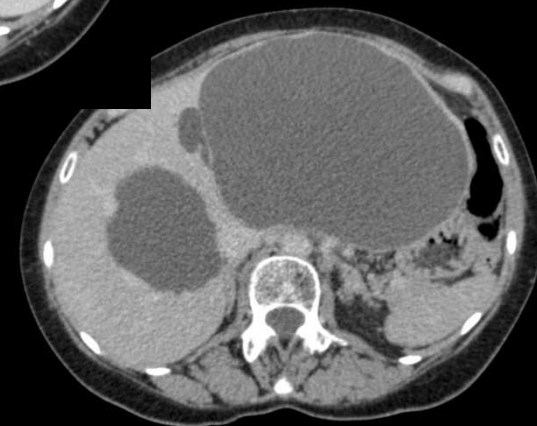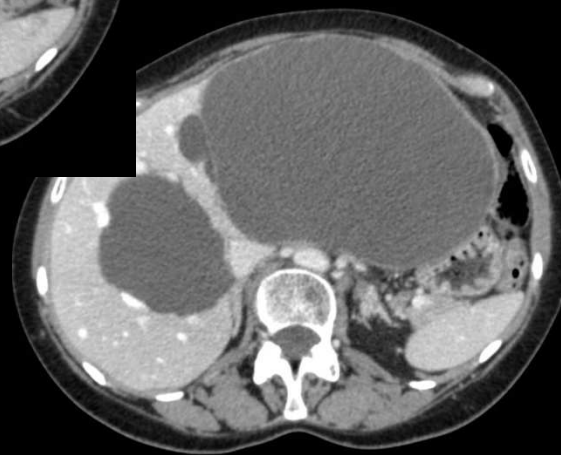
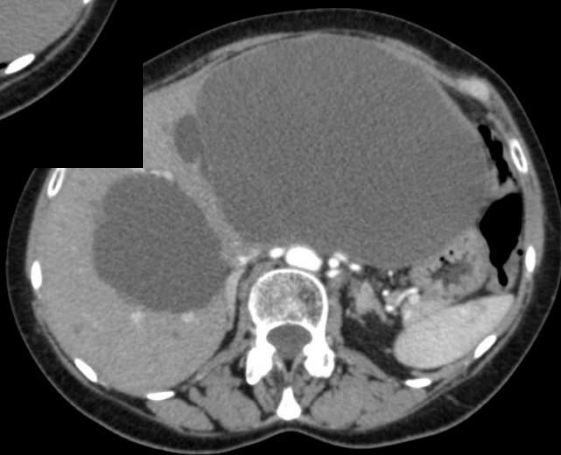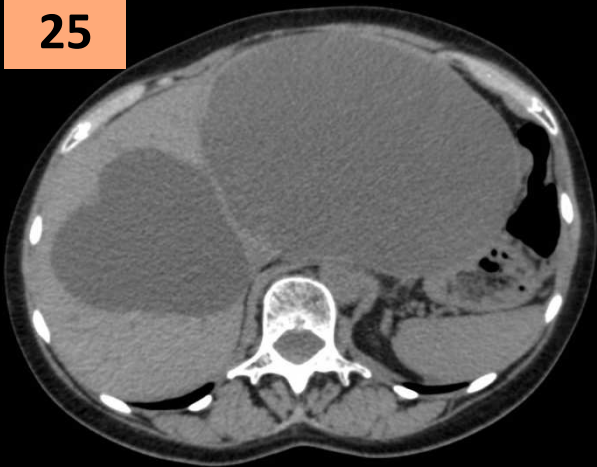


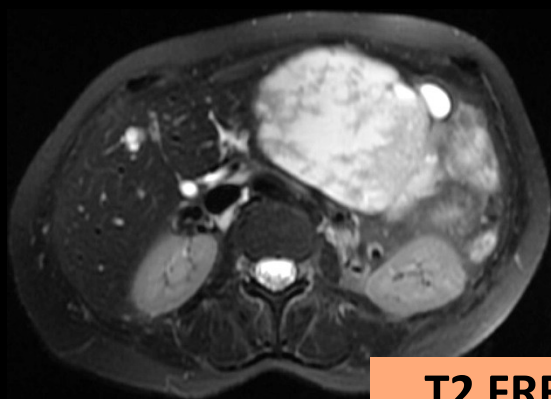25

Patiente de 57 ans

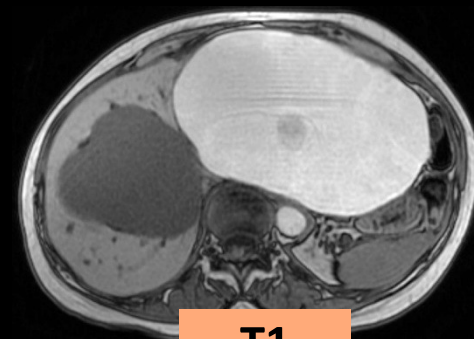
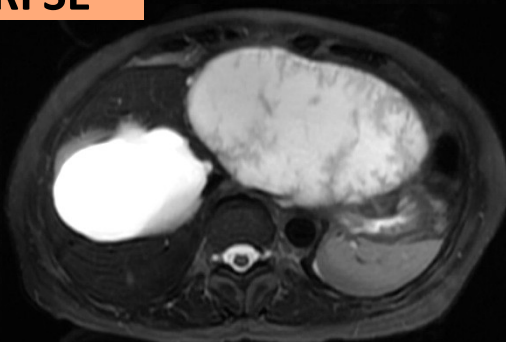
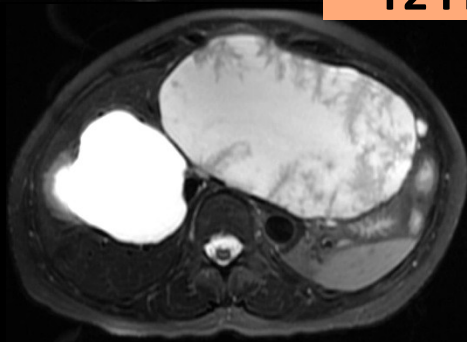
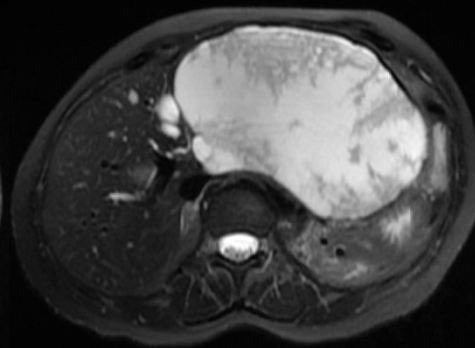
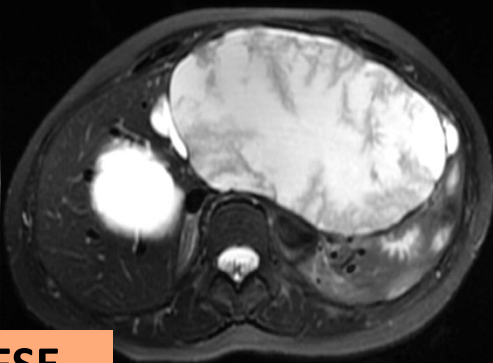
Pas d'ATCD

Douleurs épigastriques, dysphagie



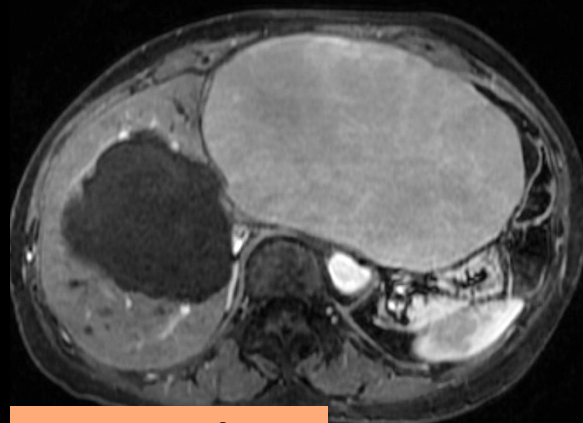

T2 FRFSE

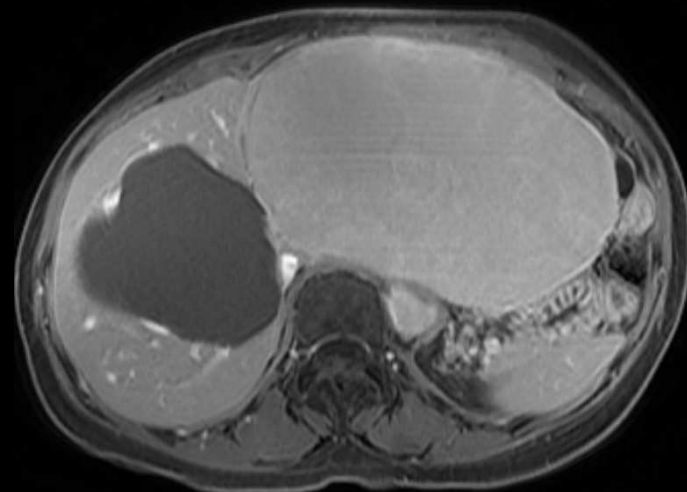
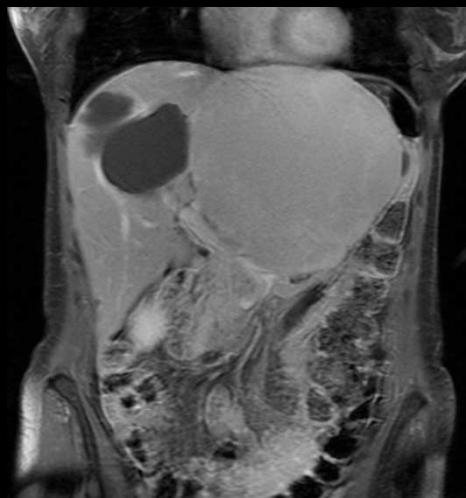
T1

Kyste biliaire hémorragique



T1 Gado

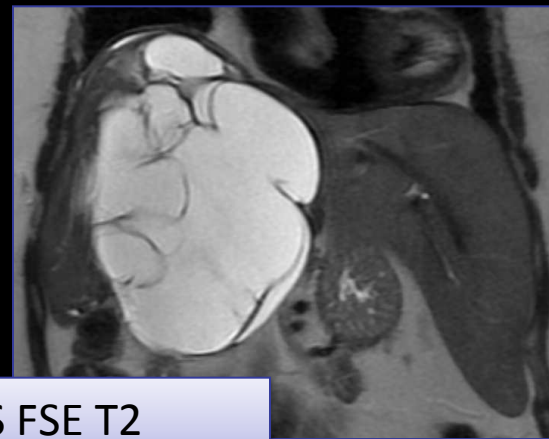
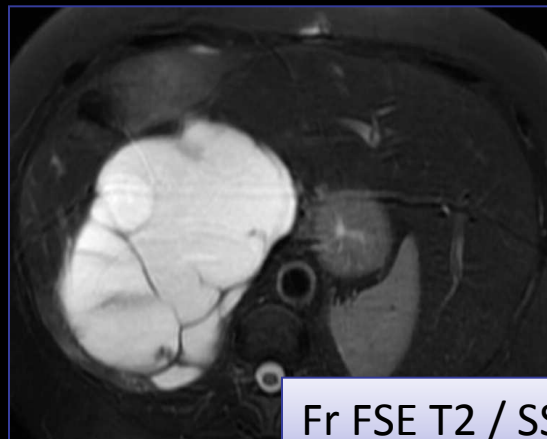
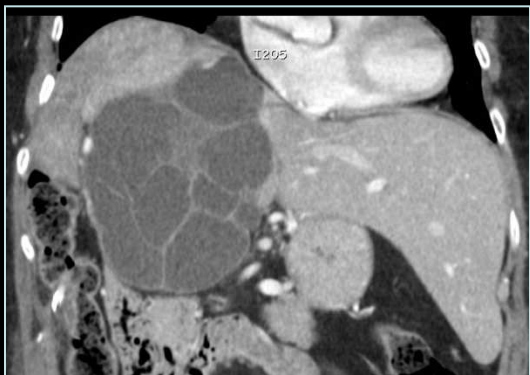
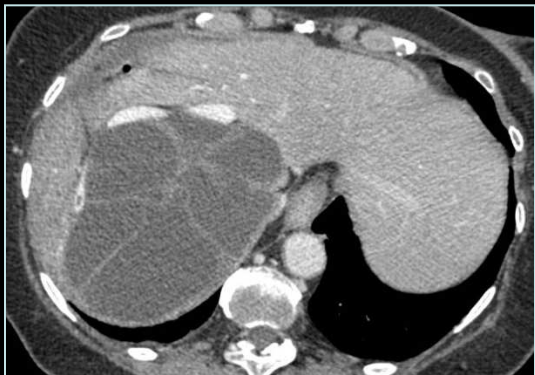26

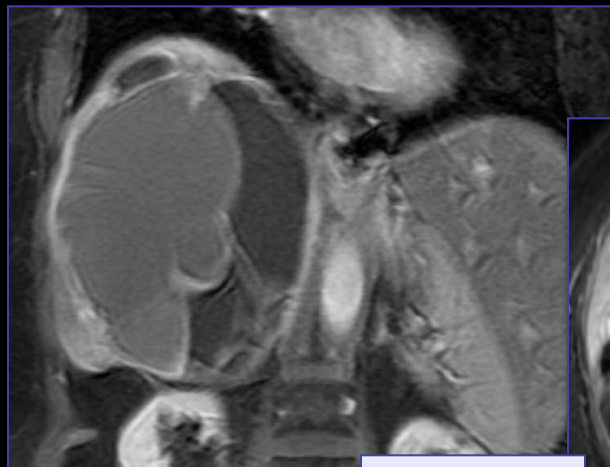
Femme de 53 ans

Douleurs épigastriques chroniques non fébriles

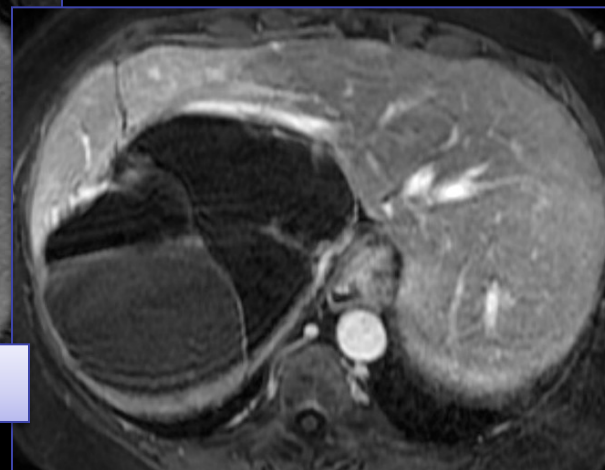Cystadénome biliaire

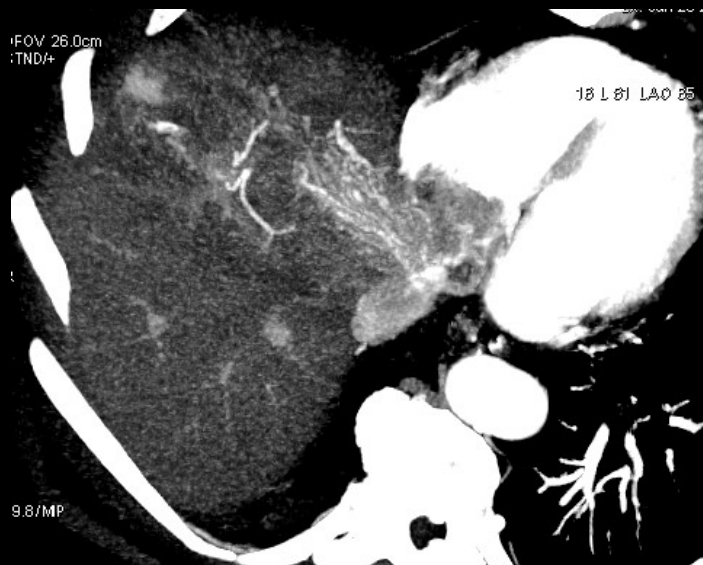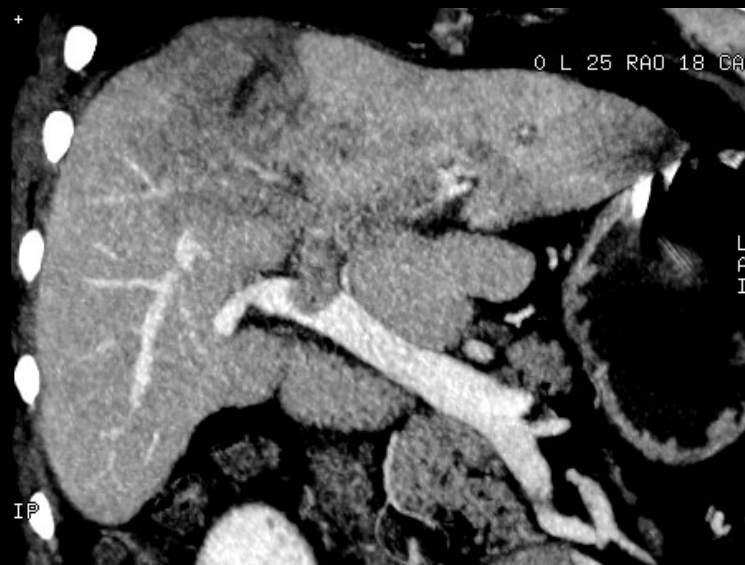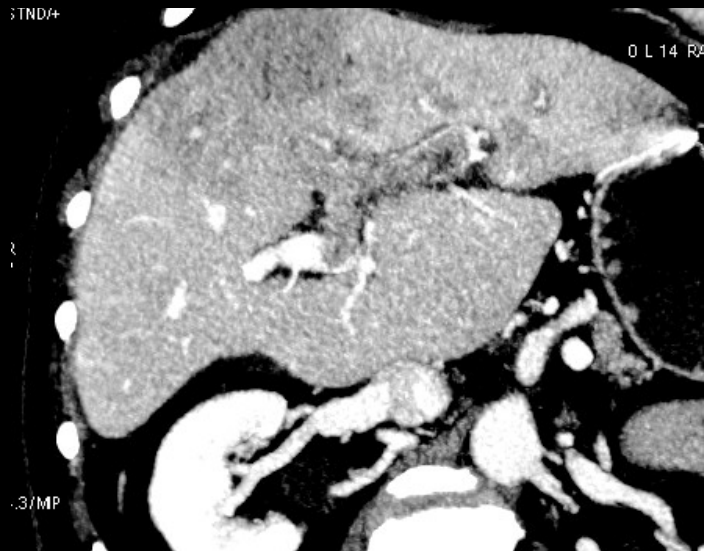


Fr FSE T2 / SS FSE T2



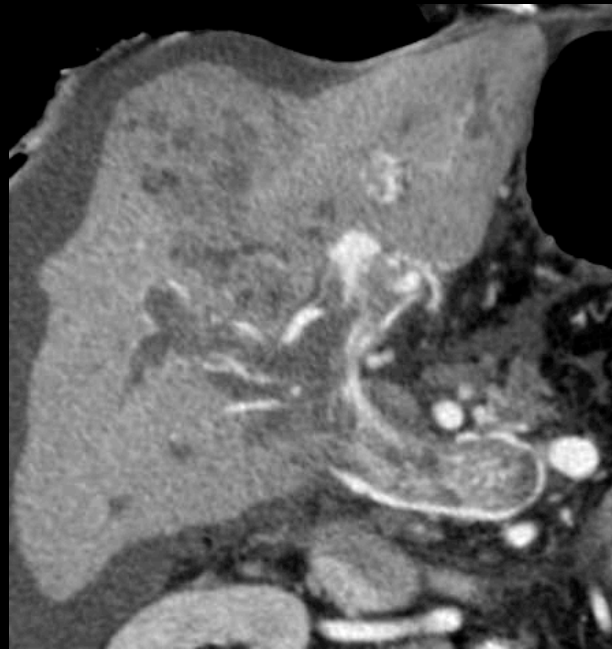
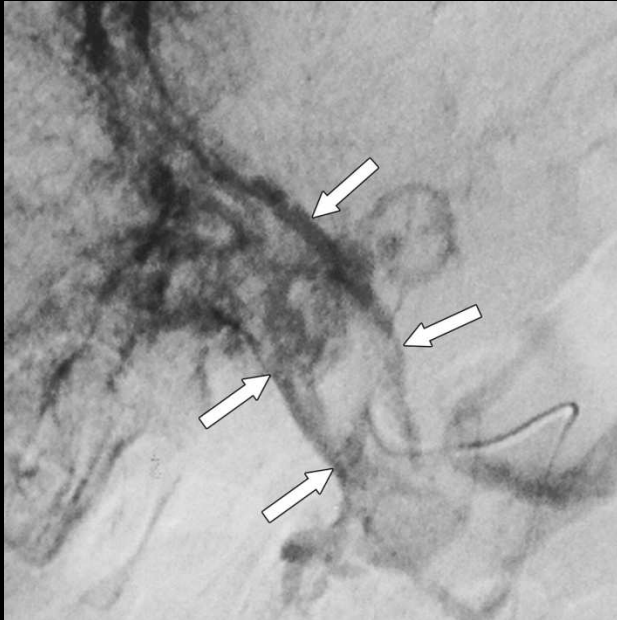
T1 gado

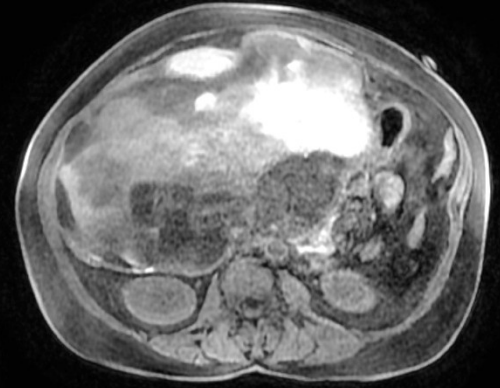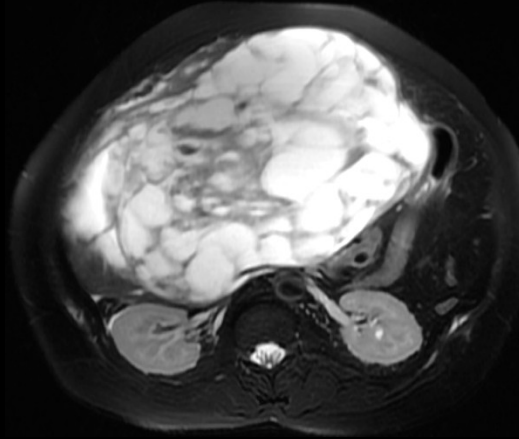
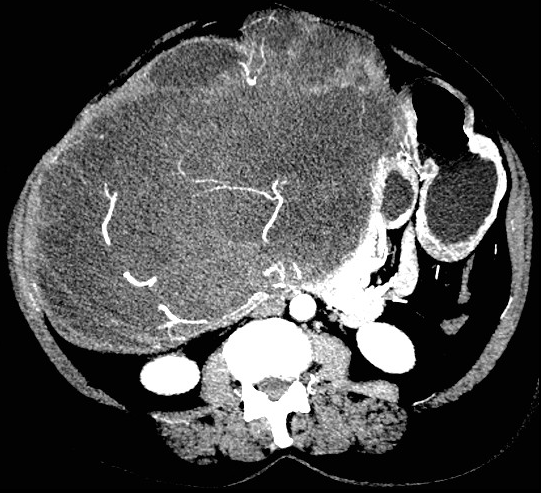




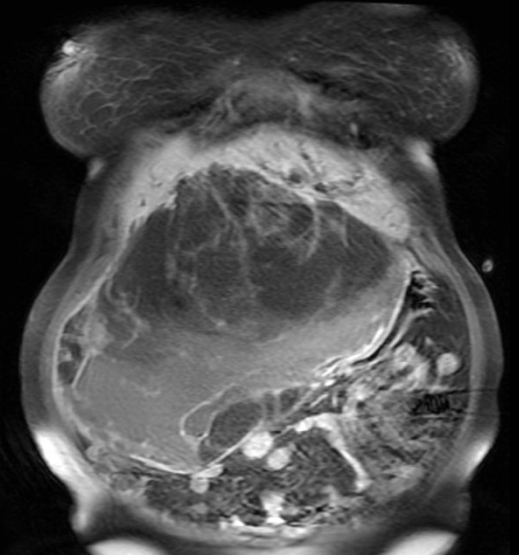
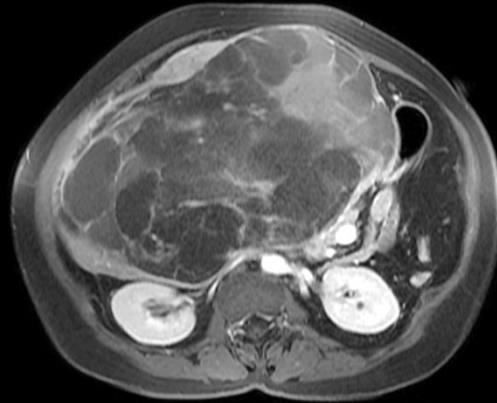
**CHC avec envahissement
des VSH, de l'OD et
portal massif**

Signe d' Okuda



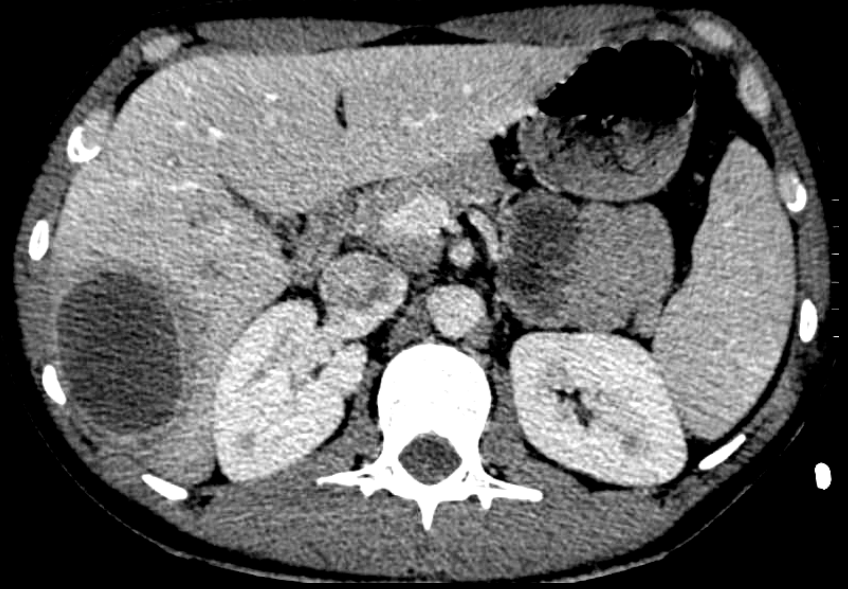

**Sarcome embryonnaire
hépatique de l'adulte**

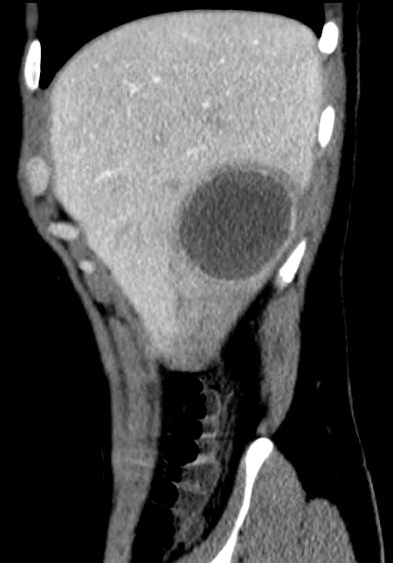
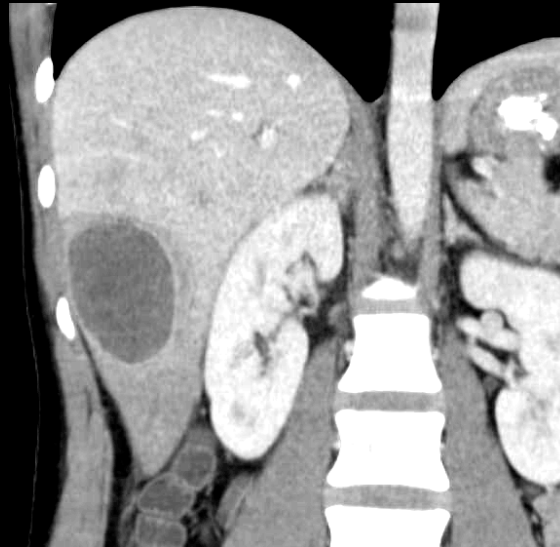
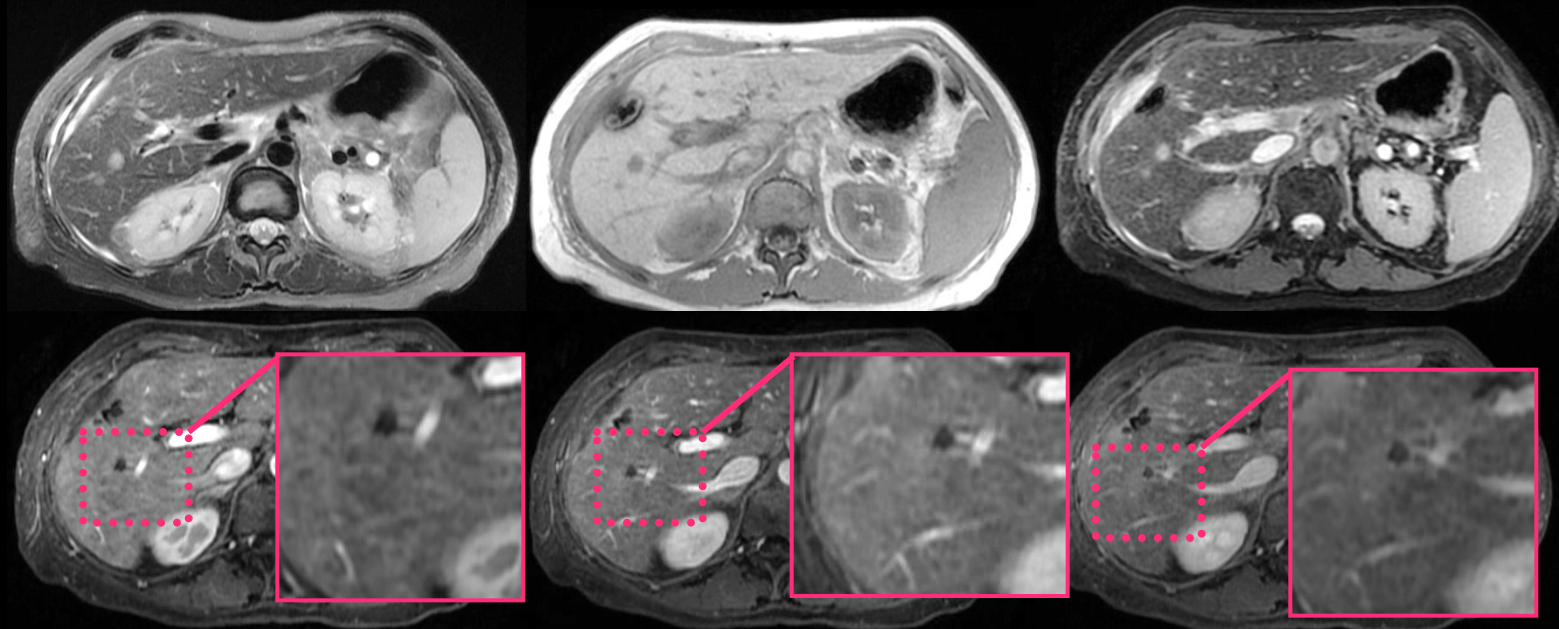
29

Homme de 24 ans. Retour du Mali.
Fièvre et syndrome inflammatoire
majeur (CRP à 512 mg/L)



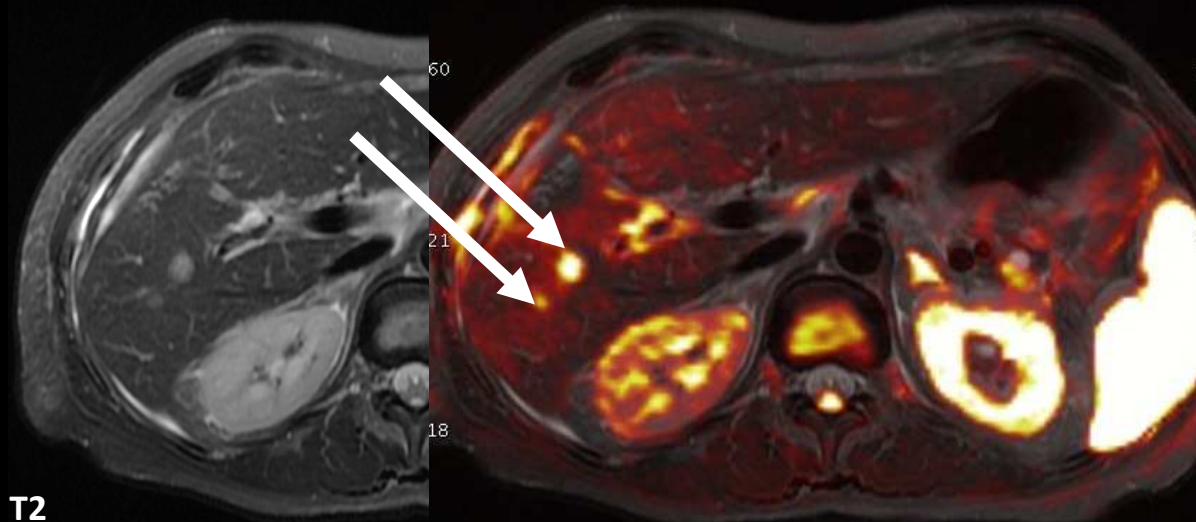
Abcès amibien





Séquences
morphologiques
(T2, T1, Fiesta)

Acquisitions
dynamiques
après Gado
(LAVA)



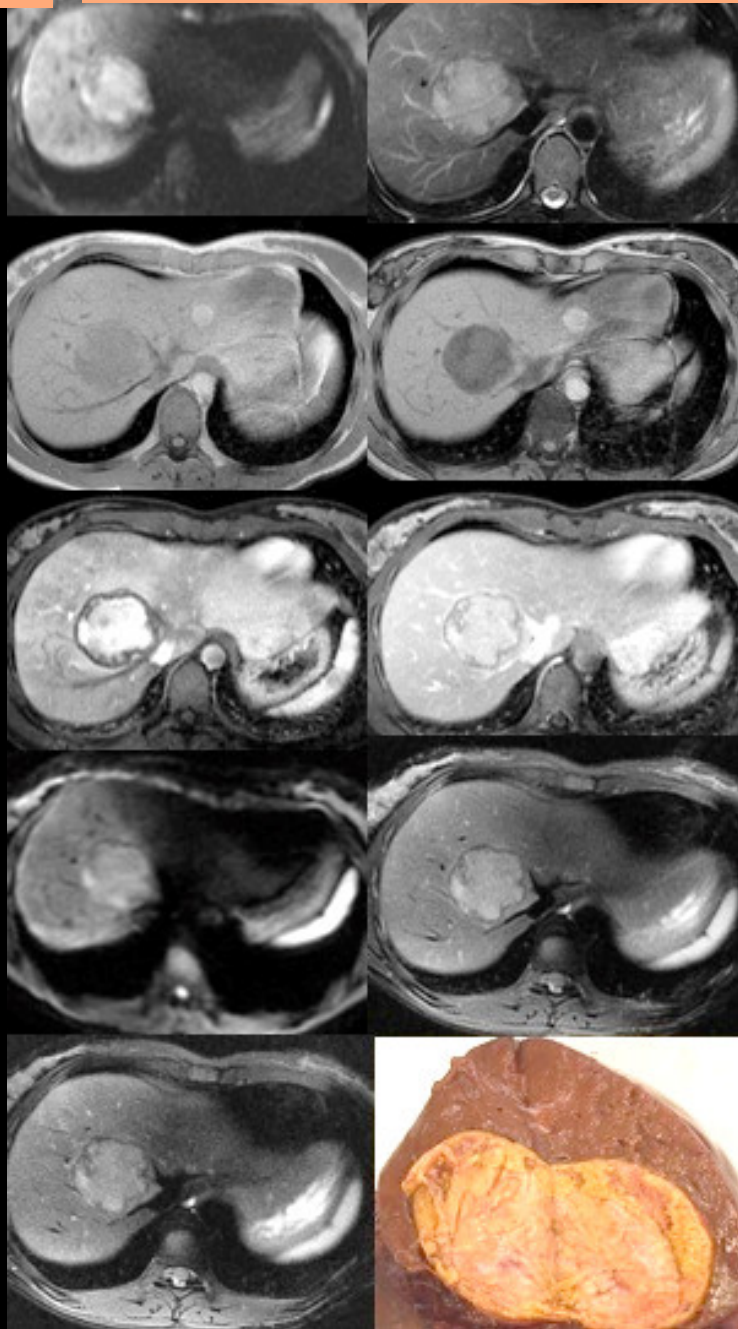
T2

Diffusion

Il y a en fait 2 lésions
contiguës du VI...
Comme le laissait
supposer le T2; mais pas
les séquences injectées !

31

Patiente de 23 ans. Découverte fortuite d'une lésion focale hépatique.



Adénome

DWI 1,5T	FSET2 1,5T
-------------	---------------

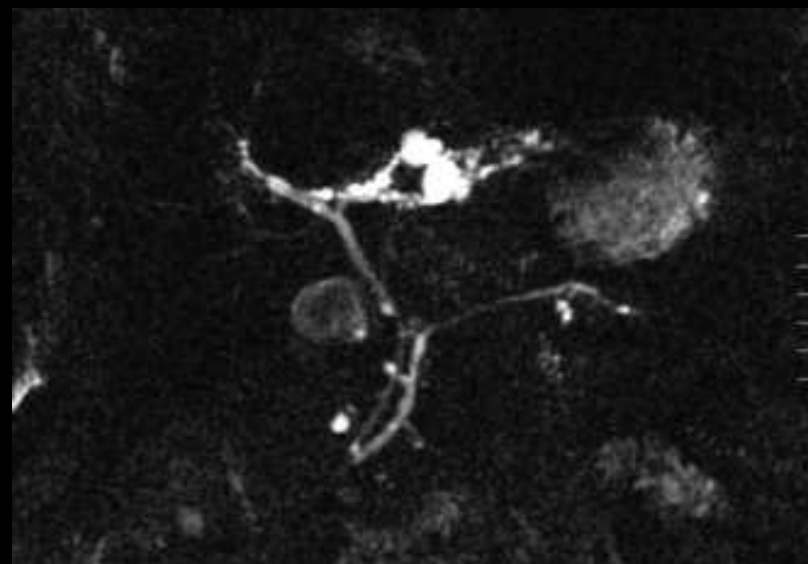
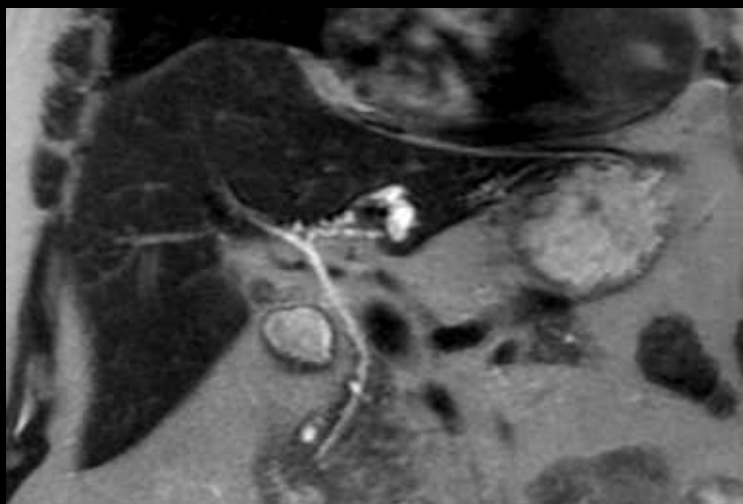
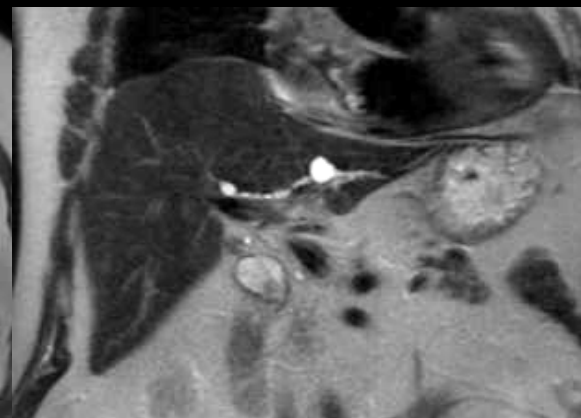
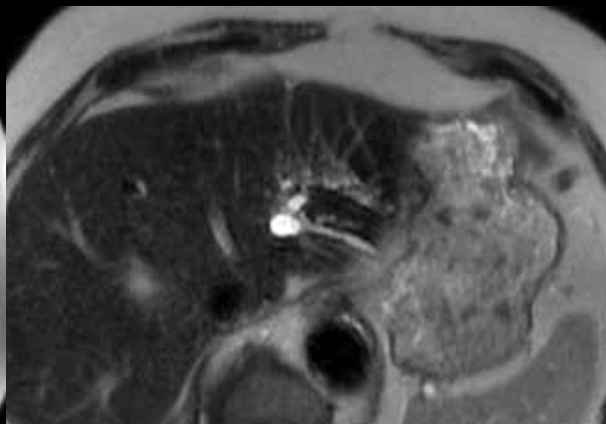
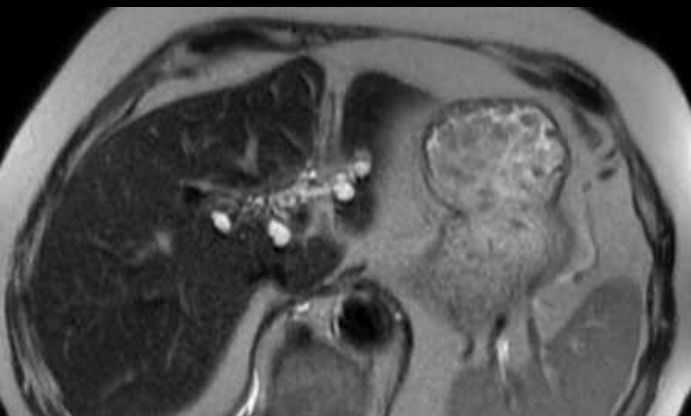
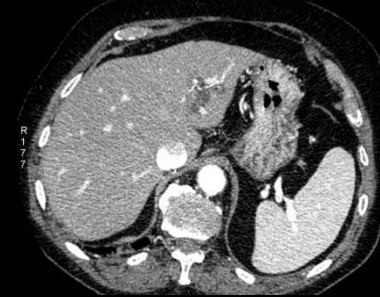IP 1,5T	OP 1,5T
---------	---------

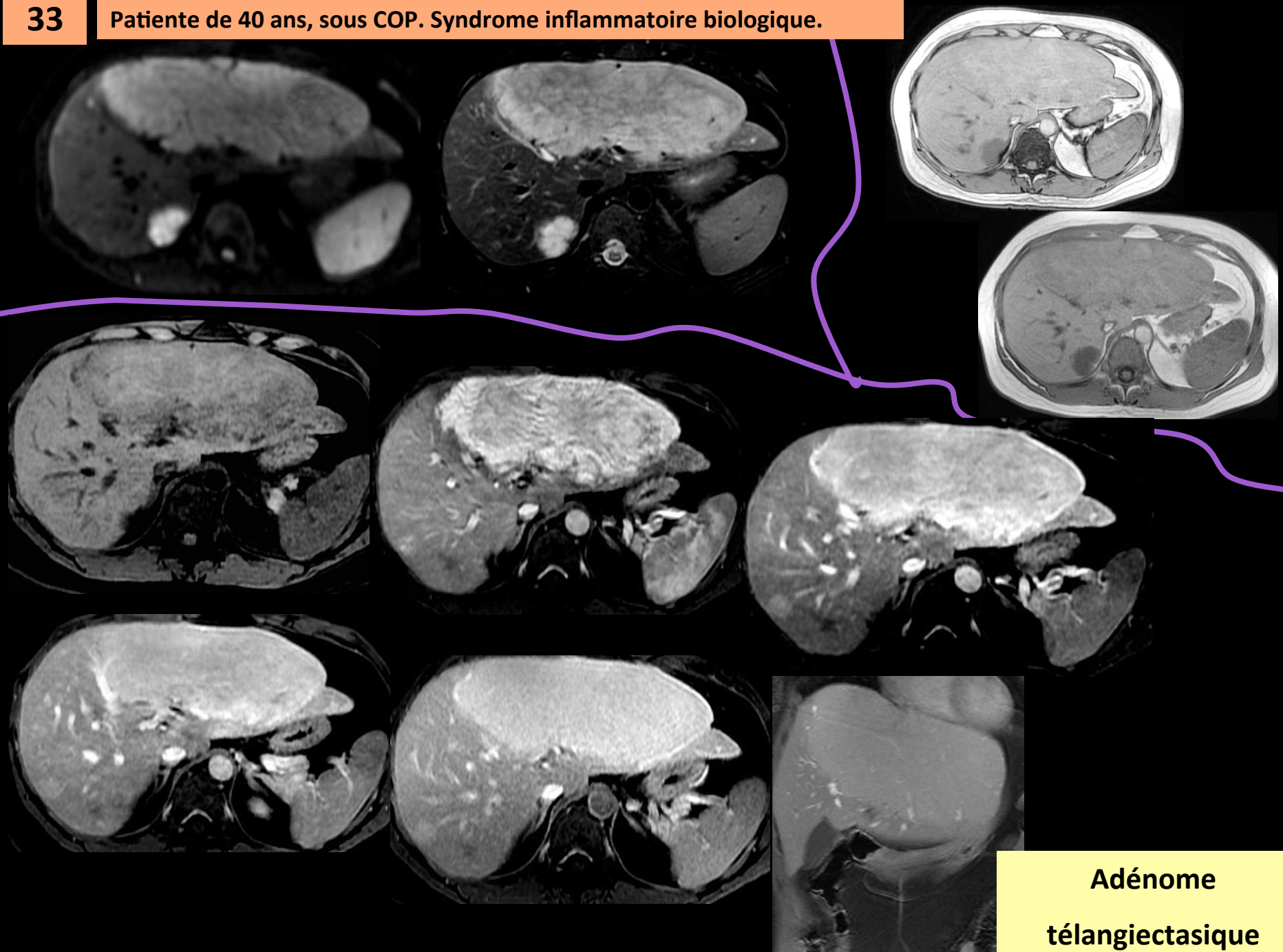1,5T LAVA 1	1,5T LAVA 3
----------------	----------------

DWI 3T	FSET2 HR 3T
--------	----------------

FSET2 S 3T	Pièce
---------------	-------

Kystes périliaires





**Adénome
télangiectasique**