

# Radioanatomie du thorax

[www.e-anatomy.org](http://www.e-anatomy.org)

**A.OLIVER**  
**E.MATHIAS**  
**AVRIL 2013**

# THORAX

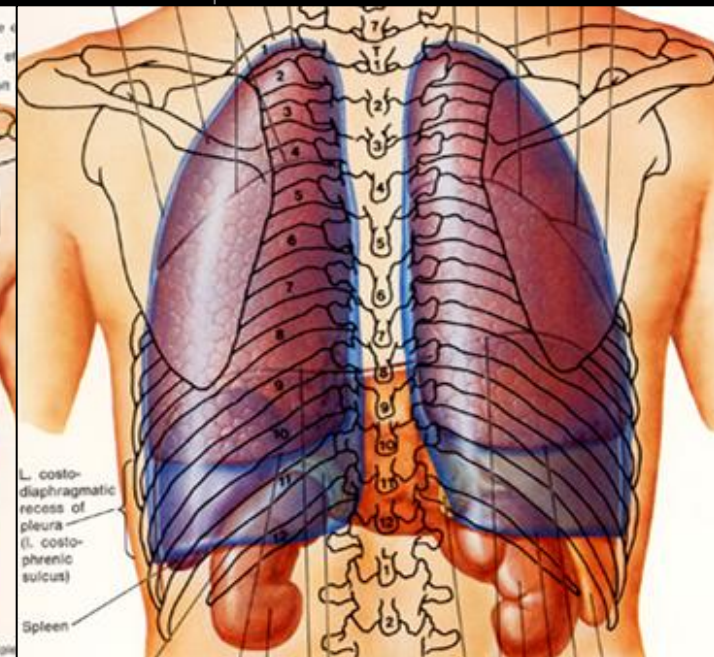
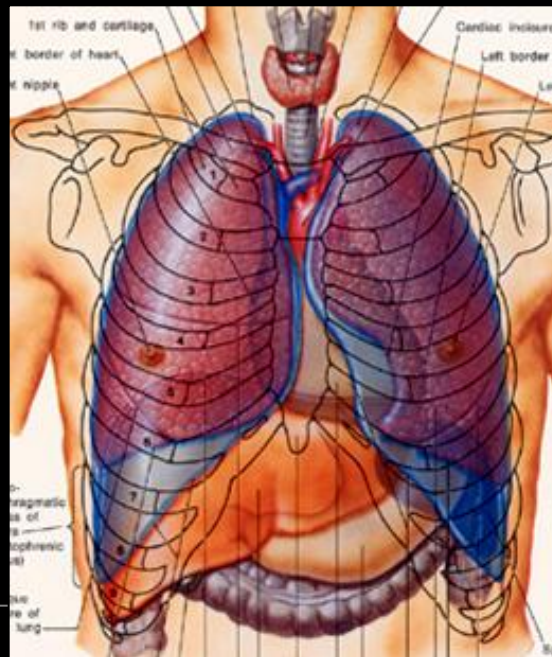
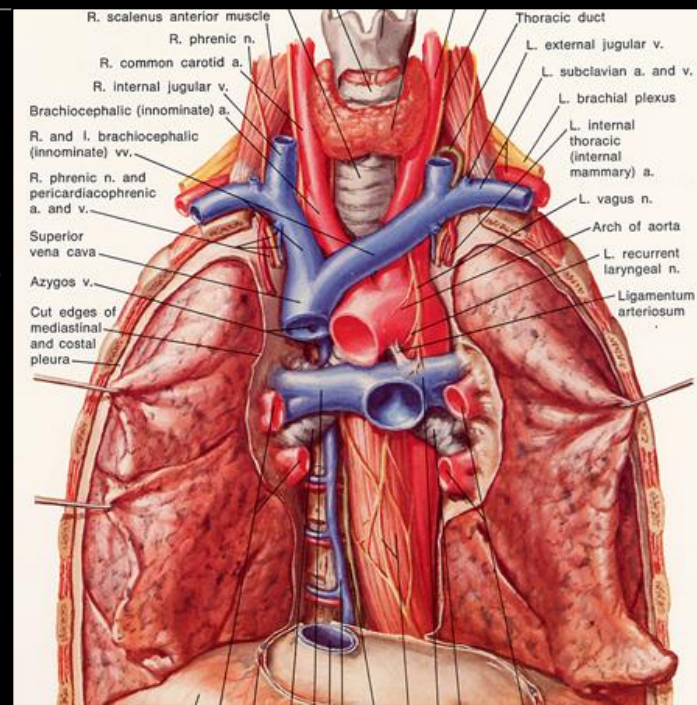
## 1/ RADIOANATOMIE PULMONAIRE ET DES BRONCHES

## 2/ RADIOANATOMIE DU MEDIASTIN

- VAISSEAUX
- CŒUR
- ŒSOPHAGE
- CHAINES GANGLIONNAIRES

## 3/ PAROI THORACIQUE

- PLEVRE
- COTES





# **1/ RADIOANATOMIE PULMONAIRE ET DES BRONCHES**

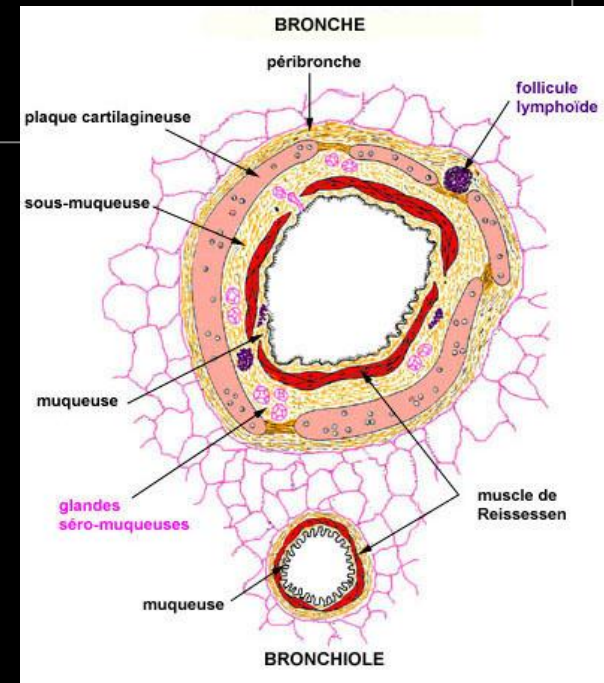
# ANATOMIE de l'ARBRE TRACHEO-BRONCHIQUE

## Trachée

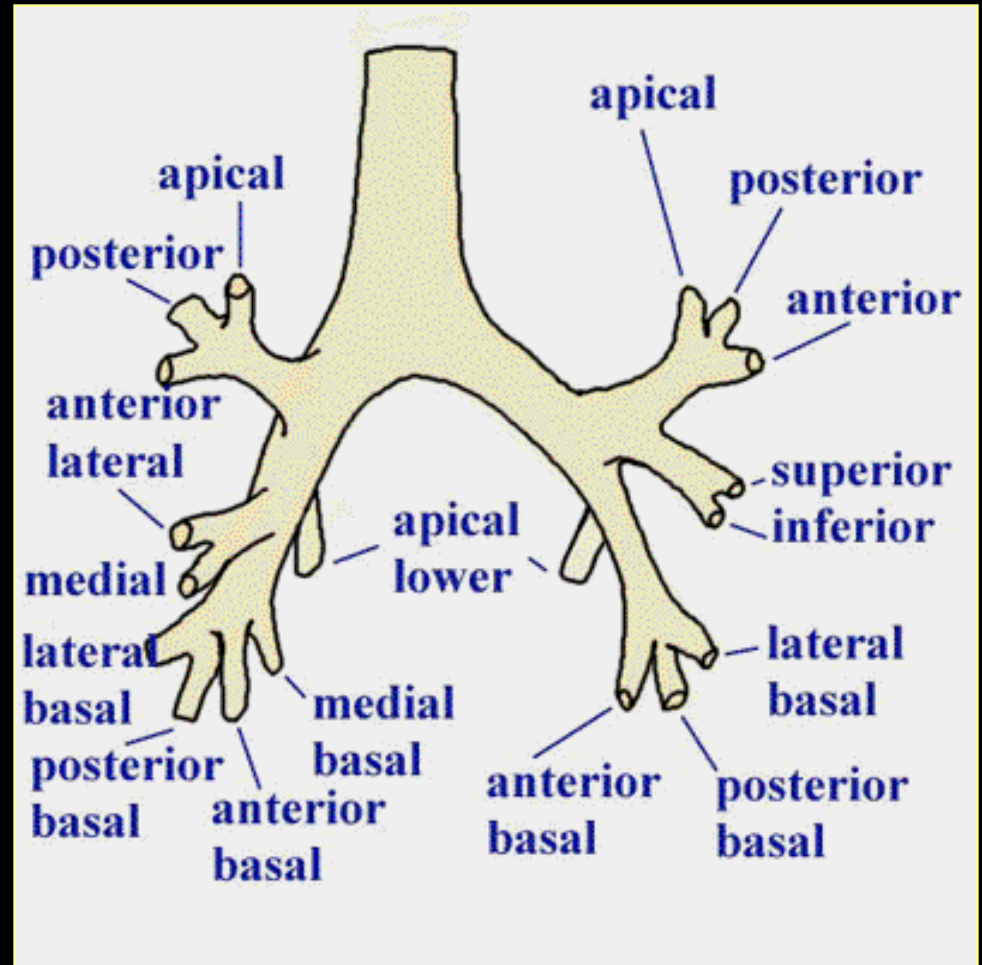
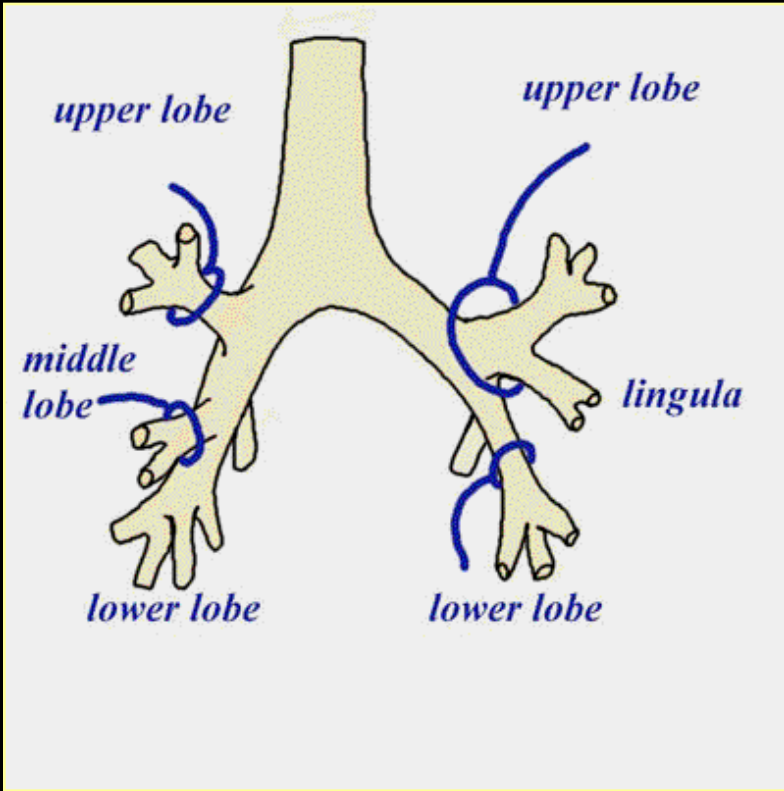
conduit semi rigide anneaux cartilagineux en avant  
membrane fibreuse postérieure  
sous glottique à carène  
diamètre inférieur à 30 mm

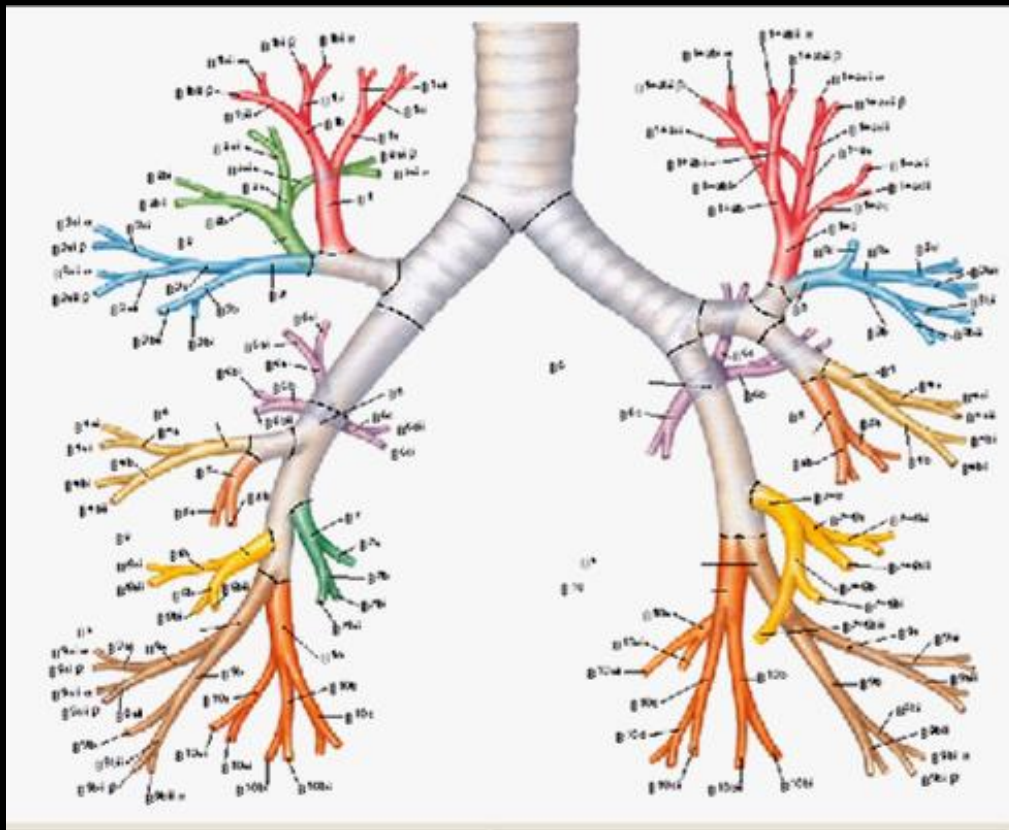
## Bronches

cartilage + m. lisse + fibres élastiques  
élastine et collagène alvéoles

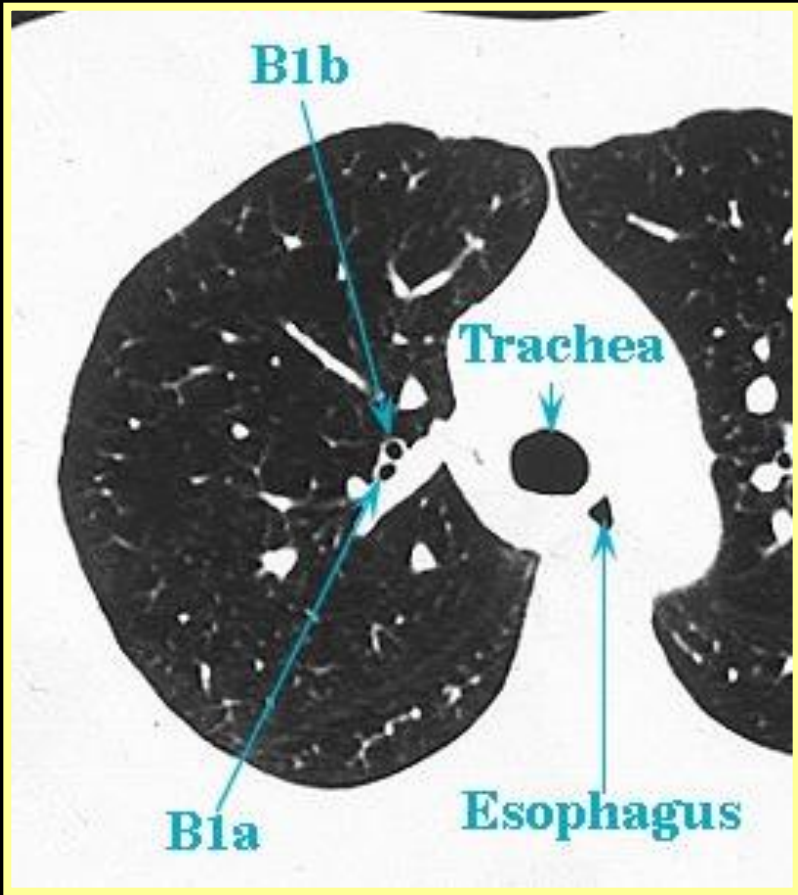
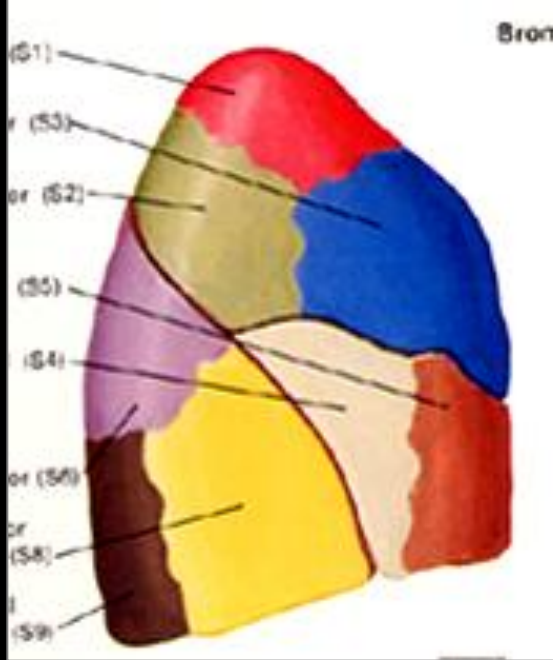


# Systeme bronchique

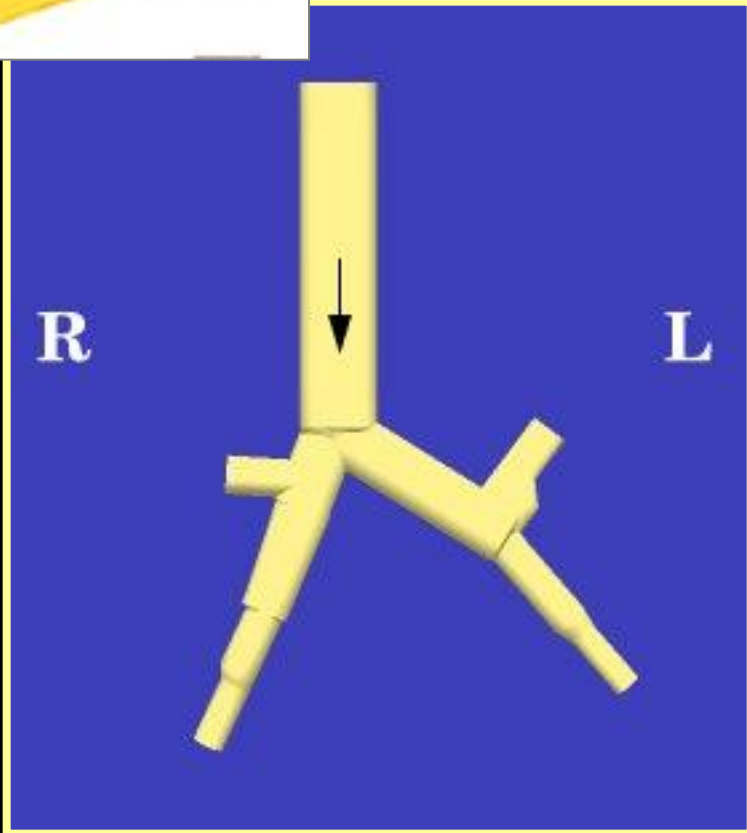




# POUMON DROIT

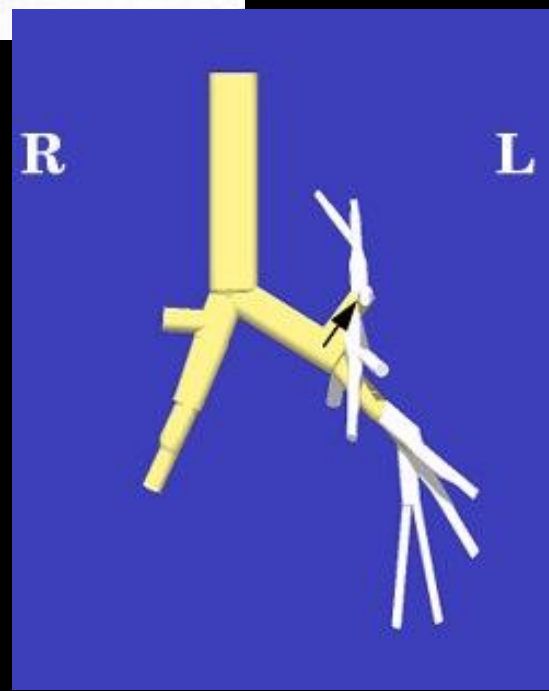
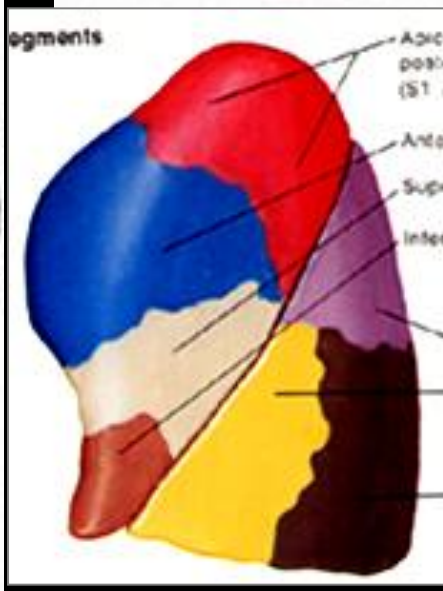
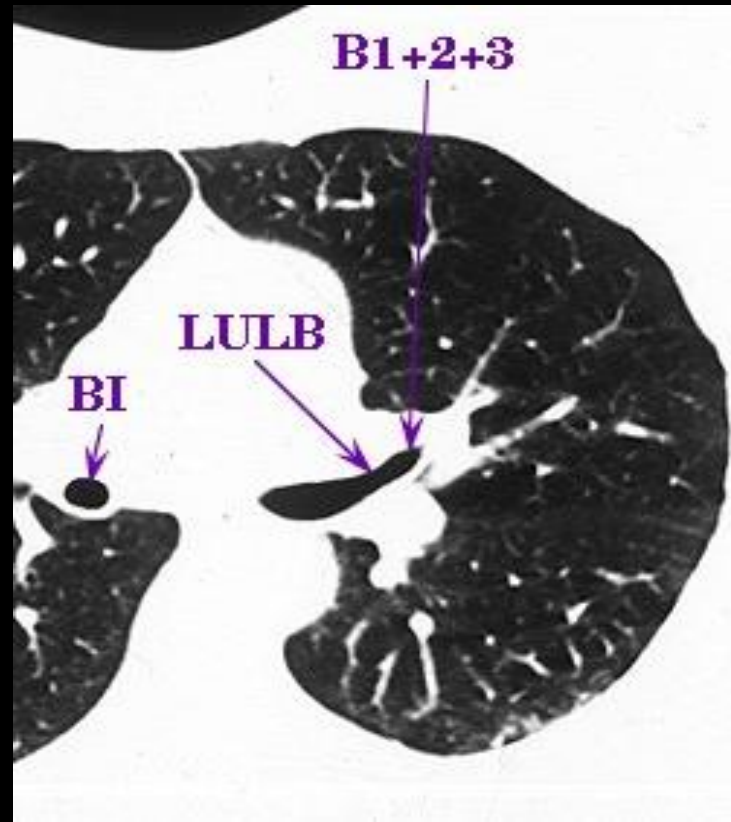
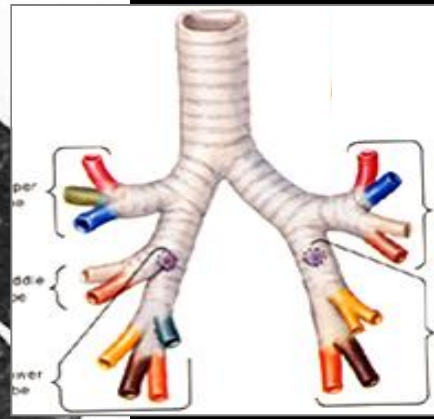
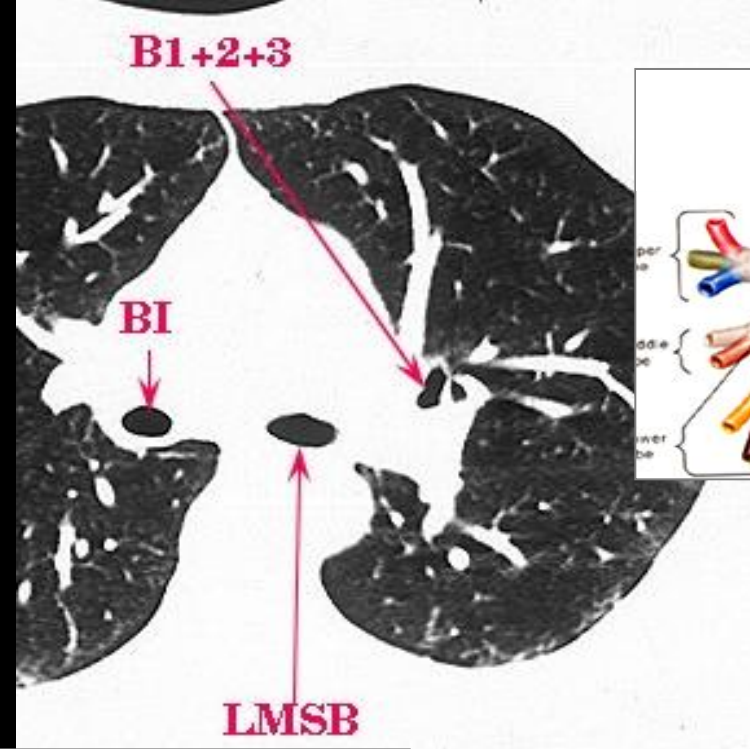


**B1 apical**

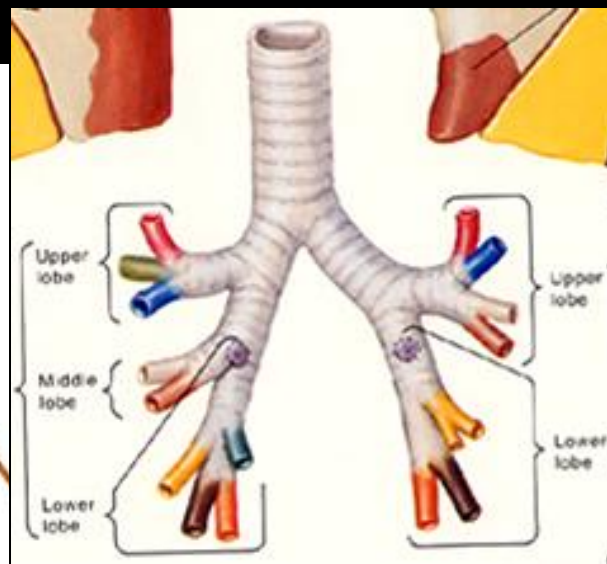


# POUMON GAUCHE

**Bronche Lobaire Supérieure**  
B1+2 apical postérieur  
B3 antérieur  
= culmen

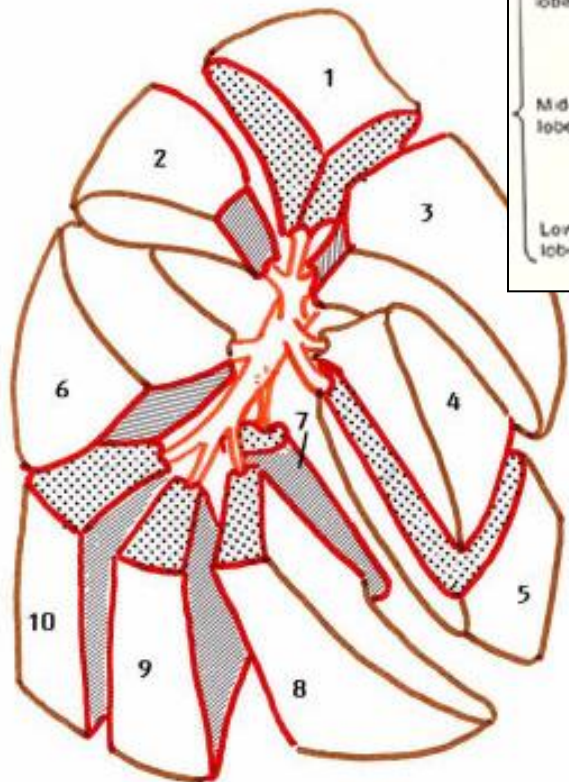


# SEGMENTATION PULMONAIRE



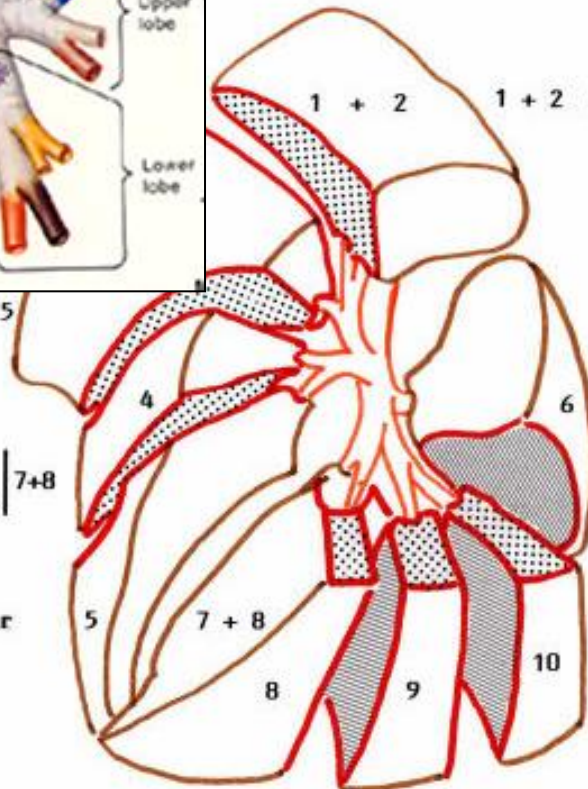
POUMON DROIT

AV  
BS



POUMON GAUCHE

AV  
BS



- 5. Médial Infér 5
- 6. Supérieur (apical du LI)
- 7. Basal médial
- 8. Basal antérieur
- 9. Basal latéral
- 10. Basal postérieur

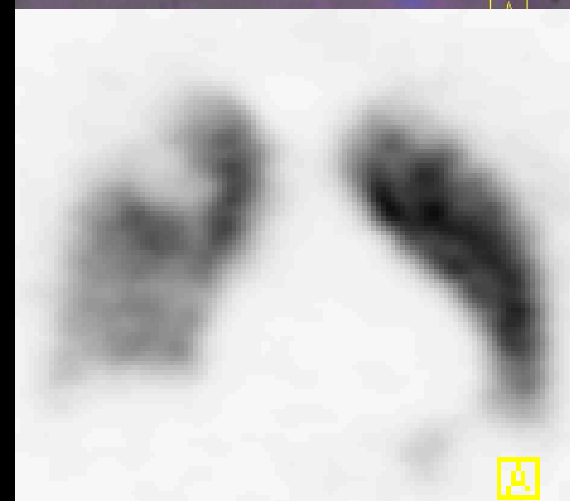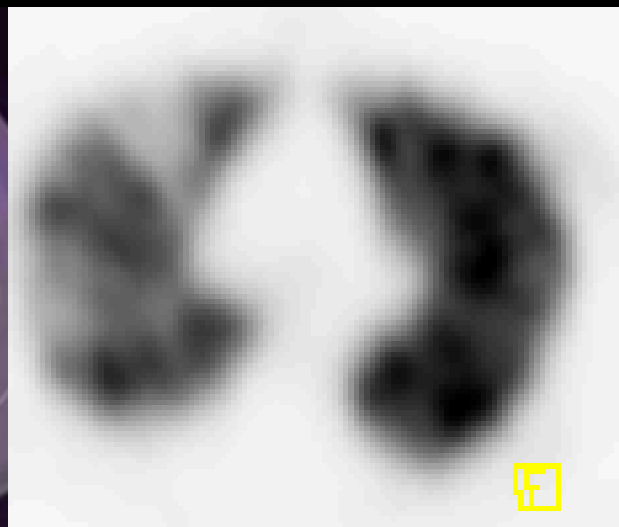
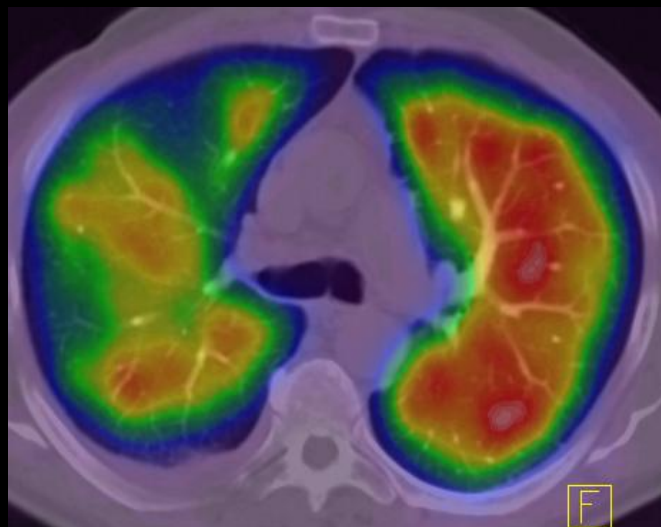
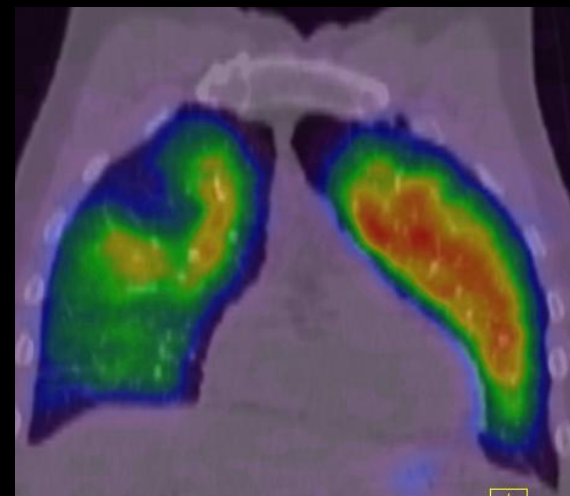
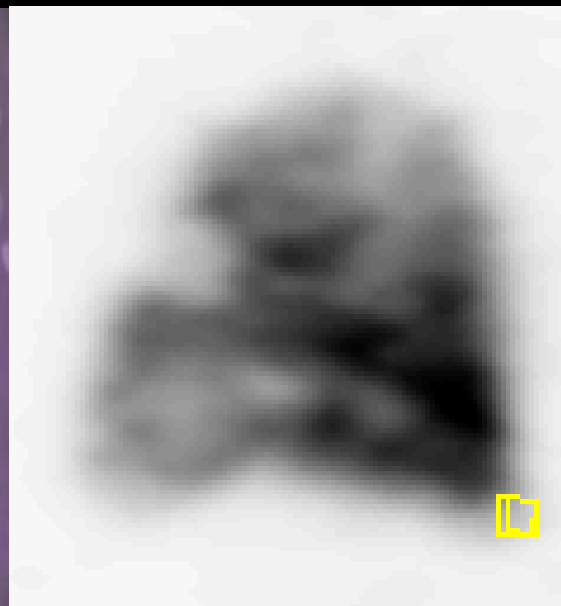
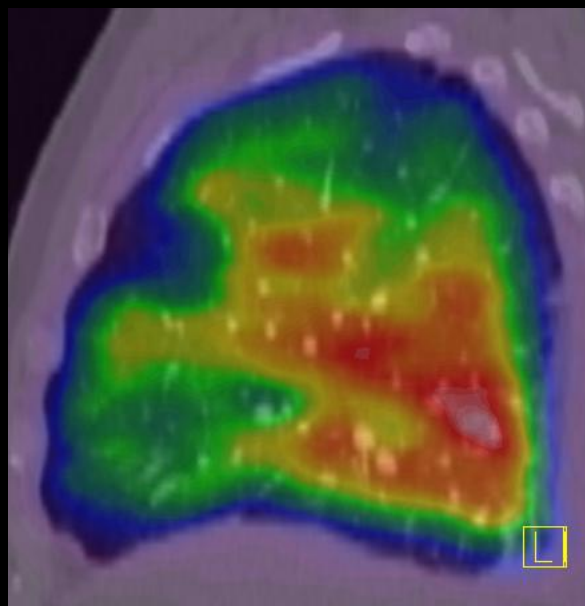
7+8

1, 2....., 10 : Nomenclature chiffrée de Boyden

7 + 8 basal antéro-médial

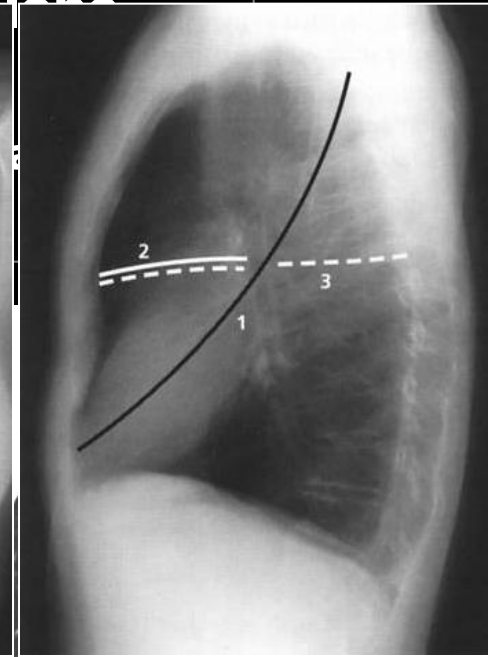
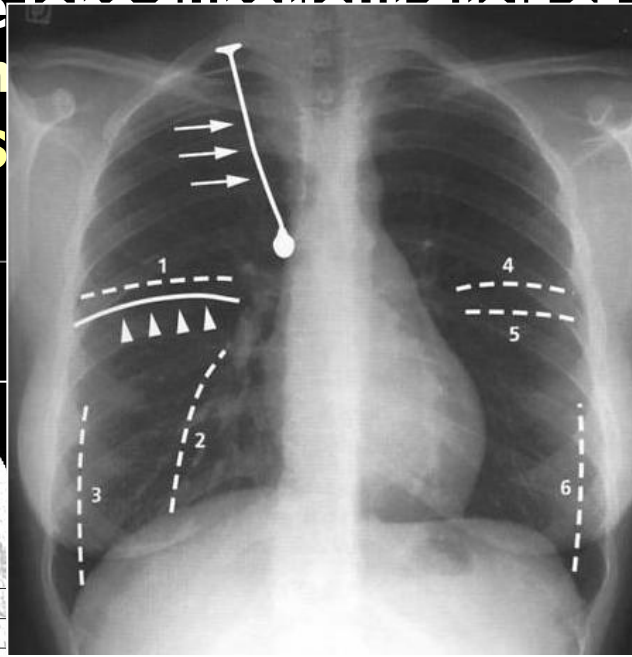
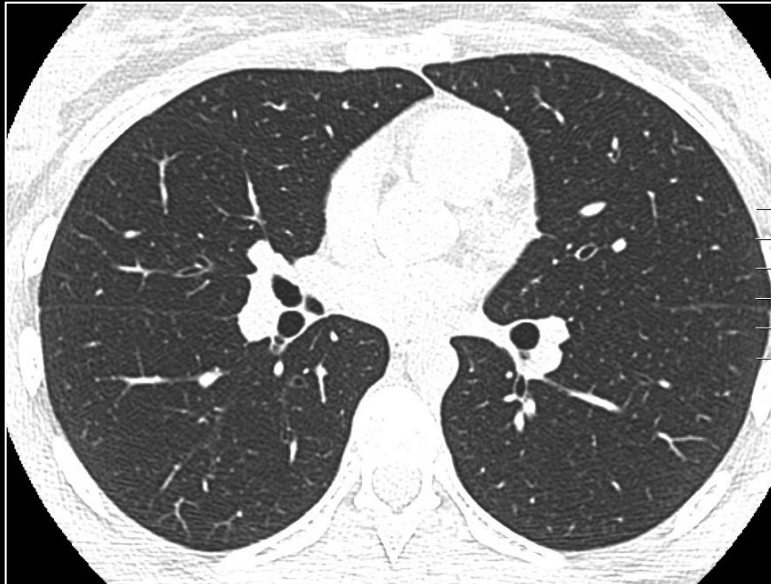1 + 2 Apico-postérieur

**Embolie pulmonaire  
segment ant et apical  
LSD**



# LES SCISSURES

- La plèvre viscérale s'insinue dans les scissures
- **GRANDES SCISSURES** entre les lobes supérieur et inférieur et sont obliques
- **PETITE SCISSURE** entre le lobe supérieur droit et lobe moyen et est proche de l'h
- **SCISSURES ACCESSOIRES** verticale externe...



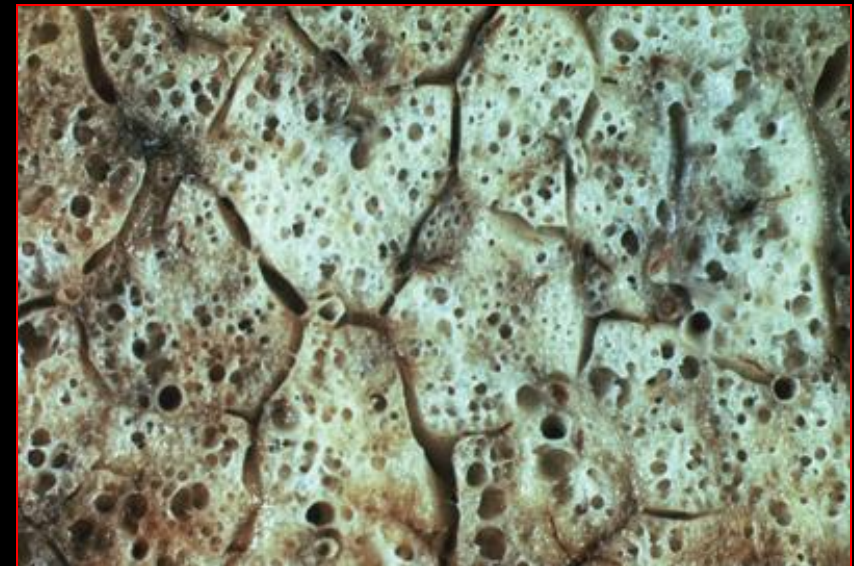
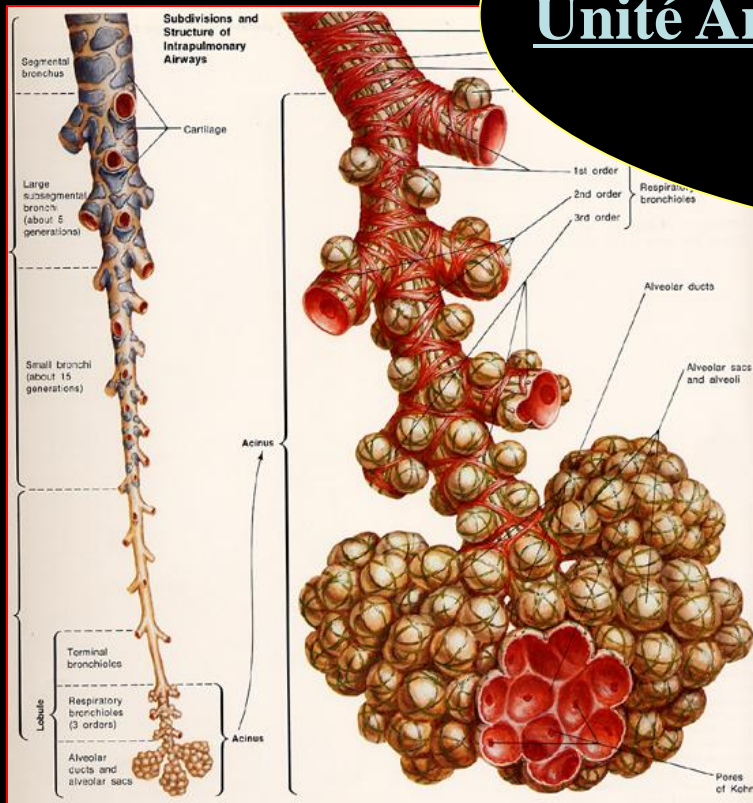
- 1.Scissure du segment S6 droit
- 2.Scissure para-cardiaque droite
- 3.Scissure verticale externe gauche
- 4.Scissure linguale
- 5.Scissure du segment S6 gauche
- 6.Scissure verticale externe gauche

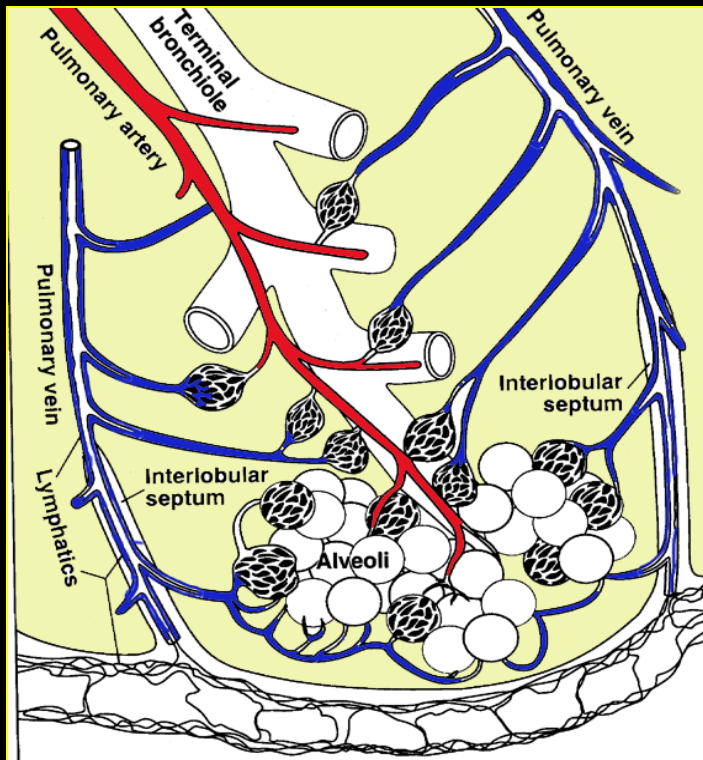
# Imagerie du Lobule Secondaire

- grâce au **Scanner Haute Résolution** (coupes millimétriques)

## Lobule II de Miller

Unité Anatomique et Fonctionnelle du poumon  
Polyédrique, 1 à 1,5 cm  
Contient 3 à 5 acini





**Bronchiole centrolobulaire**

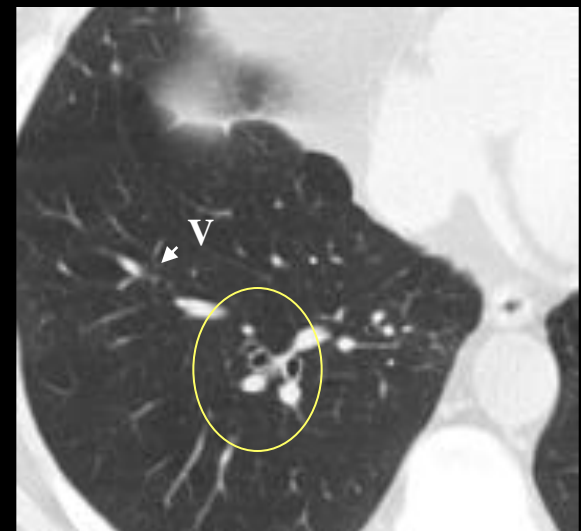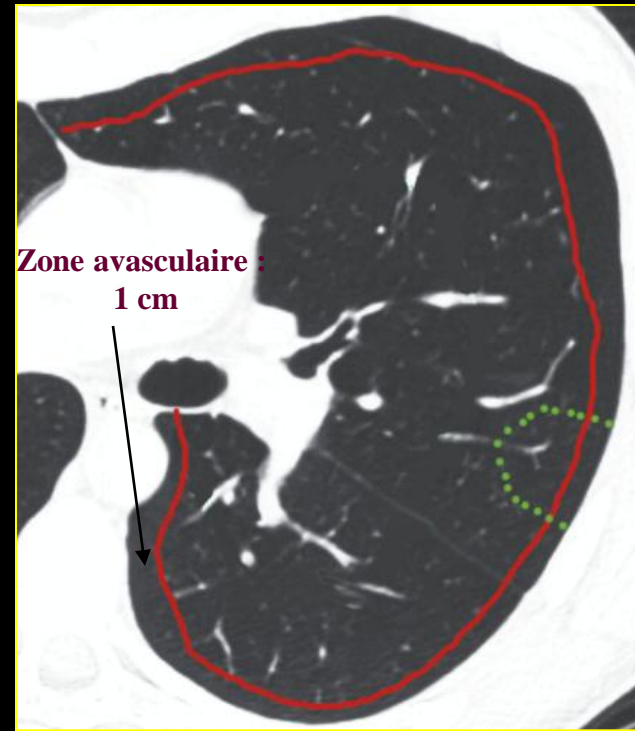
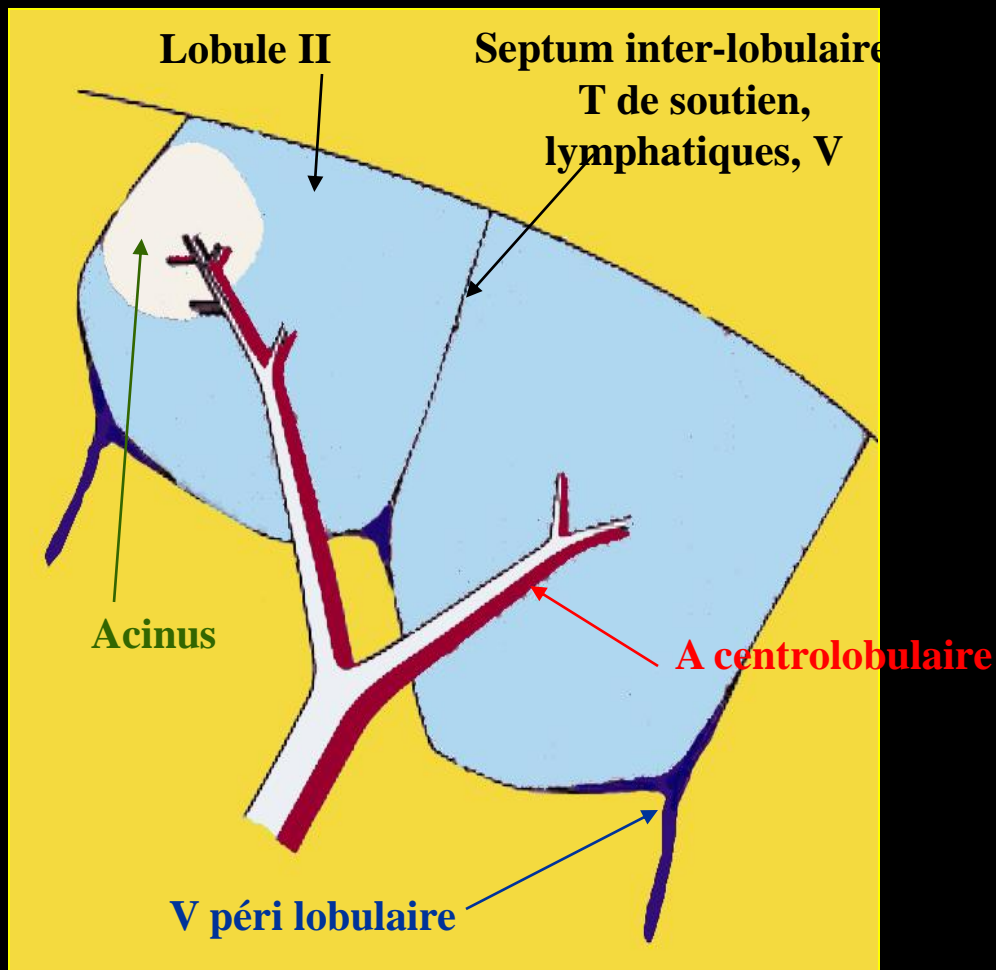


**Bronchioles terminales**



**Bronchioles respiratoires/ bordées  
d'alvéoles (=acinus ou lobule primaire  
de Miller)**

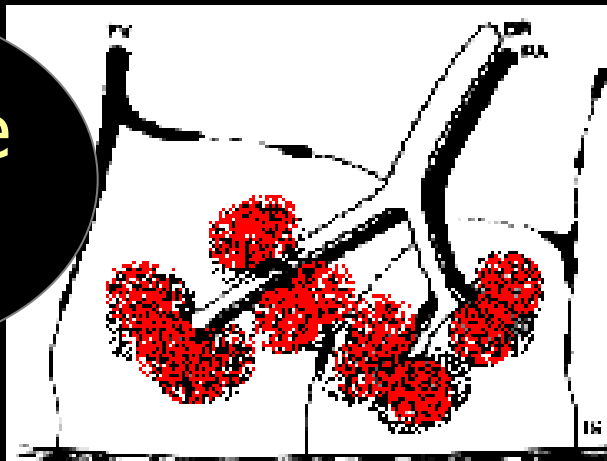- ✓ **Membrane Air/Sang** : Échanges gazeux alvéolo-capillaires
- ✓ **Secteur Interstitiel** (de soutien) :
  - Inter et péri lobulaire (V et lymphatiques)
  - Sous pleural
  - Péri Bronchovasculaire (jusqu'au hile)
- ✓ **Secteur aérique** : alvéolaire, bronchique




**A l'état normal :**  
**Bronchioles et septa non vus, en périphérie**  
**A. visualisées plus loin que V.**

# Différentes atteintes pulmonaires

Aérique  
Alvéoles,  
Bronches

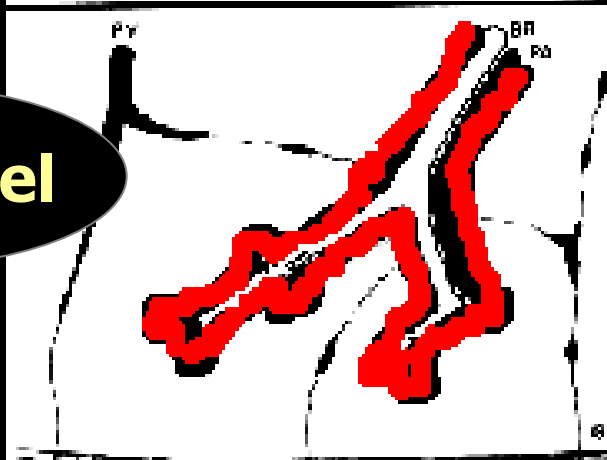


Centilobular

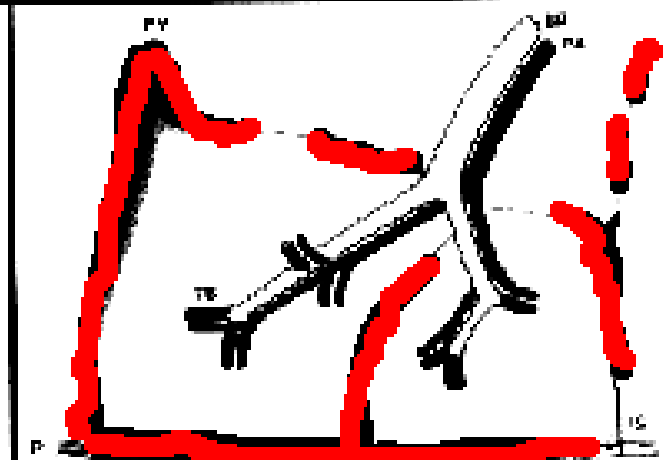


Panlobular

Interstitiel

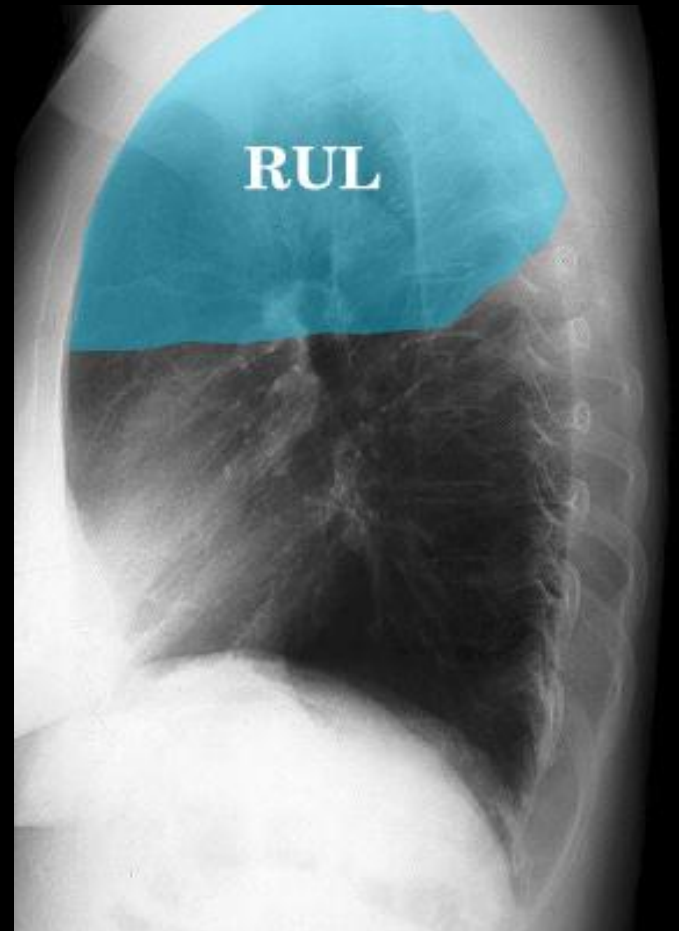
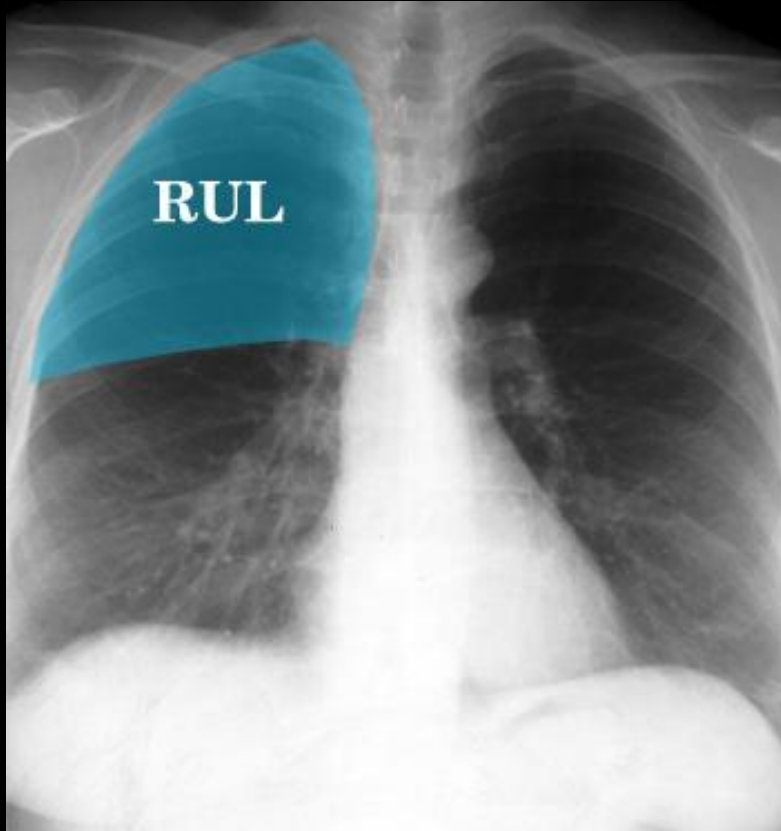


T. Soutien péri-broncho-vascul

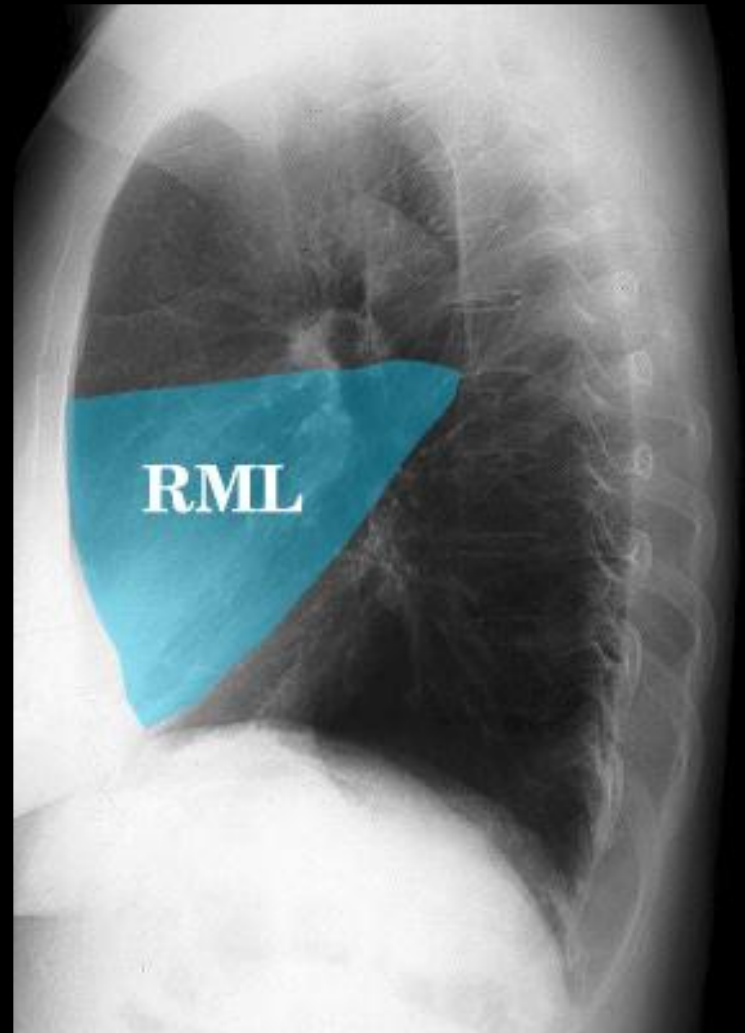
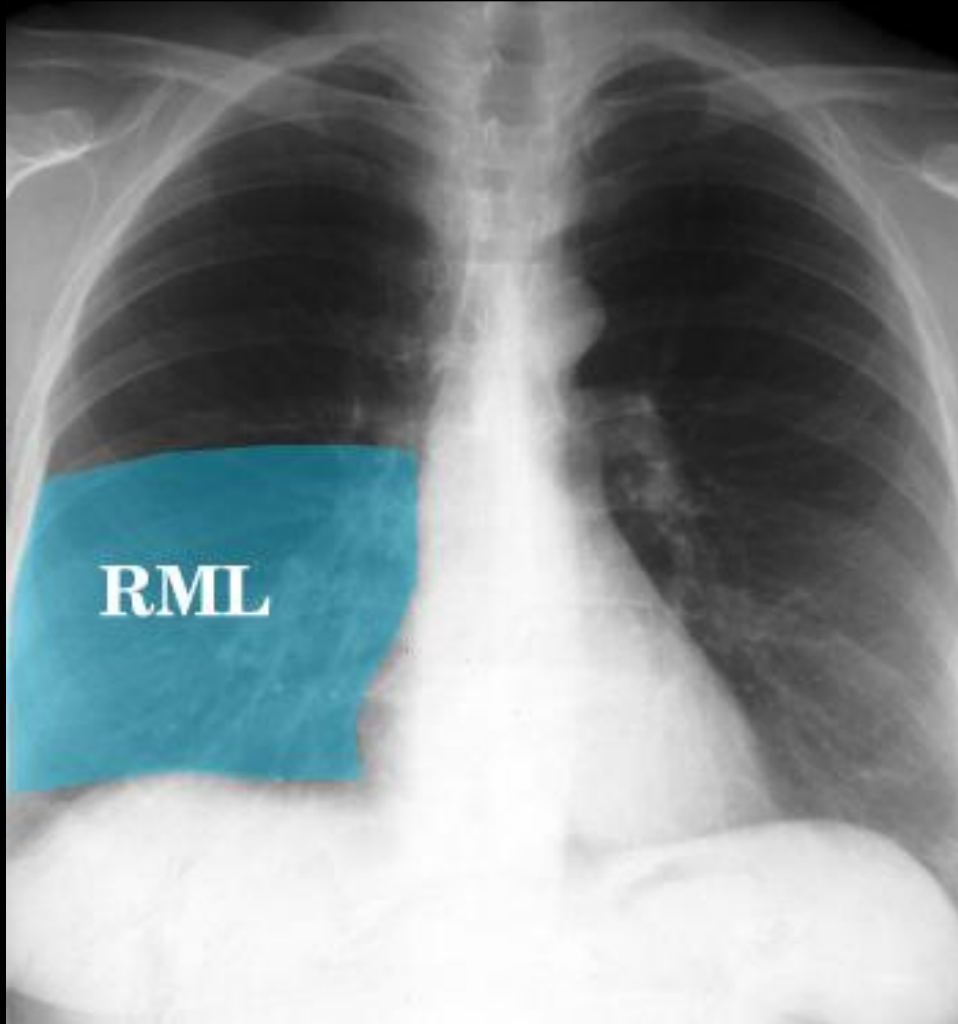


Septal (Perilobular)

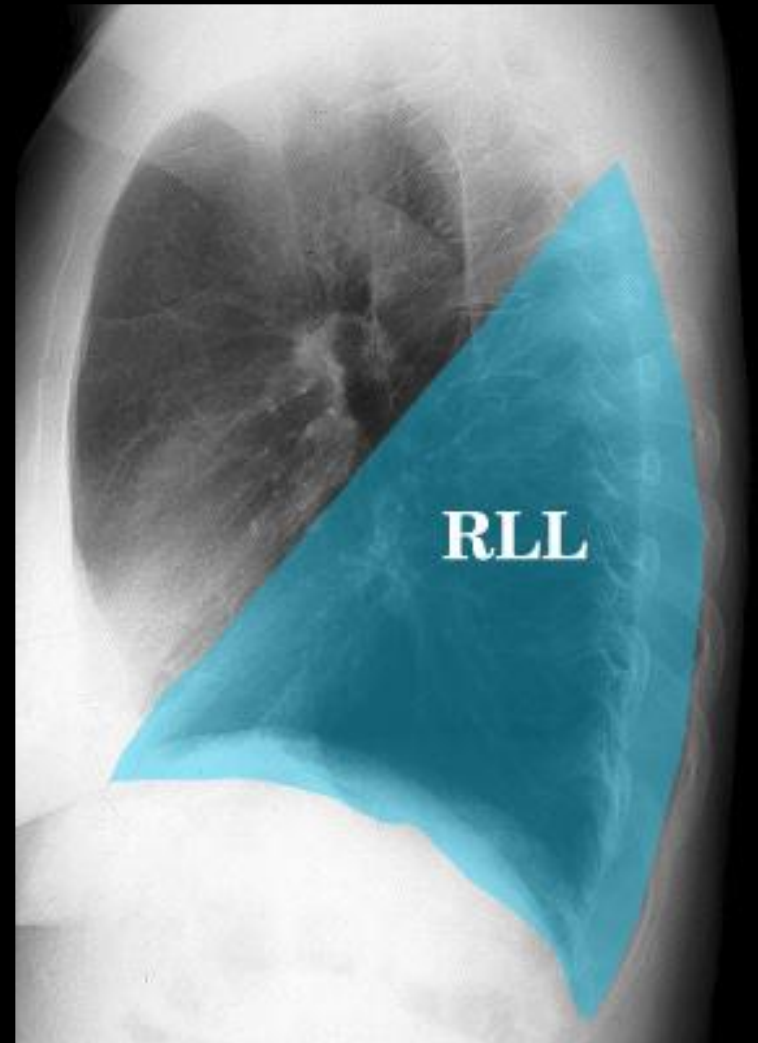
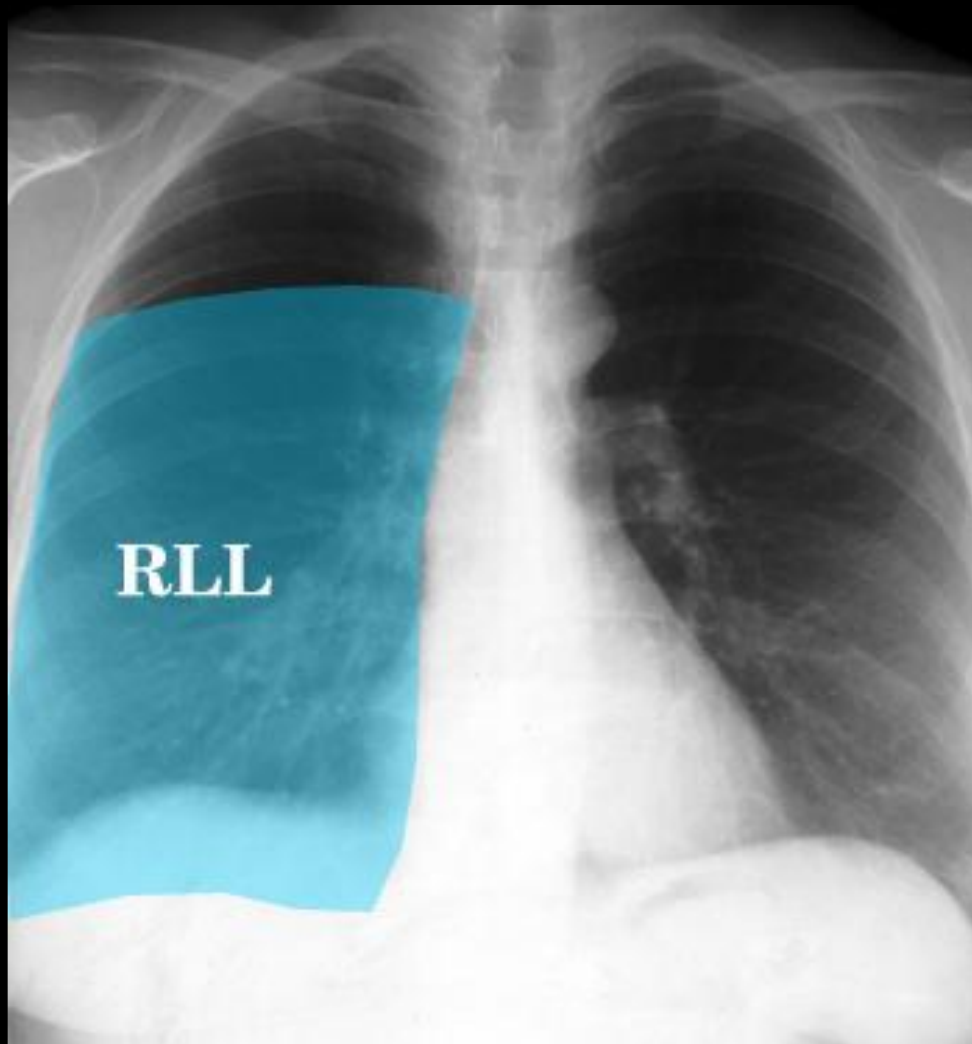
## Radiographie standard



**Lobe supérieur droit**

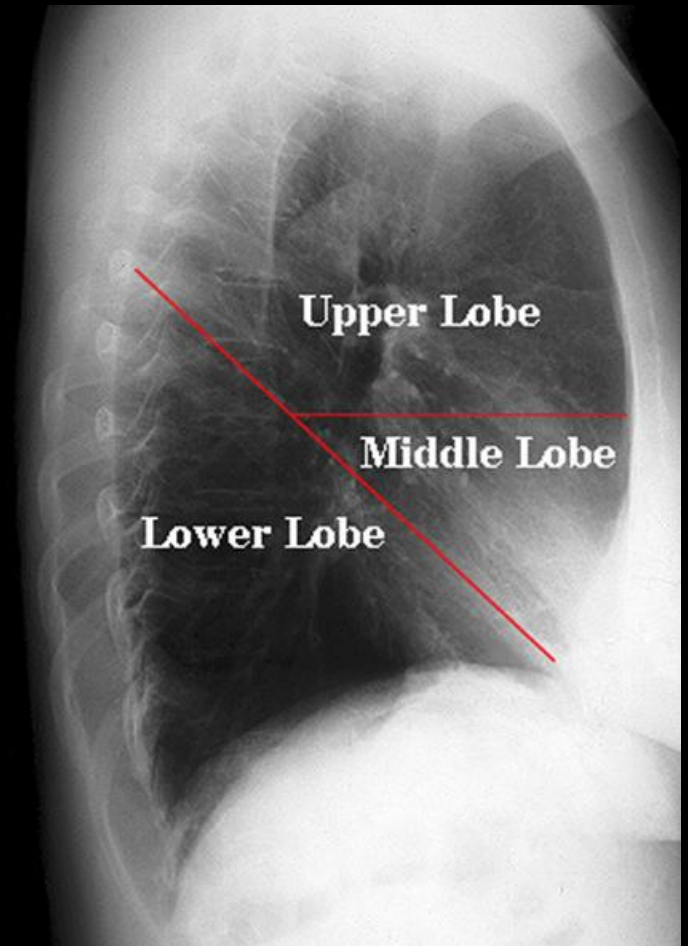
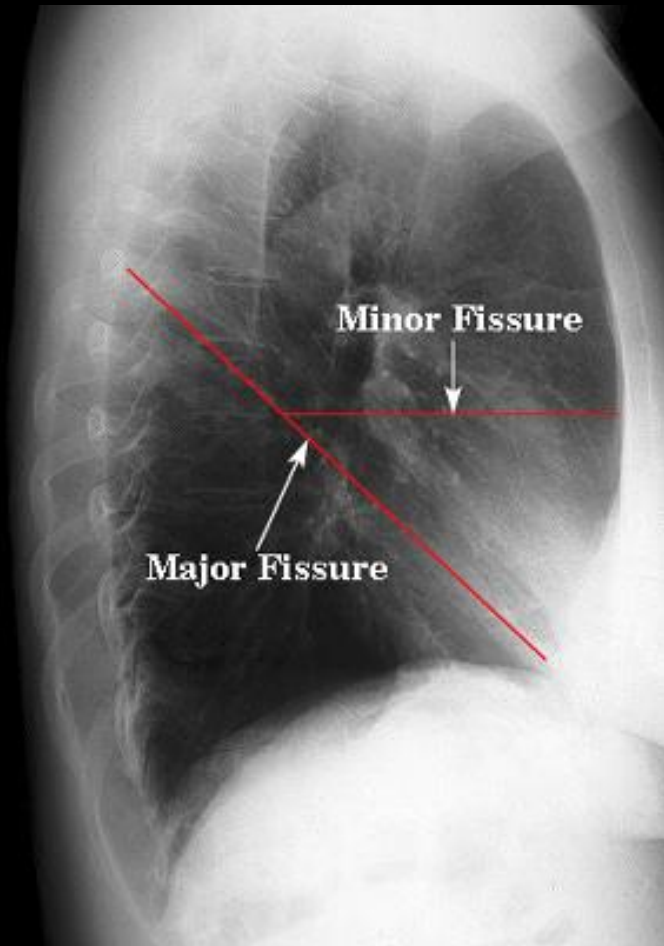


**Lobe moyen**



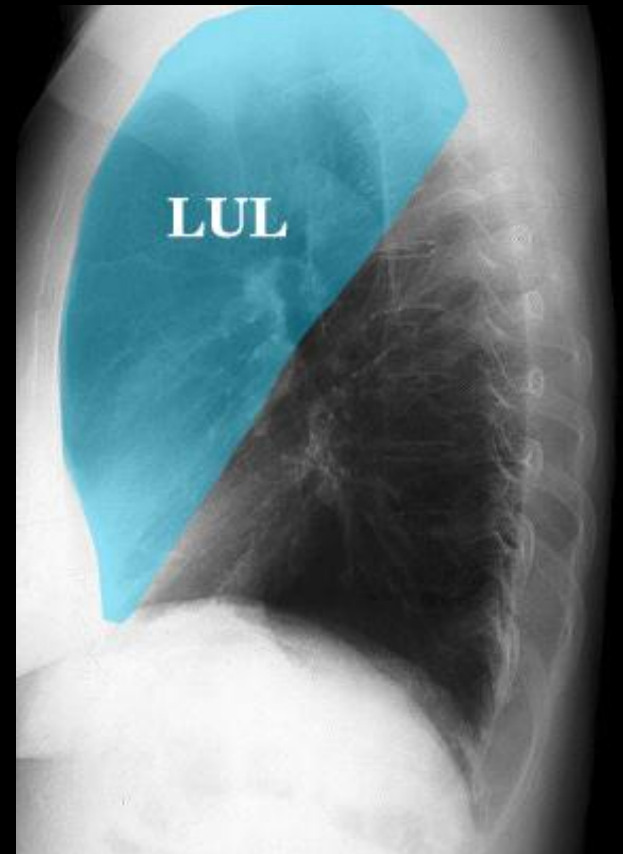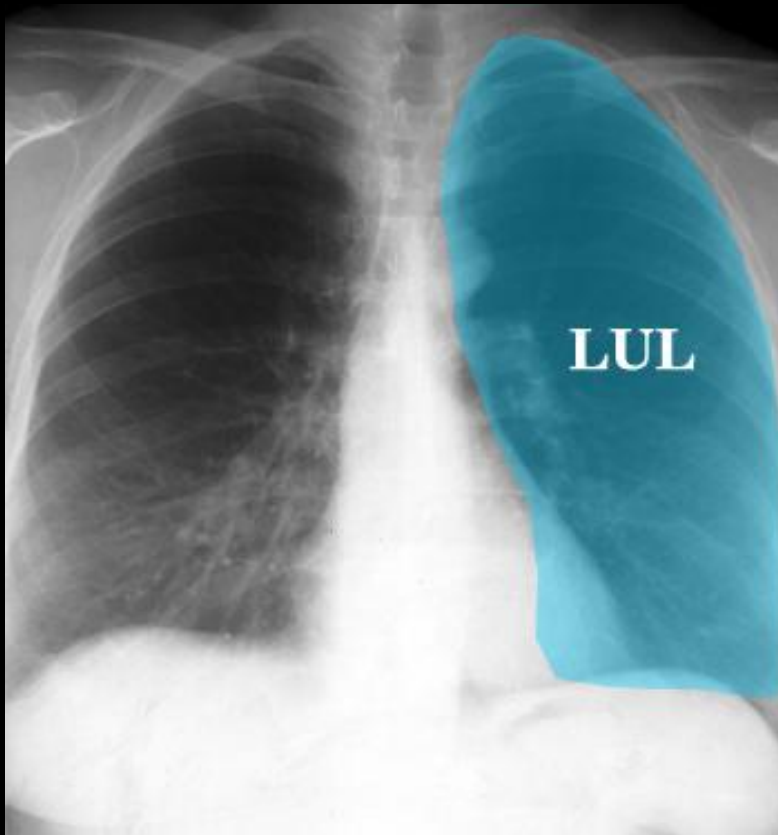
**Lobe inférieur droit**

# A droite: les scissures

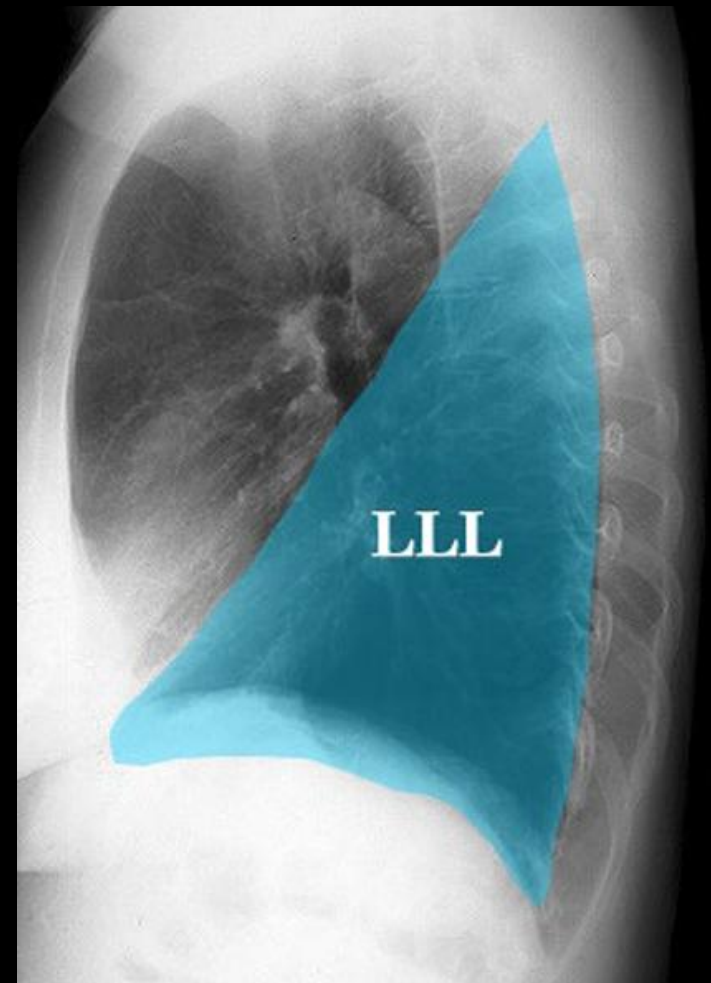
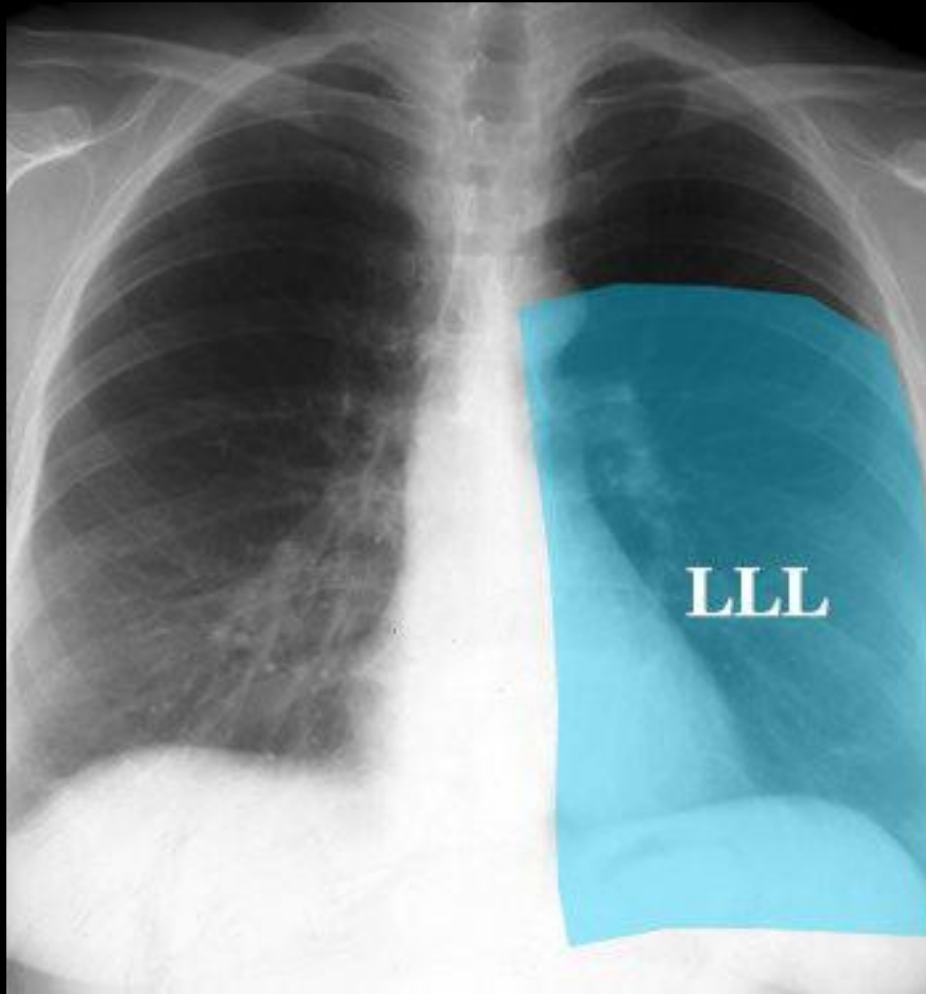


# Application : Le signe de la silhouette de Felson

- 2 structures de tonalité hydrique se confondent si elles sont situées dans le même plan
- De grande valeur pour la détermination topographique d'une opacité intra thoracique qu'elle soit médiastinale ou pulmonaire : en effet deux opacités qui se silhouettent (en effaçant leur bord) se trouvent sur un même plan.
- ex : opacité dans le lobe moyen effaçant le bord droit du coeur.

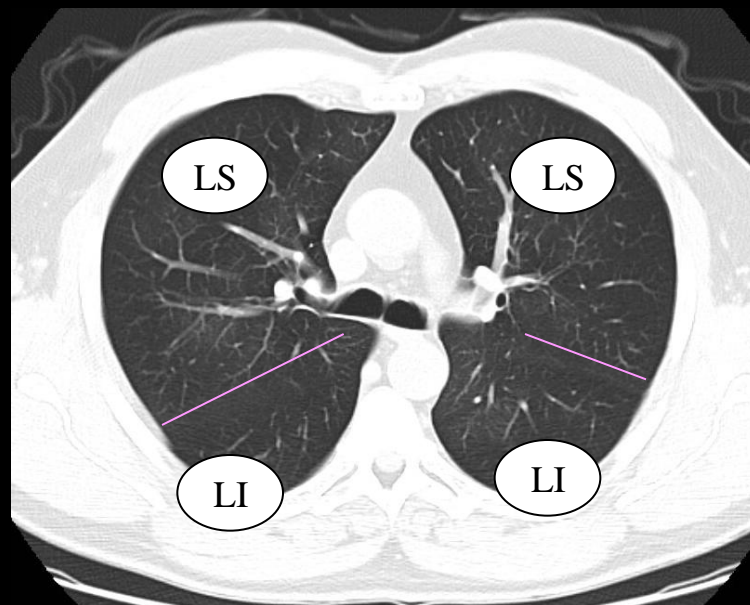
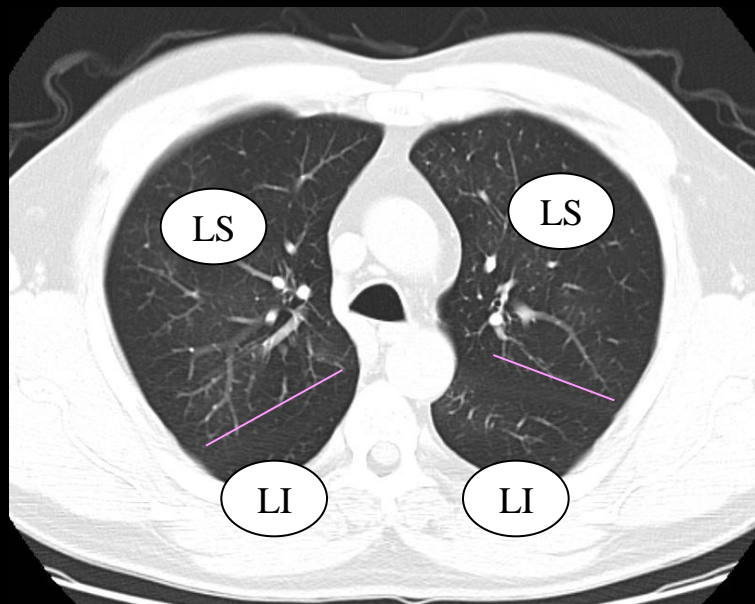
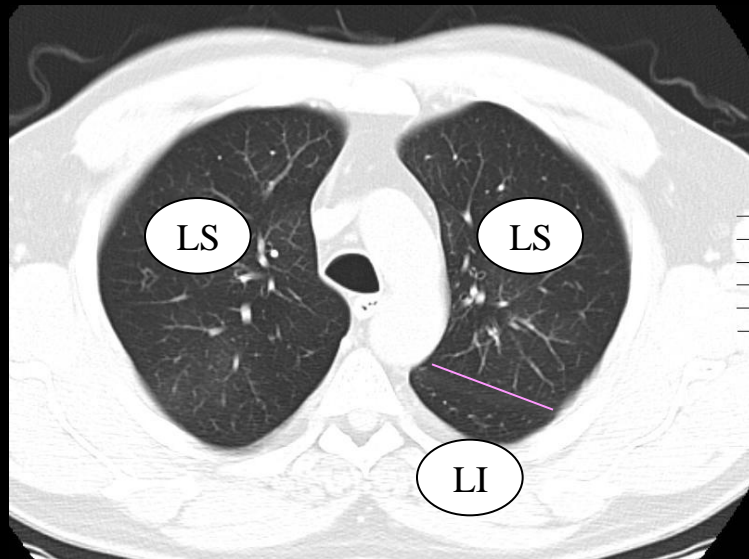
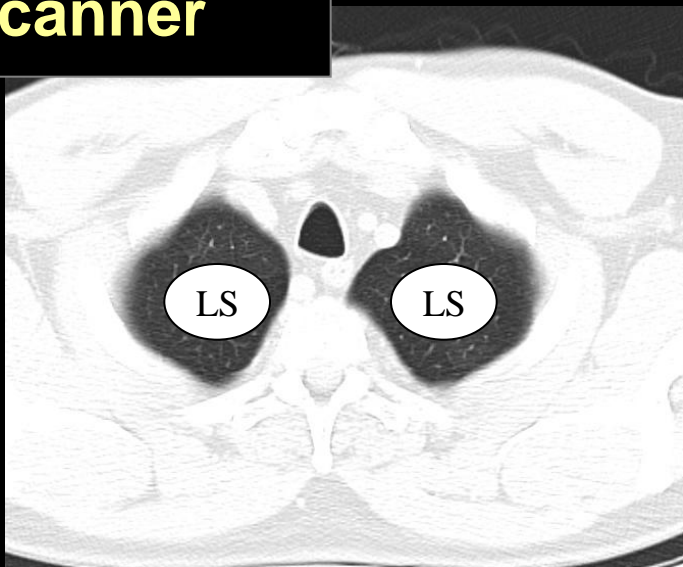


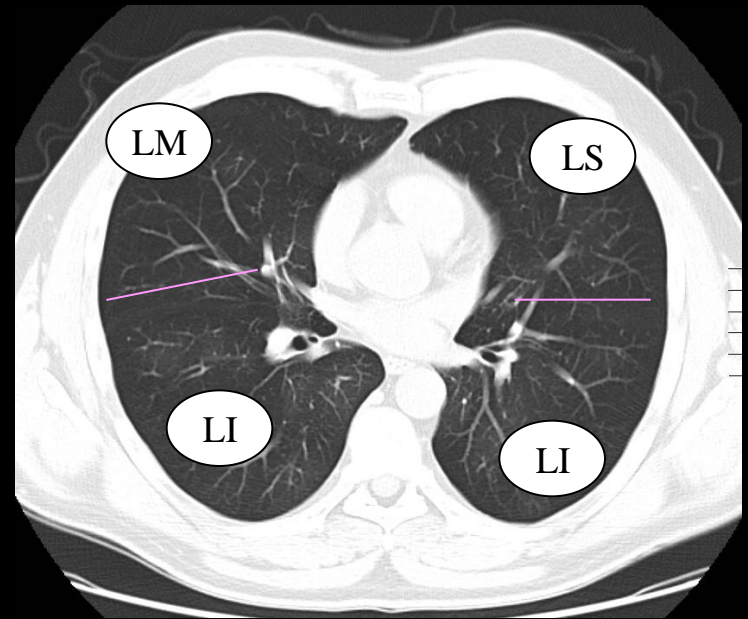
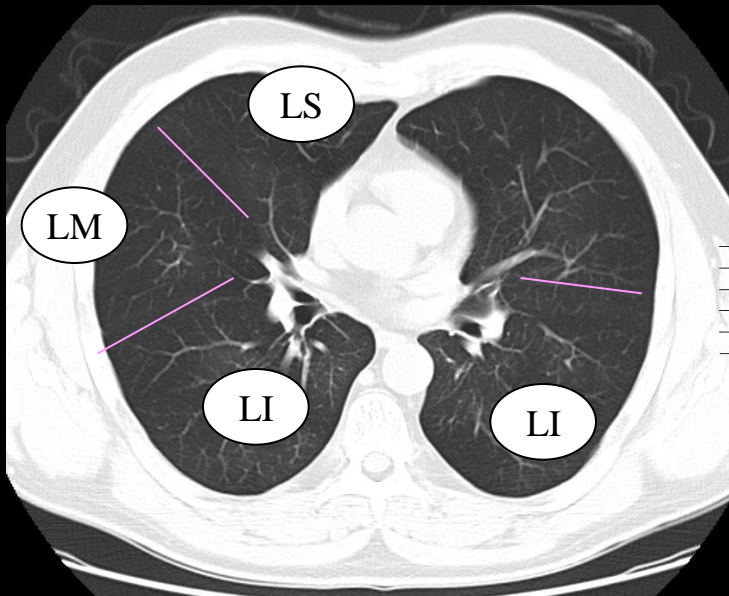
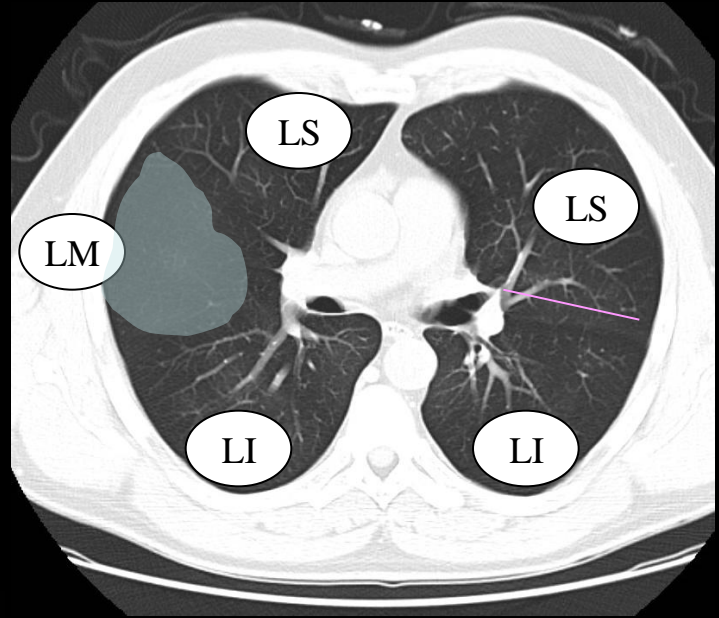
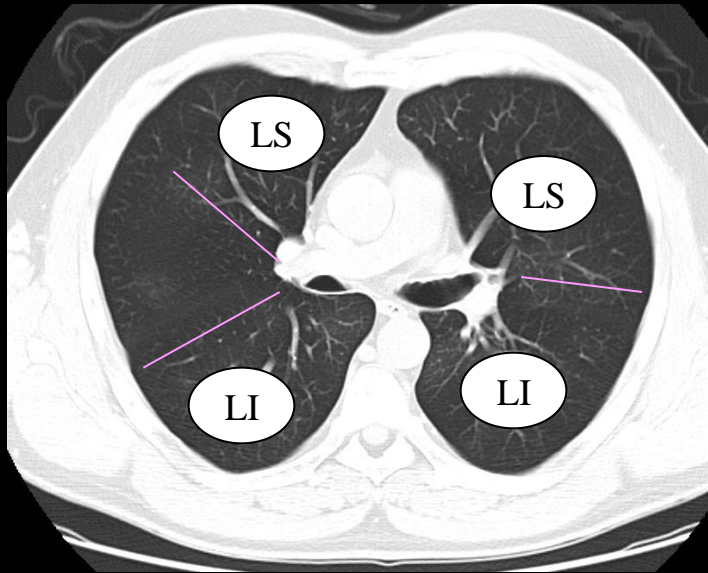
**Lobe supérieur gauche**

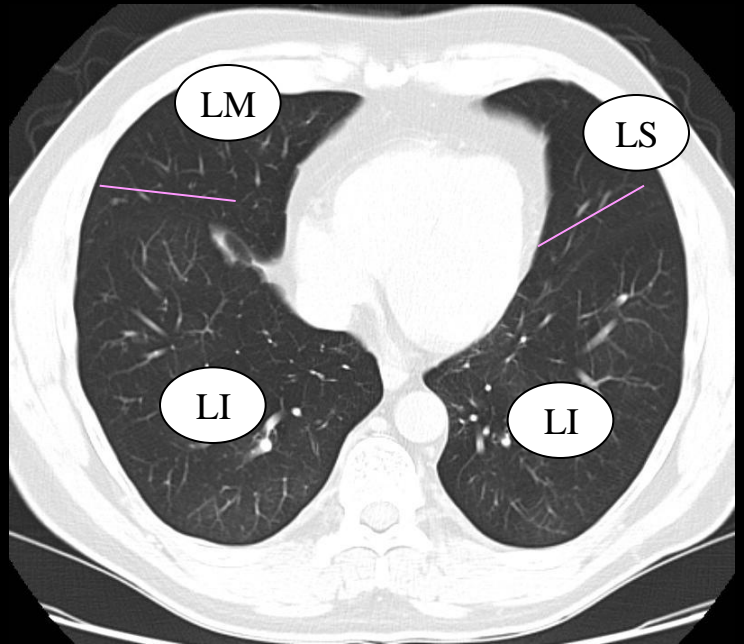
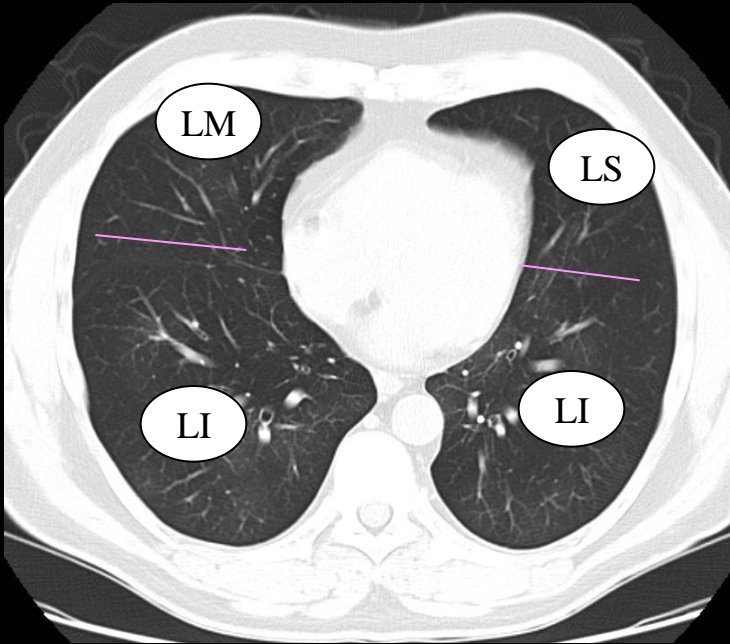
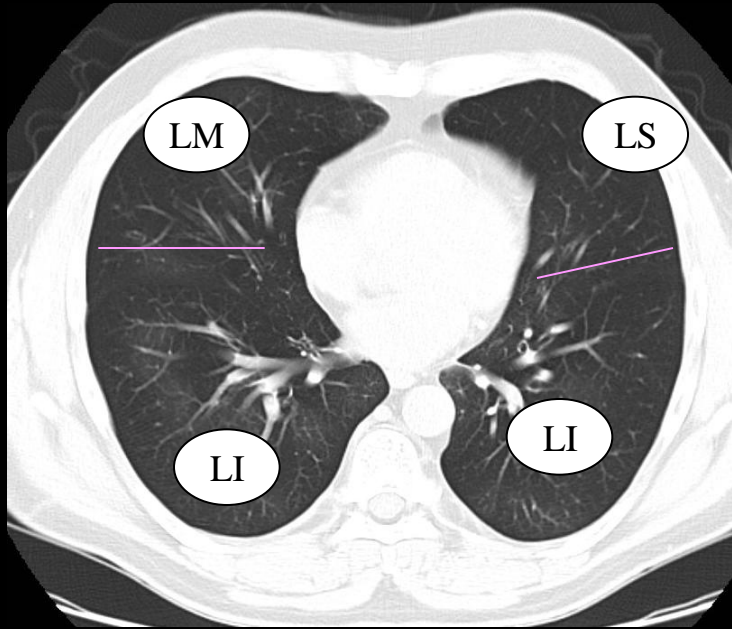
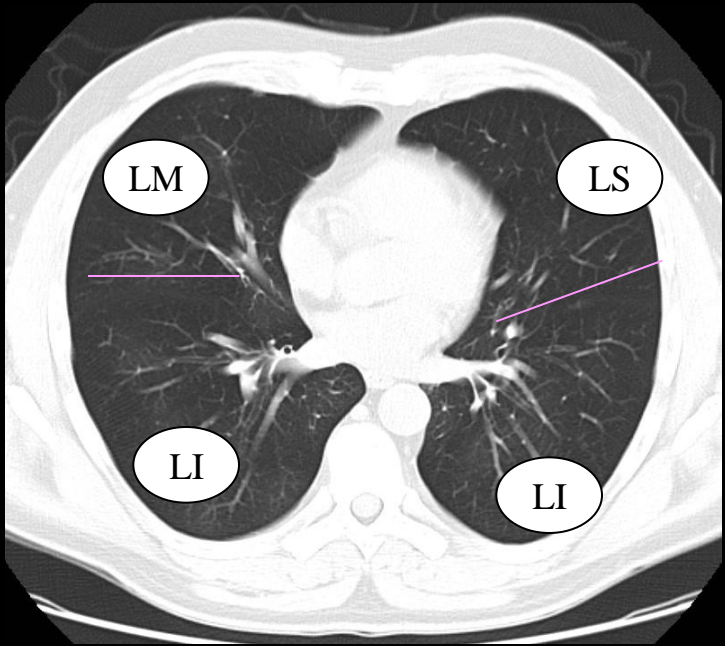


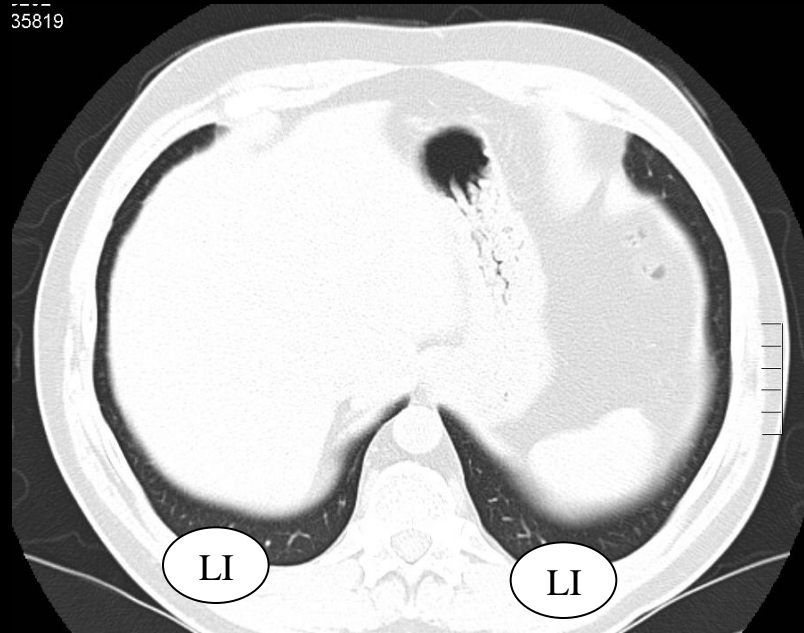
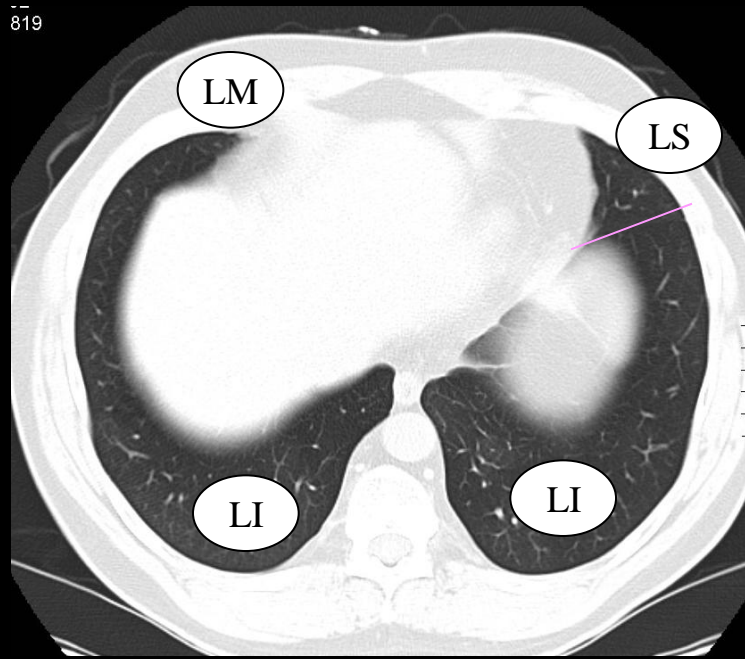
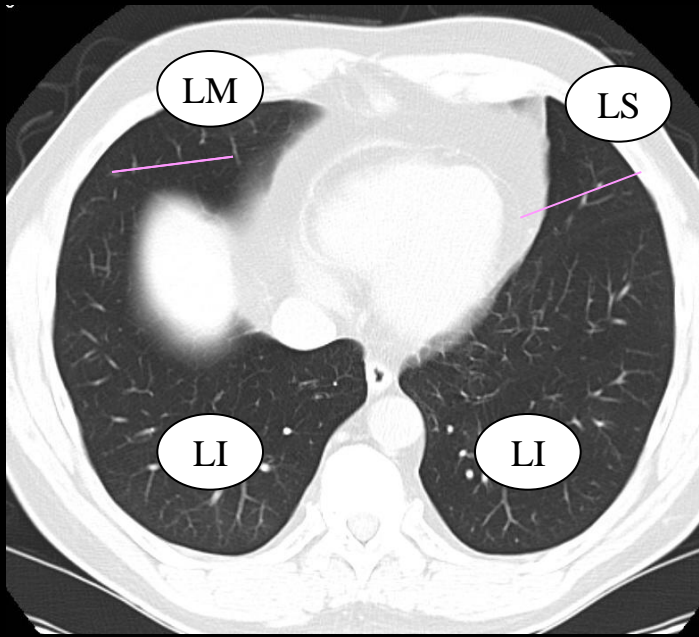
**Lobe inférieur gauche**

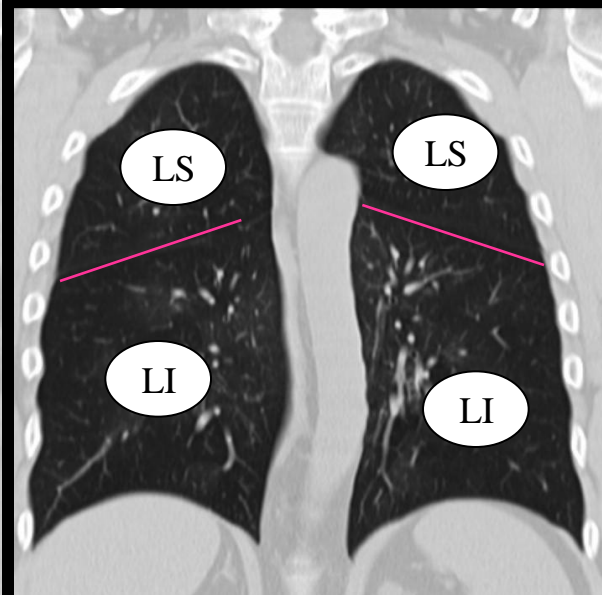
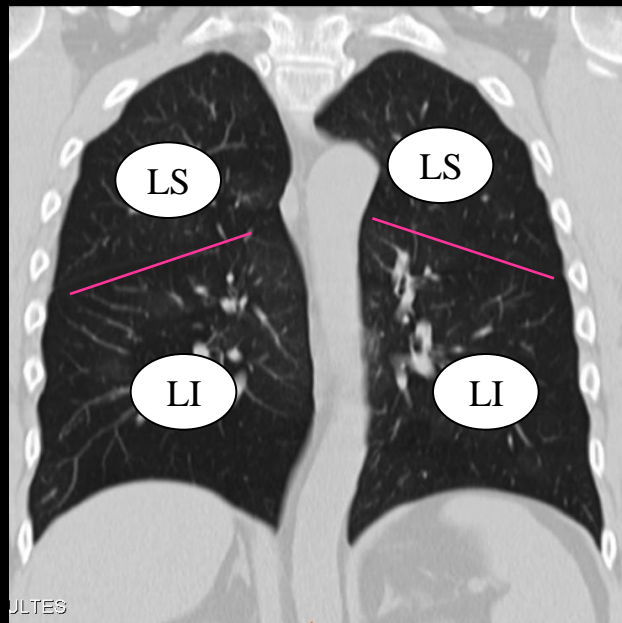
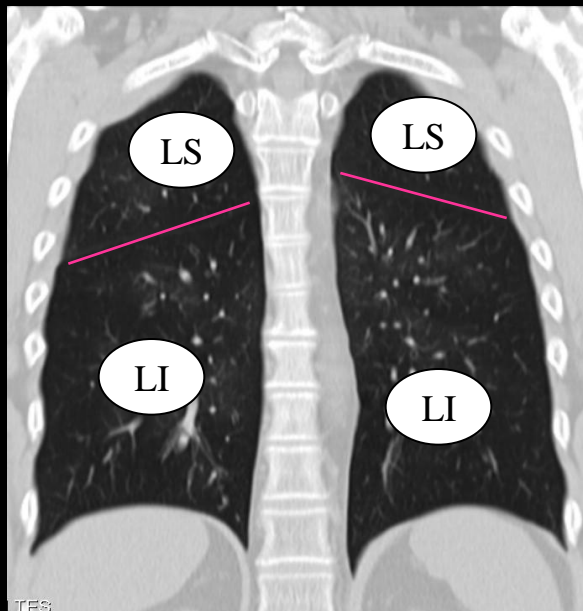
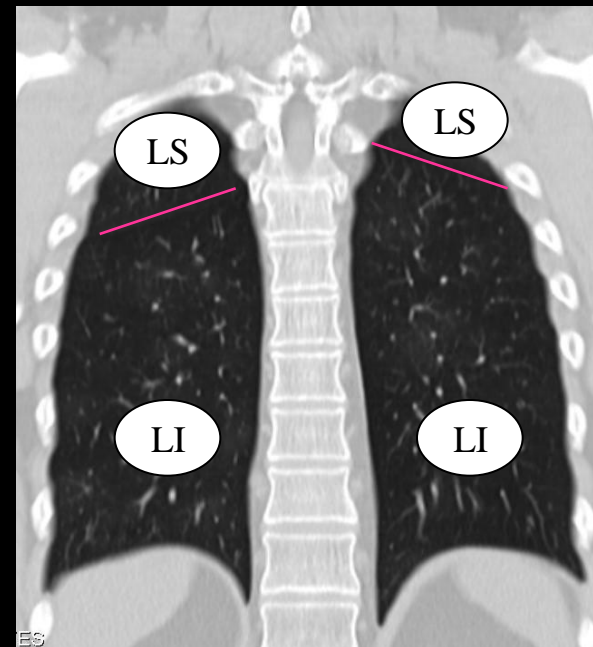
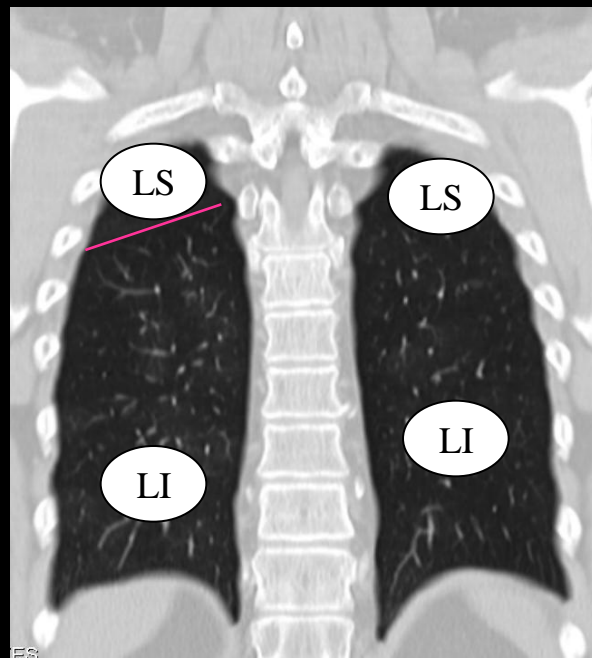
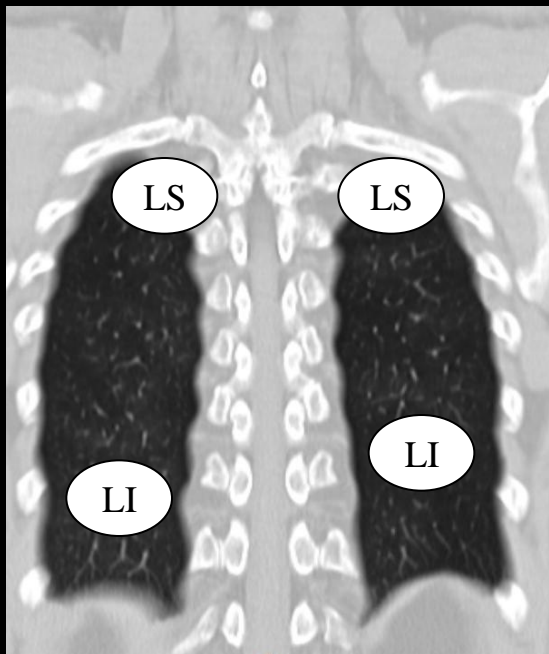
# Scanner

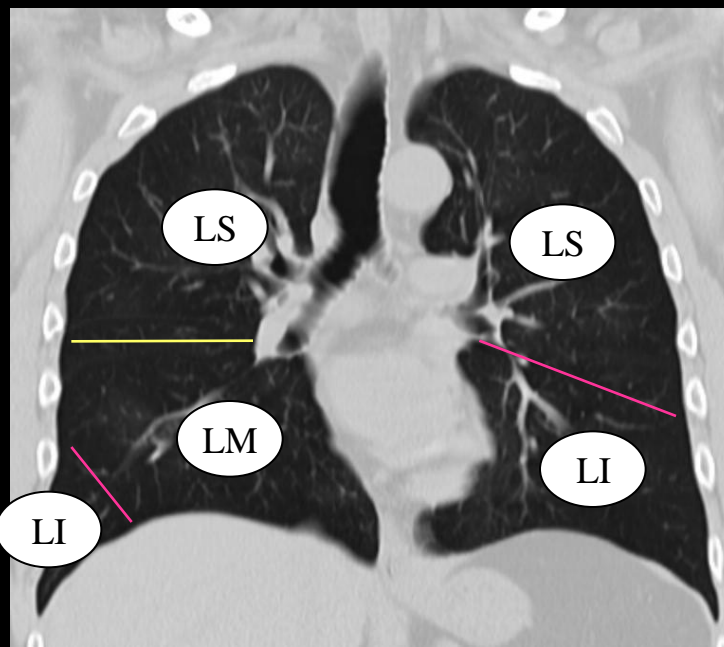
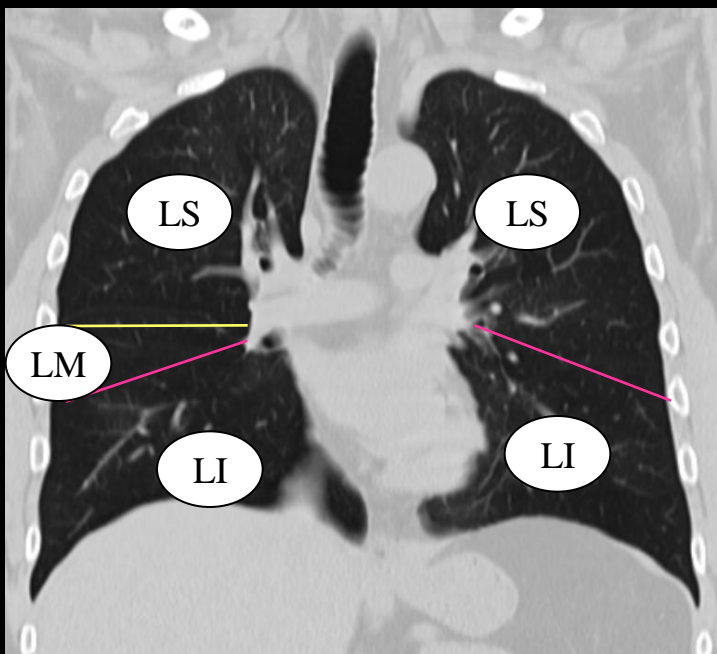
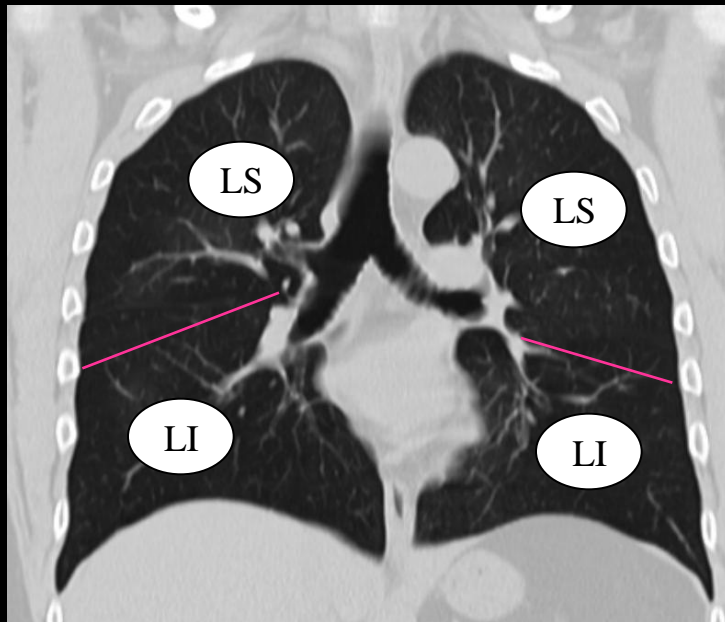
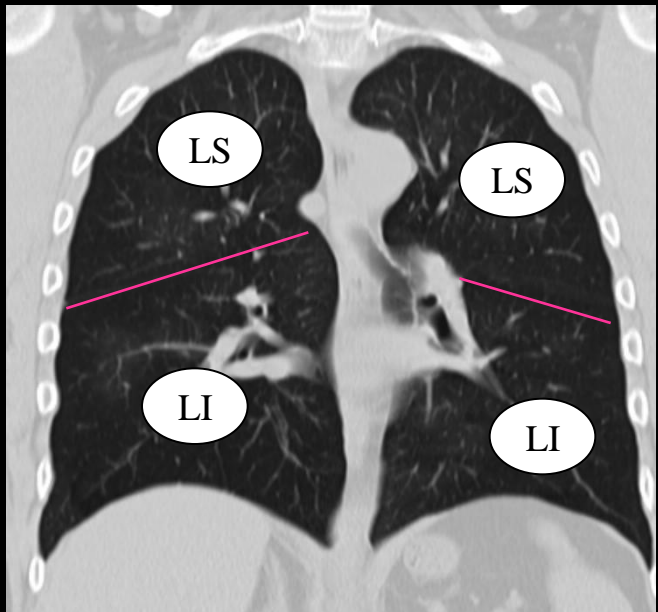


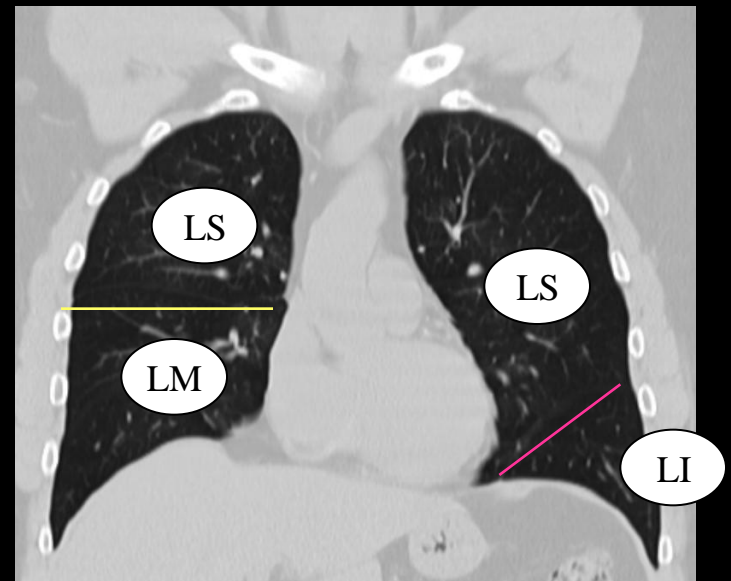
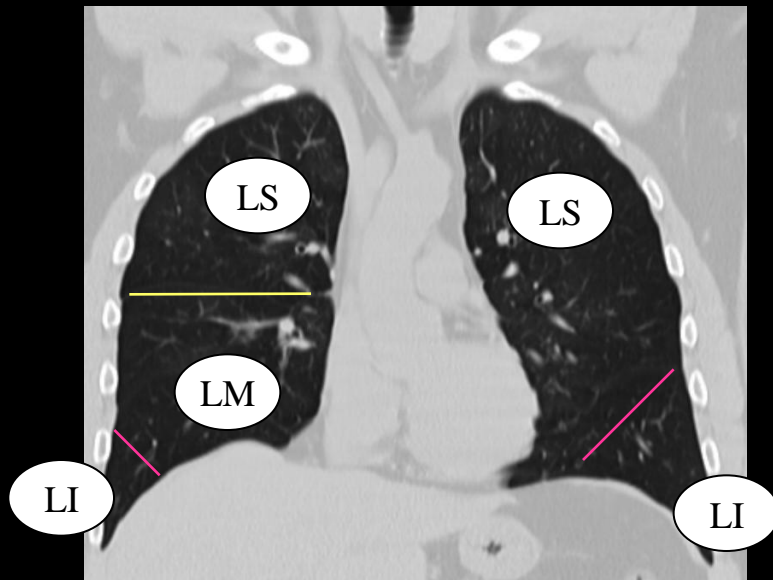
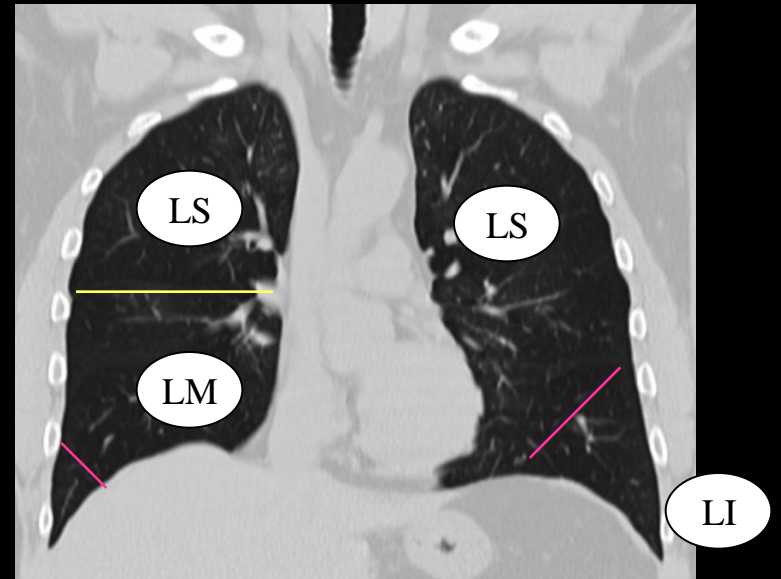
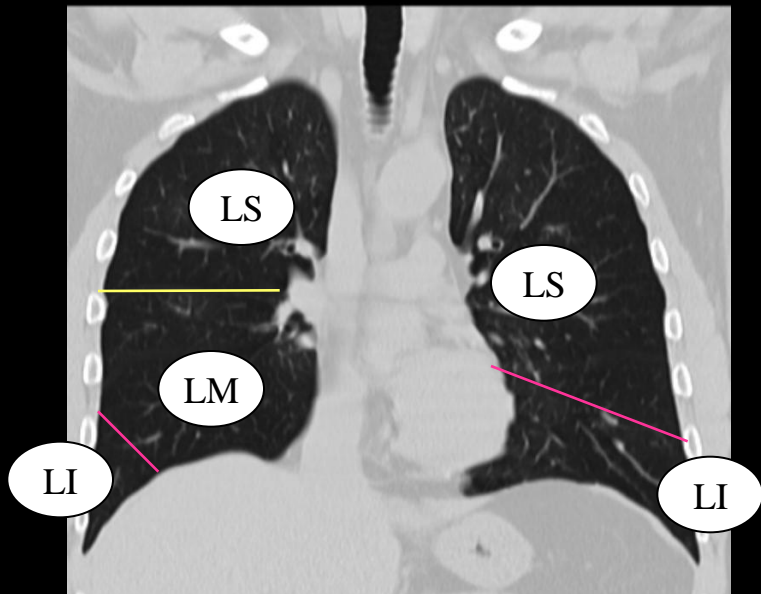








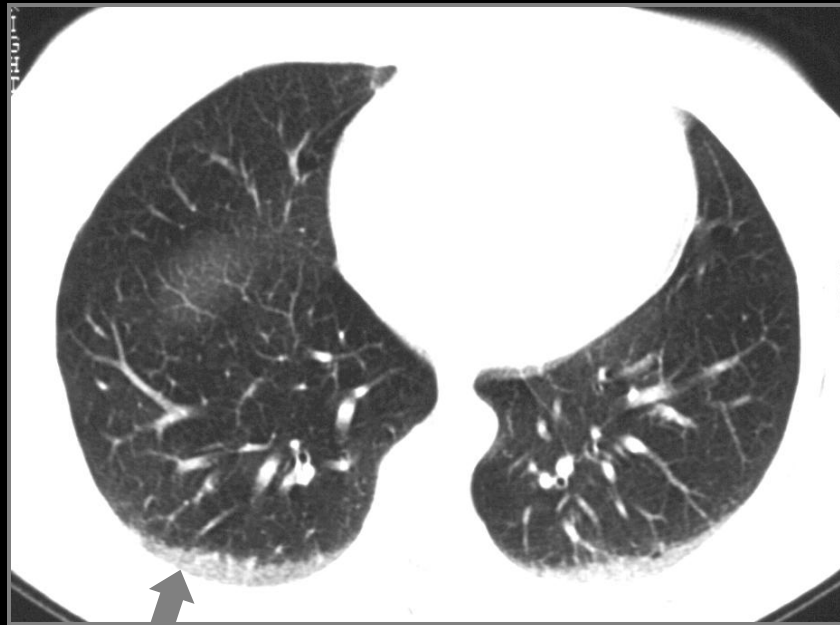






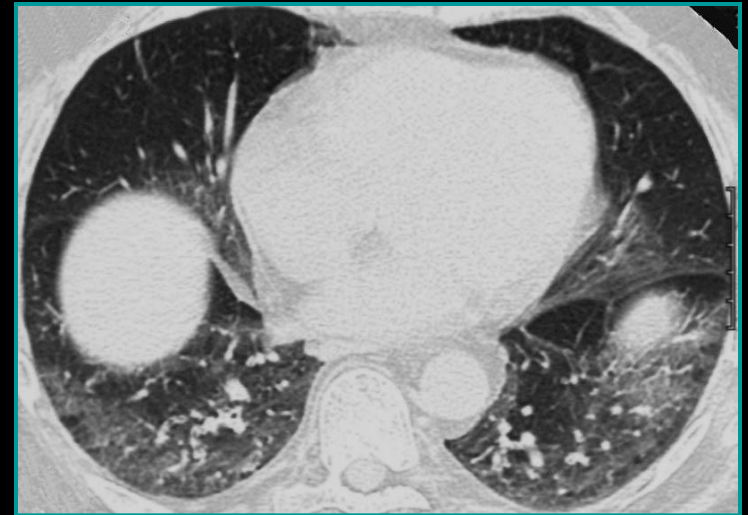**UN PEU DE PATHOLOGIE ET  
VARIATIONS ANATOMIQUES...**

# Stase Physiologique

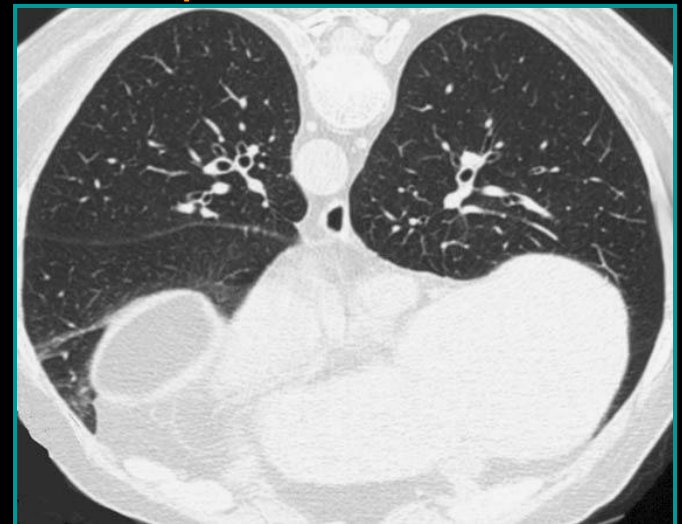

Territoires  
Déclives

inspiration



procubitus


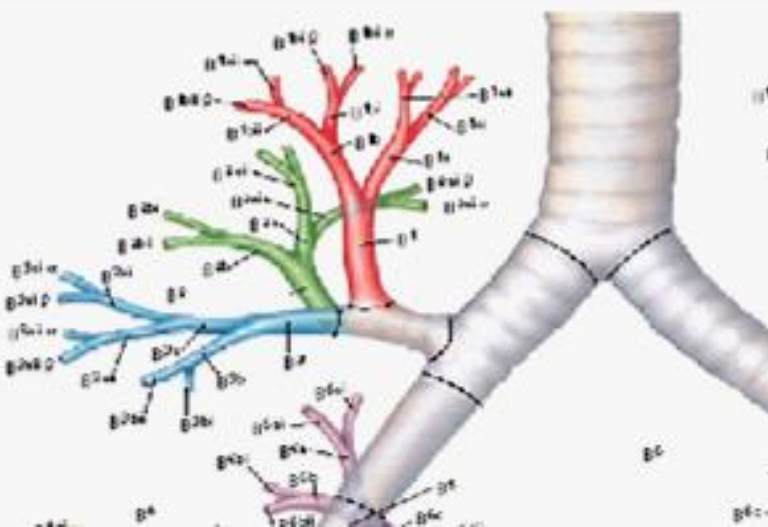
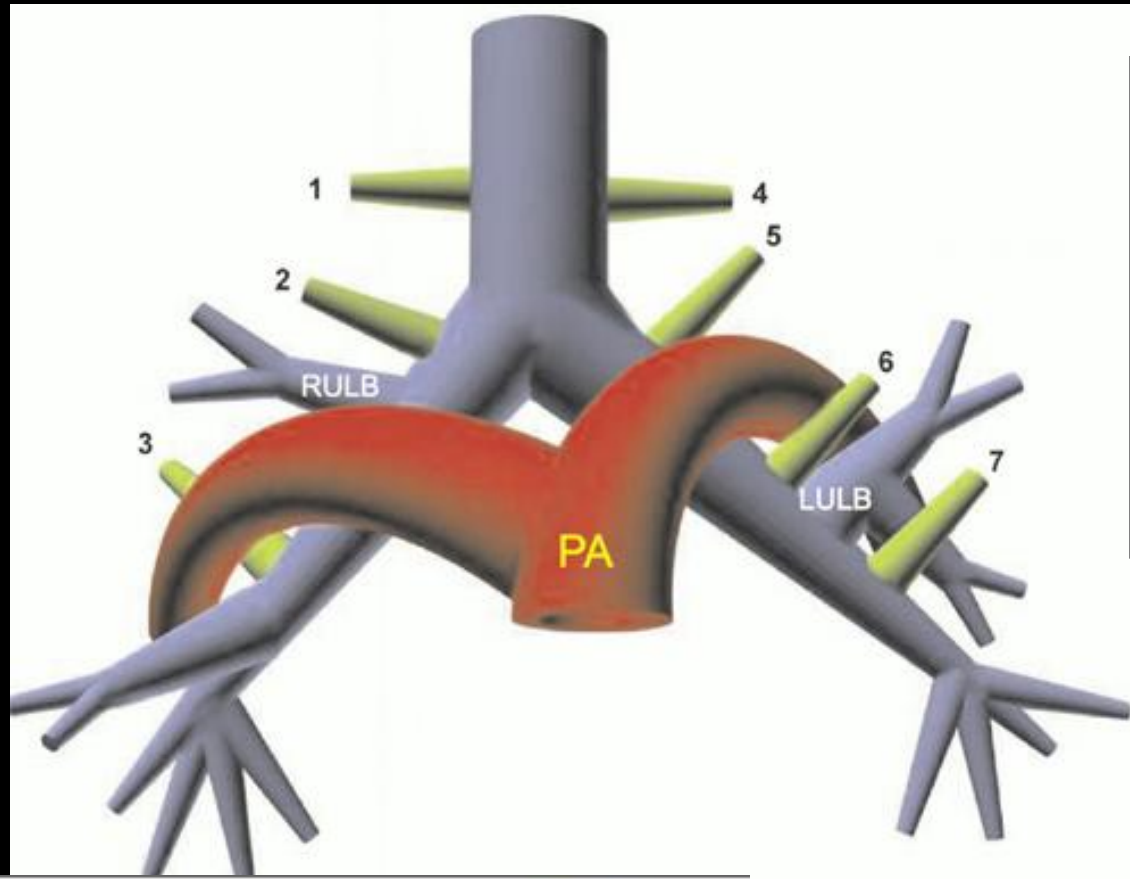


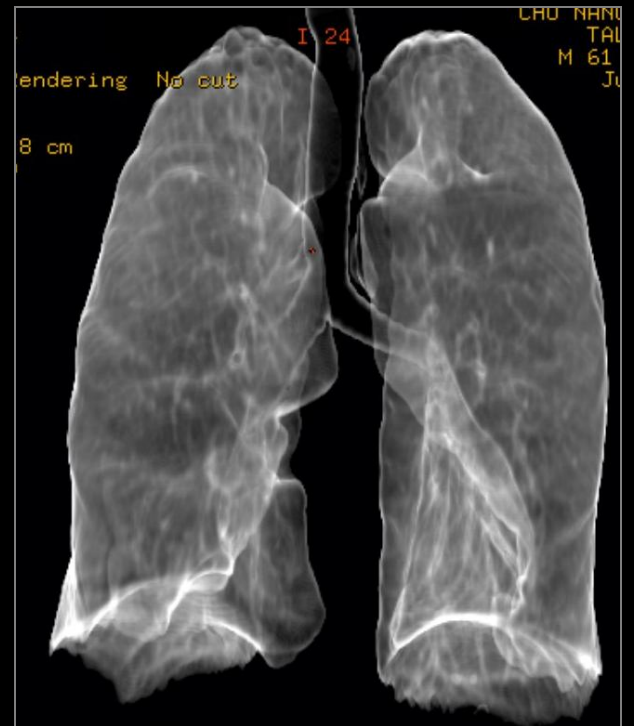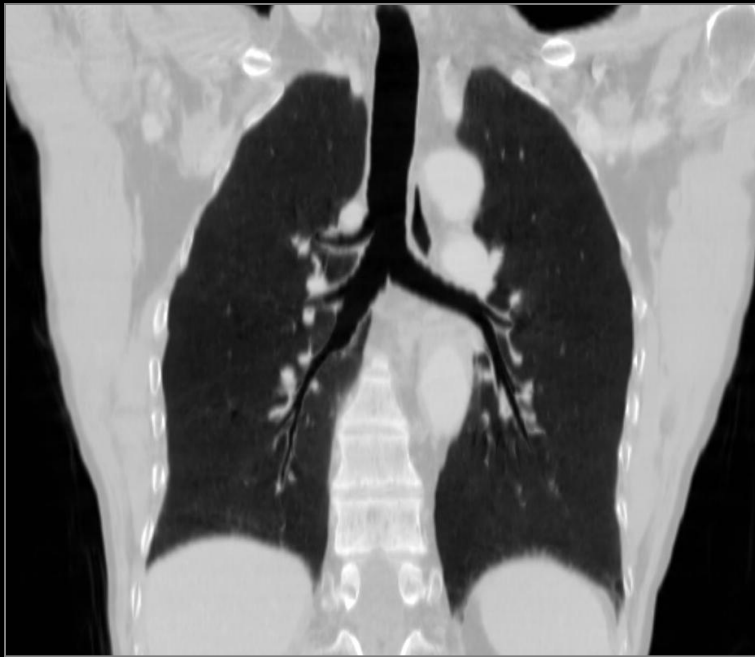
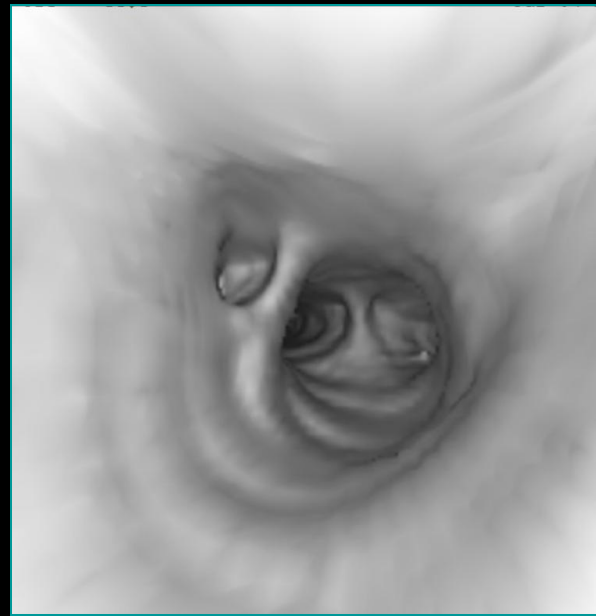
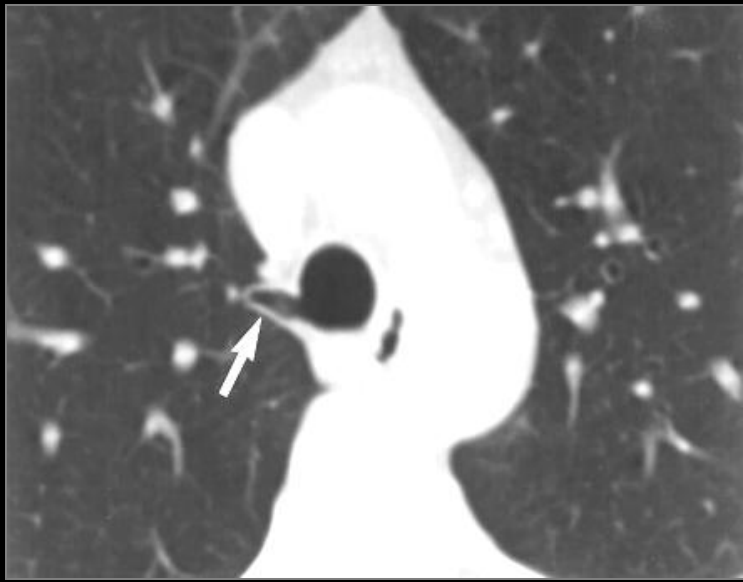
## Bronche ectopique

Les plus fréquentes 2%

Origine déplacée

drainage territoire normal  
anatomiquement

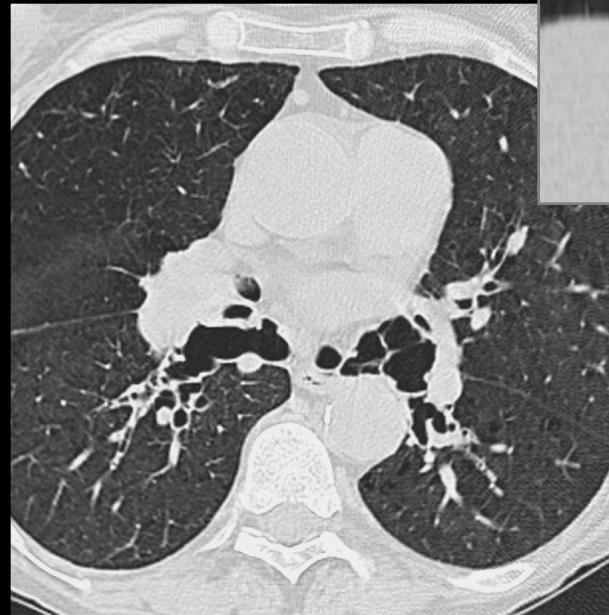
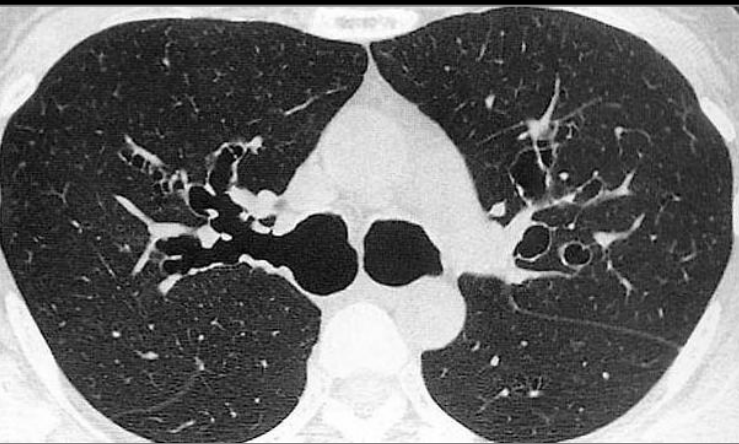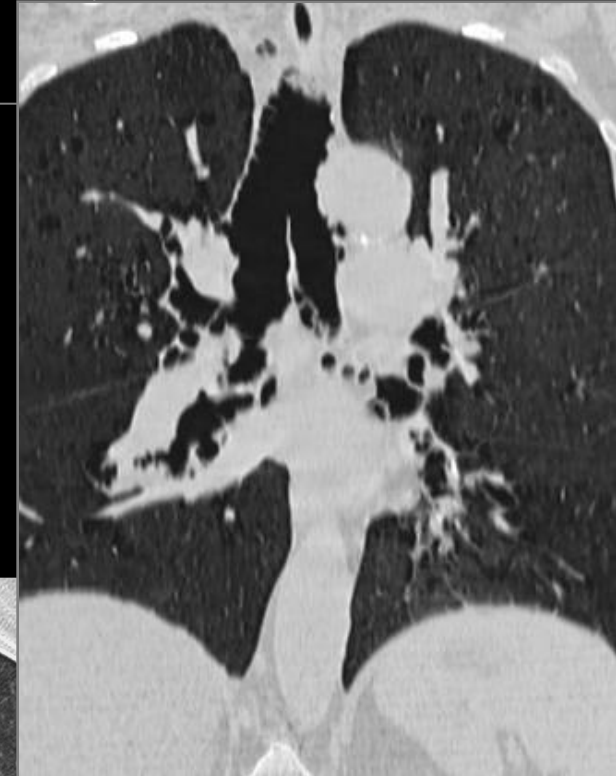
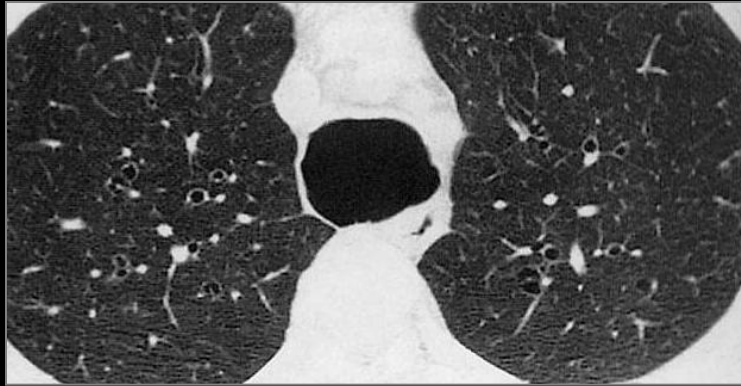




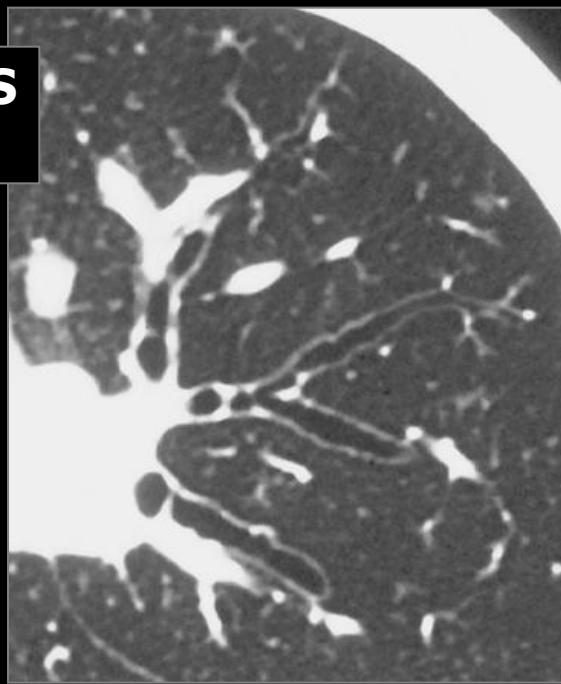
# Trachéobronchomégalie (maladie de Mounier-Kuhn)

Maladie des tissus musc. et élastiques

Maladie intrinsèque VA ou associée à maladie Ehler Danlos



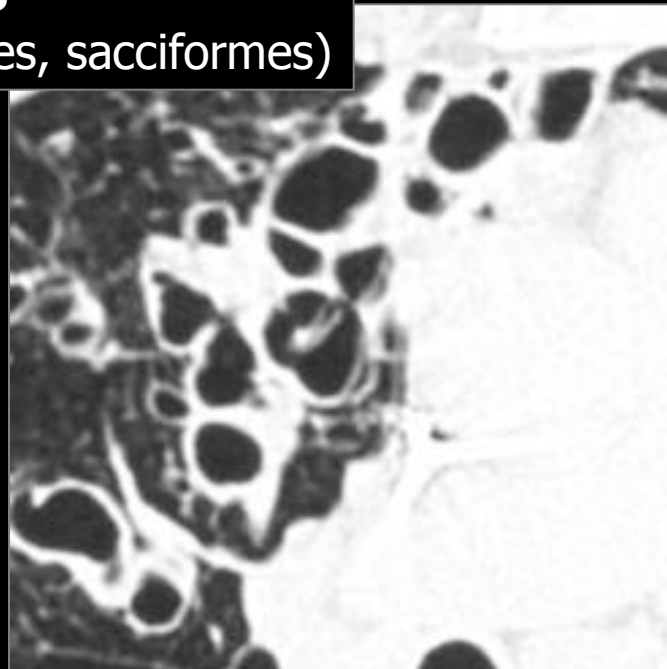
**CYLINDRIQUES**  
(= fusiformes)



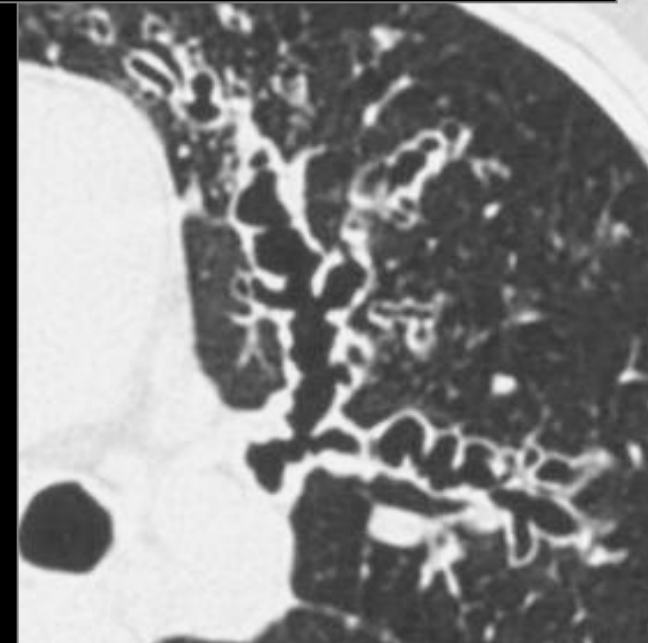
**Bronchiectasies**  
**Classification de Reid**  
**(1950)**

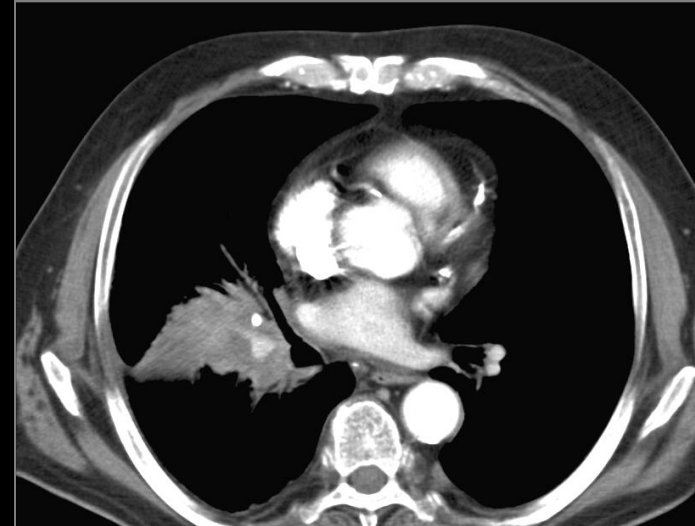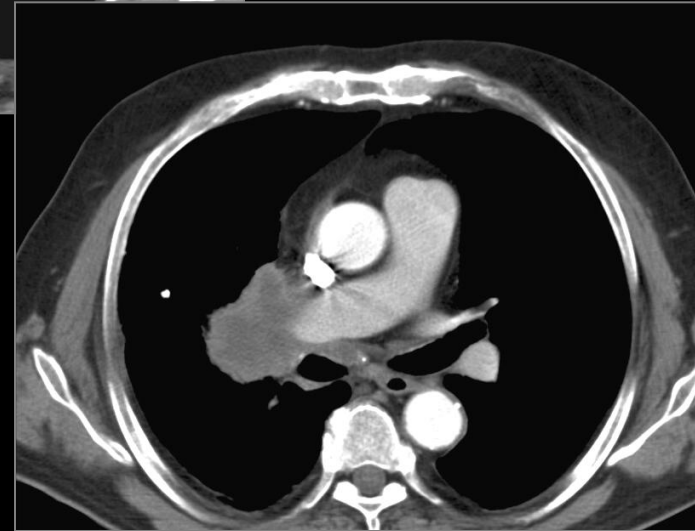
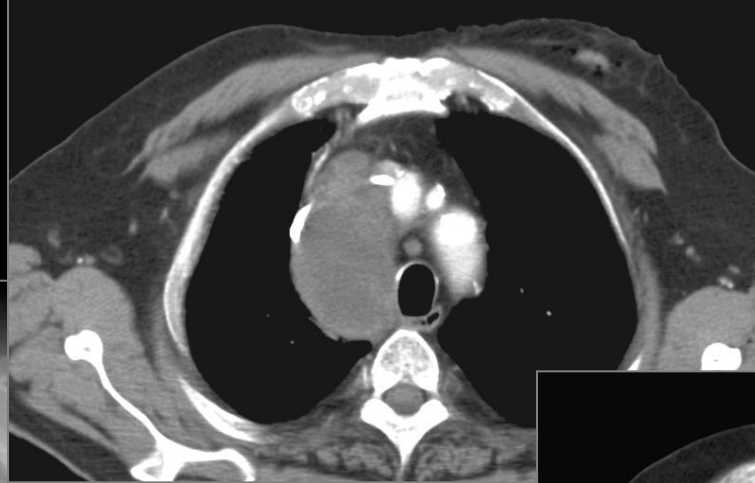
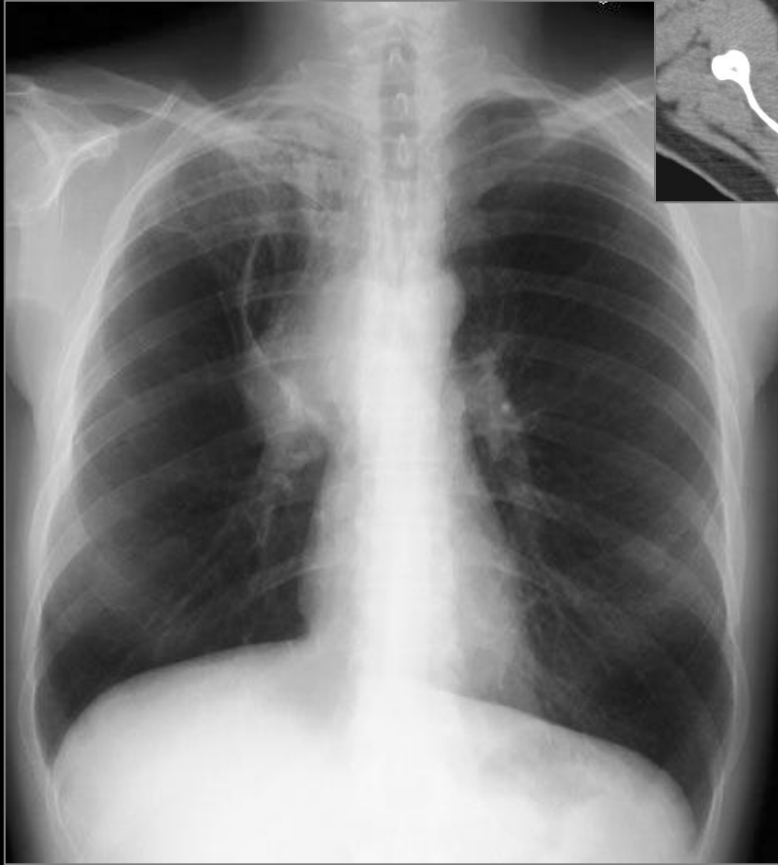


**KYSTIQUES**  
(= ampullaires, sacciformes)

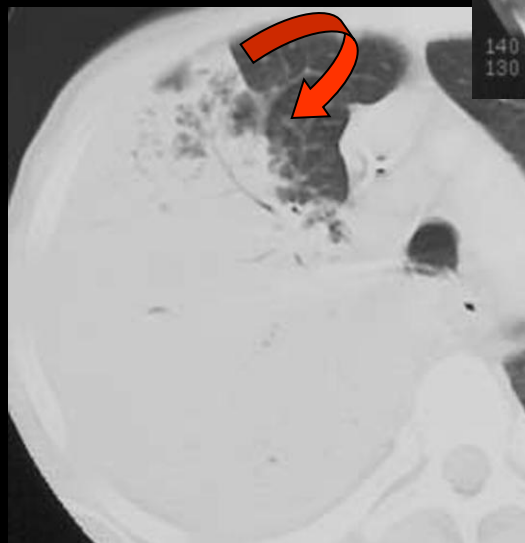
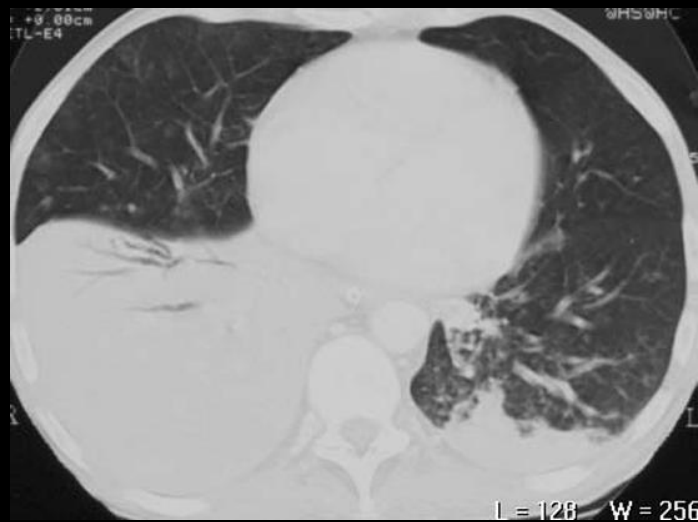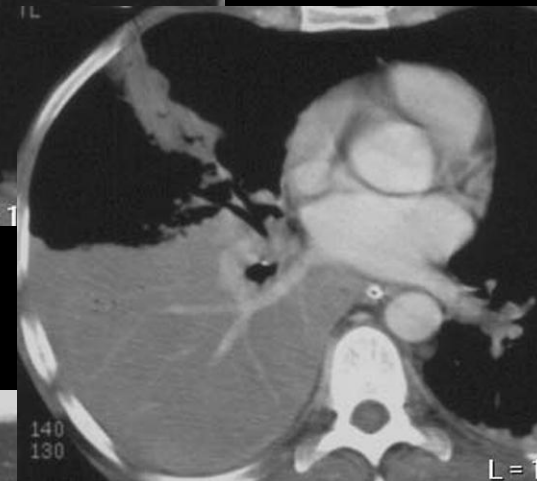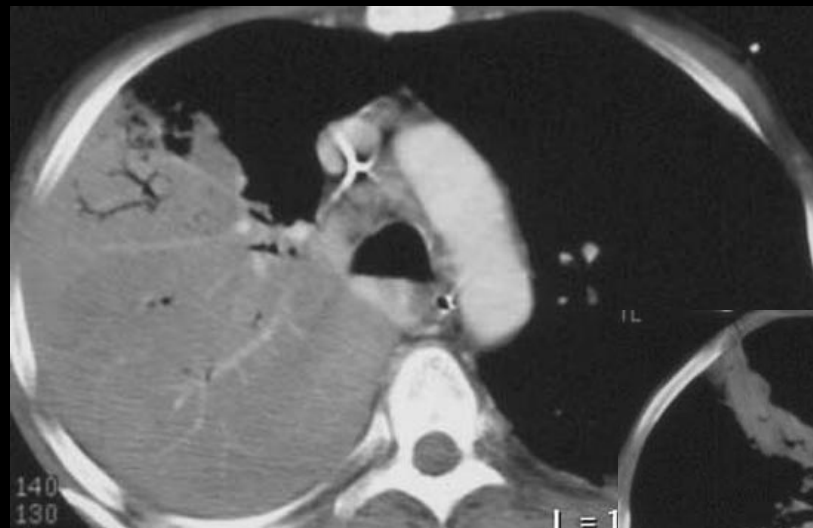


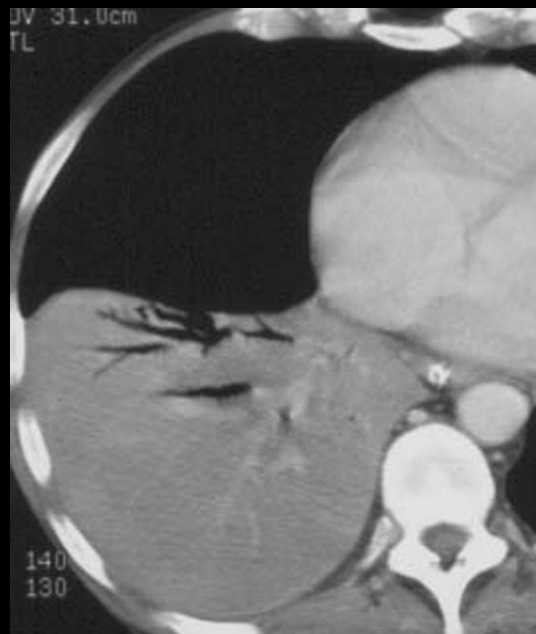**VARIQUEUSES**  
(= moniliformes, en grappe)

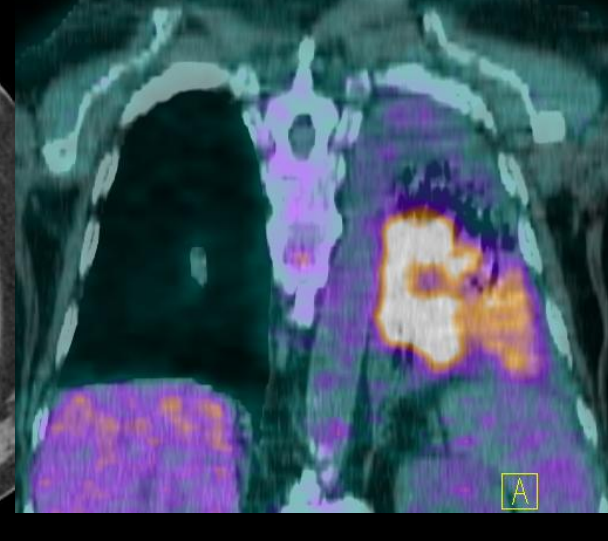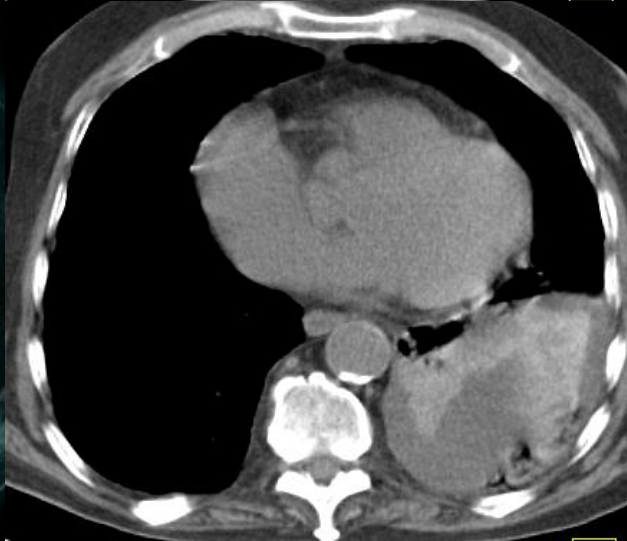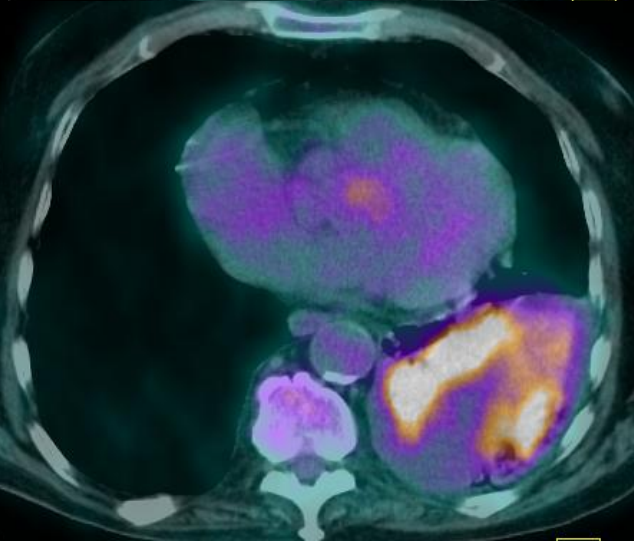
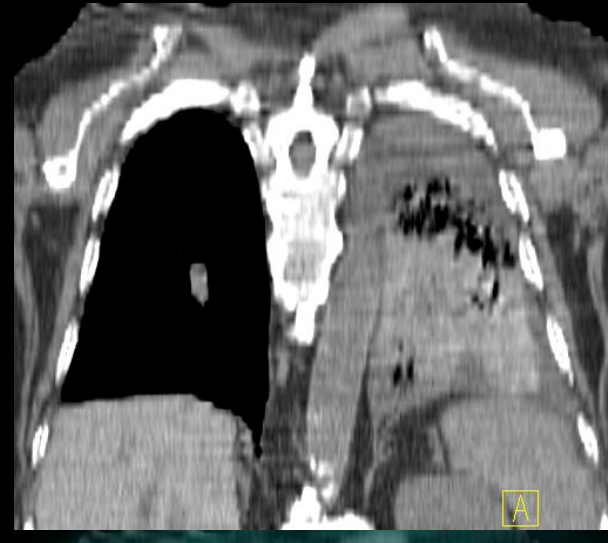
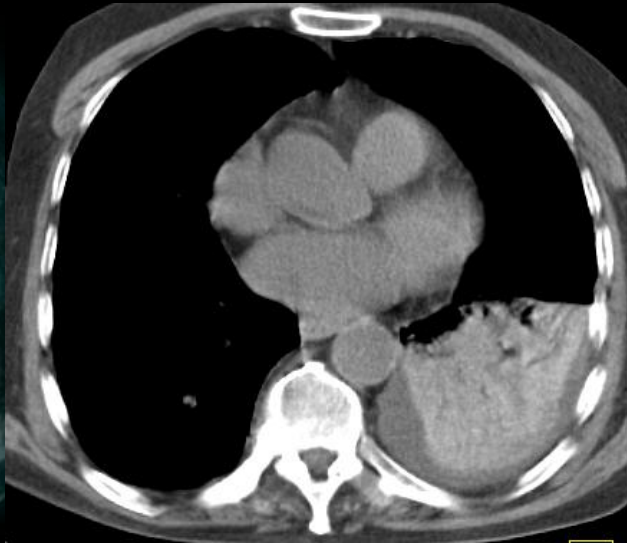
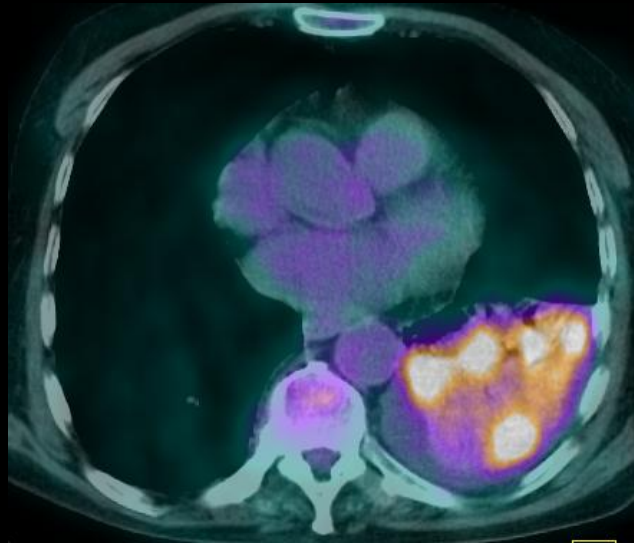




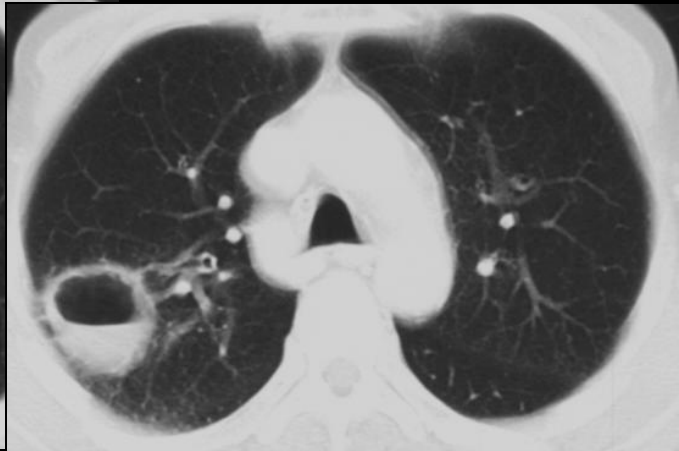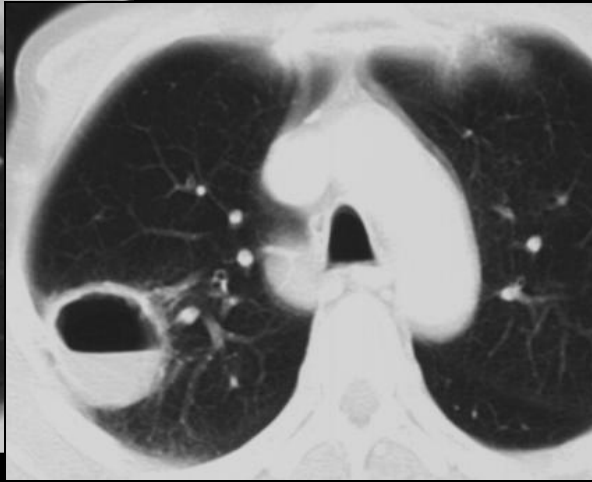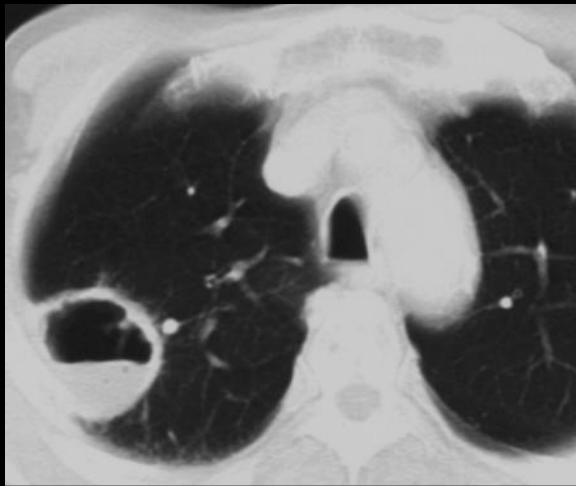**Scissure azygos et carcinome à petites cellules**



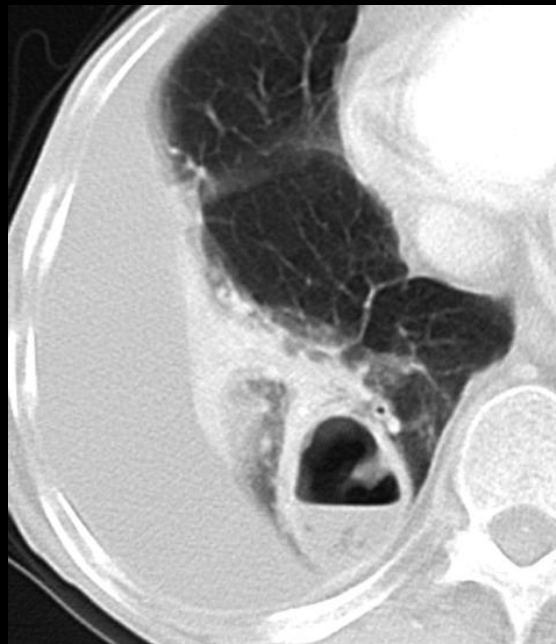
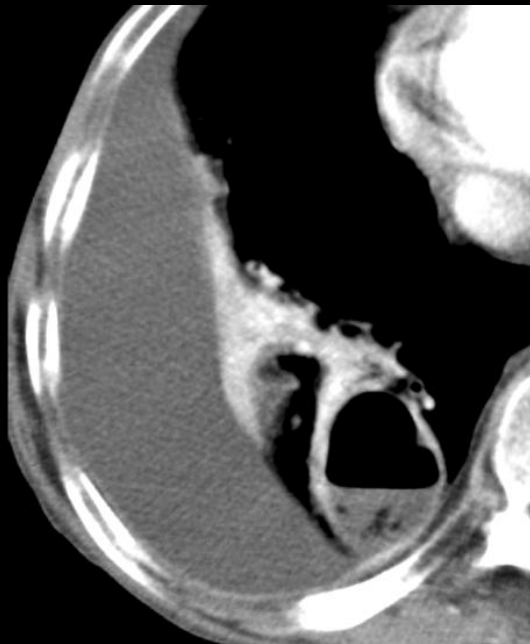**PFLA du lobe inférieur ( hépatisation )**



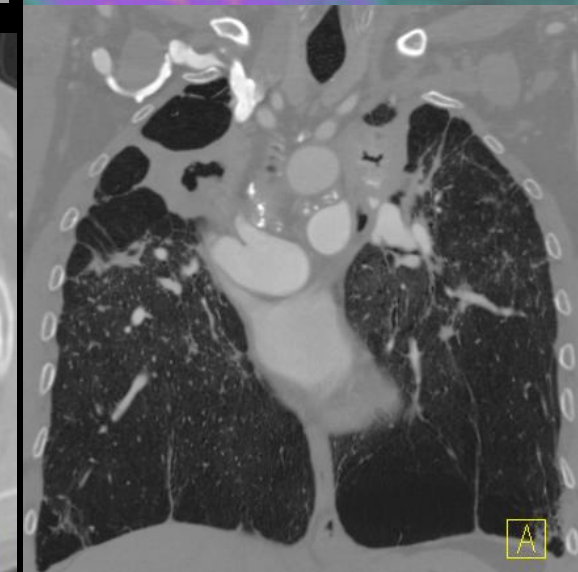
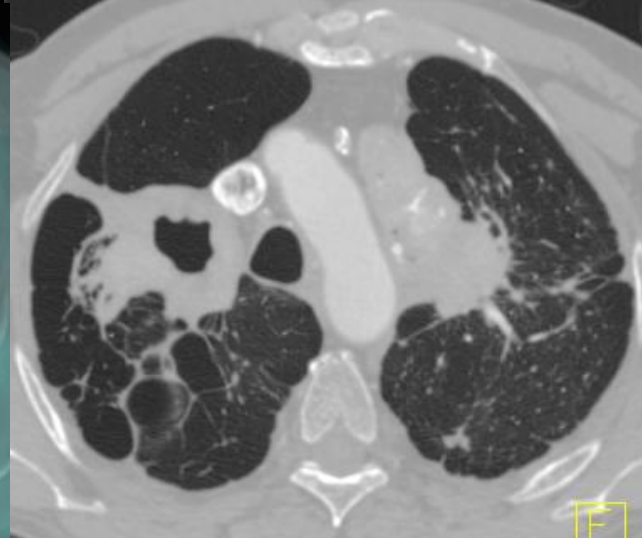
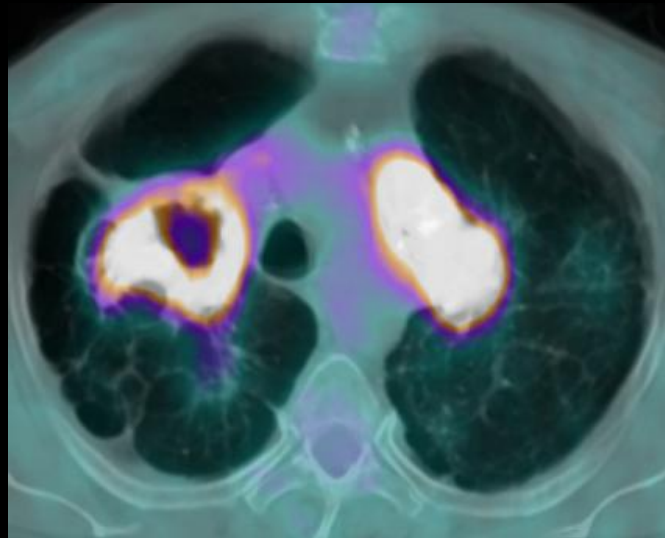
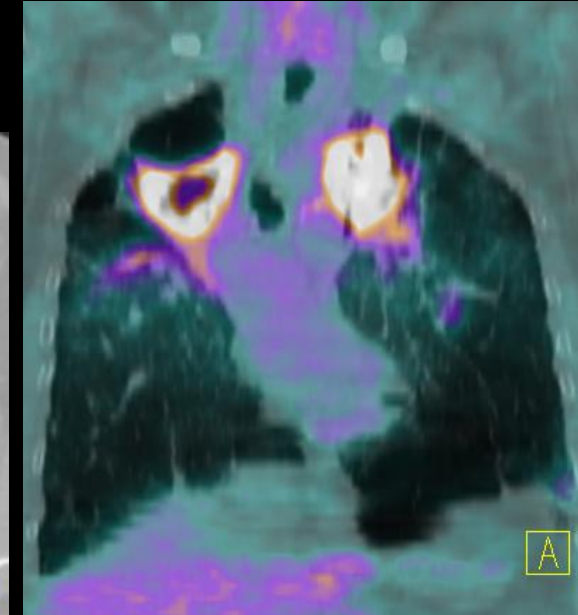
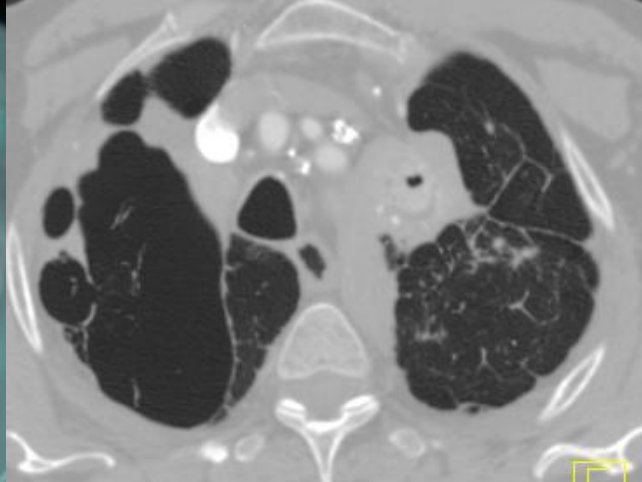
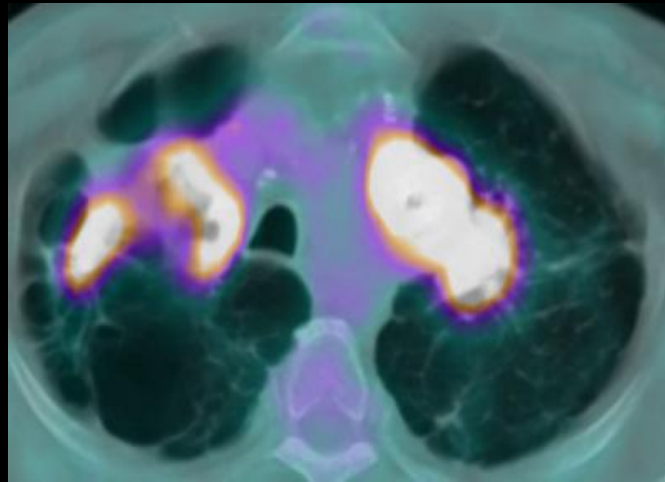
**Pleuro-pneumopathie du lobe inférieur**

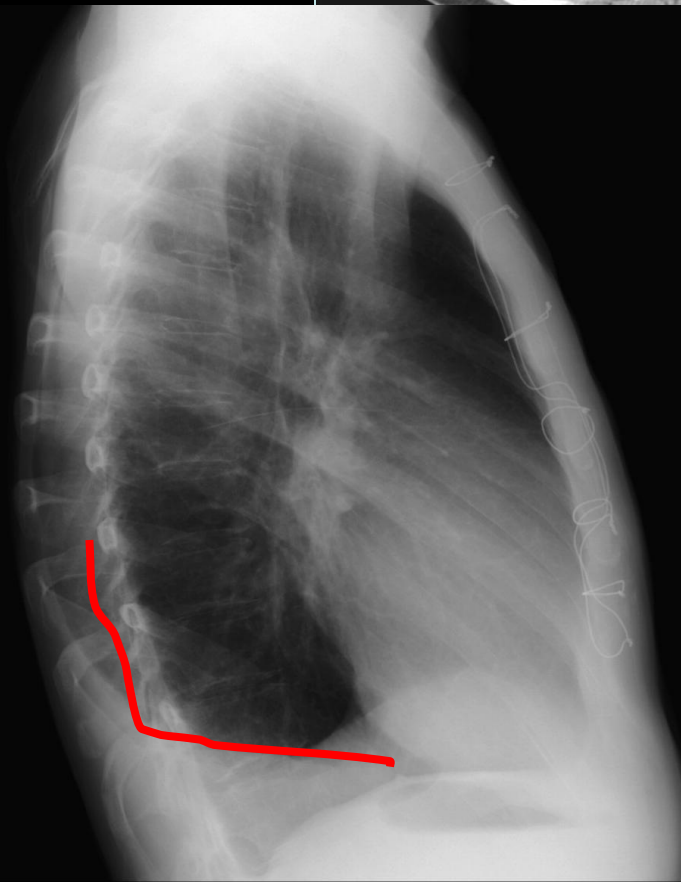
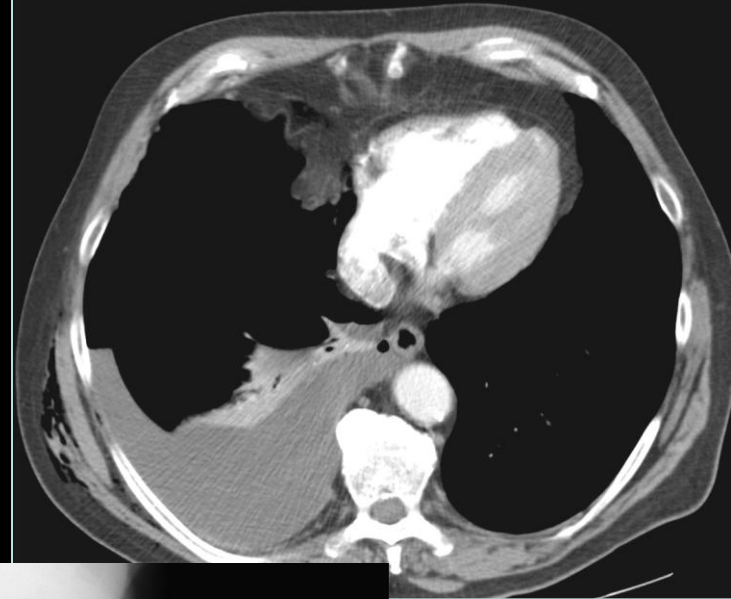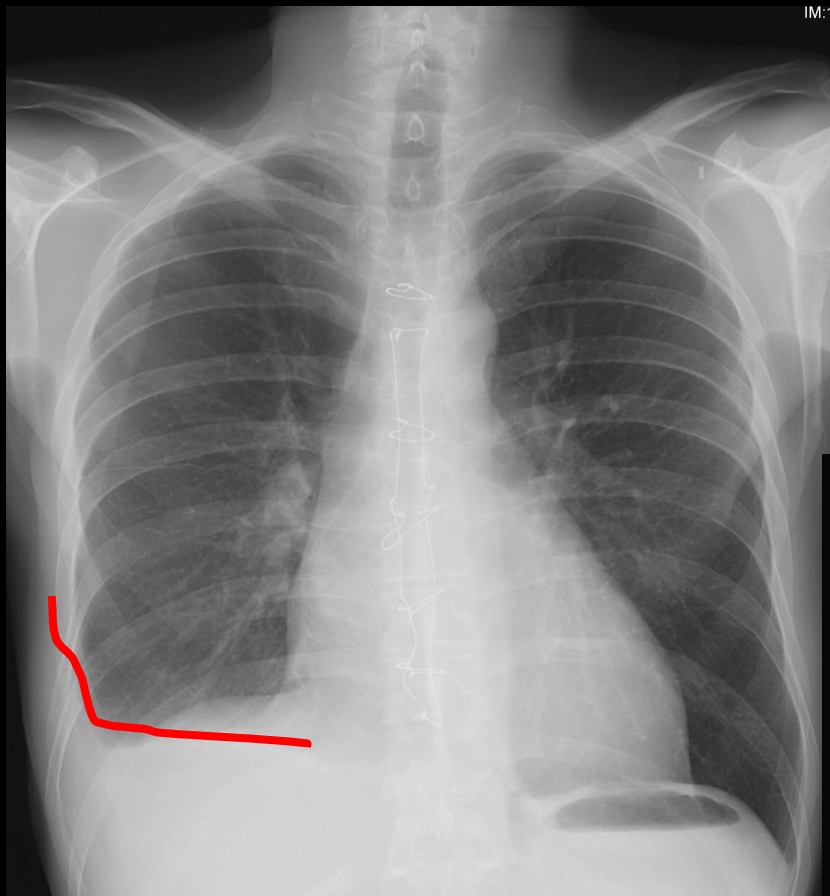


**abcès du poumon**

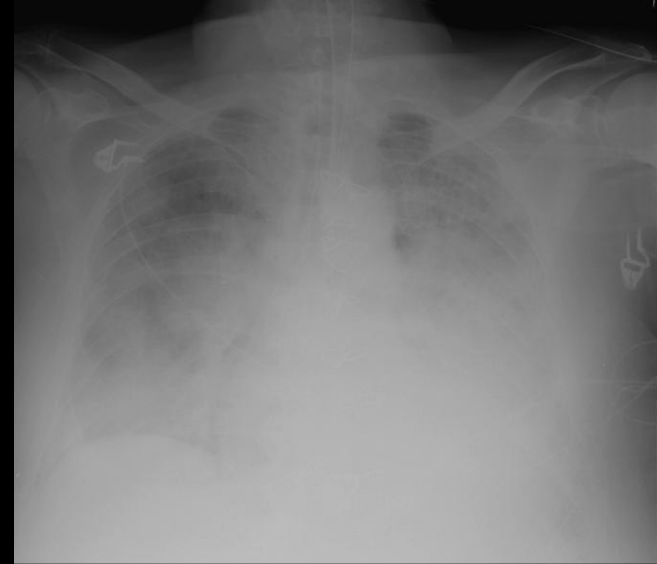
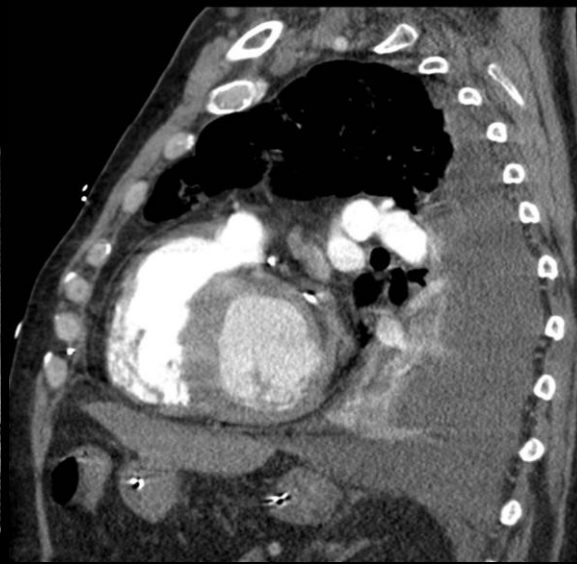
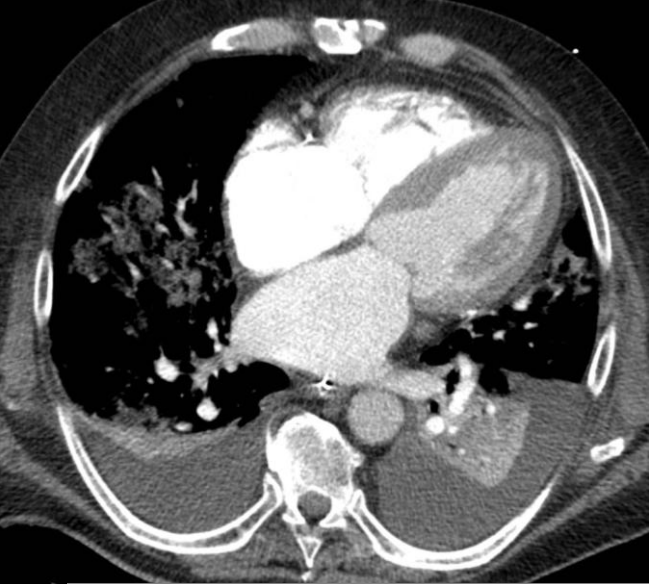


# Aspergillome

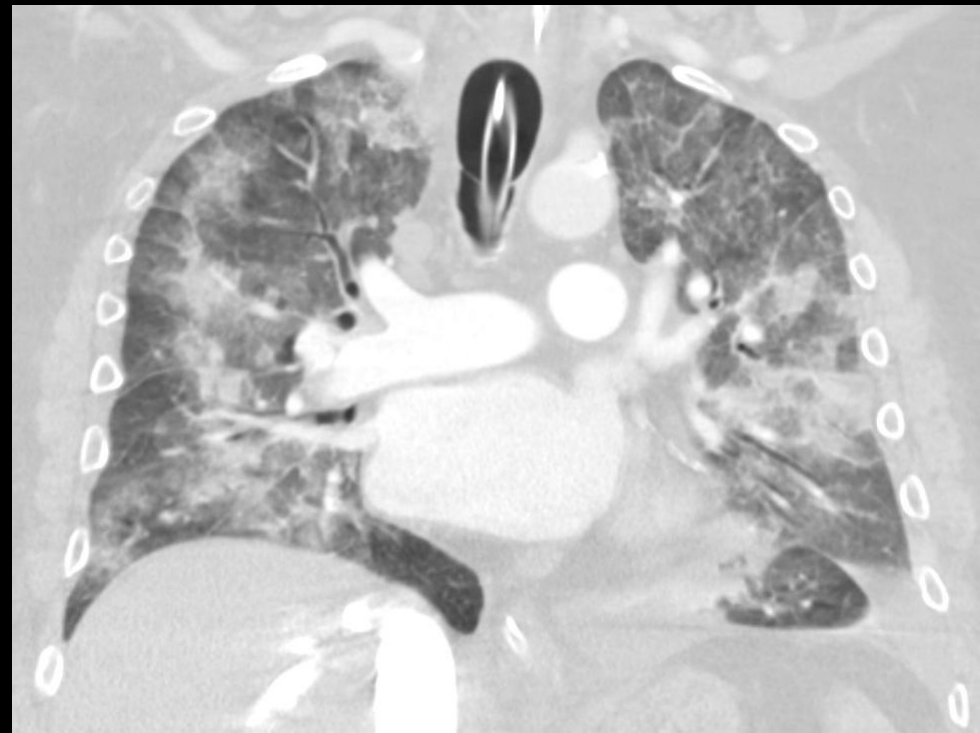
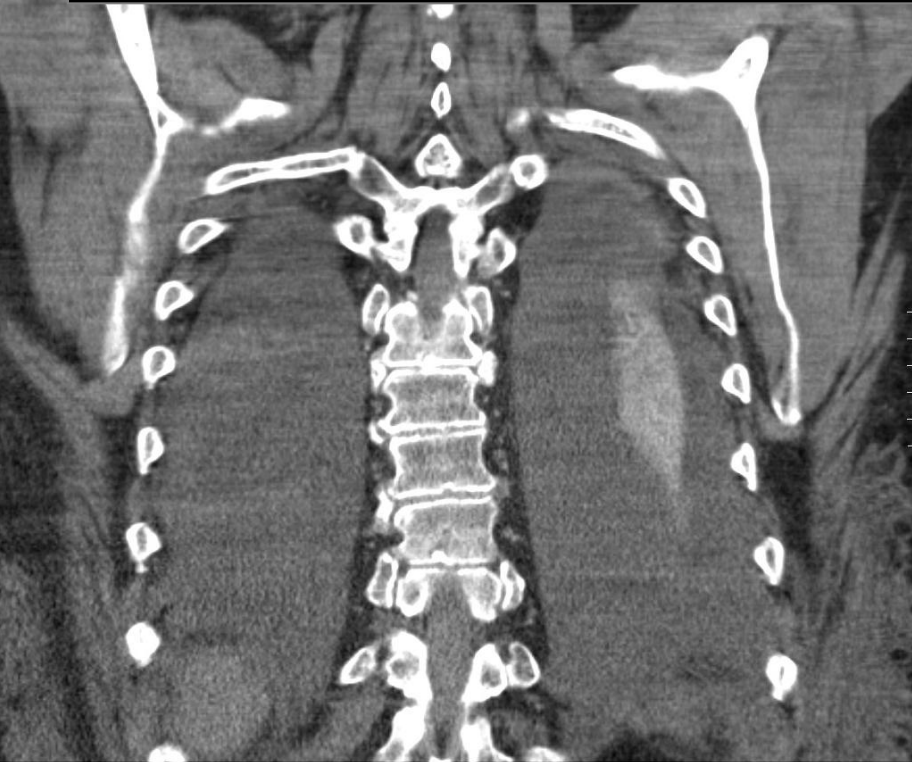


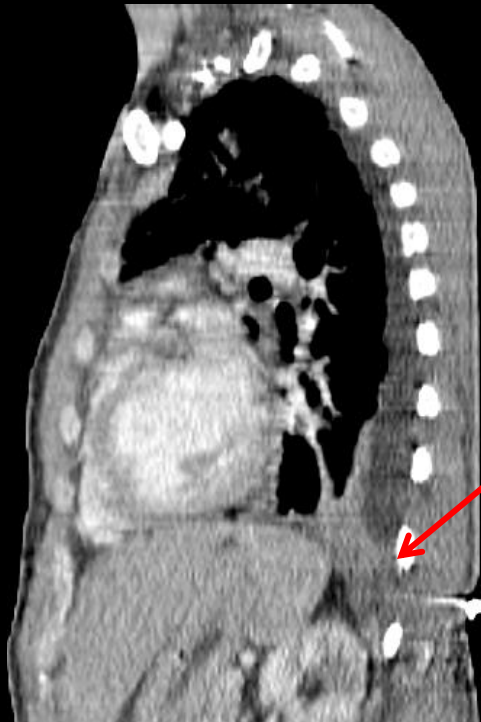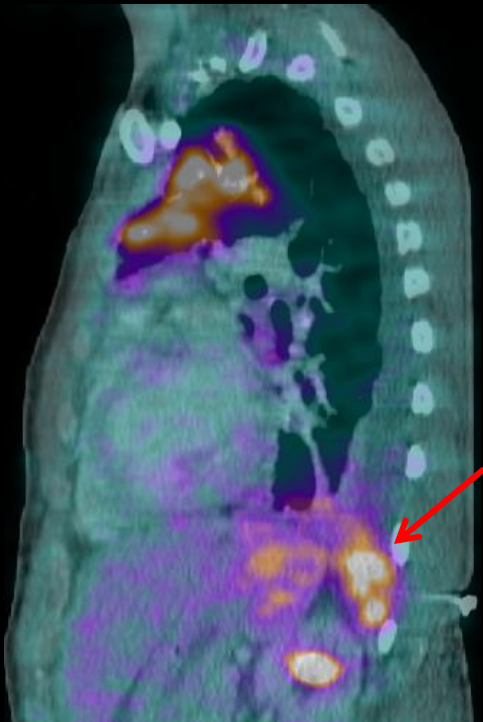
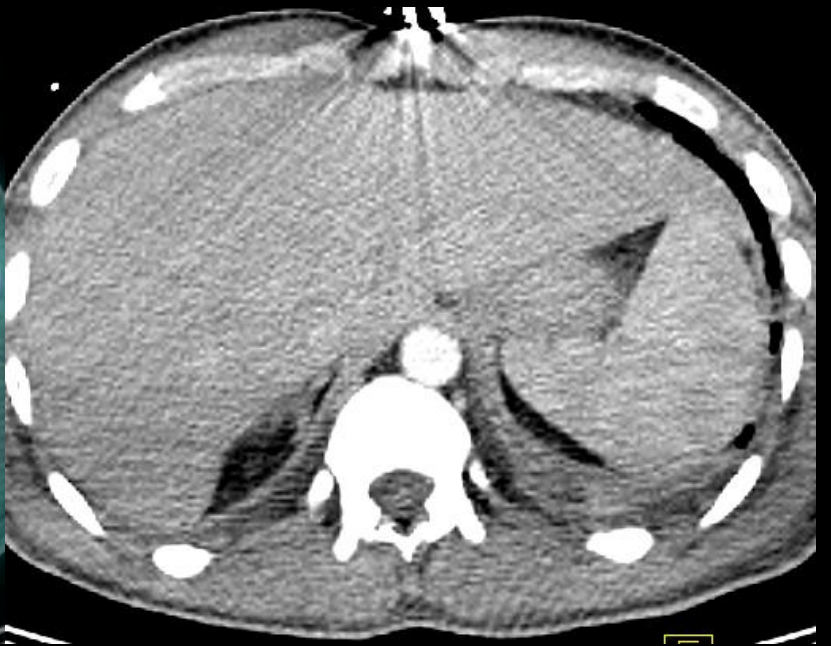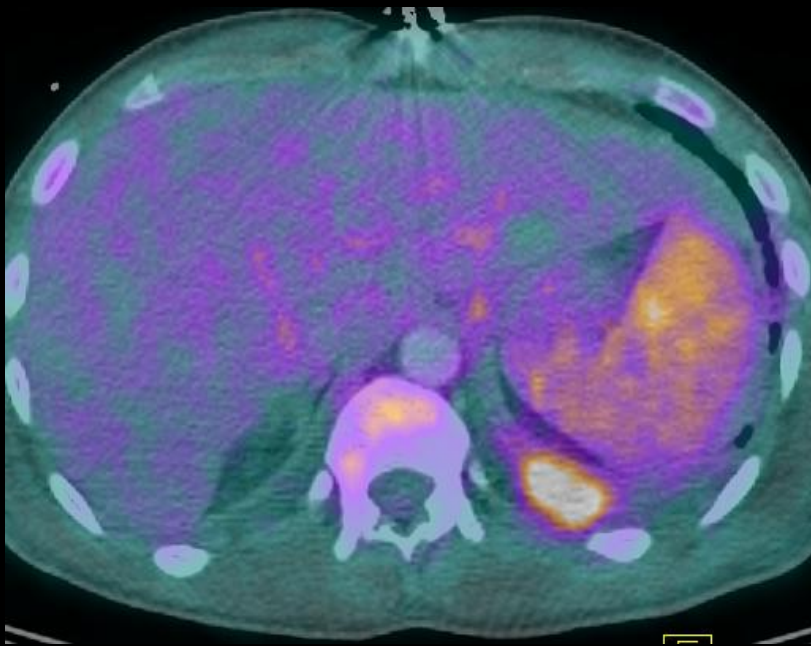


**Épanchement pleural  
droit**

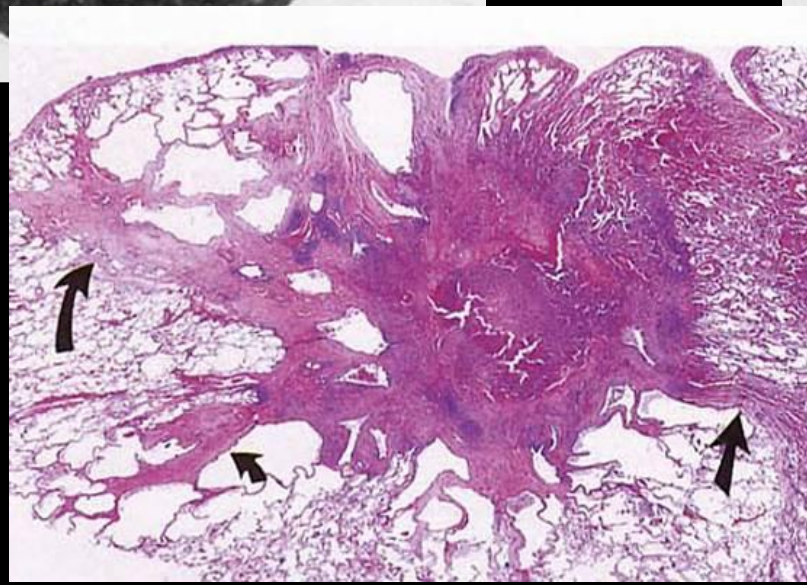
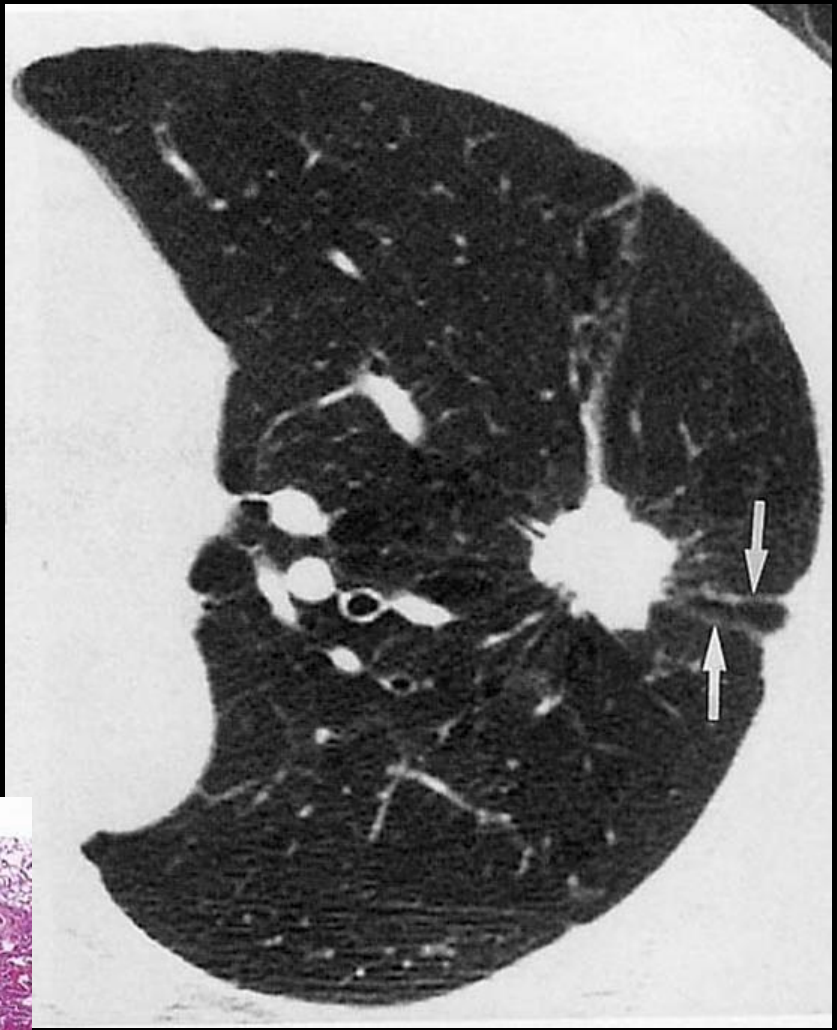
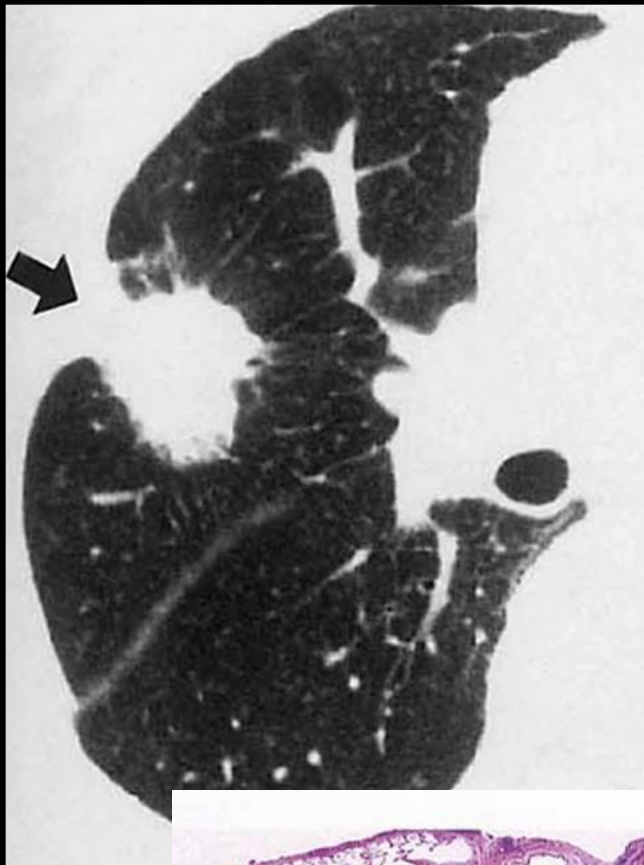

**Pleurésie bilatérale décompensation cardiaque**



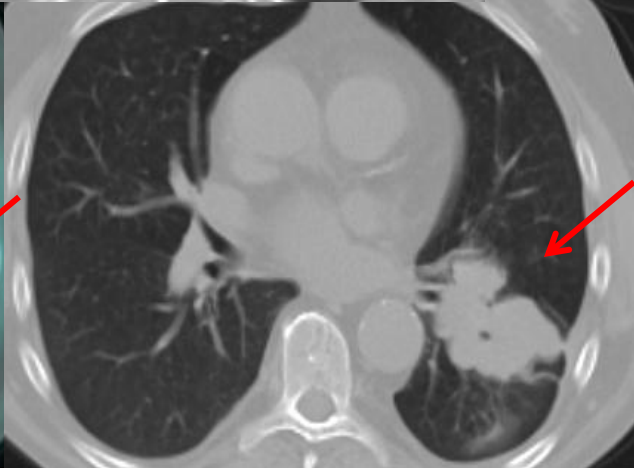
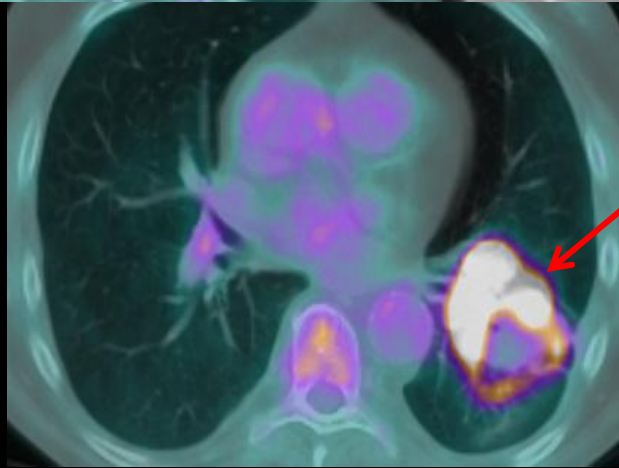
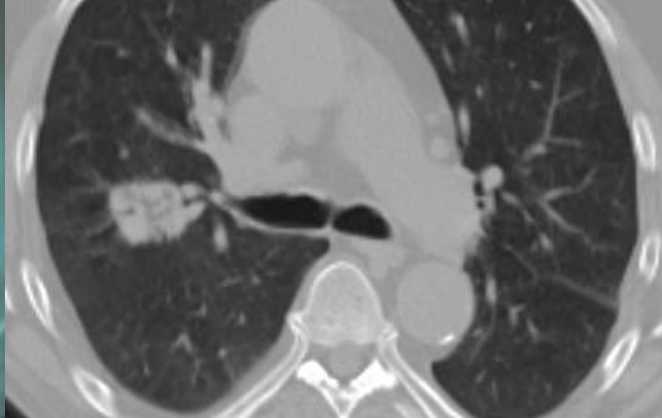
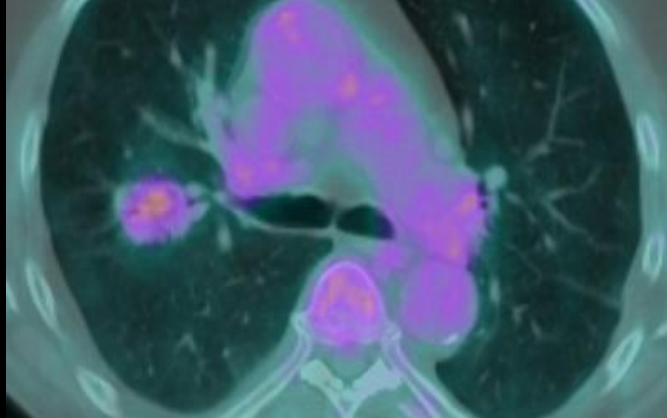
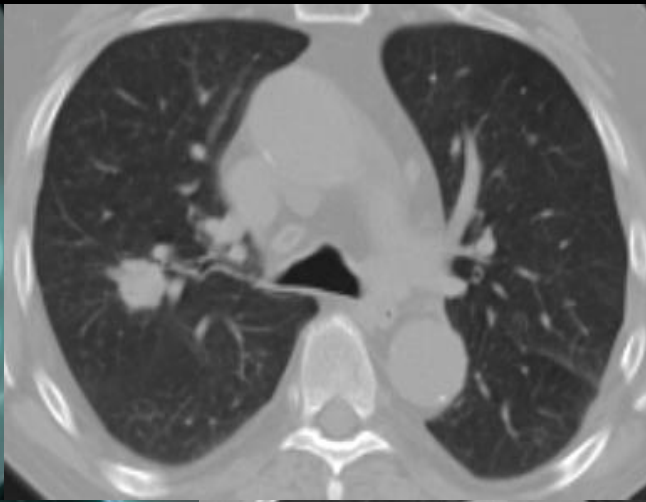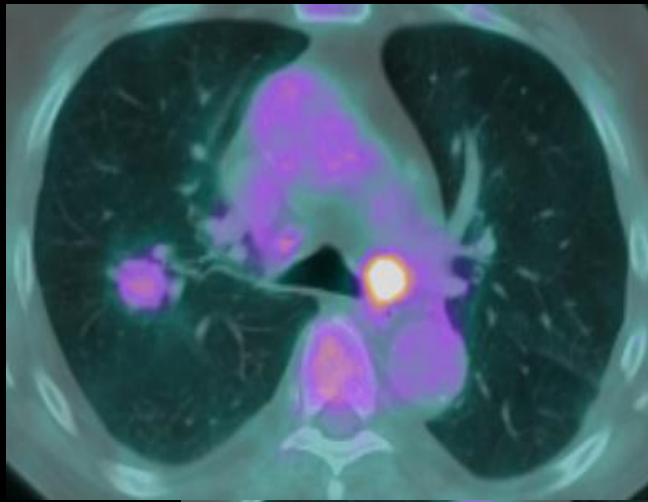


**Pleurésie  
enkystée**



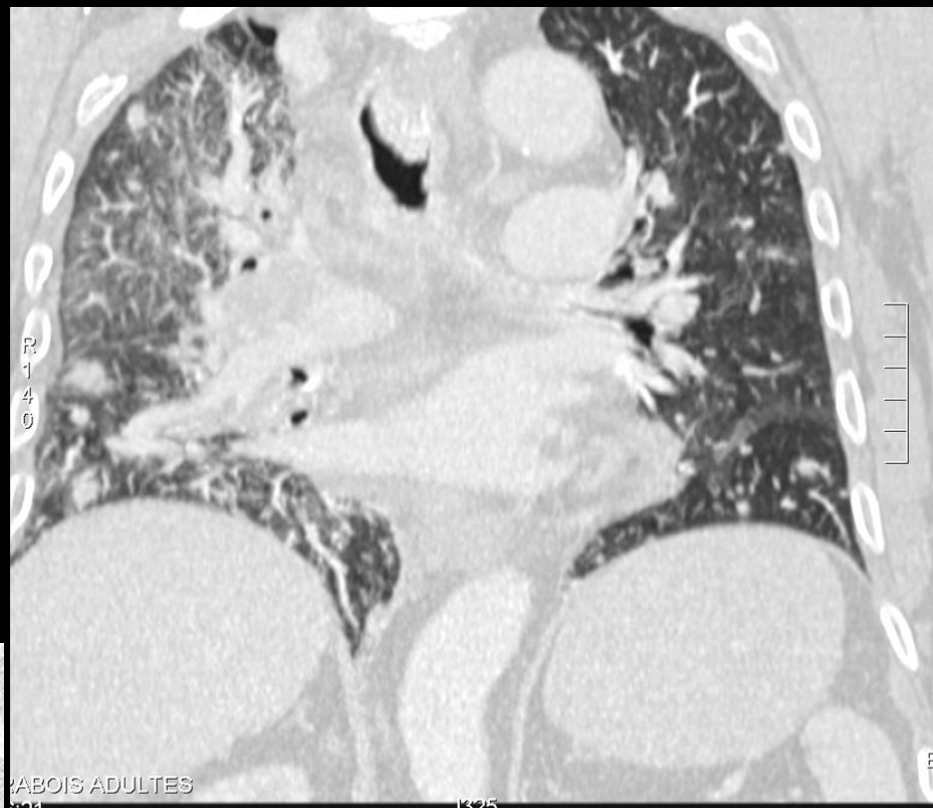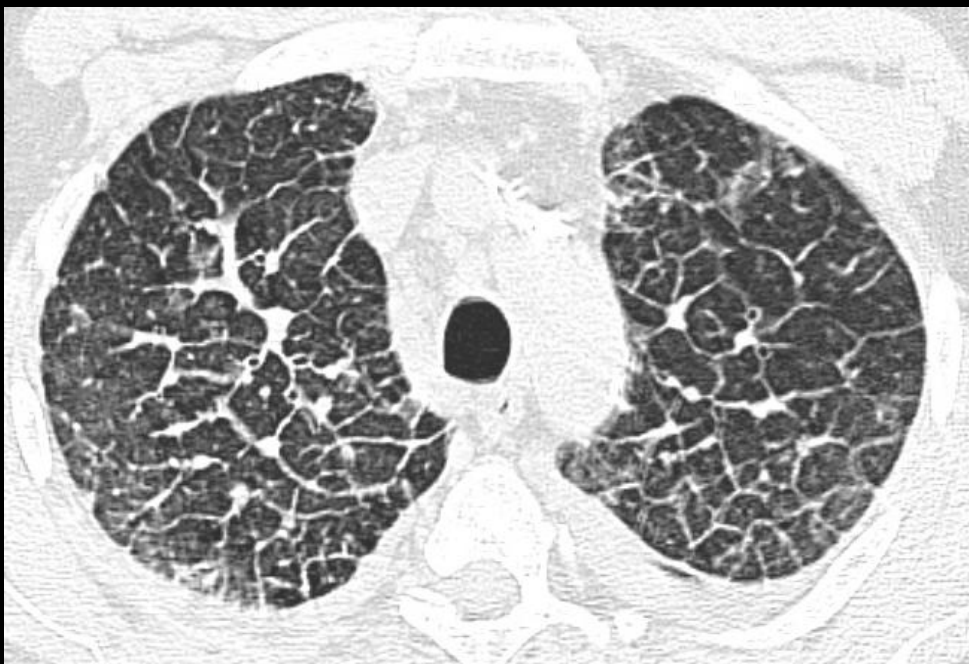
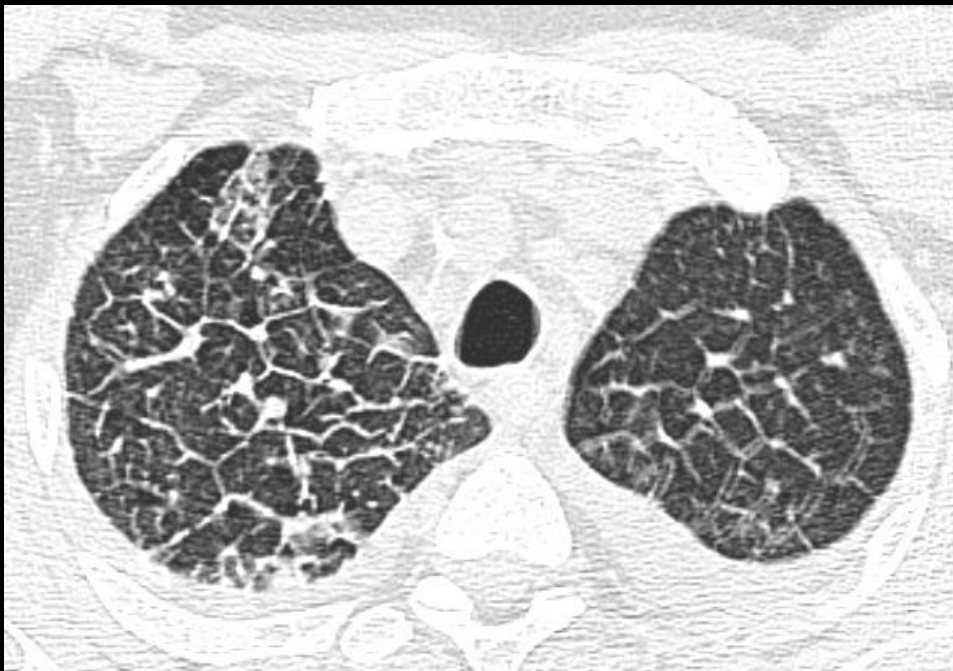
**adénocarcinomes  
infiltration et rétraction de  
la plèvre**

**Carcinome  
épidermoïde  
gauche et lésion  
synchrone à droite**



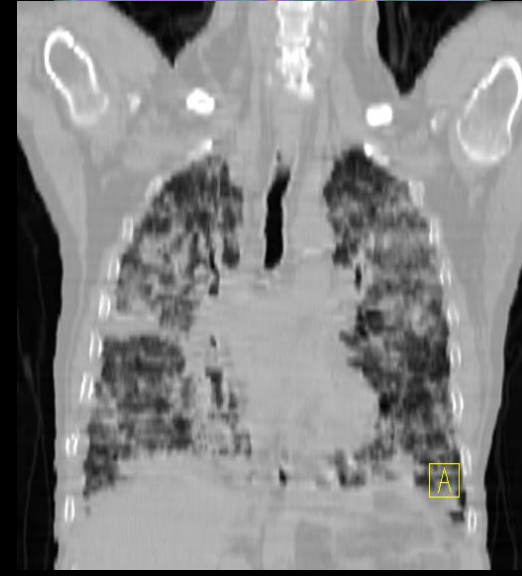
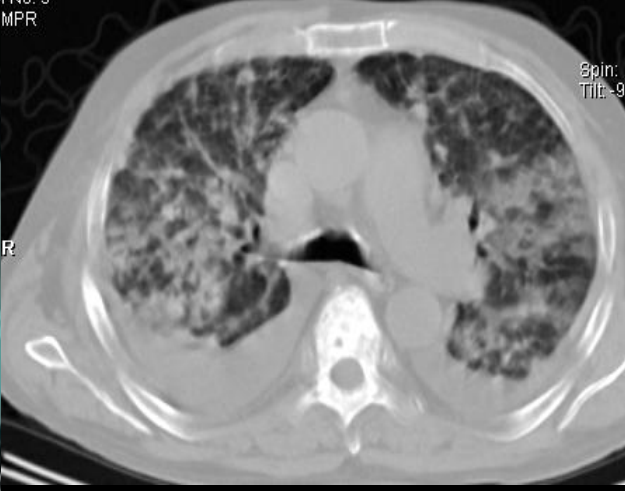
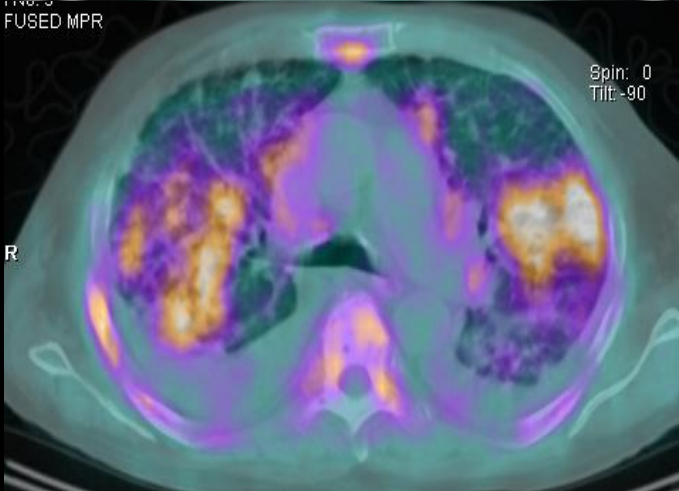
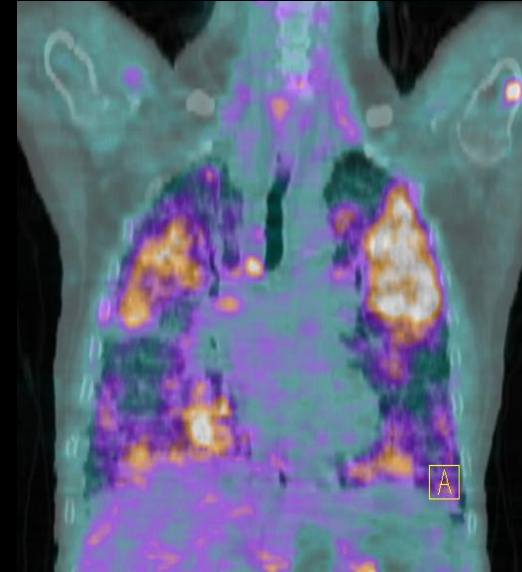
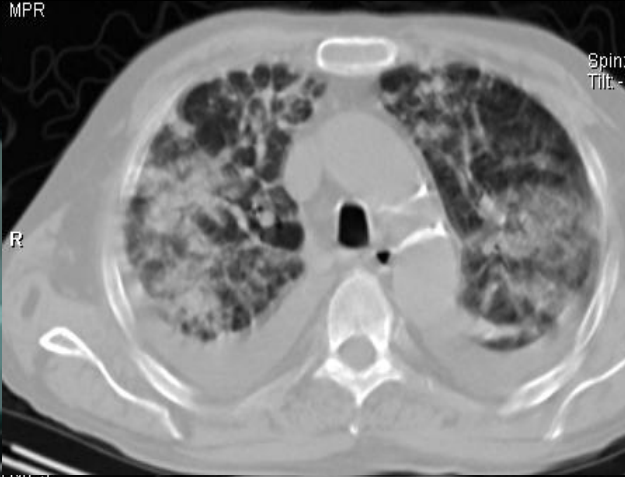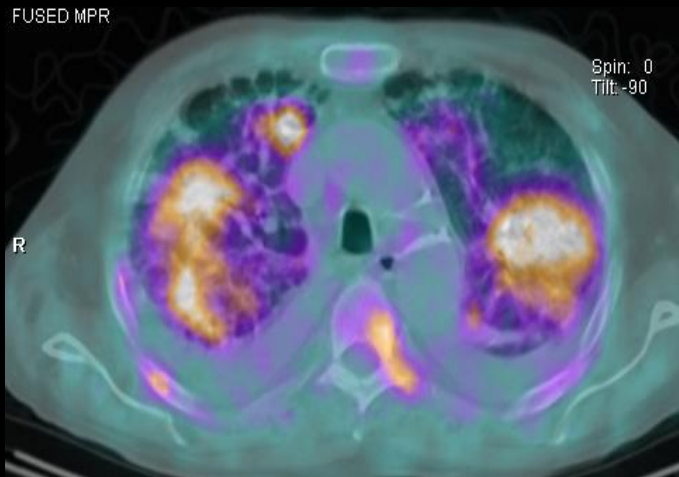


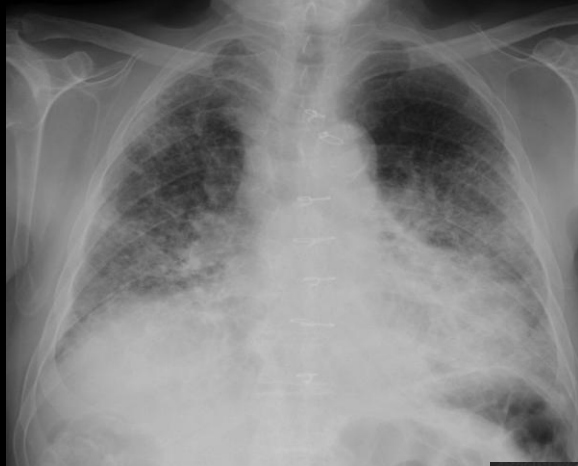**Atteinte parenchymateuse interstitielle...**



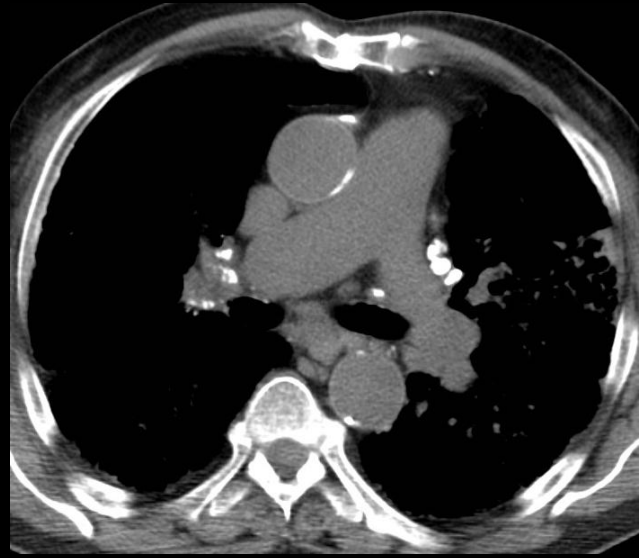
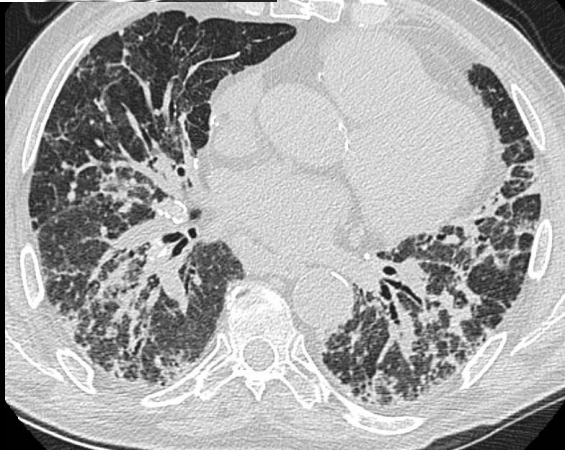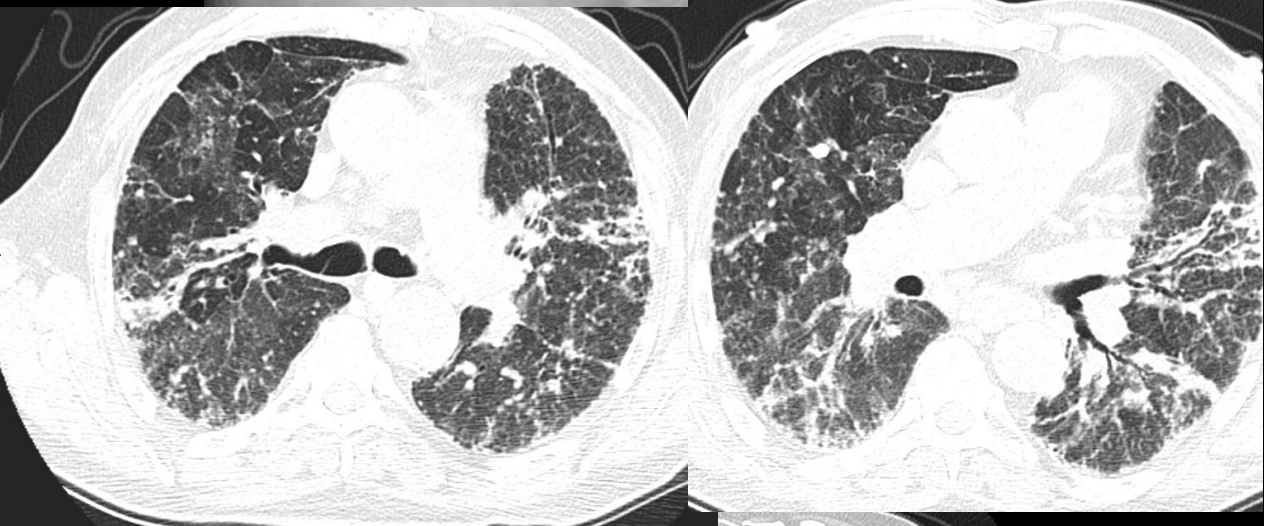
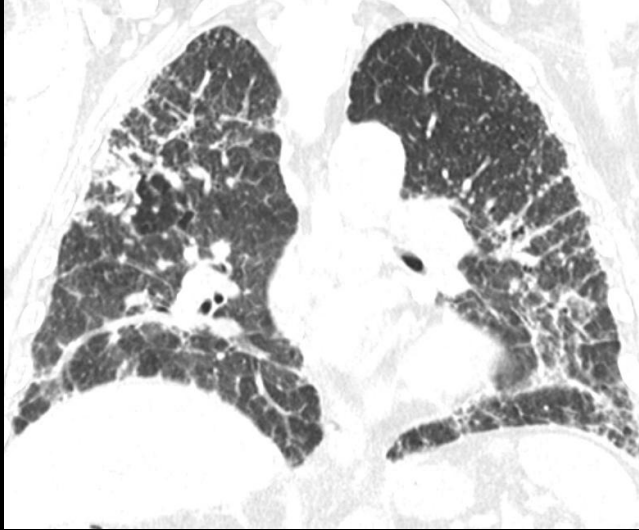
**Épaississements des  
septas et  
micronodules :  
lymphangite**

# Lymphangite

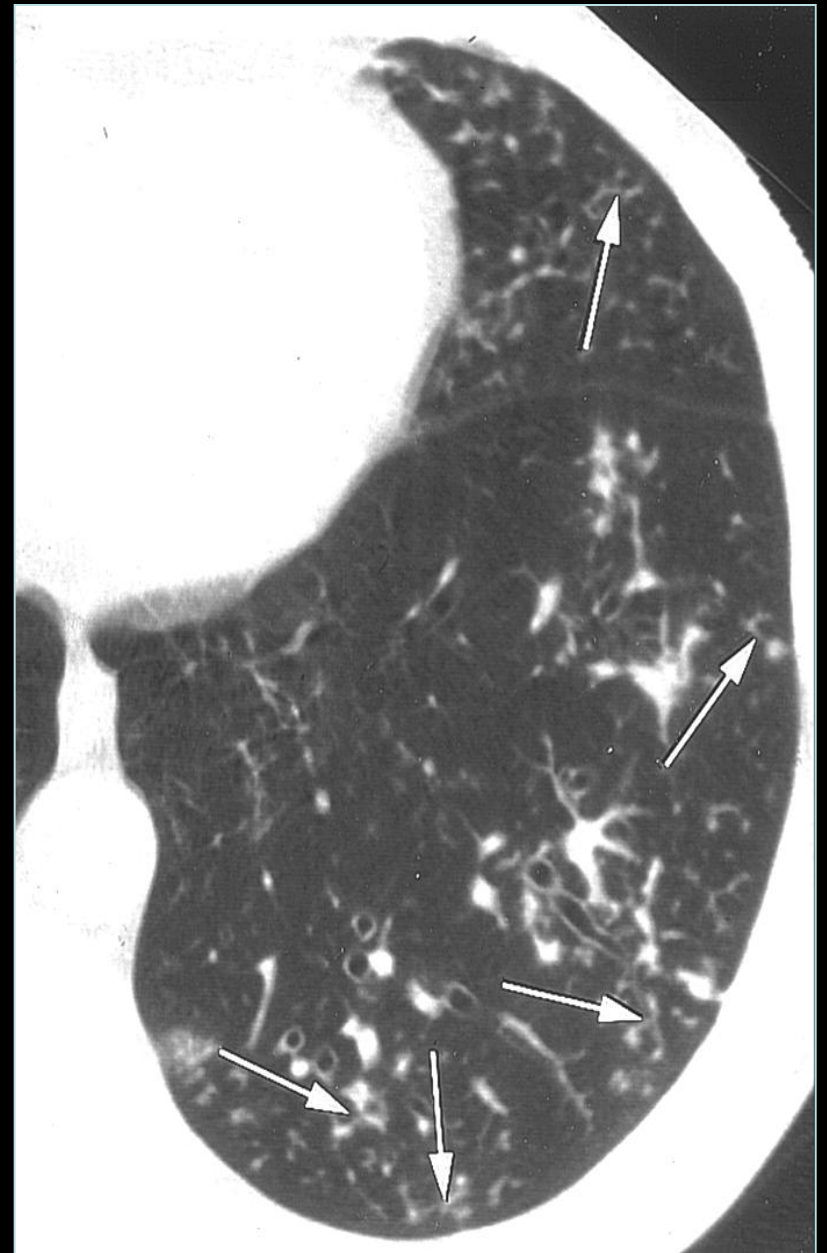
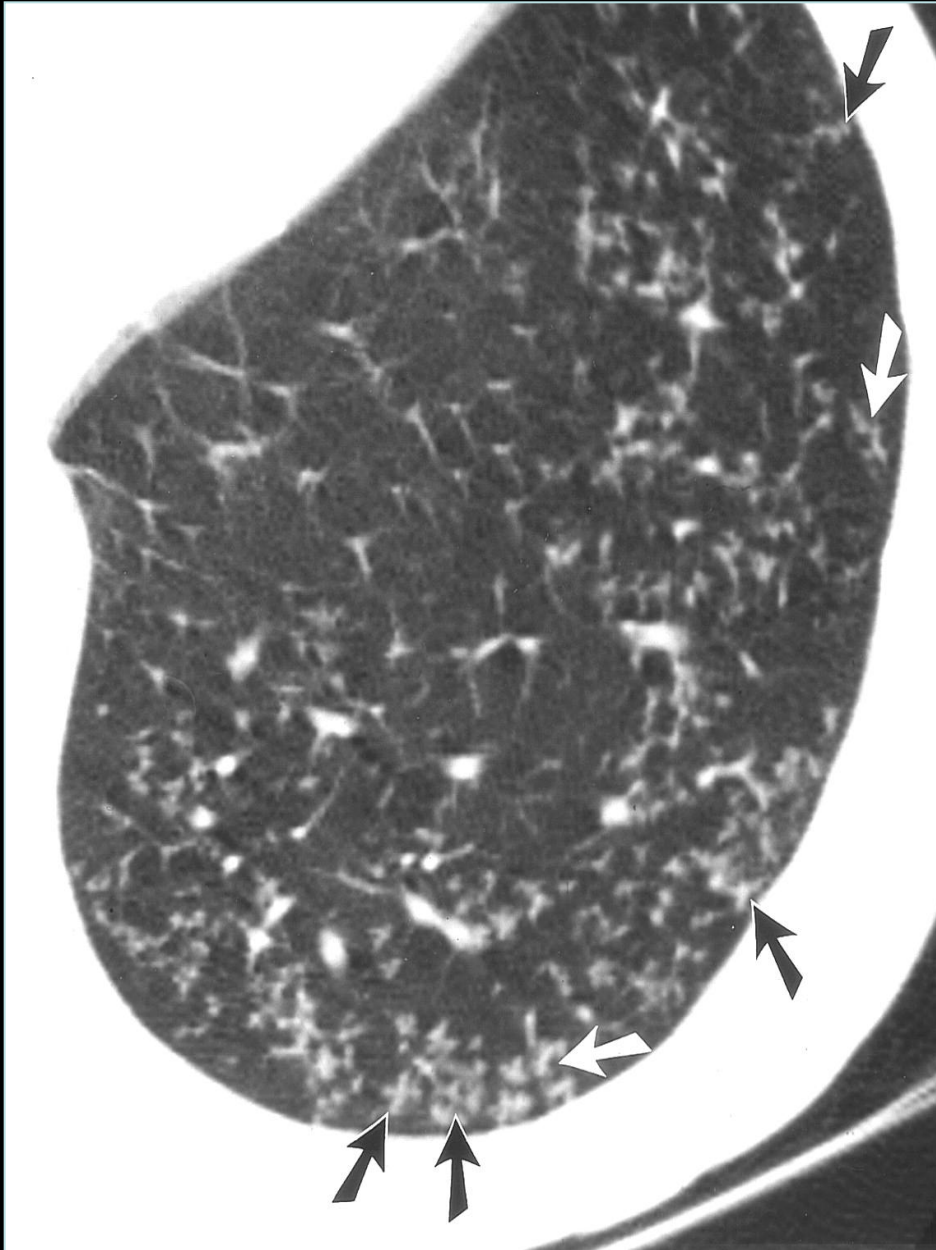




**silicose**

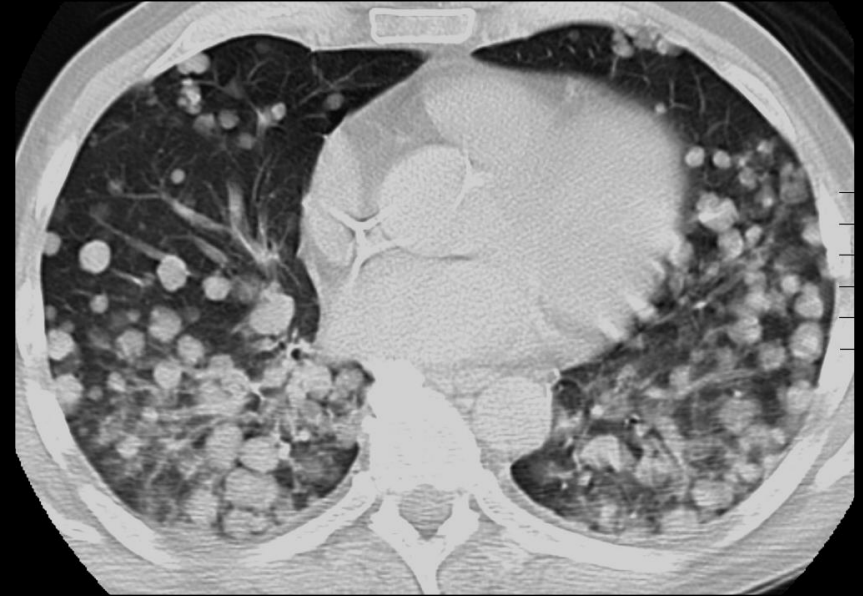
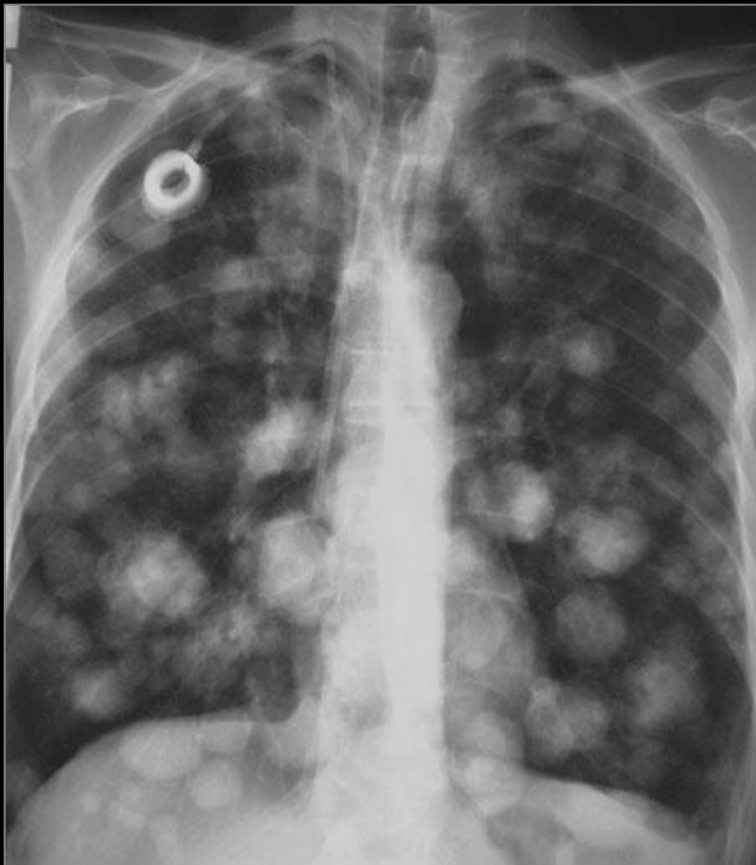

# Bronchiolite bactérienne

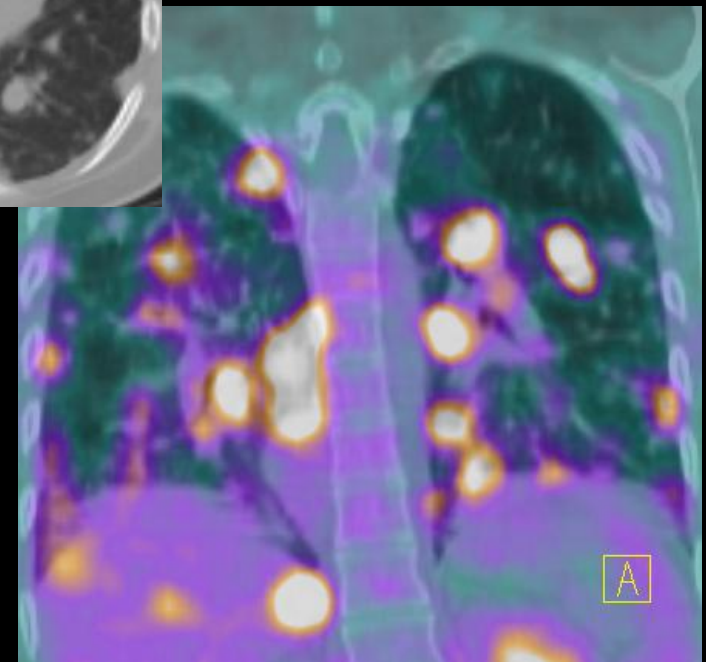
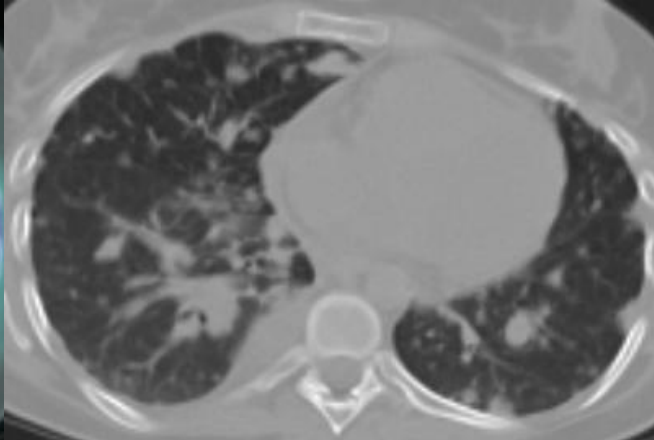
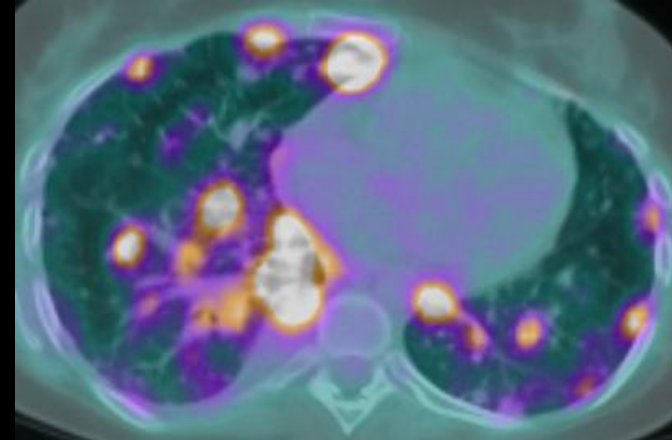
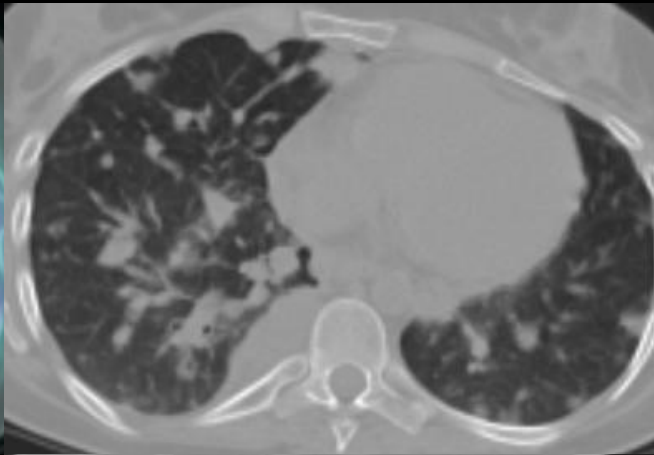
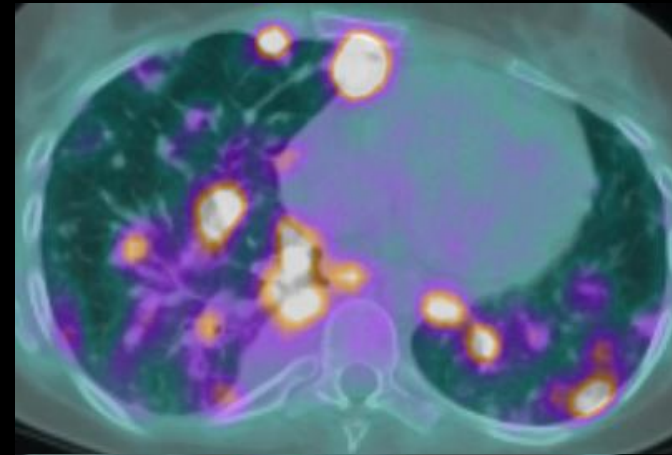


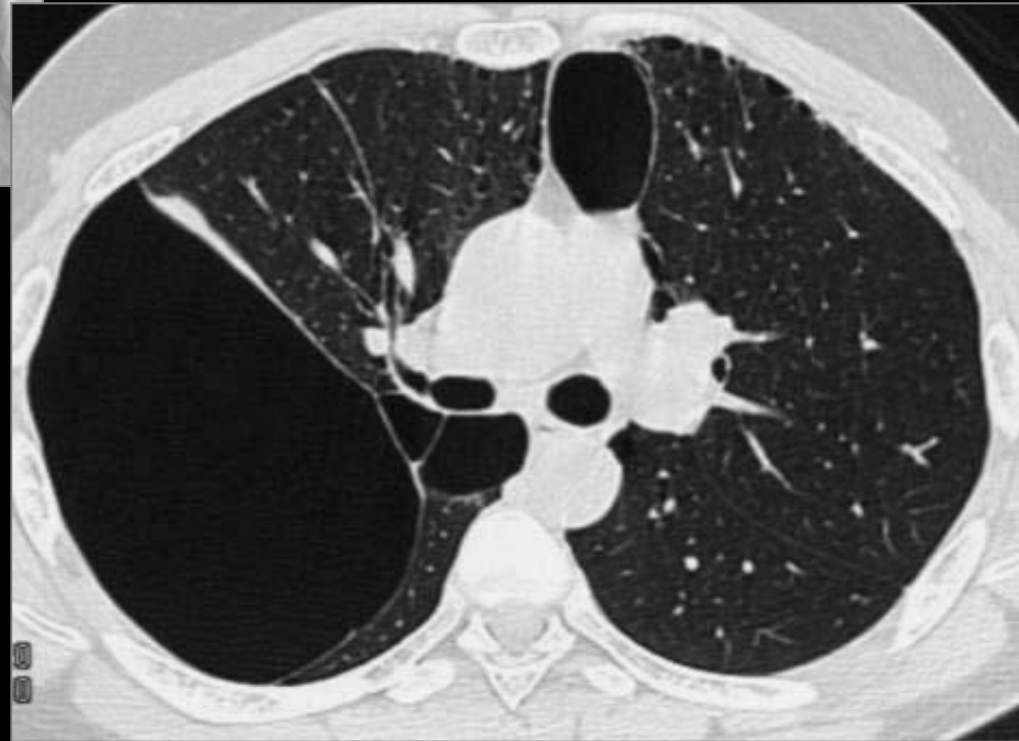
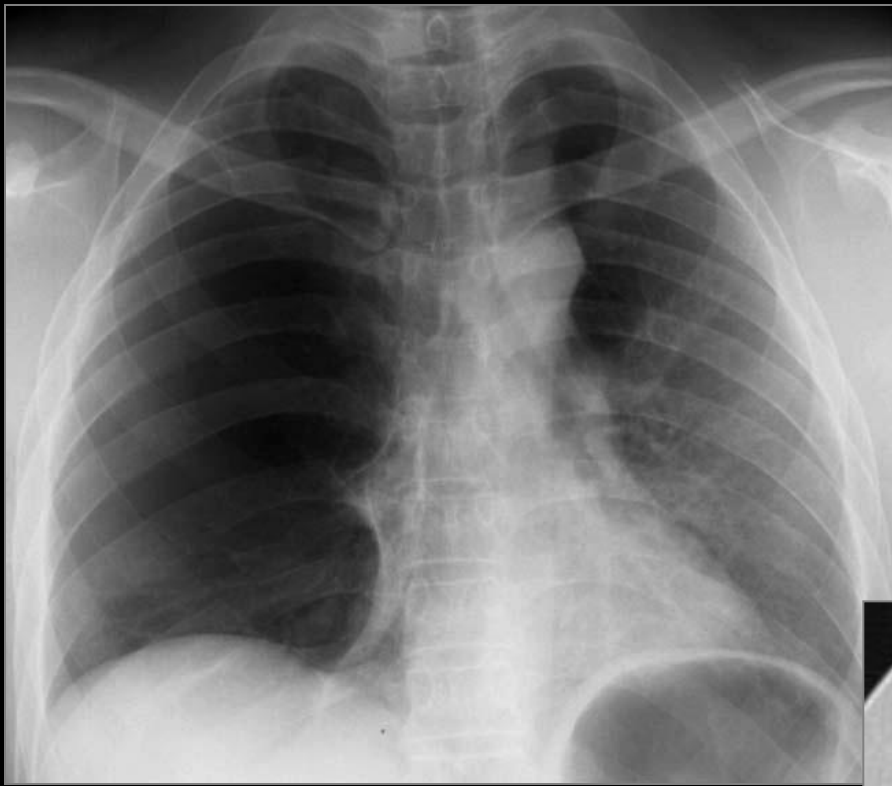
## Opacités macro nodulaires

**Lâcher de ballon**  
**Métastases pulmonaires**  
**Distribution hématogènes**



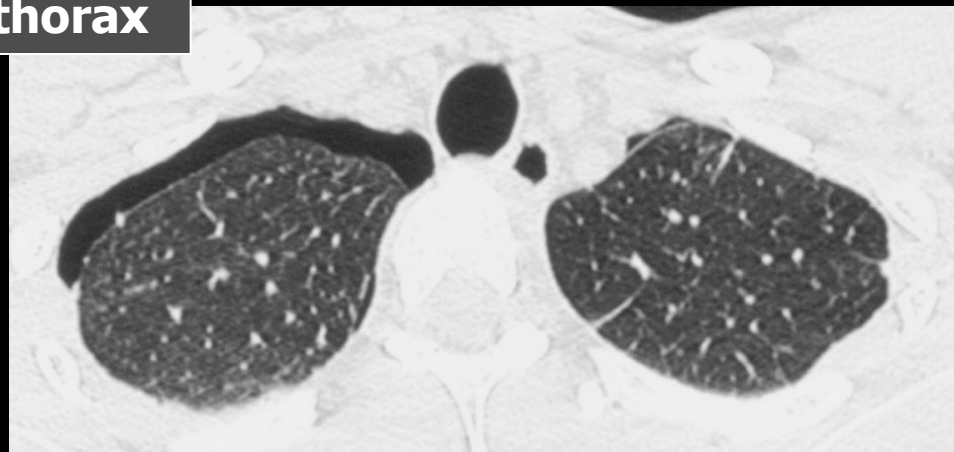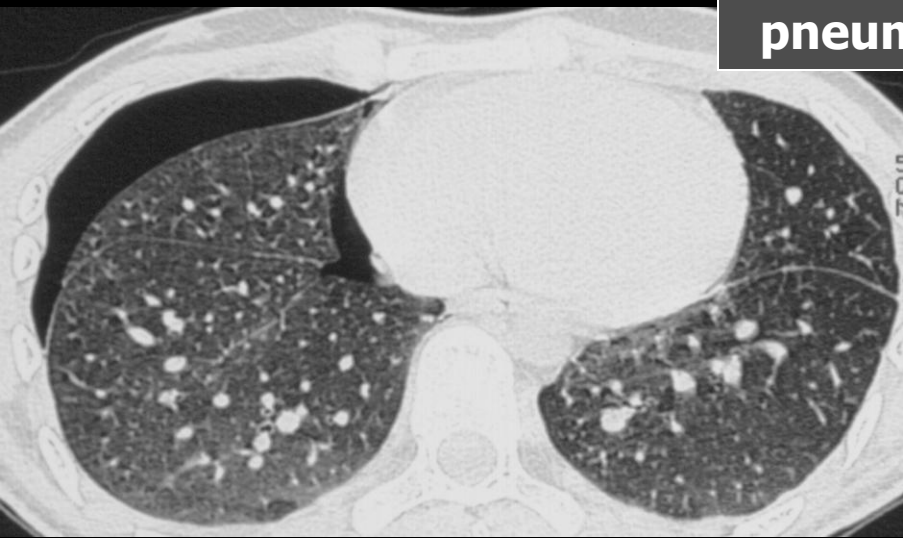
# Lâcher de ballons



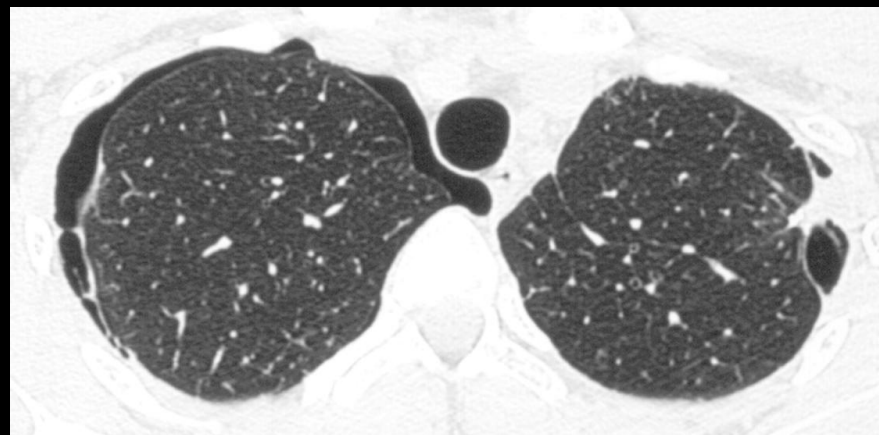
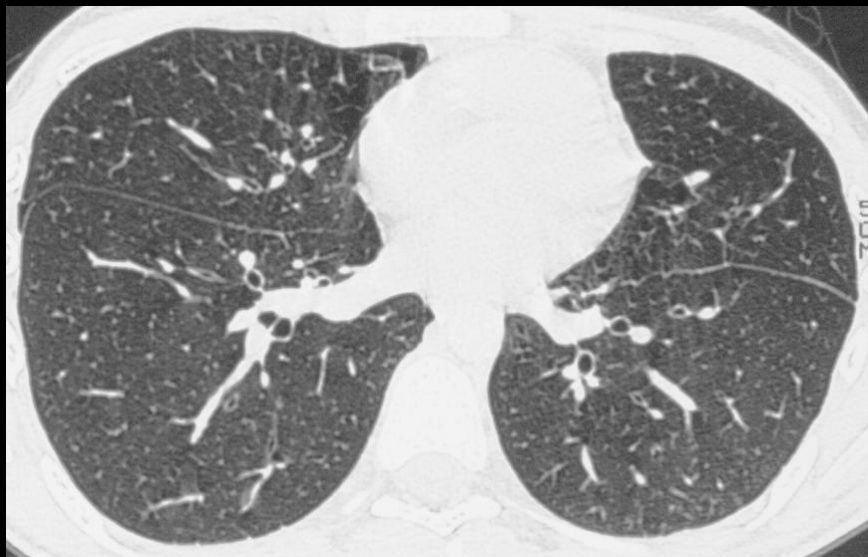

**Hyperclartés**  
**Bulles**  
**d'emphysème**

**pneumothorax**

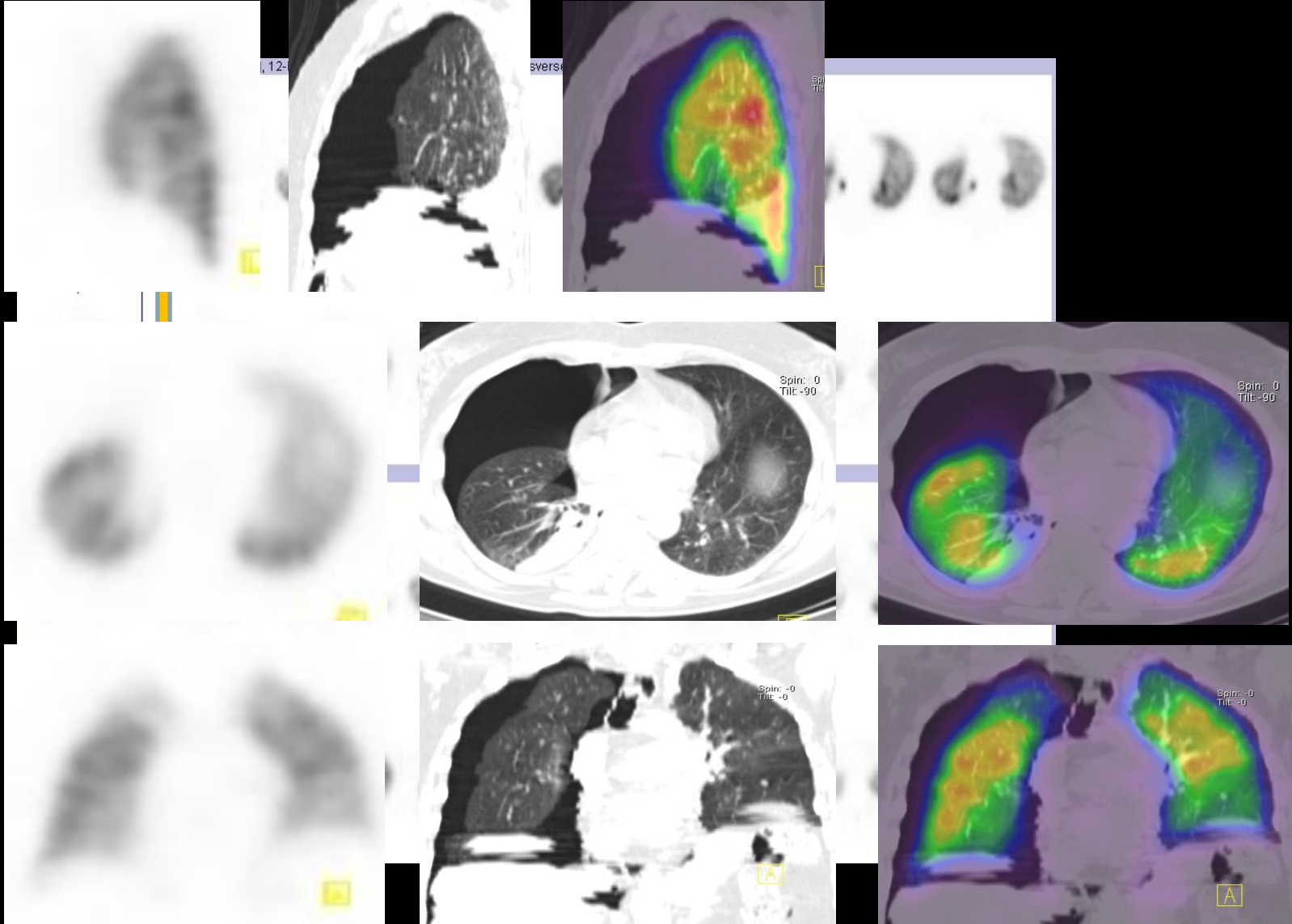


**coupes en expiration**



**coupes en inspiration**

# Scintigraphie pulmonaire

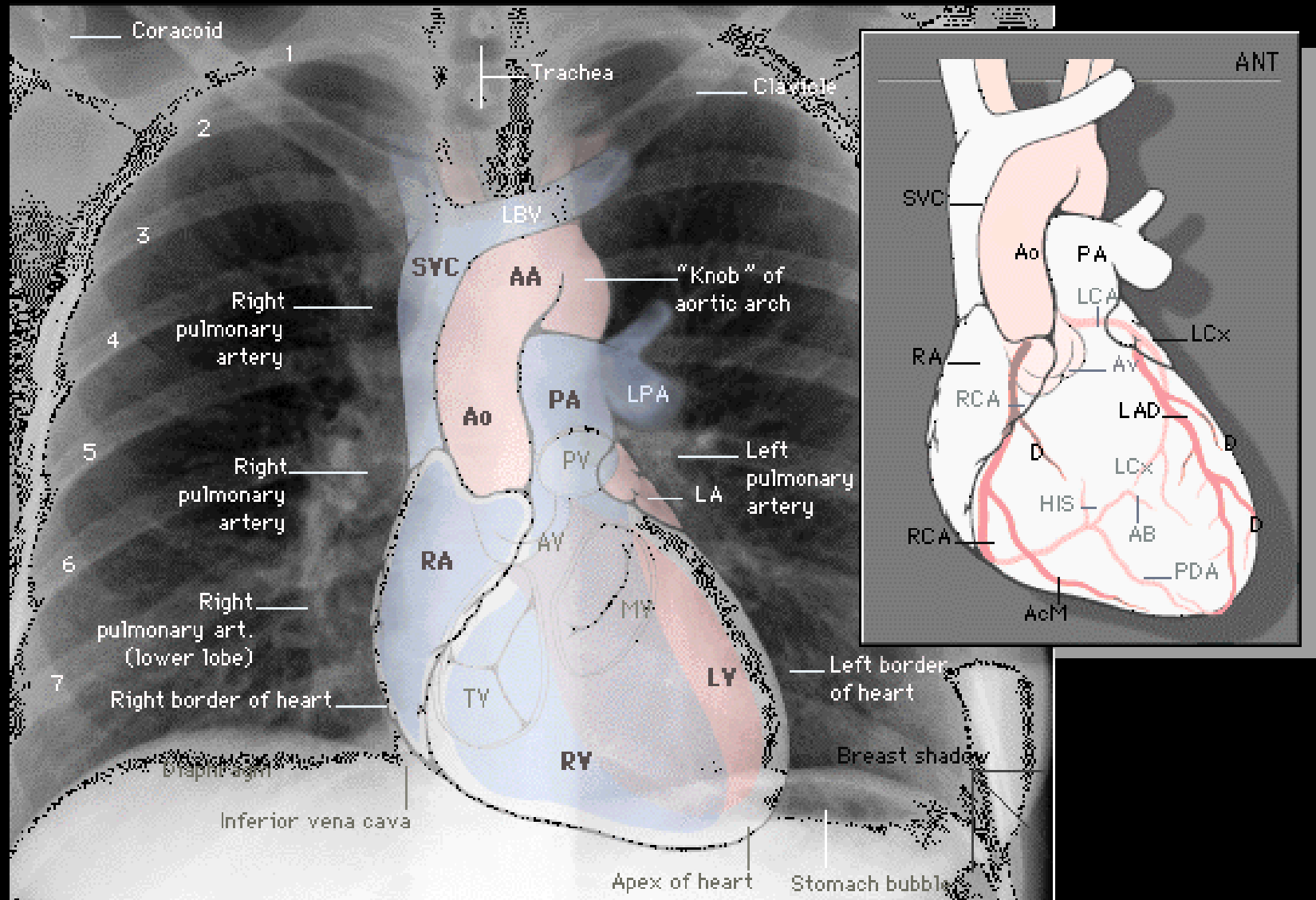




## 2/ RADIOANATOMIE DU MEDIASTIN

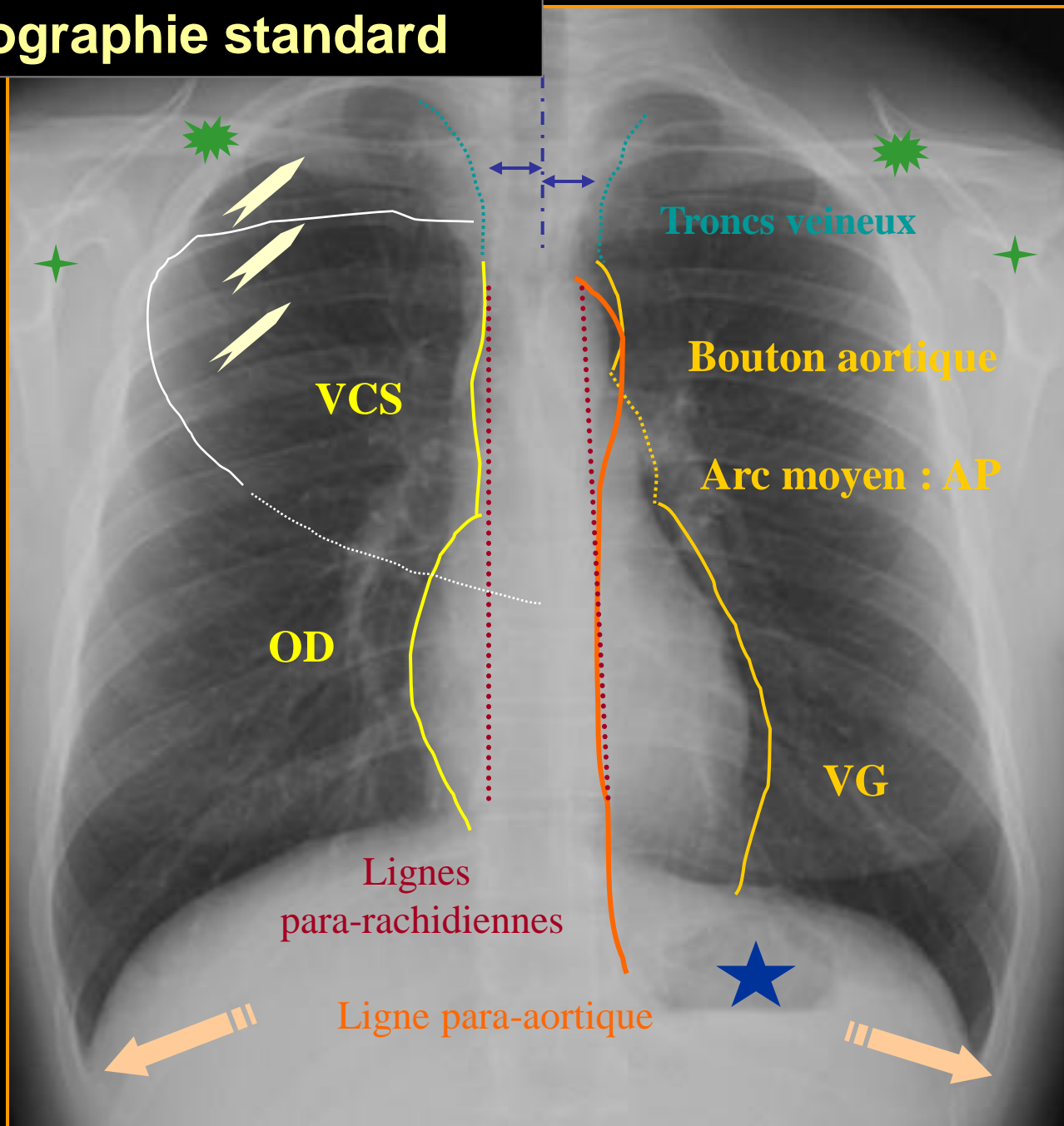
- **GENERALITES**
- **VAISSEAUX**
- **CŒUR**
- **ŒSOPHAGE**
- **CHAINES GANGLIONNAIRES**

# Reconnaître les structures vasculaires

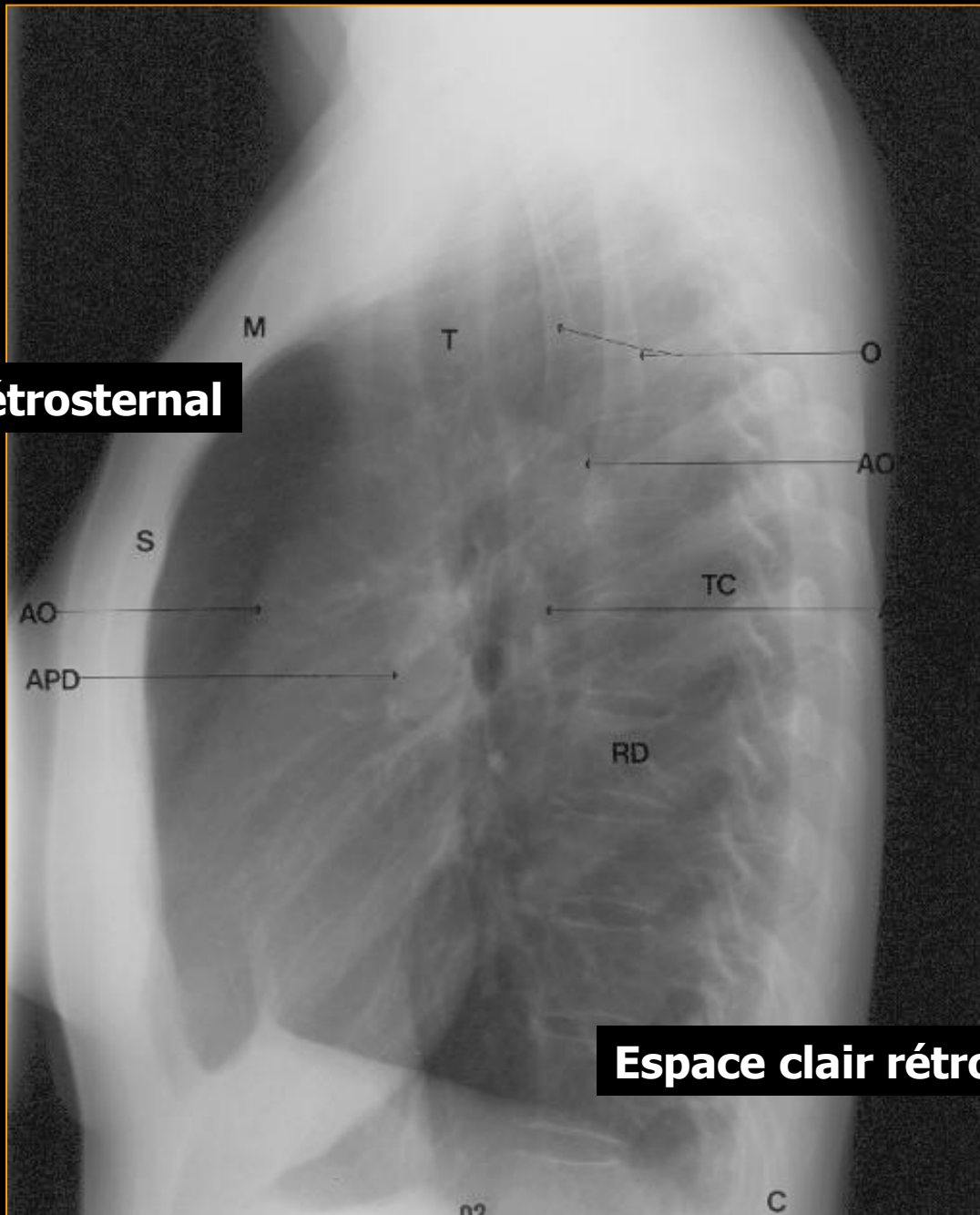


# Radiographie standard

DE FACE

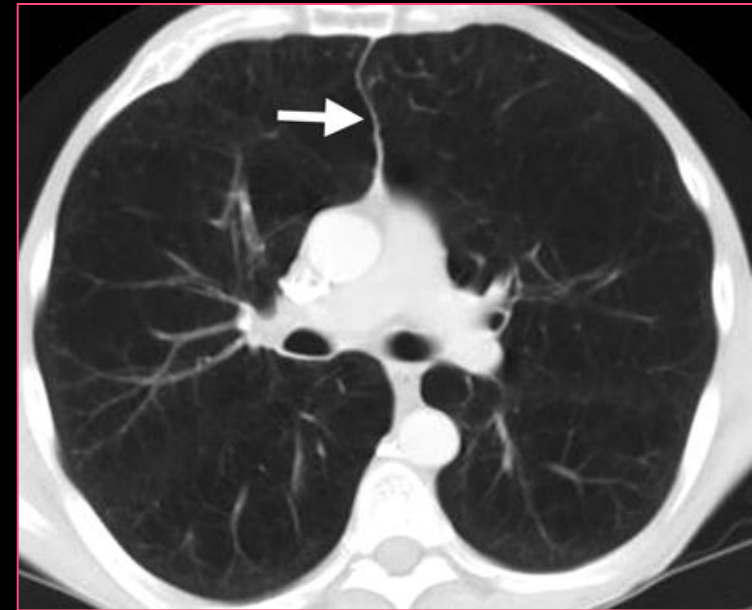
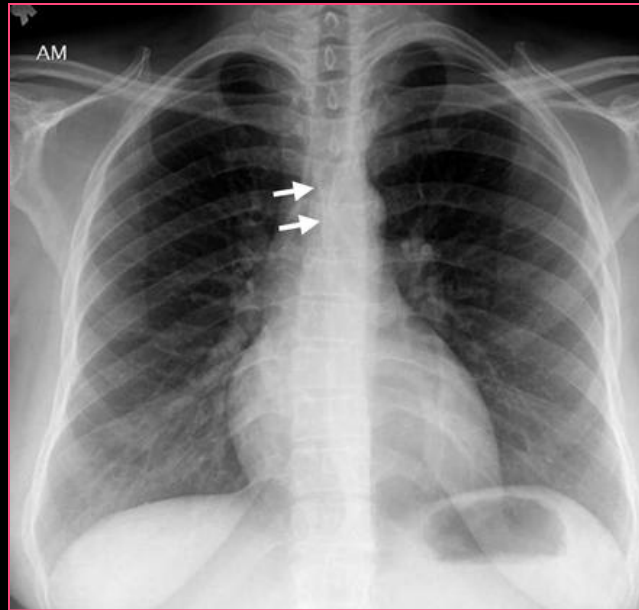
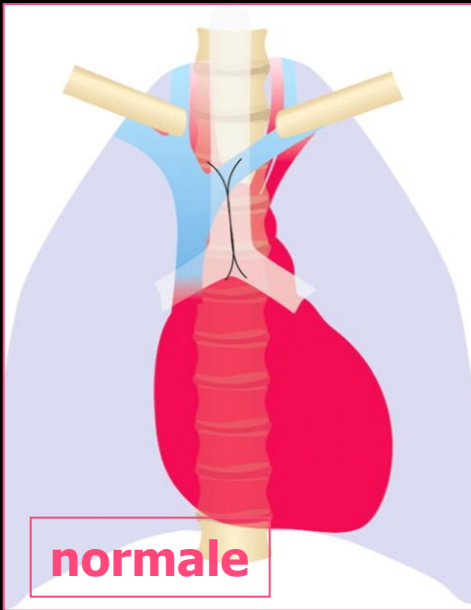


**Espace clair rétrosternal**

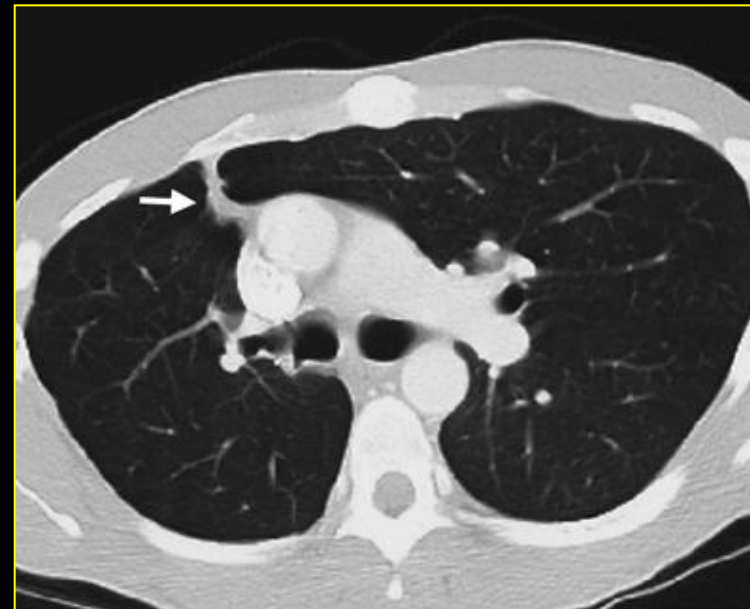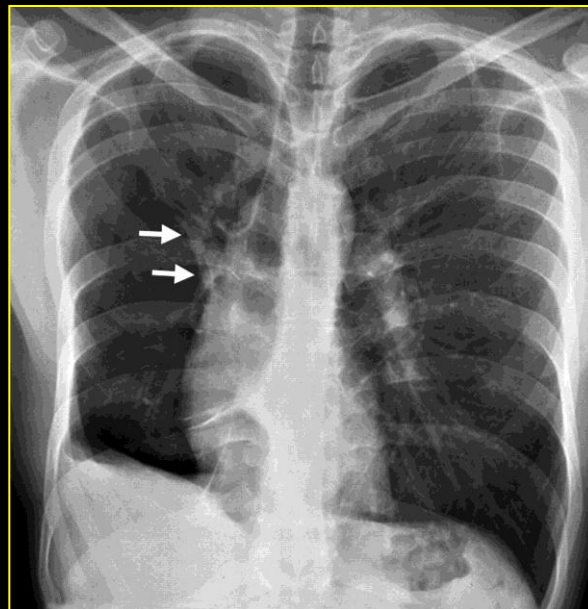


**Espace clair rétrocardiaque**

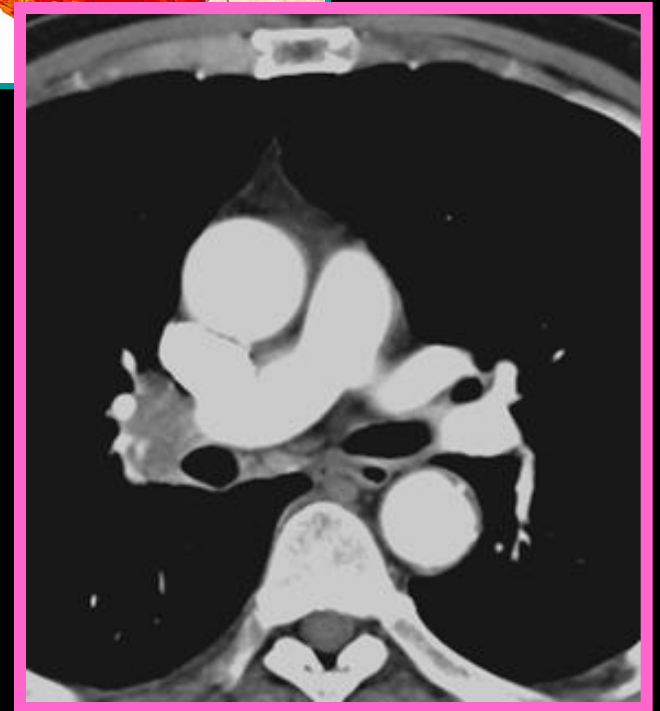
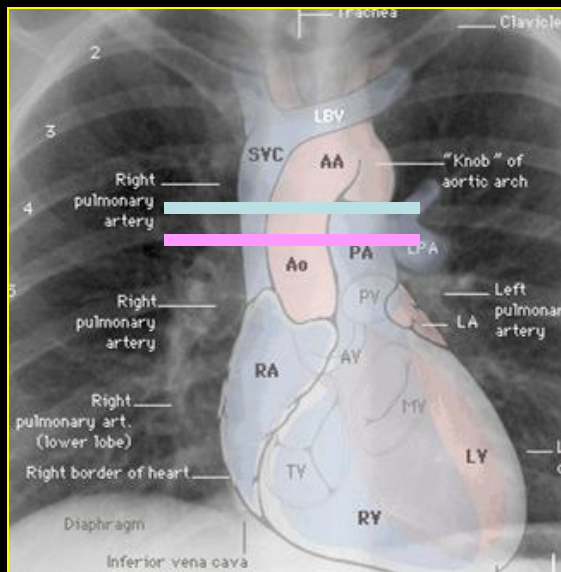
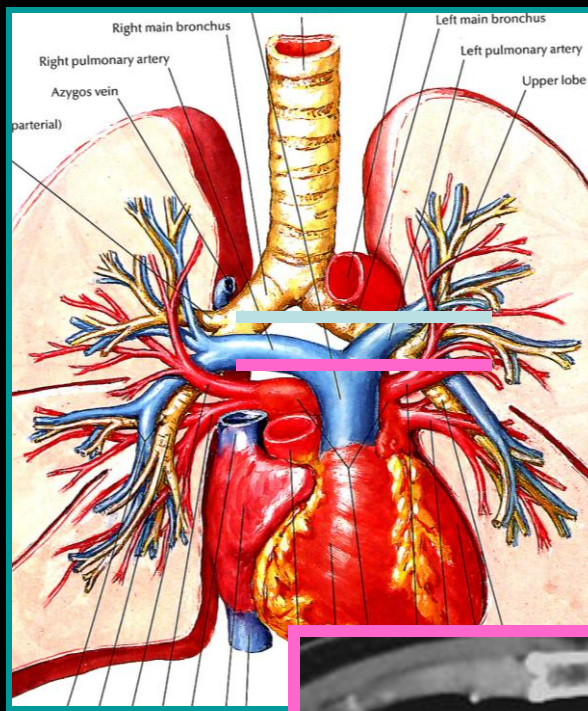
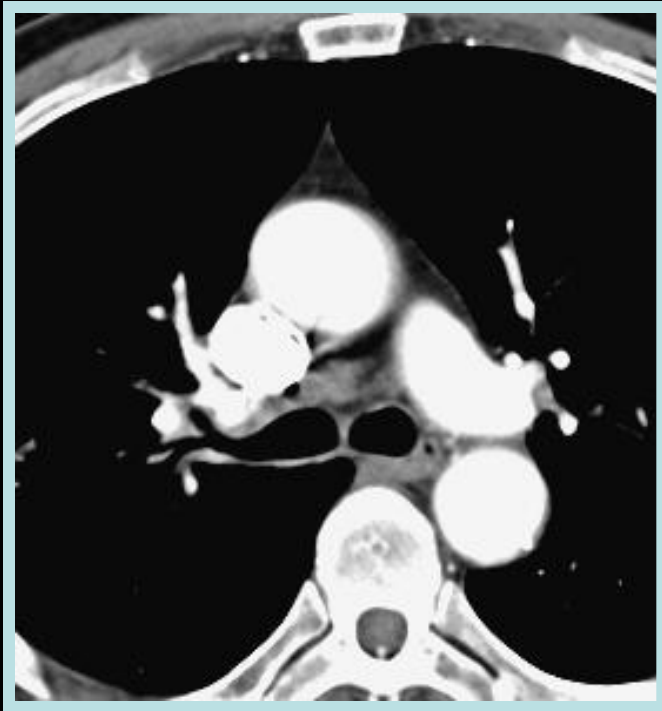
# Ligne de jonction médiastinale antérieure

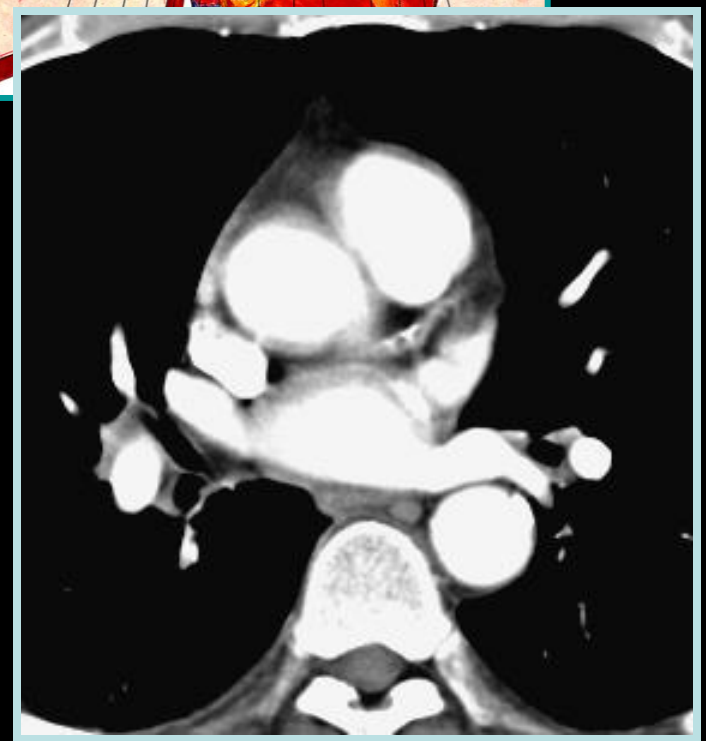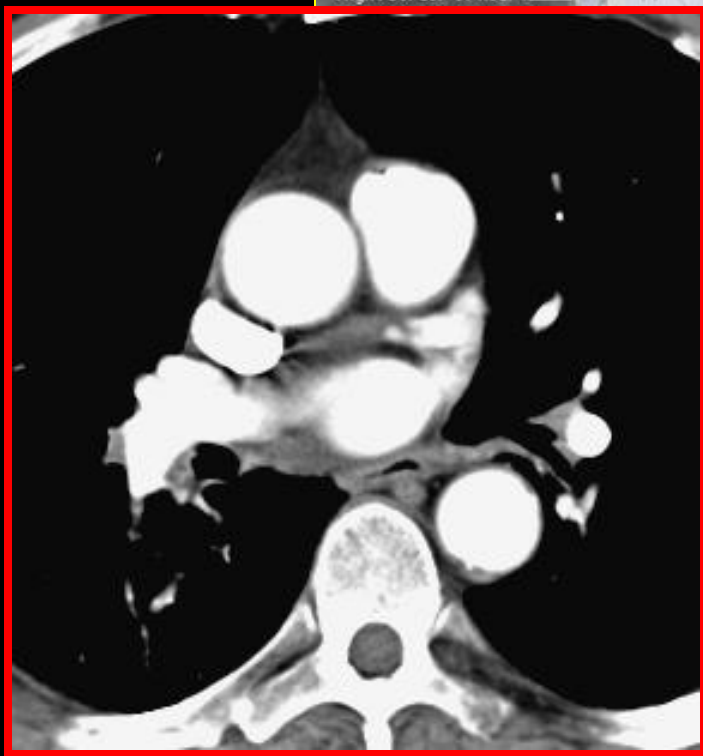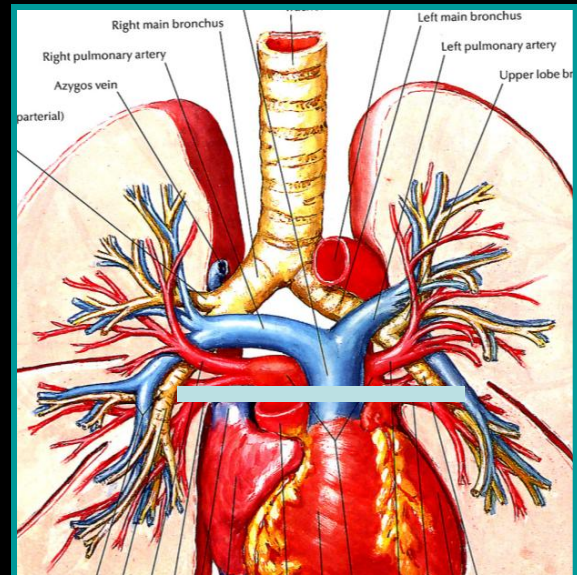
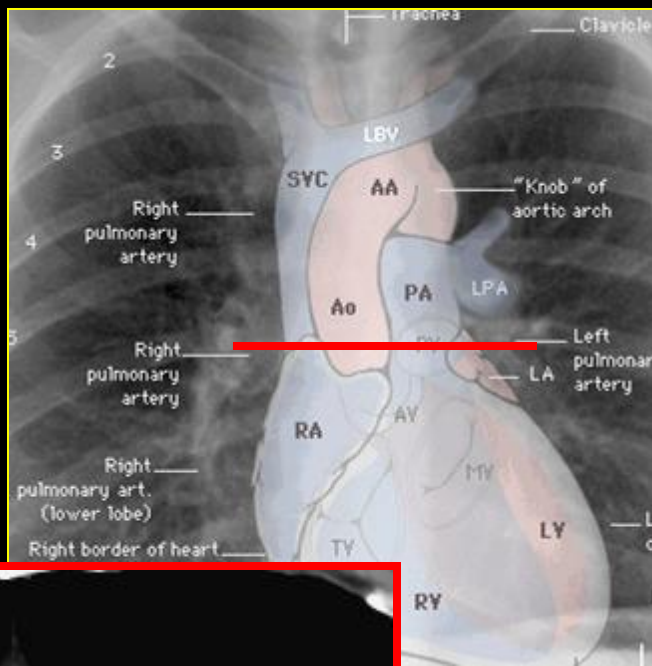


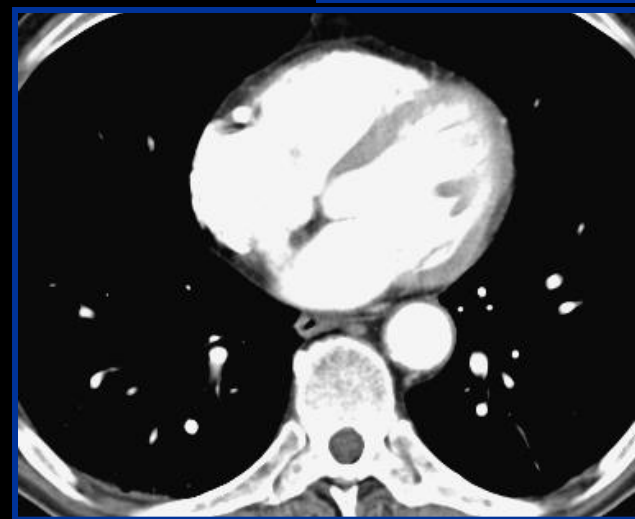
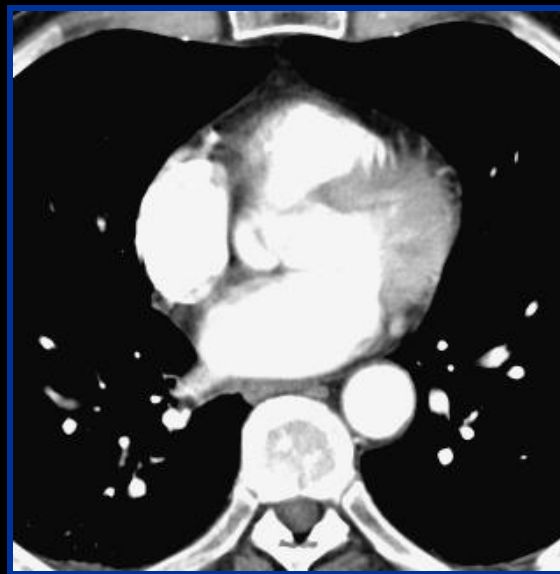
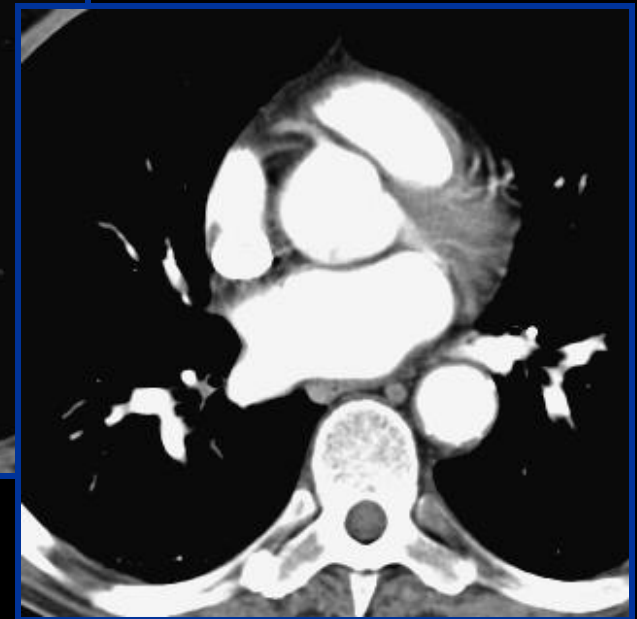
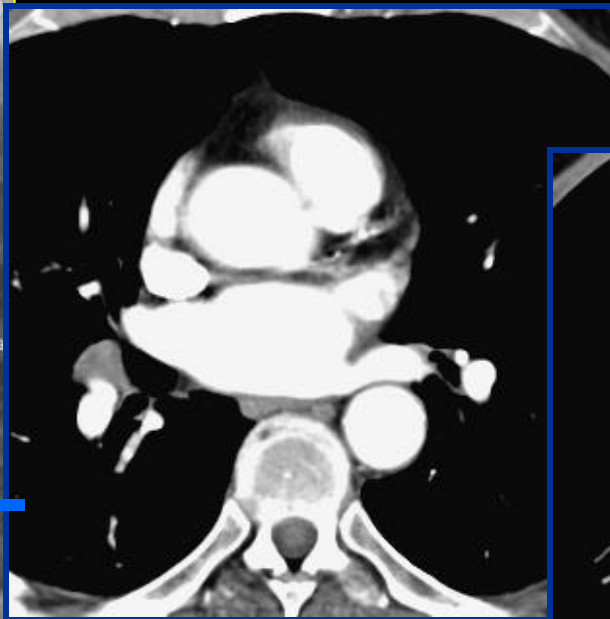
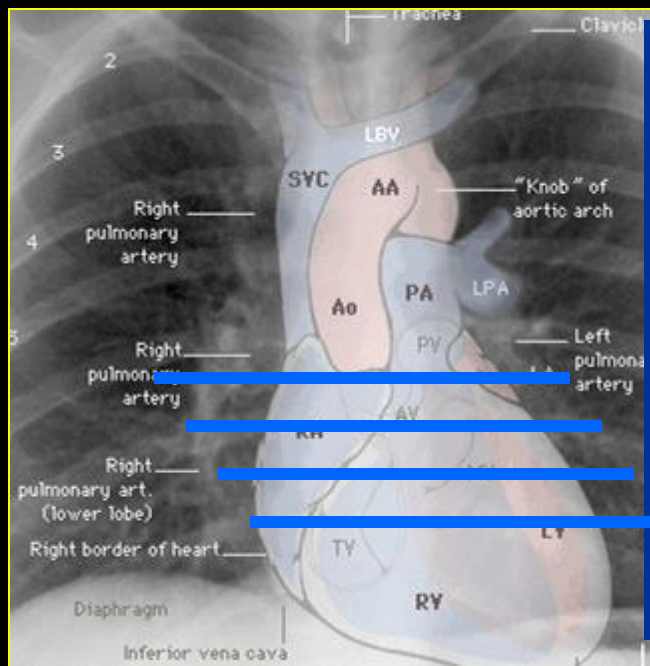
**Déplacement  
après lobectomie  
moyenne droite**

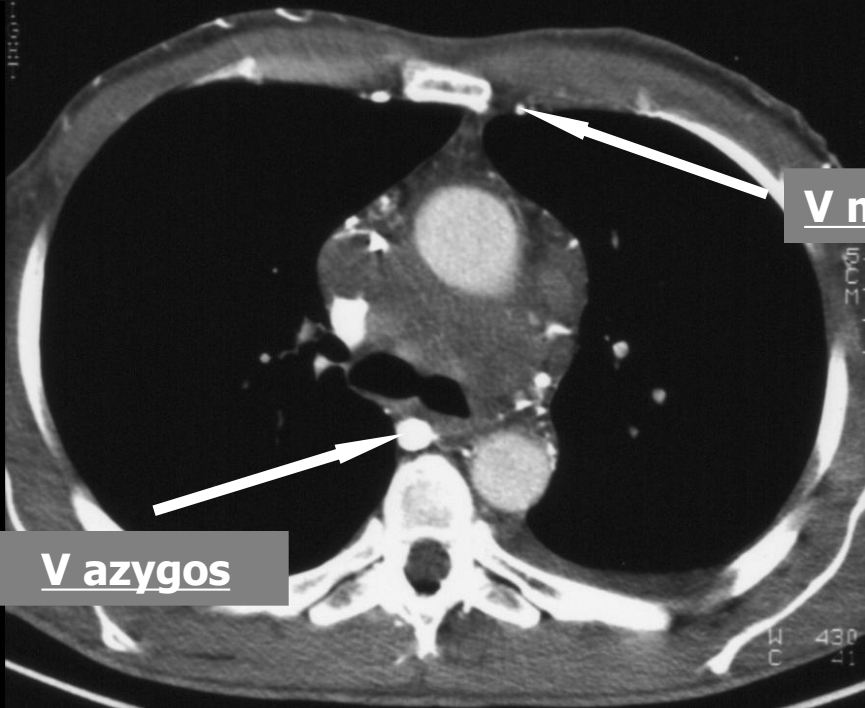
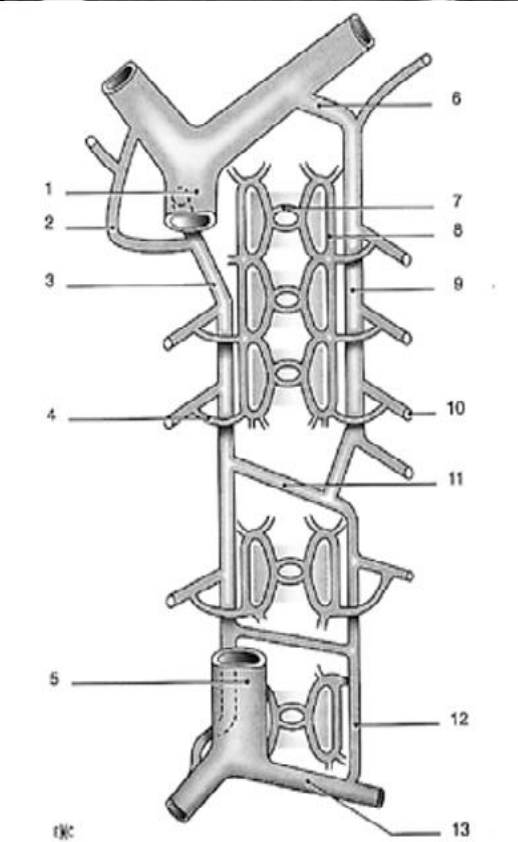
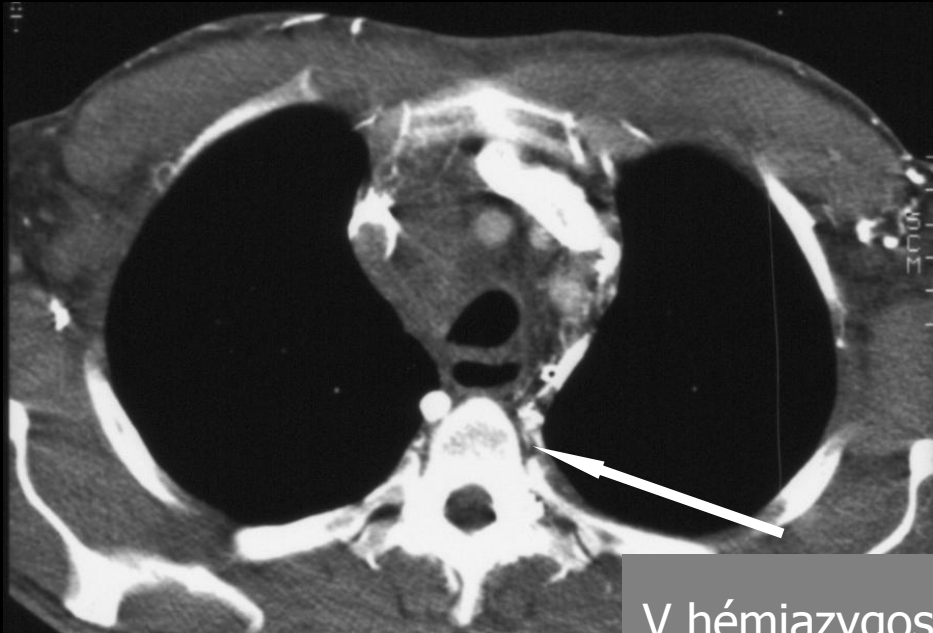
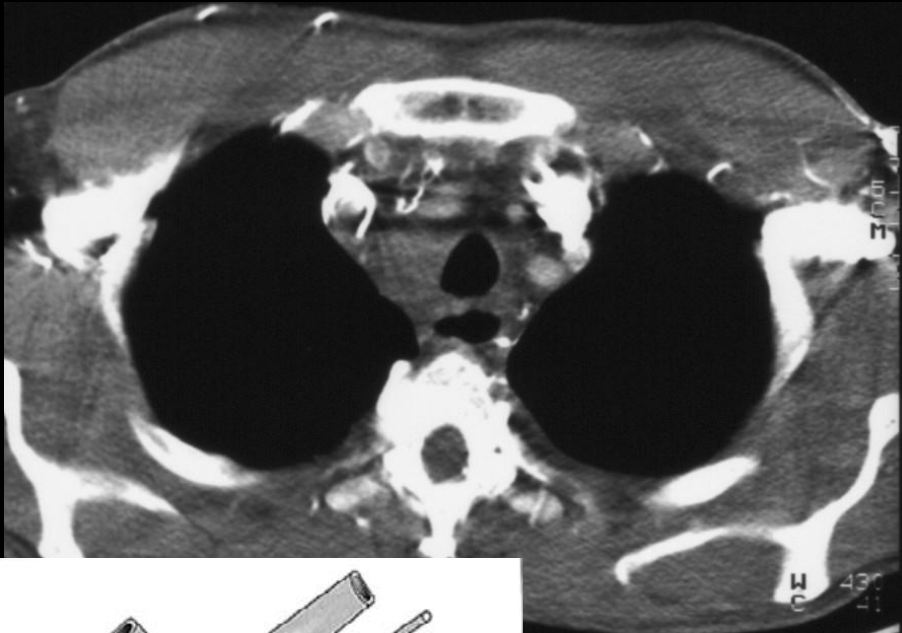









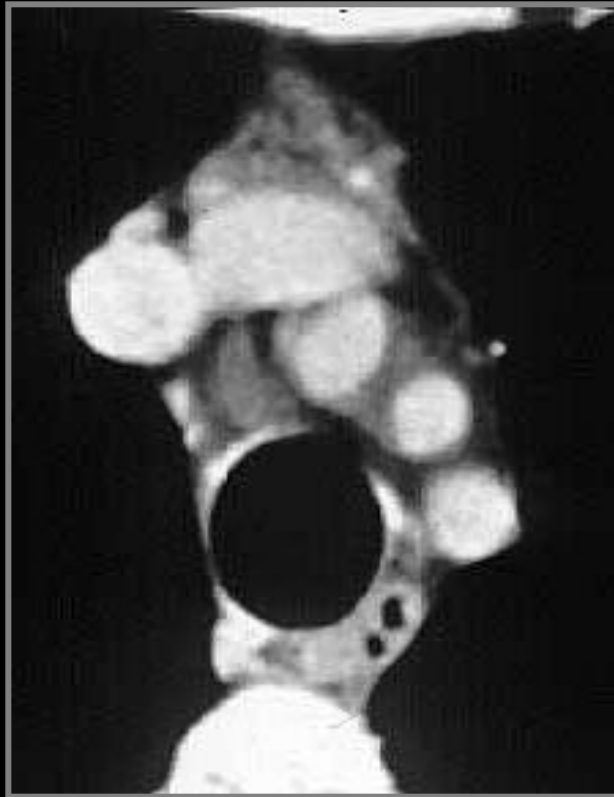




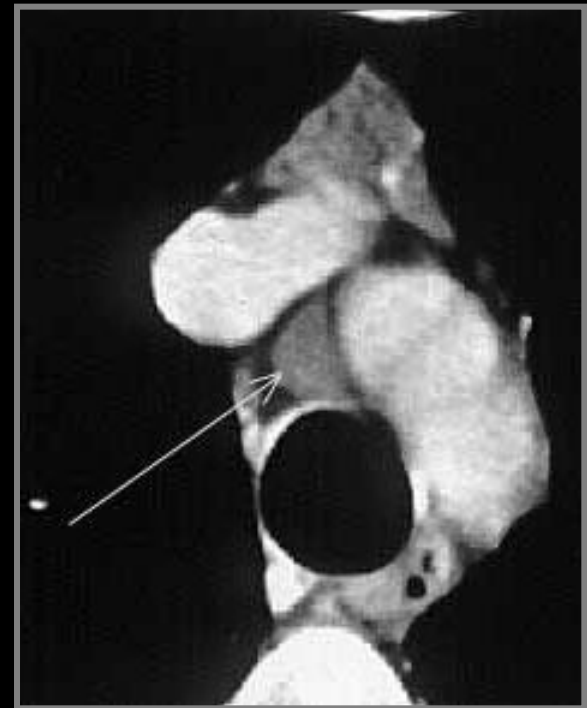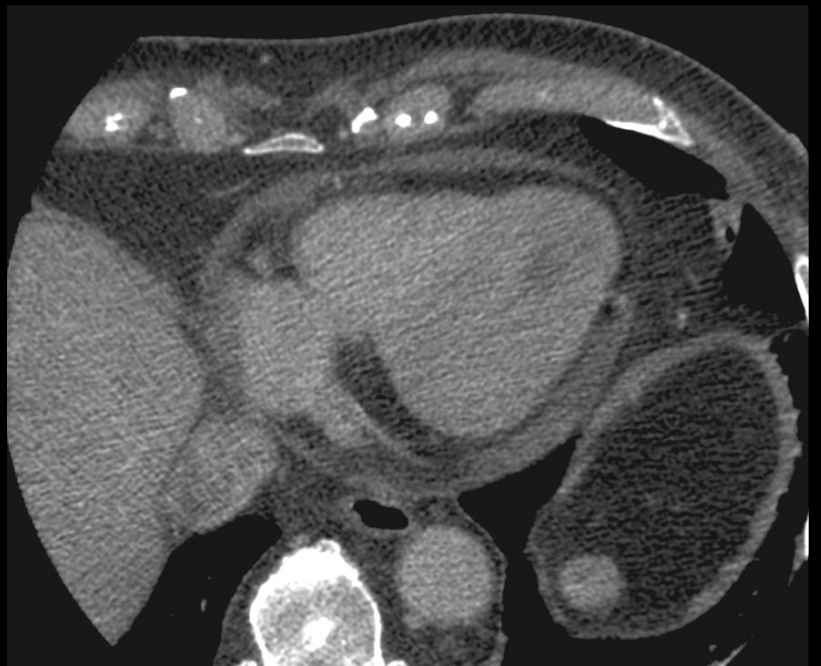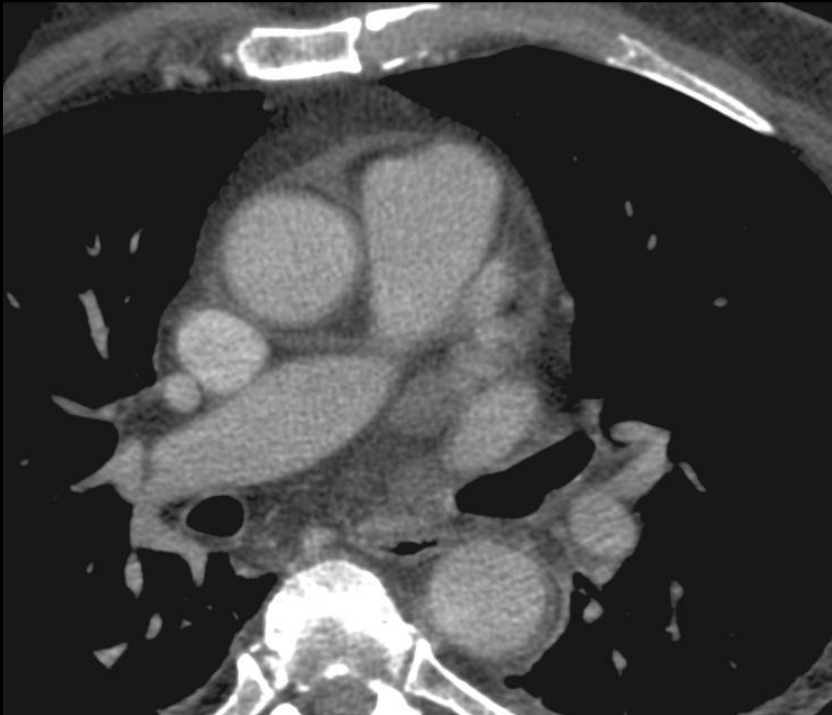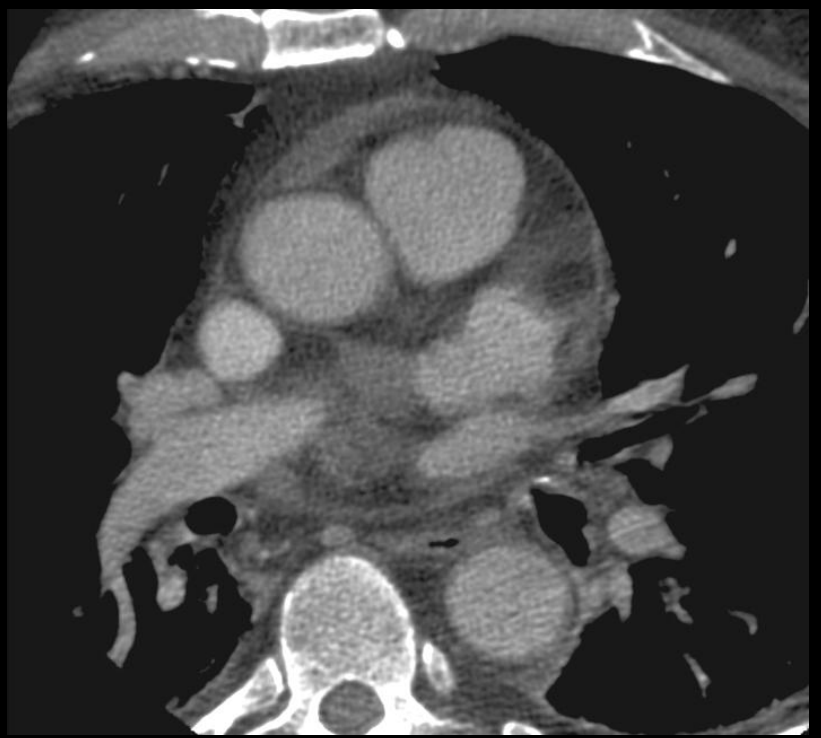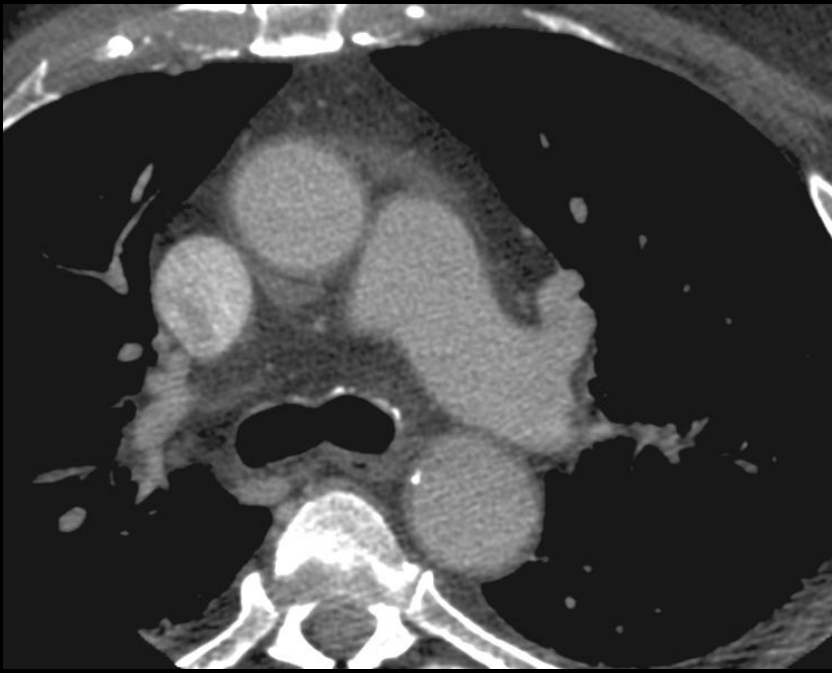
**UN PEU DE PATHOLOGIE ET  
VARIATIONS ANATOMIQUES...**

# Pièges et erreurs

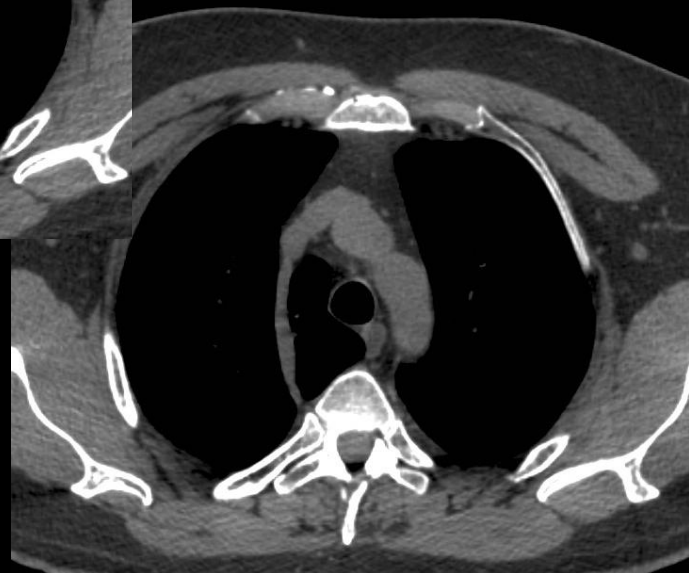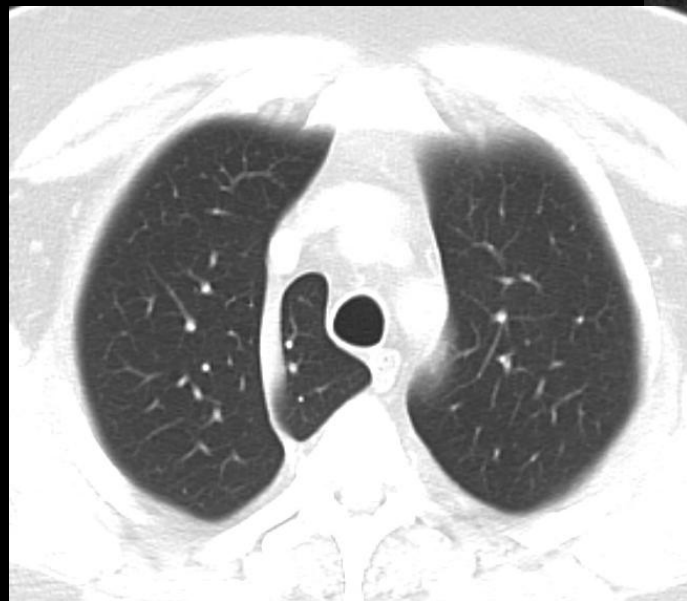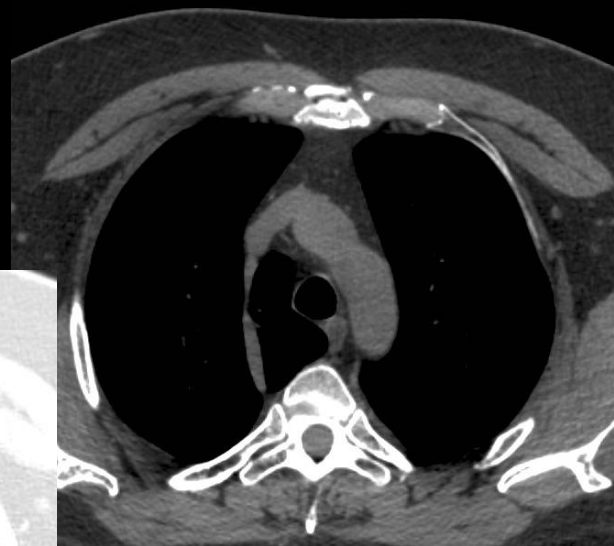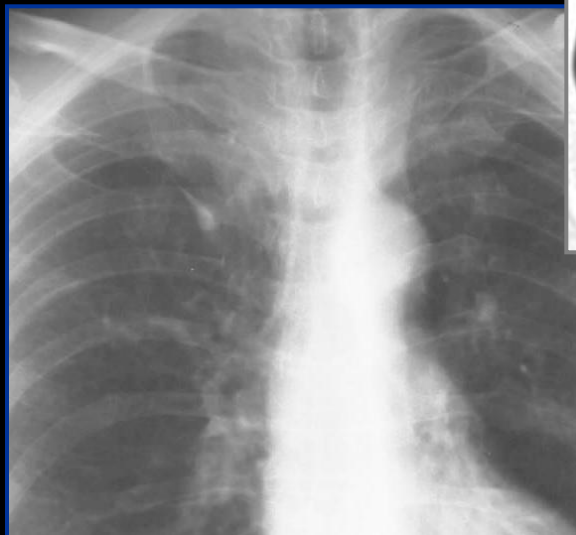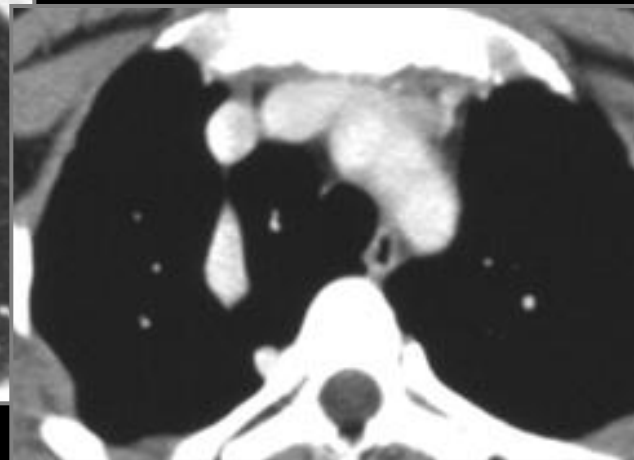


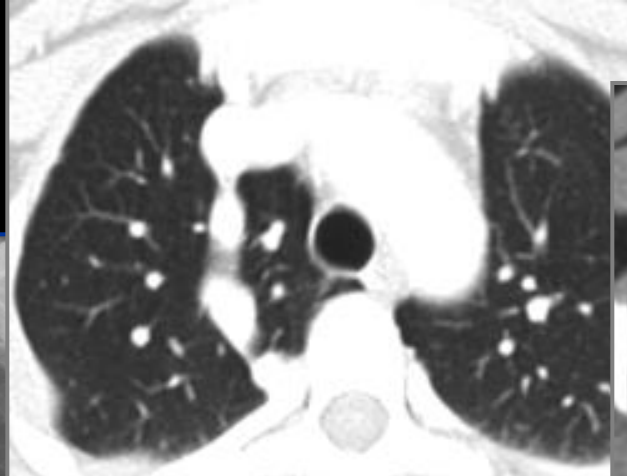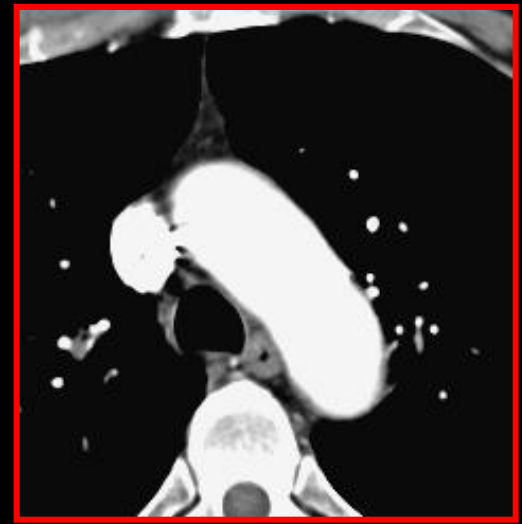
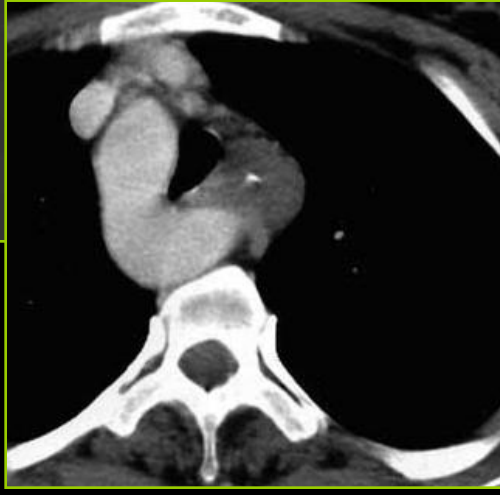
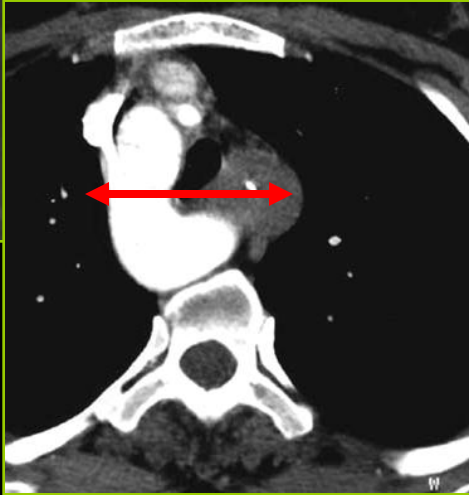
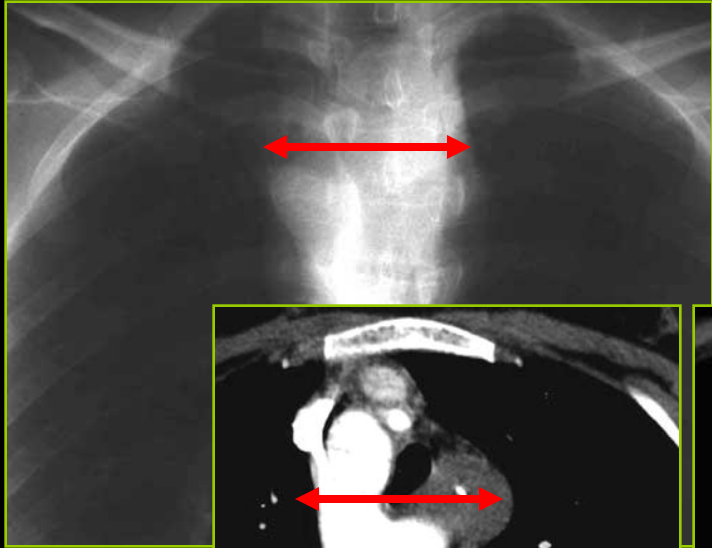
**Récessus péricardique**



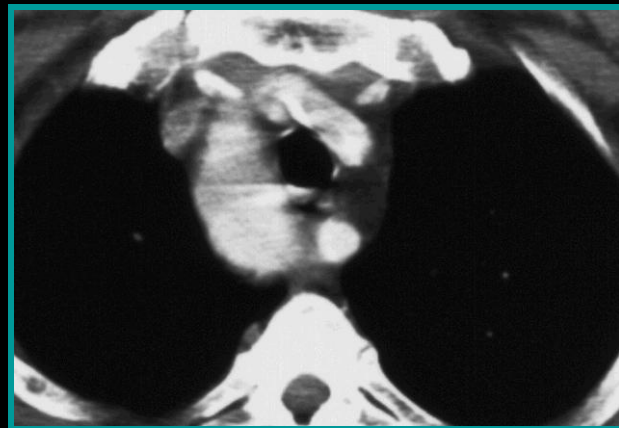
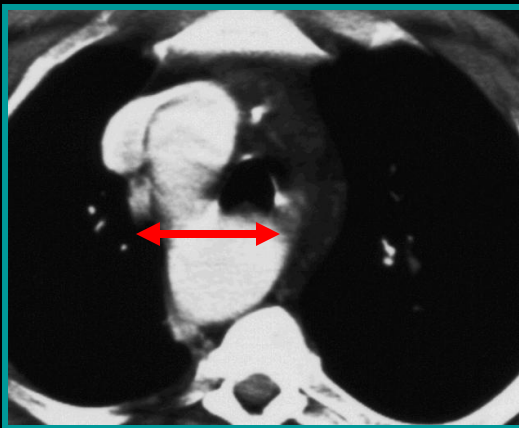


# Scissure azygos





**Arche aortique à droite**



# Double Veine cave sup

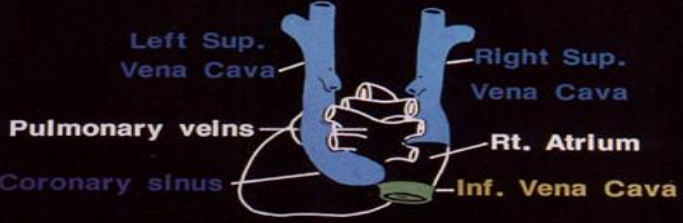
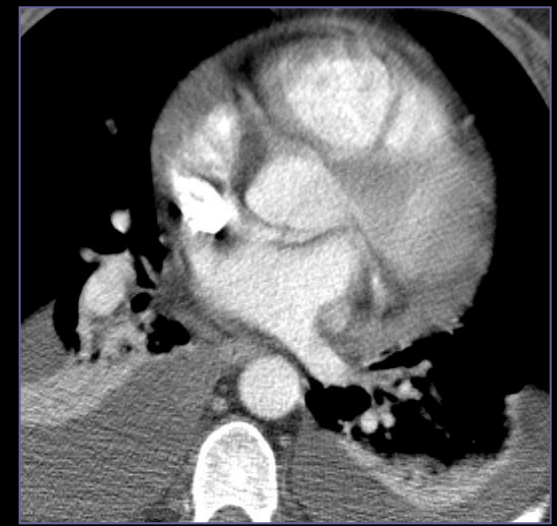
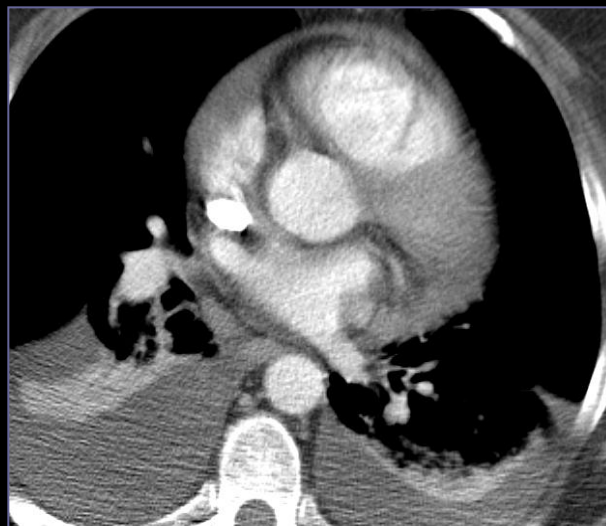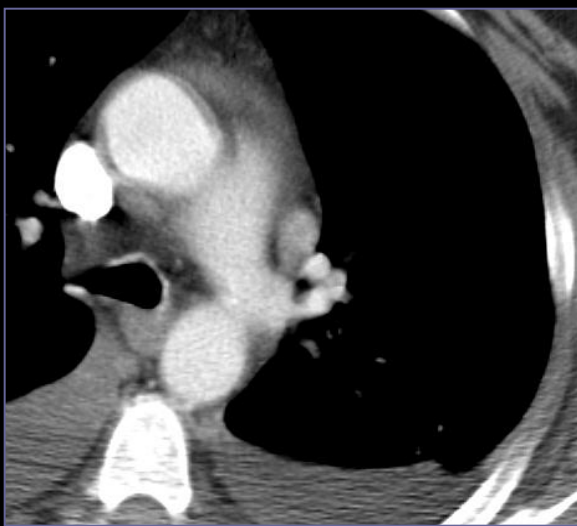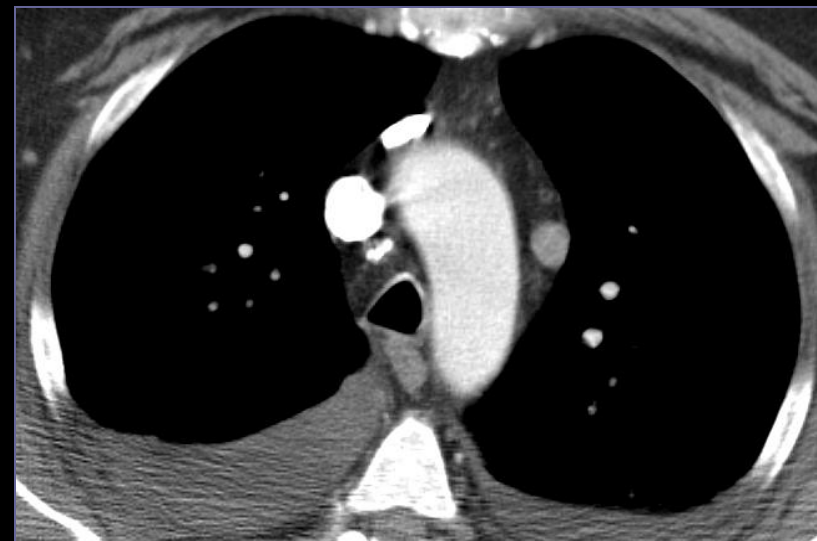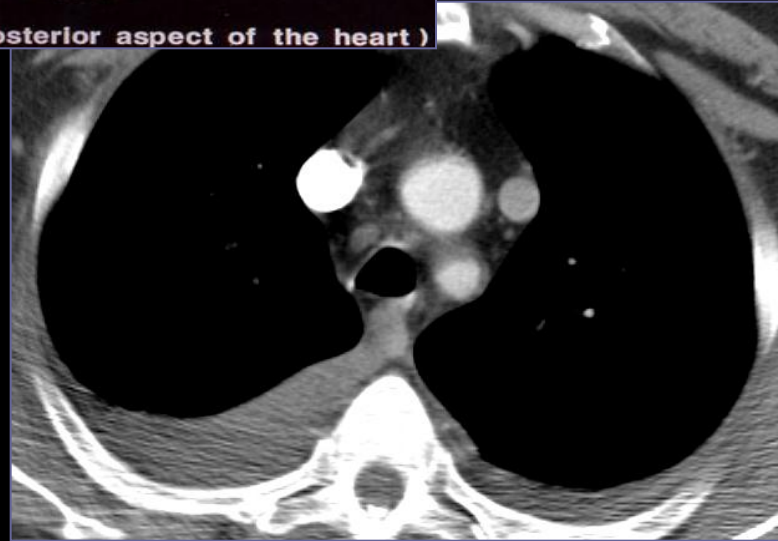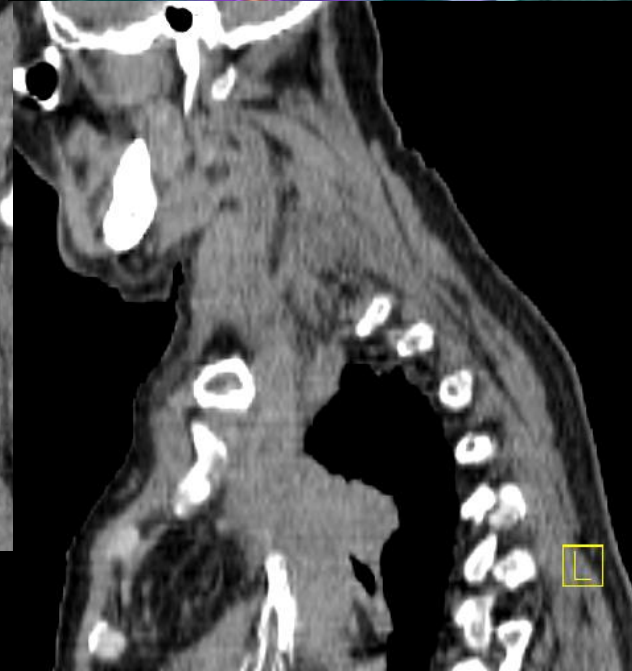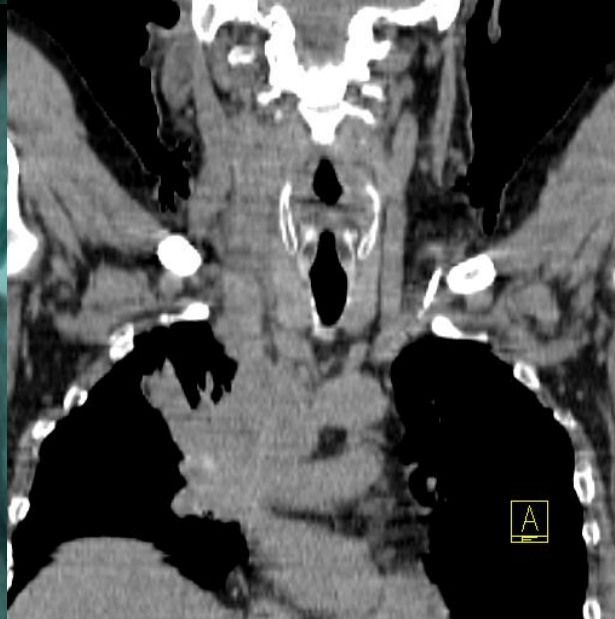


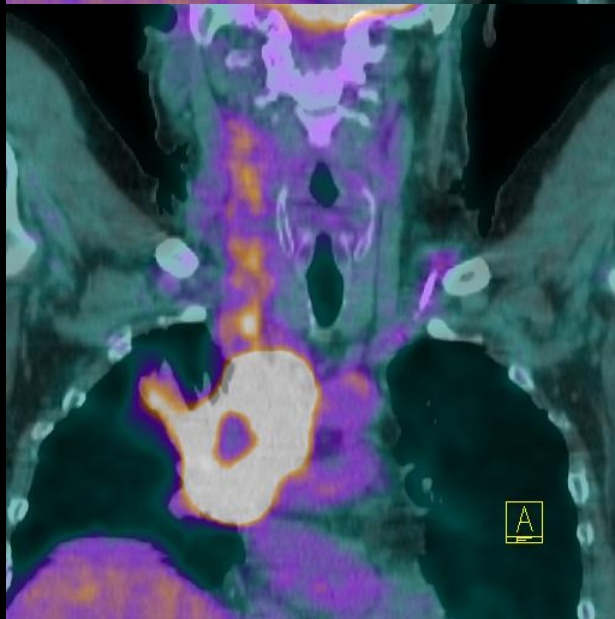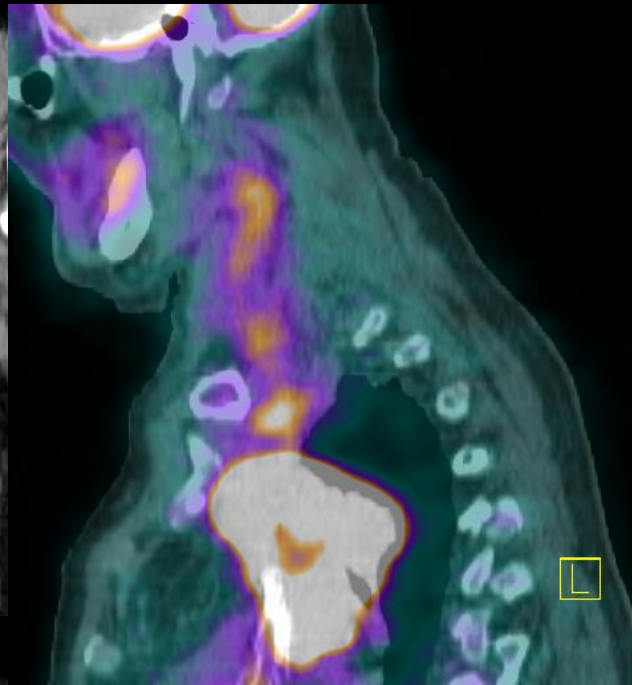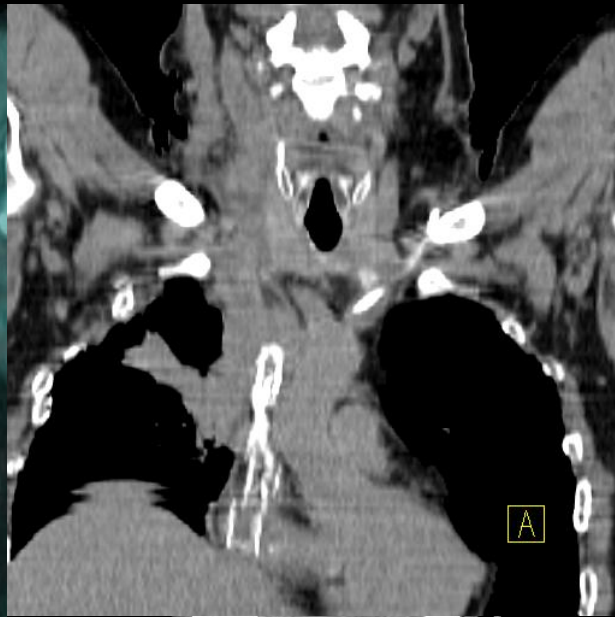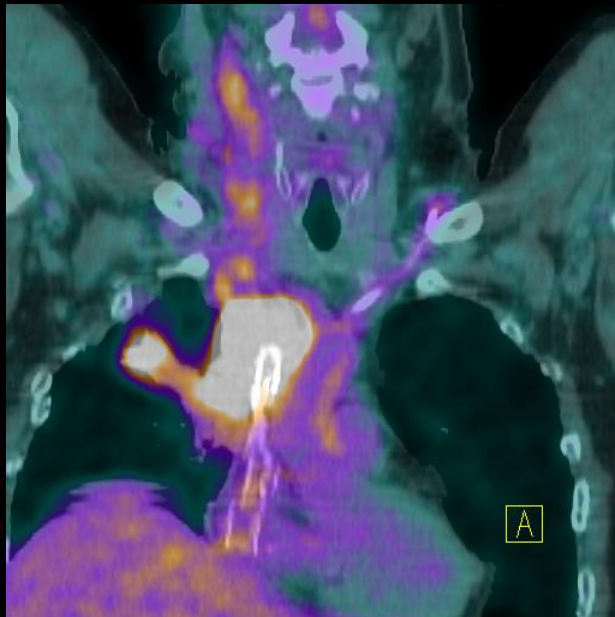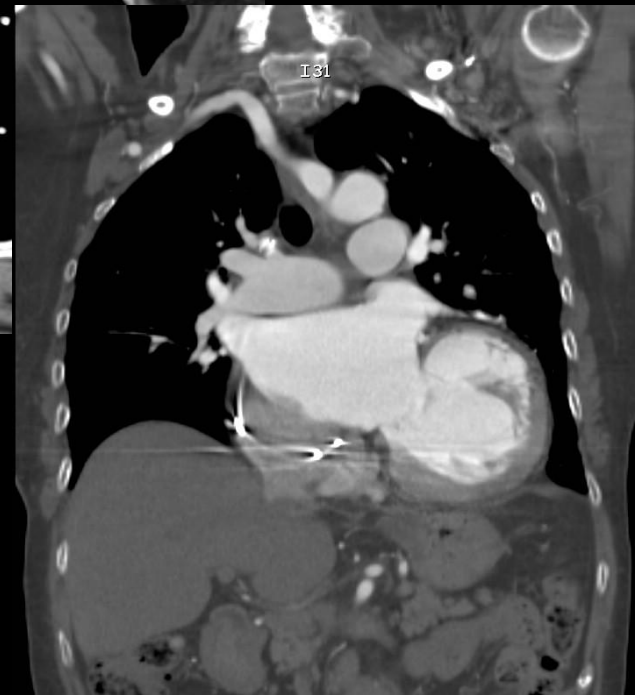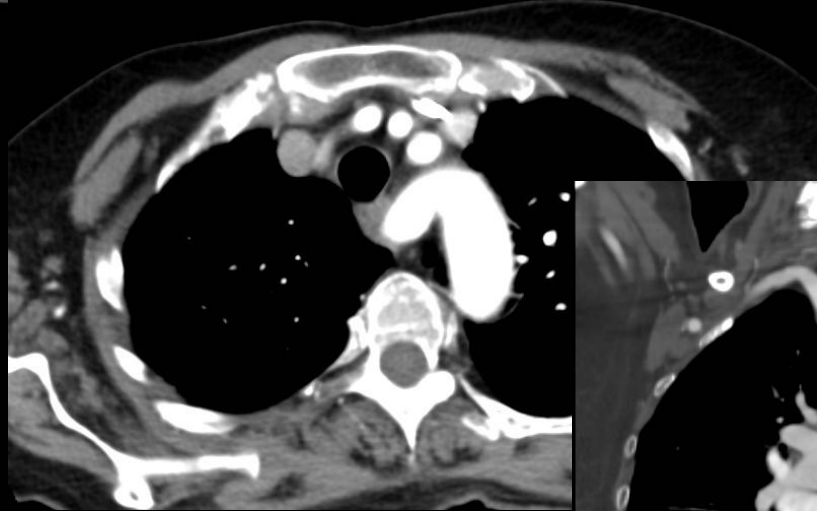
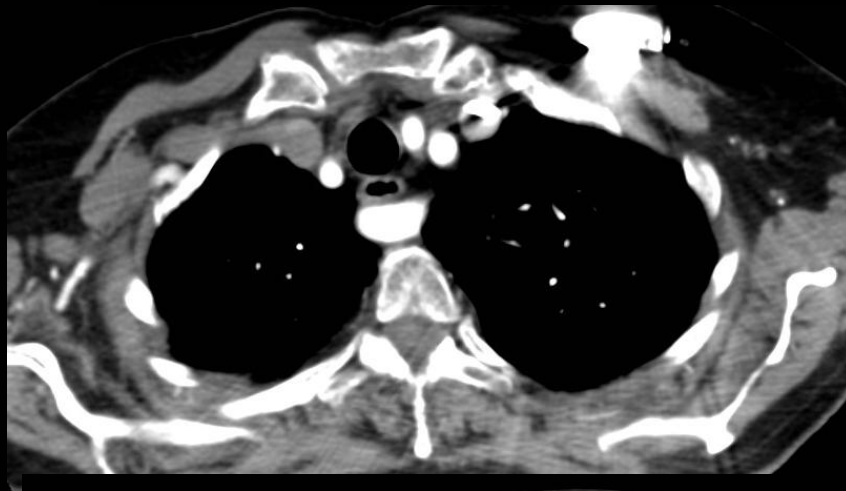Fig 8B

(Viewed from posterior aspect of the heart)

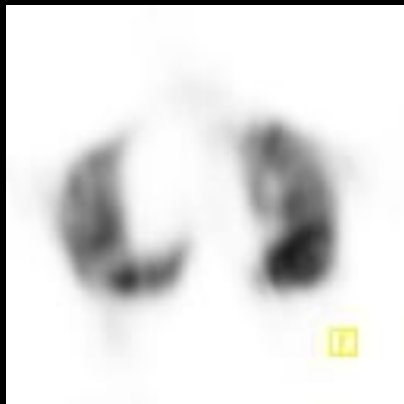
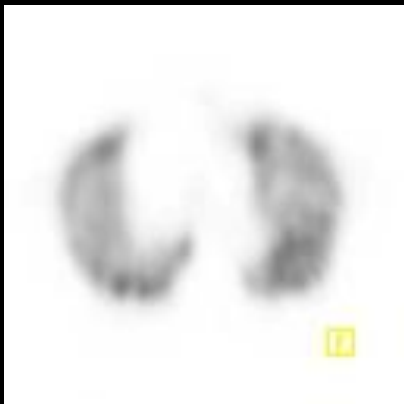
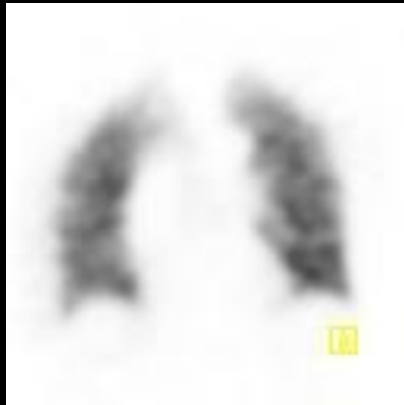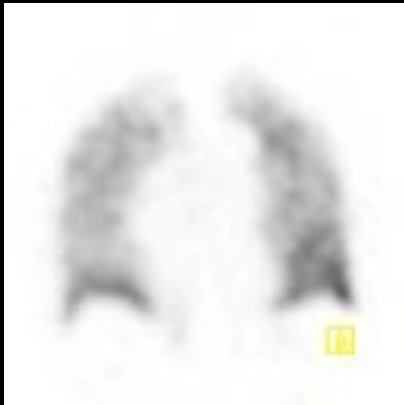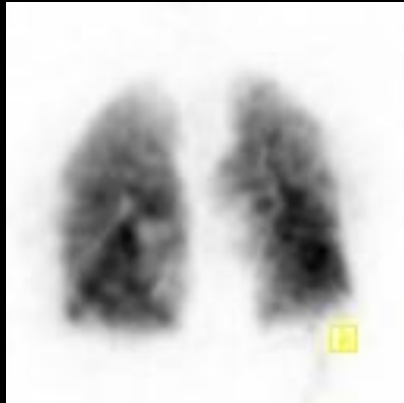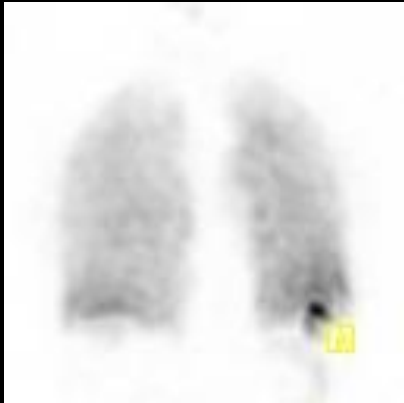




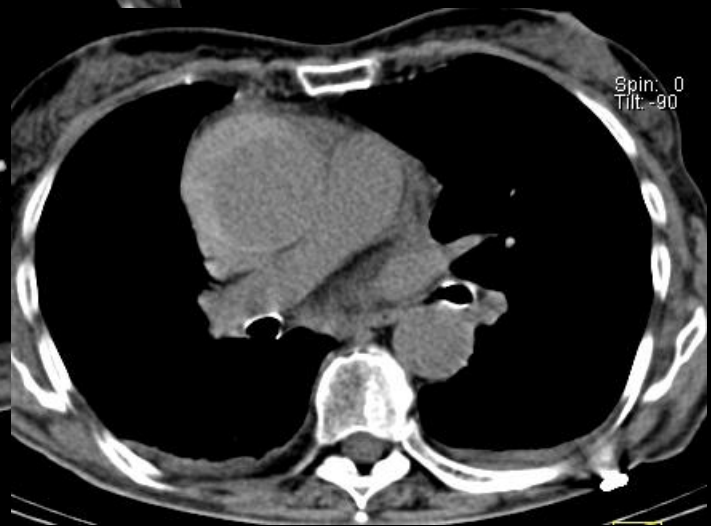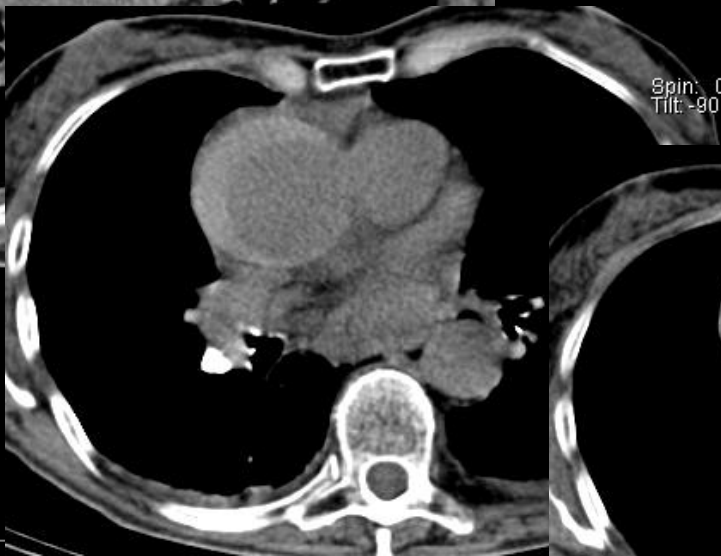
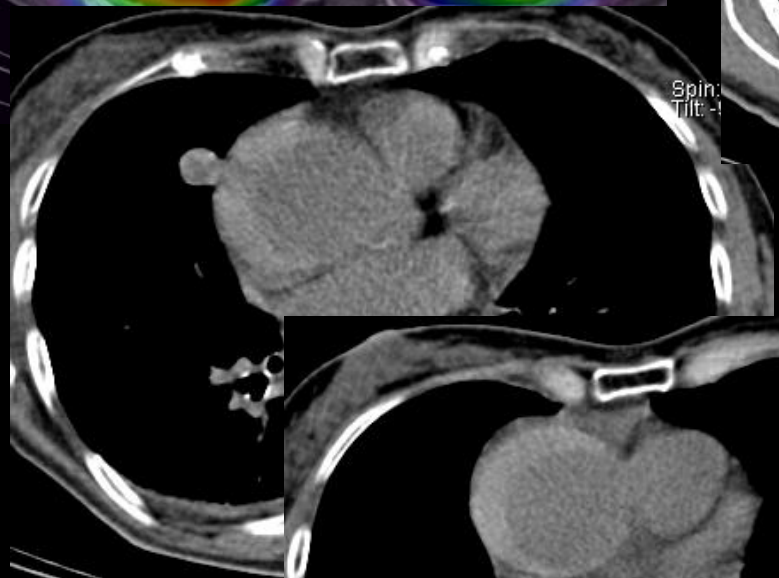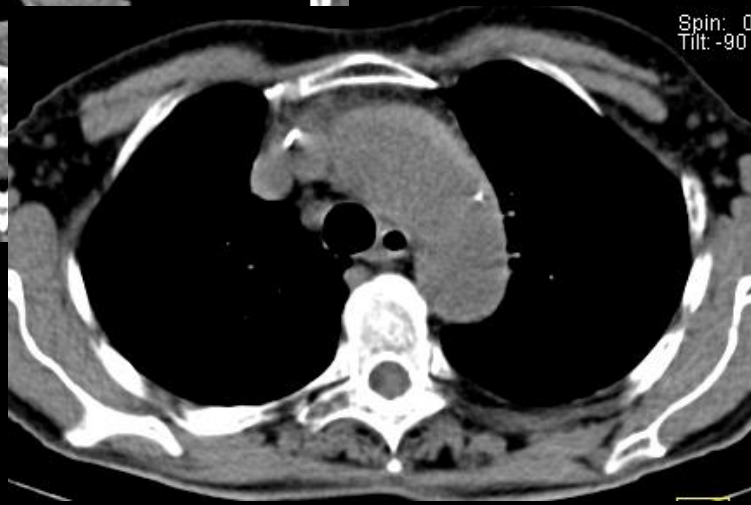
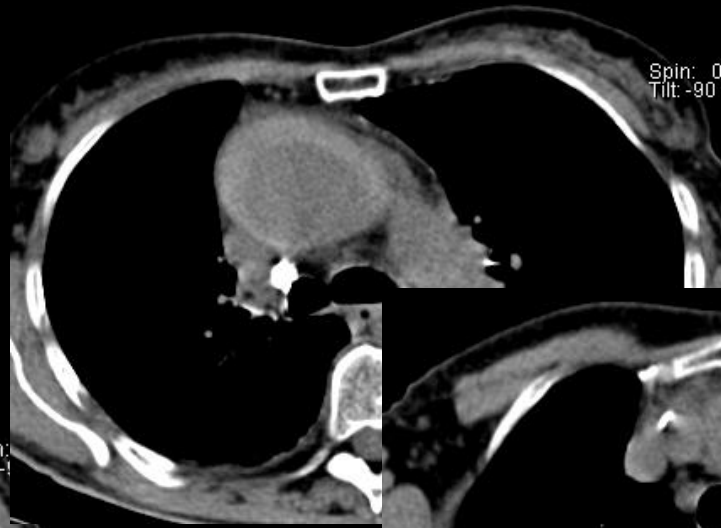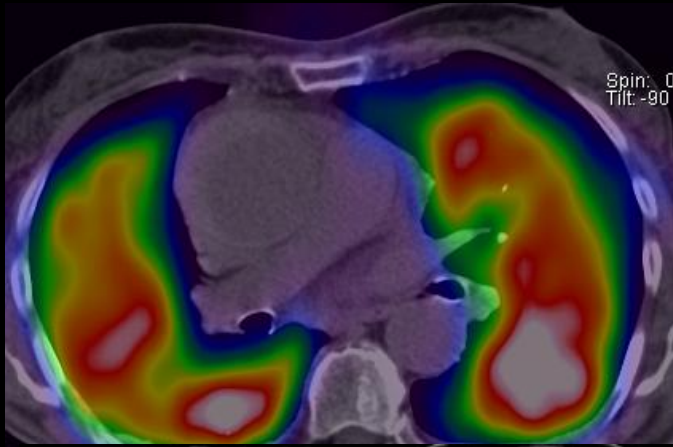
**Envahissement VBC droite**



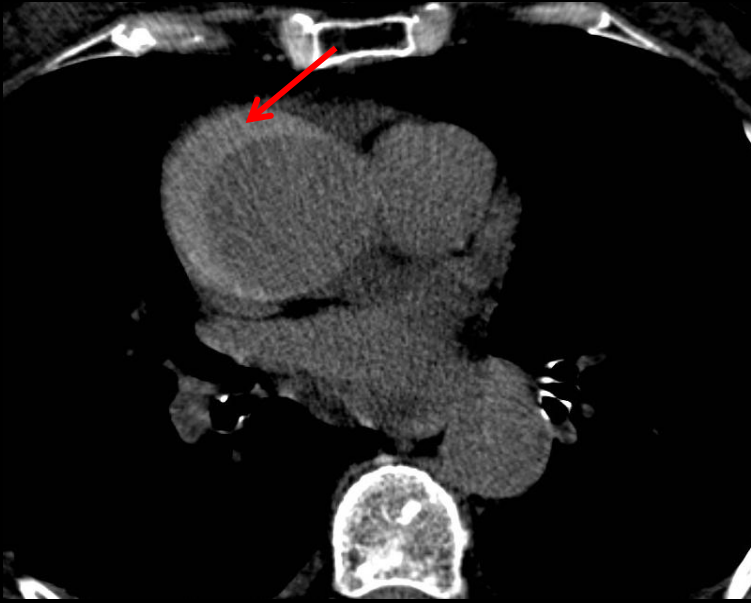**Artère sous clavière droite  
rétrooesophagienne: arteria lusoria**



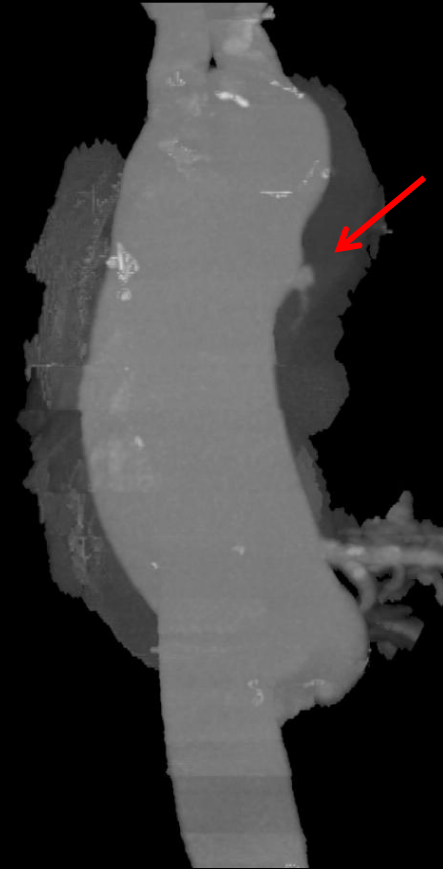
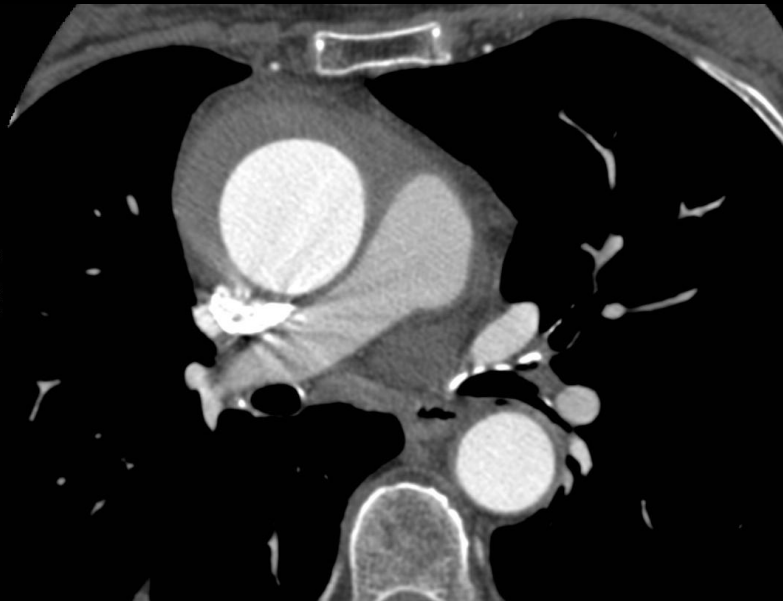
?

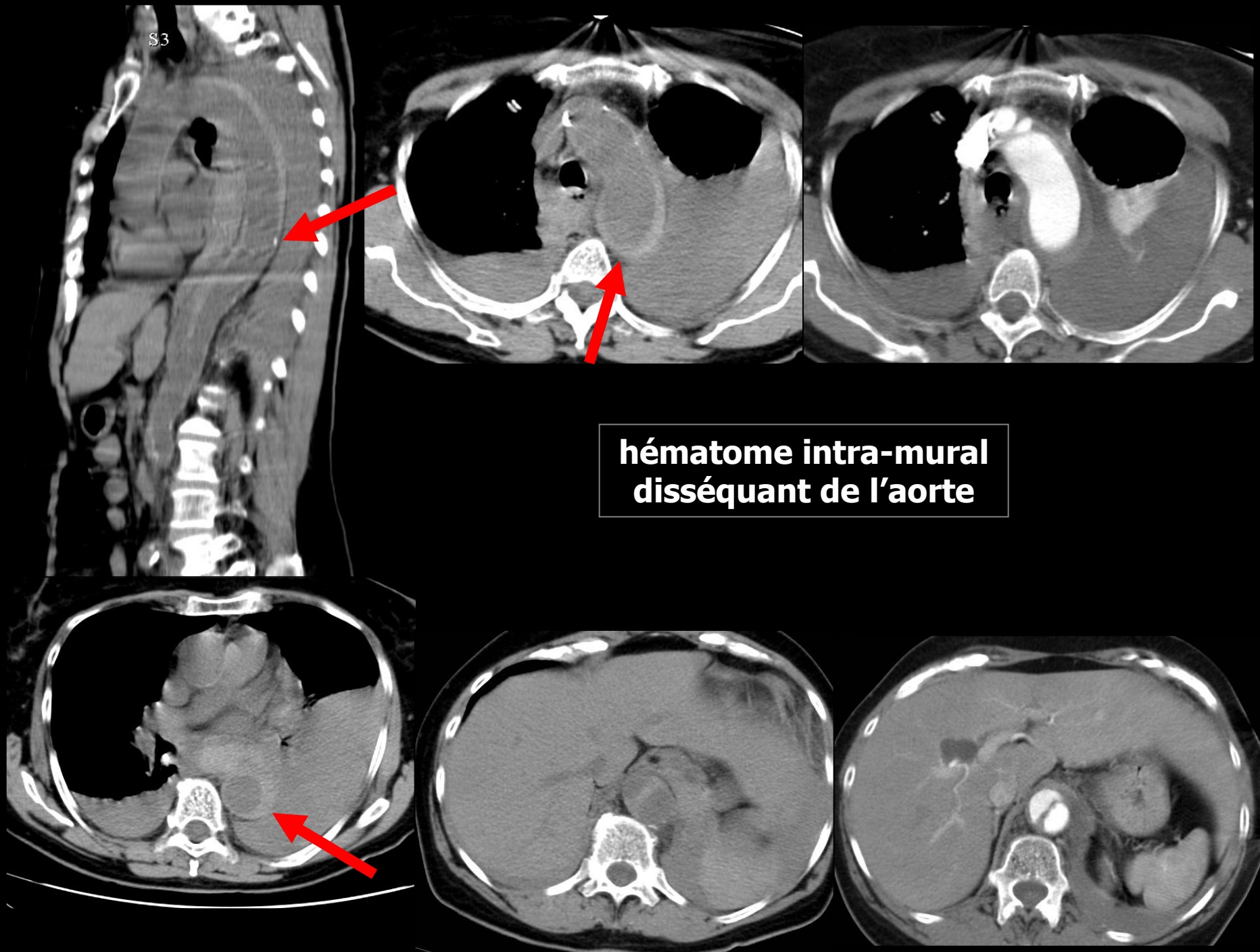


**hématome intra-mural  
disséquant de l'aorte**

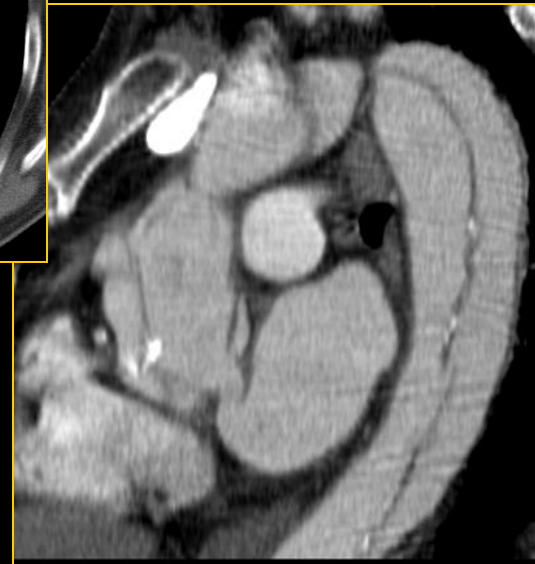
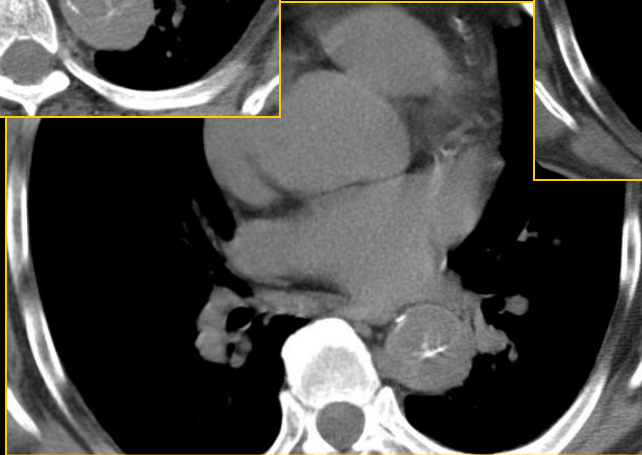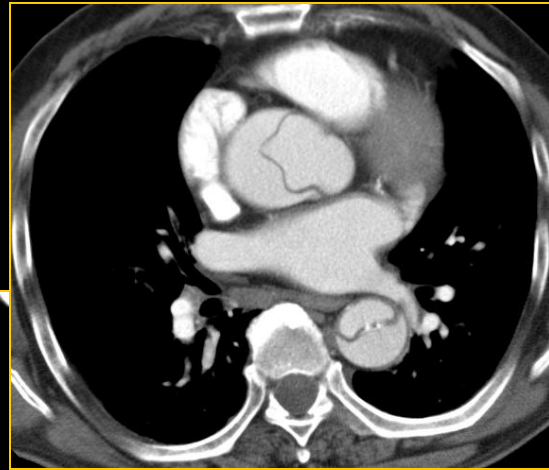
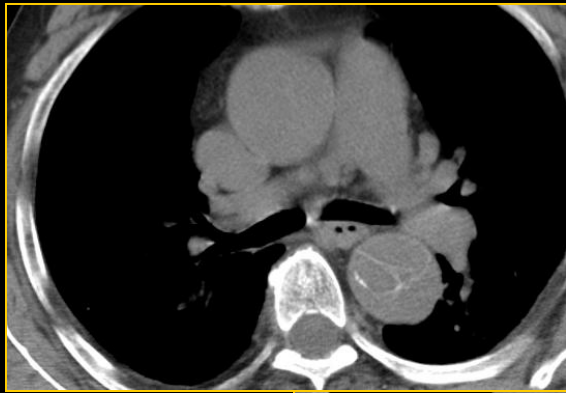
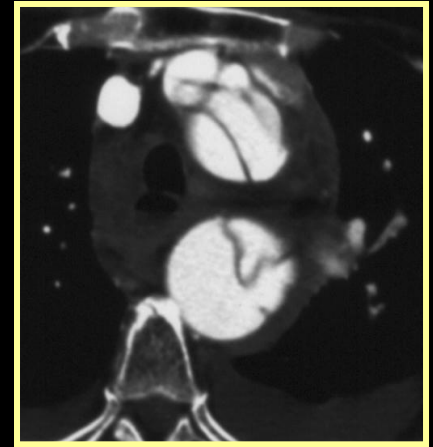
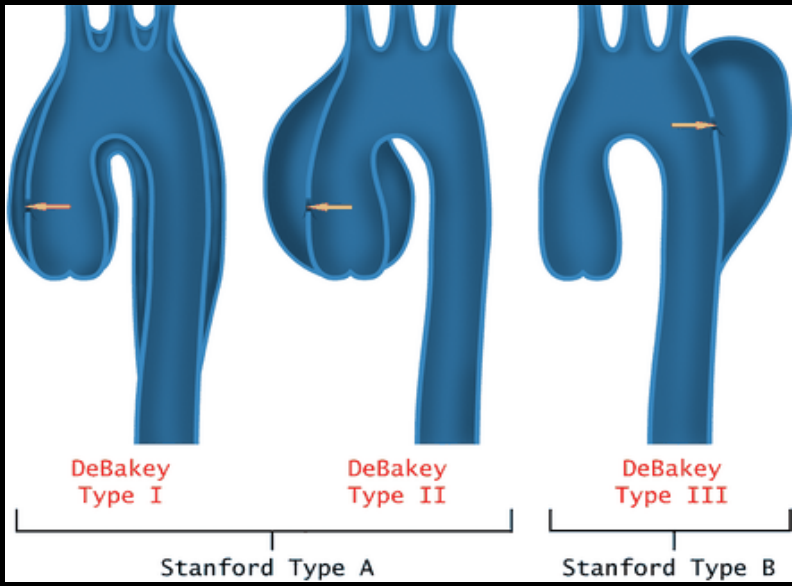


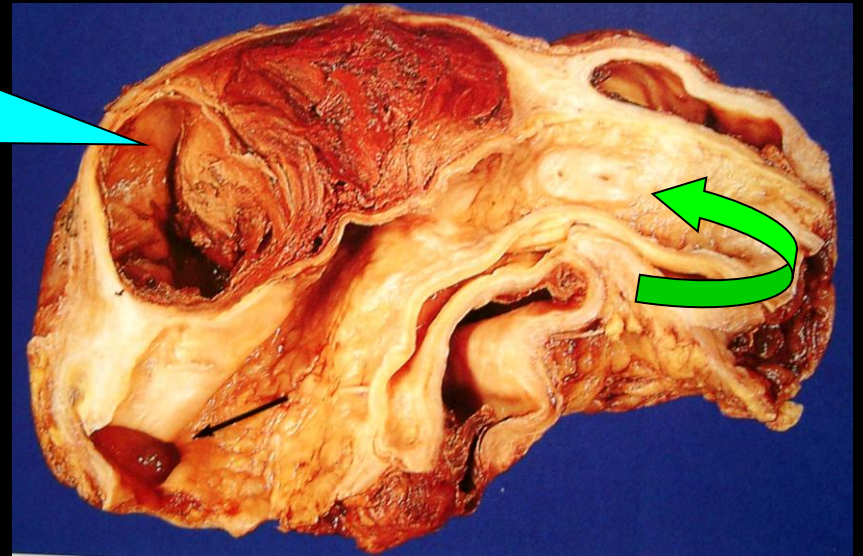
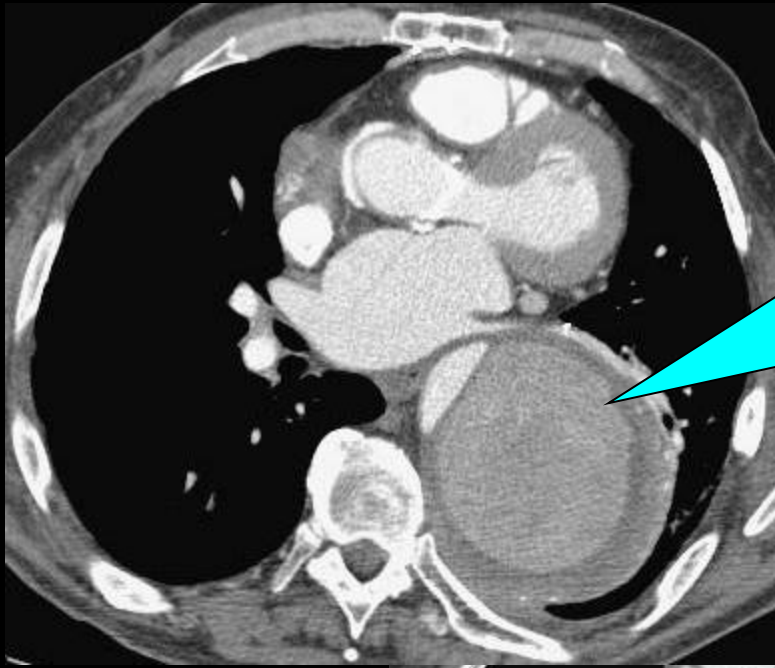
**hématome intra-mural  
disséquant de l'aorte**



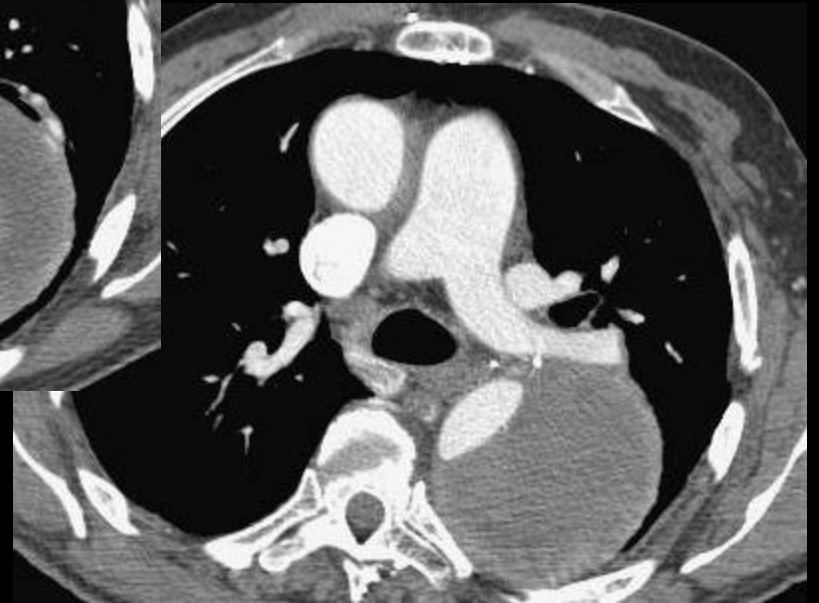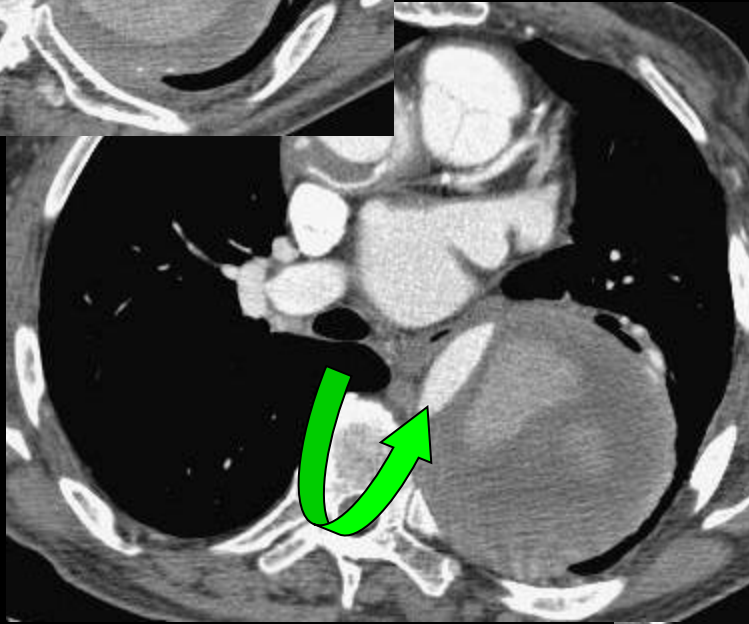


# Dissection aortique aiguë

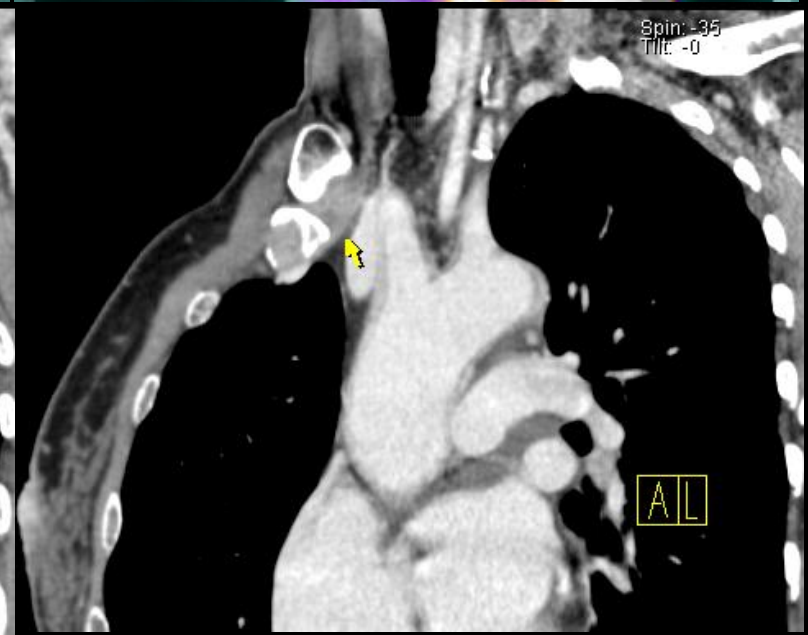
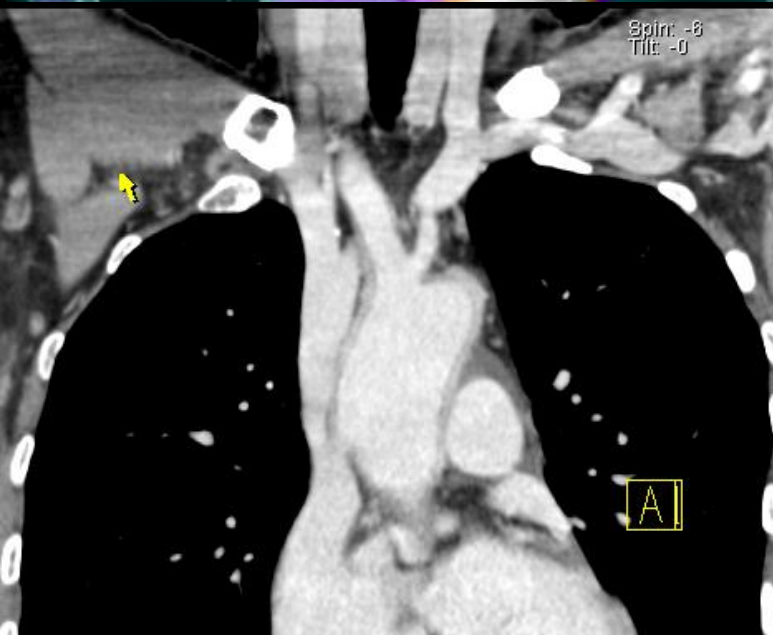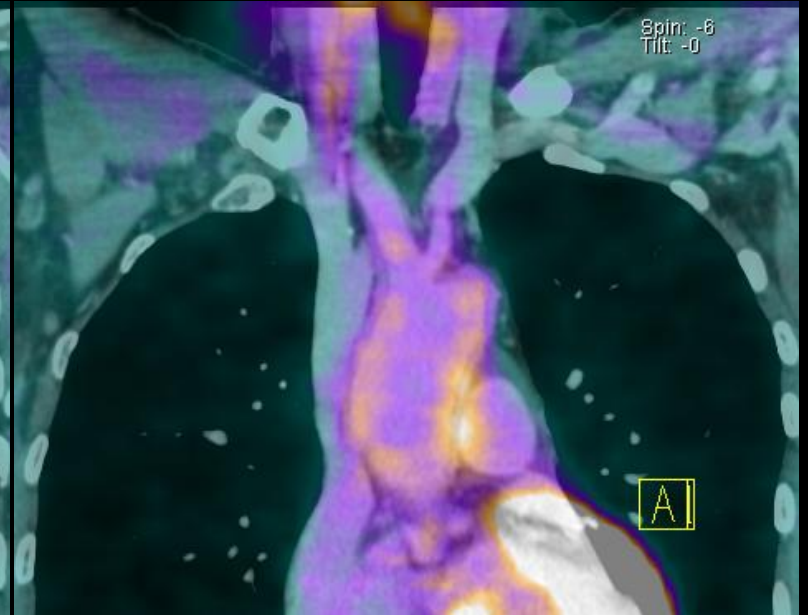

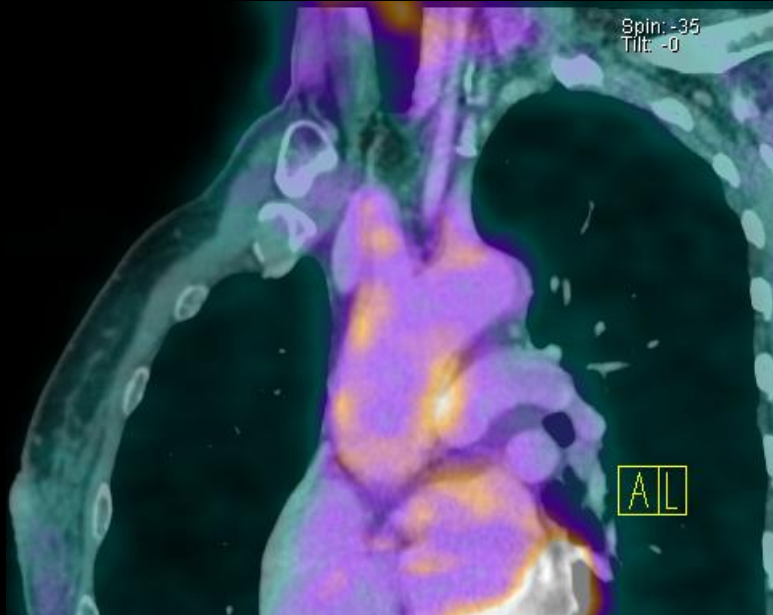


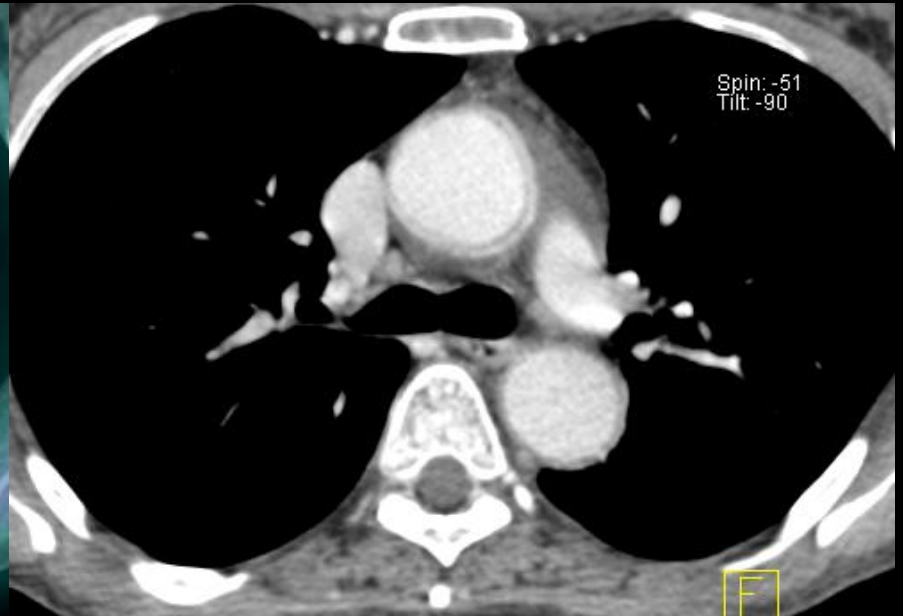
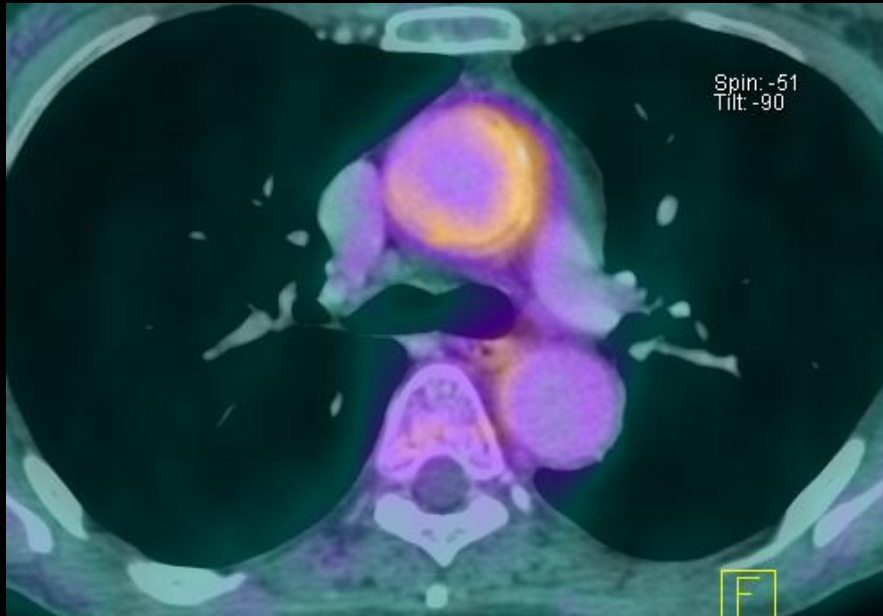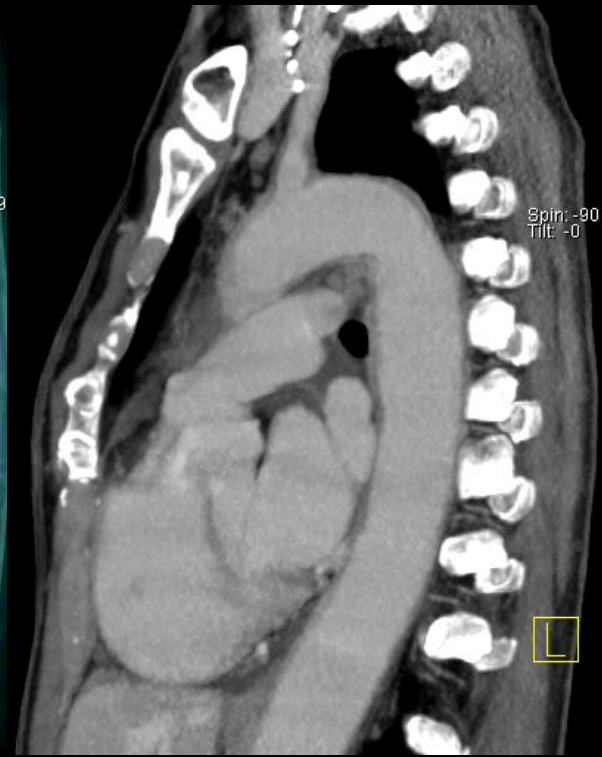
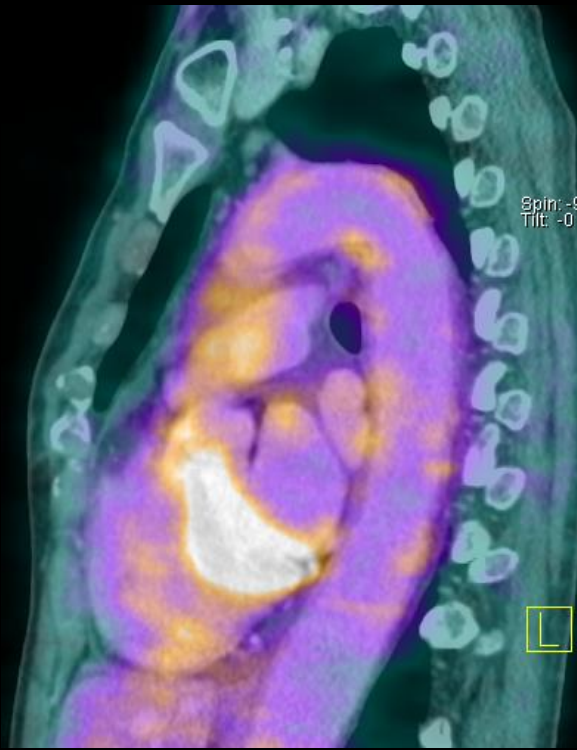
**Dissection aortique et  
dilatation anévrysmale  
du faux chenal**

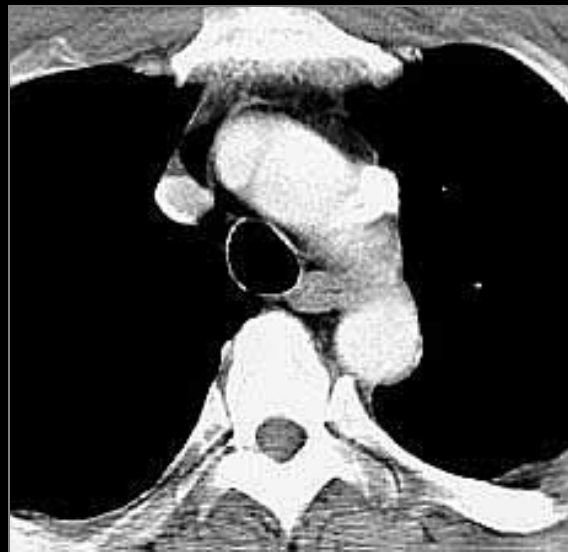
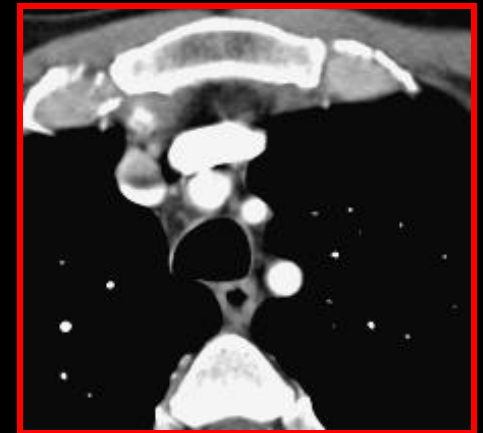
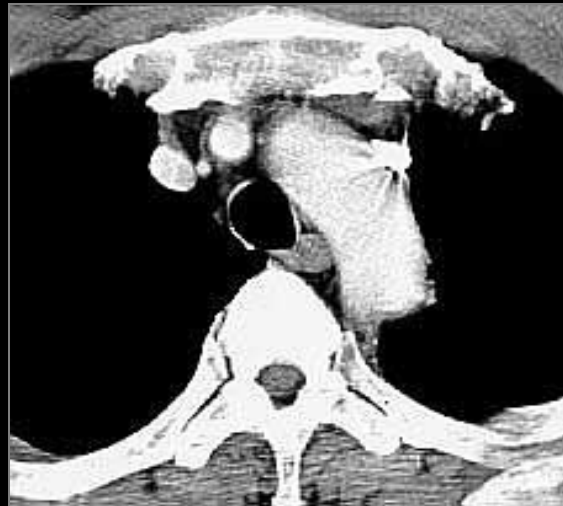
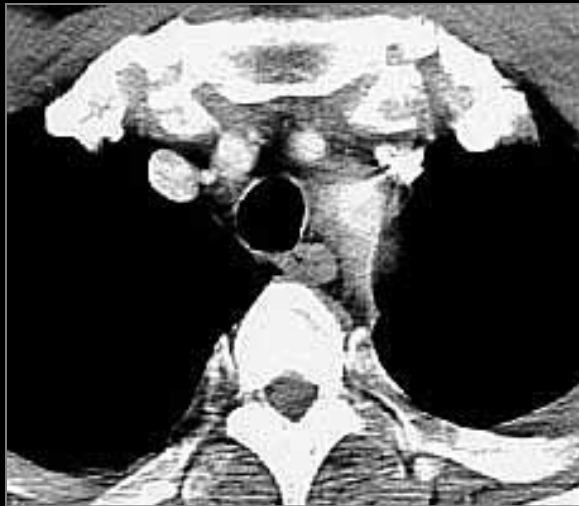

# Aortite (Maladie de Takayashu)

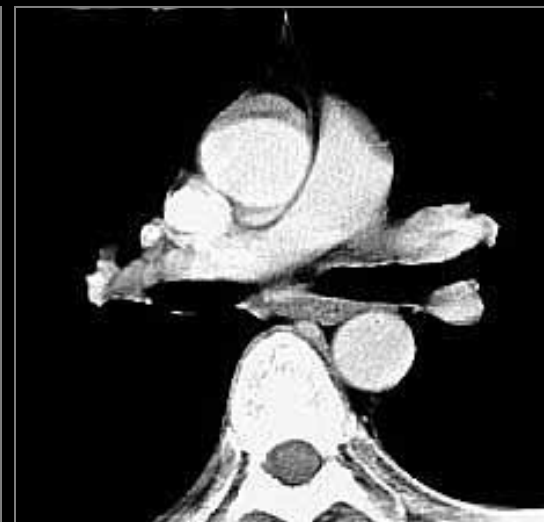
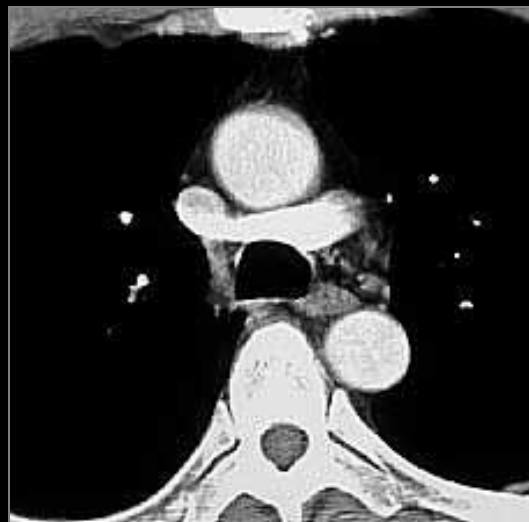
# Aortite (Maladie de Takayashu)

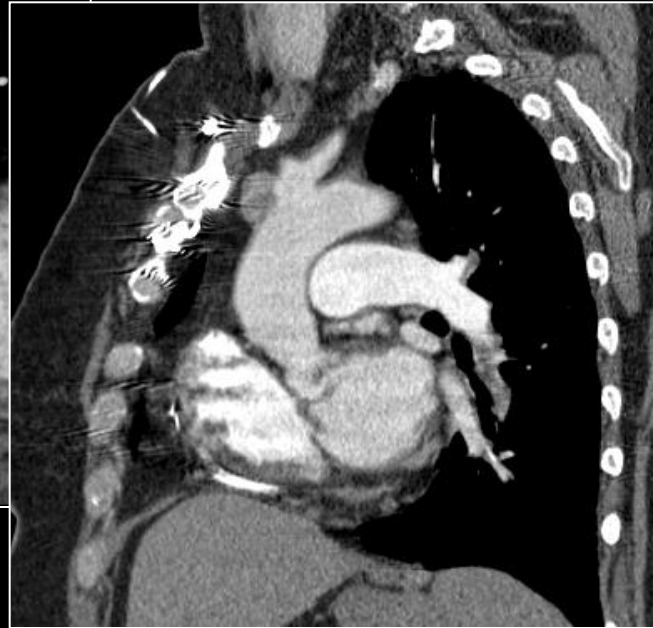
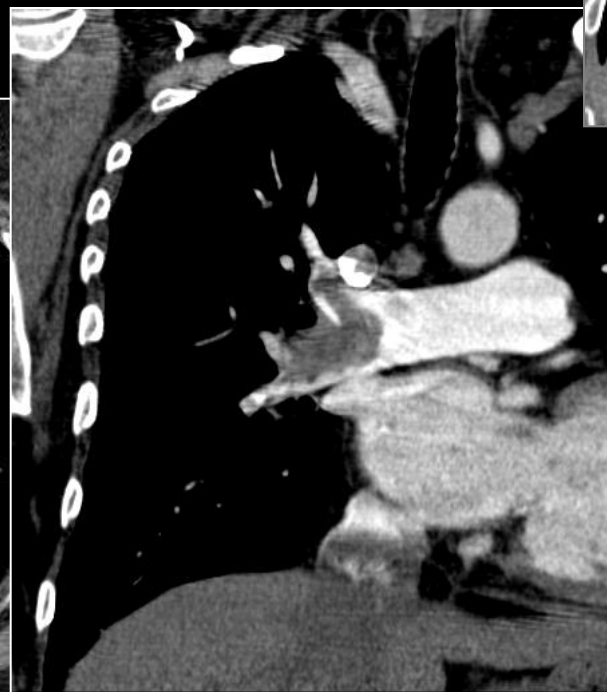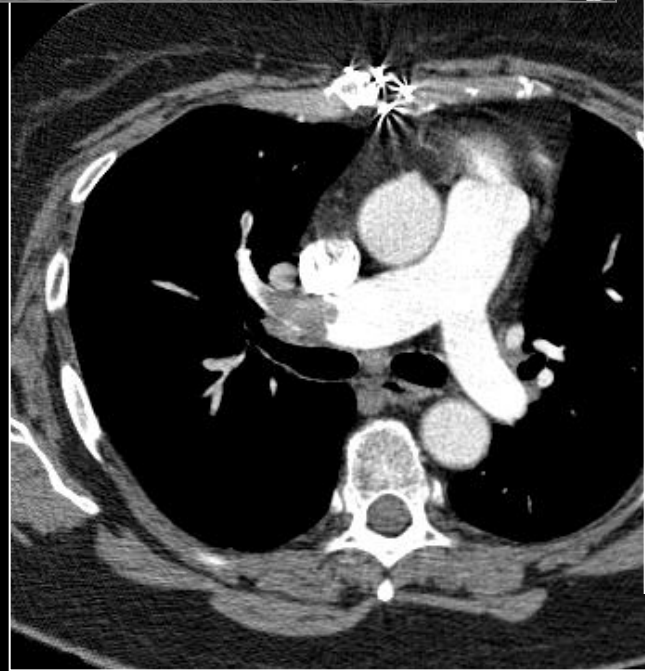

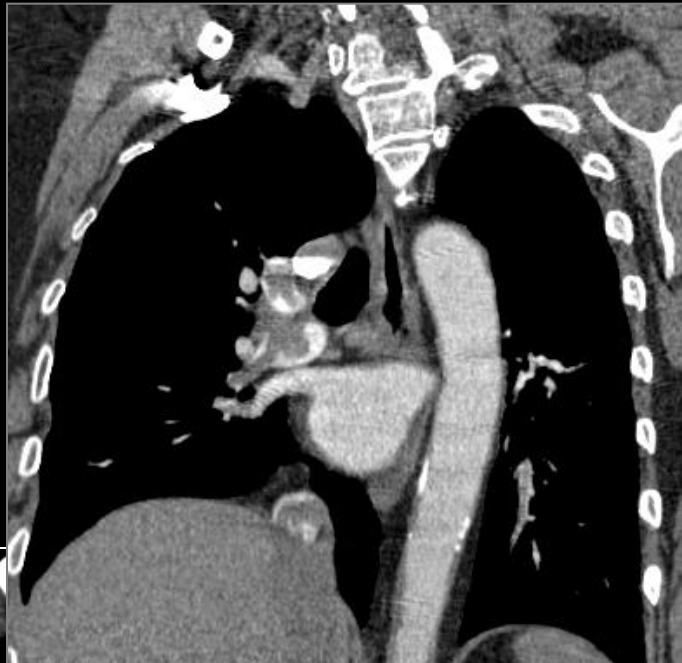
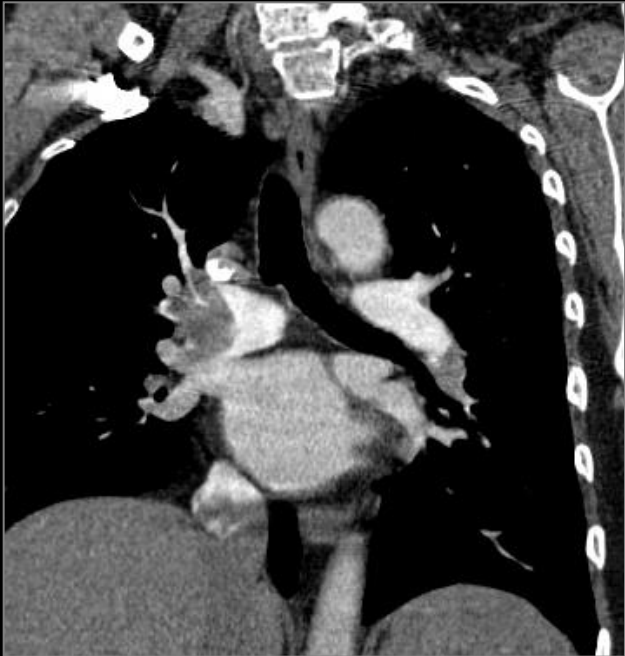

**Veine brachiocéphalique G  
aberrante**



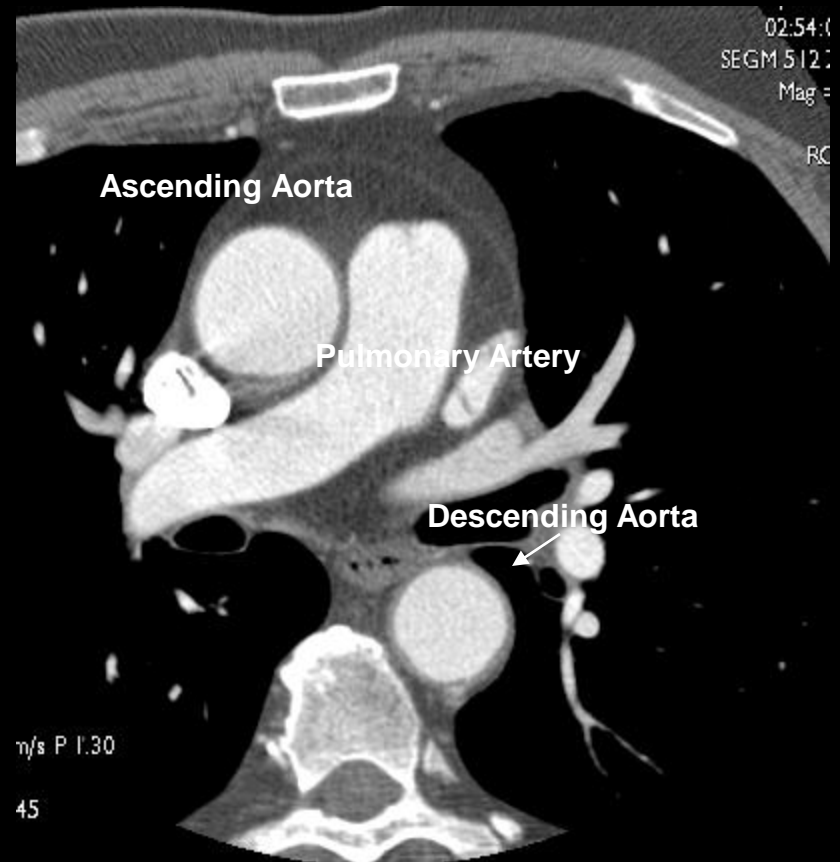
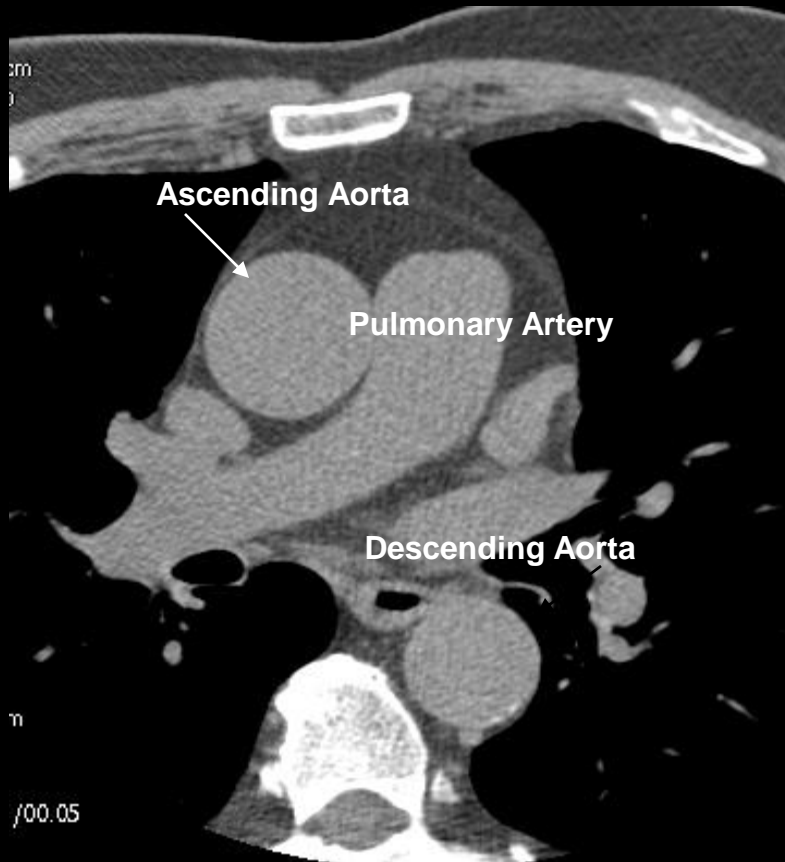
**Artères pulmonaires**  
**Embolie pulmonaire**



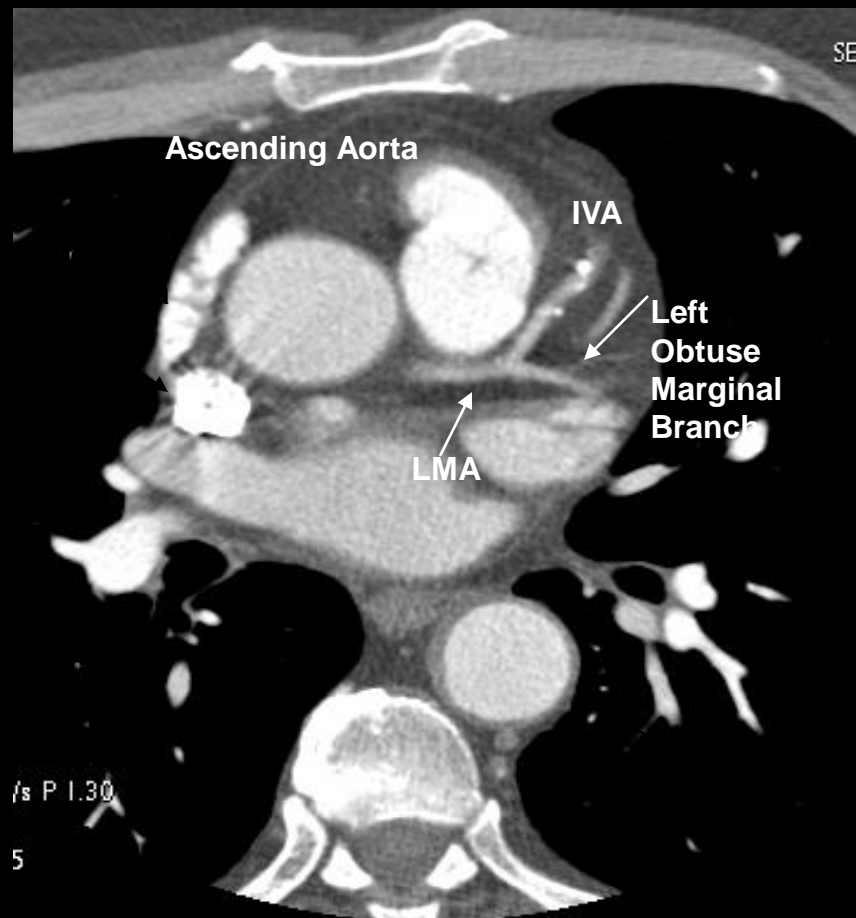
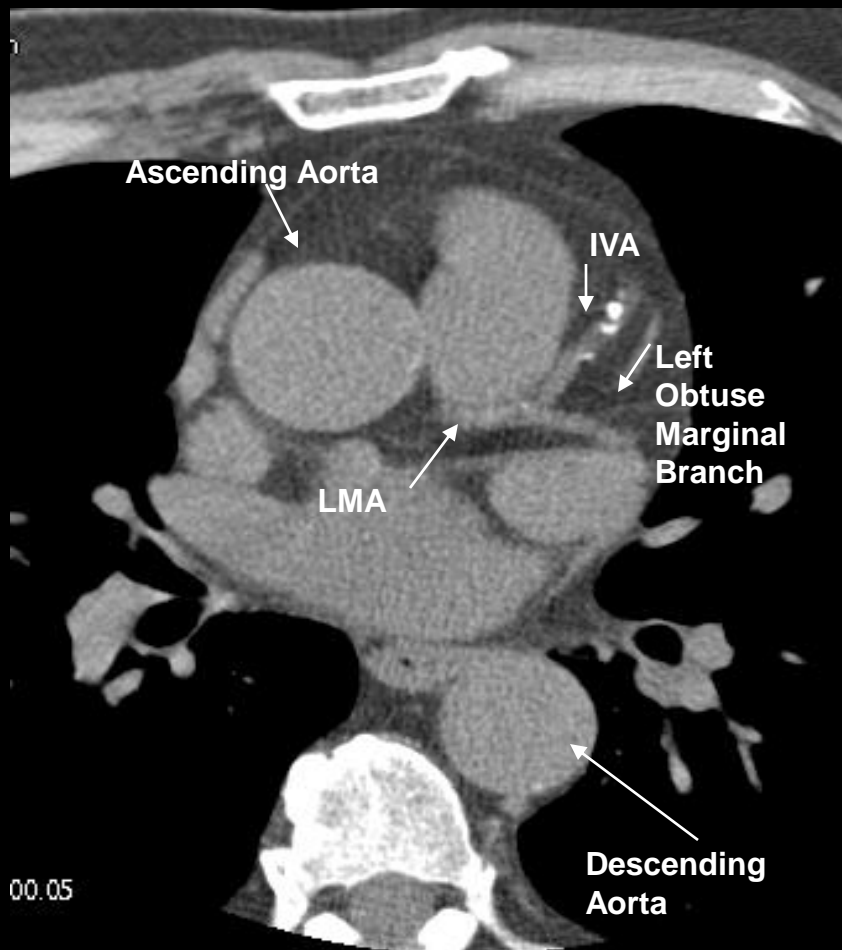


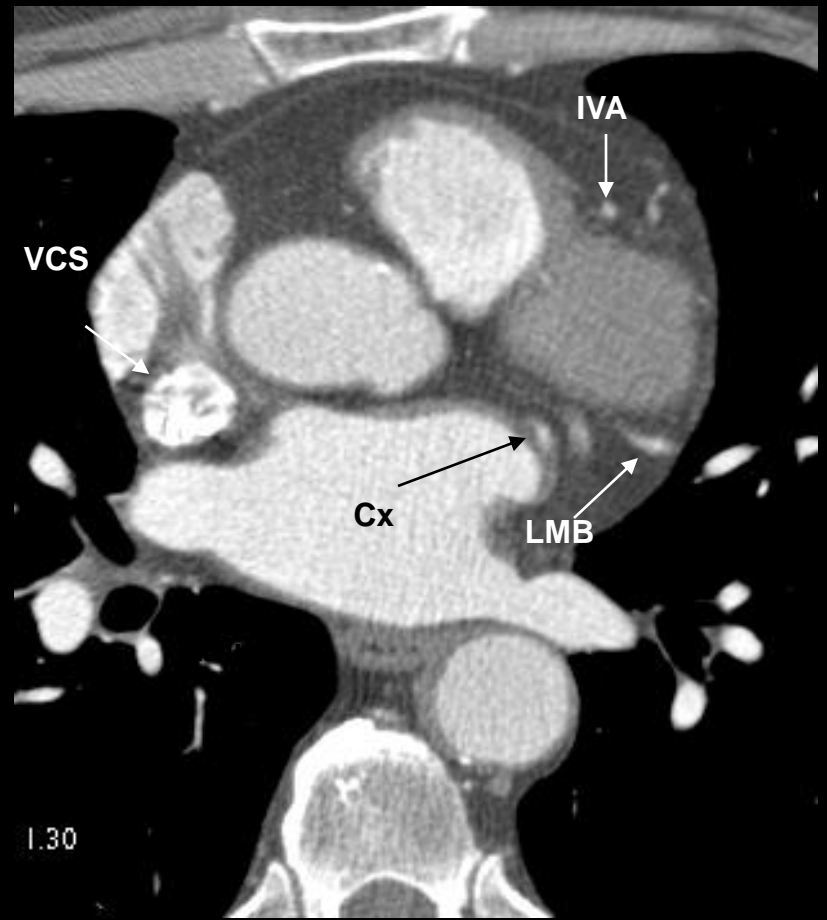
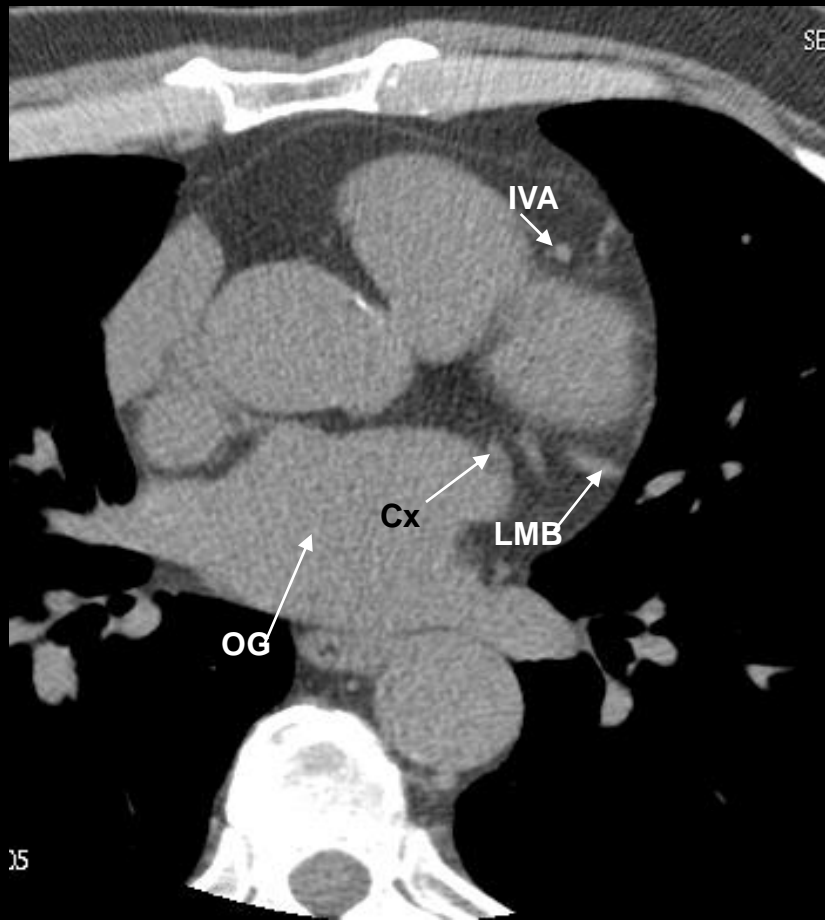
## 2/ RADIOANATOMIE DU MEDIASTIN

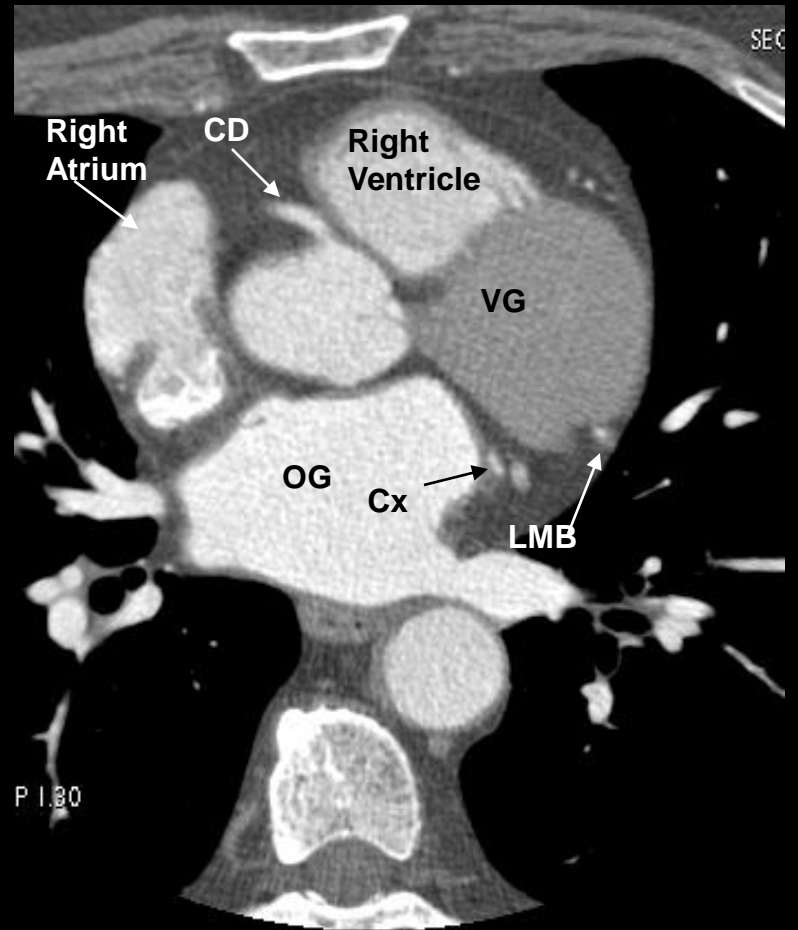
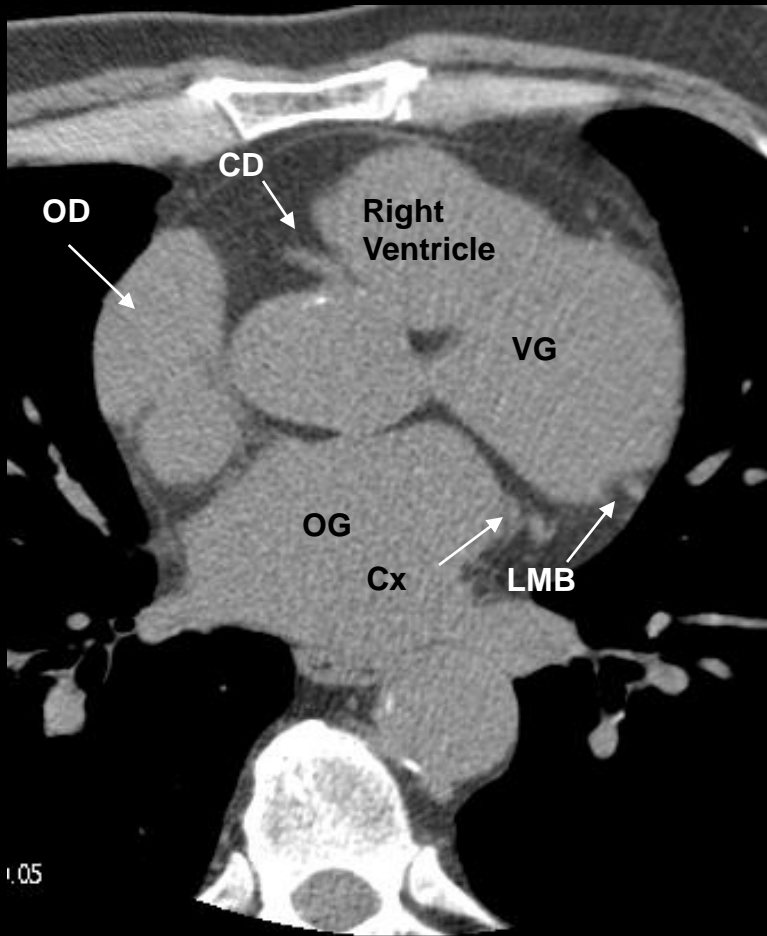
- **VAISSEAUX**
- **CŒUR**
- **ŒSOPHAGE**
- **CHAINES GANGLIONNAIRES**

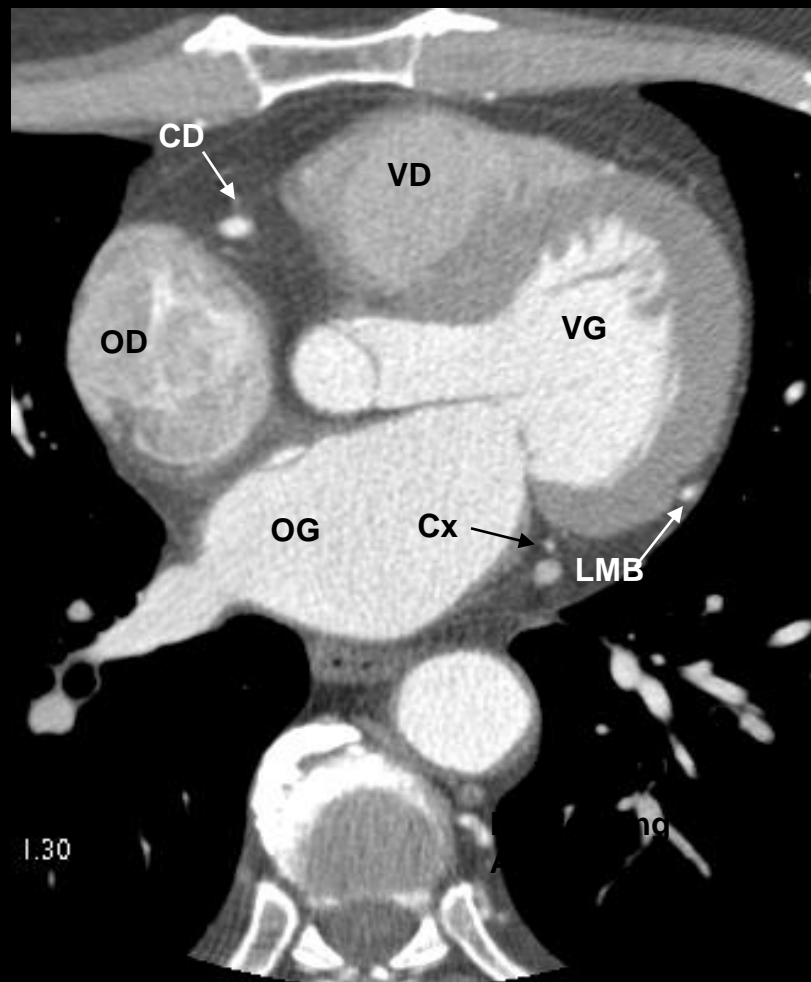
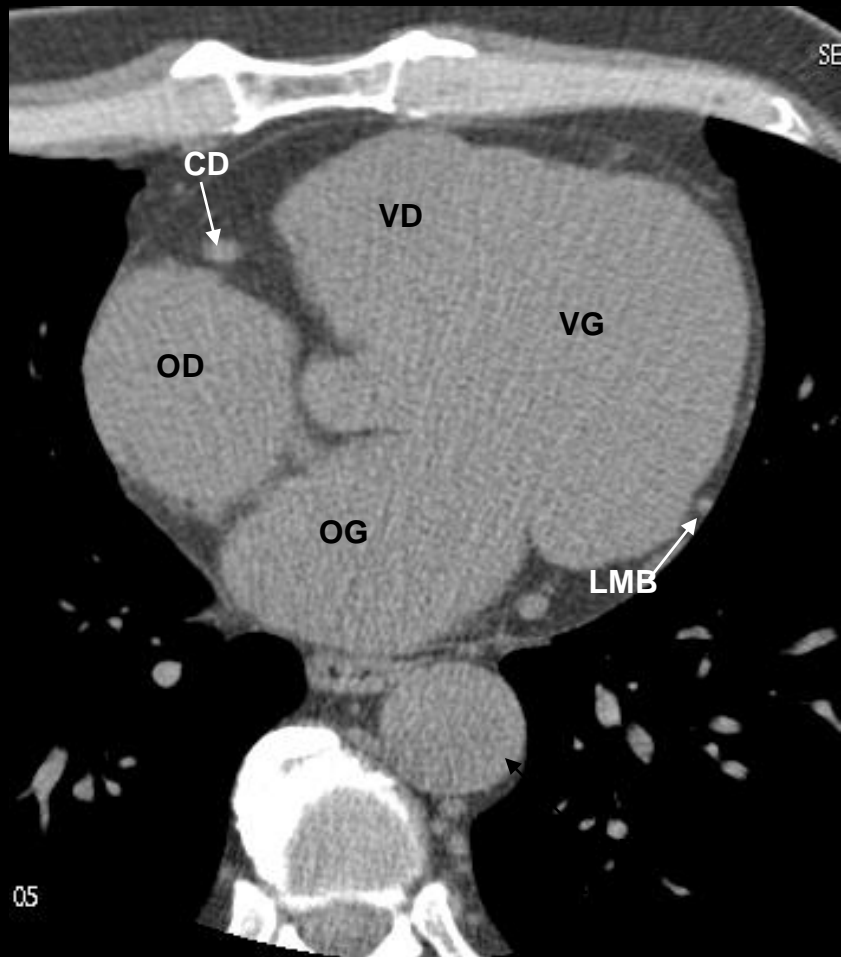


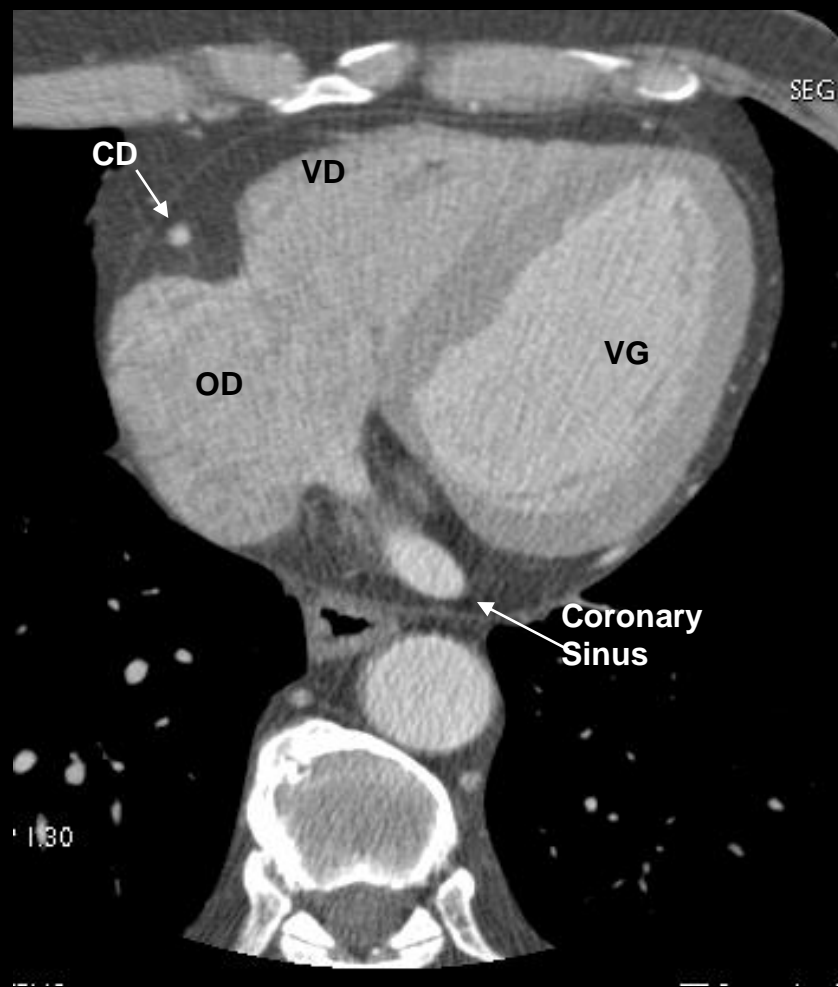
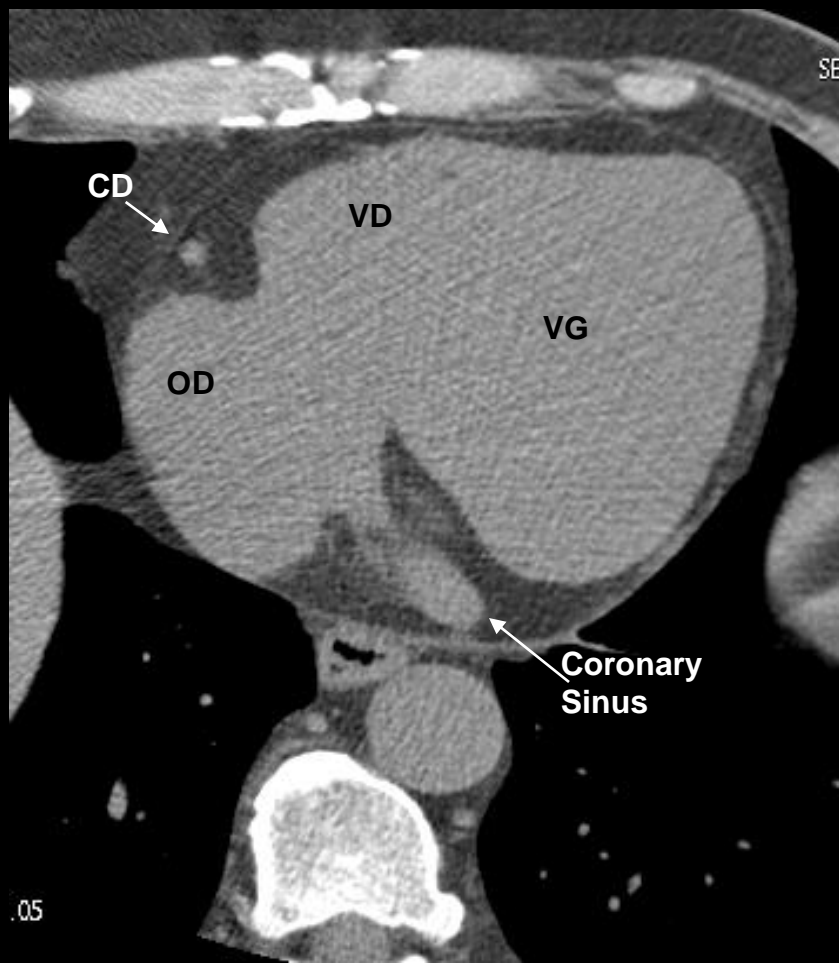
**LMA - Left Main Artery (tronc commun)**  
**LAD - Left Anterior Descending Artery (inter ventriculaire IVA)**  
**LCX - Left Circumflex Artery (circonflexe)**  
**LMB - Left Obtuse Marginal Branch (branche marginale gauche)**  
**RCA - Right Coronary Artery (coronaire droite)**  
**PDA - Posterior Descending Artery (rétro ventriculaire postérieure)**

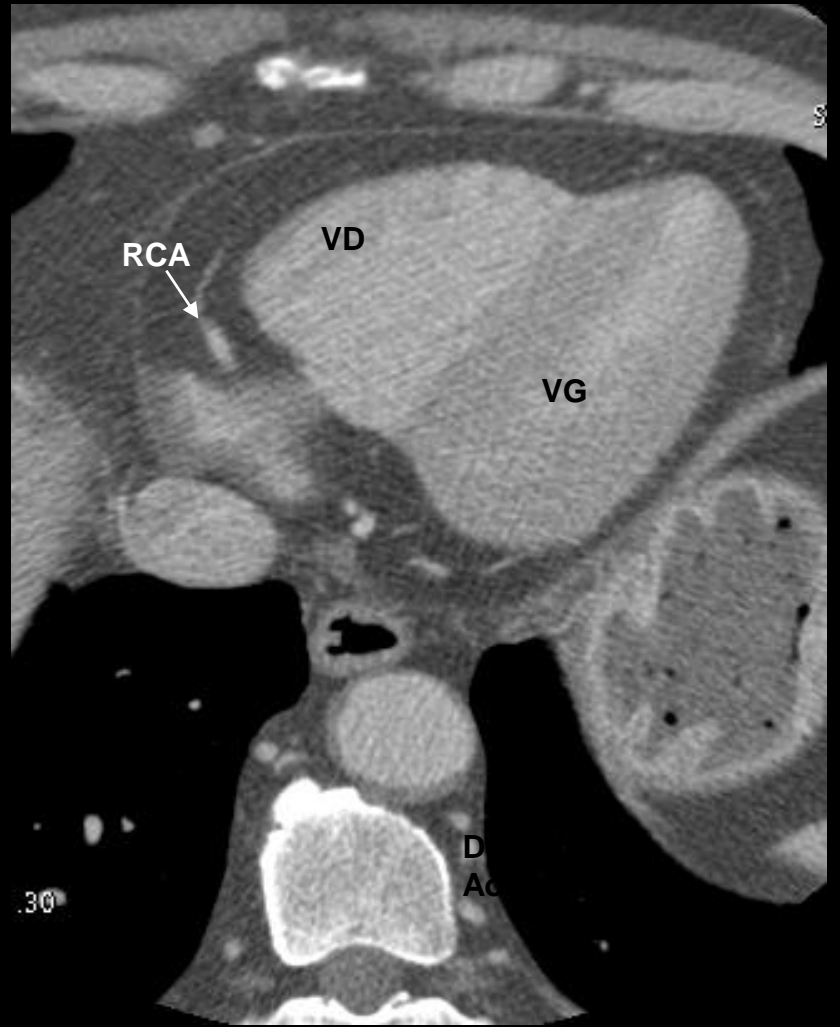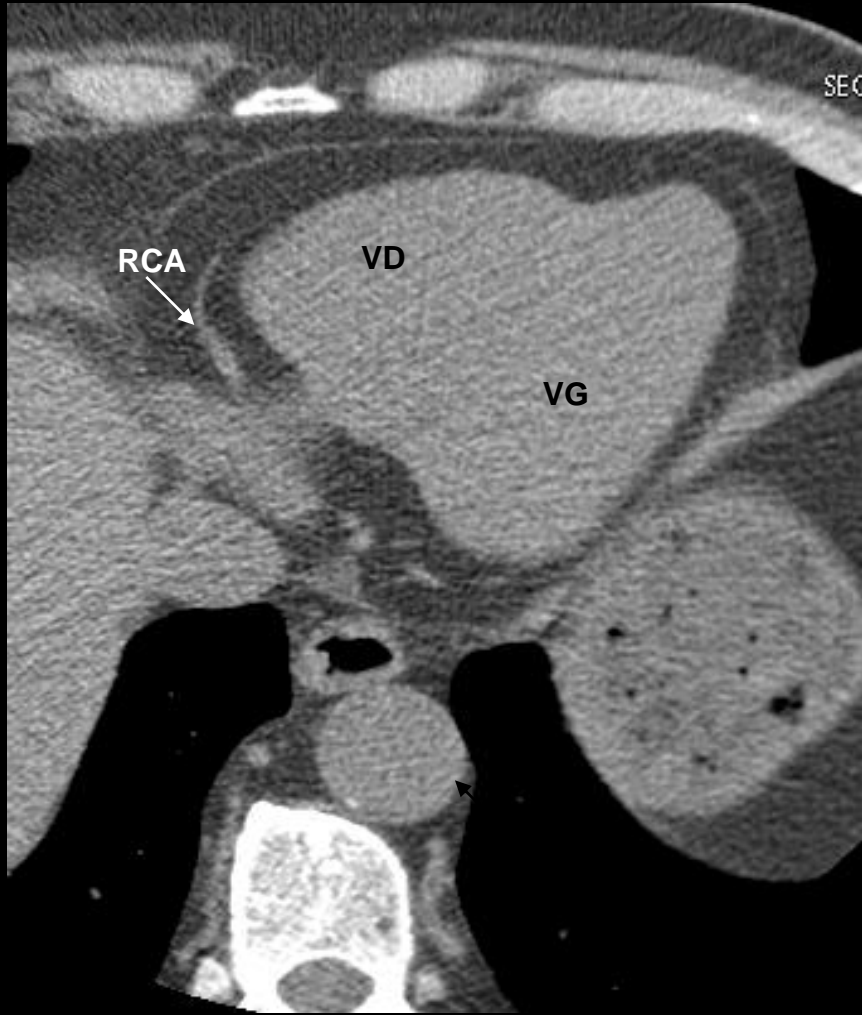


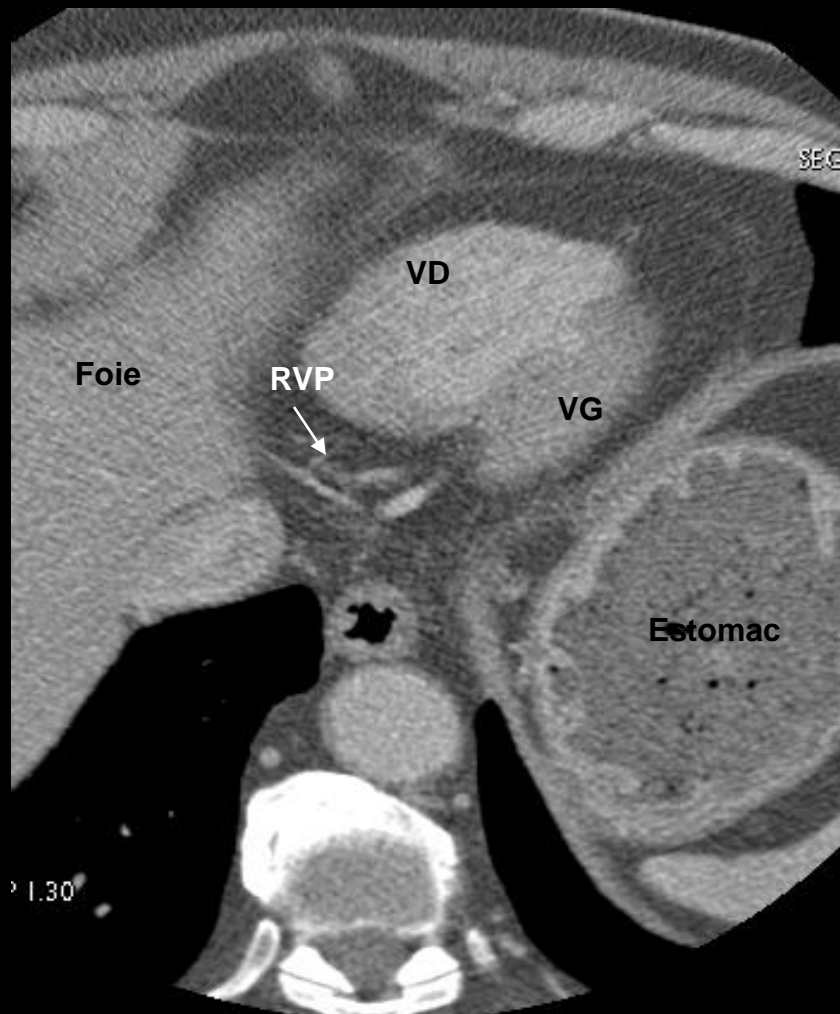

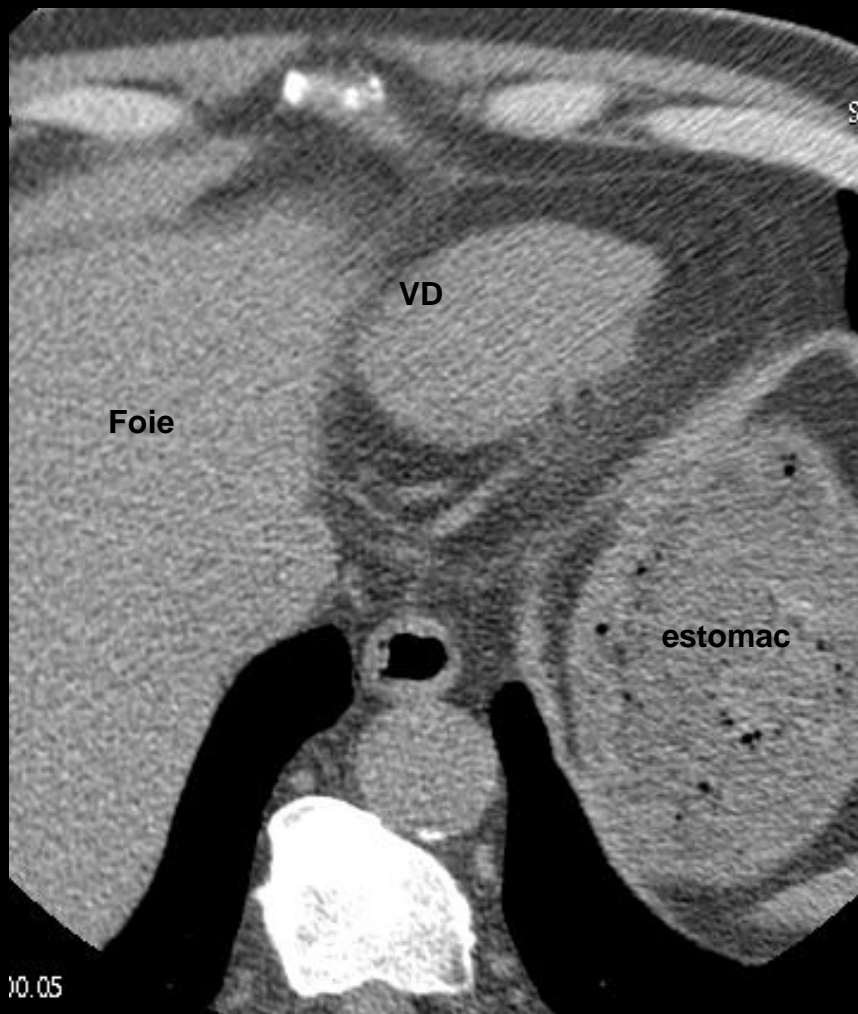


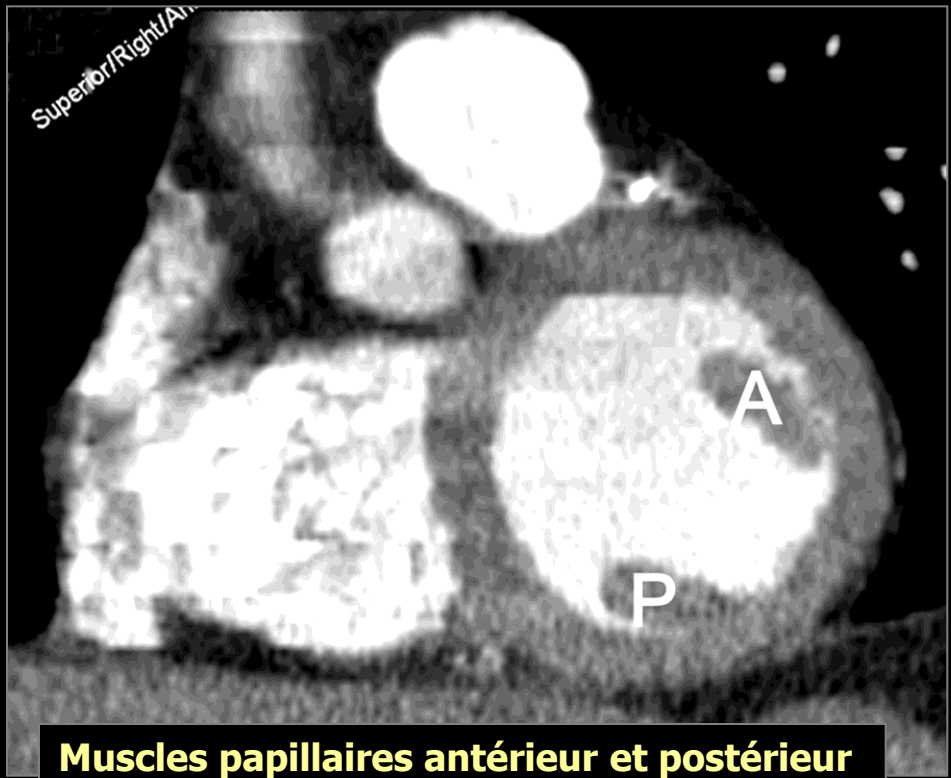


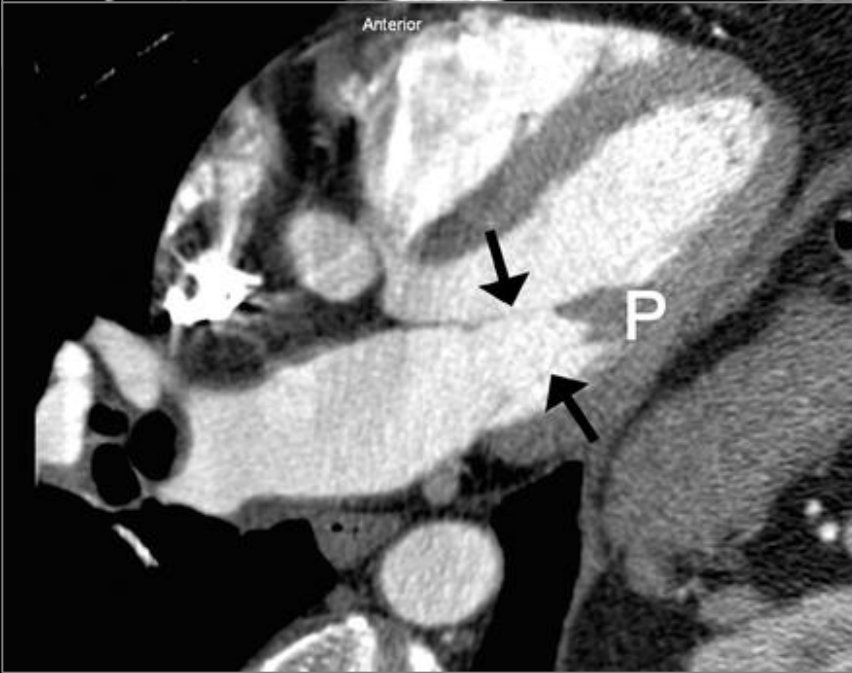
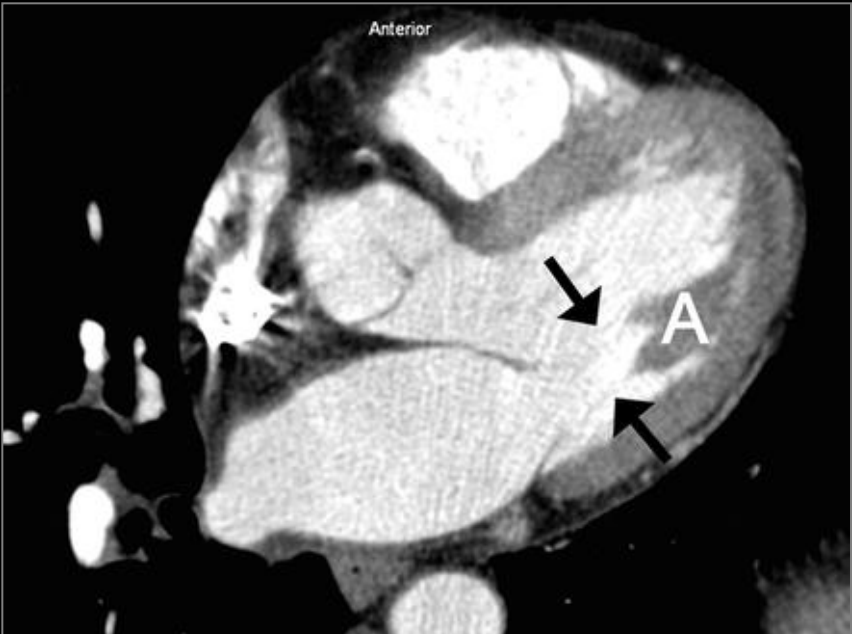
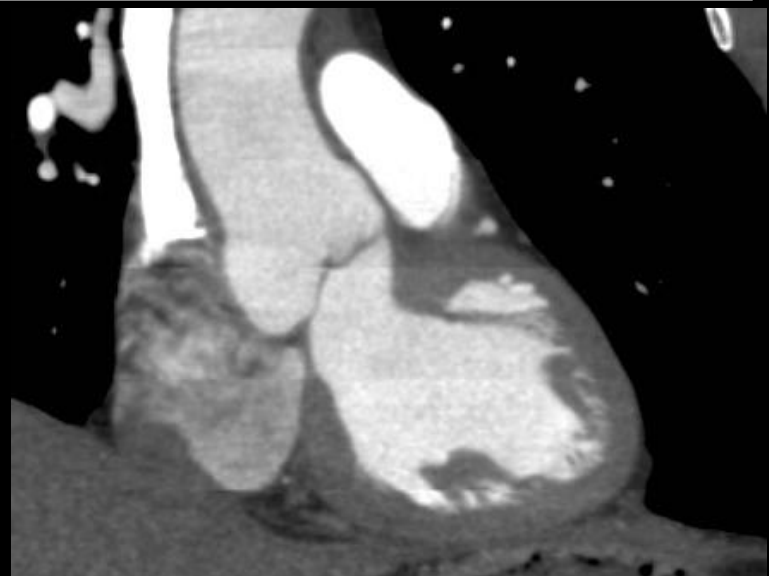




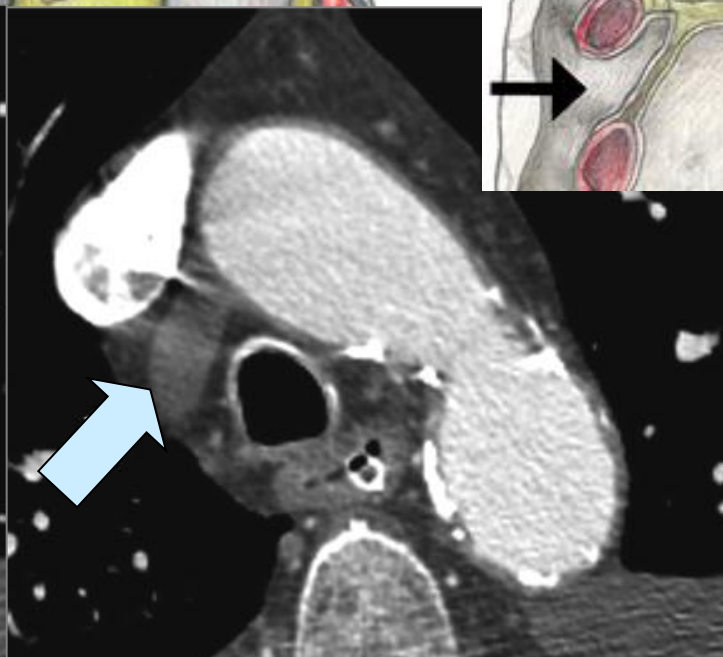
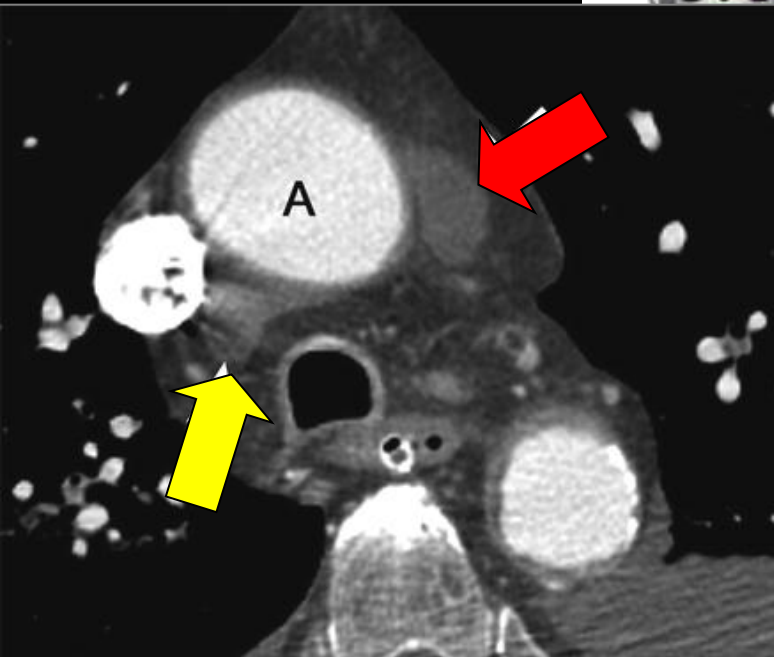
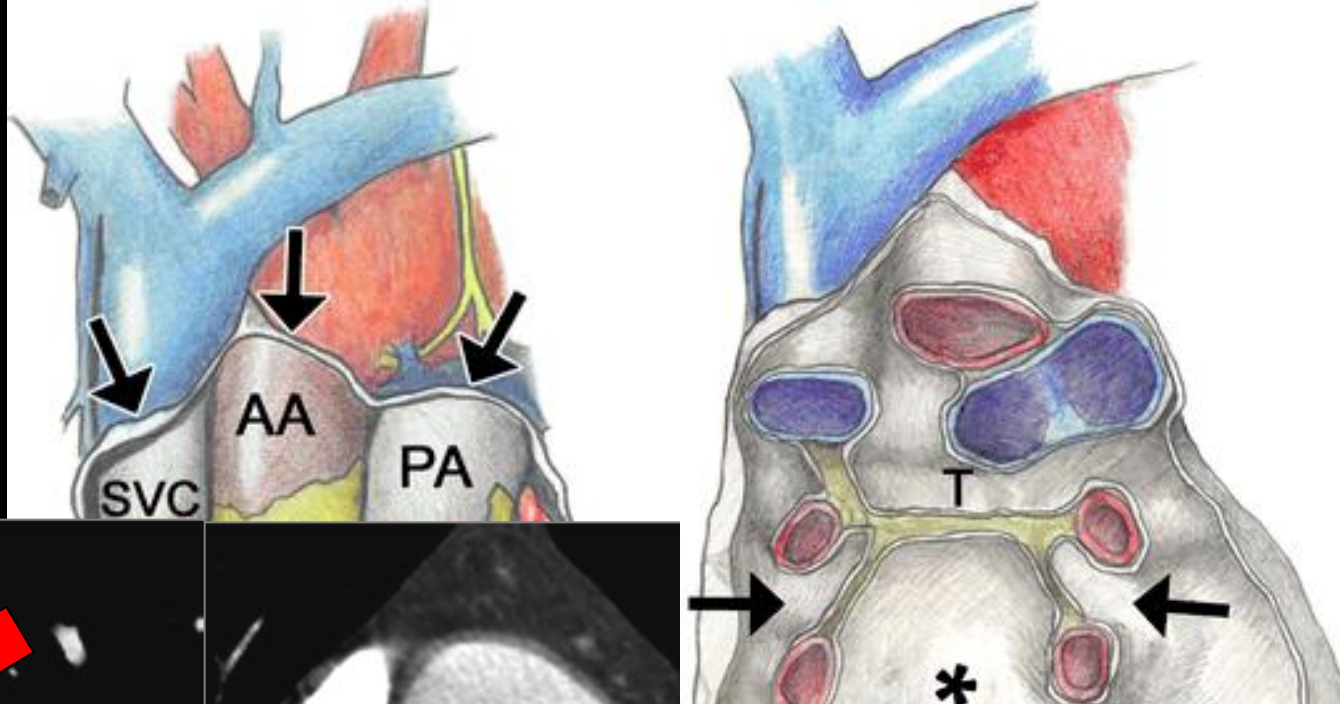
# Ventricules



**Muscles papillaires antérieur et postérieur  
Et cordages mitraux**



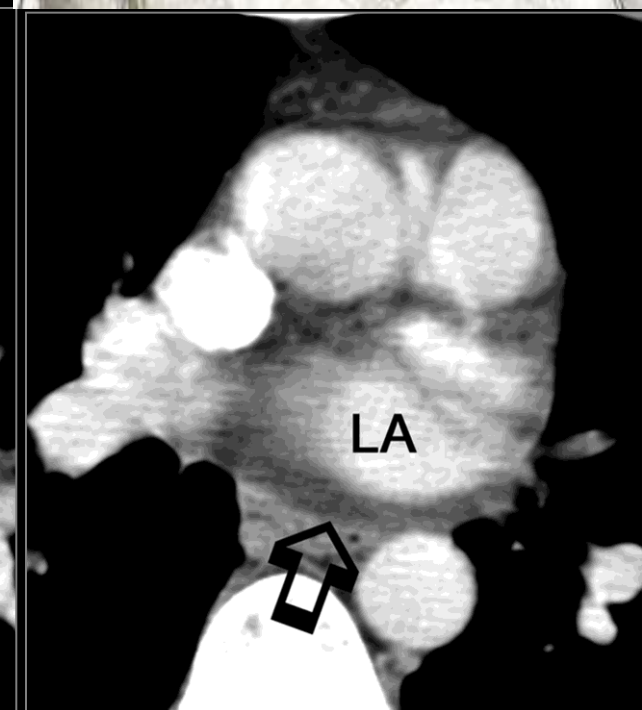
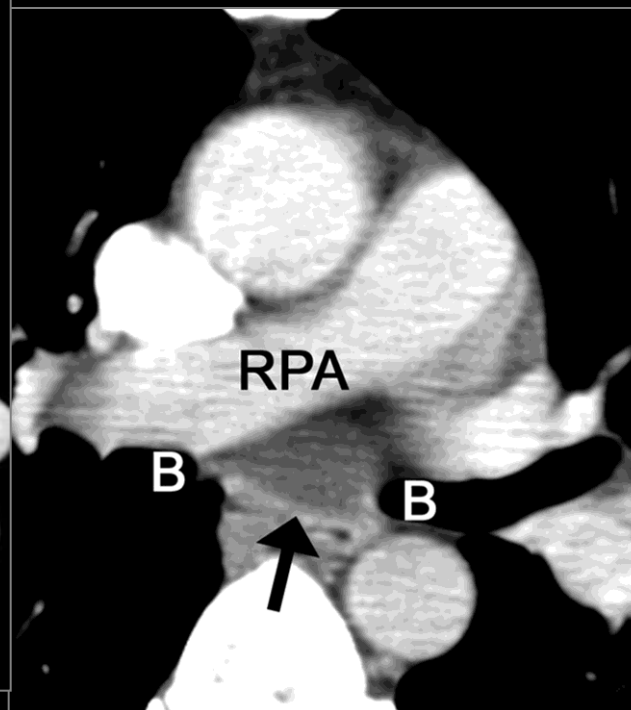
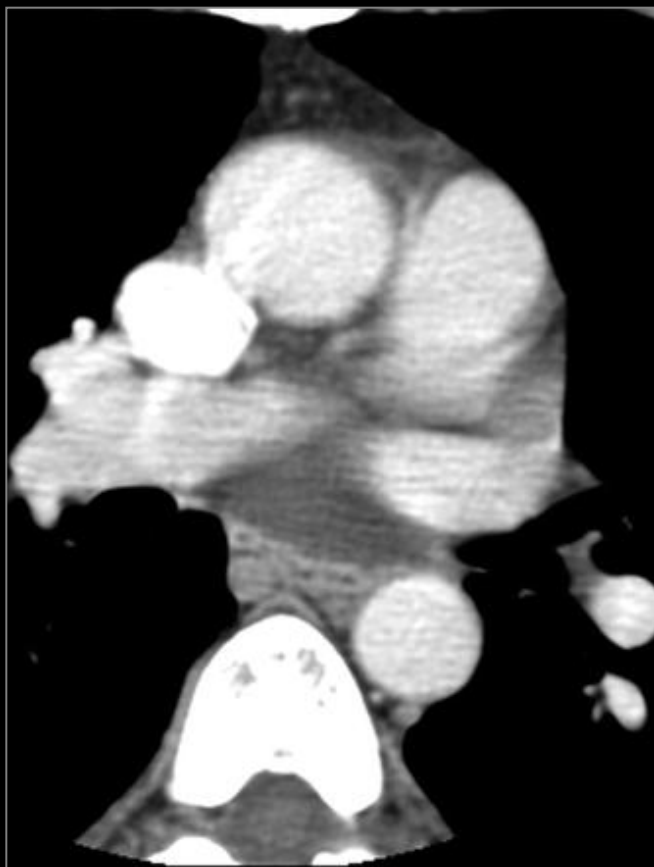
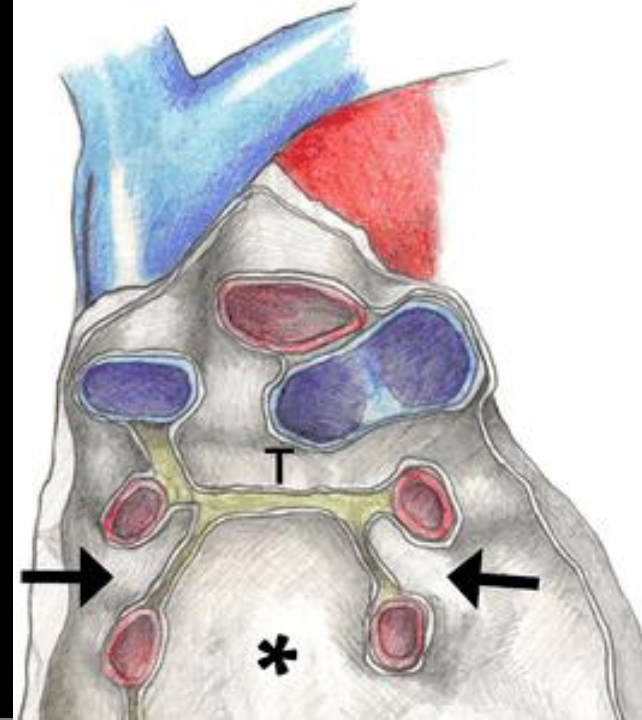
## Recessus péricardiques

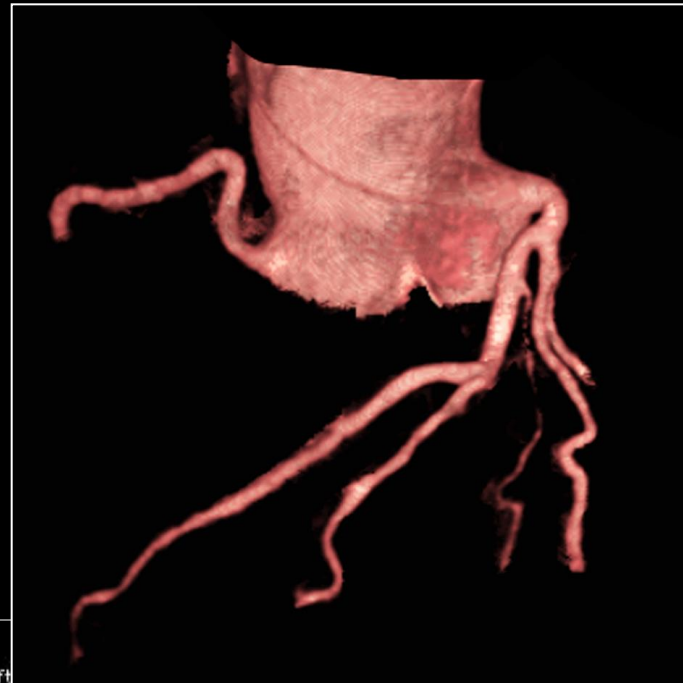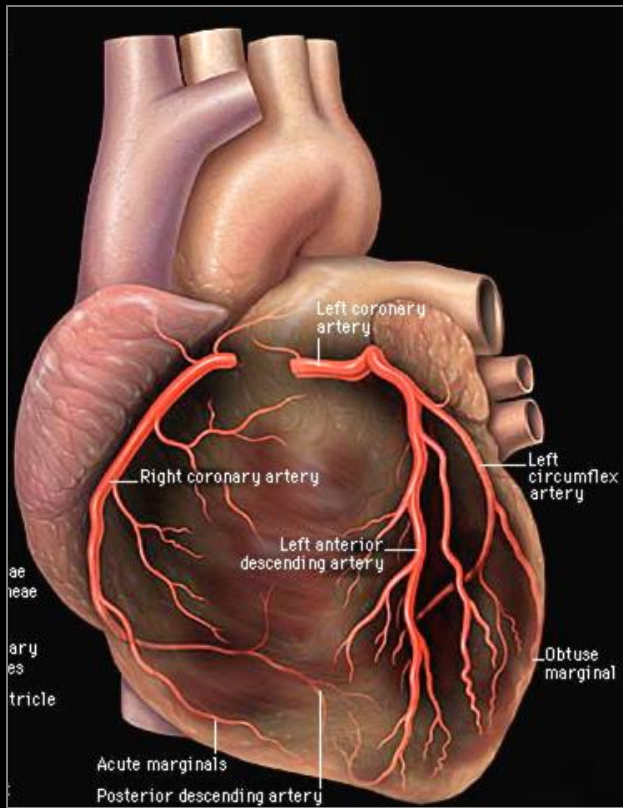


**Recessus péricardique aortique supérieur**  
provient du sinus transverse  
s'étend à la face antérieure de l'aorte ascendante avec des portions  
**antérieure, postérieure** et latérale droite

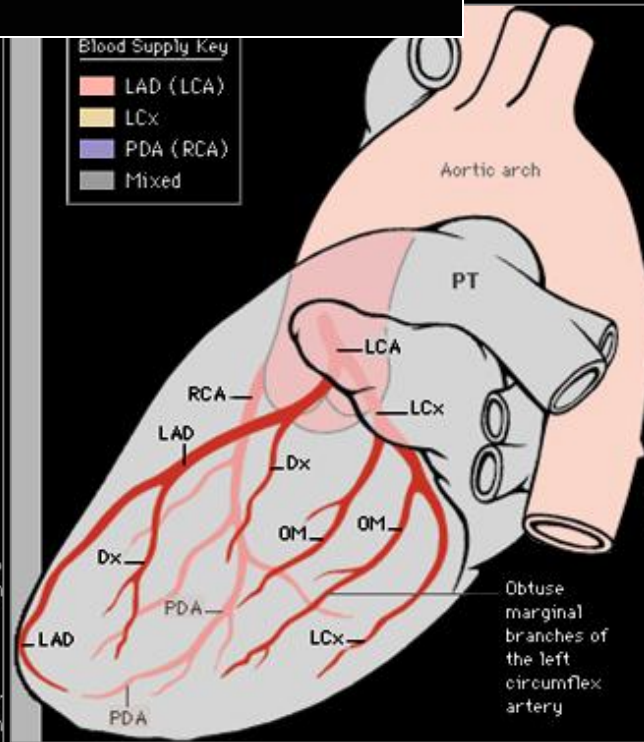
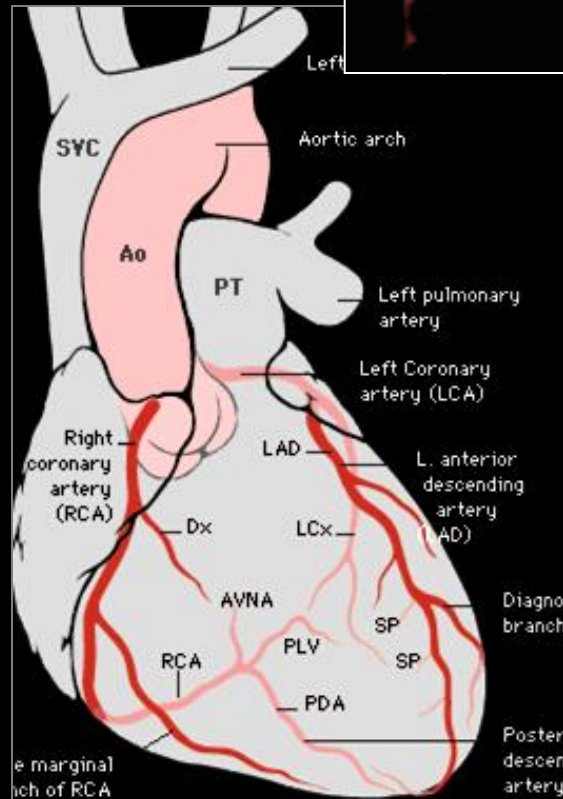
## Recessus péricardique postérieur

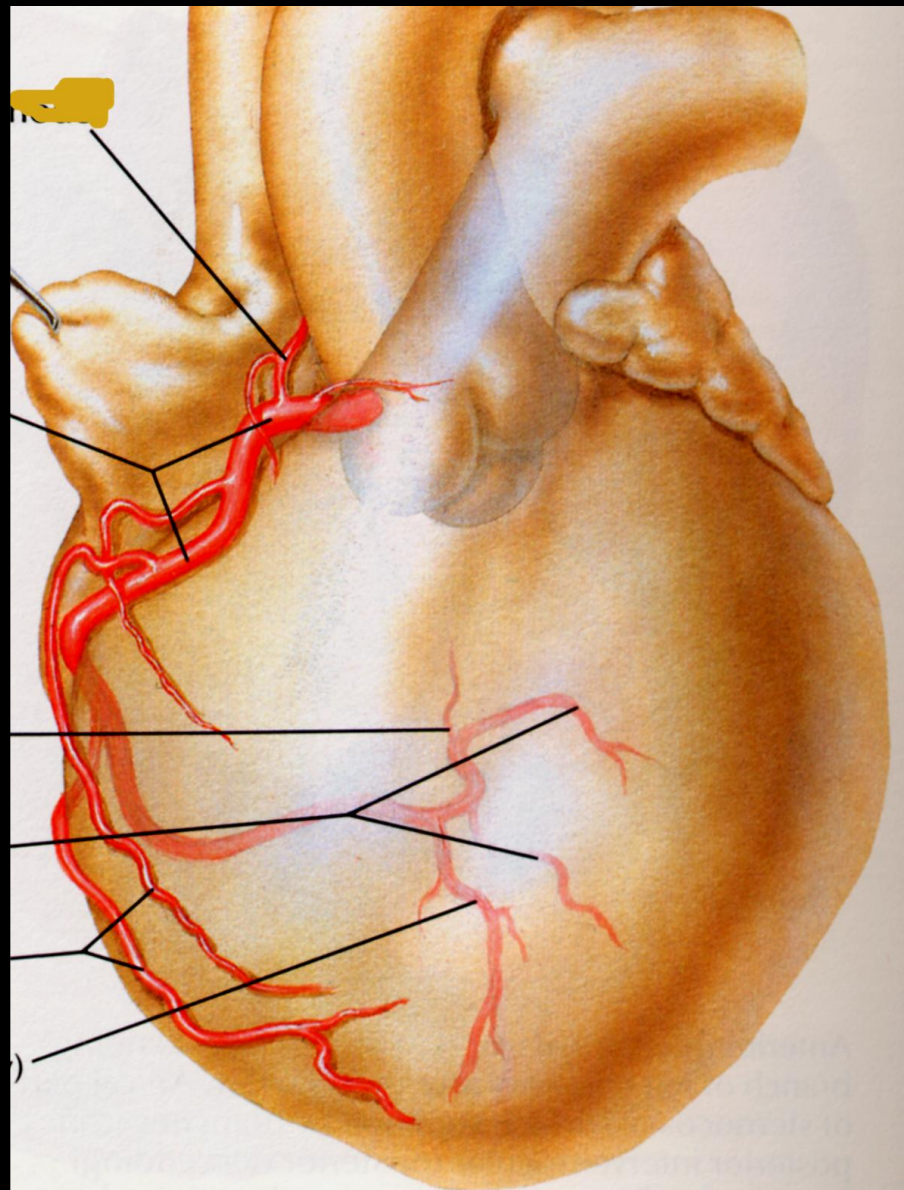
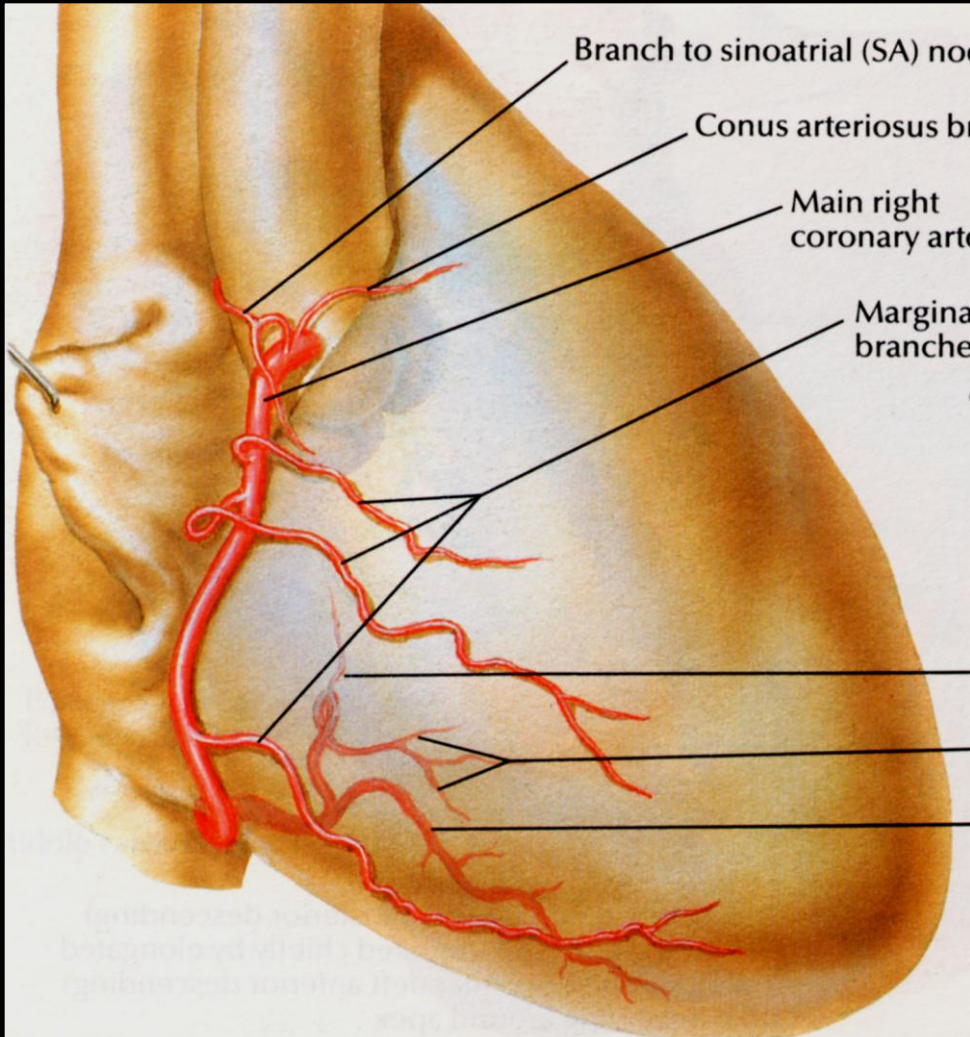
Extension supérieure du sinus oblique  
En arrière de l'AP droite sous carinaire





# Étude des coronaires

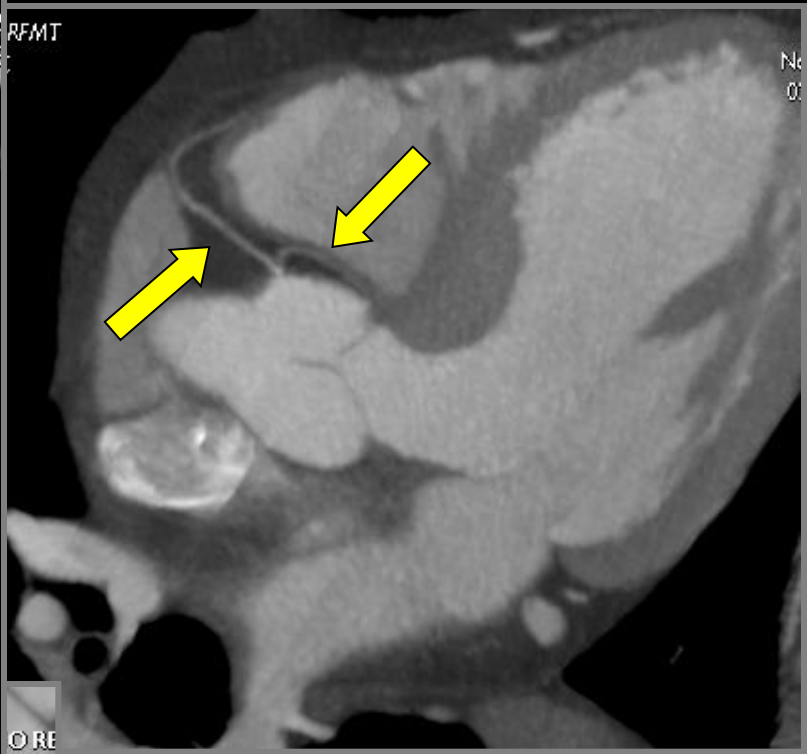
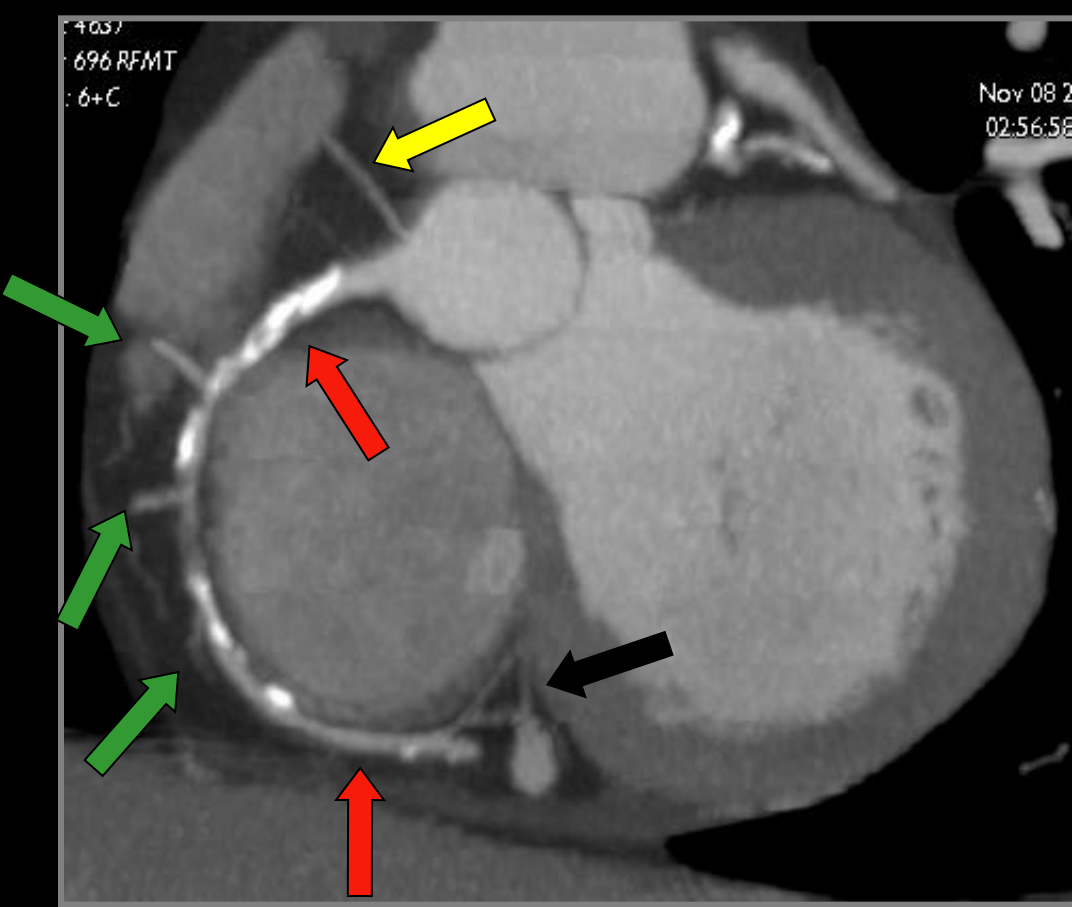




**Coronaire droite**

4037  
696 RFMT  
: 6+C

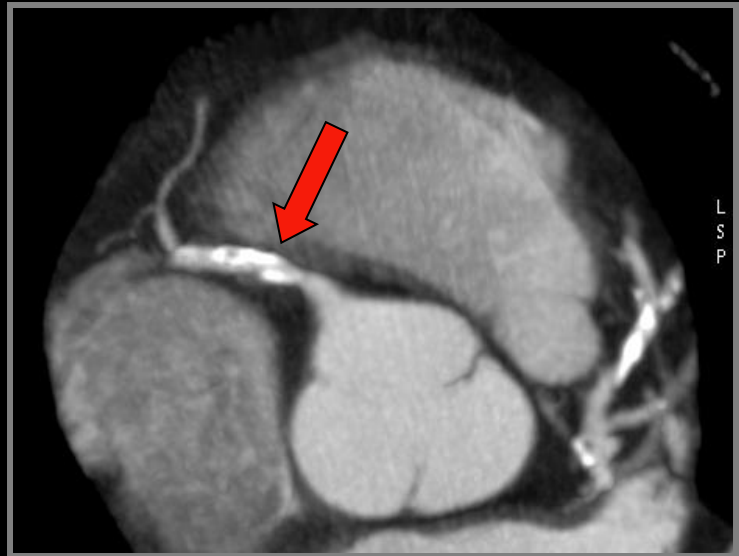
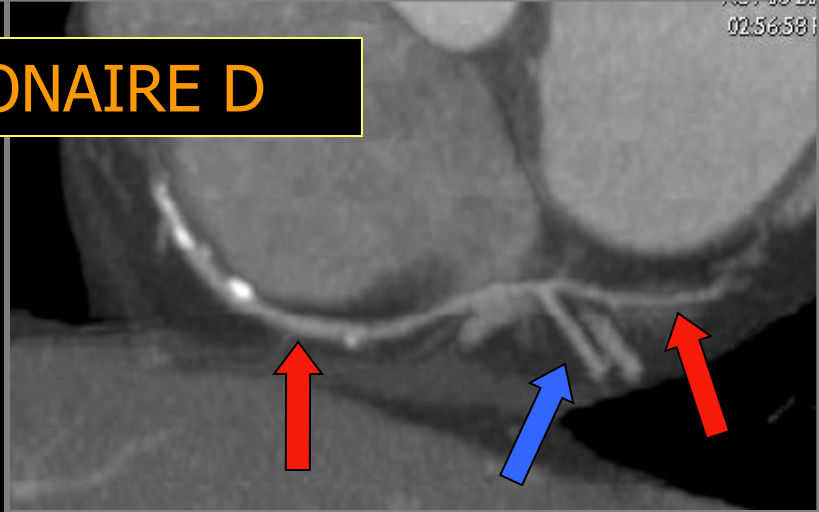
Nov 08 2008  
02:56:58



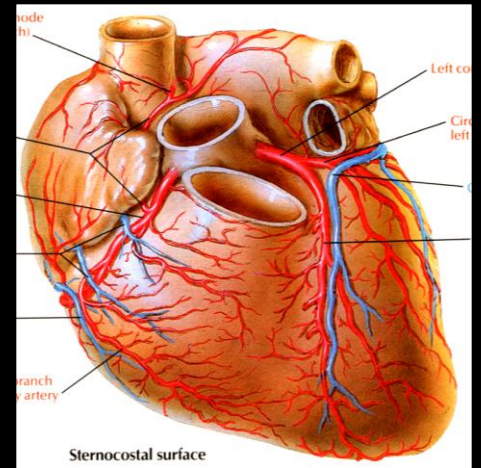
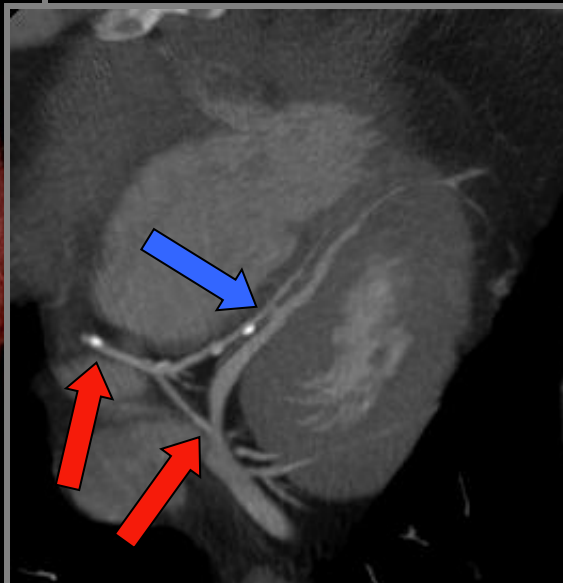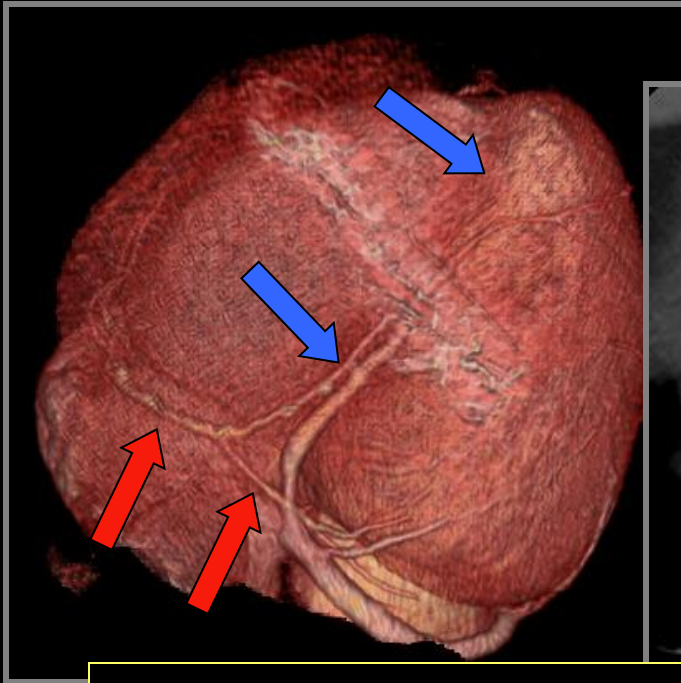
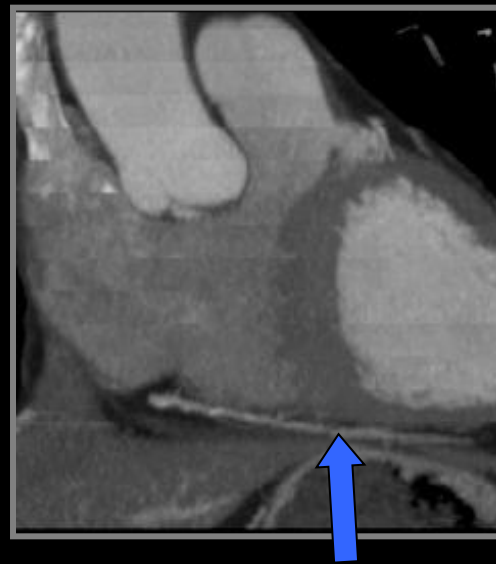
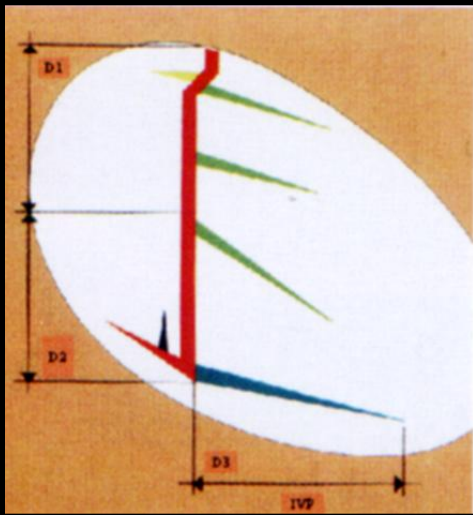
ORE

Nov 08 2008  
02:56:58

**CORONAIRE D**

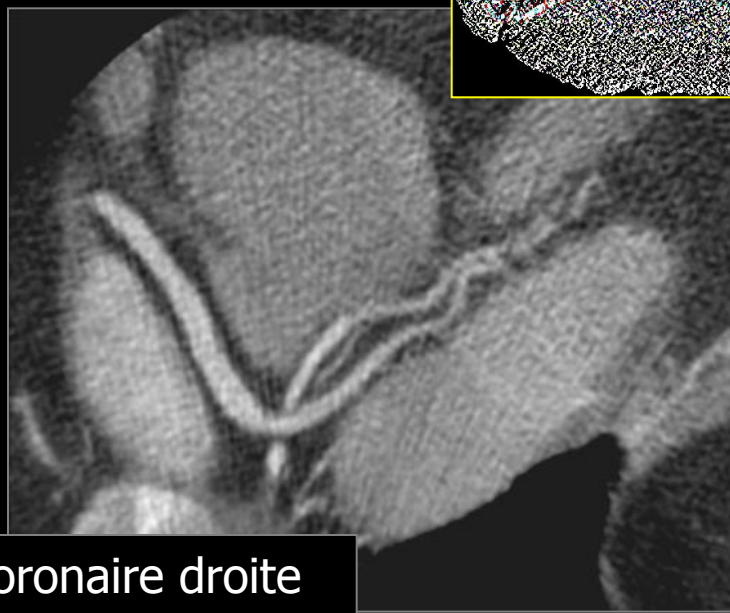
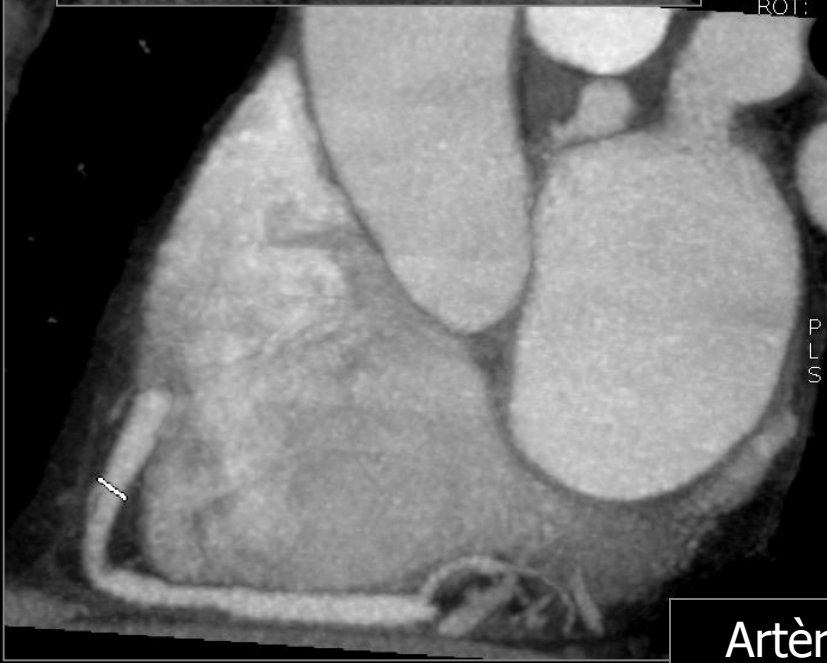
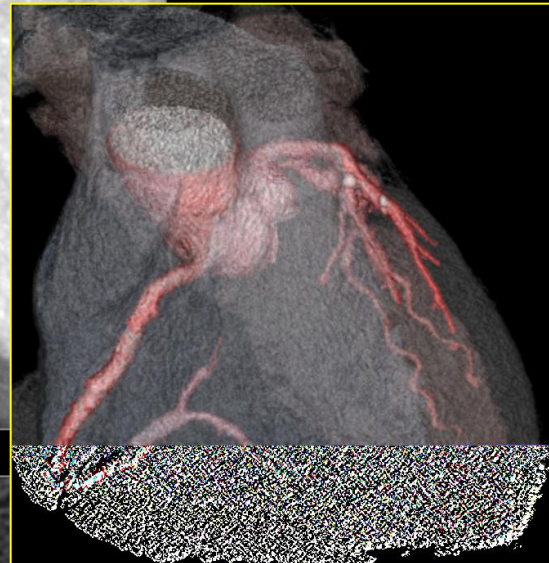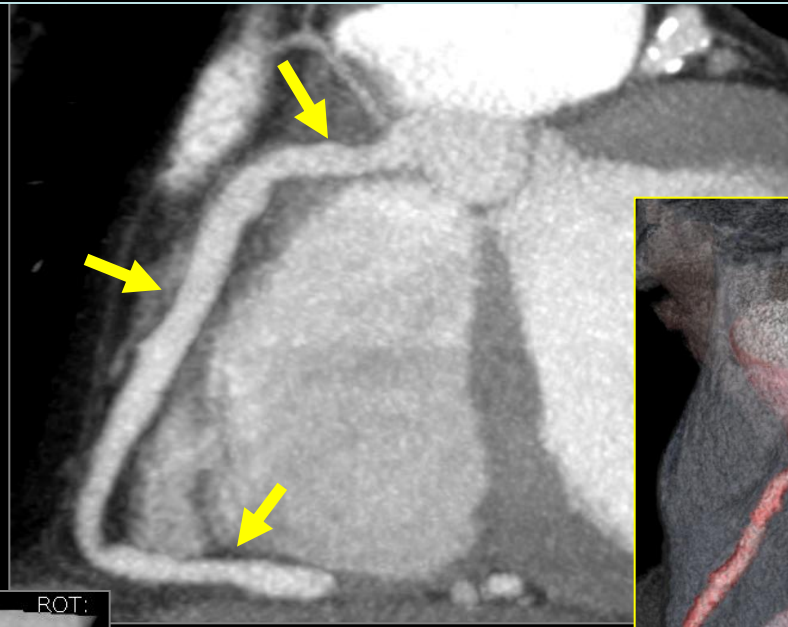

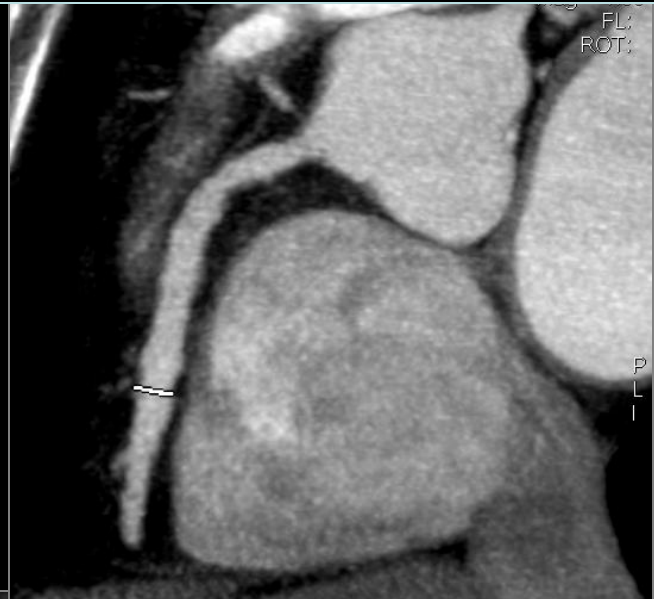
L  
S  
P

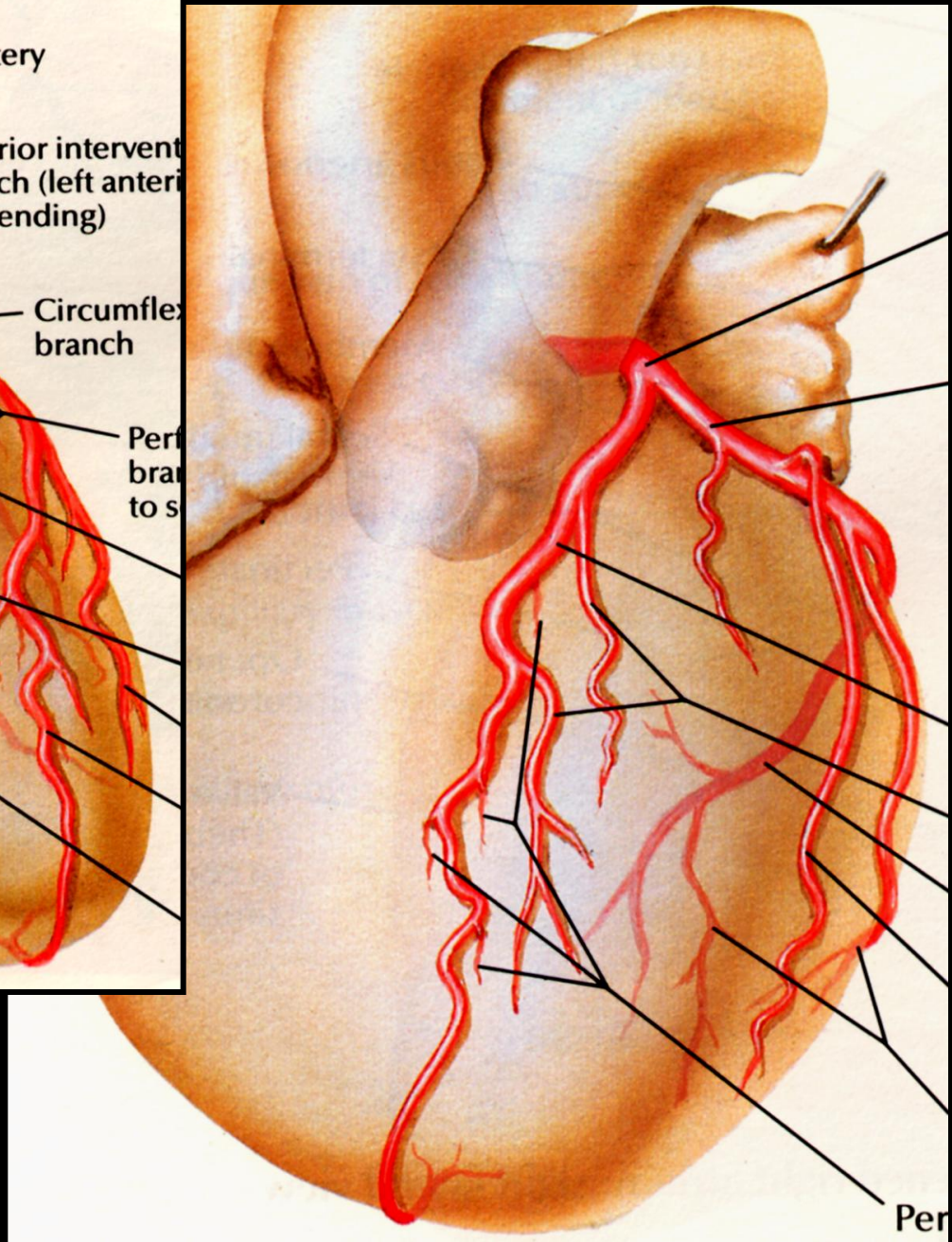
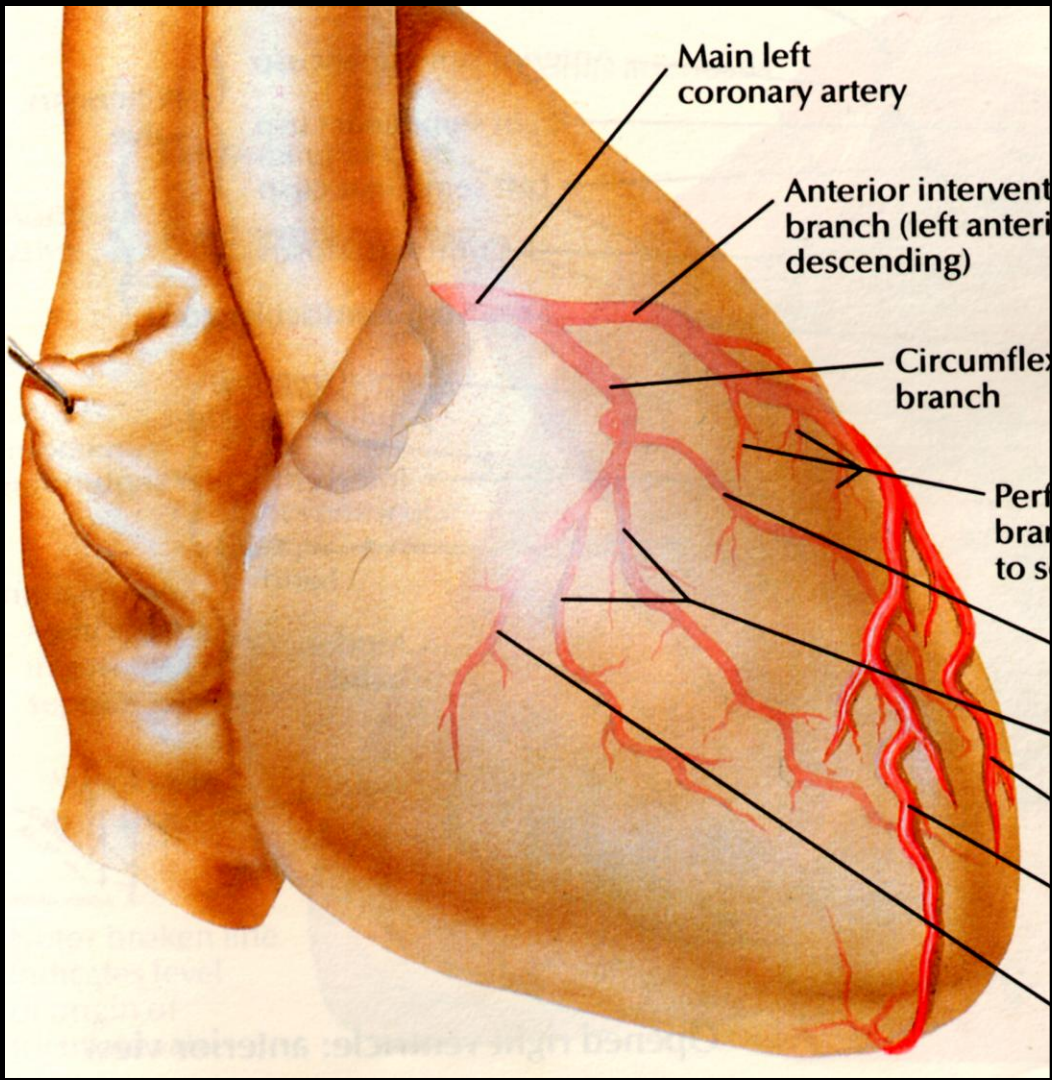


**CORONAIRE D**  
branche rétro et inter ventriculaire postérieure

**Homme de 54 ans, bilan coronarien angiographique non invasif  
angor d'effort sans ischémie authentifiée**

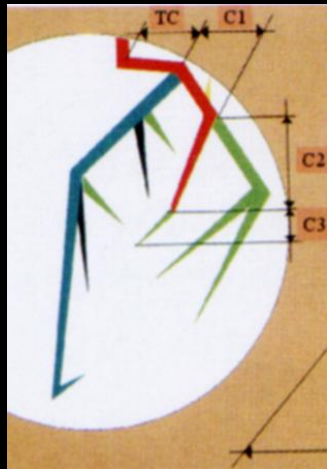
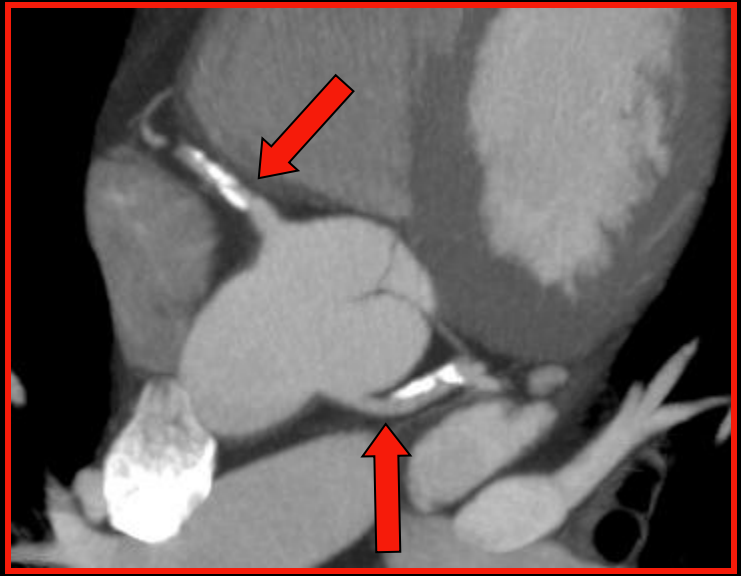
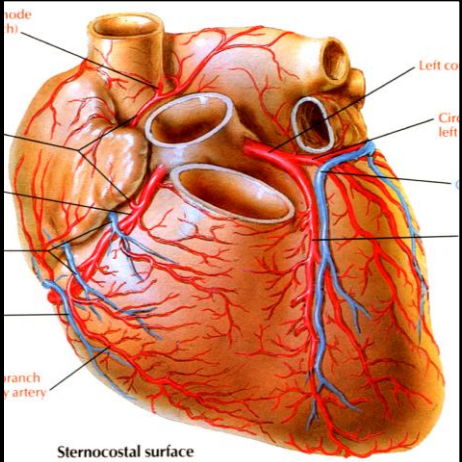
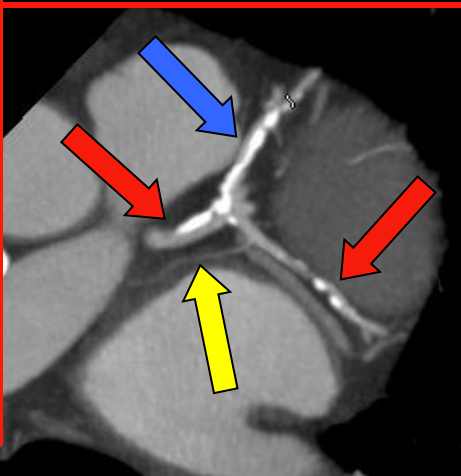
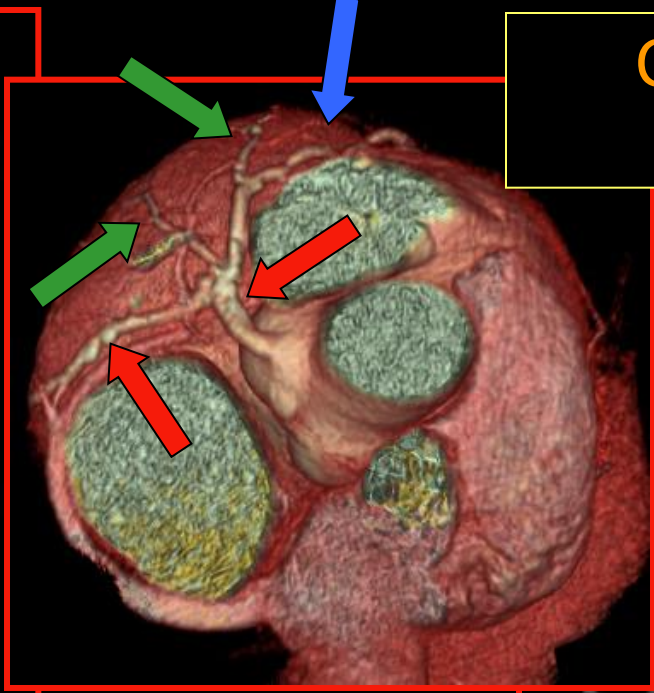
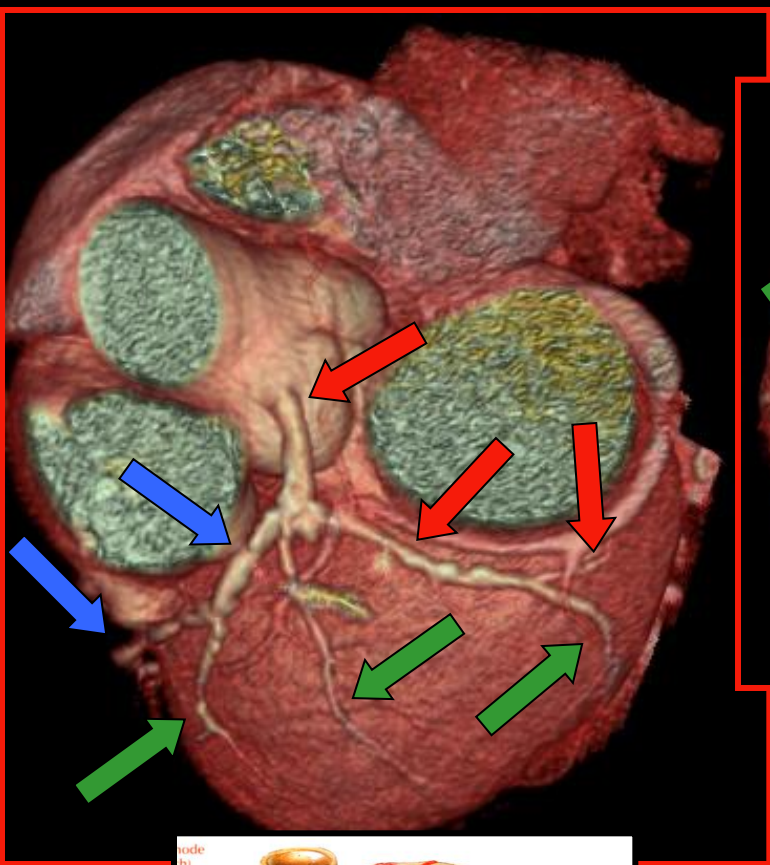


**Artère coronaire droite**

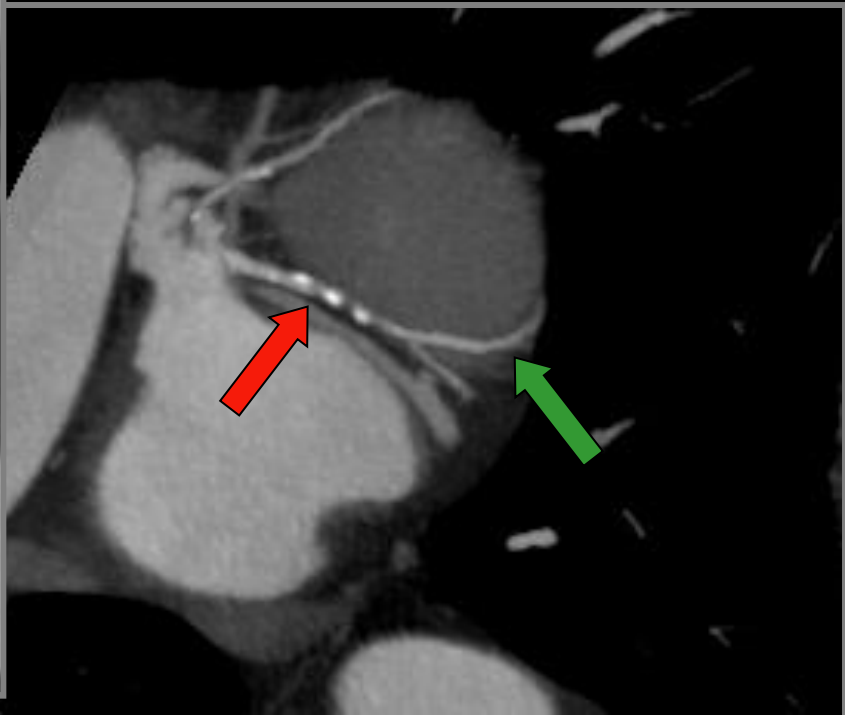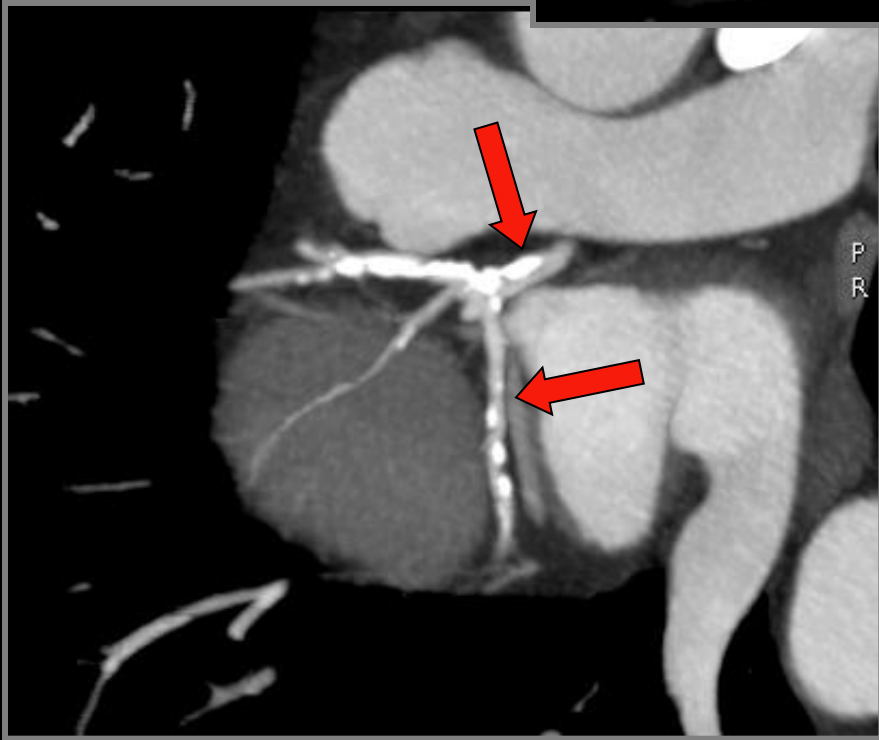
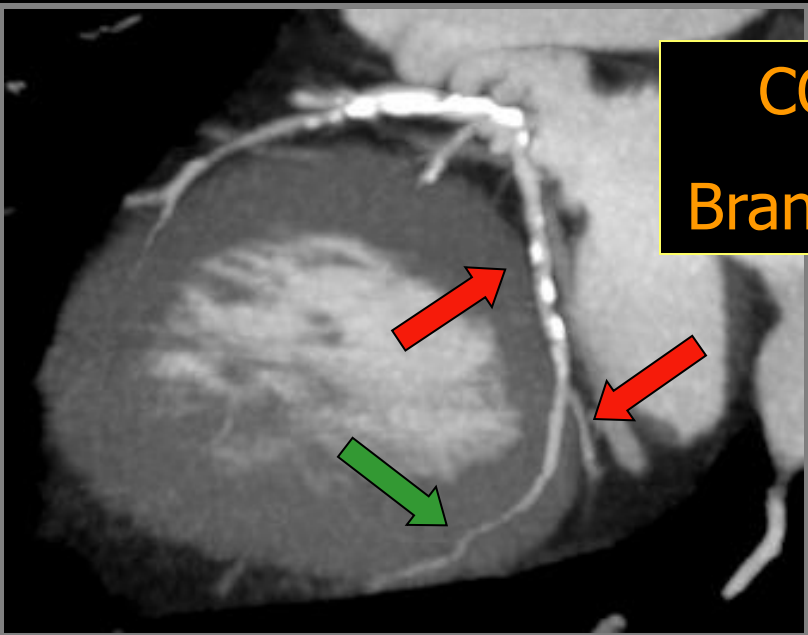


**Coronaire gauche**

# CORONAIRE GAUCHE

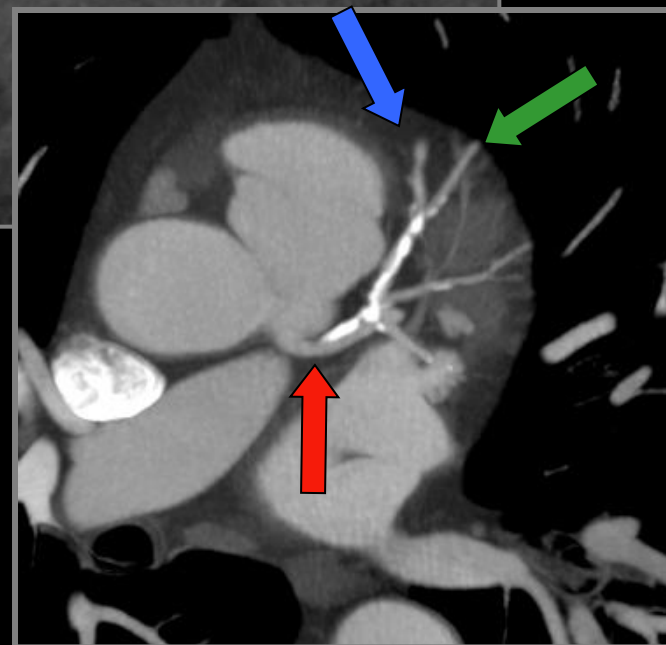
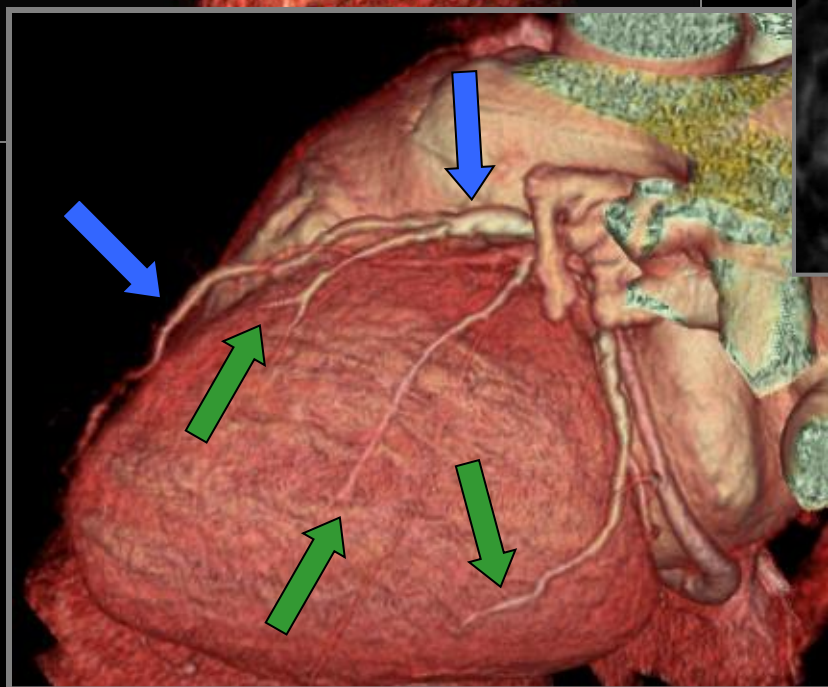
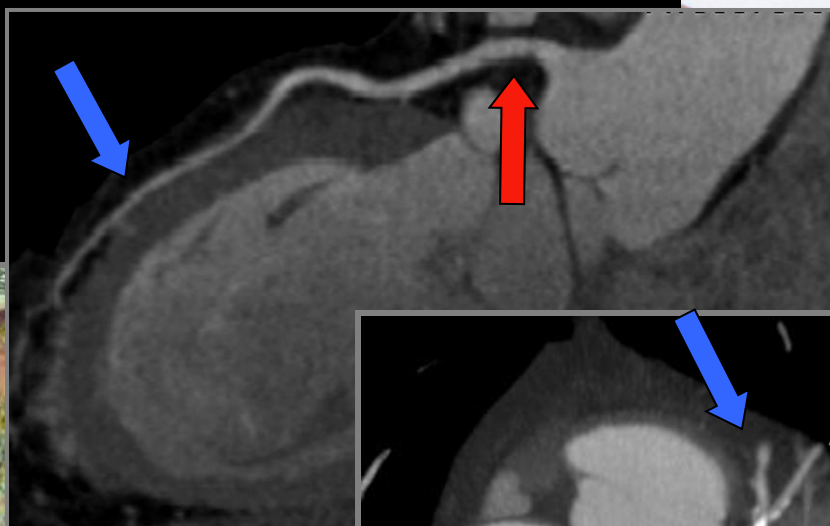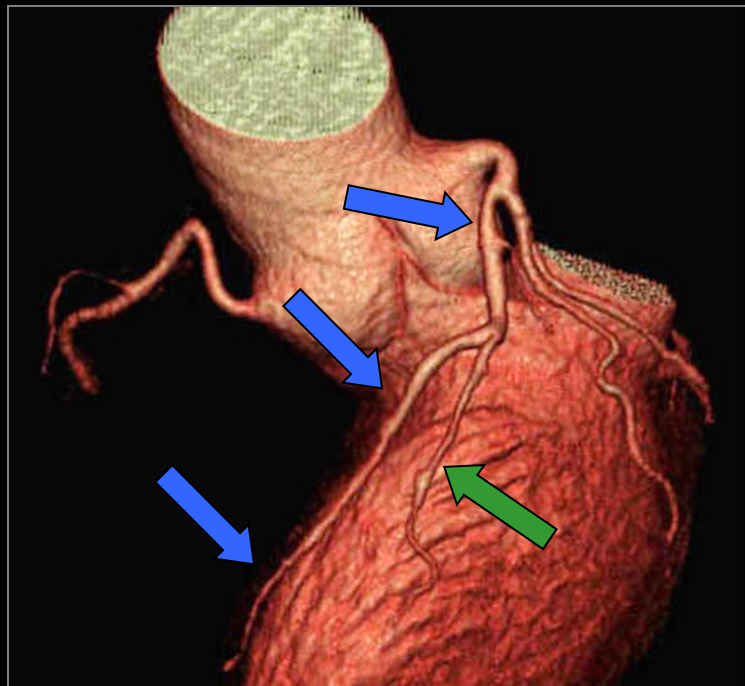
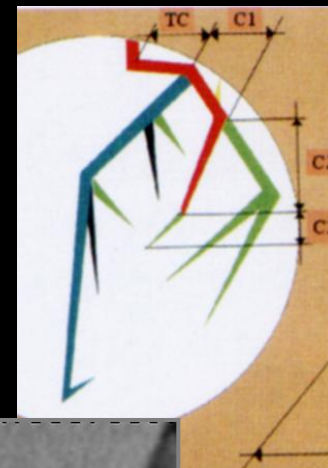


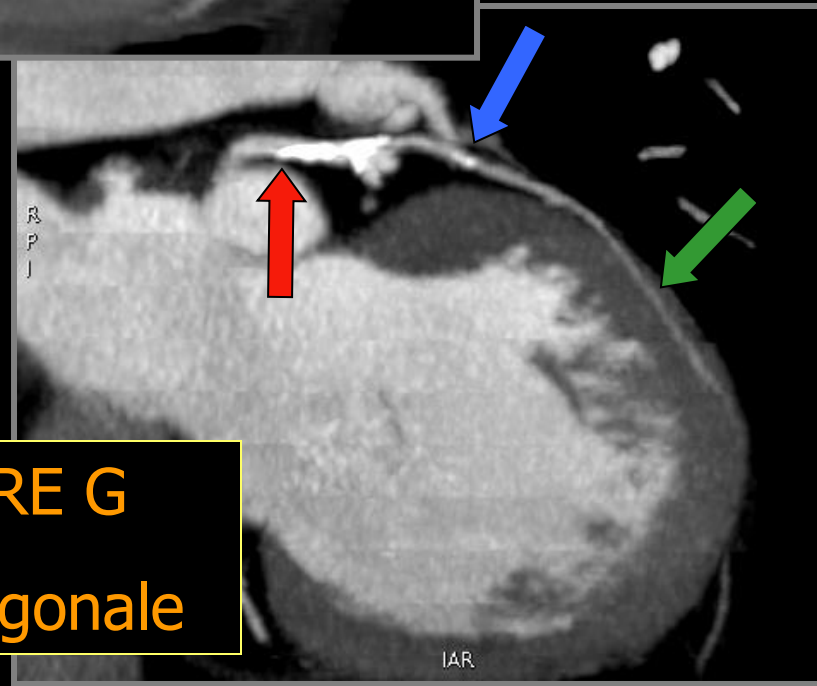
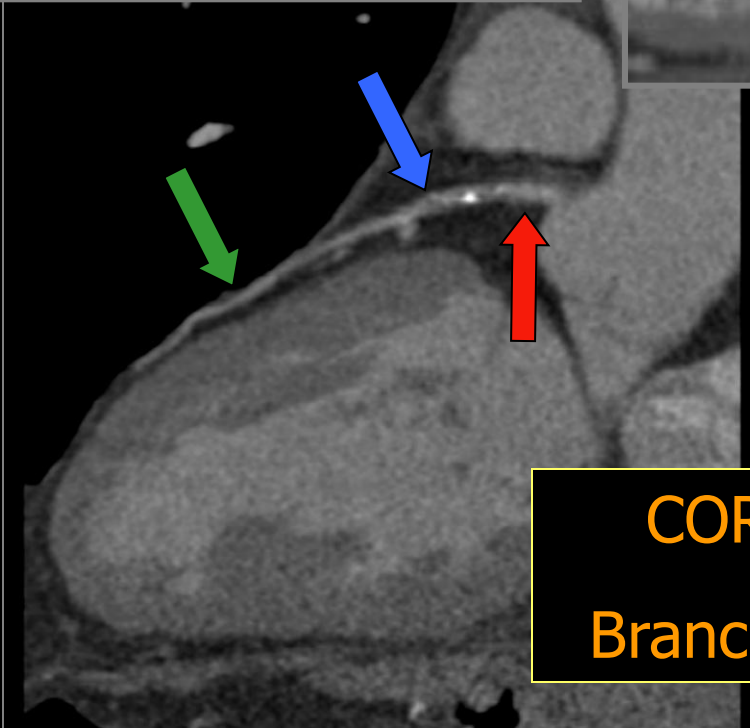
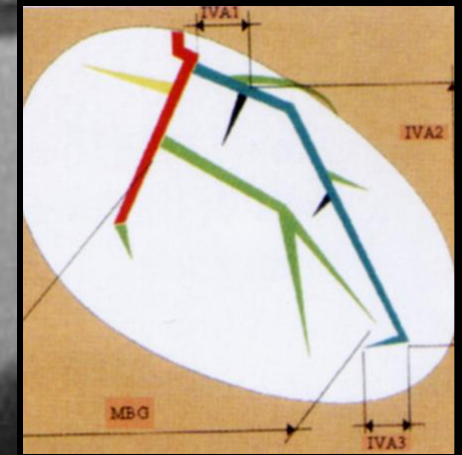
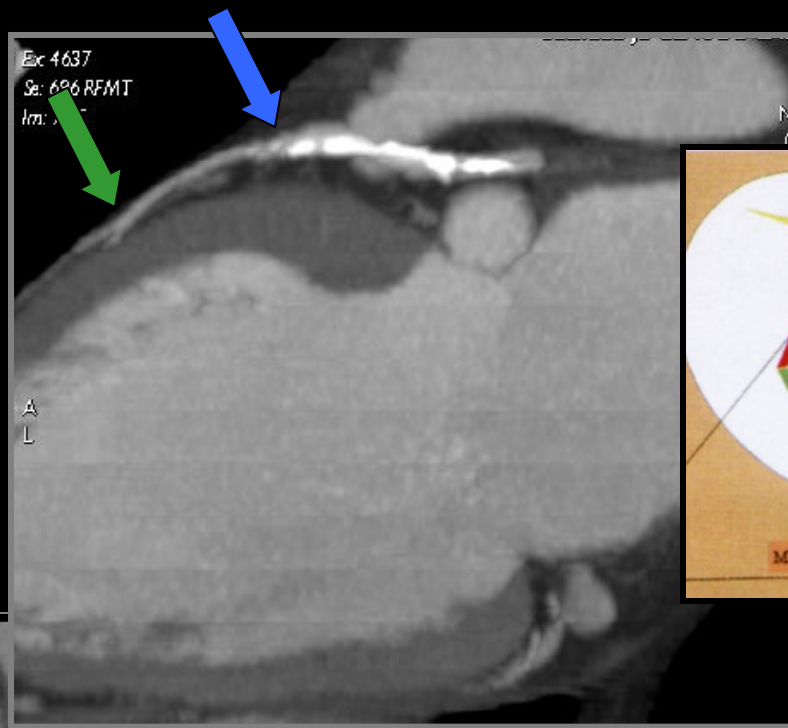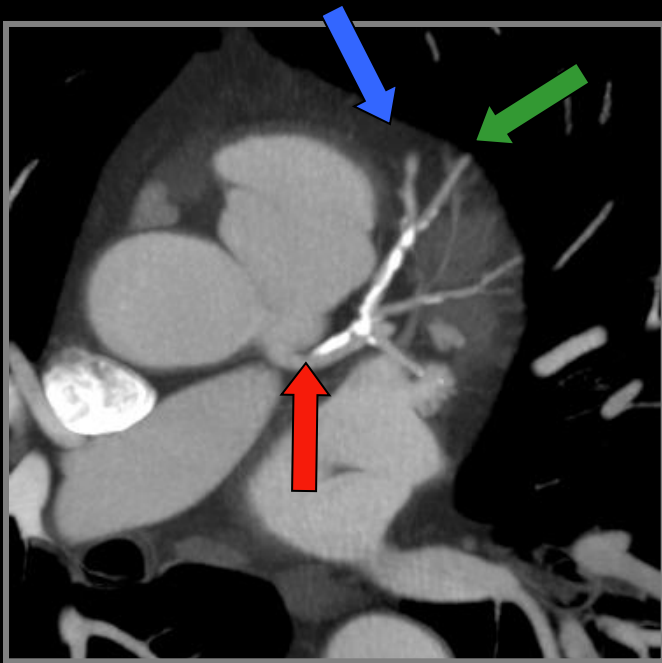
**CORONAIRE G**  
**Branche Circonflexe**



# CORONAIRE G

Branche  
interventriculaire  
antérieure



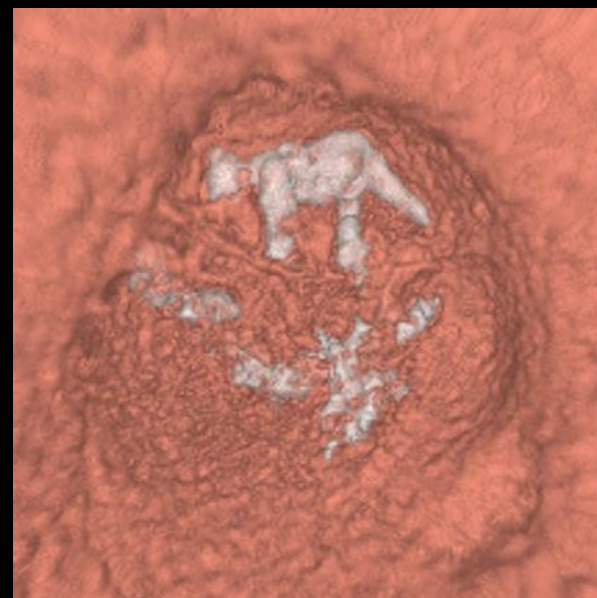
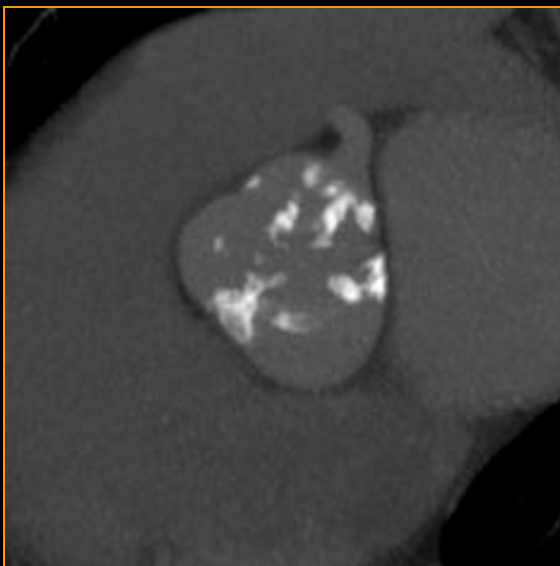
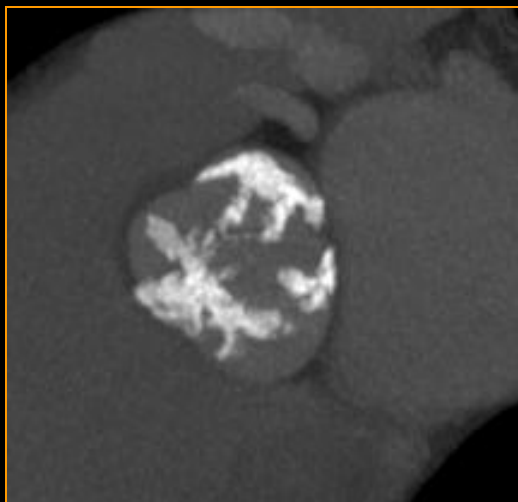
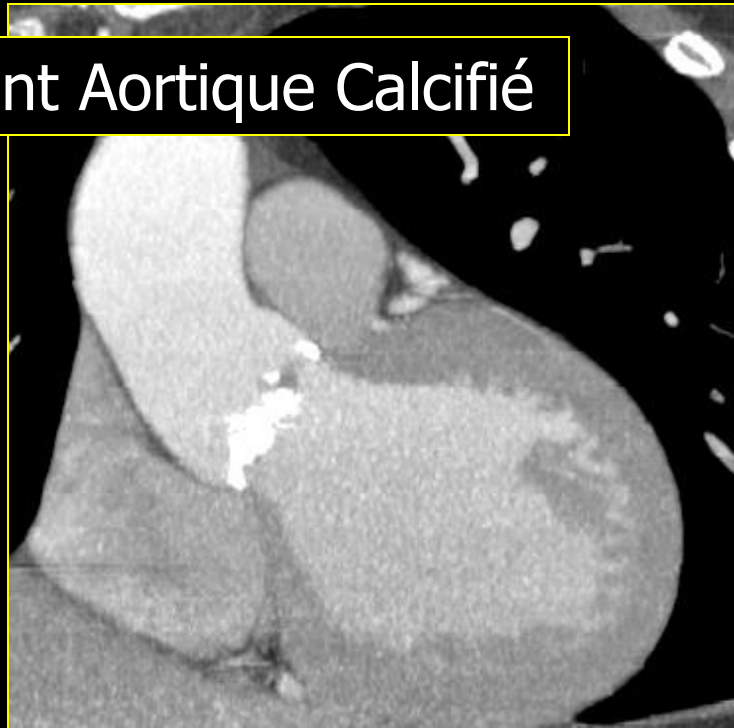
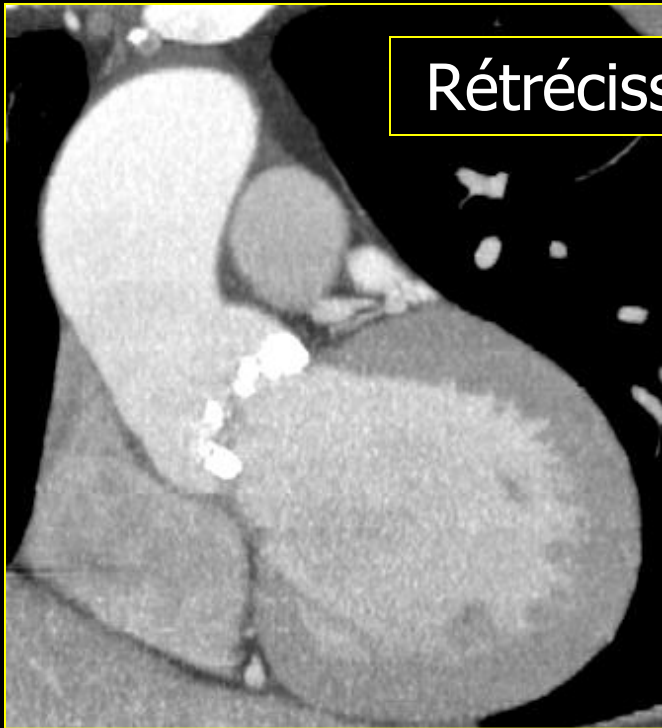

**CORONAIRE G**  
**Branche Diagonale**

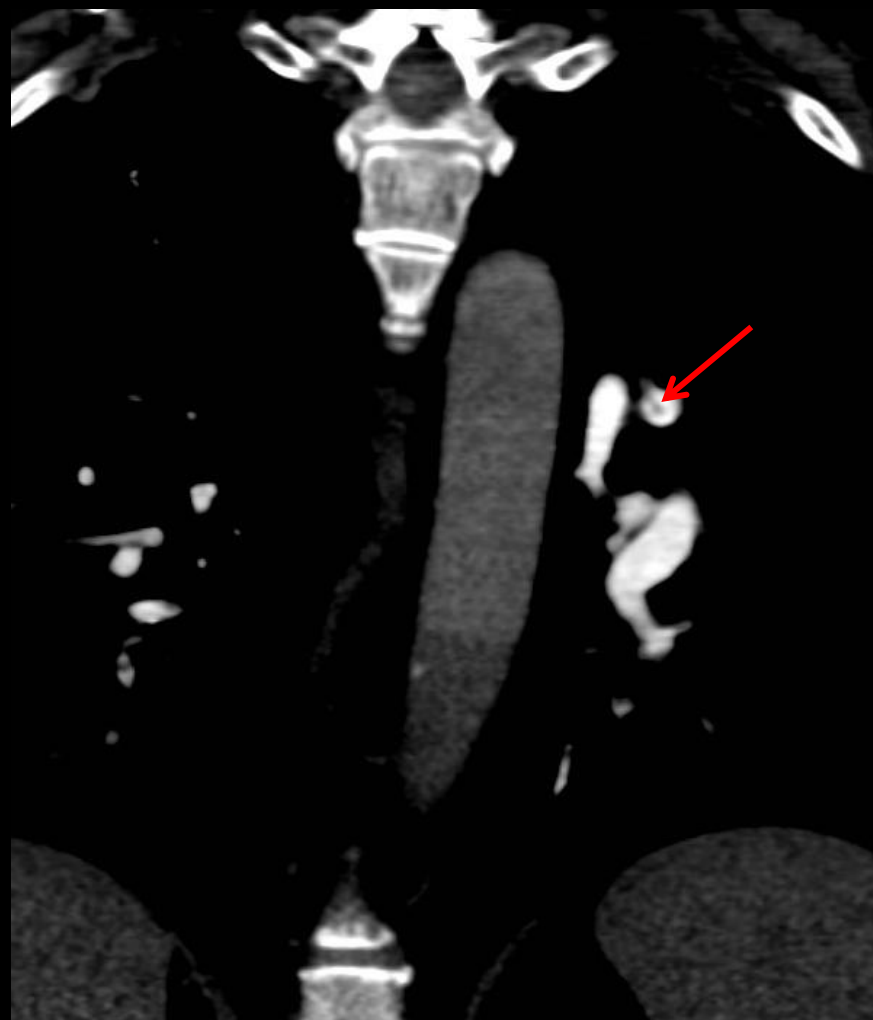
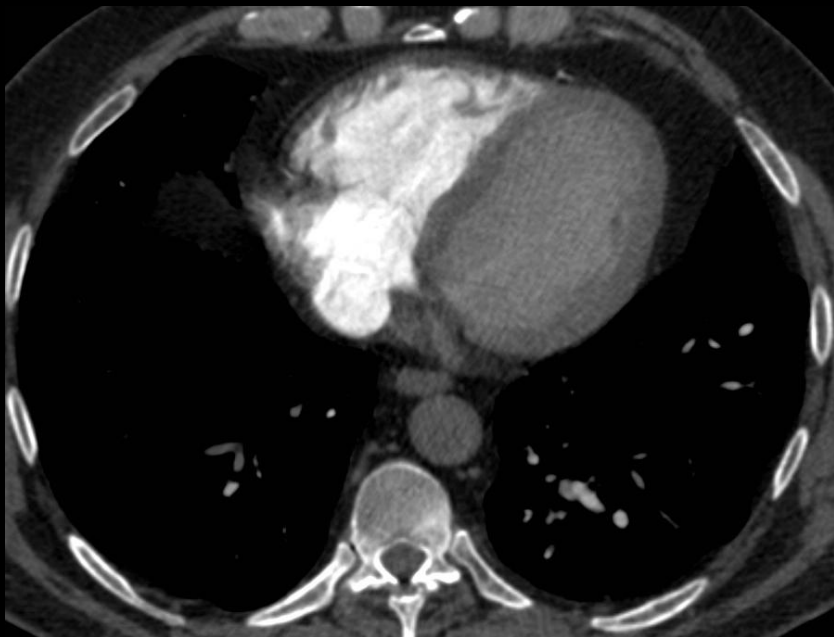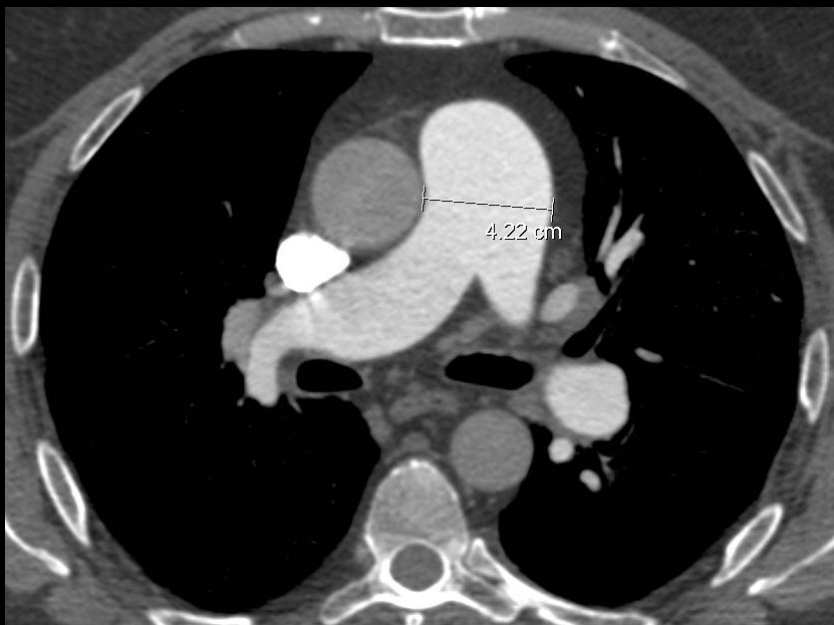


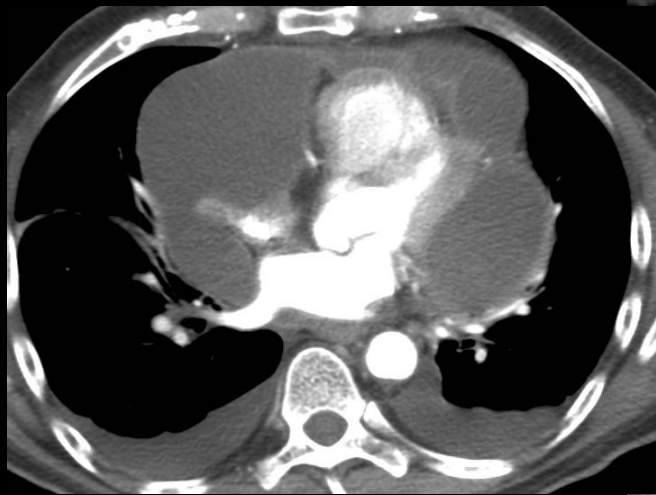
**UN PEU DE PATHOLOGIE ET  
VARIATIONS ANATOMIQUES...**

# Rétrécissement Aortique Calcifié

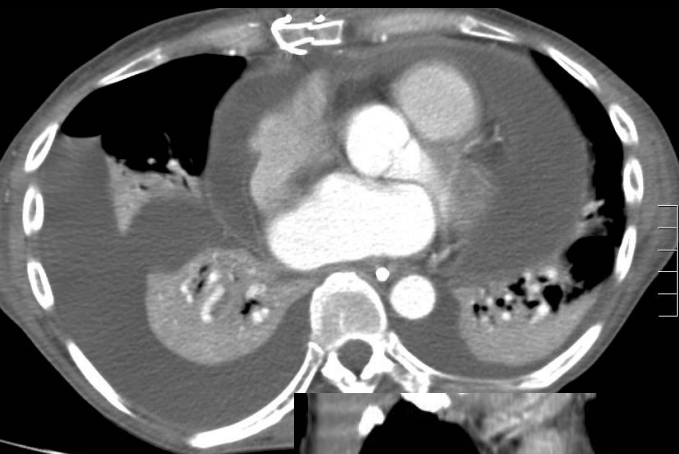
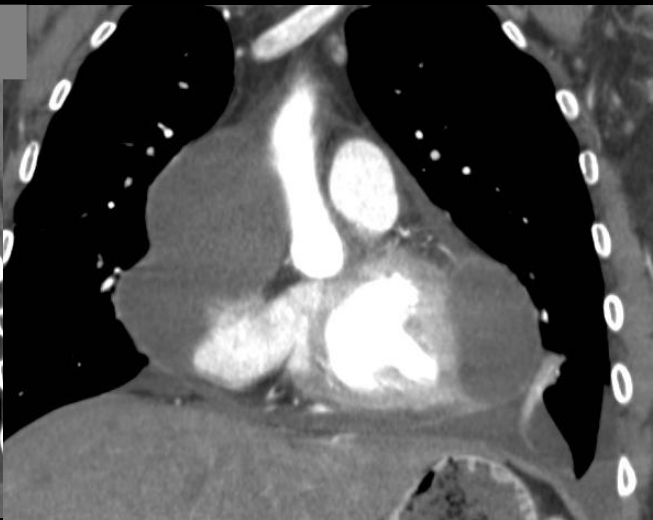
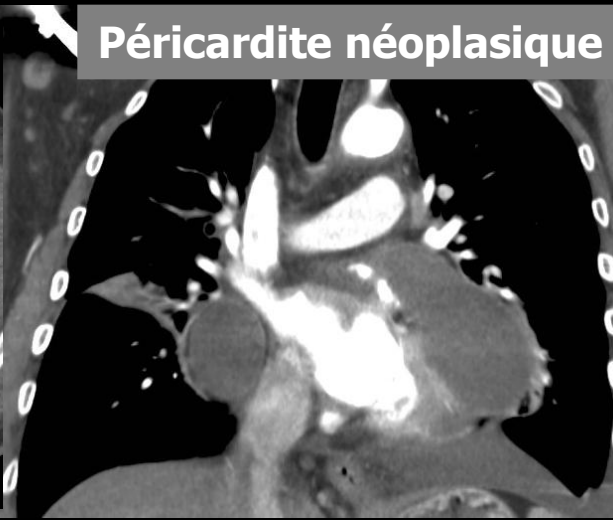


# HTAP post-embolique

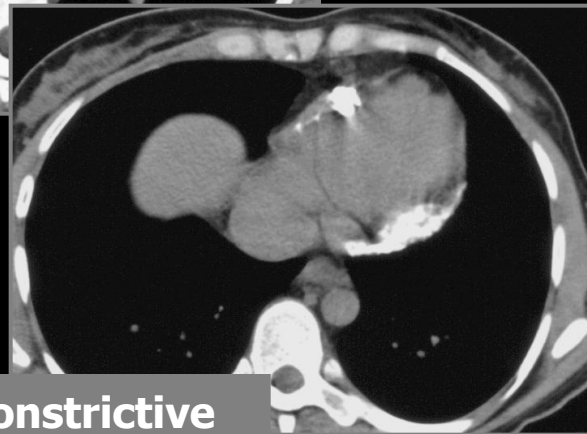
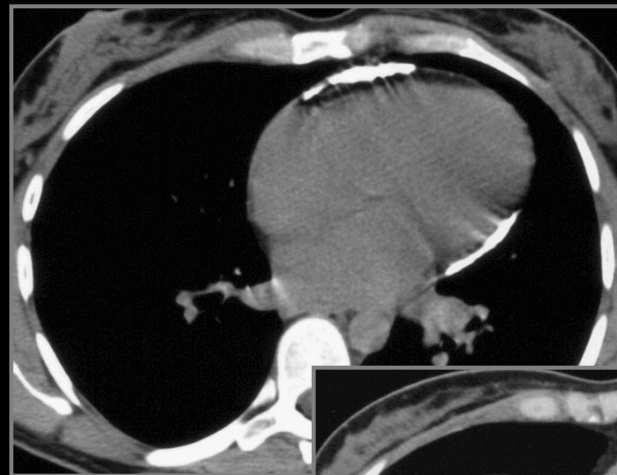
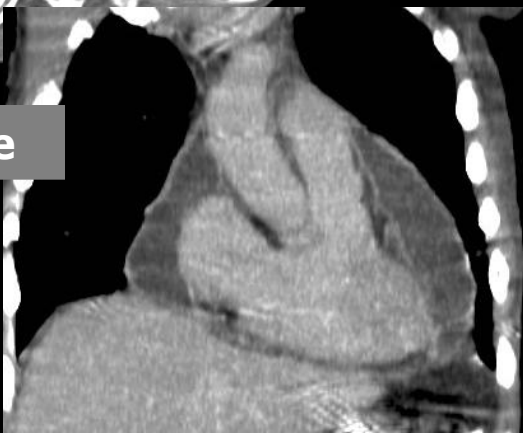




**Péricardite néoplasique**

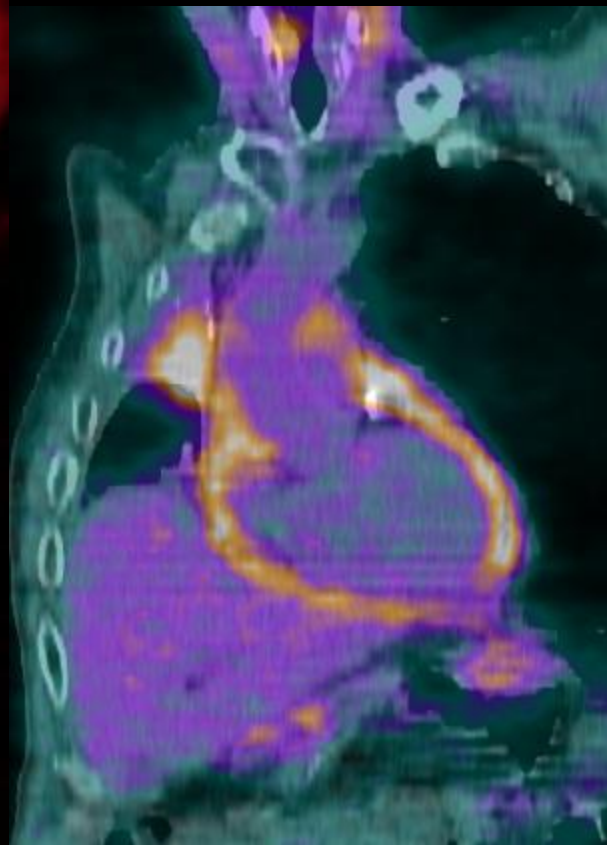
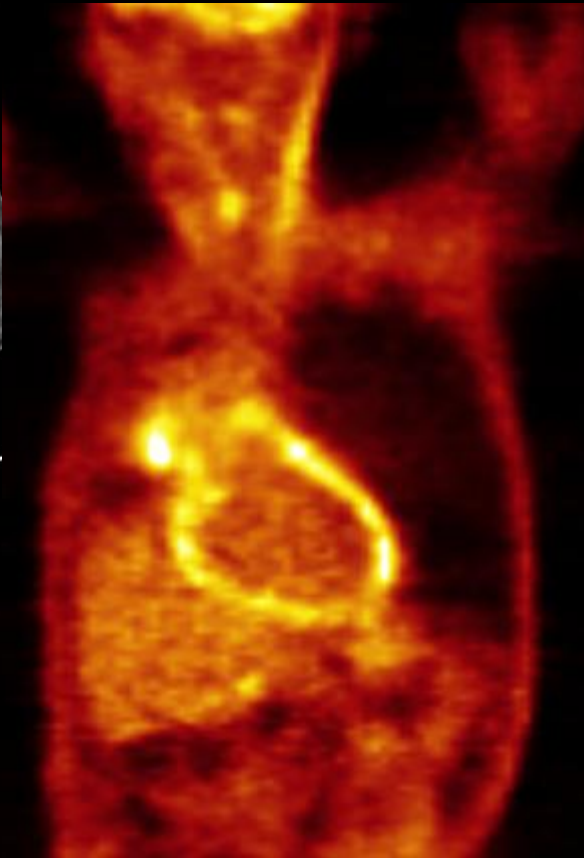
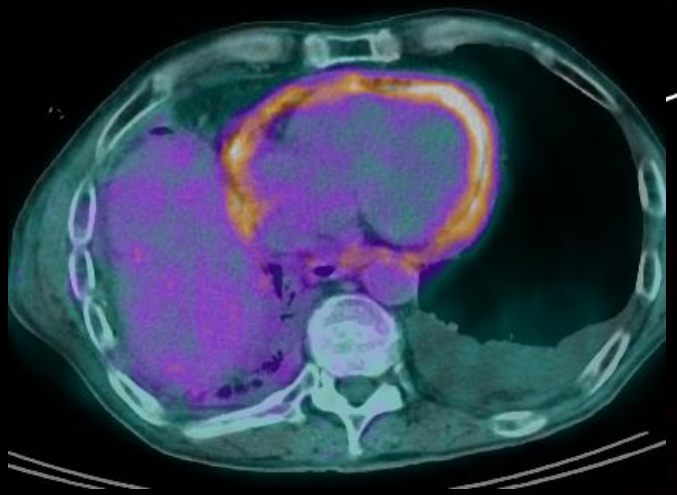
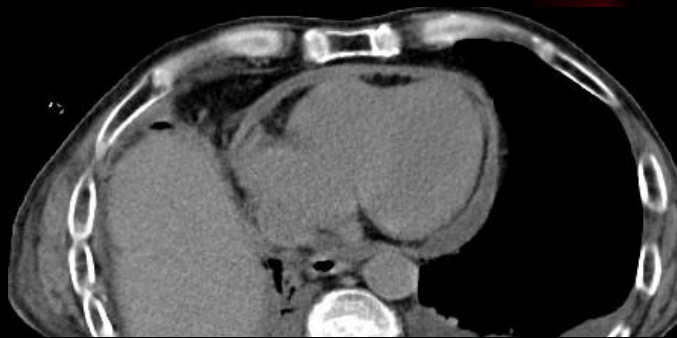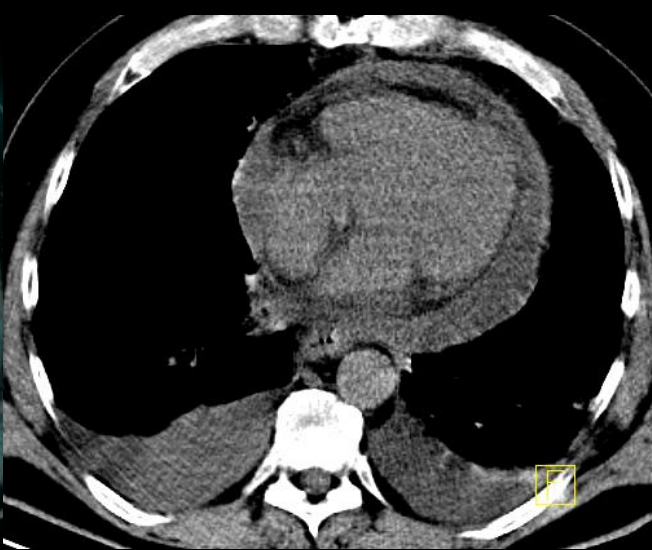
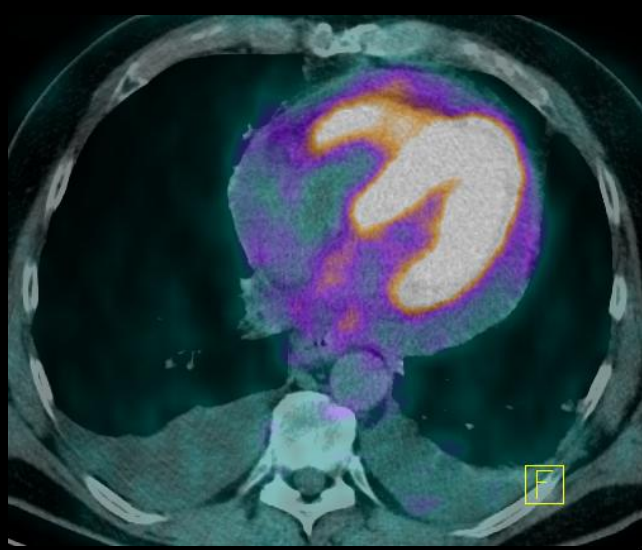


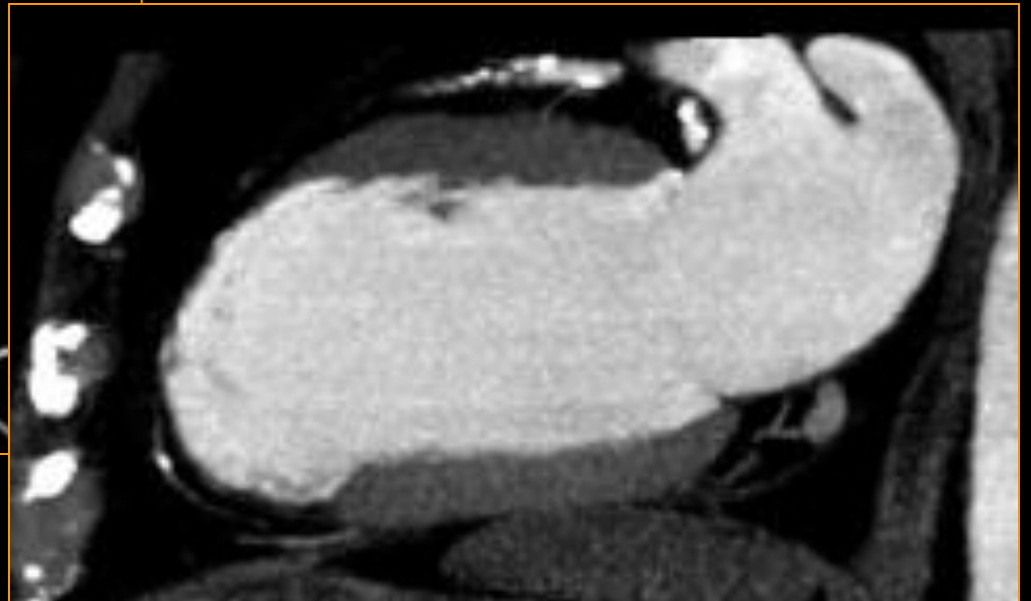
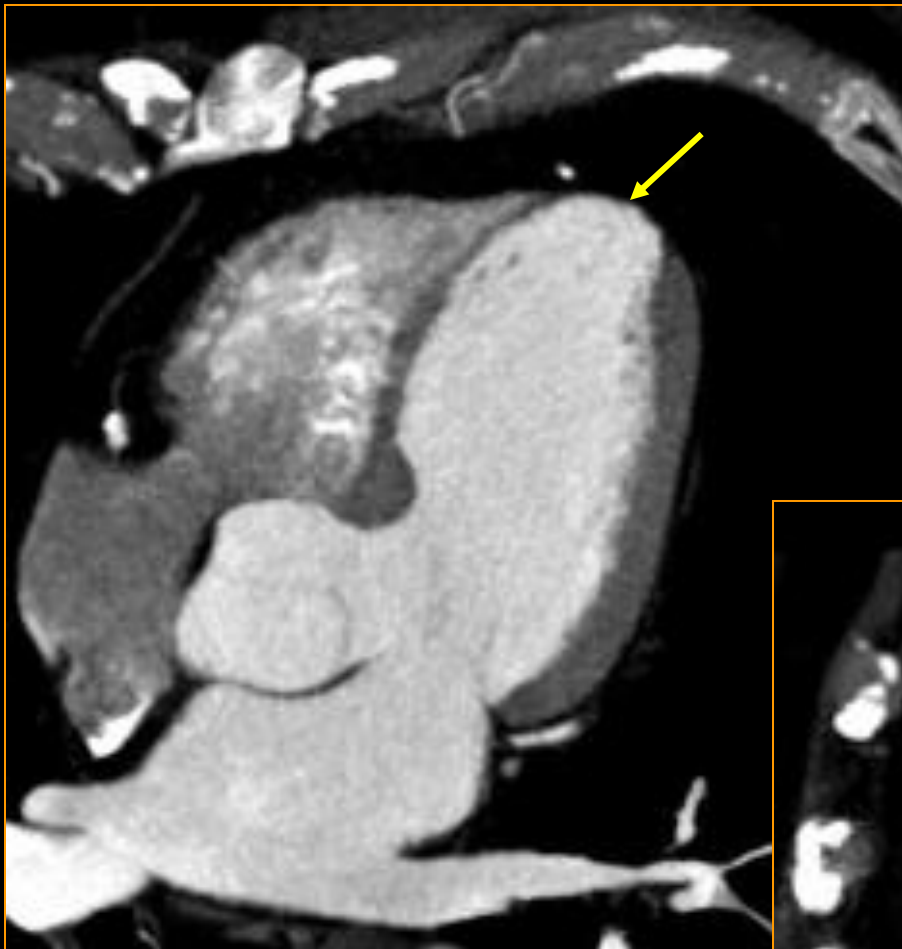
**Péricardite**



**Péricardite constrictive**

# Péricardites





Anévrisme ventriculaire



## 2/ RADIOANATOMIE DU MEDIASTIN

- VAISSEAUX
- CŒUR
- **ŒSOPHAGE**
- CHAINES GANGLIONNAIRES

## *Définition*

- Segment du tube digestif reliant l'hypopharynx à l'estomac
- Tube musculaire de 25 cm de longueur (de C6 à D11)
- 3 régions anatomiques : cervicale, thoracique et abdominale
- Passe en arrière de la trachée, traverse le médiastin postérieur dans toute sa hauteur, se déplace progressivement vers la gauche.
- Traverse le diaphragme à hauteur de T10 par le hiatus oesophagien ou il présente un rétrécissement

# Anatomie

Œsophage **cervical** : de C6 à T1, 16 à 21 cm des AD

Œsophage **thoracique** : T1 à T10, 21 à 37 cm des AD

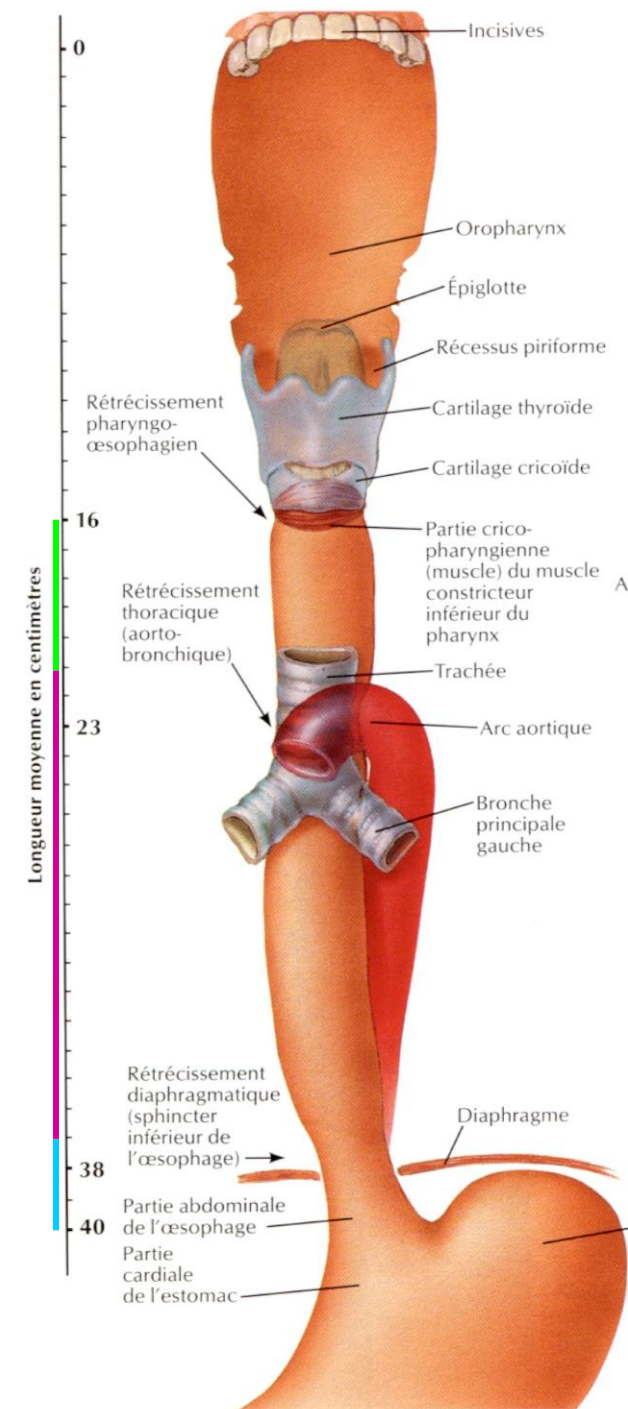
Œsophage **abdominal** : T10-11, 37 à 40 cm des AD

Œsophage intra-thoracique :

**Tiers supérieur** : de l'orifice supérieur du thorax à la bifurcation trachéale, à 24 cm approximativement des incisives supérieures

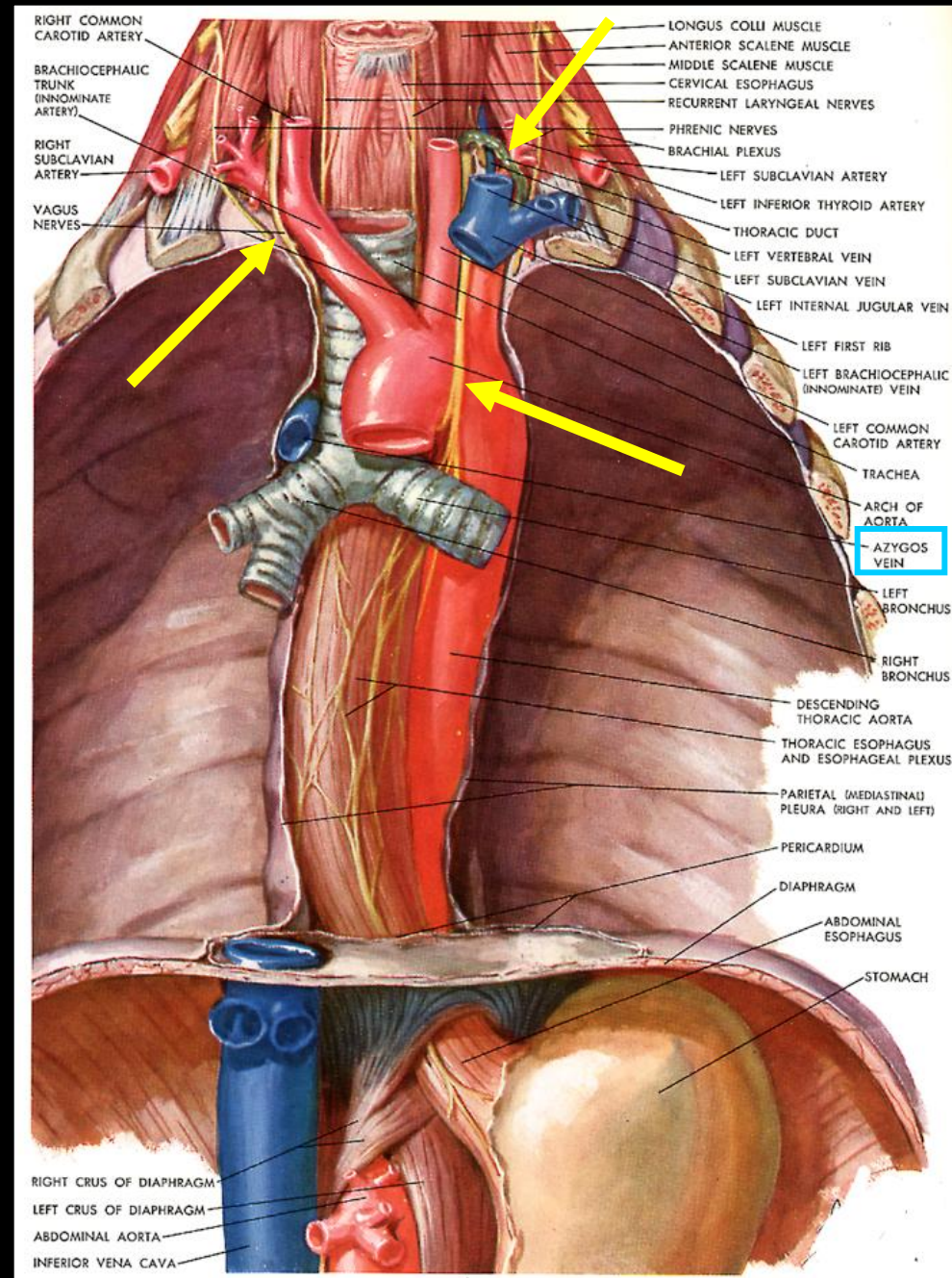
**Tiers moyen** : débutant à la hauteur de la bifurcation trachéale, de 24 à 32 cm approximativement des incisives supérieures

**Tiers inférieur** : (incluant l'oesophage abdominal), de 32 à 40 cm approximativement des incisives supérieures.



# Rapports

- **Trachée** : axe du médiastin postérieur, bifurque en T5, l'oesophage y adhère par les muscles de Luscha
- **Conduit thoracique** : monte en arrière plaqué contre l'aorte, en rapport avec l'oesophage sur une partie de son trajet.
- **Nerfs vagues** :  
droit : passe en arrière de l'oesophage  
gauche : en avant de l'oesophage
- **Chaîne orthosympathique latéro-vertébrale** et ses ganglions
- **Azygos, hémiazygos, hémiazygos accessoire**



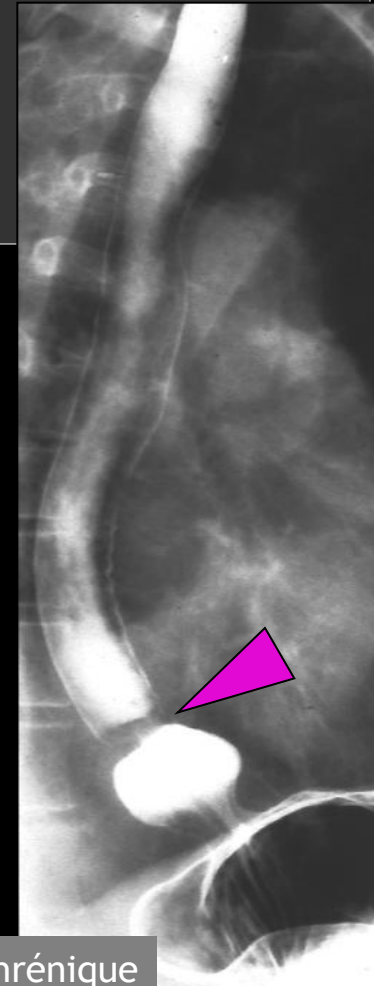
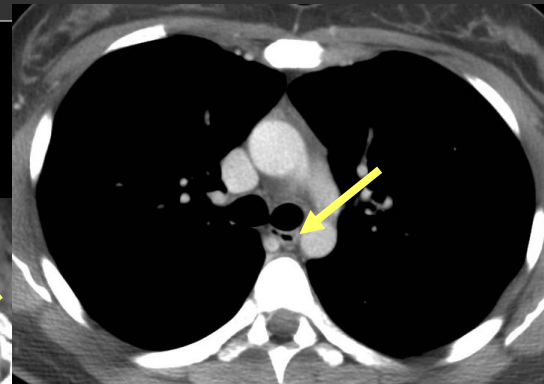
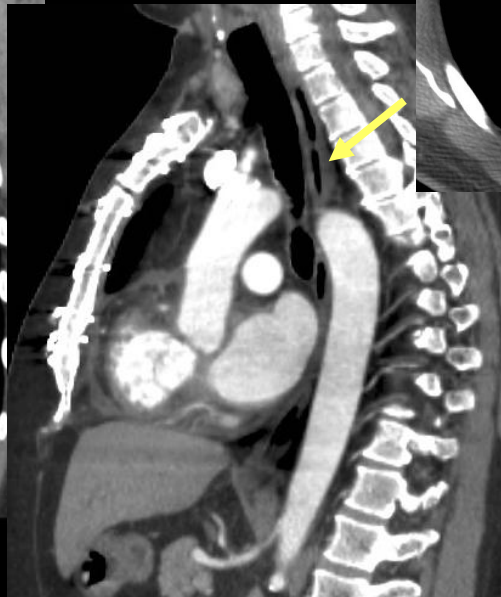
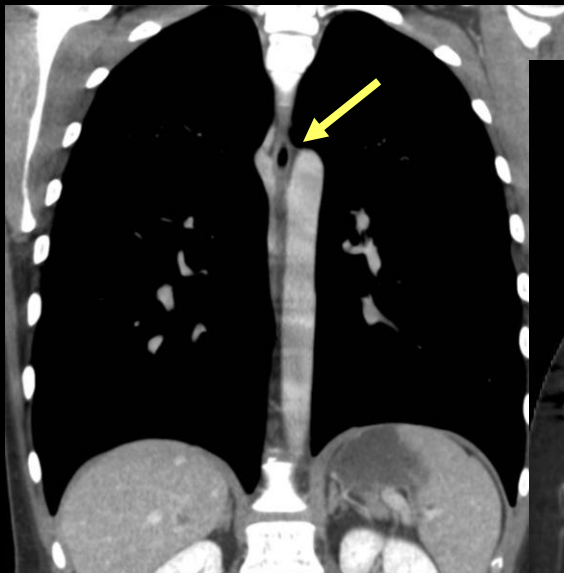
## Transit oesophagien

### - double contraste

- BaSO4 haute densité-viscosité faible
- air dégluti ou mieux **insufflé**

## Scanner: pathologie tumorale ++

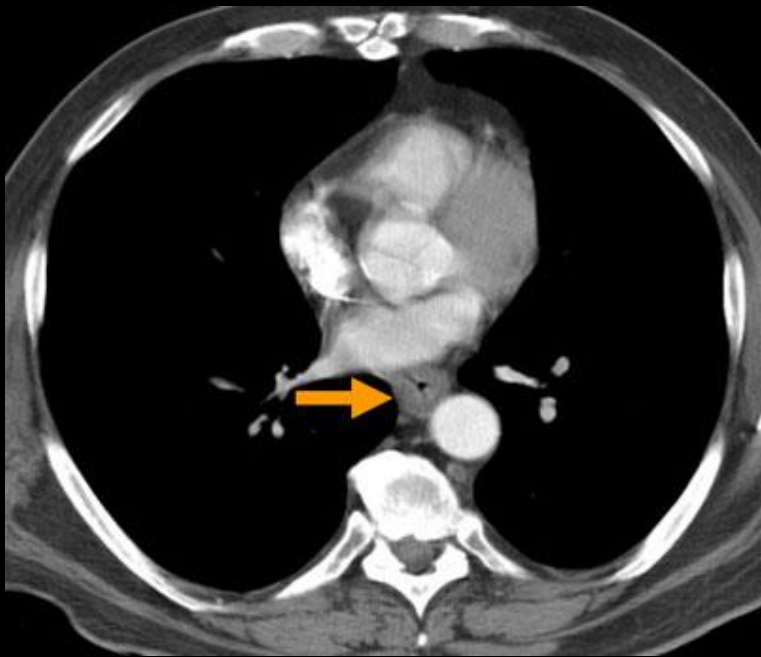
Avec ingestion d'hydrosolubles ++++



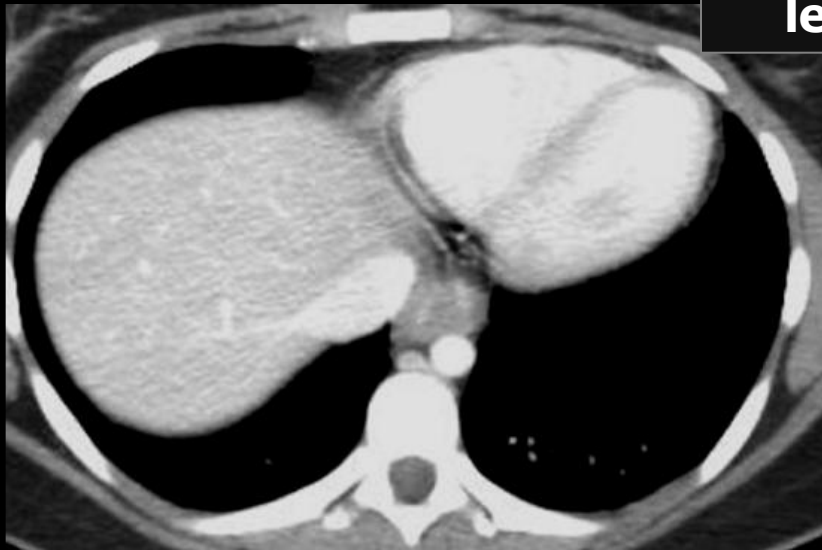ampoule épiphrénique



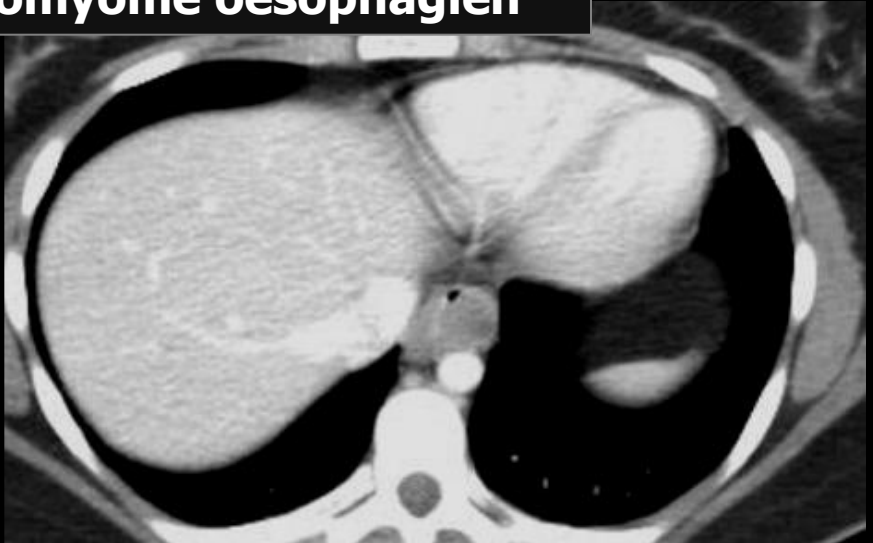
**UN PEU DE PATHOLOGIE ET  
VARIATIONS ANATOMIQUES...**

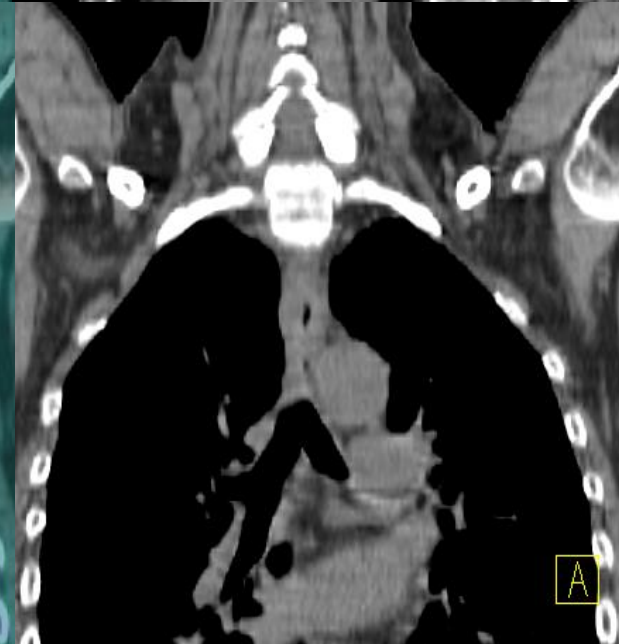
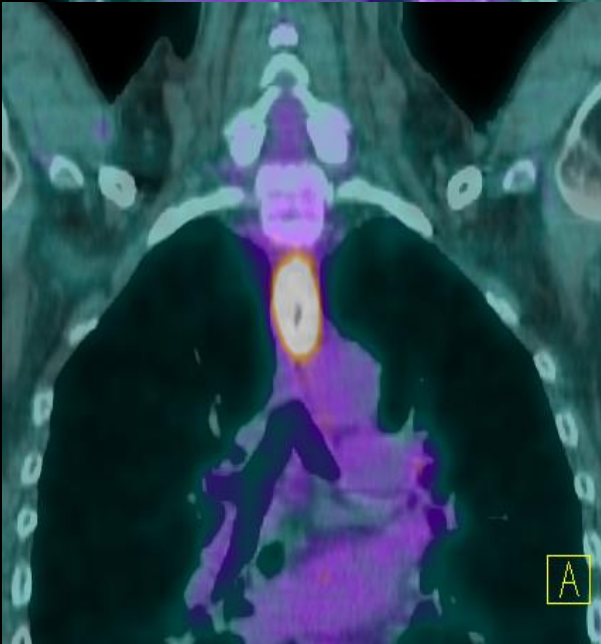
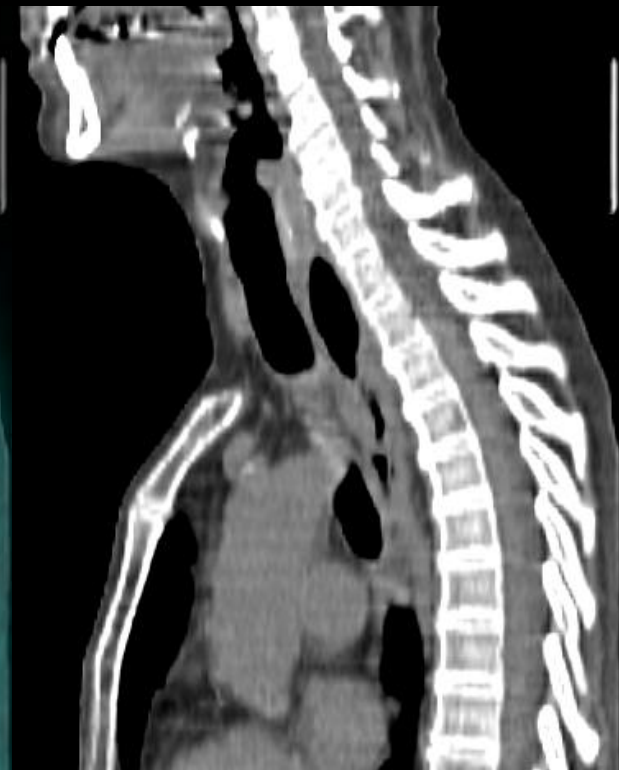
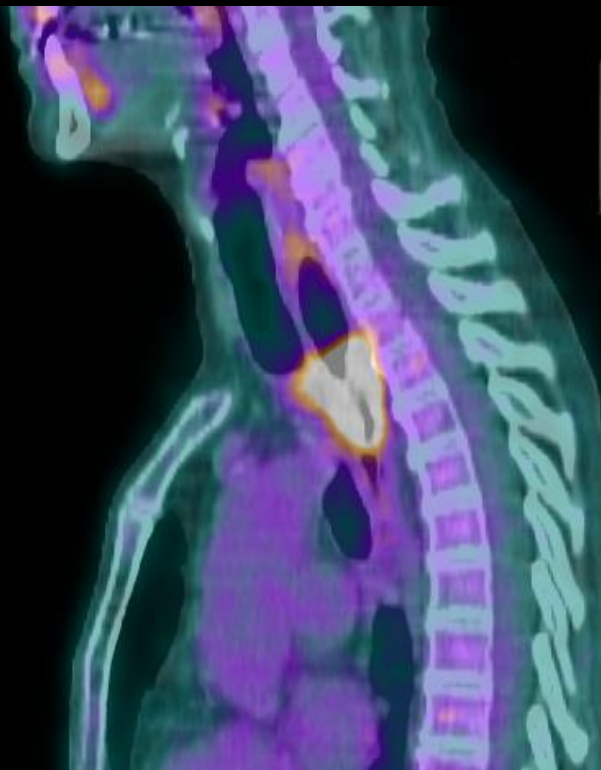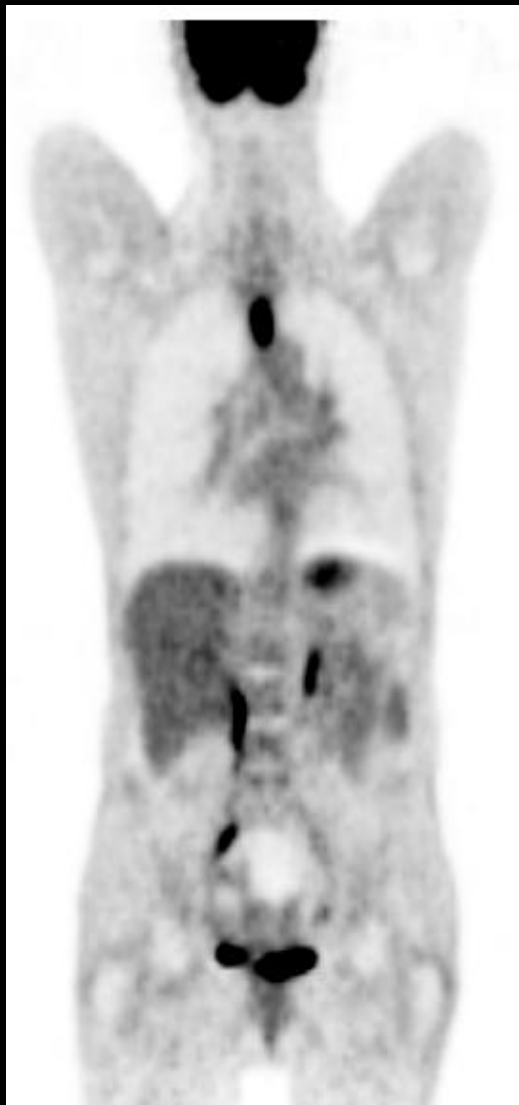**carcinome épidermoïde  
de l'oesophage**

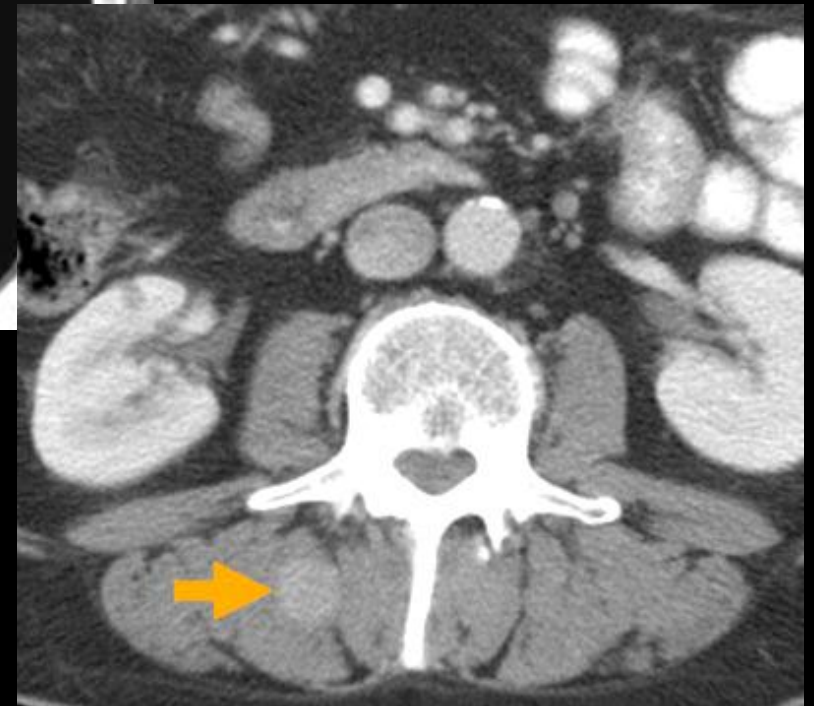
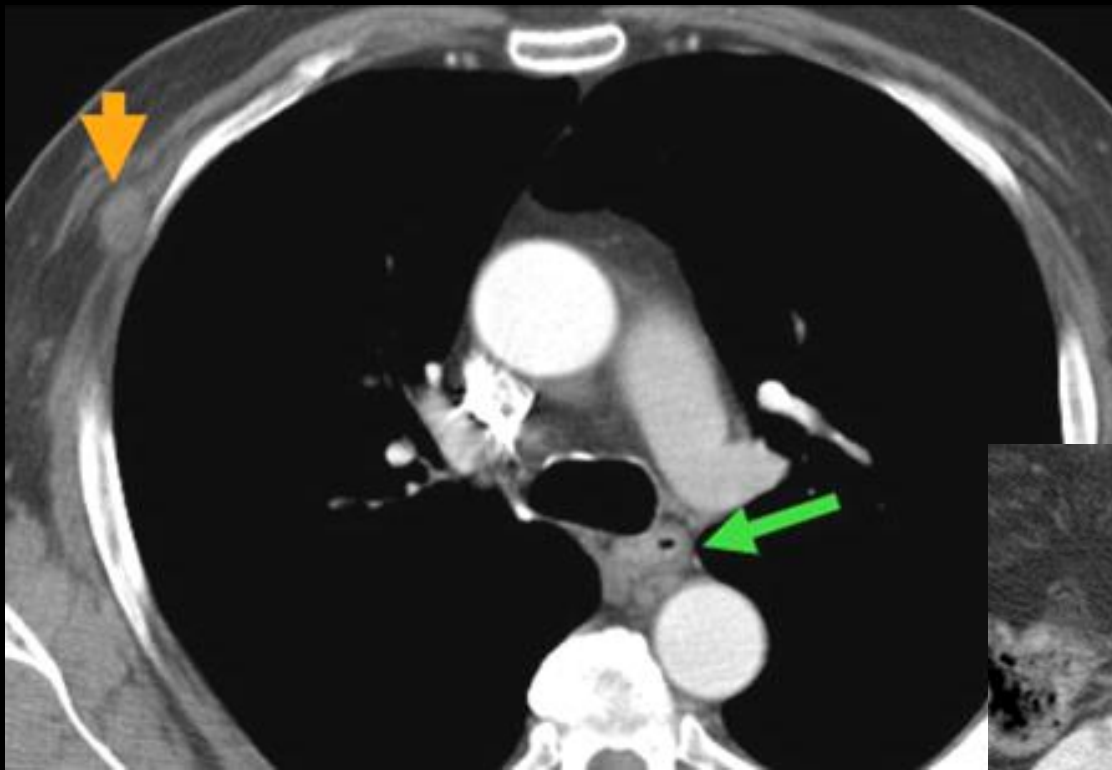


**leiomyome oesophagien**

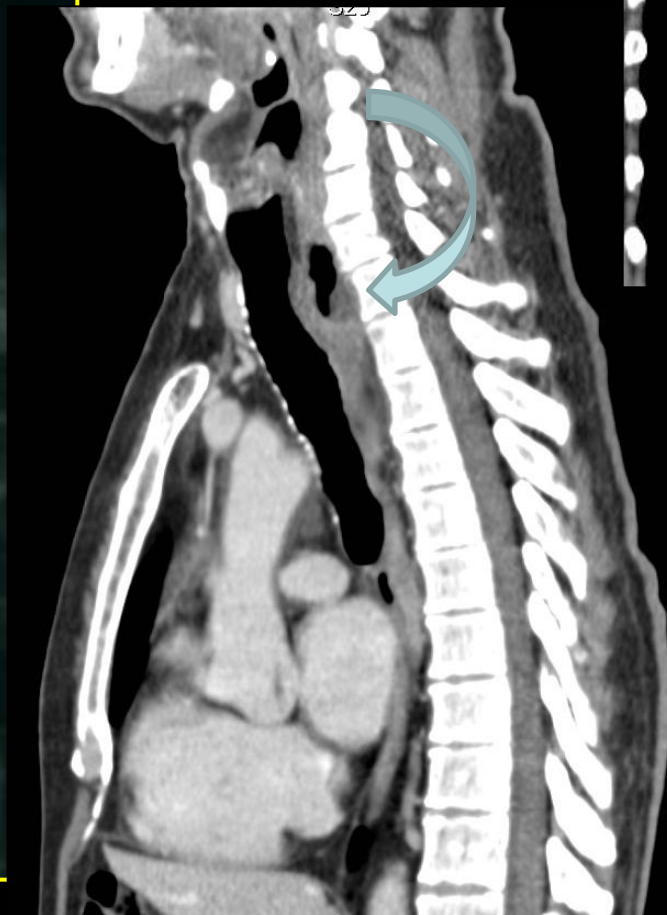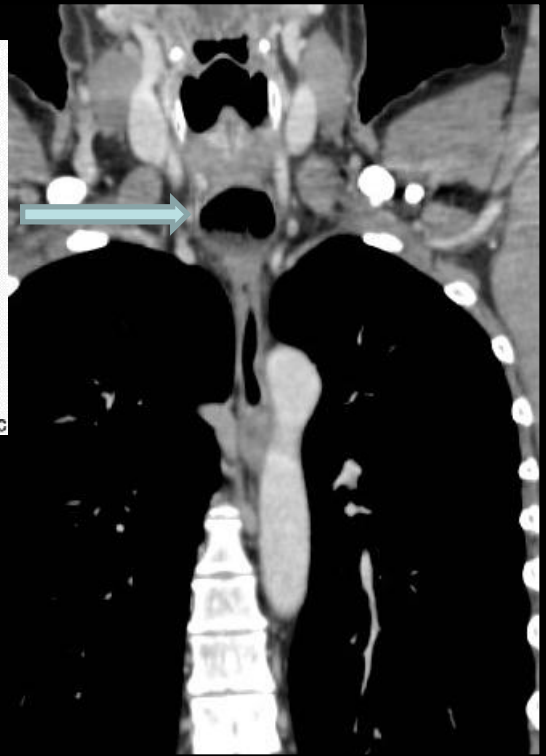
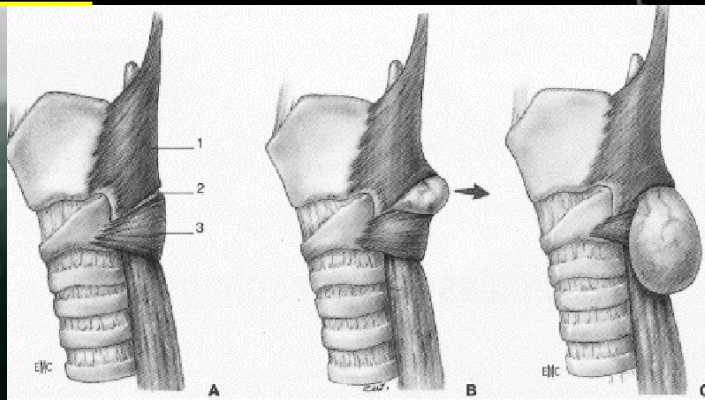

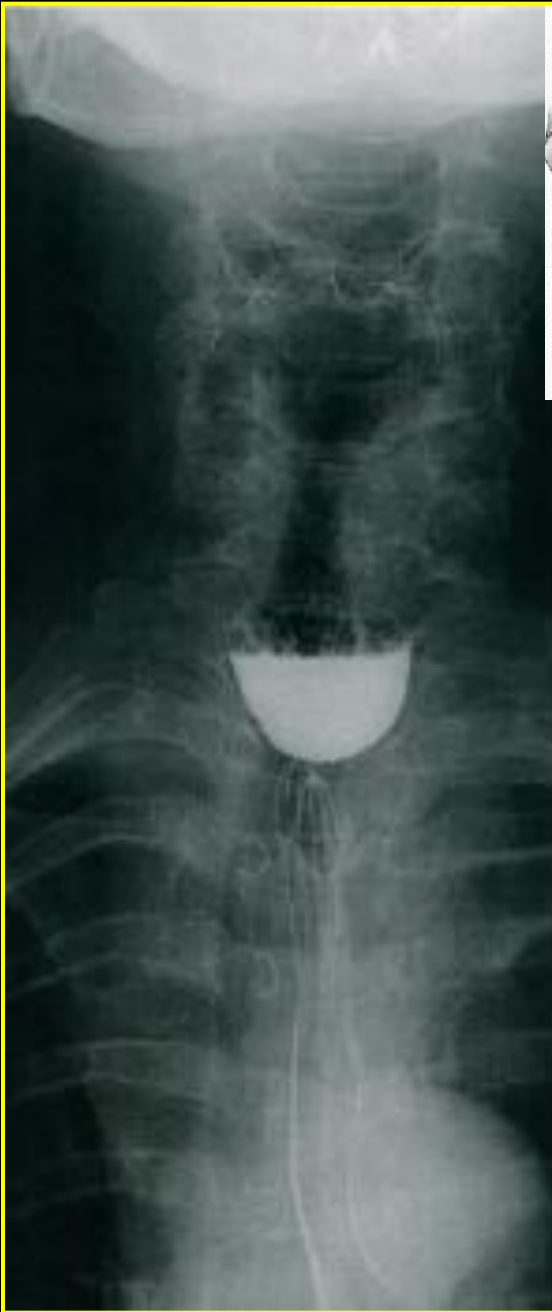


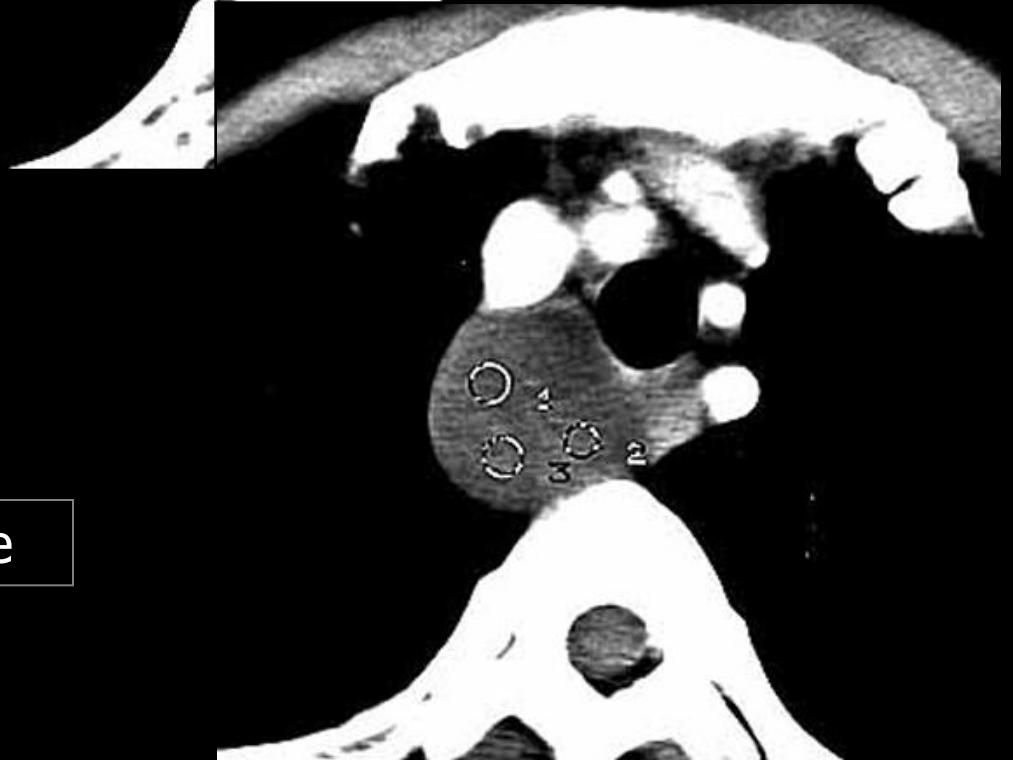
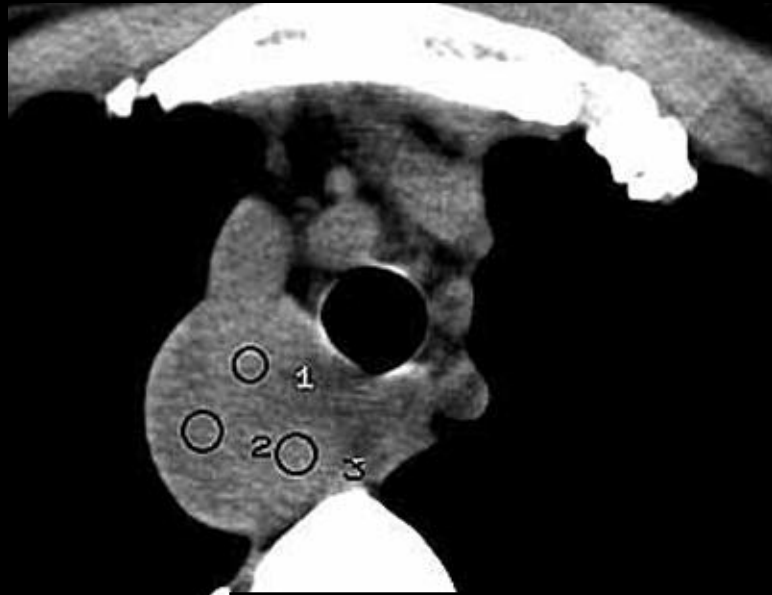
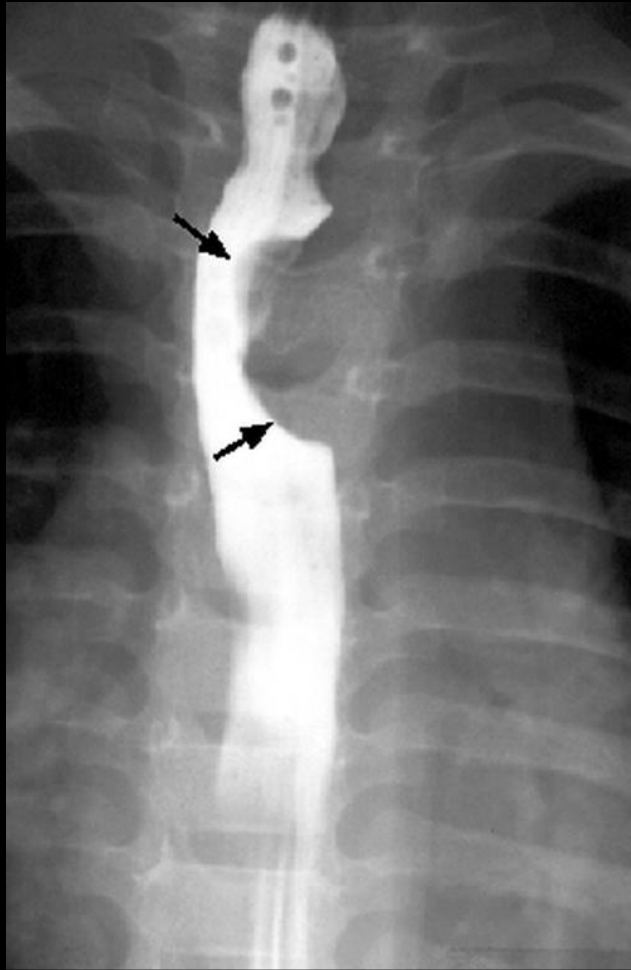**carcinome épidermoïde  
de l'oesophage**



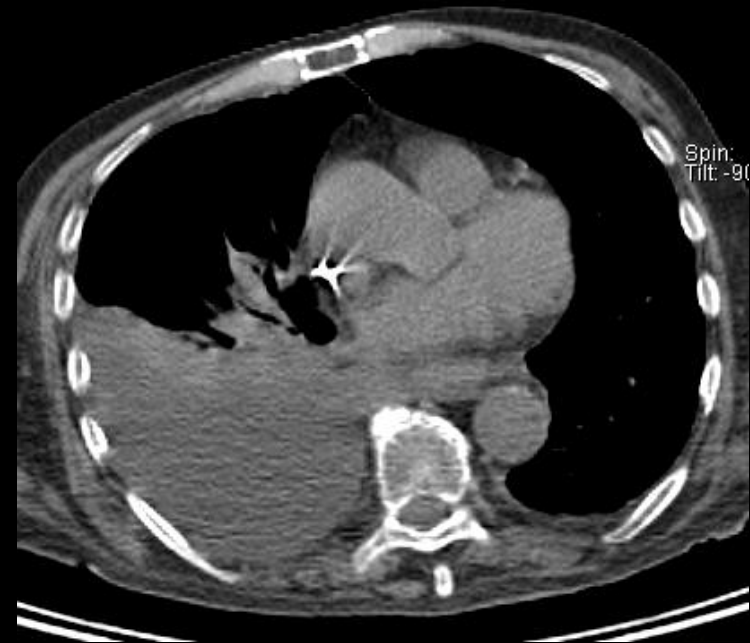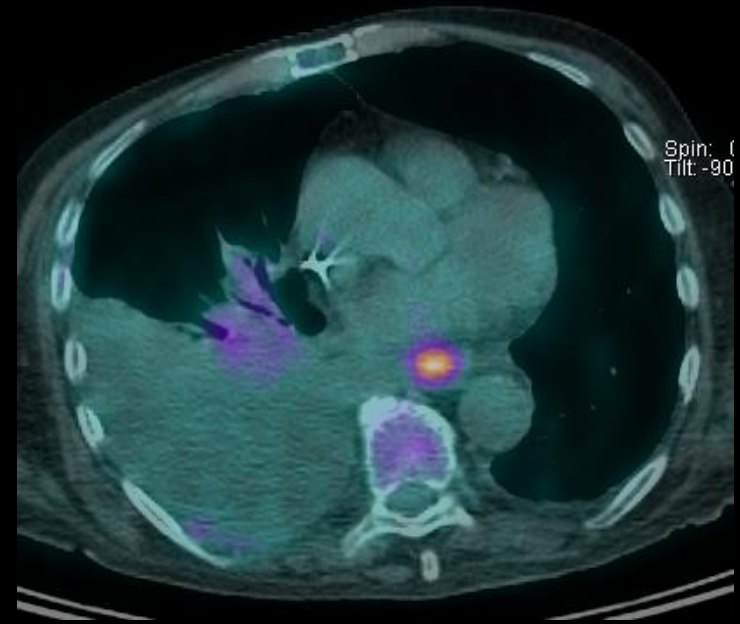
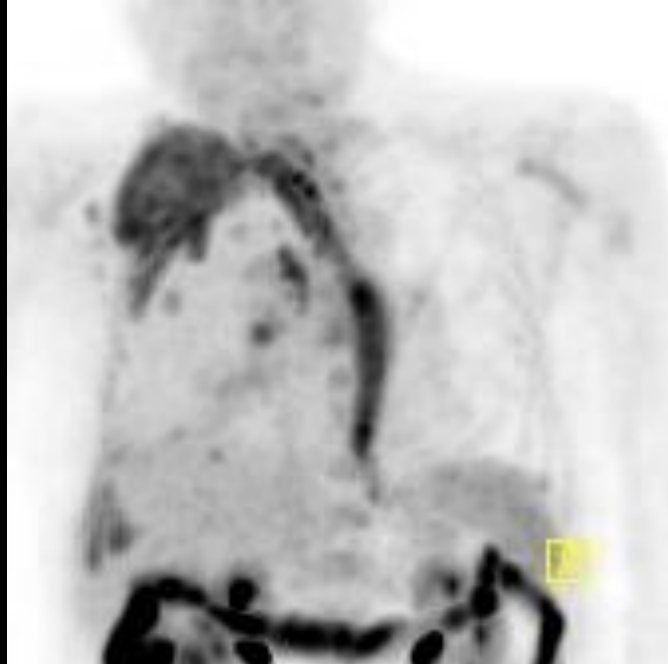Carcinome épidermoïde  
de l'œsophage  
et métastases



**Diverticule de Zenker symptomatique**



Duplication oesophagienne



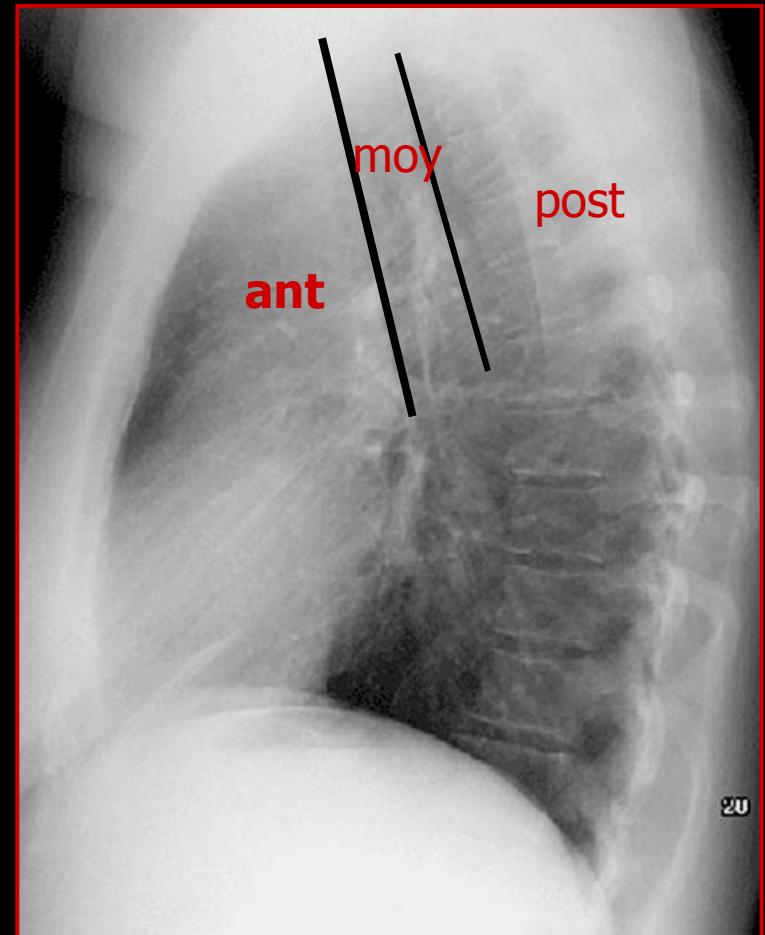
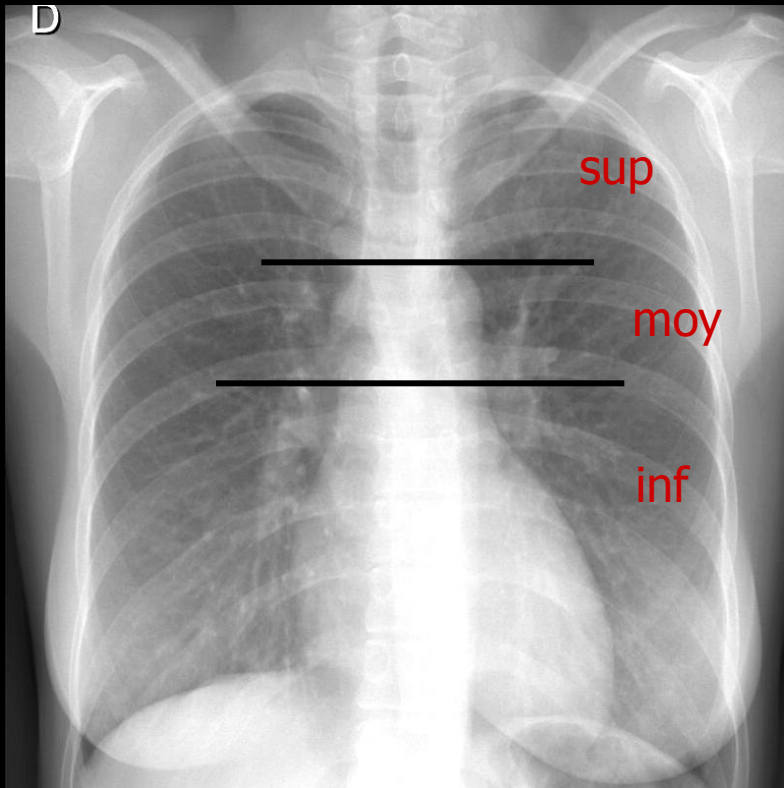
oesophagite

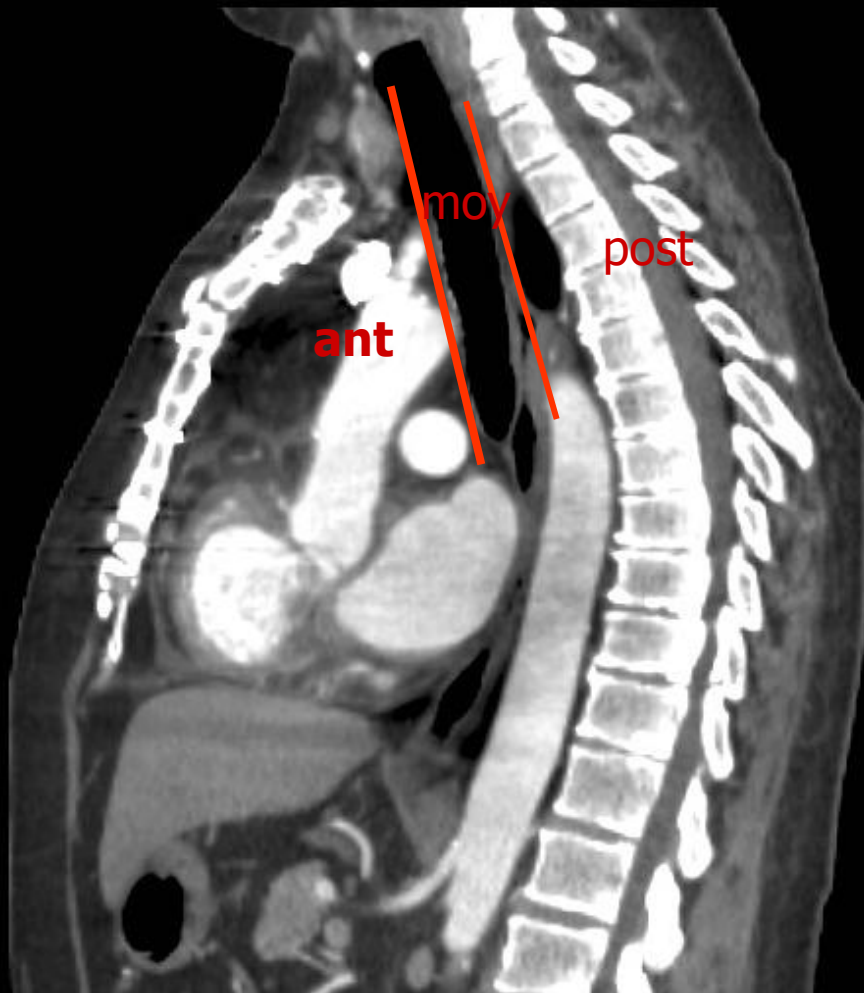
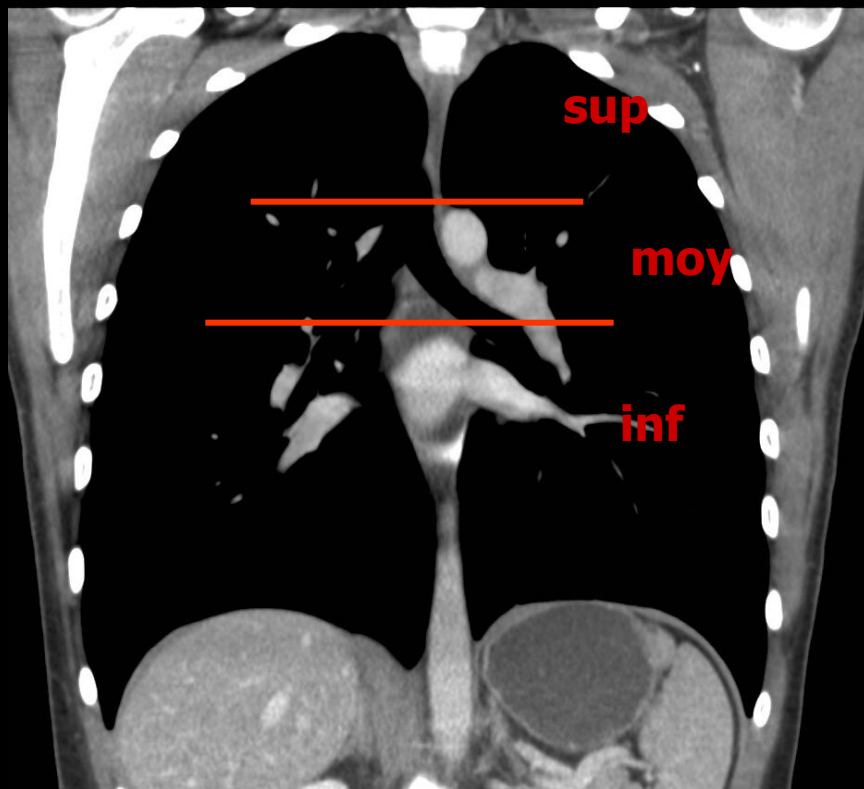


## 2/ RADIOANATOMIE DU MEDIASTIN

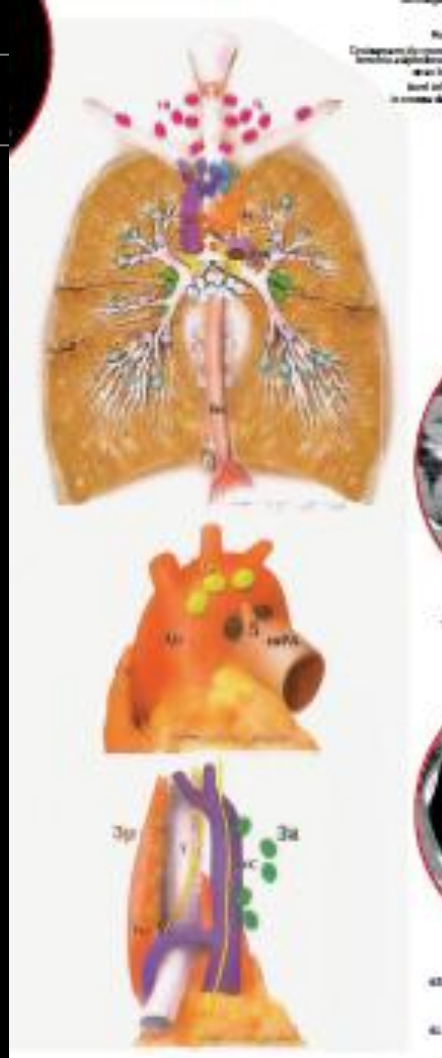
- VAISSEAUX
- CŒUR
- ŒSOPHAGE
- **CHAINES GANGLIONNAIRES**

# Les régions du médiastin





# Les loges ganglionnaires du médiastin



### SUPRACLAVICULAR ZONE

1 Lower cervical, supraclavicular, and internal thoracic nodes

### Upper Mediastinal Nodes

Upper zone

- 2r Upper paratracheal right
- 2l Upper paratracheal left
- 3r Prevascular
- 3l Prevascular
- 4r Lower paratracheal right
- 4l Lower paratracheal left

### Aortic Nodes

AP zone

- 5 Subcarinal
- 6 Para-aortic (ascending, aorta or pretracheal)

### Inferior Mediastinal Nodes

Subcarinal zone

- 7 Subcarinal

Lower zone

- 8 Parasternal (upper, lower, anterior)
- 9 Pulmonary ligament

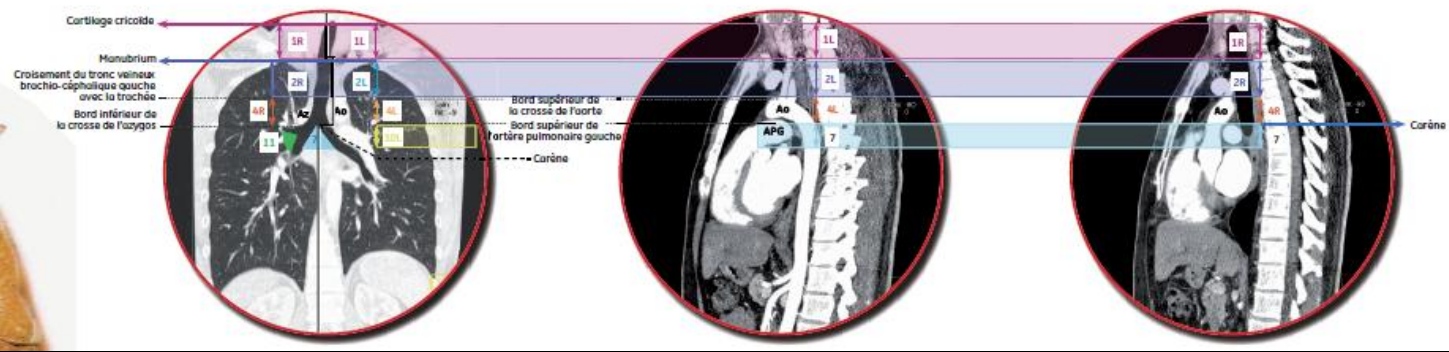
### HILAR NODES

Hilar/interlobar zone

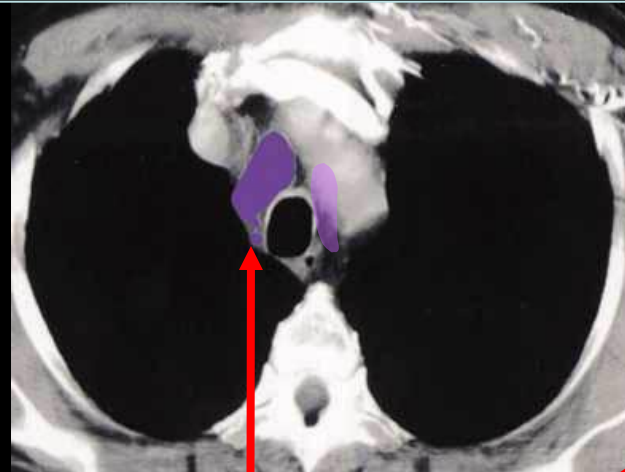- 10 Hilar
- 11 Interlobar

Peripheral zone

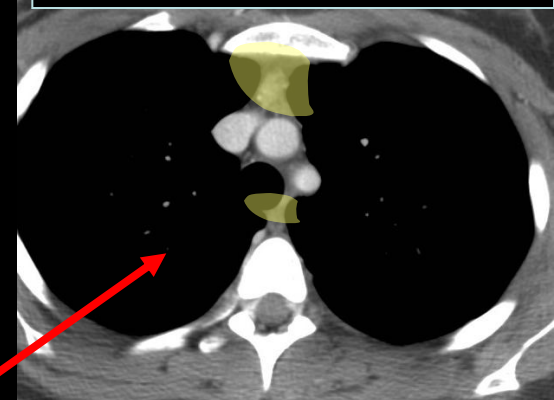- 12 Lower
- 13 Segmental
- 14 Subsegmental



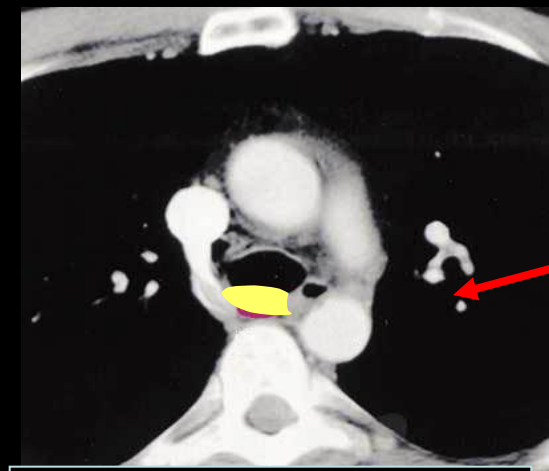
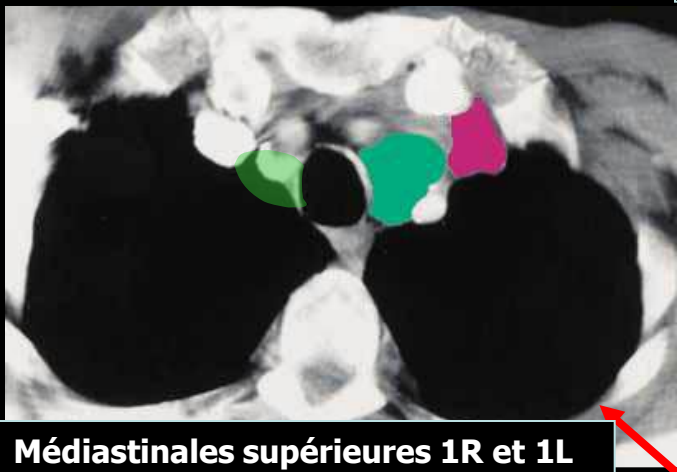
Paratrachéales supérieures 2R et 2L



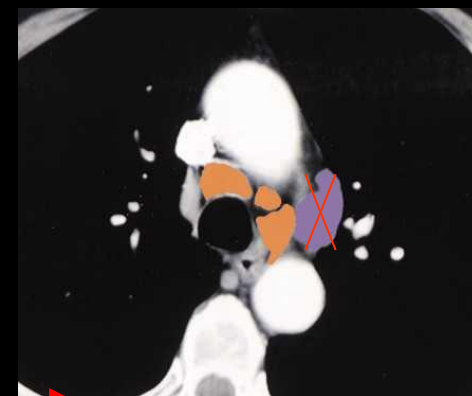
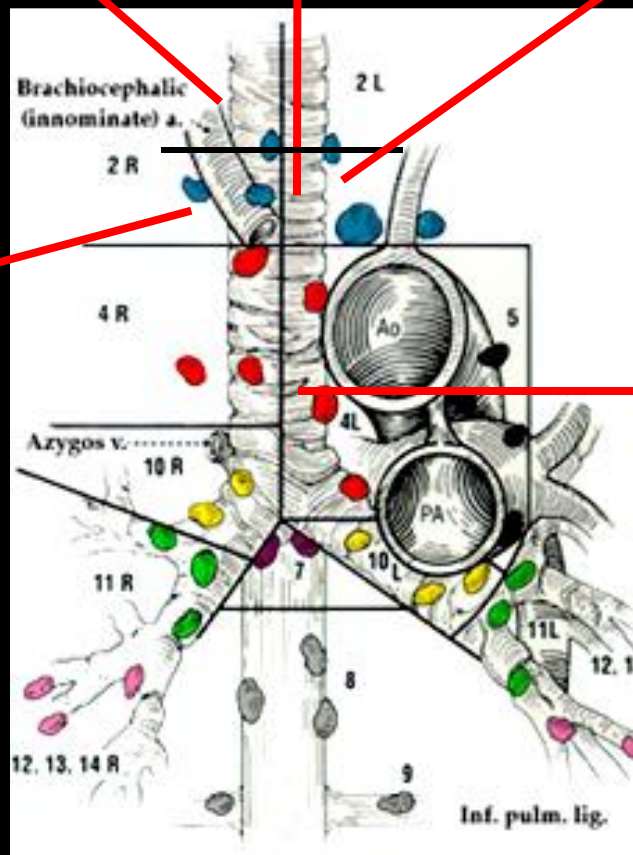
Prévasculaire 3A  
rétrotrachéale 3R



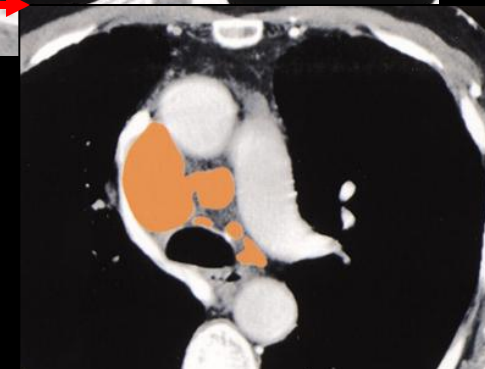
Médiastinales supérieures 1R et 1L



rétrotrachéale 3R

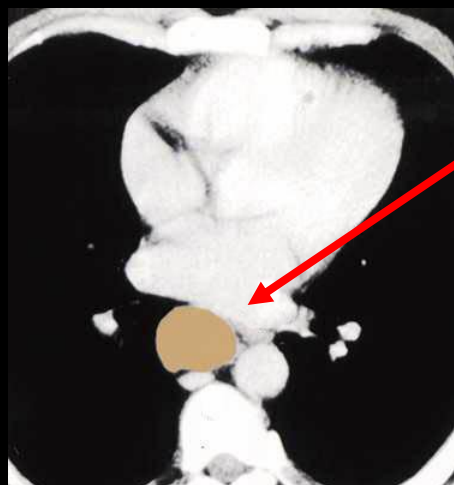
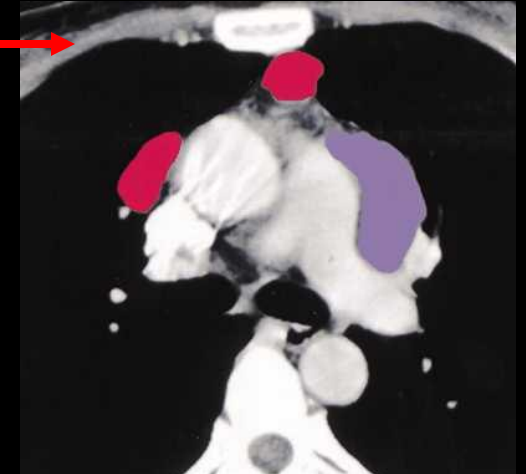
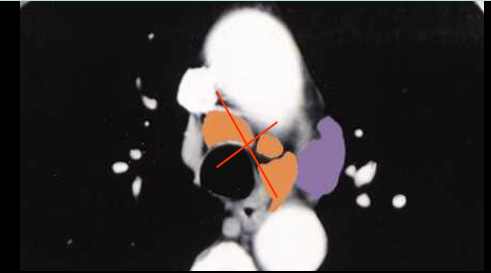
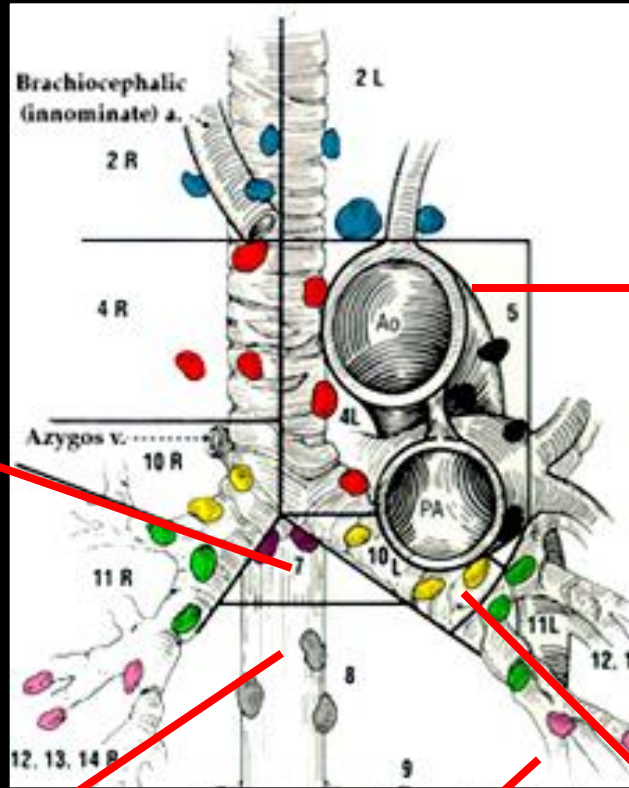
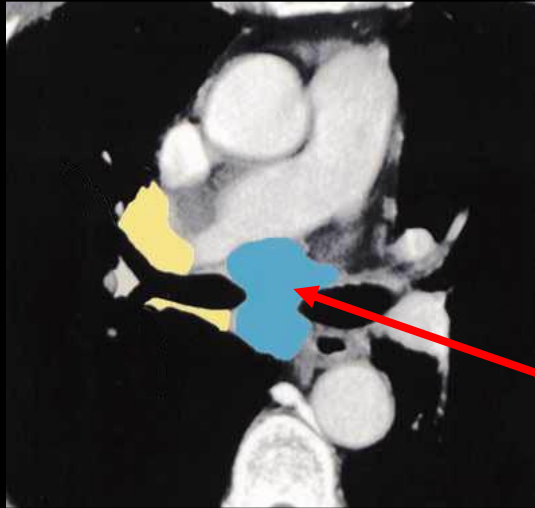


Paratrachéales inférieures  
droite et gauche 4R et 4 L

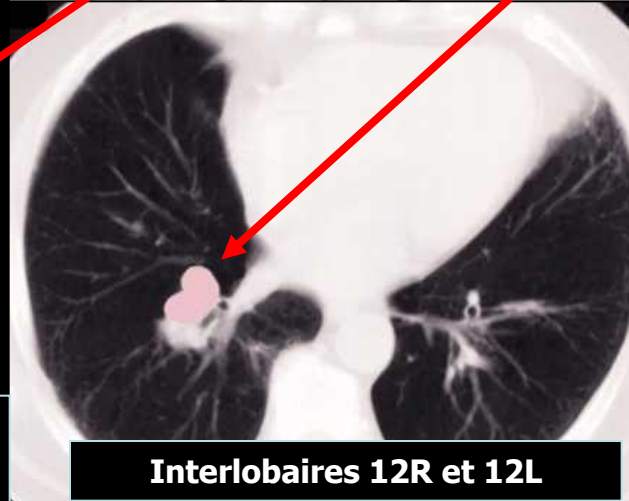


Fenêtre aorto pulmonaire 5

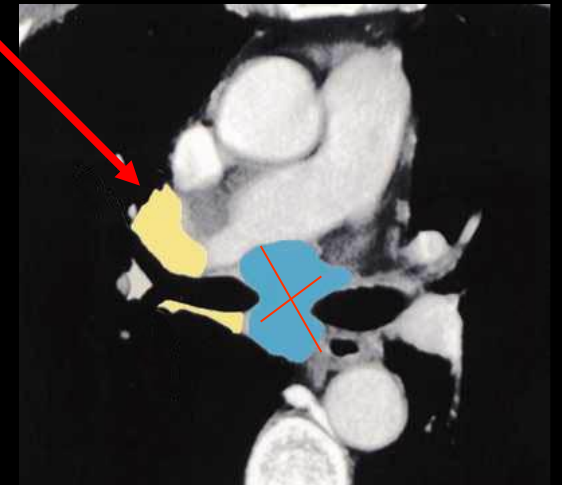
Sous carinaires 7



Para oesophagienne 8  
Œsophage sous carinaire



Interlobaires 12R et 12L









Hilaires 10R et 10L

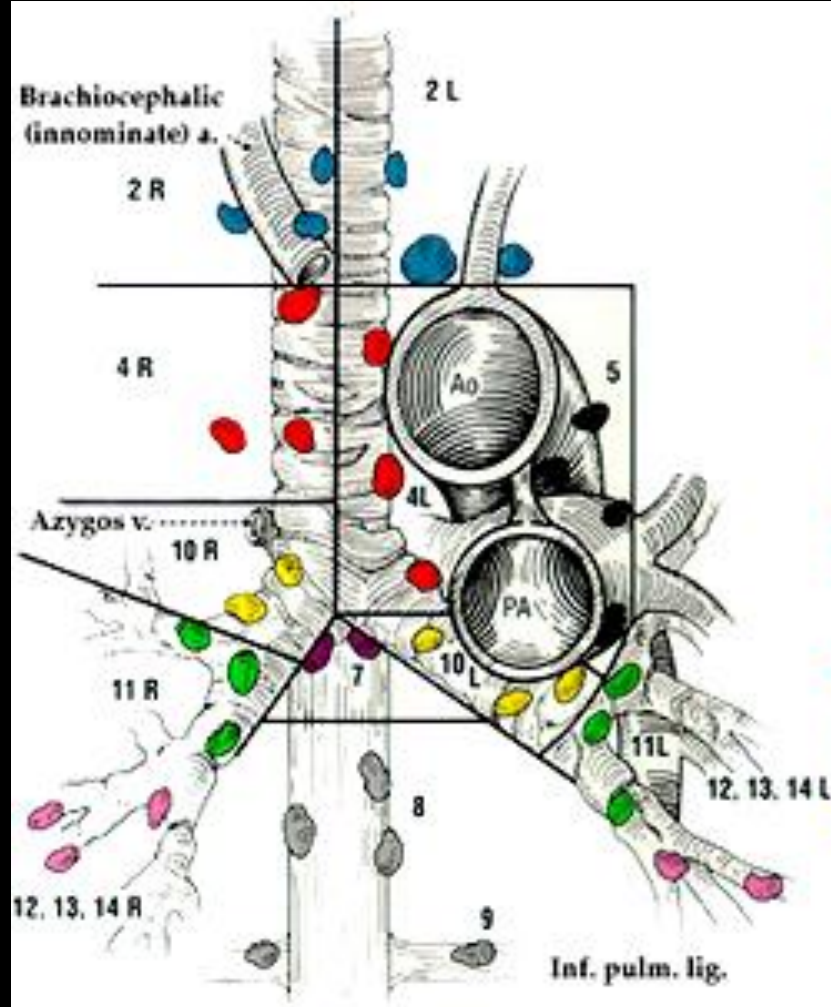
# Regional Nodal Stations For Lung Cancer Staging

## N<sub>1</sub> NODES

### SUPERIOR MEDIASTINAL NODES

### LOCATION

- |   |   |  |
|---|---|--|
|    | 2R Right upper paratracheal nodes       | Between intersection of caudal margin of innominate a. with trachea and the apex of the lung (supra-innominate nodes). |
|    | 2L Upper left paratracheal nodes        | Between top of aortic arch and apex of the lung (supra-aortic nodes).  |
|    | 4R Right lower paratracheal nodes       | Between intersection of caudal margin of innominate a. with trachea and cephalic border of azygos v.                   |
|    | 4L Left lower paratracheal nodes        | Between top of aortic arch and carina (medial to ligamentum arteriosum)  |
|    | 10R Right tracheo-bronchial angle nodes | From cephalic border of azygos v. to origin of RUL bronchus.   |
|  | 10L Left tracheo-bronchial angle nodes  | Between carina and LUL (medial to ligamentum arteriosum).  |



# CLASSIFICATION TNM

Tx	Tumeur prouvée par la cytologie bronchique, mais non visualisée ni à la radio, ni en bronchoscopie	T3	Tumeur <b>&gt;7cm</b> OU avec <b>envahissement direct</b> de: <ul style="list-style-type: none"> <li>o Paroi thoracique (y compris la tumeur de Pancoast Tobias)</li> <li>o Diaphragme</li> <li>o Nerf phrénique</li> <li>o Plèvre médiastinale</li> <li>o Péricarde pariétal</li> </ul> OU une tumeur dans la bronche souche <b>≤ 2 cm de la carène sans l'envahir</b> OU associée à une atélectasie ou une pneumopathie obstructive <b>du poumon entier</b> OU présence d'un <b>nodule(s) tumoral(s) distinct dans le même lobe</b>
T0	Pas de tumeur primaire	T4	Tumeur de toute taille envahissant <b>directement une des structures suivantes</b> : médiastin, cœur, gros vaisseaux, trachée, nerf laryngé récurrent, oesophage, corps vertébral, carène, OU nodule(s) tumoral(s) distinct <b>homolatéral dans un autre lobe</b>
Tis	Carcinome in situ		
T1	Tumeur de 3cm ou moins, entourée de parenchyme pulmonaire ou de plèvre, sans invasion des bronches lobaires proximales		
T1a	<b>≤ 2 cm</b>		
T1b	<b>2 cm et ≤ 3cm</b>		
T2	Tumeur <b>&gt;3cm</b> mais <b>≤ 7cm</b> ou tumeur <b>≤ 7cm</b> avec un des critères: <ul style="list-style-type: none"> <li>o Envahissement de la <b>plèvre viscérale</b></li> <li>o Associée à une <b>atélectasie ou pneumonie obstructive</b> pouvant s'étendre à la région hilare mais n'intéressant <b>pas tout un poumon</b></li> <li>o Tumeur envahissant la bronche lobaire principale mais <b>≥ 2cm de la carène</b></li> </ul>		
T2a	<b>&gt;3cm</b> mais <b>≤ 5cm</b>		
T2b	<b>&gt;3cm</b> mais <b>≤ 7cm</b>		



# Détermination du N

- Nx: non évalué
- N0: absence d'envahissement ganglionnaire
- N1: Envahissement ganglionnaire **intra-pulmonaire, péribronchique et/ou hilare homolatéral** y compris par envahissement direct
- N2: Envahissement ganglionnaire **médiastinal homolatéral et/ou sous carénaire**
- N3: Envahissement ganglionnaire **médiastinal et hilare controlatéral, sus claviculaire, scalène, homo- ou controlatéral**

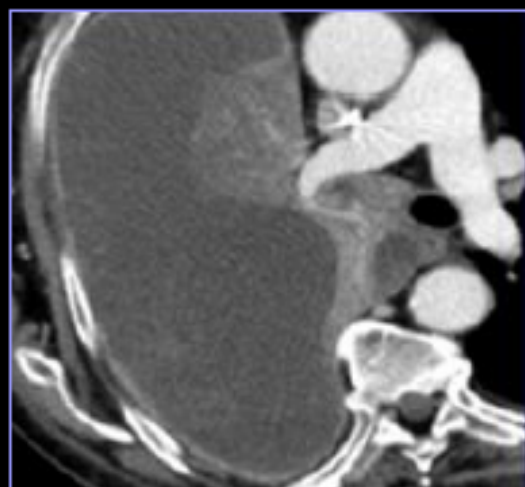Rusch VW, The IASLC Lung Cancer Staging Project: proposals for the revision of the N descriptors in the forthcoming seventh edition of the TNM classification for lung cancer. J Thorac Oncol 2007 ; 2 : 803-12

**Rôle respectifs du PET CT +++ et de la médiastinobiopsie pour le diagnostic d'envahissement des ganglions contro-latéraux**



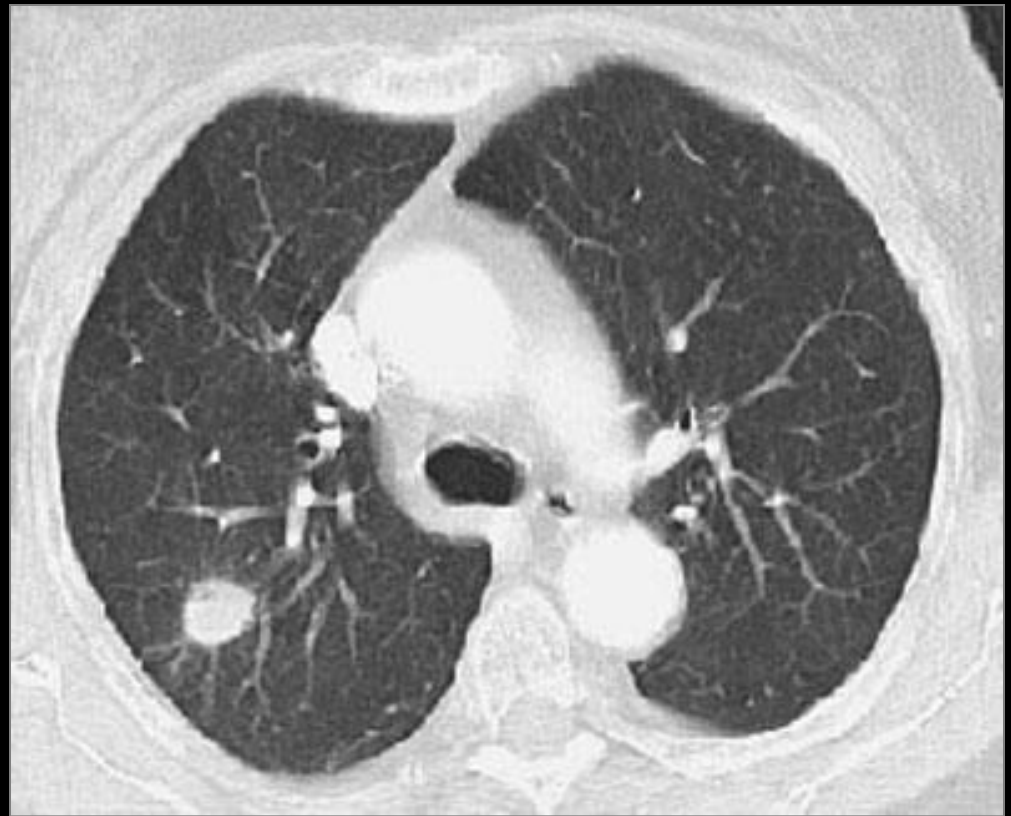
# Détermination du M

- Peu modifiée
- M0: pas de métastase
- M1: métastase à distance
- Distinction entre:
  - M1a: métastases pulmonaires
    - Tumeur avec nodules pleuraux ou épanchement pleural ou péricardique malin
    - Nodule(s) tumoral distinct dans un lobe controlatéral,
  - M1b: métastases extra-pulmonaires

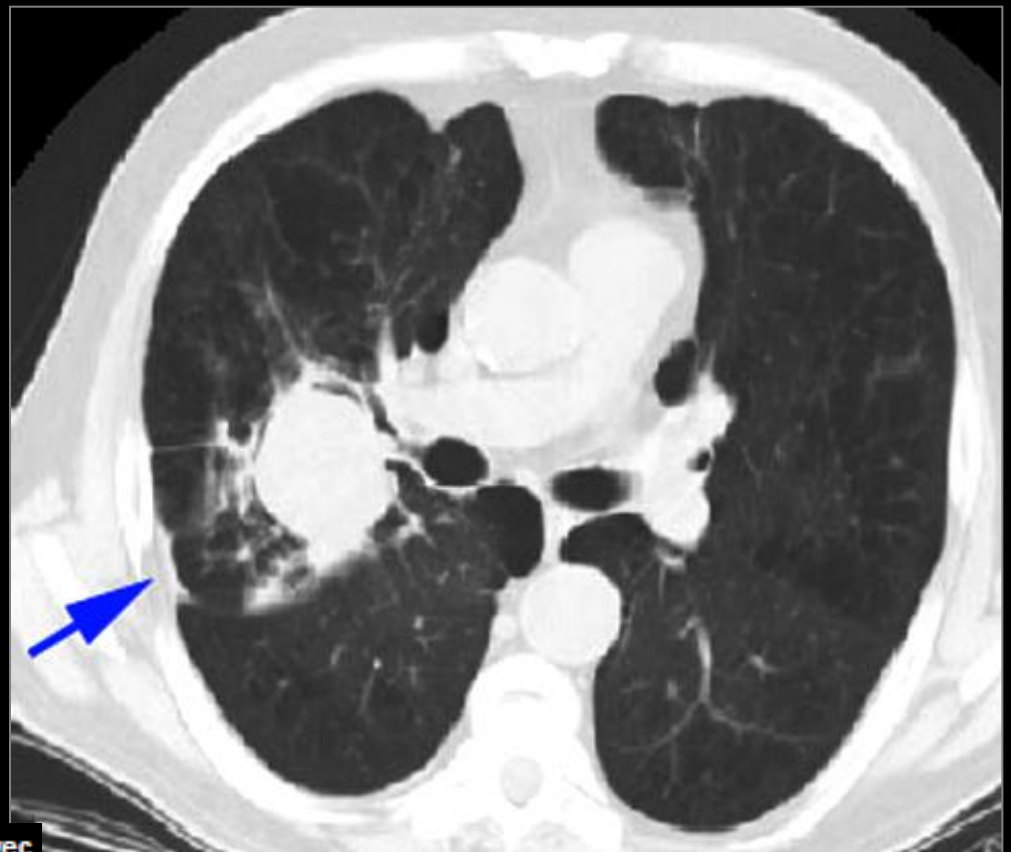


# Quelques exemples

**T1a**

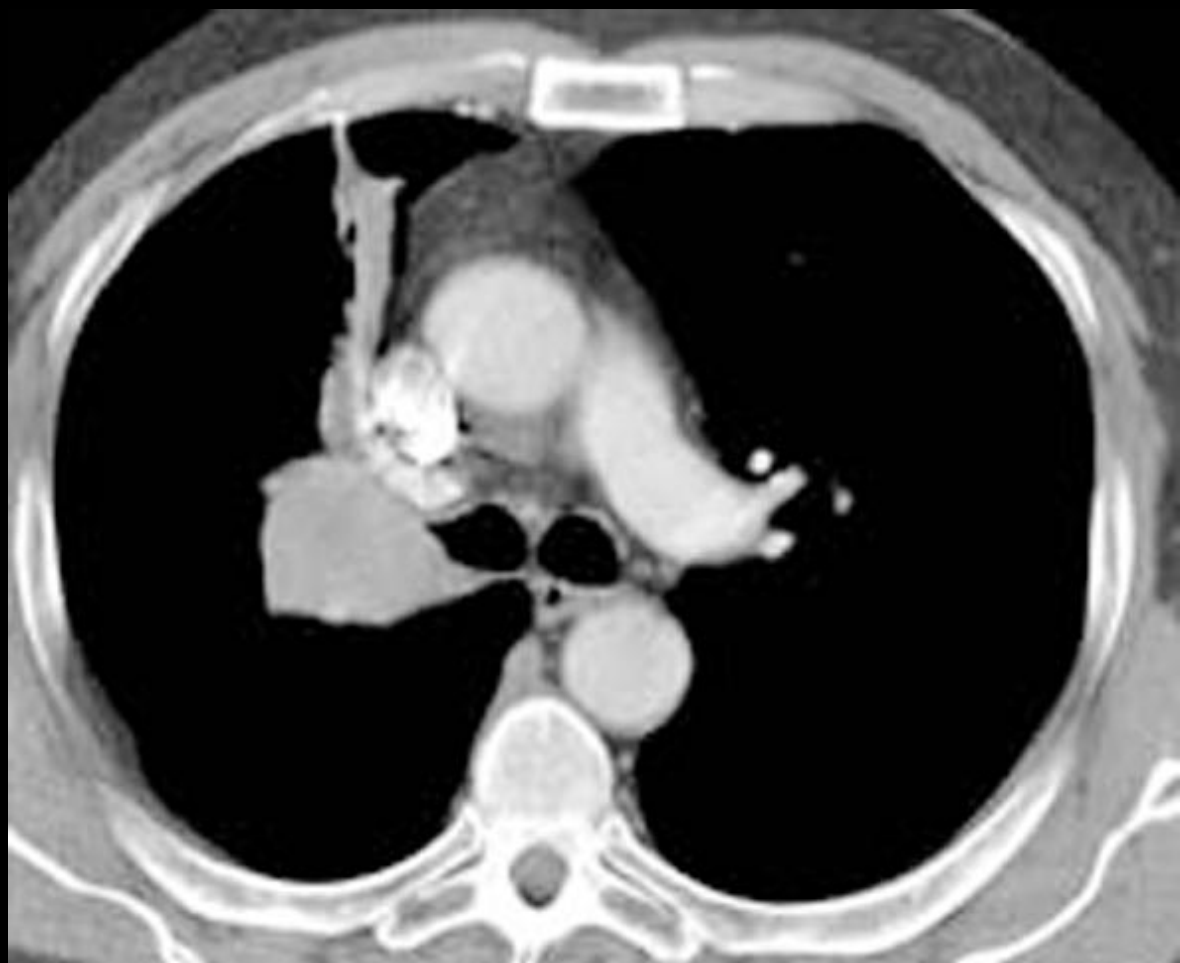

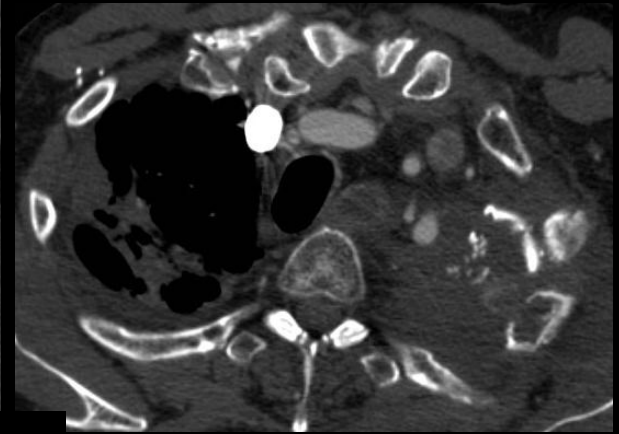
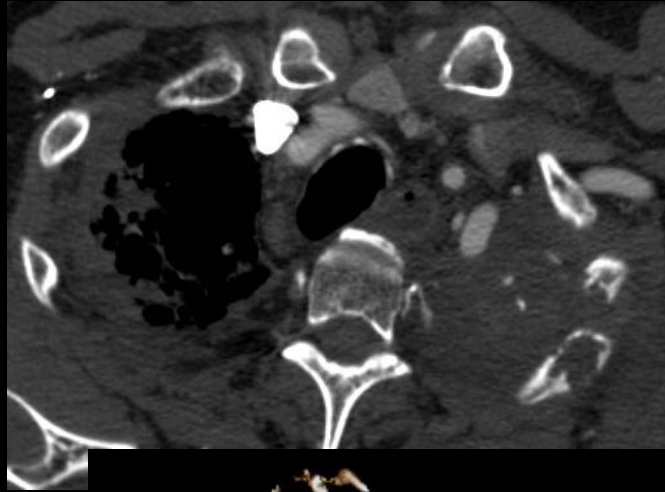
**T2b**



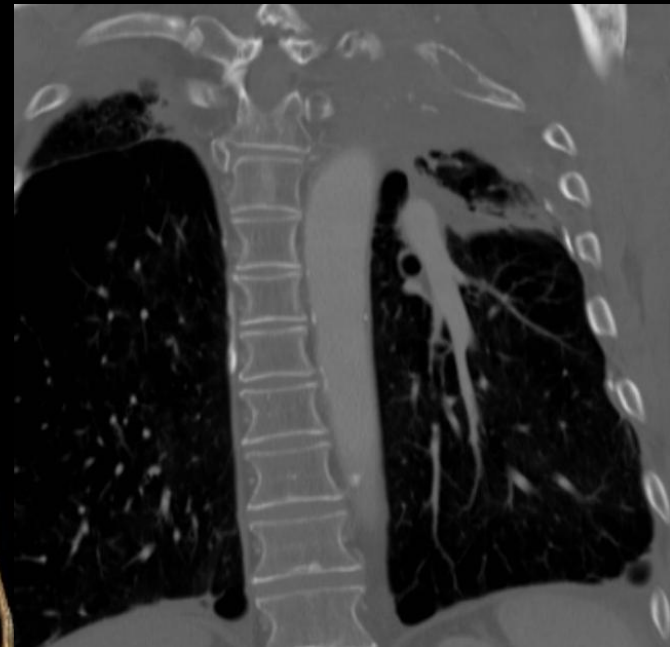
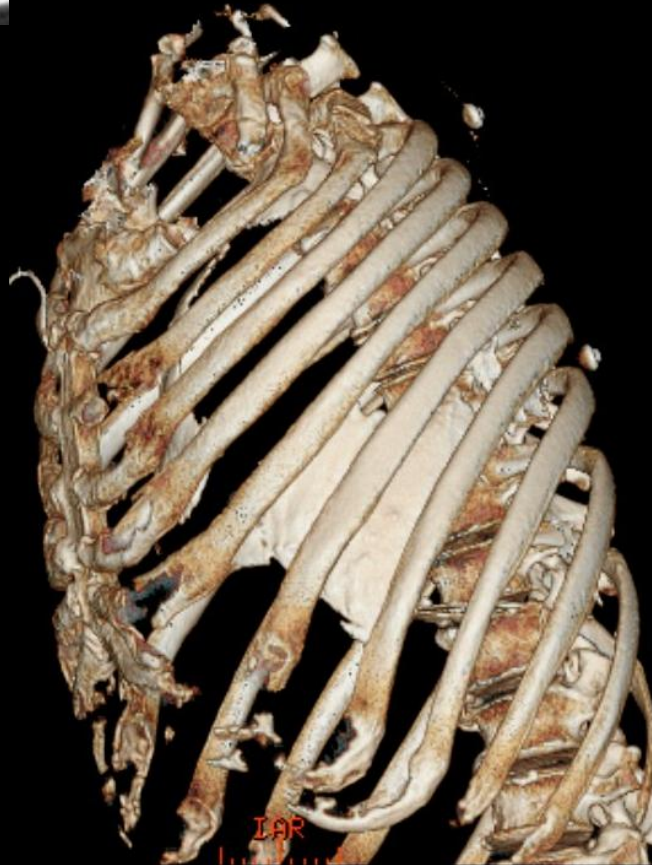T2	Tumeur >3cm mais ≤ 7cm ou tumeur ≤ 7cm avec un des critères: <ul style="list-style-type: none"><li>o Envahissement de la <b>plèvre viscérale</b></li><li>o Associée à une <b>atélectasie ou pneumonie obstructive</b> pouvant s'étendre à la région hilare mais n'intéressant <b>pas tout un poumon</b></li><li>o Tumeur envahissant la bronche lobaire principale mais <b>≥ 2cm de la carène</b></li></ul>
T2a	>3cm mais ≤ 5cm
T2b	>3cm mais ≤ 7cm

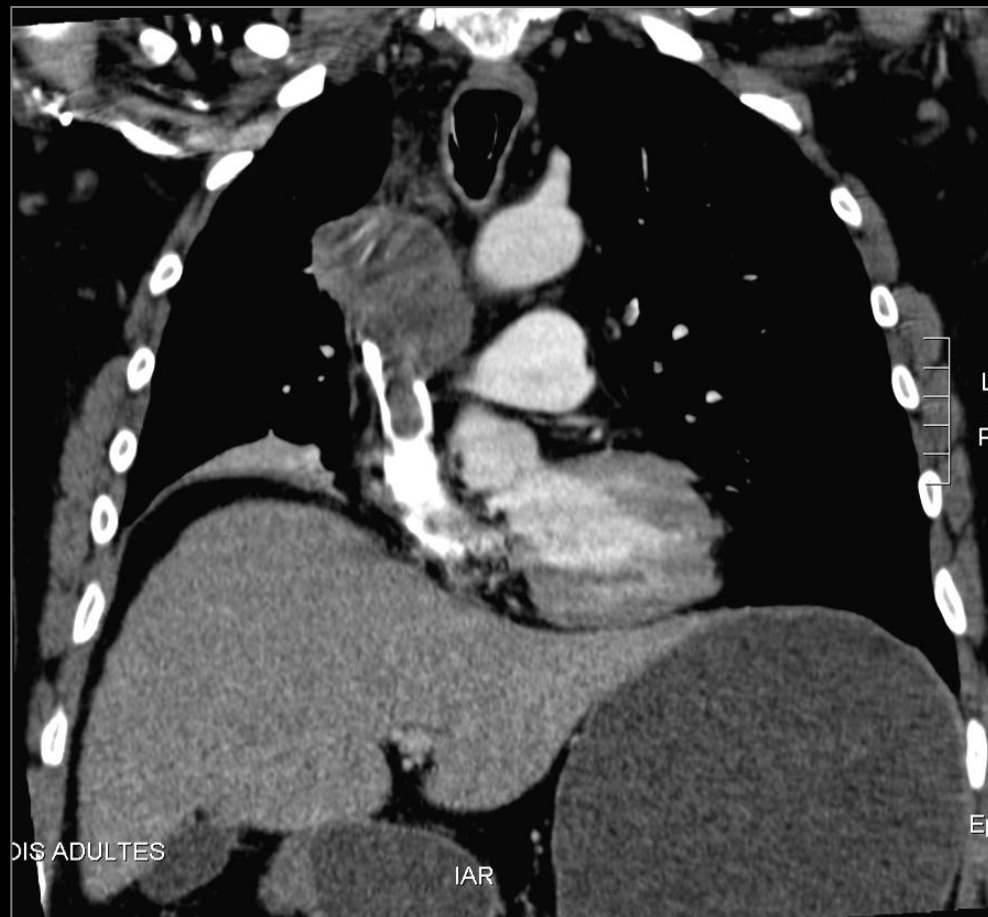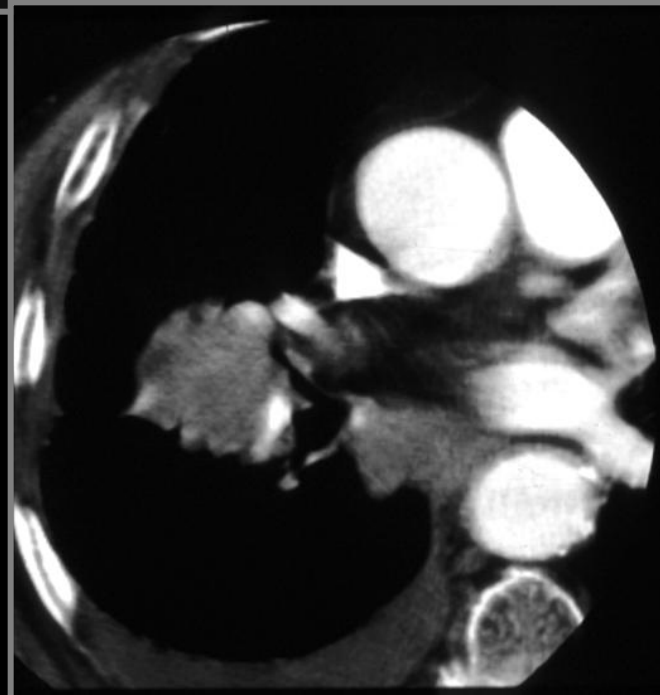
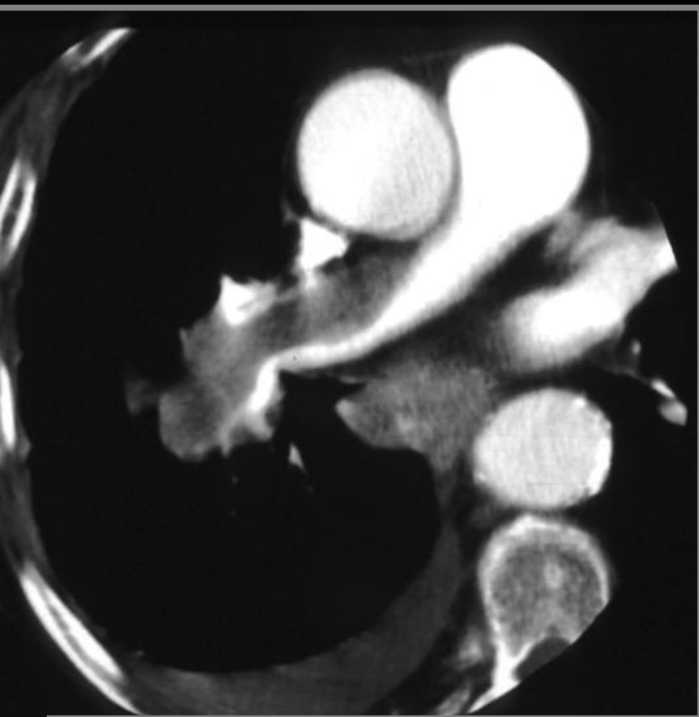
**T3**





**T4:**  
**Pancoast**  
**Tobias**





**Extension vasculaire T4**

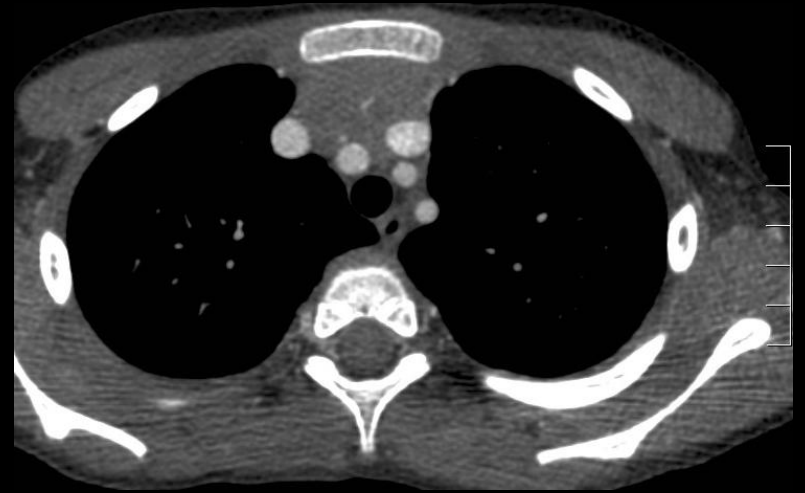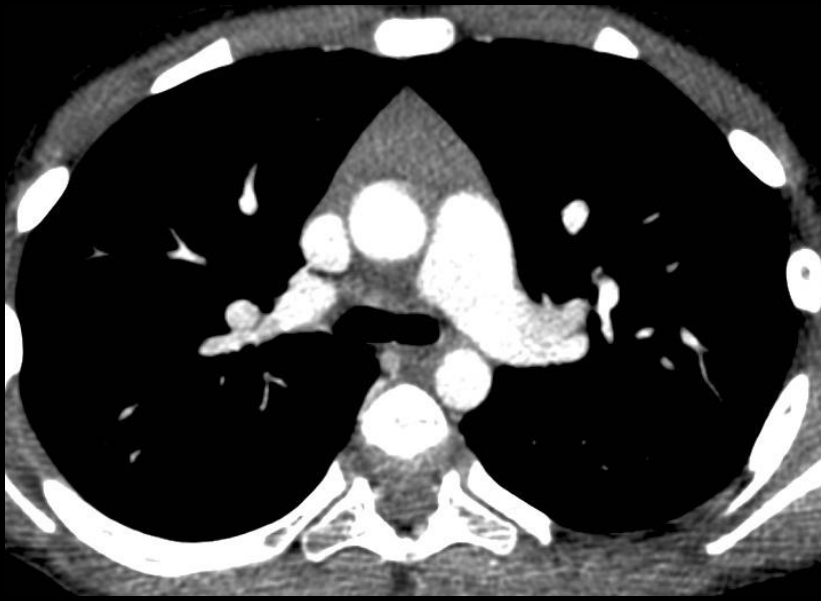## Principaux changements 1997 vs 2009 :

1. T4 nodule même lobe → T3
2. T4 dissémination pleurale ou péricardique → M1
3. M1 nodule supplémentaire autre lobe ipsilatéral → T4

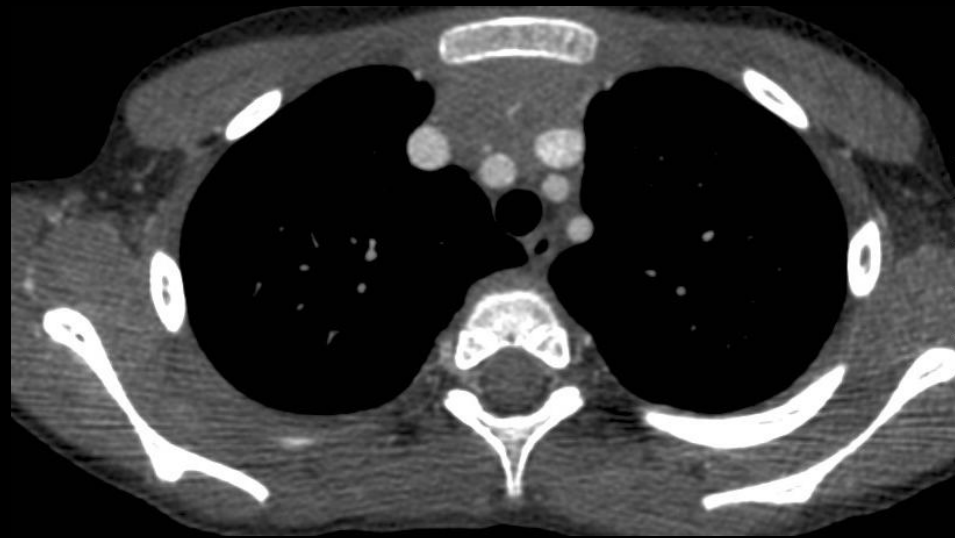- Reclasser la dissémination pleurale de T4 à M1a
- Classer la présence de nodules controlatéraux en M1a
- Classer la présence de métastases à distance en M1b

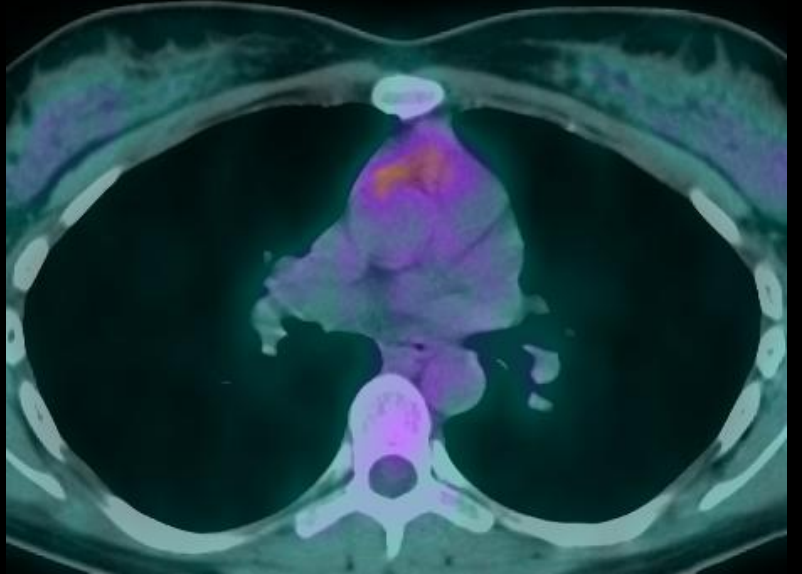
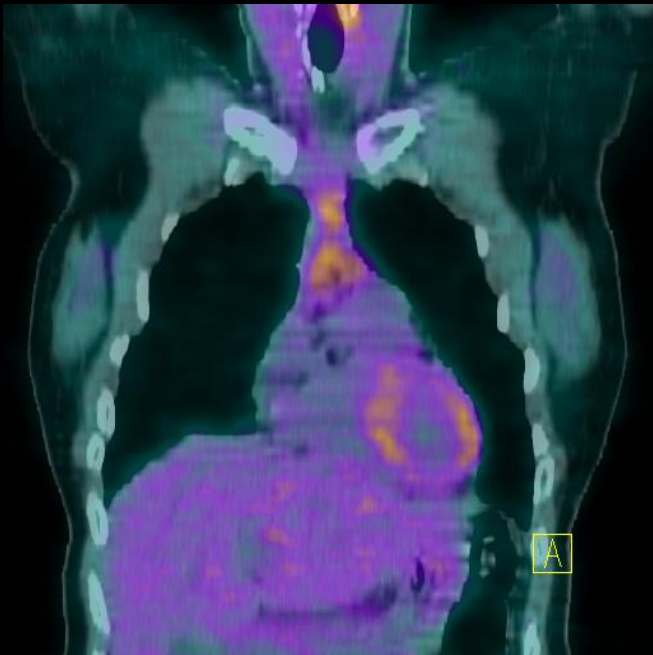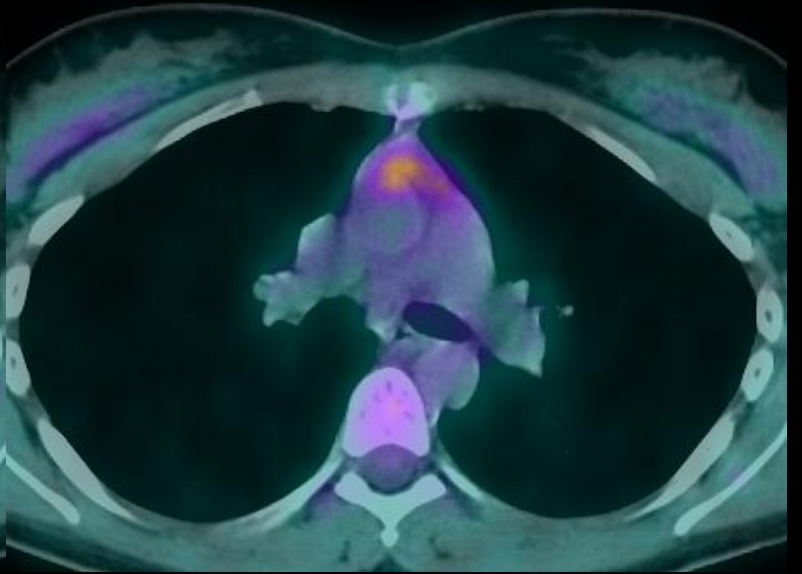
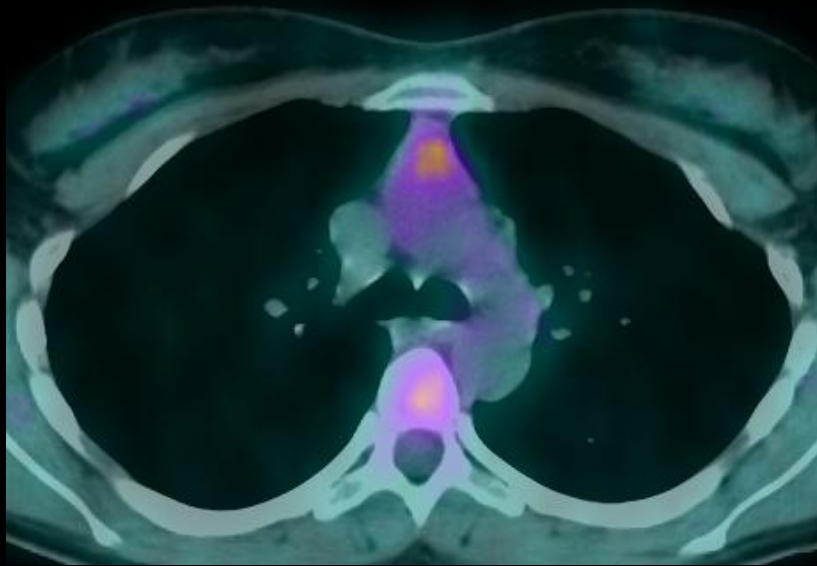


**UN PEU DE PATHOLOGIE ET  
VARIATIONS ANATOMIQUES...**



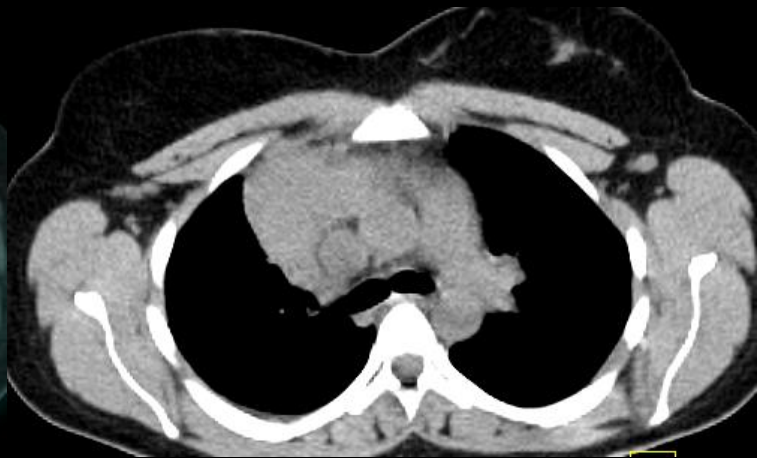
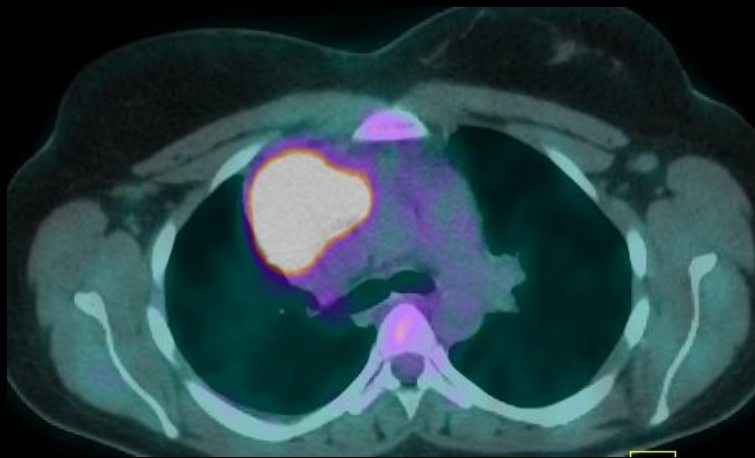
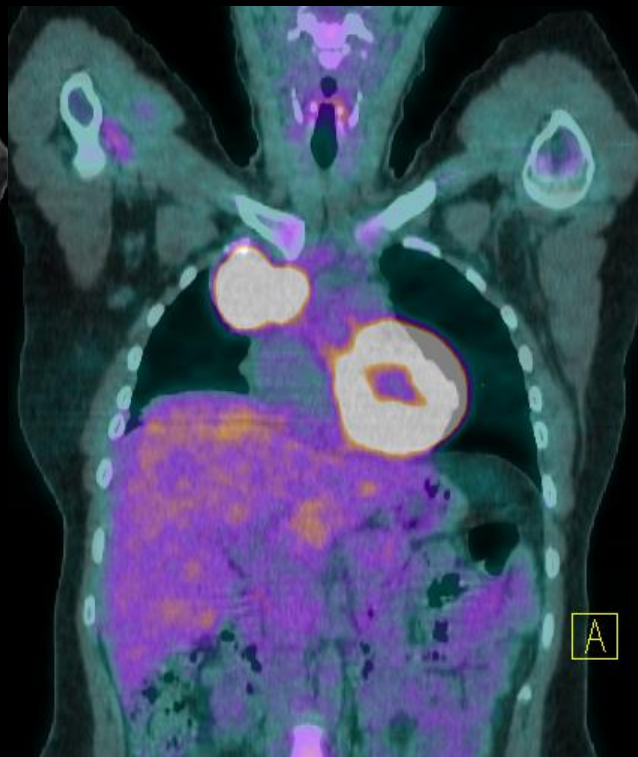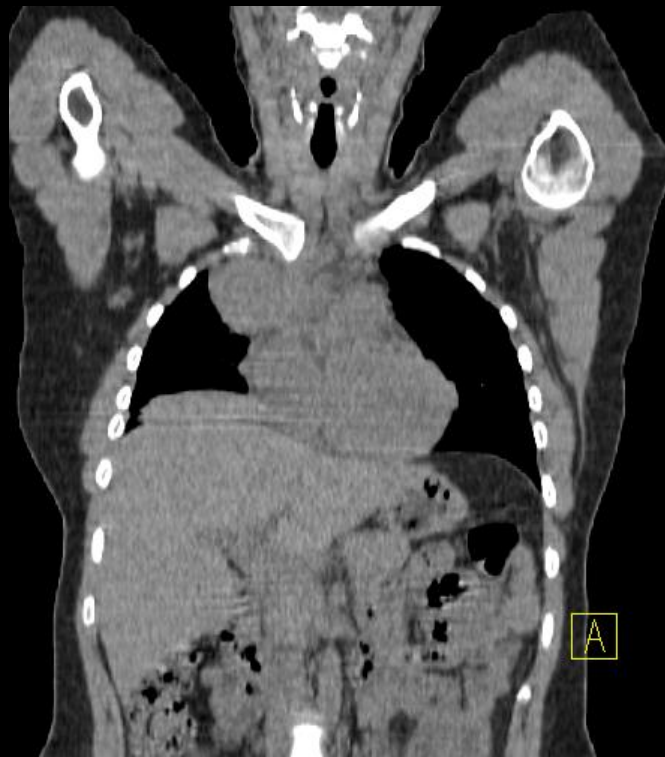
**Thymus**

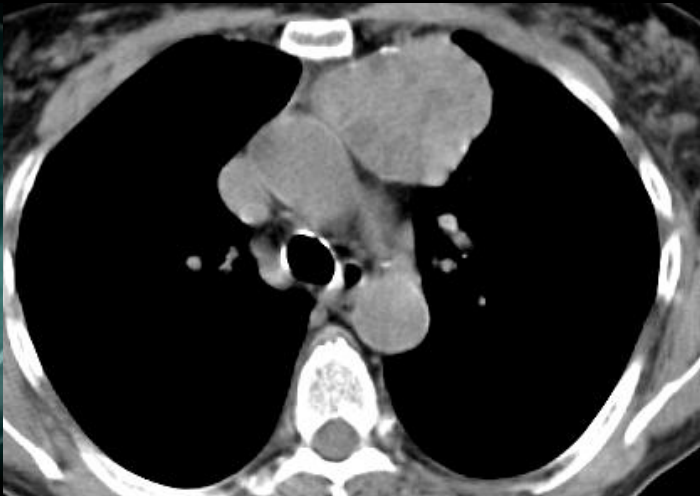
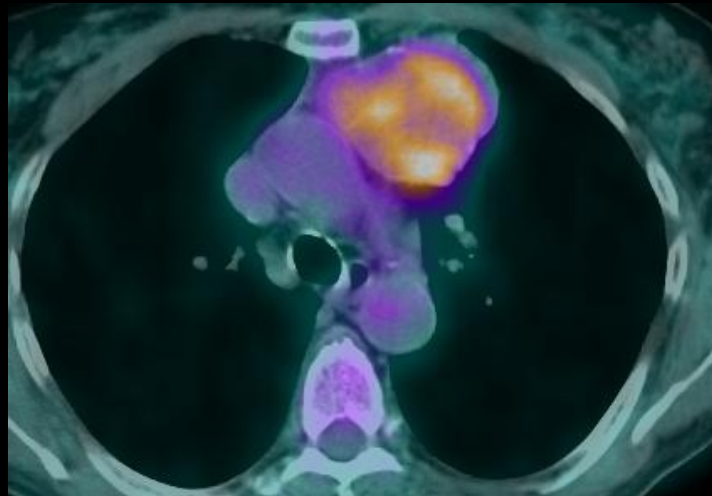
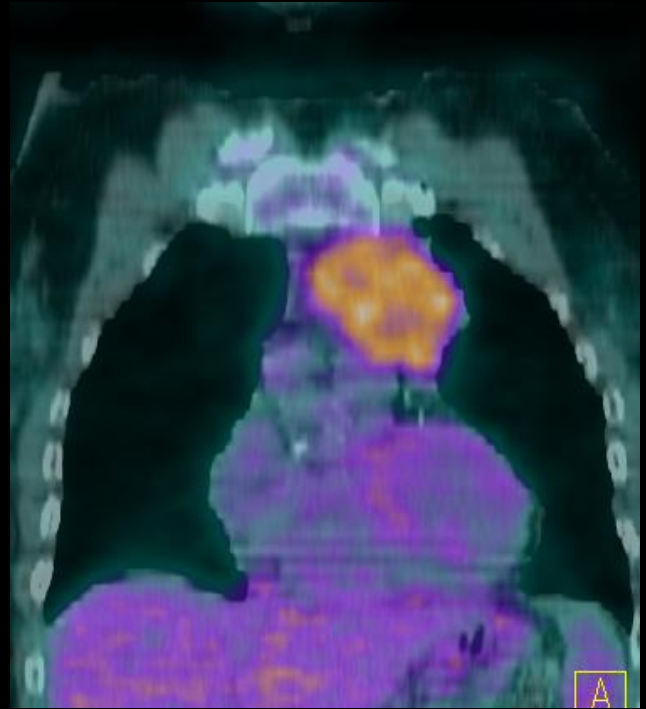
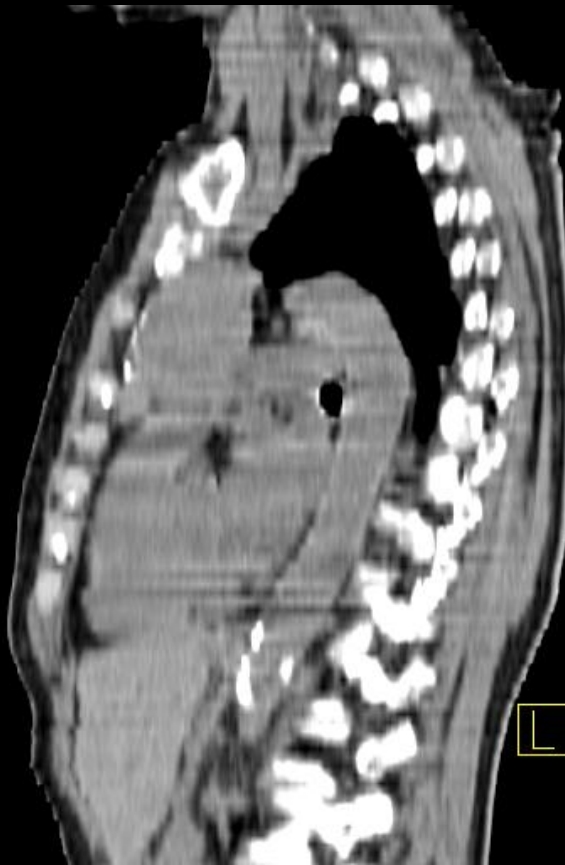
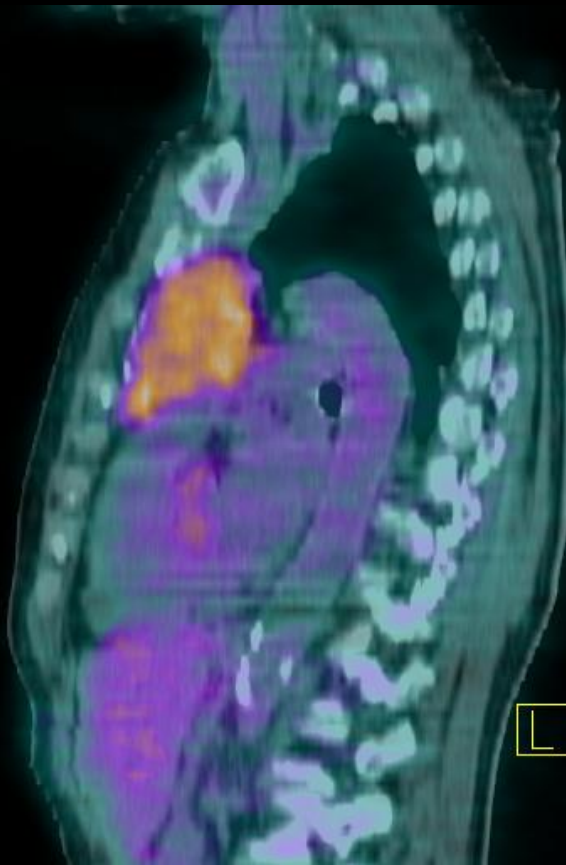




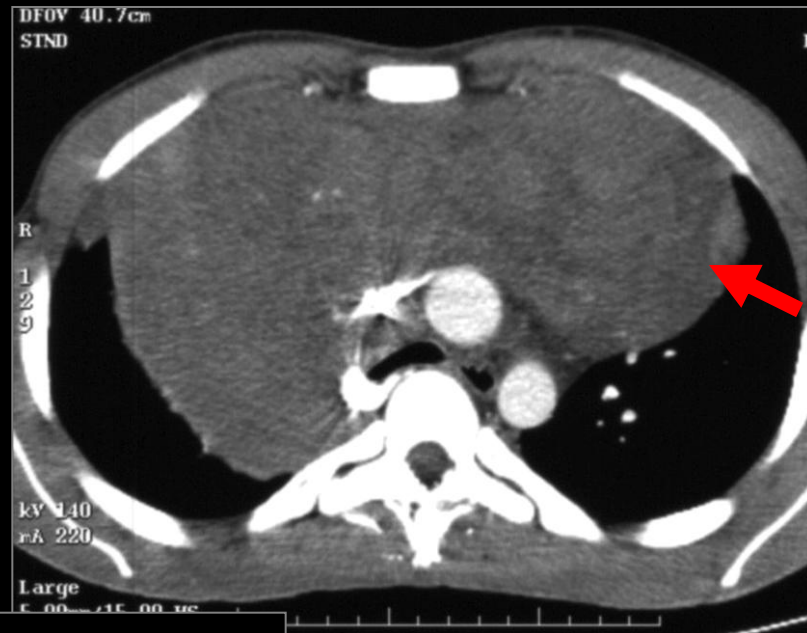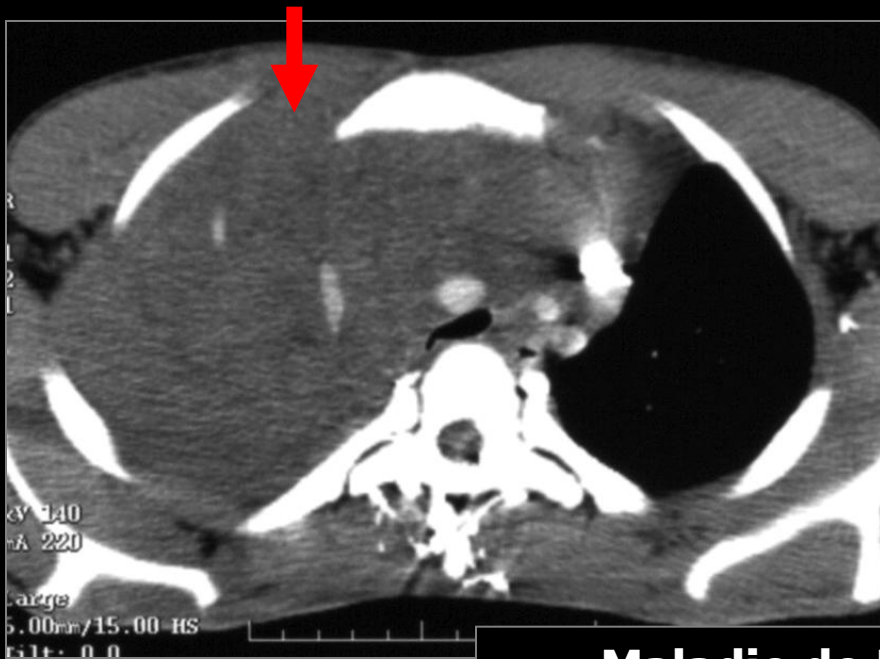**Reliquat thymique**

**Thymome**

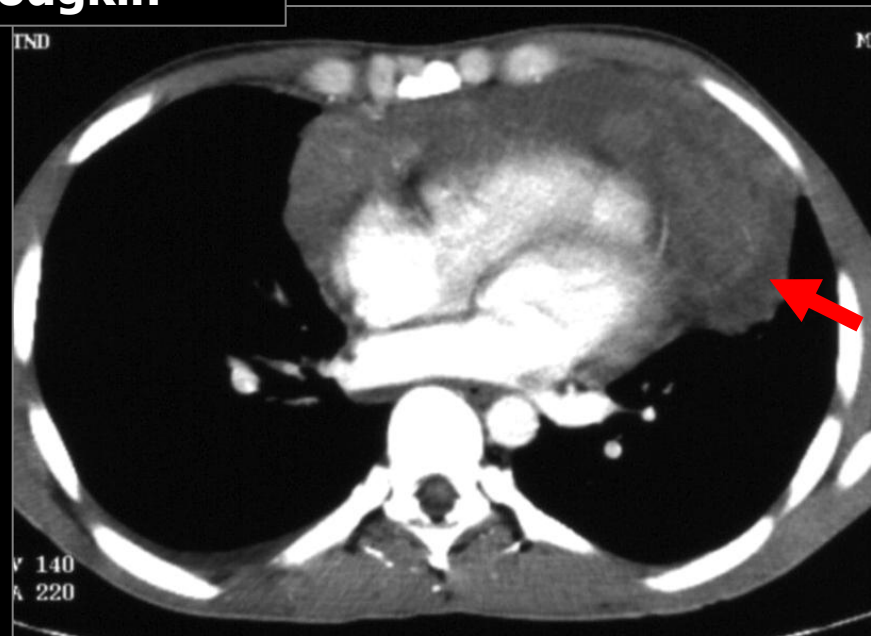
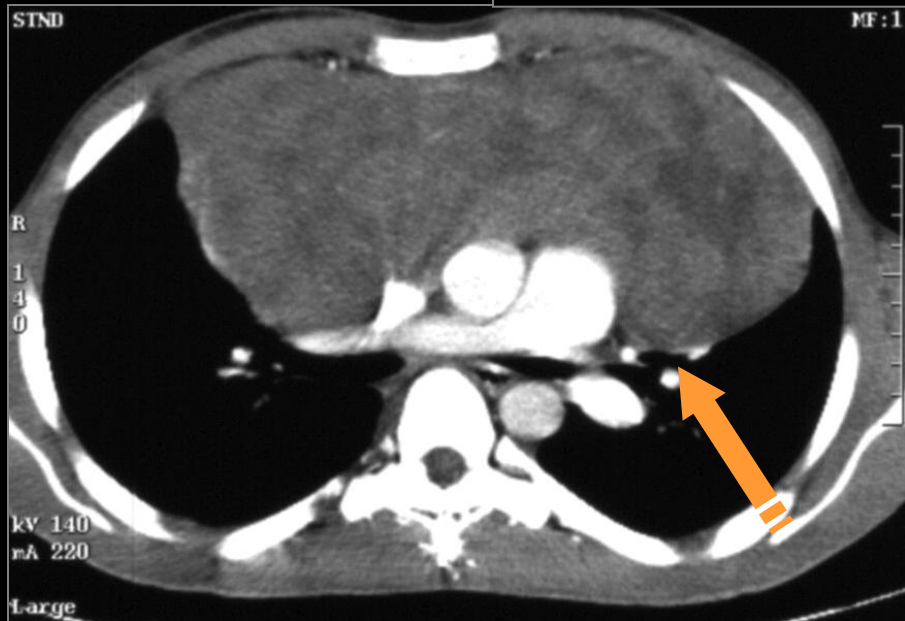


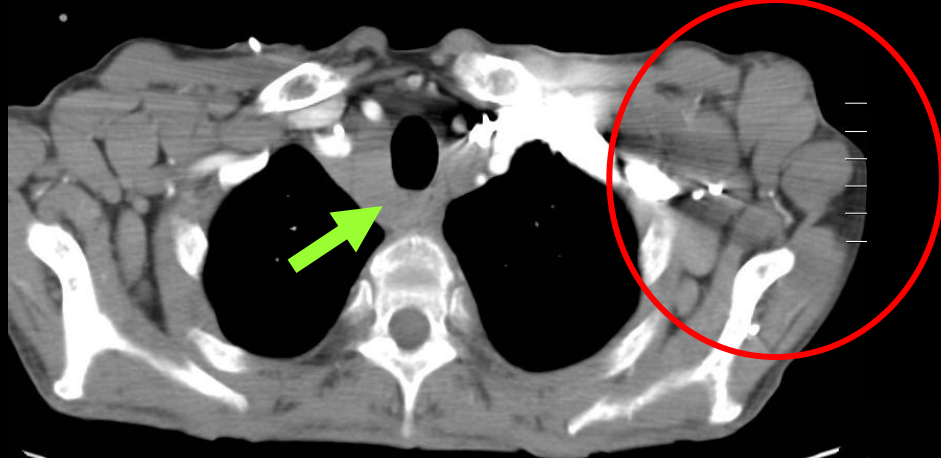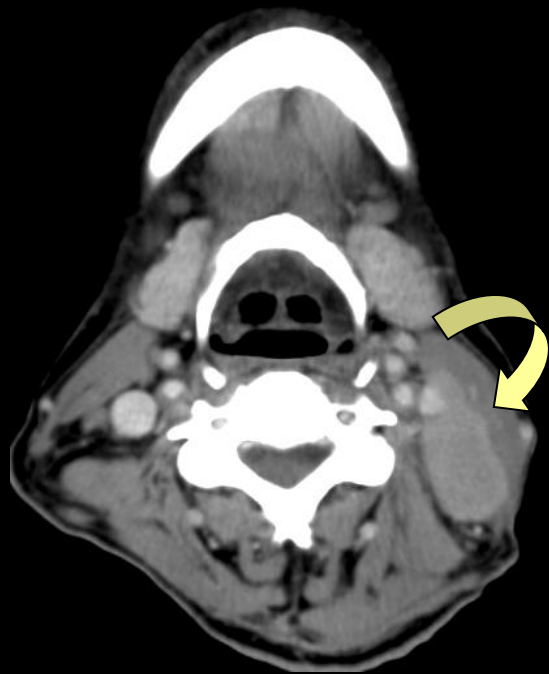


**Thymome**

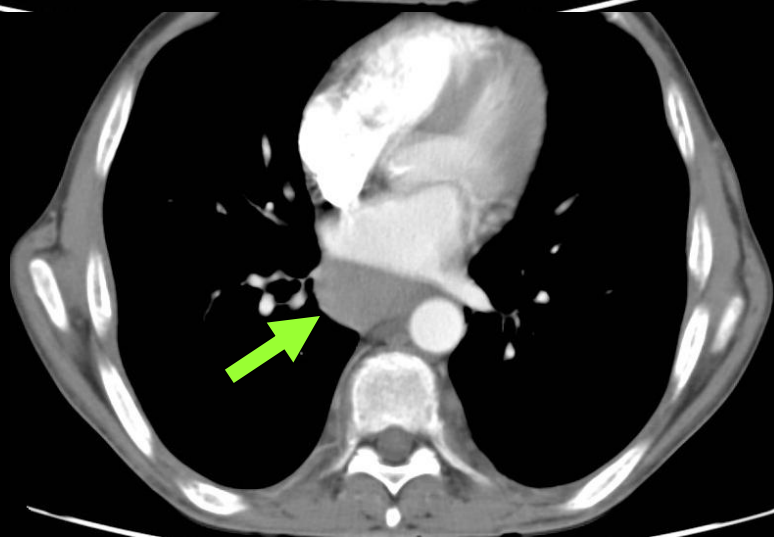
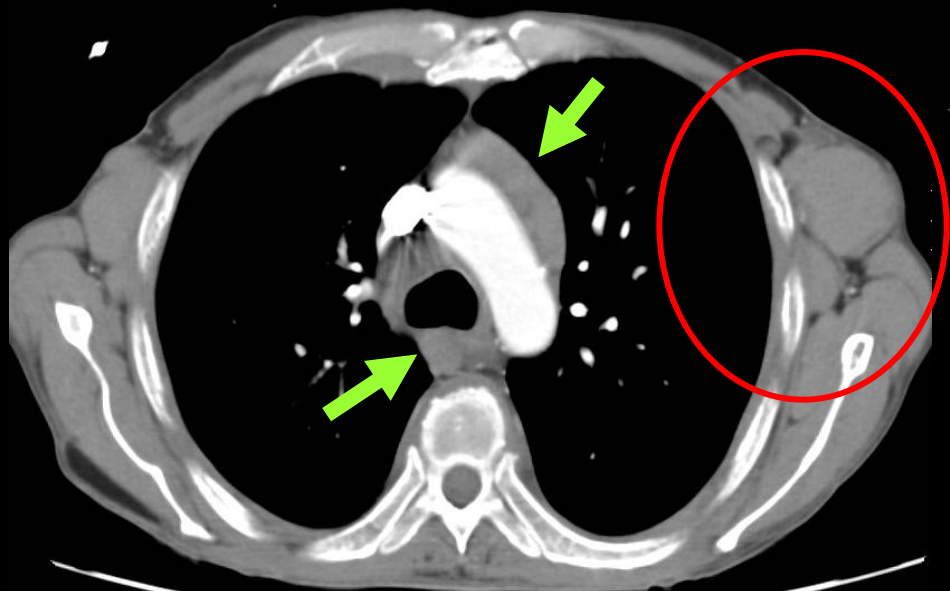
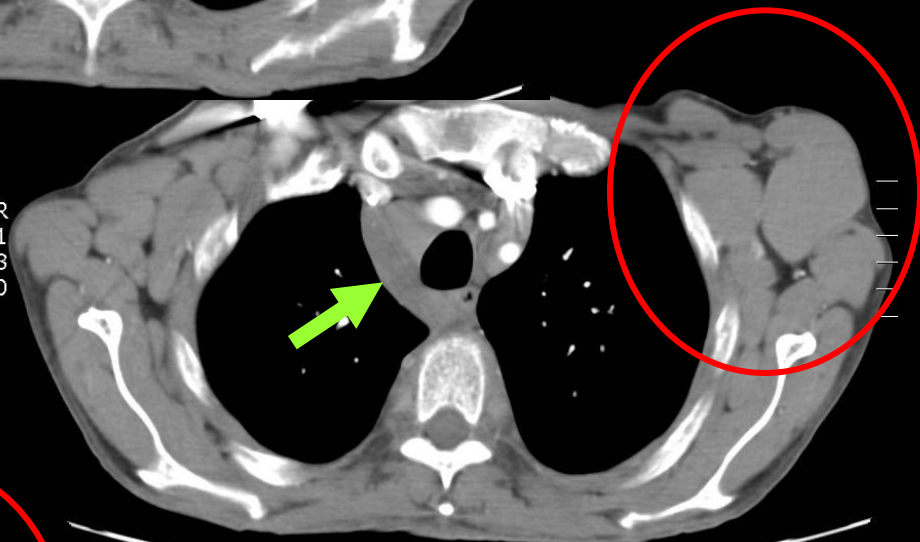


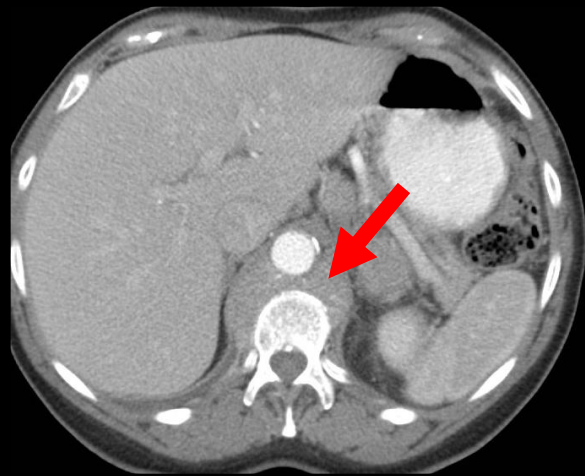
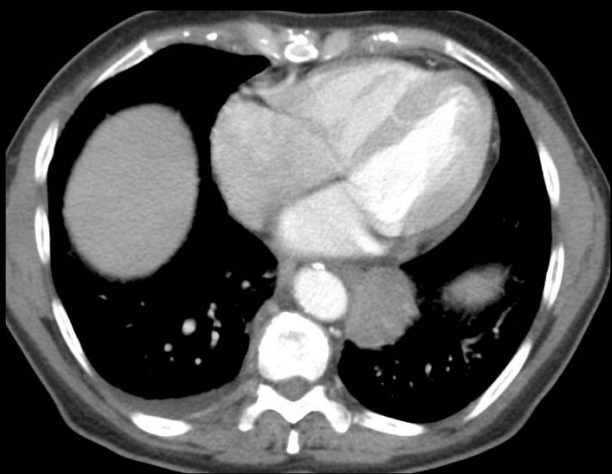
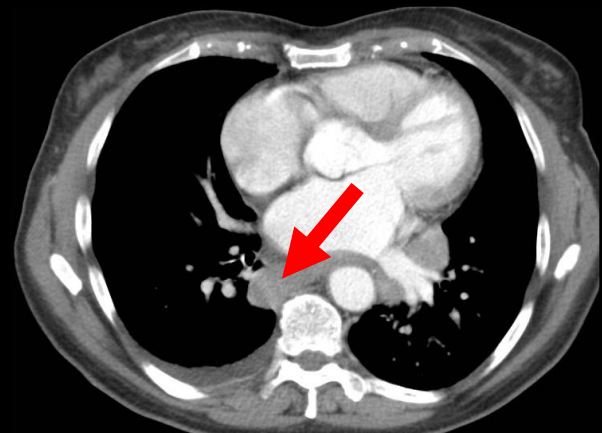
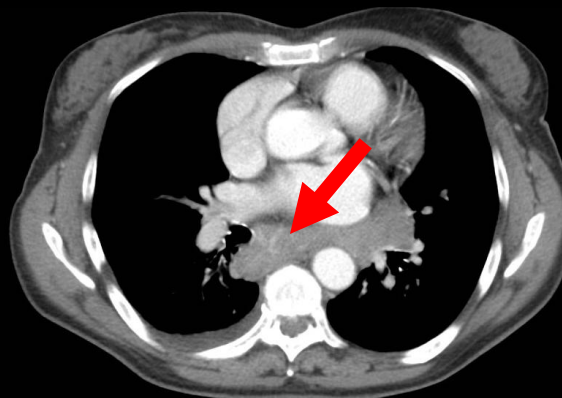
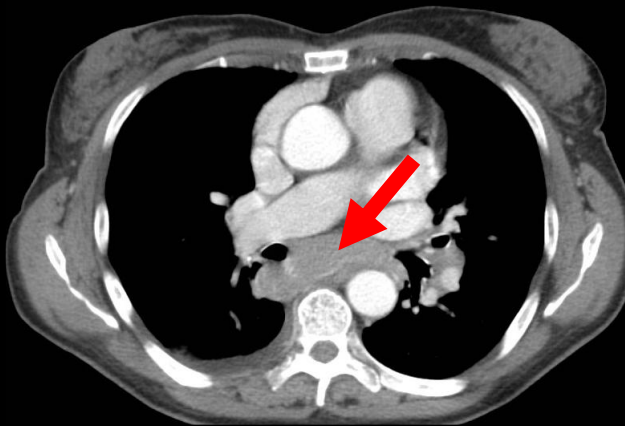
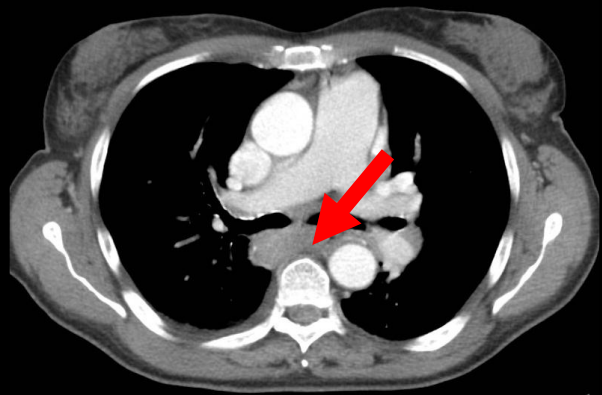
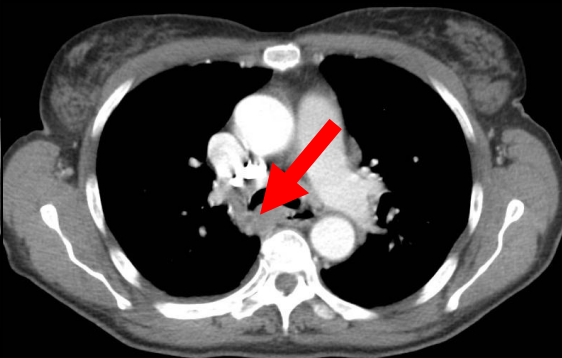
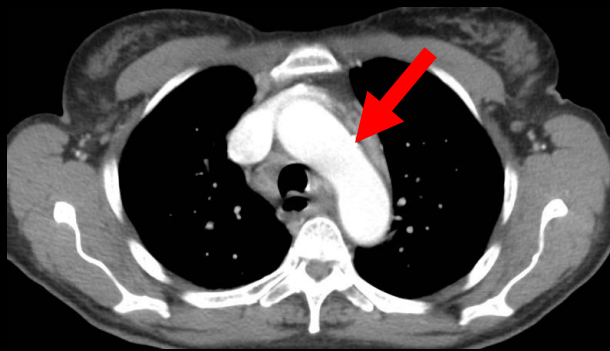
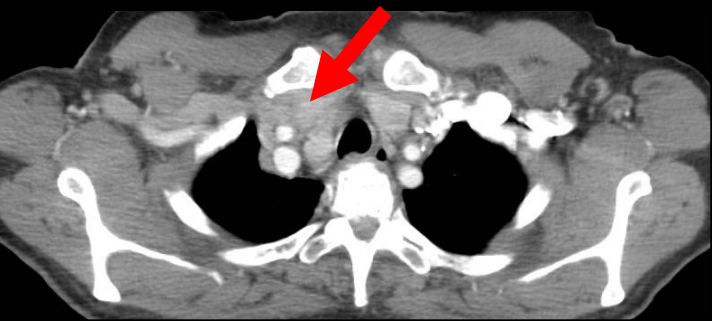
## Maladie de Hodgkin

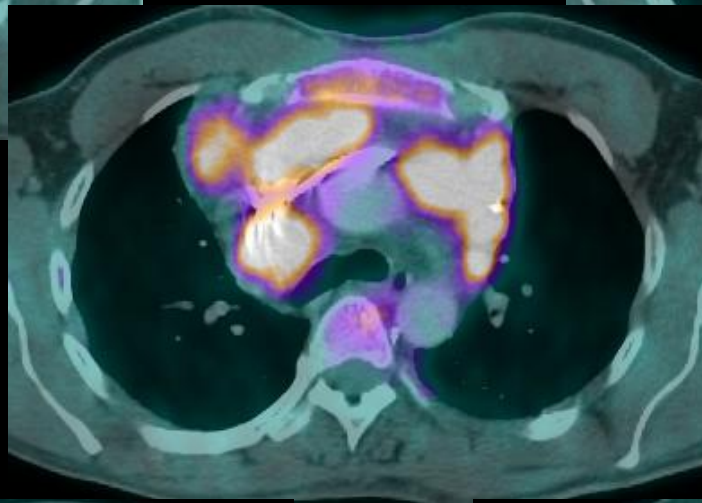
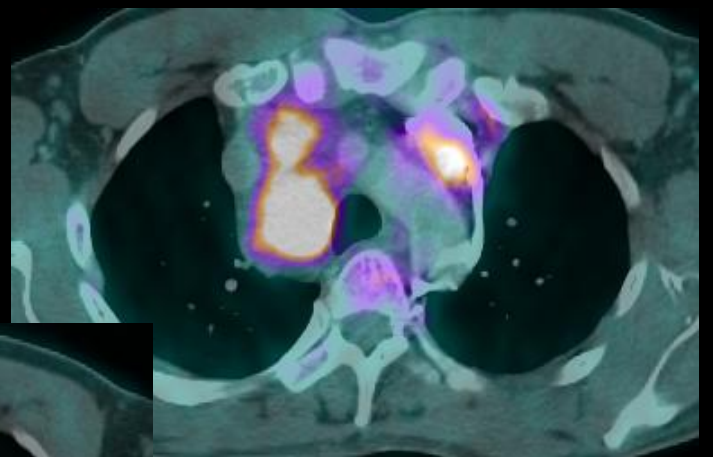
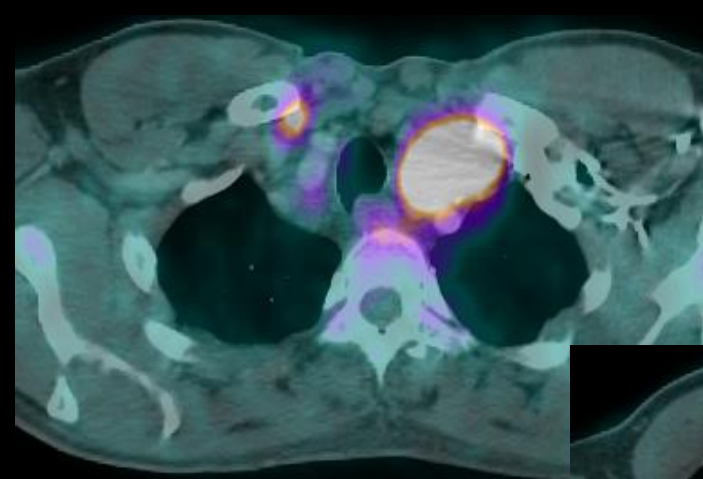




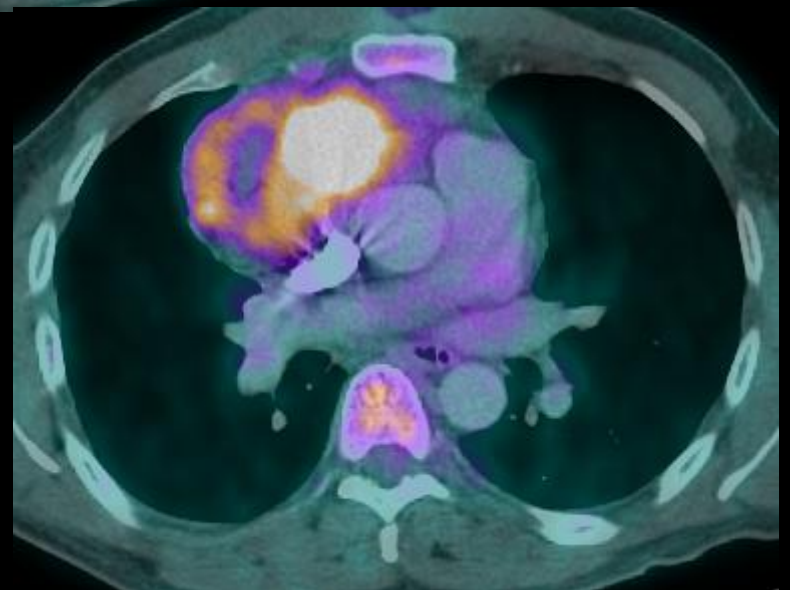
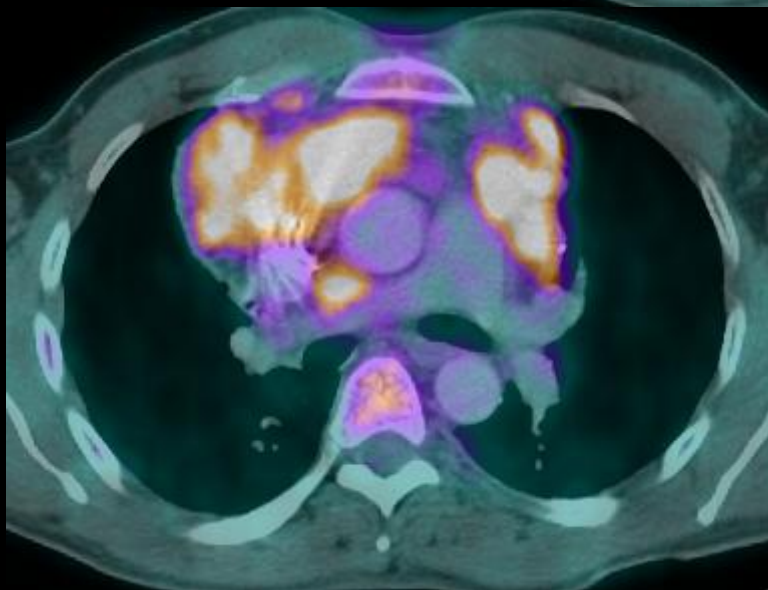
R  
1  
8  
0

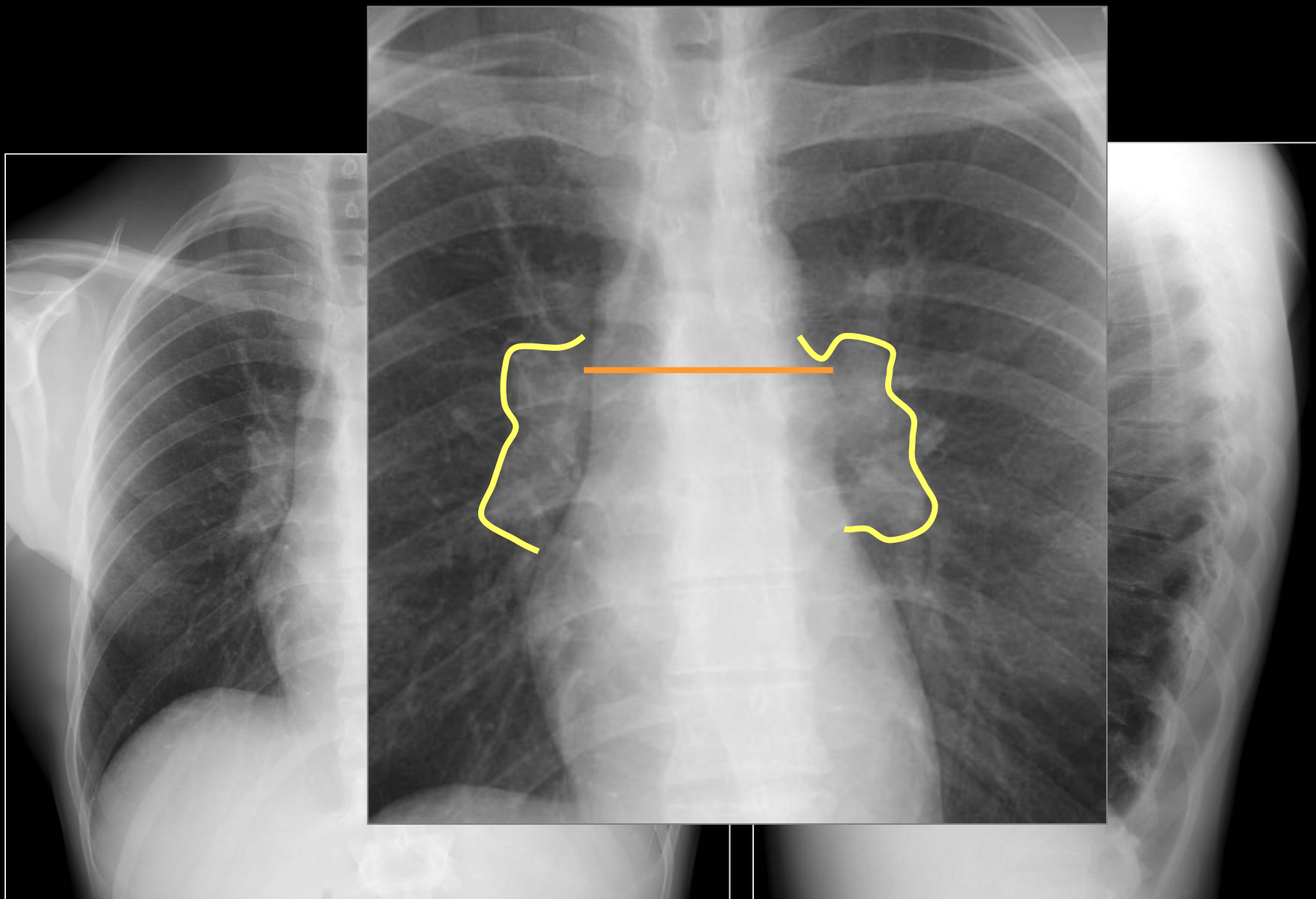




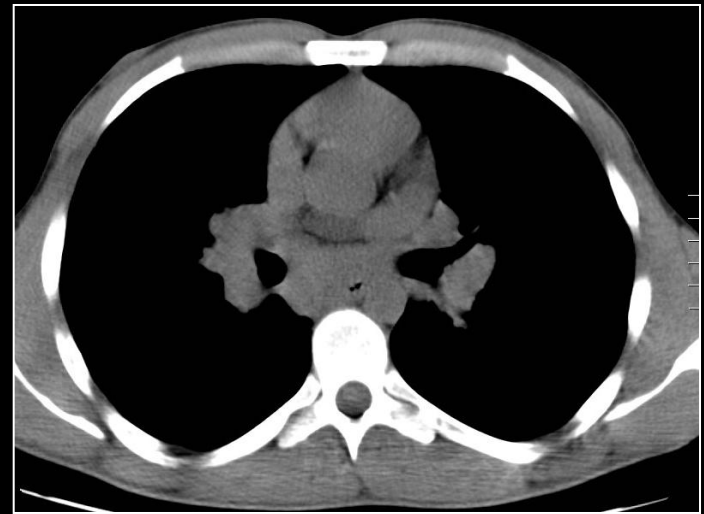
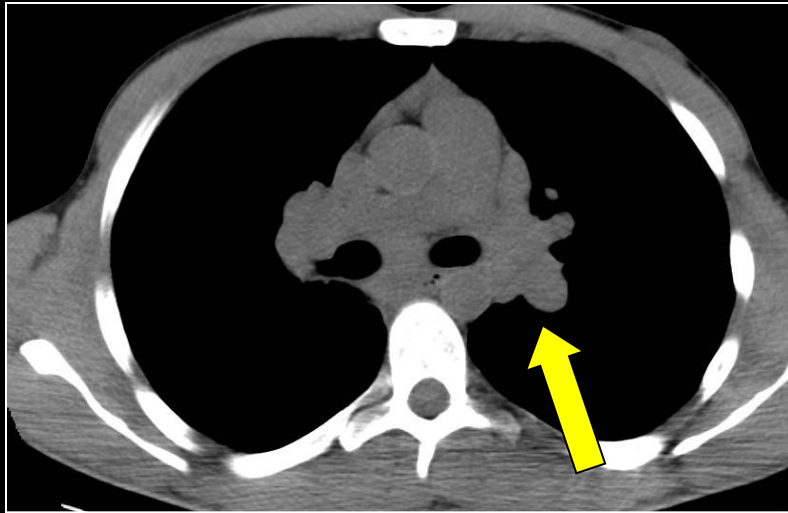


**Maladie de  
Hodgkin**

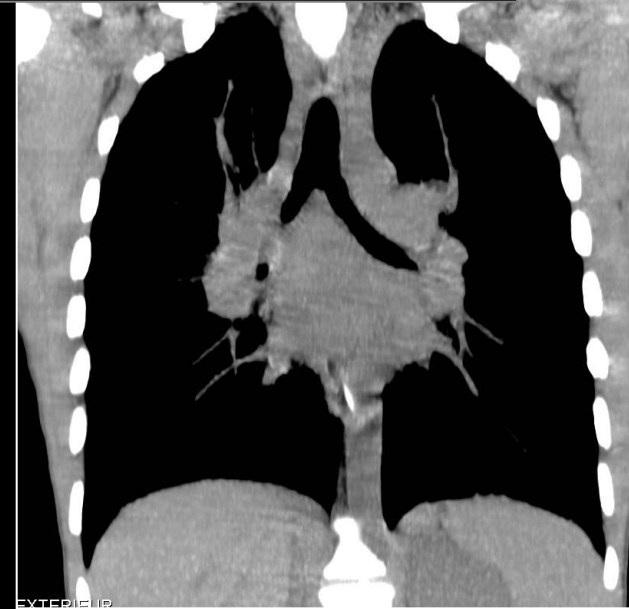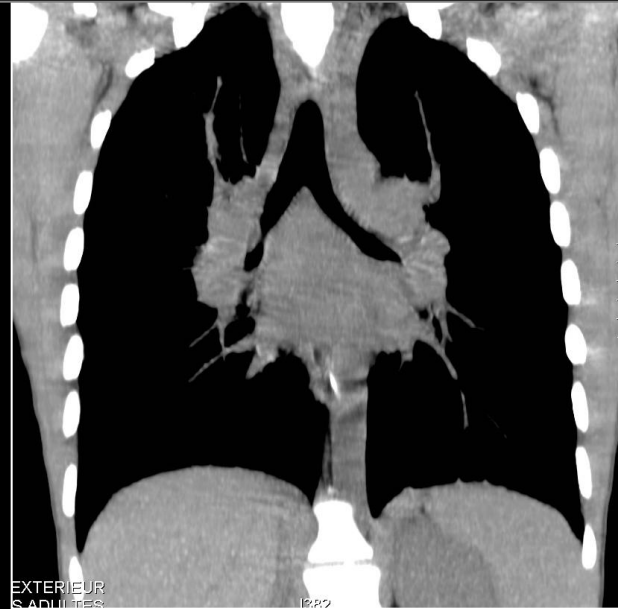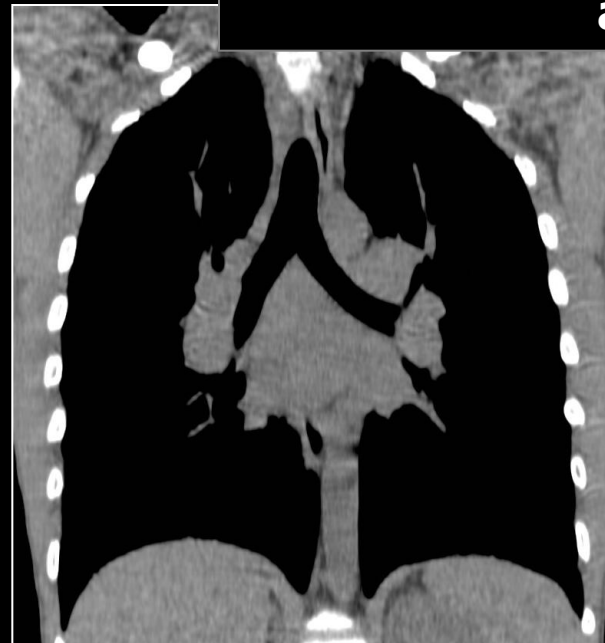




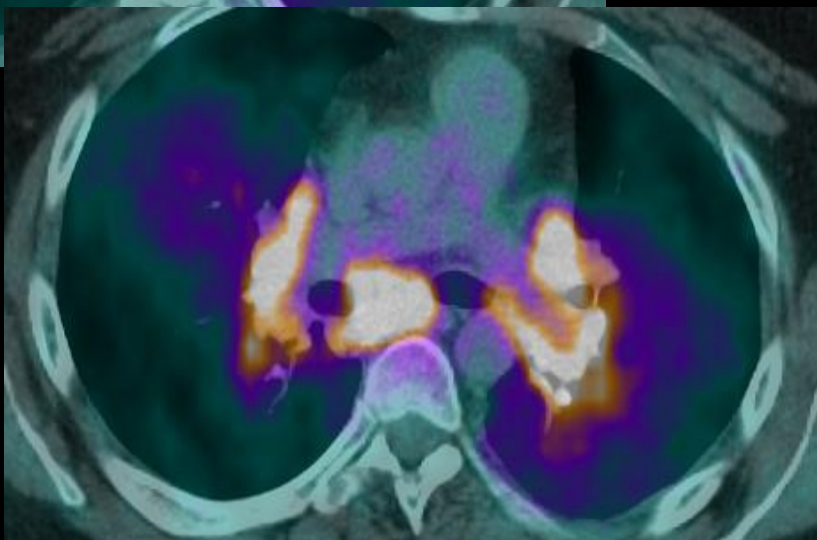
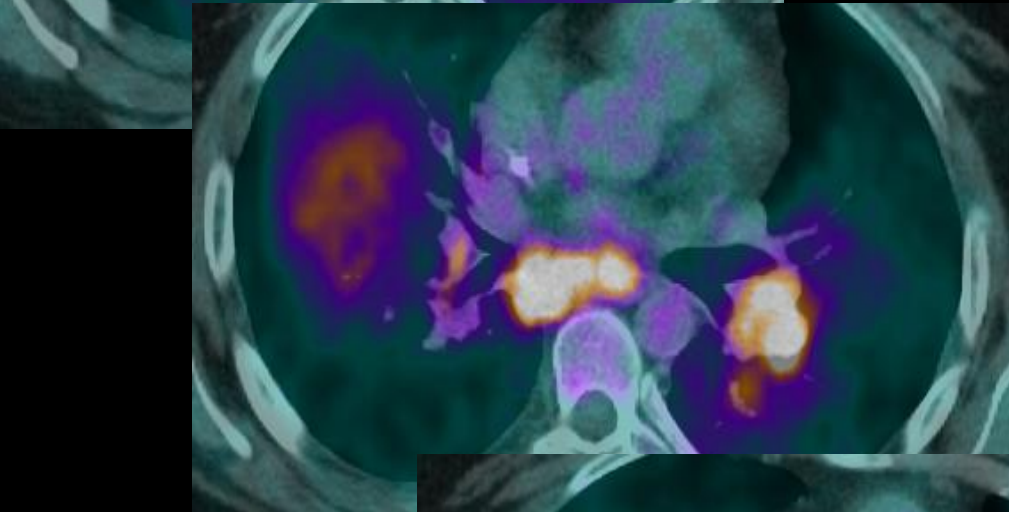
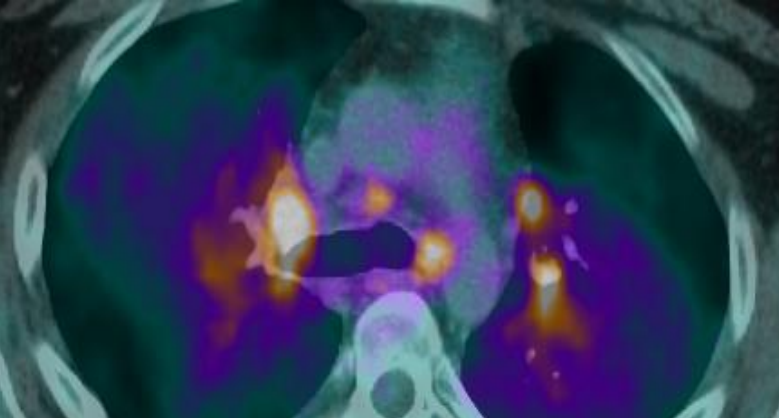
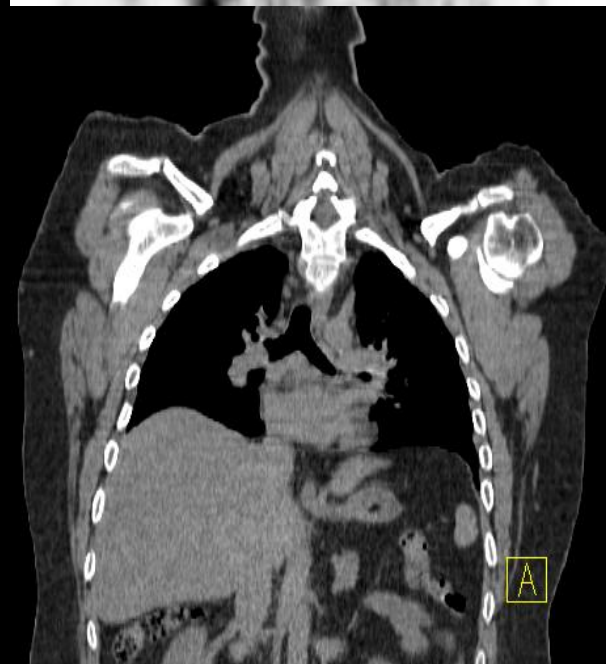
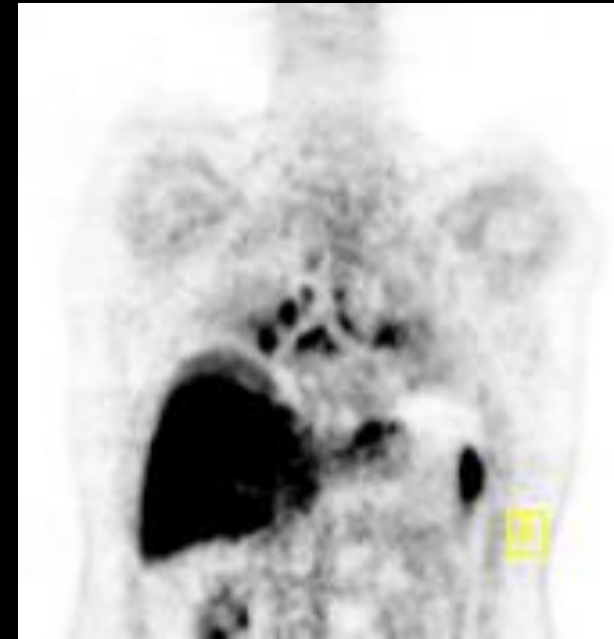**ADENOPATHIES ET GANGLIONS MEDIASTINAUX à  
prédominance inter bronchique**

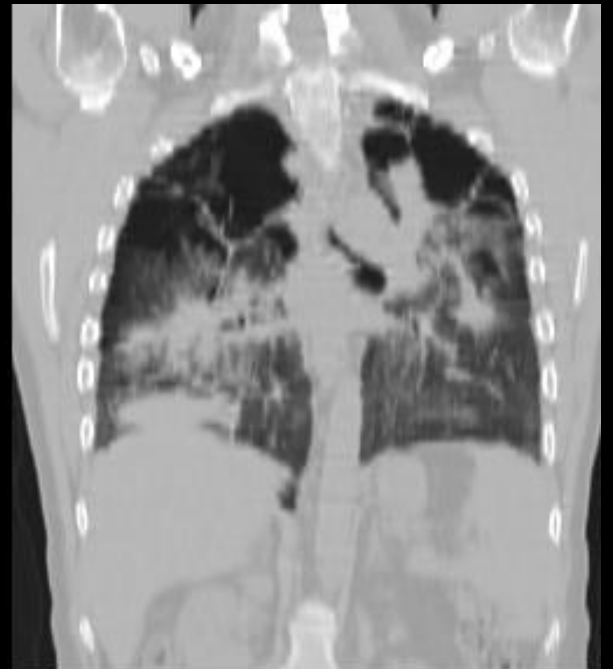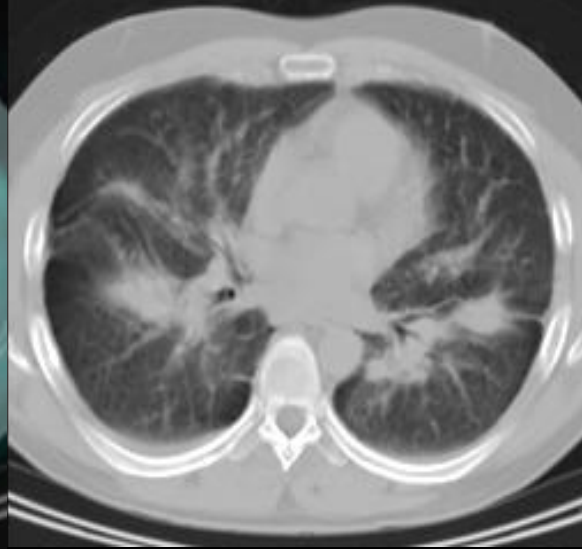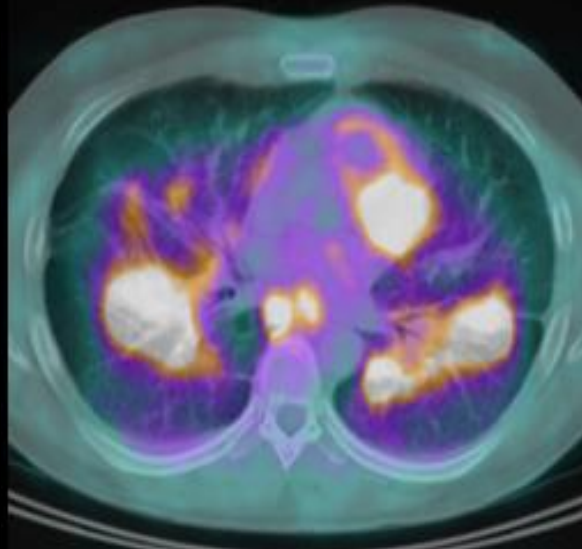
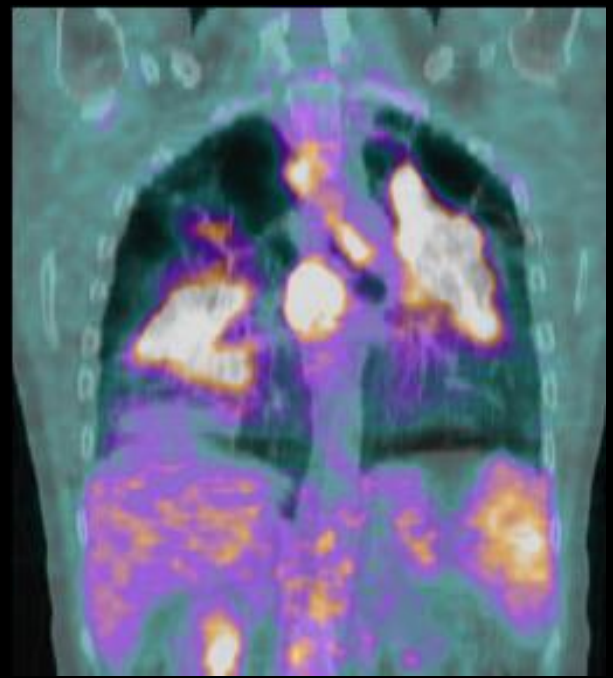
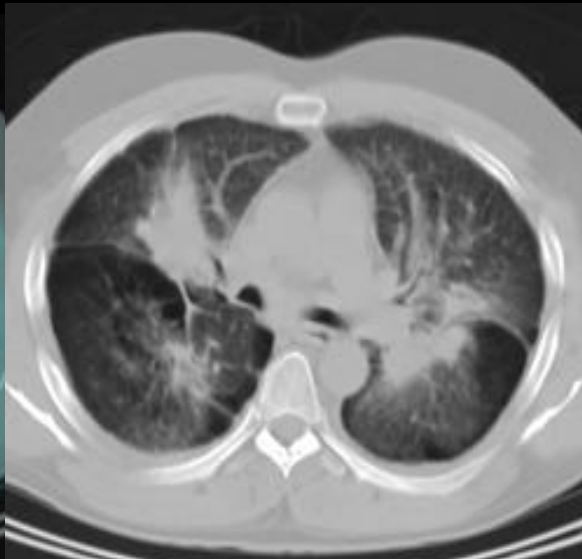
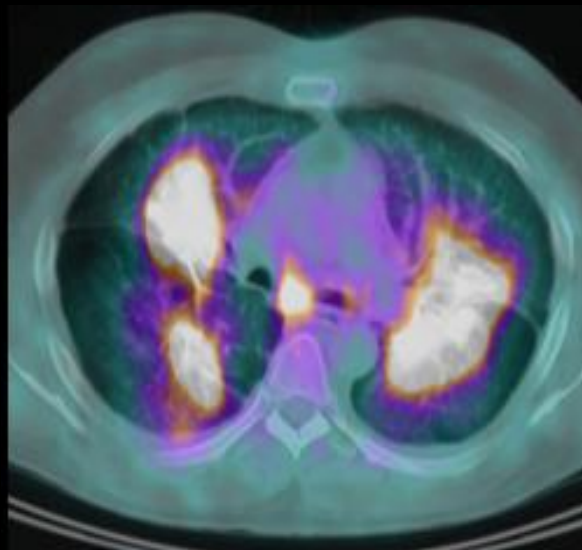


**ADENOPATHIES ET GANGLIONS MEDIASTINAUX  
à prédominance inter bronchique**

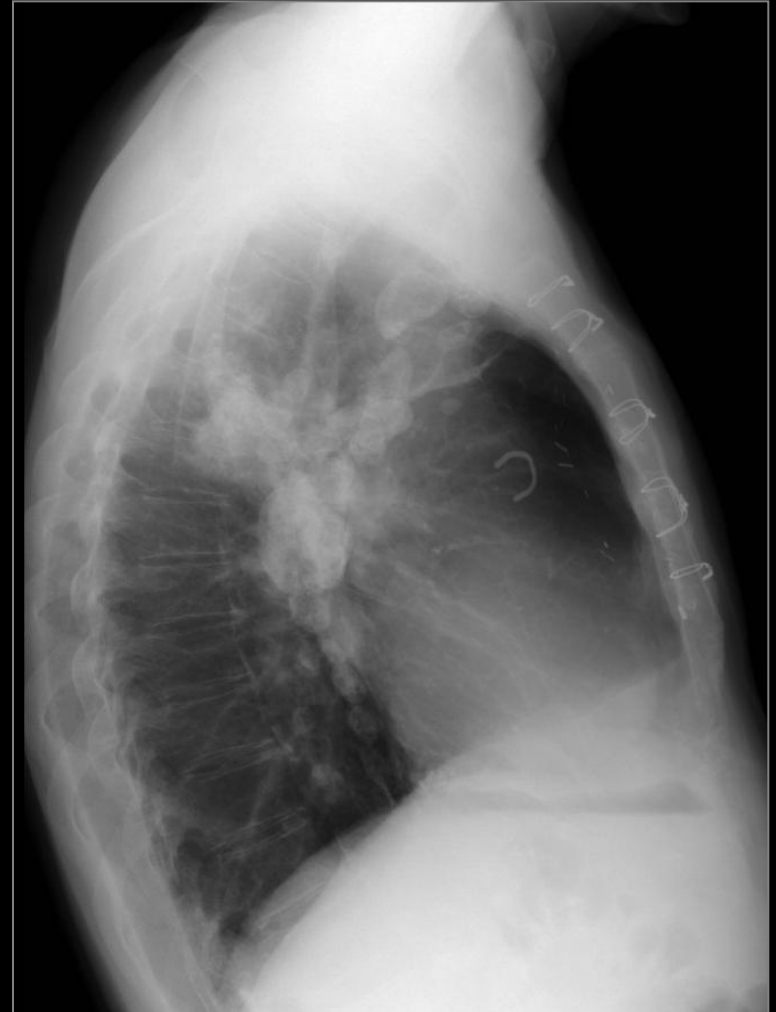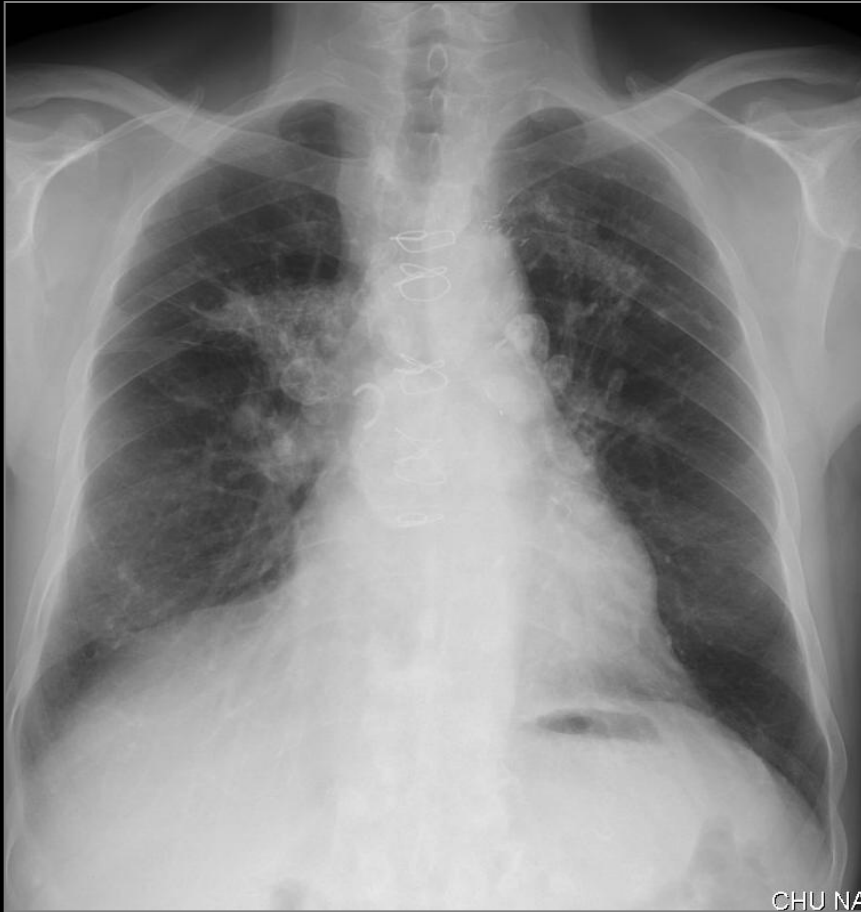


# Sarcoïdose

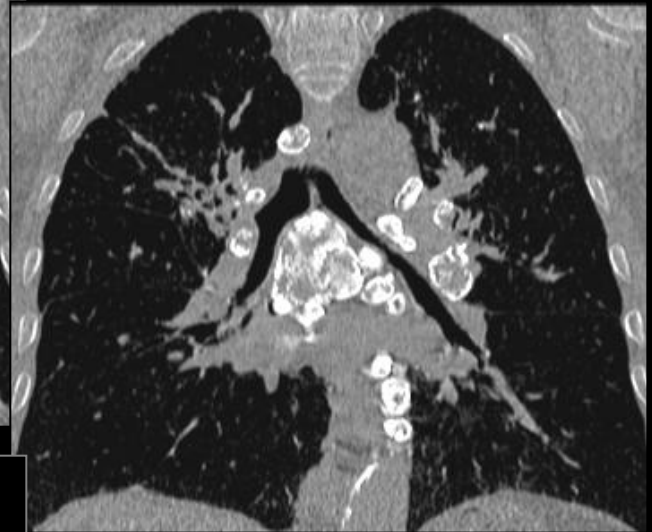
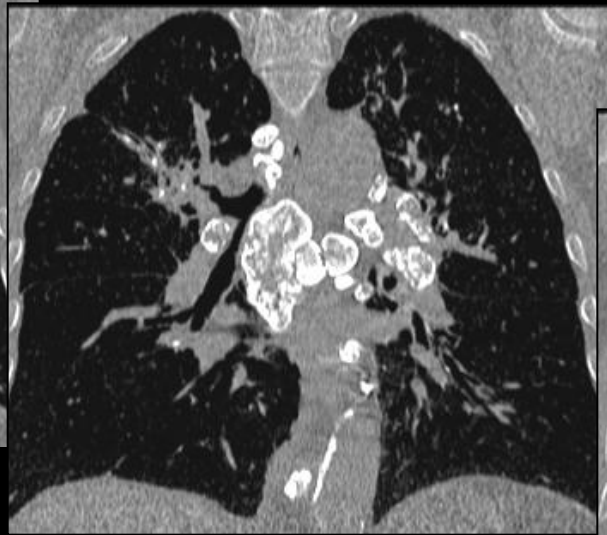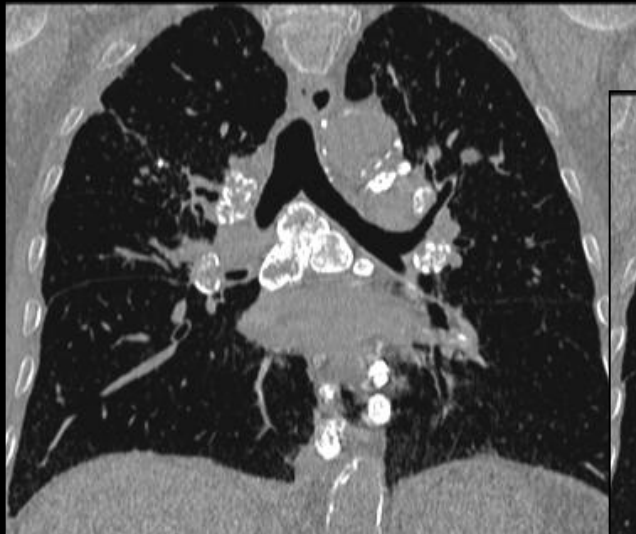
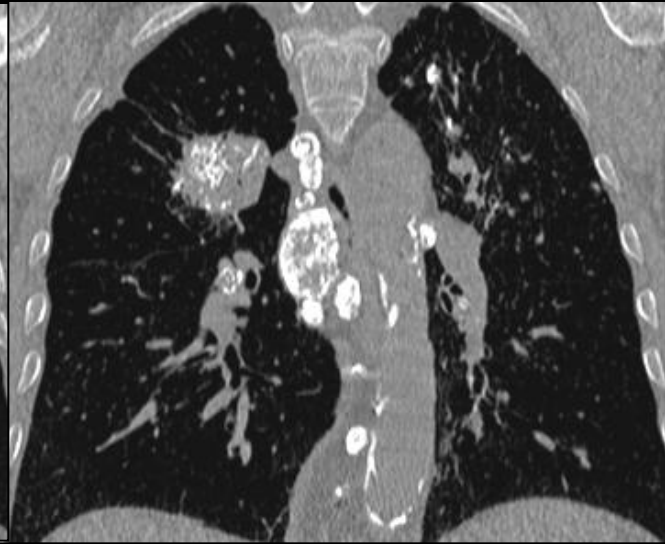
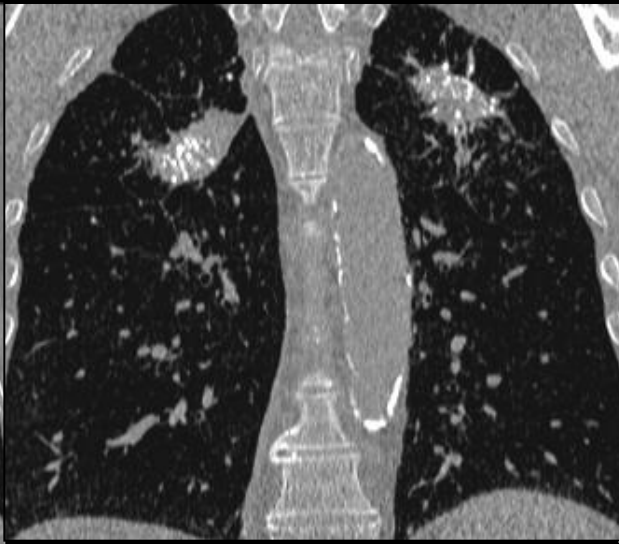

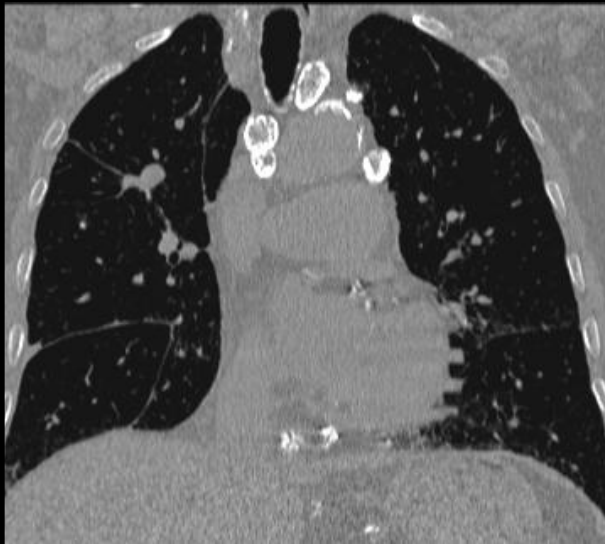


**Sarcoïdose avec atteinte parenchymateuse**

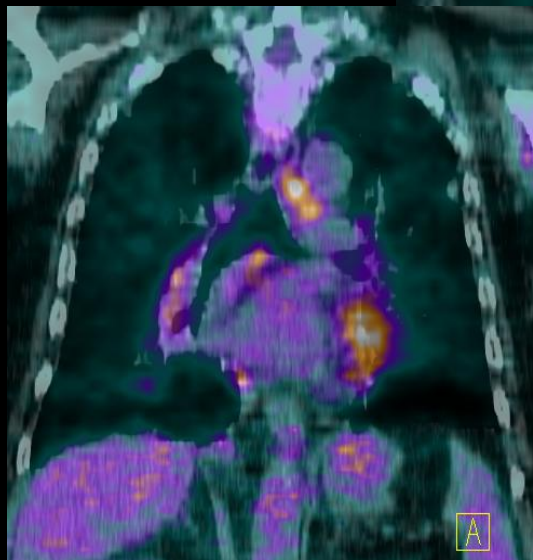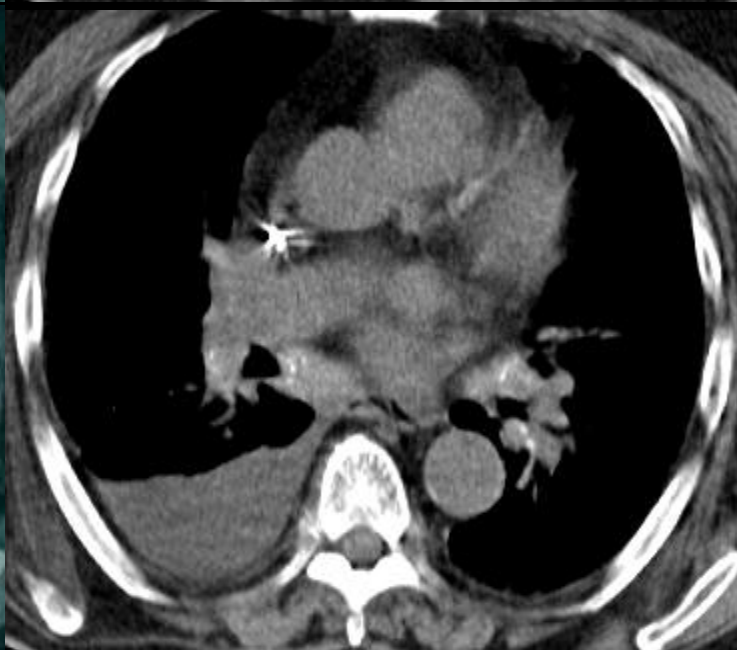
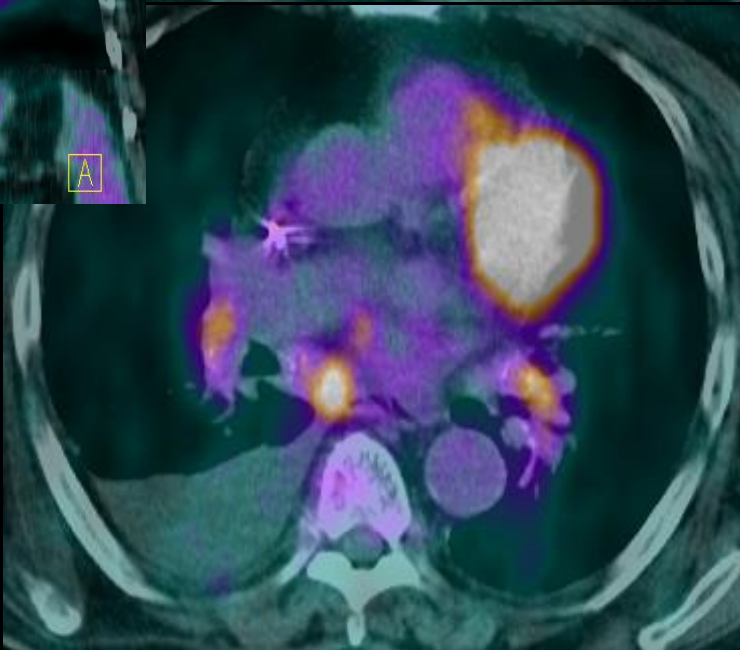
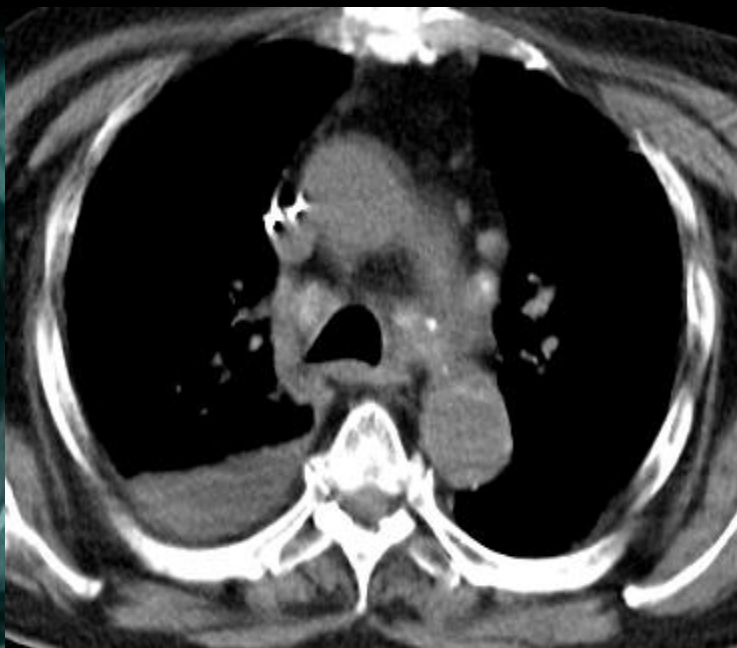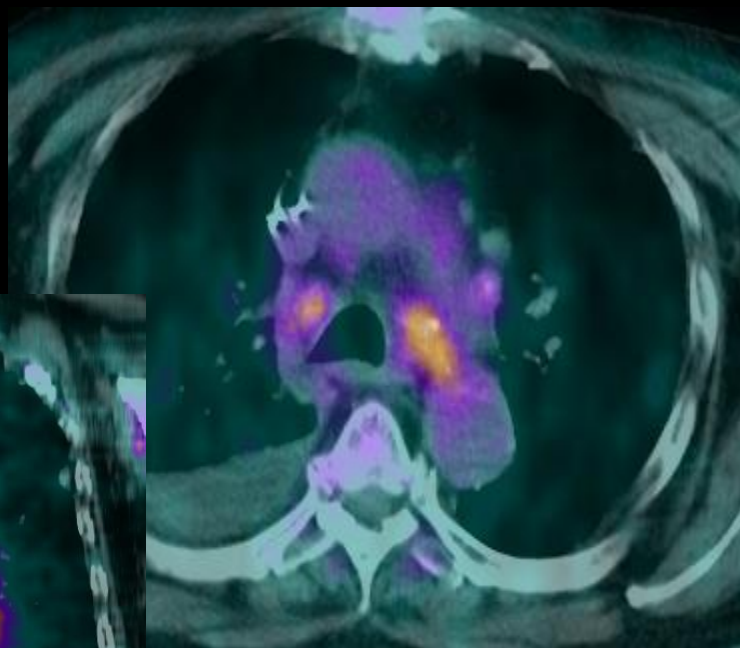


**Élargissement hilare droit et médiastin**

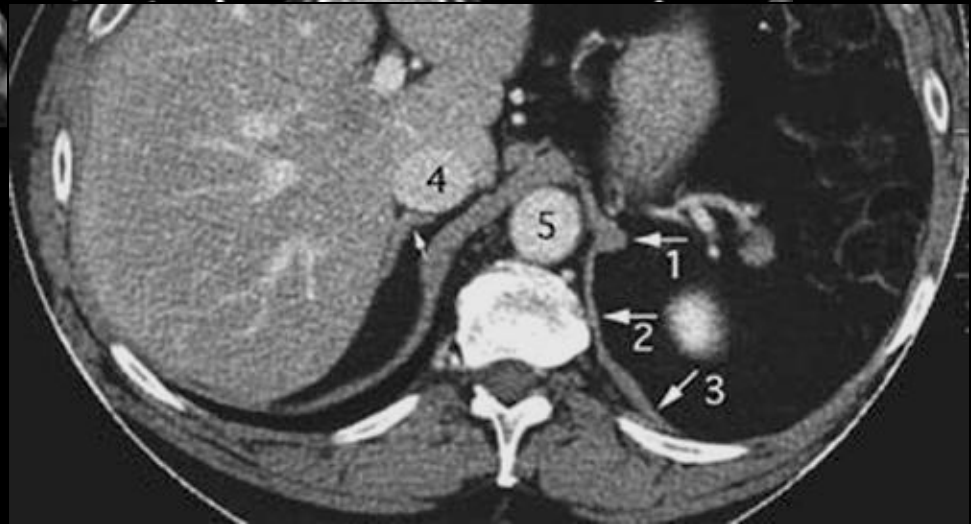
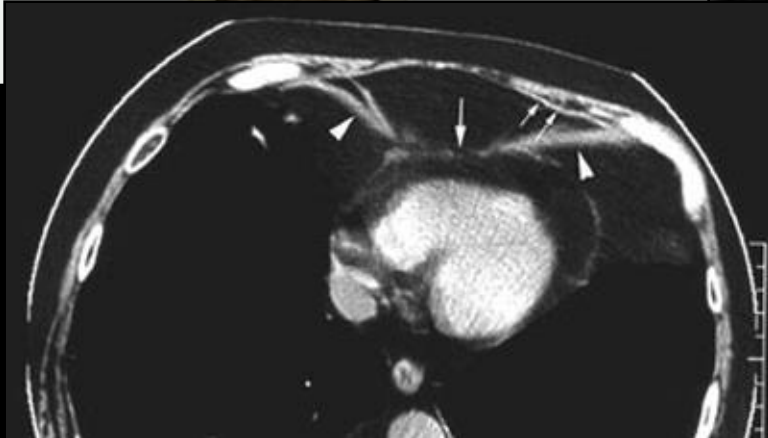
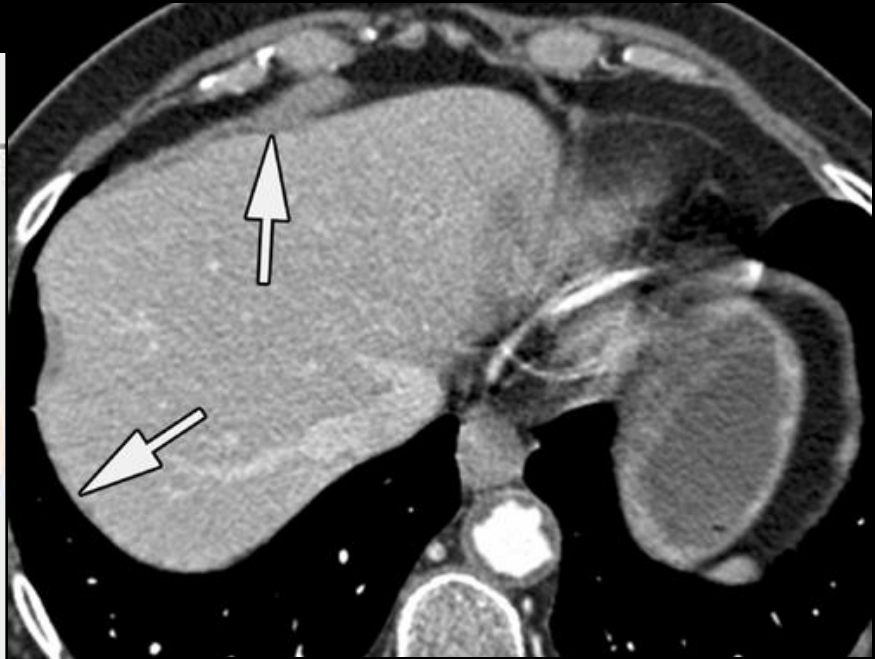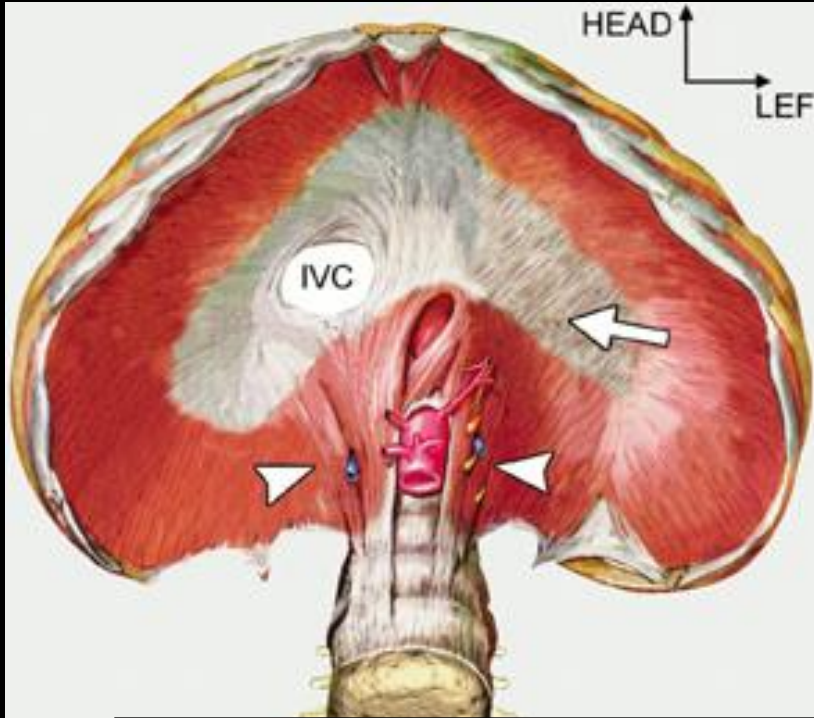


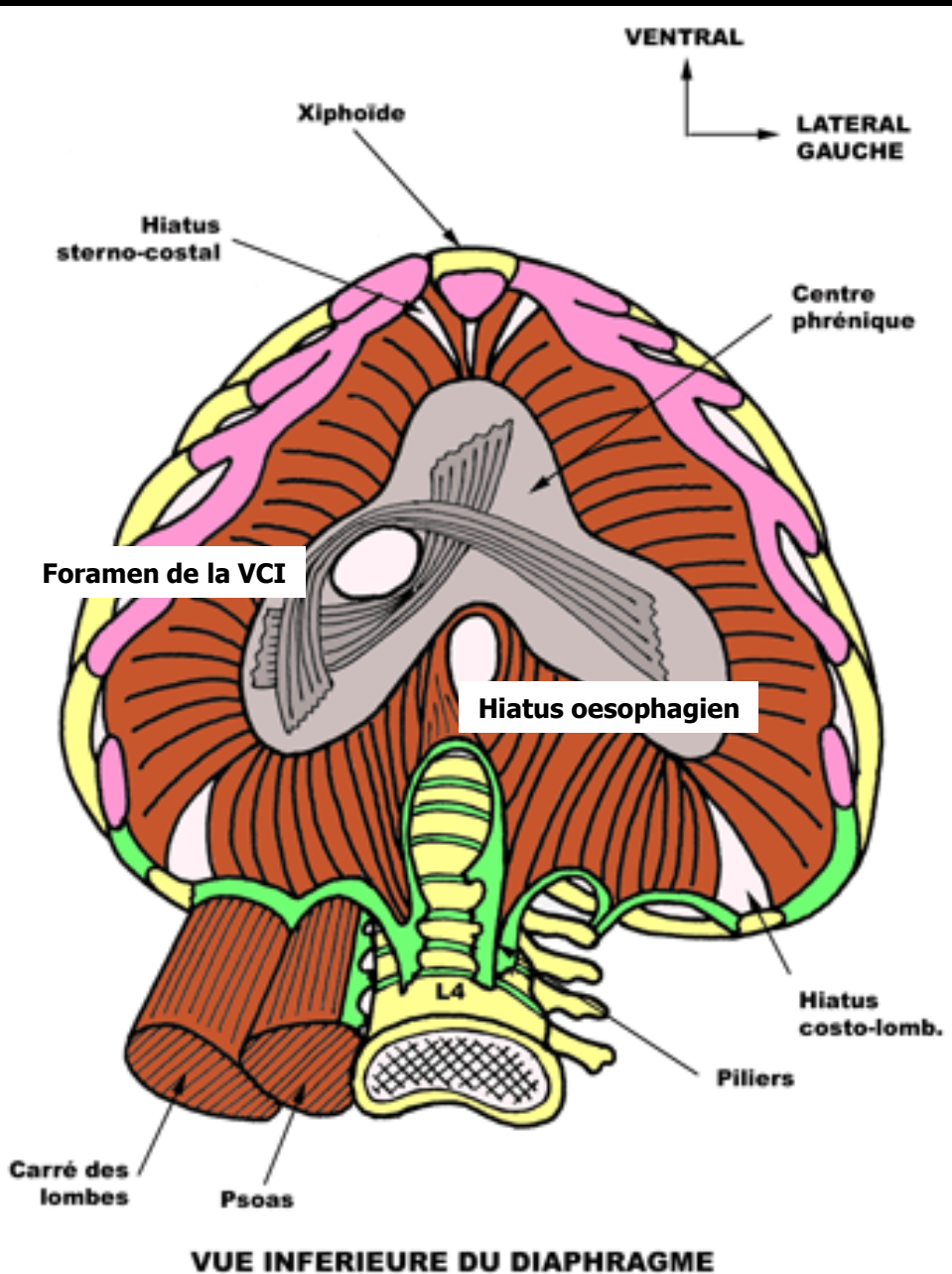
**ADP calcifiées et masses biapicales : silicose**

# Silicose



# DIAPHRAGM





## Orifices :

### • T12 :

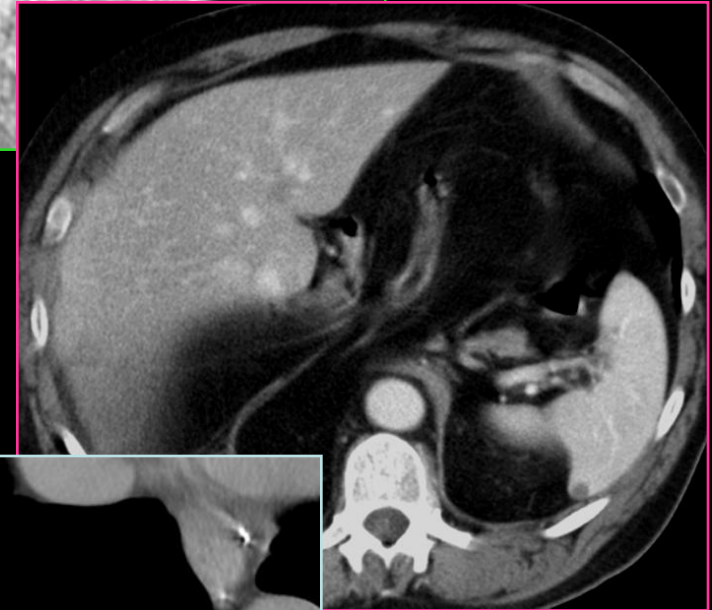
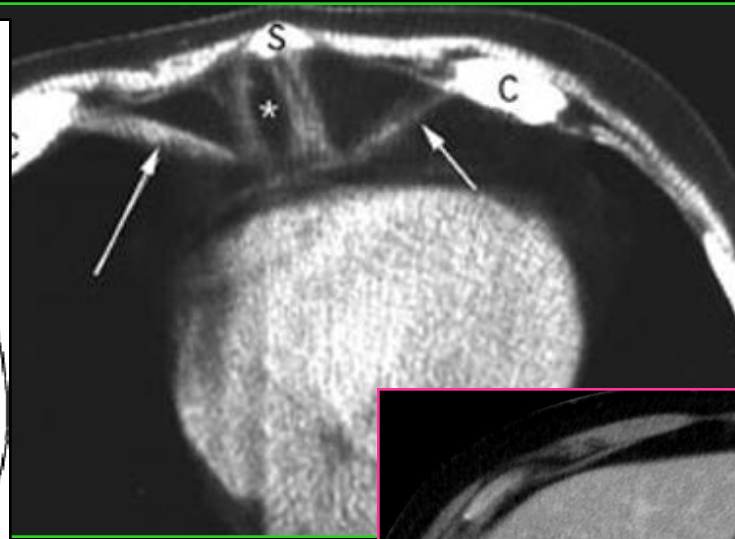
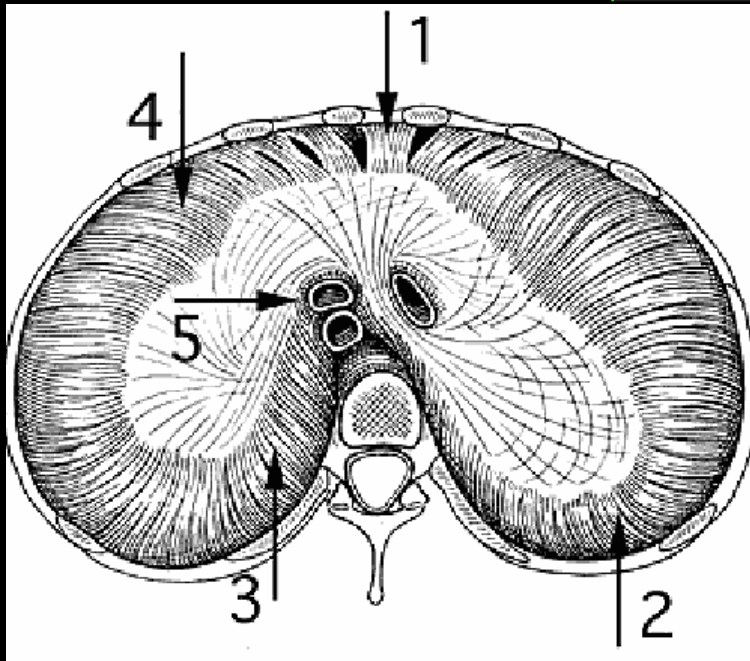
- AO
- Canal thoracique

### • T10 :

- œsophage
- Nerfs X

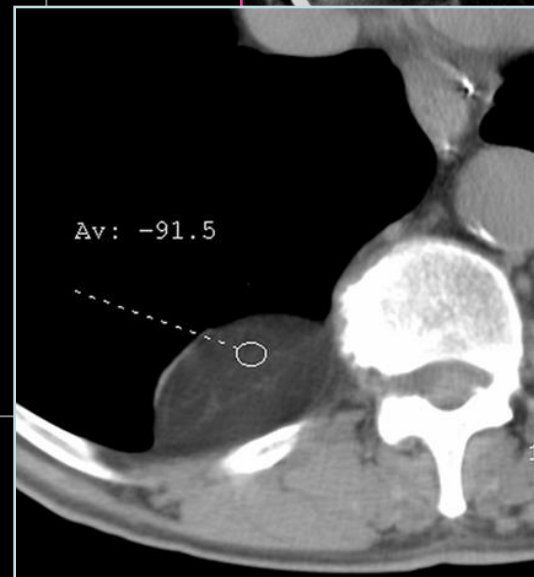### • T9 :

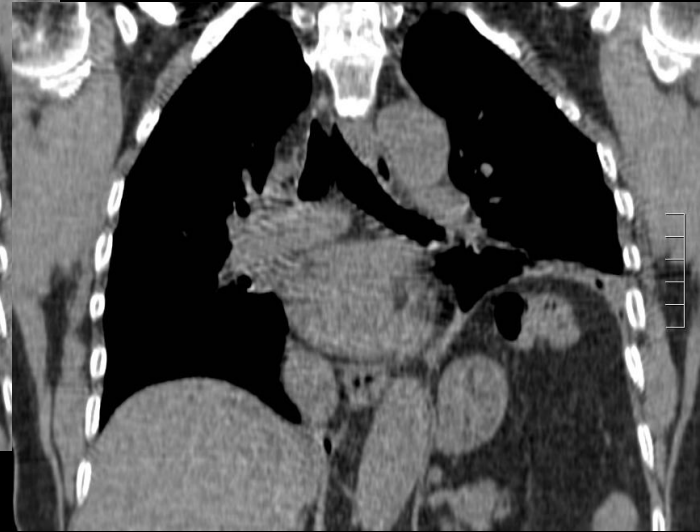
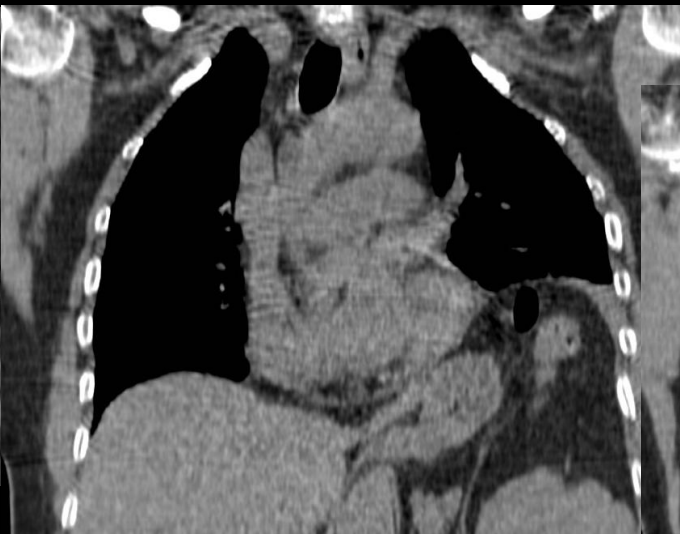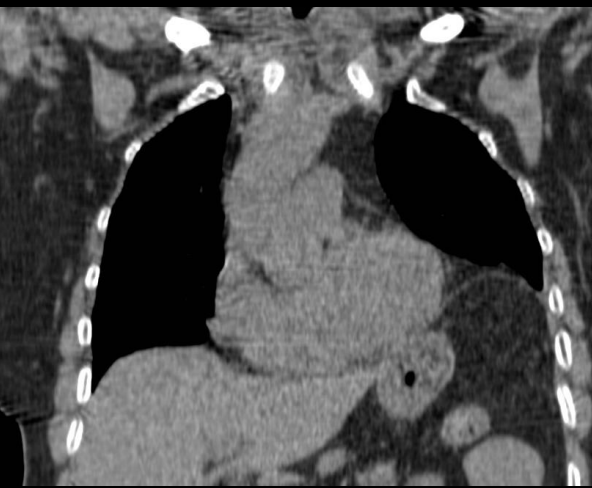- VCI
- N. phrénique D



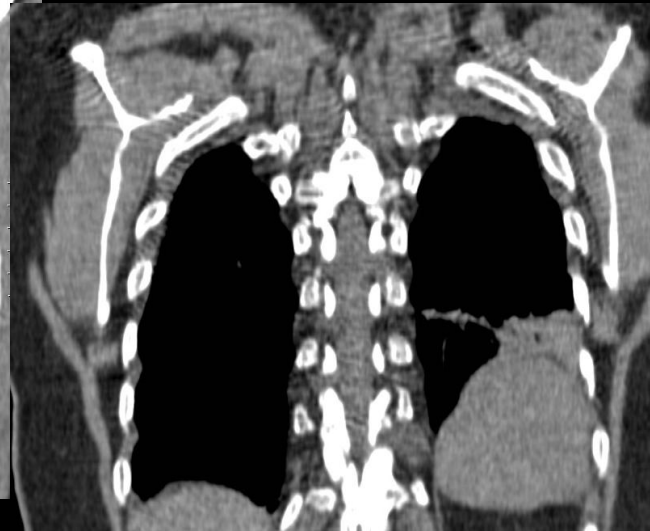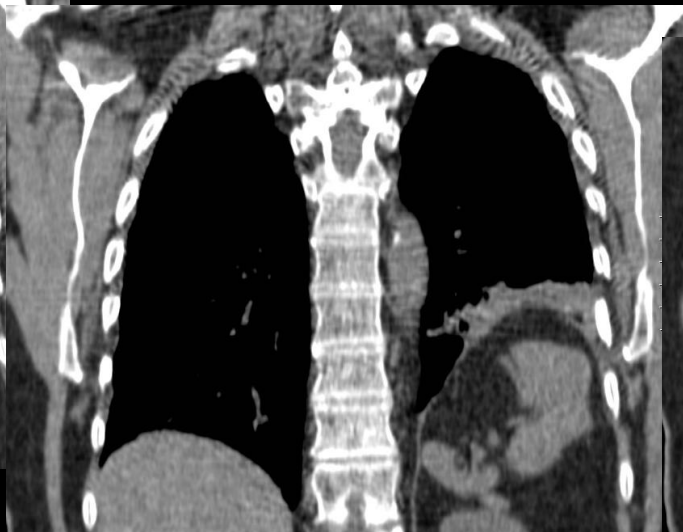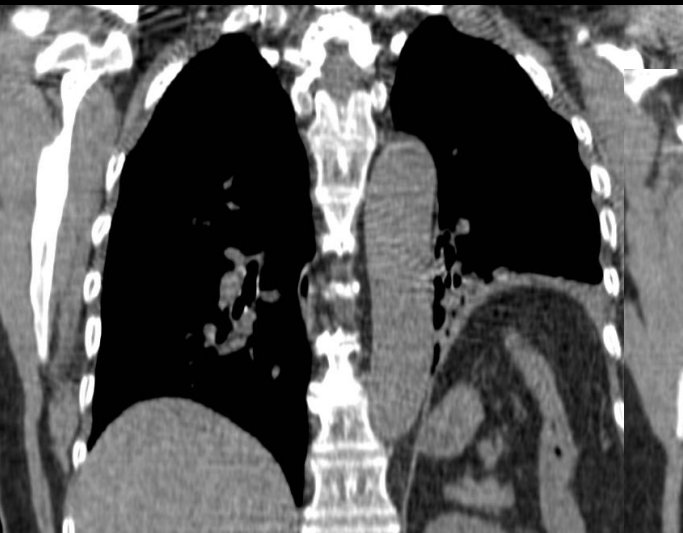
### Points de faiblesse :

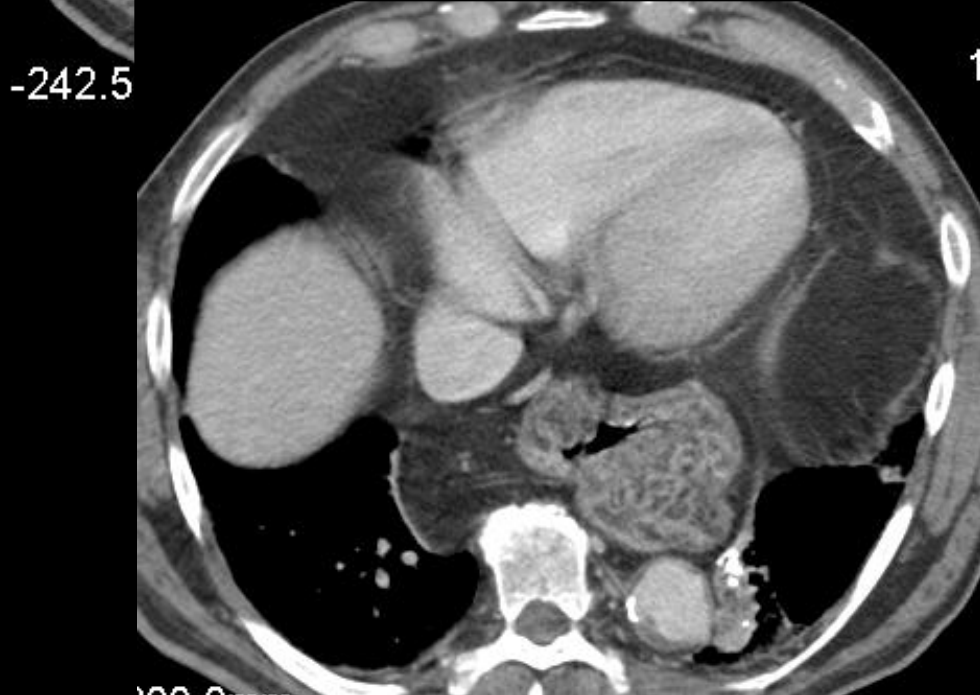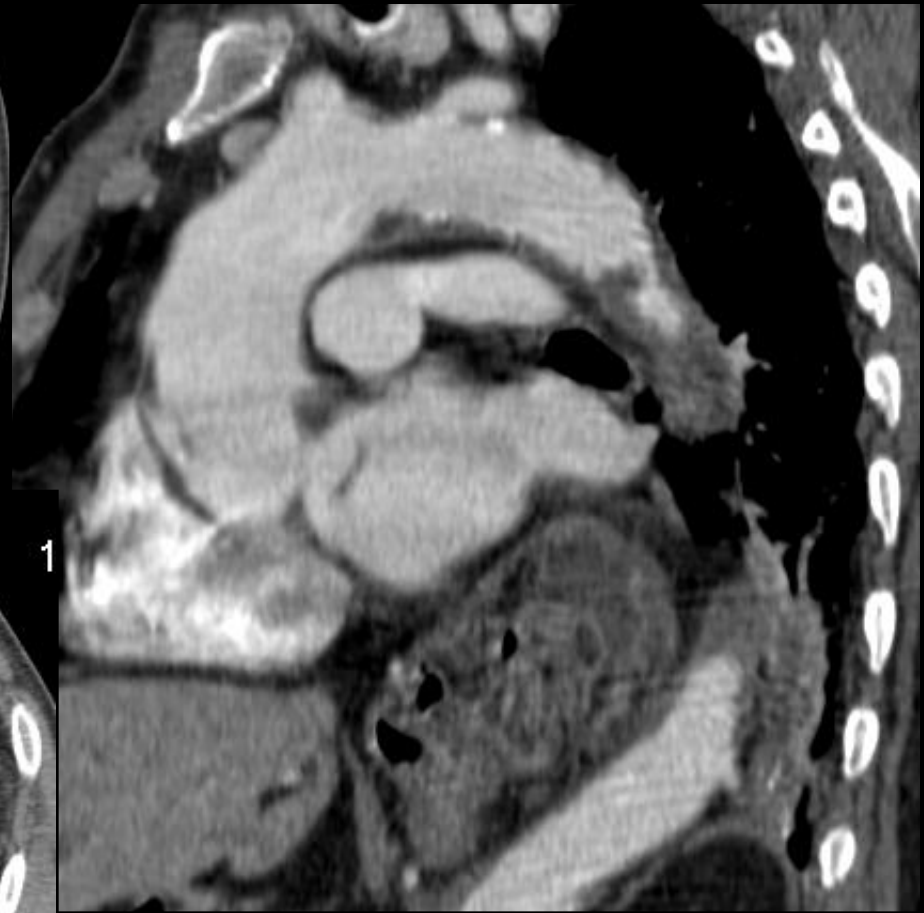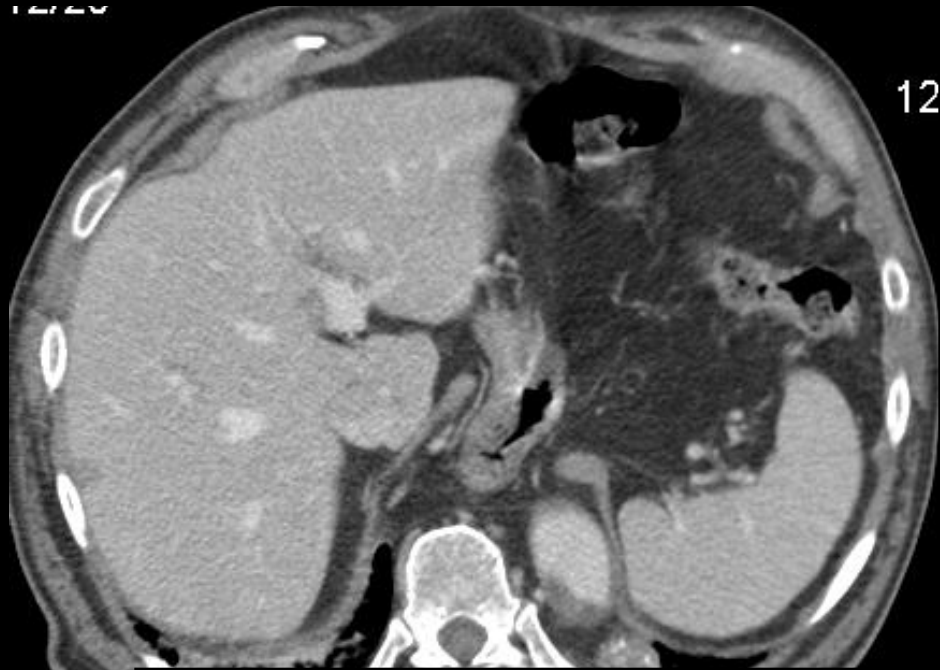- Hiatus postérieur : Bochdalek
- Hiatus rétro-costo-xyphoïdiens
  - lat : Morgani
  - médian : fente de Larrey
- Hiatus oesophagien





Paralysie phrénique

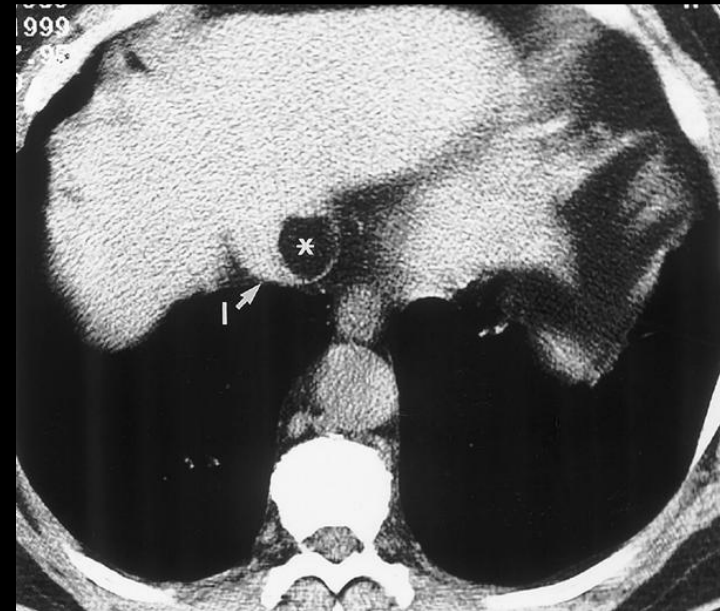
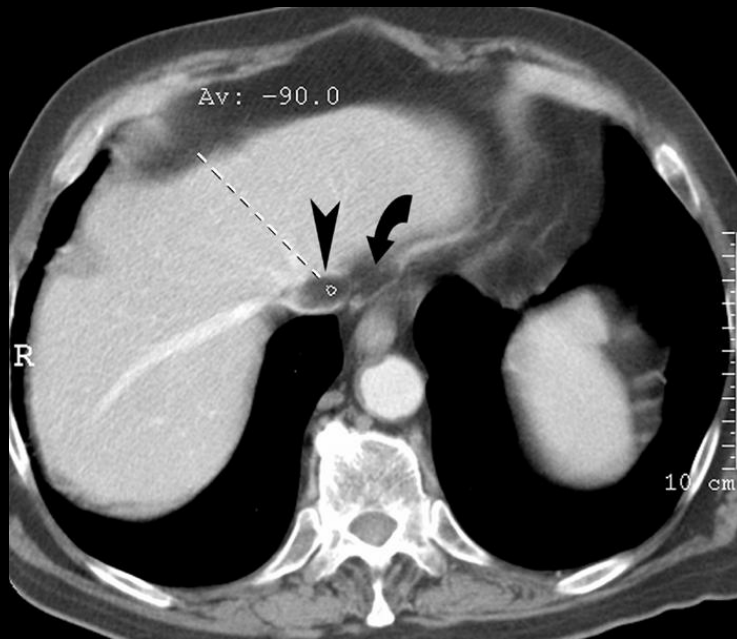
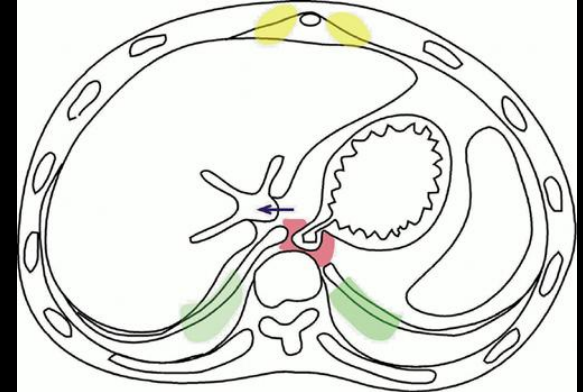




HH par glissement

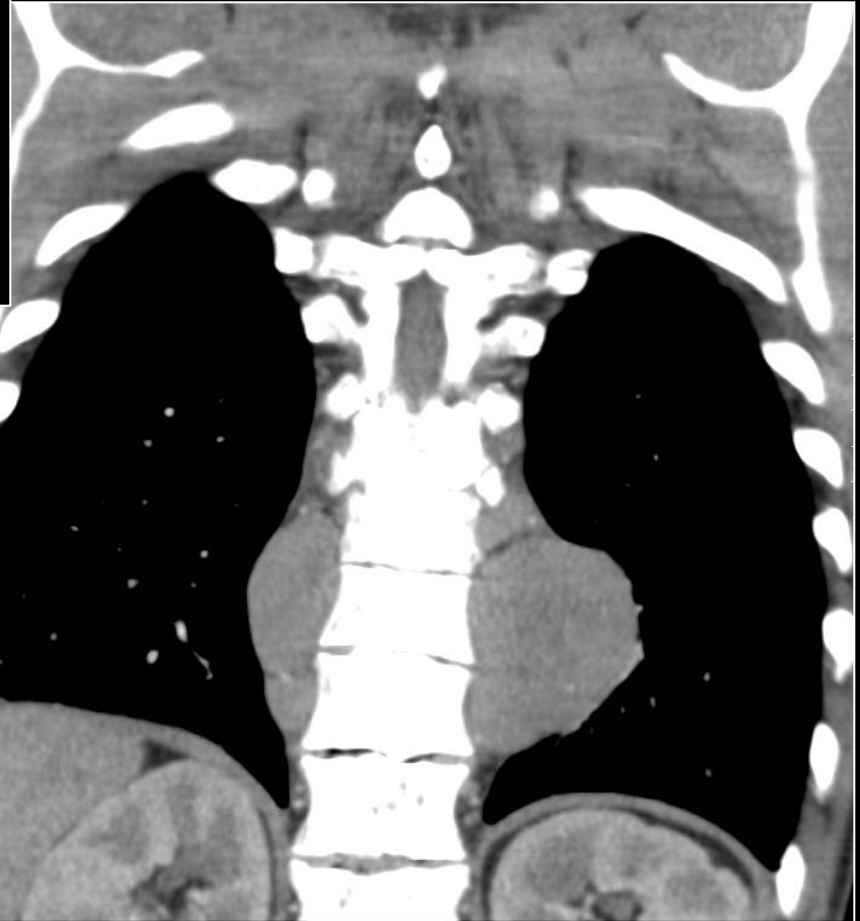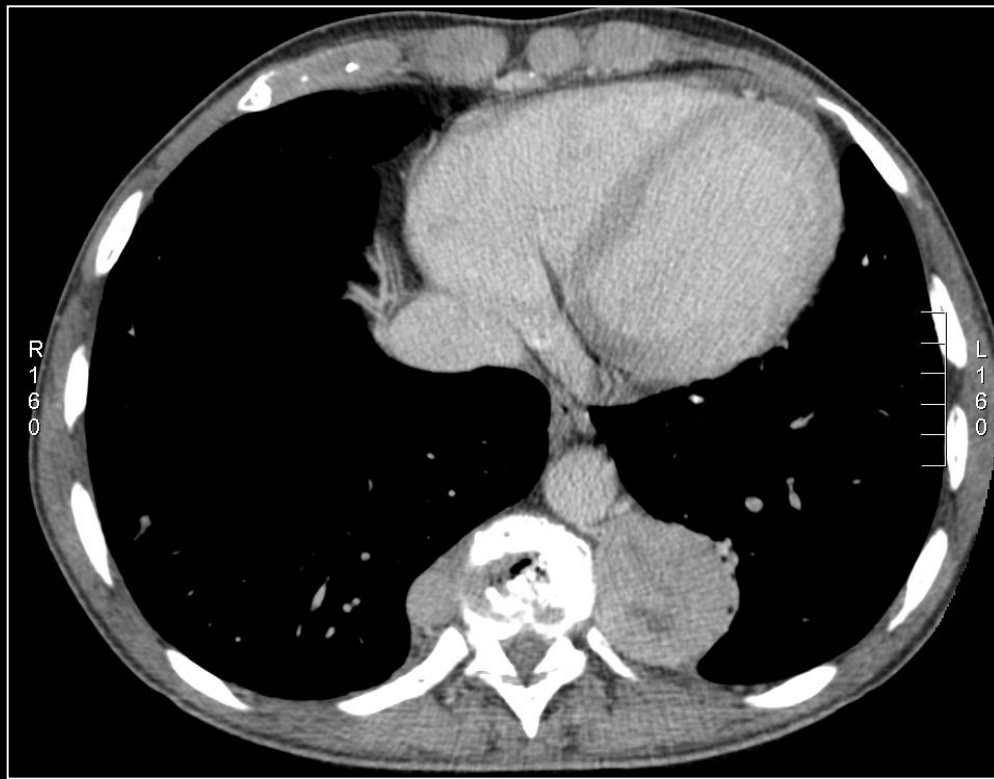
# PSEUDO-LIPOME INTRA-CAVE

- confluence v sus-hép/VCI
- en continuité avec graisse péri-oesophagienne
- IIaire angulation et rétrécissement portion médiale de la VCI
- image variable selon la respiration



# A retenir

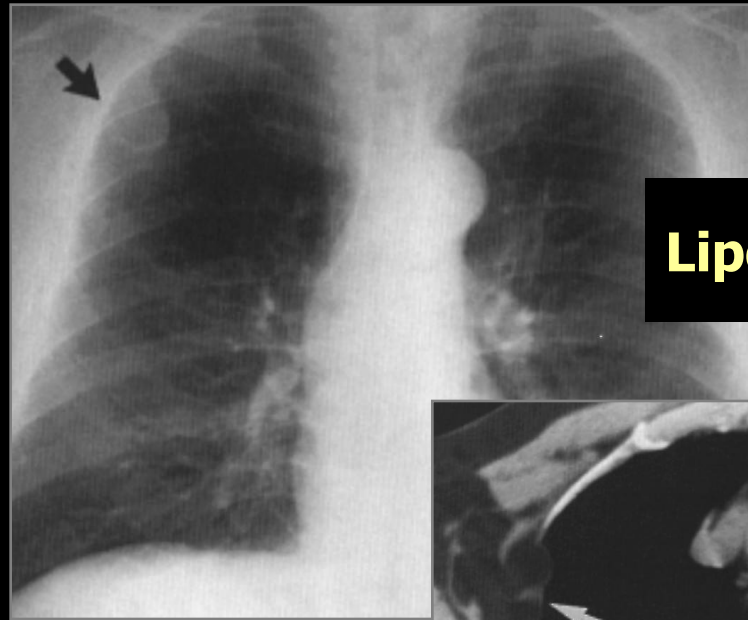
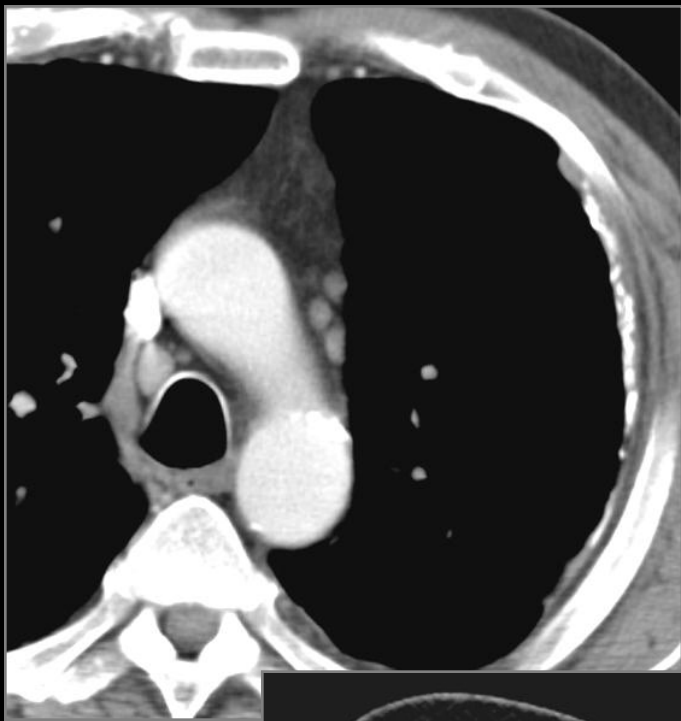- Lésions du médiastin antérieur :
  - Thyroïde
  - Thymus
  - Lymphome
  - Tumeur germinale
- Lésions du médiastin antéro-inférieur :
  - Kyste pleuro-péricardique
  - hernie de la fente de Larrey
  - Lipome, hémangiome, lymphangiome
- Lésions du médiastin moyen :
  - Adénopathies
  - Kyste bronchogénique
  - Œsophage
  - Vasculaire
- Lésions du médiastin postérieur :
  - Hématopoïèse extramédullaire
  - Tumeurs neurogènes
  - Kyste bronchogénique
  - Abscès juxta-osseux (BK, etc)



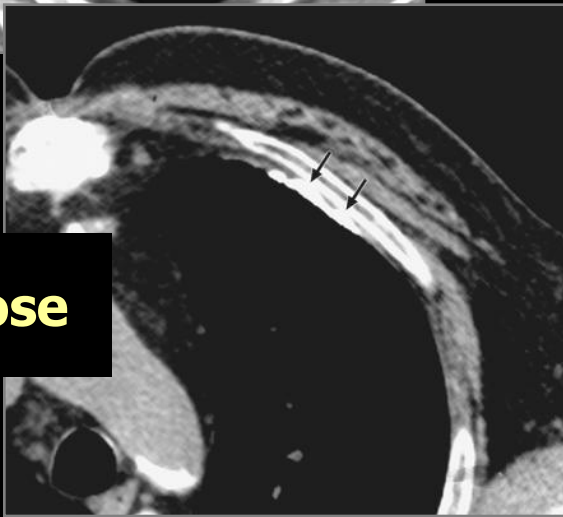
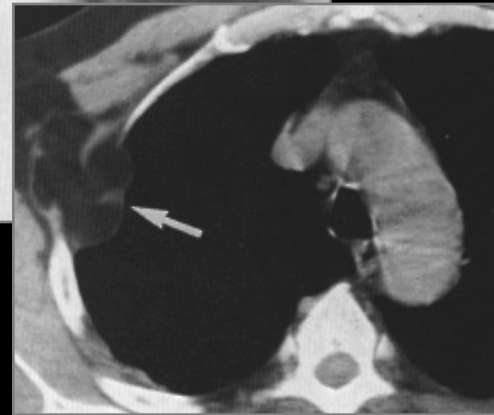**Hématopoïèse  
extramédullaire**

### 3/ PAROI THORACIQUE

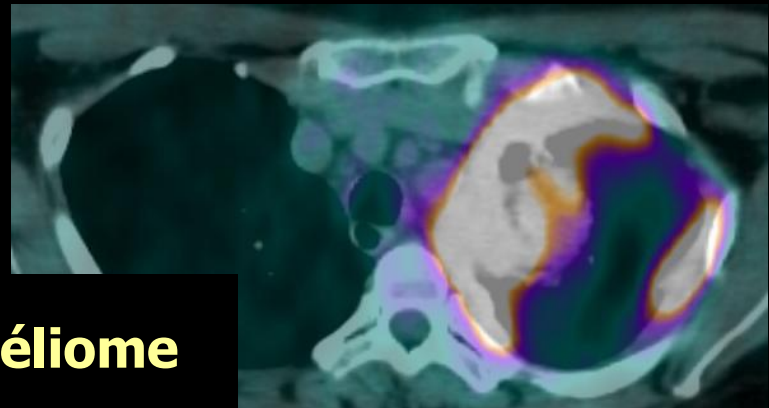
- **PLEVRE**
- CÔTES



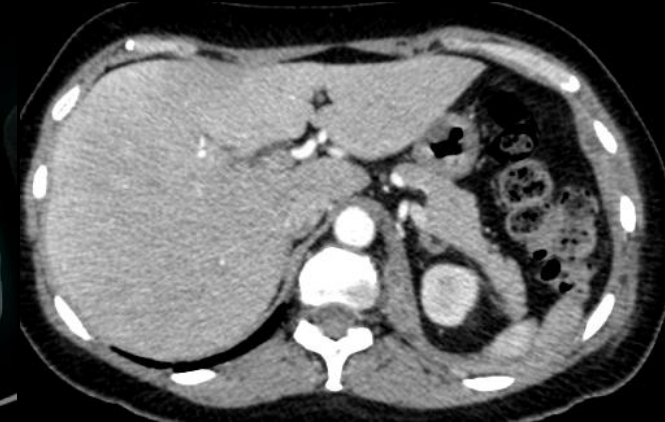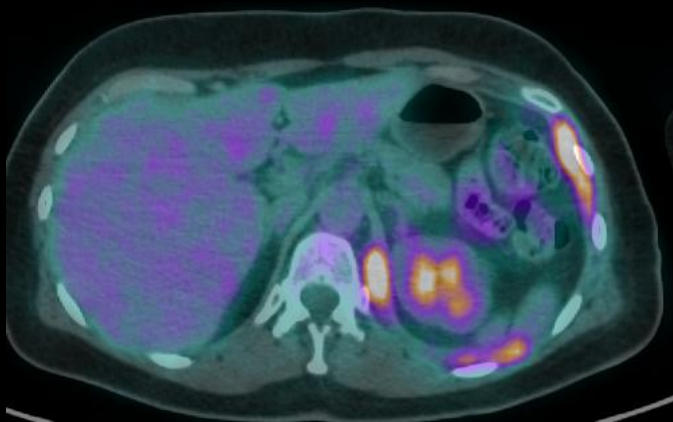
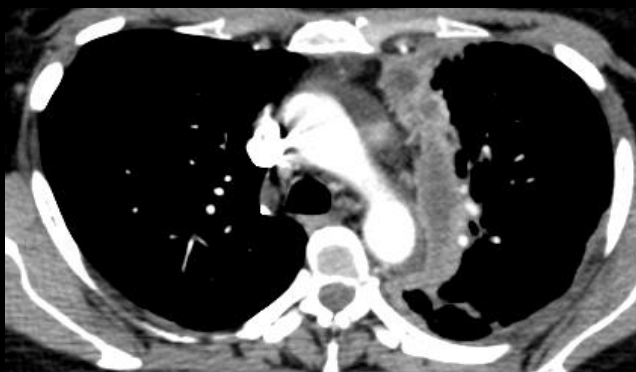
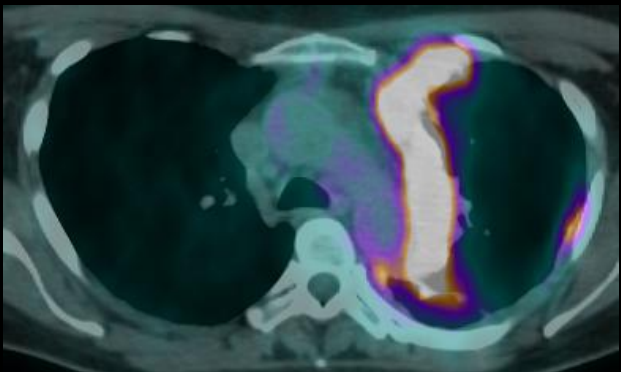
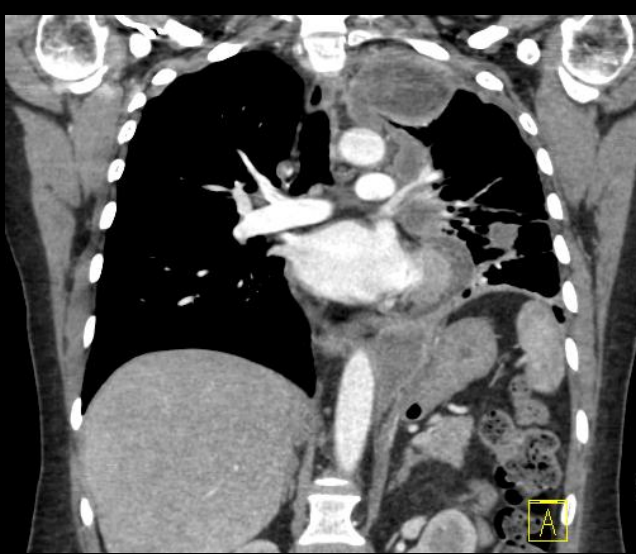
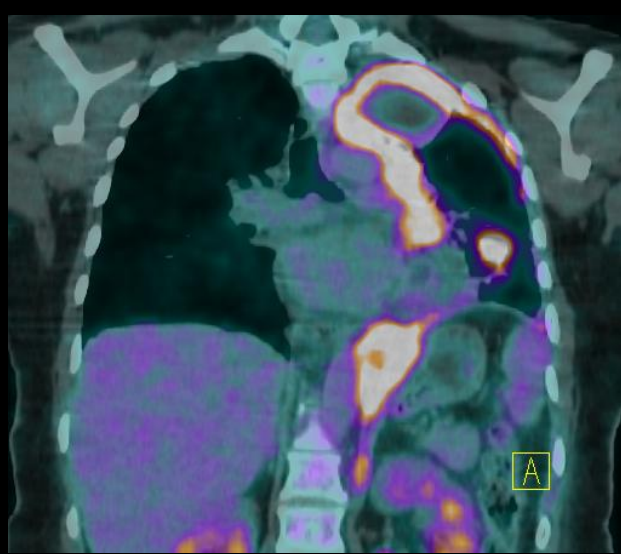
**Lipome**



**Asbestose**

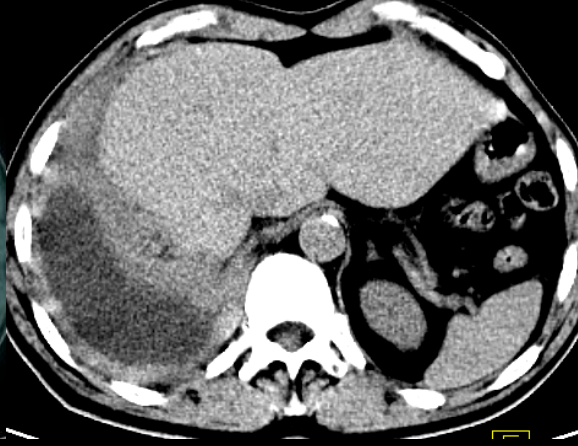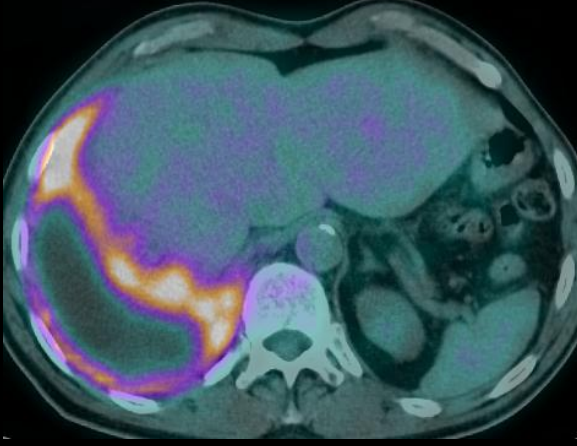
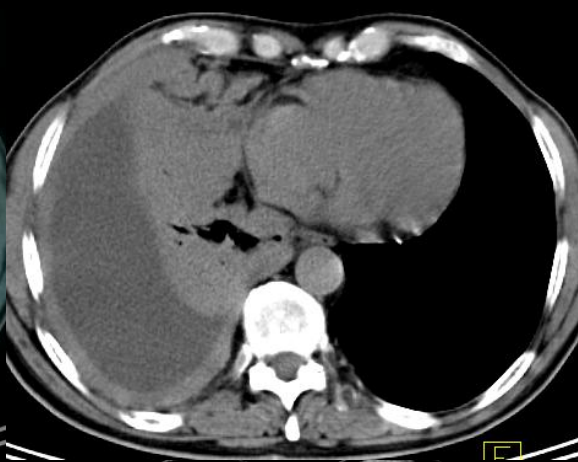
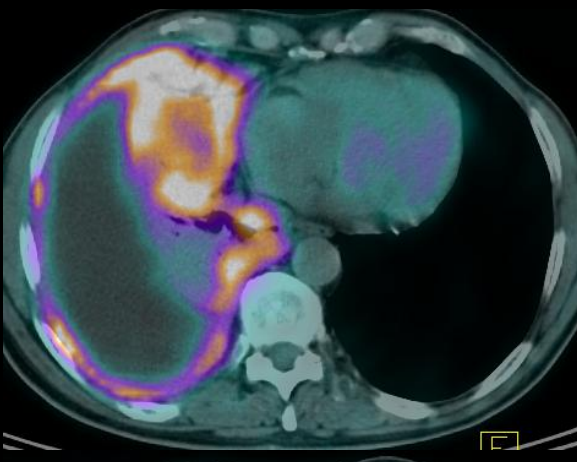
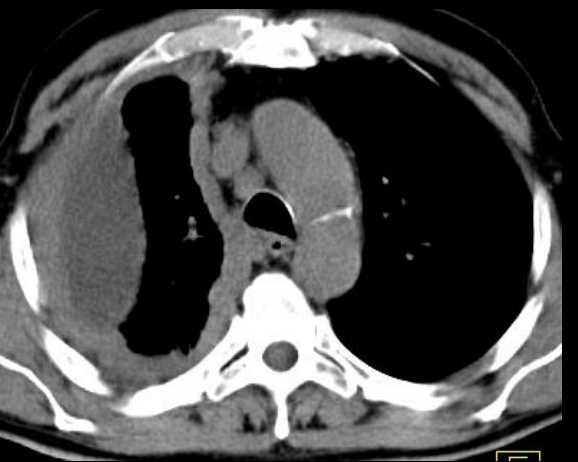
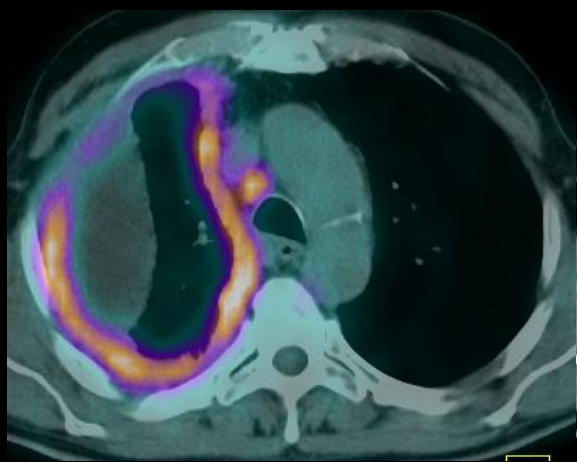
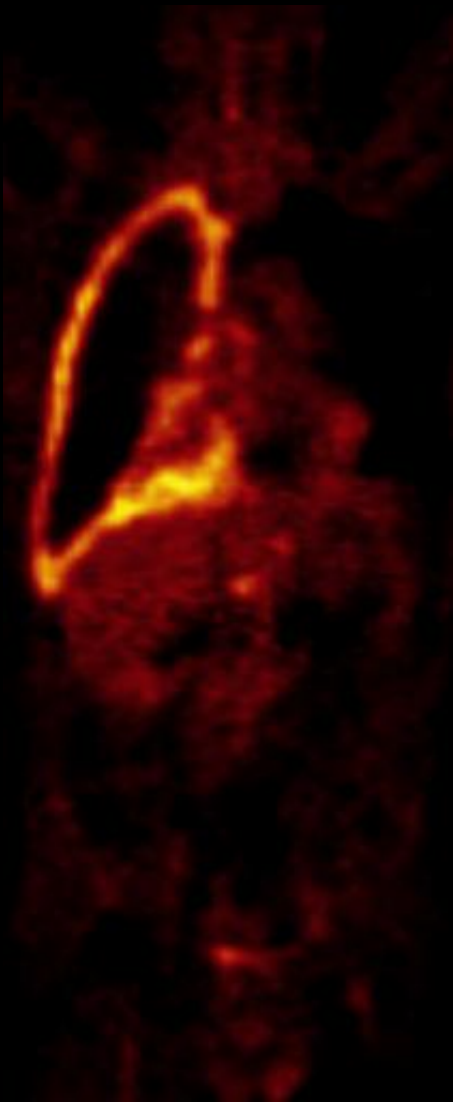


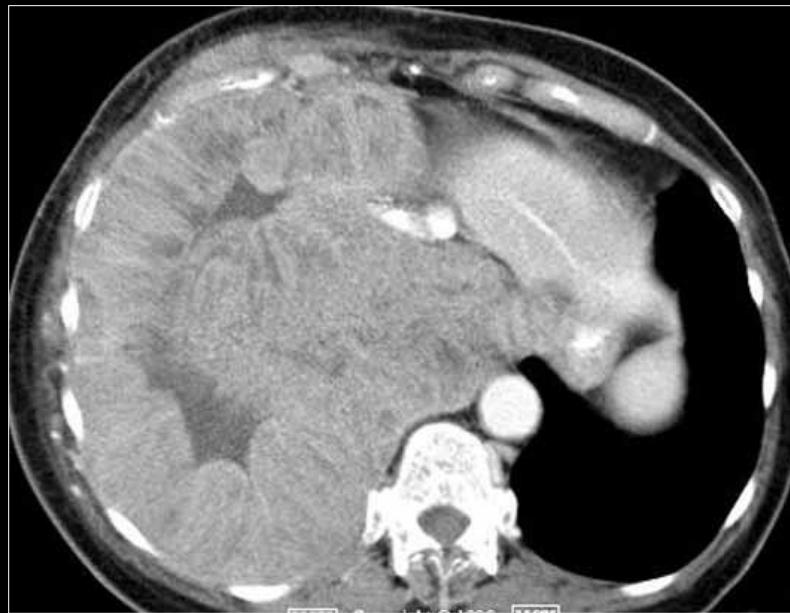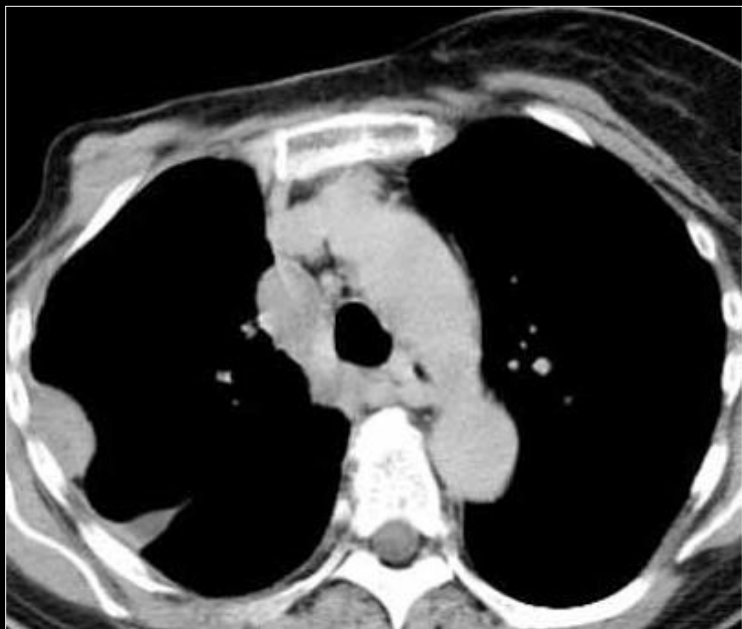**Mésothéliome**



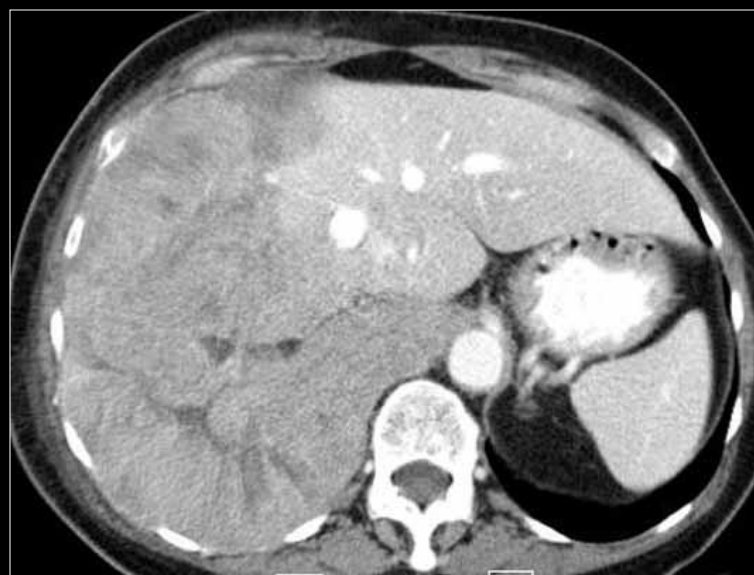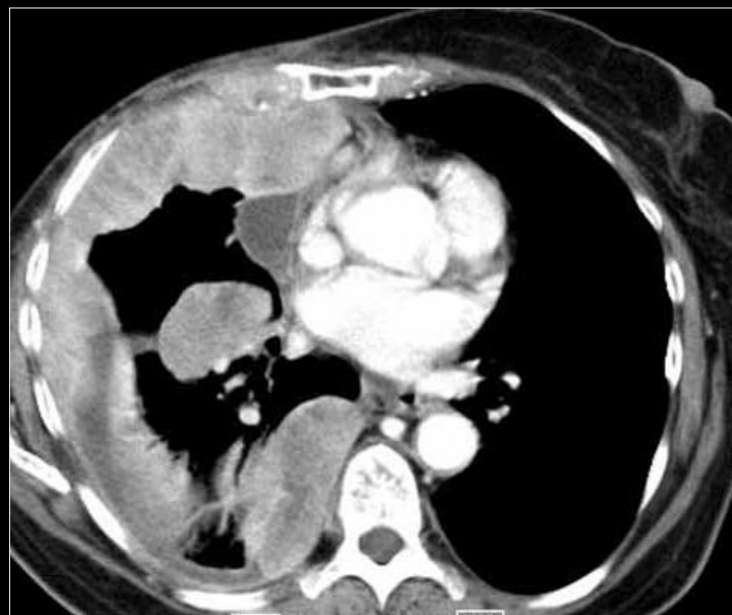
**Mésothéliome**

# Pachypleurite



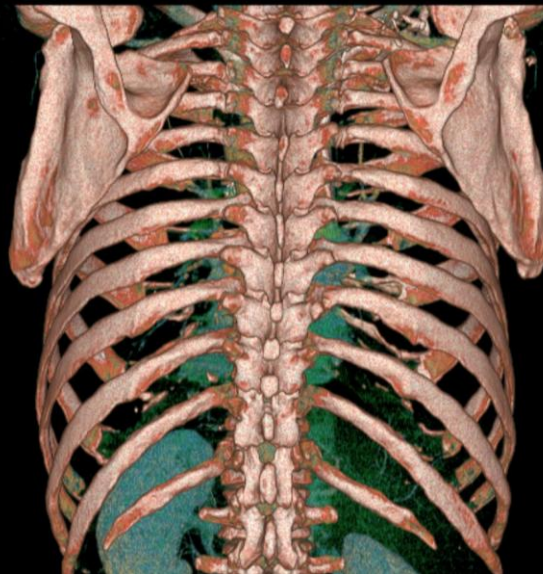

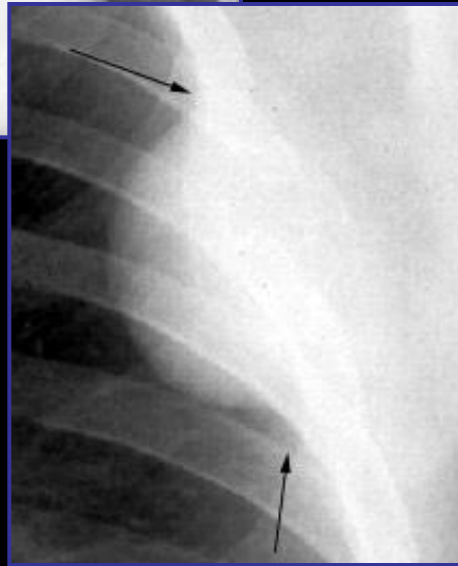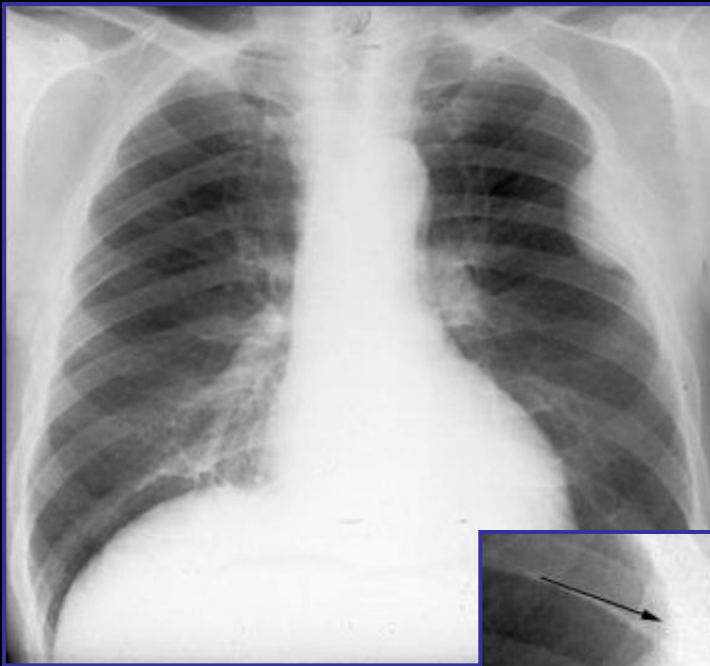
**Métastases K sein**



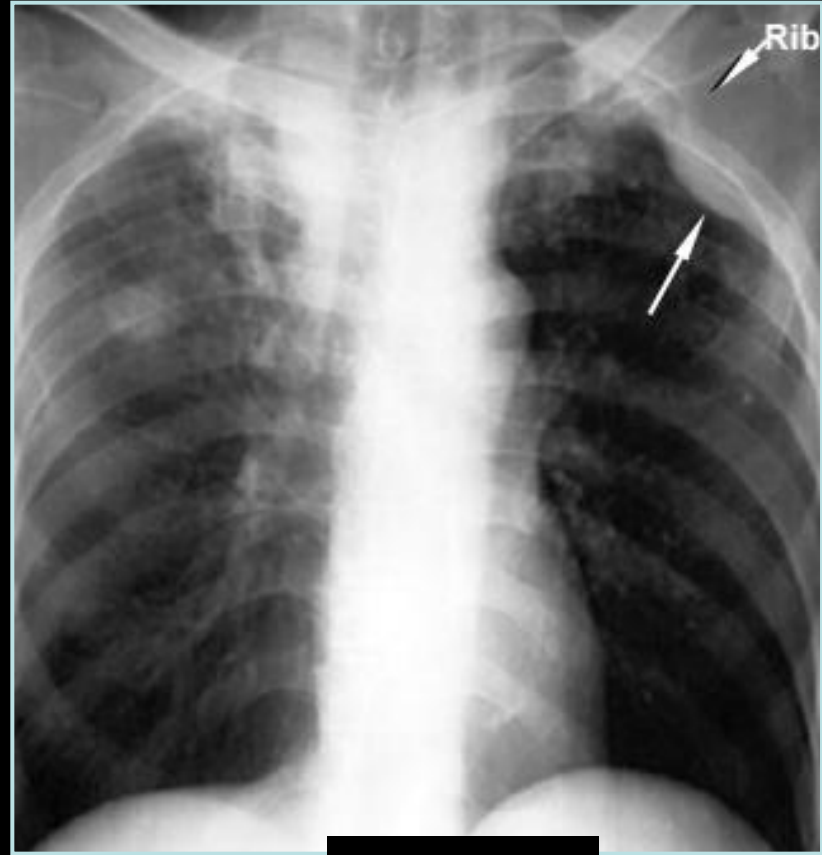
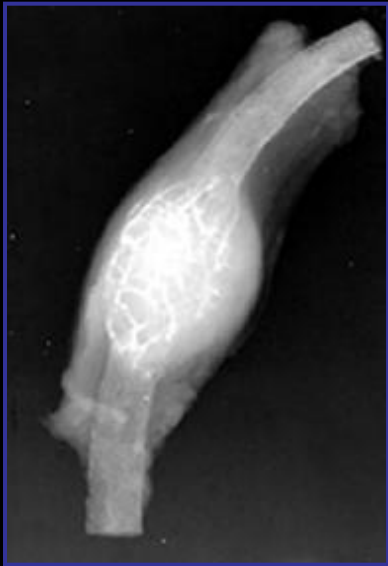
## 3/ PAROI THORACIQUE

- PLEVRE
- CÔTES

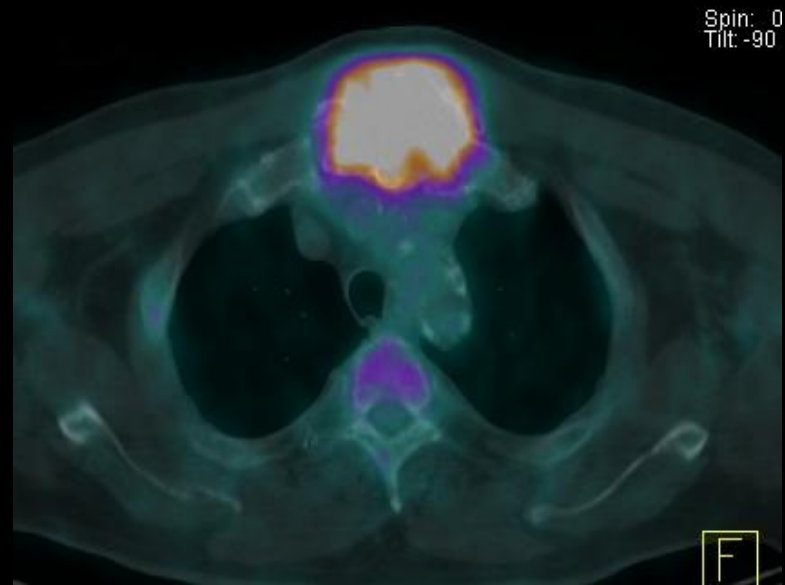
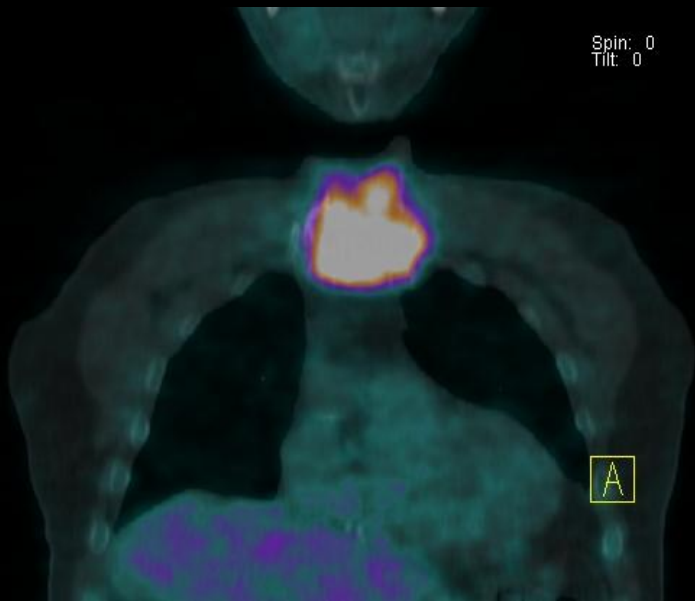


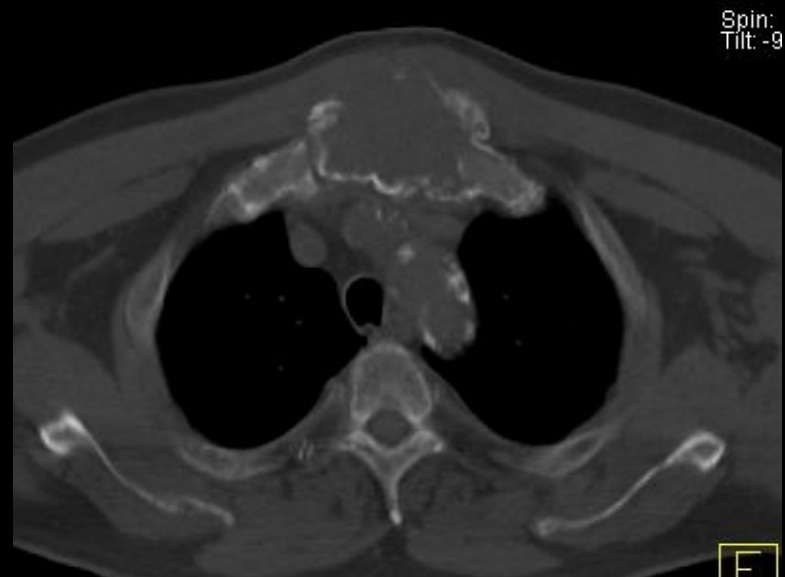
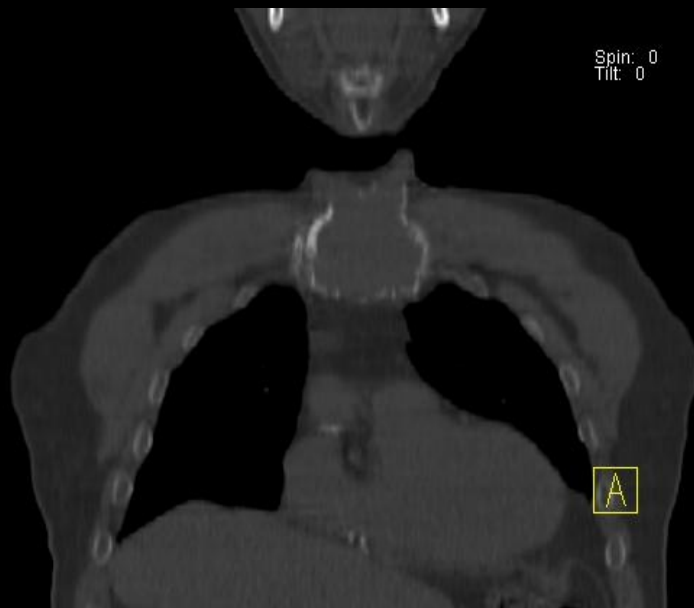**Plasmocytome**



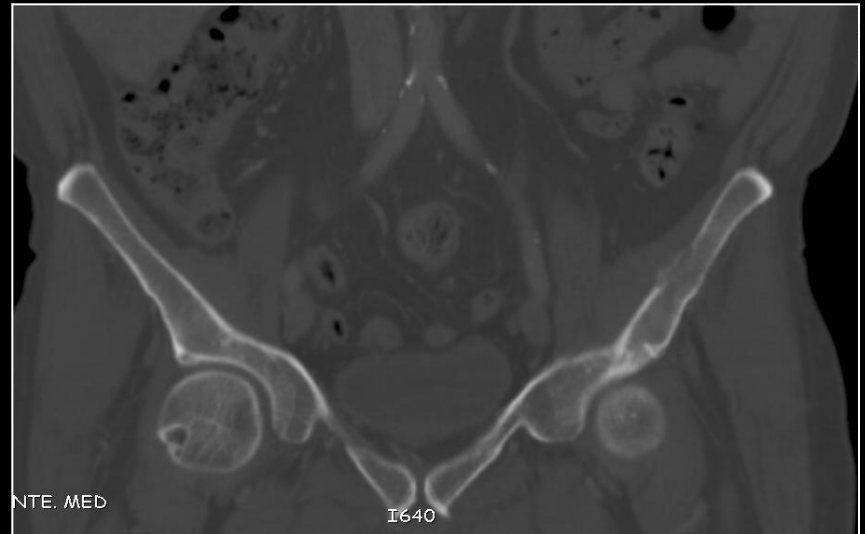
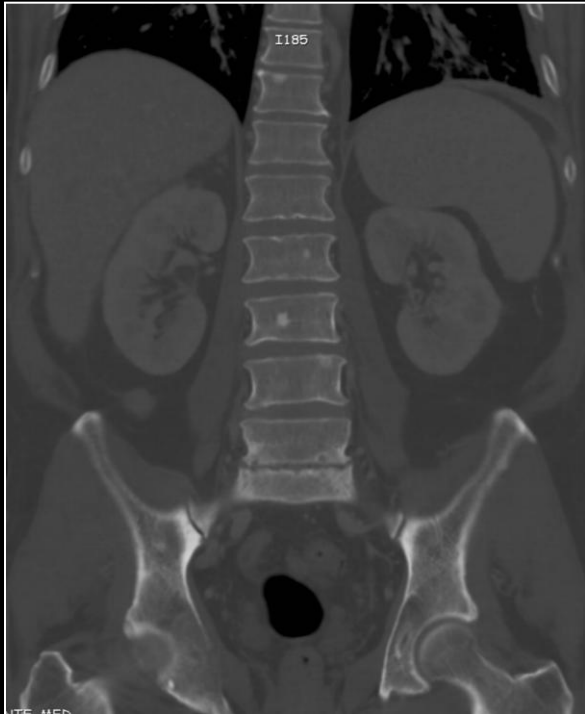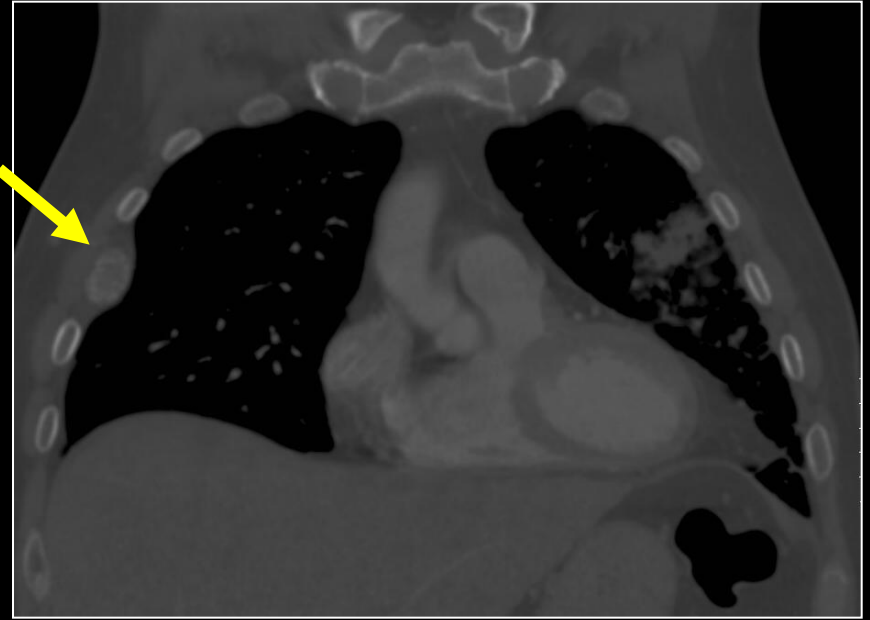
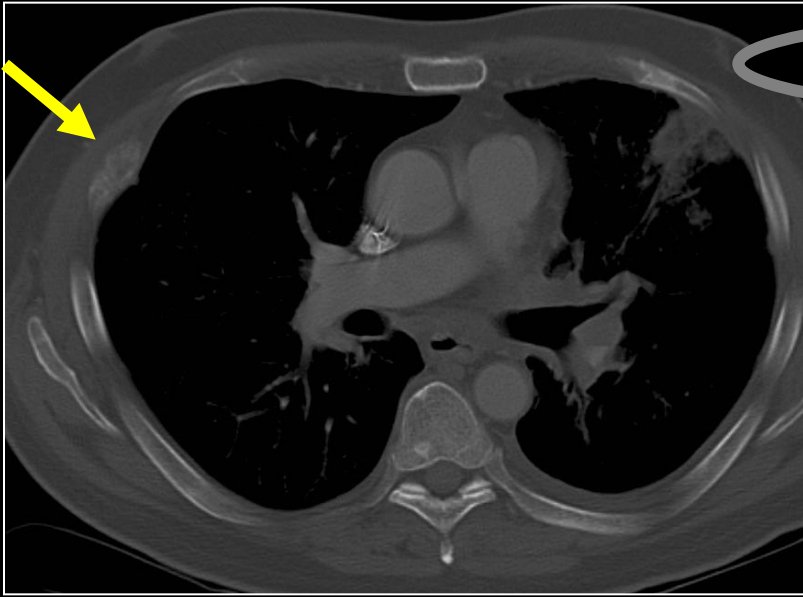
**Métastase**



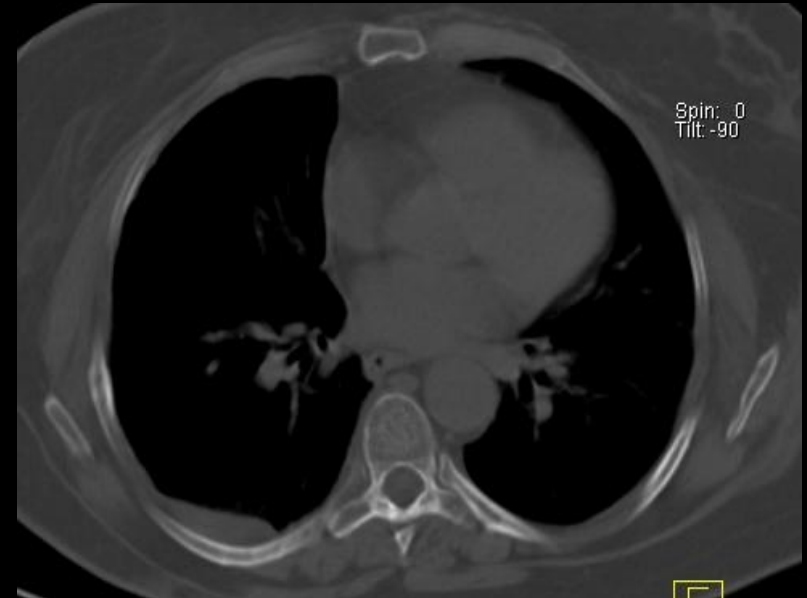
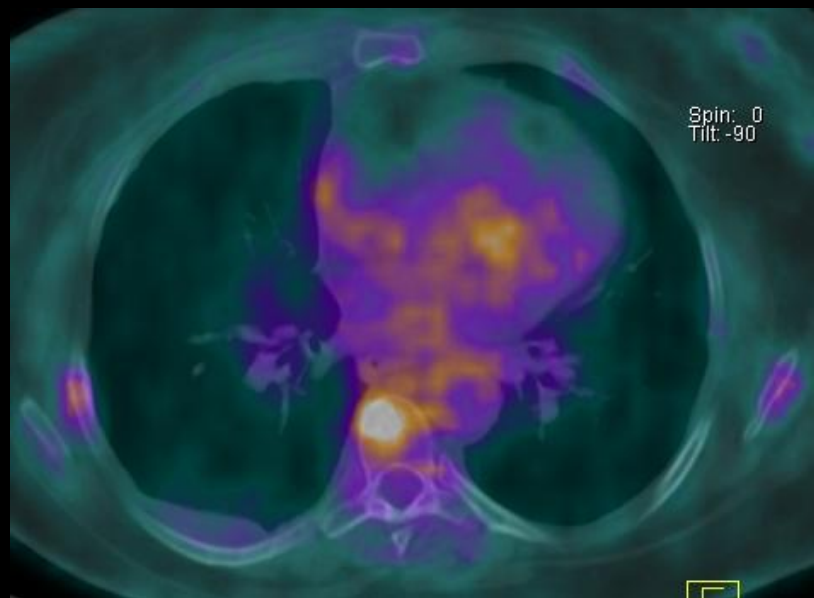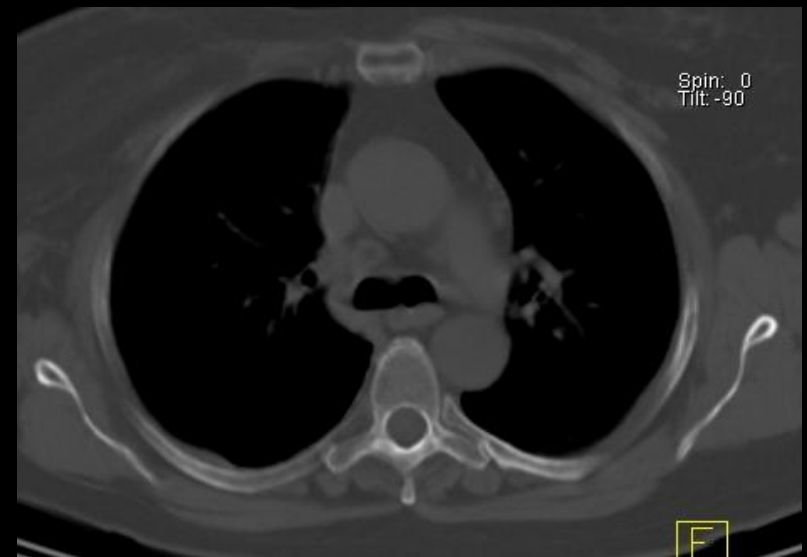
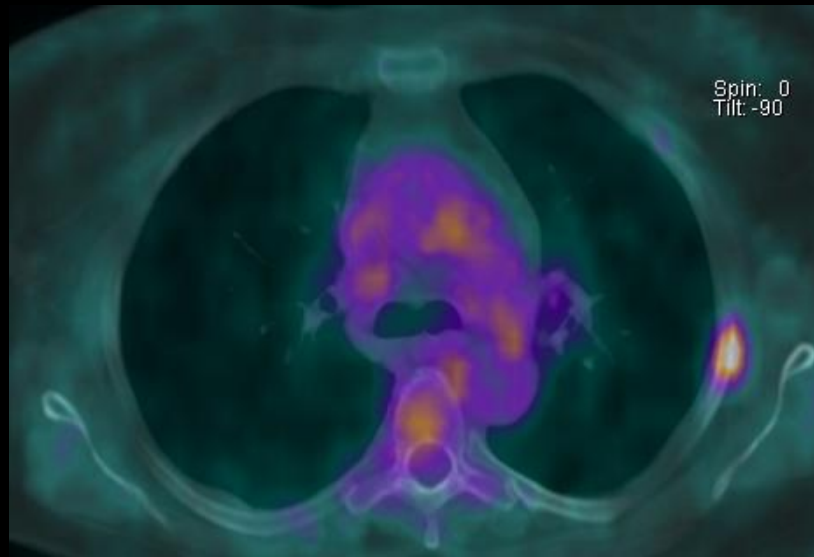**plasmocytome**

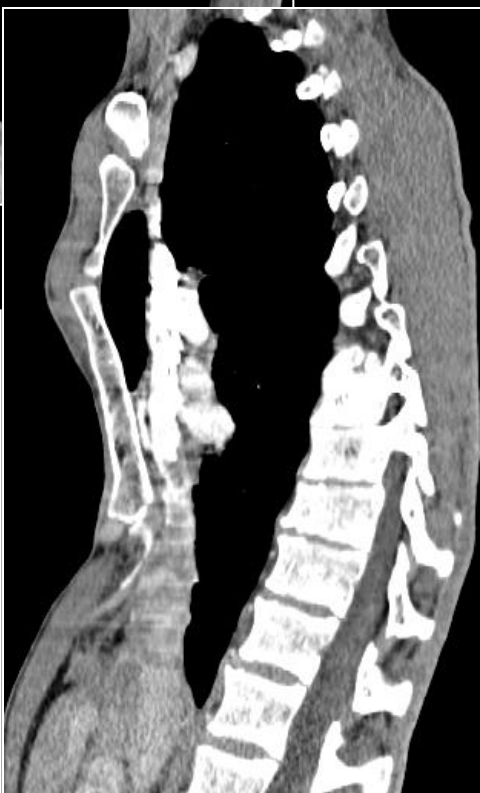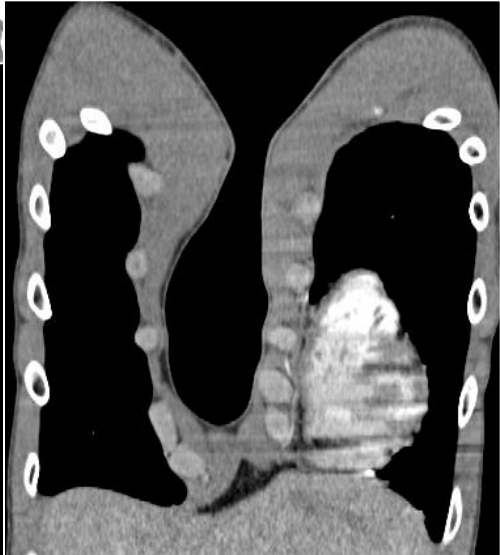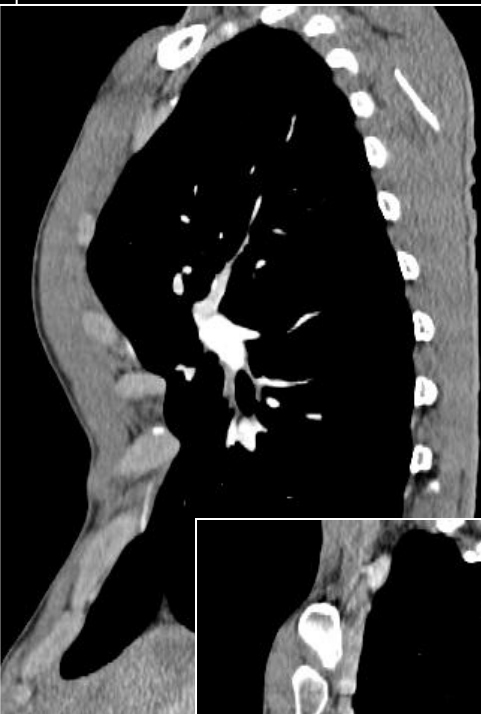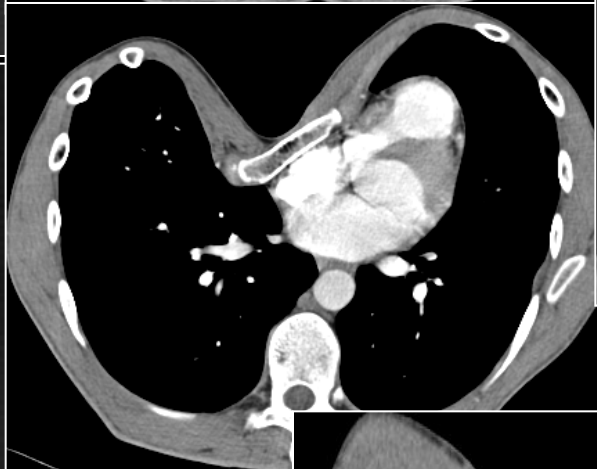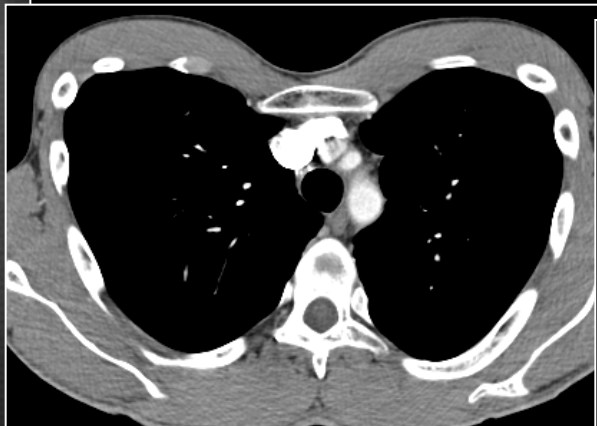
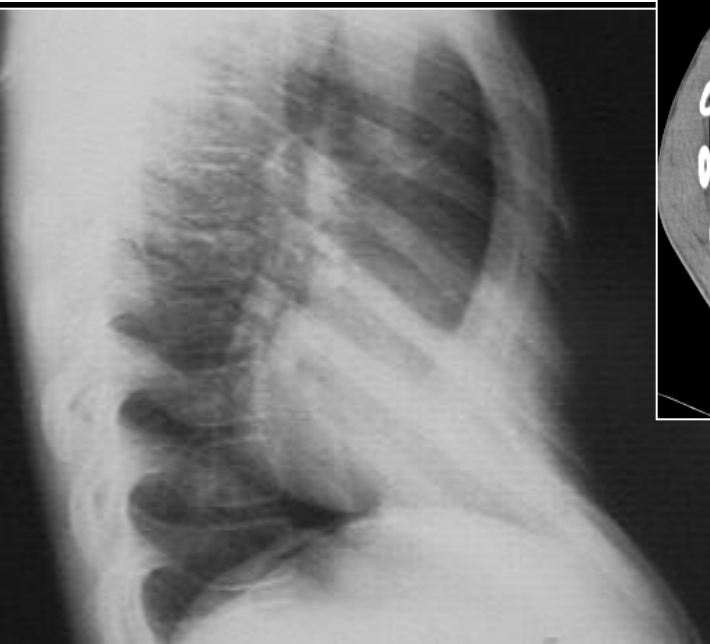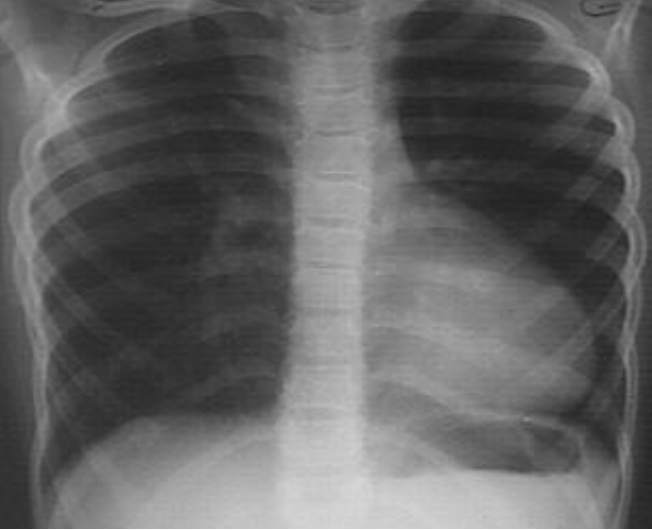


# Métastase de carcinome bronchique



# Métastase de carcinome bronchique





**Pectus excavatum**

***Merci de votre attention!!!***