

# **Tumeurs malignes des Voies Biliaires**

**Valérie CROISE-LAURENT**

# Plan

- **Tumeurs de la vésicule biliaire**
- **CCK IH**
- **CCK hilaires**
  - Diagnostic positif
  - Bilan d'extirpabilité
- **Tumeurs du bas cholédoque**

# Points Clés

---

- Incidence : 2000 nvx cas/an (3% des cancers digestifs)
- Augmentation cste dans les pays occidentaux
- **Classification :**
  - Tumeurs de la vésicule biliaire
  - Cholangiocarcinomes intra-hépatiques
  - Cholangiocarcinomes extra-hépatiques
    - Hilaires : Tumeur de Klatskin (60%)
    - De la voie biliaire principale (25%)

## Macroscopie

Masse Intraparenchymateuse  
(« Mass forming »)

Infiltration canalaire  
(« Periductal infiltrating »)

Prolifération tumorale  
endocanalaire  
(« Intraductal growth »)

## Aspects en Imagerie

Cholangiocarcinome  
intrahépatique

Cholangiocarcinome hilaire

Cholangiocarcinome EH

## Microscopie

– ADK glandulaires

– ADK glandulaires

– ADK papillaires

# Une dénomination commune mais ....

	Tumeurs de la vésicule	CCK IH	CCK hilaires	CCK de la VBP
<b>FDR</b>	Calculs Long common channel	CSP Hépatopathies Maladies biliaires congénitales	CSP	
<b>Circonstances de découverte</b>	Fortuite Masse segment V	Masse	Ictère	Ictère
<b>Aspects en imagerie</b>	Infiltration diffuse paroi Masse	Masse parenchymateuse	Infiltrante Polypoïde	Infiltrante Polypoïde
<b>Diagnostics différentiels</b>	CCK IH Métastase	LFH	Mirizzi, CSP, cholangite Causes néoplasiques extrinsèques	ADK pancréas...
<b>Preuve du cancer</b>	Possible	Possible	Non (Cytologie sur brossage)	Echoendo.
<b>Stratégie thérapeutique</b>	Cholécystectomie +/- bi ou trisegmentectomie Ou hépatectomie drte élargie au V	Réssection segments hép	Réssection biliaire et hépatique	DPC

Rôle majeur de

l'imagerie

# Plan

- **Tumeurs de la vésicule biliaire**
- **CCK IH**
- **CCK hilaires**
  - Diagnostic positif
  - Bilan d'extirpabilité
- **Tumeurs du bas cholédoque**

# I. Tumeurs de la vésicule biliaire

- **Masse intrahépatique centrée sur la vésicule**
  - Masse contours irréguliers
  - **Diagn. différentiels** :
    - CCK IH
- **Sténose hilaire avec masse, épicode collet vésiculaire**
  - Masse hilaire et dilatation VBIH ++++++
  - **Diagn. différentiels** :
    - CCK hilaire, obstacles hilaires
- **Infiltration diffuse ou localisée de la paroi vésiculaire**
  - Epaissement irrégulier diffus ou focal
  - **Diagn. Différentiels** :
    - Cholécystite chronique
    - Cholécystite xantho granulomateuse

Uchiyama et al. J Hepatobiliary  
Pancreas Surg 2009

Yun EJ et al. Abdom Imaging 2004

Kim et al. AJR 2008

Lane et al. Radiographics 1989

Jung et al. Eur Radiol 2005

Choi et al. Abdom Imaging 2004

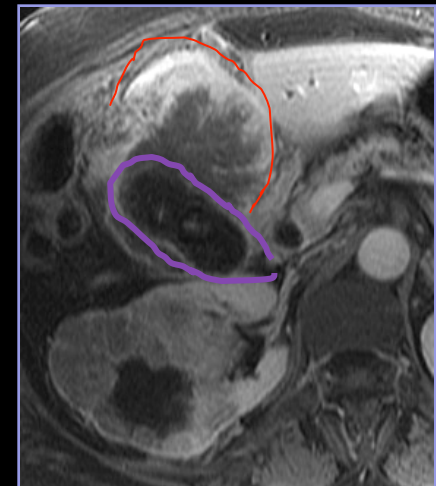
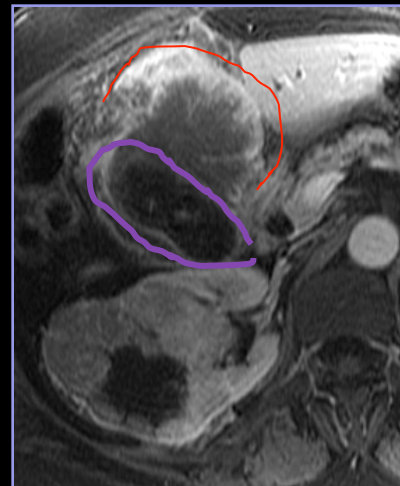
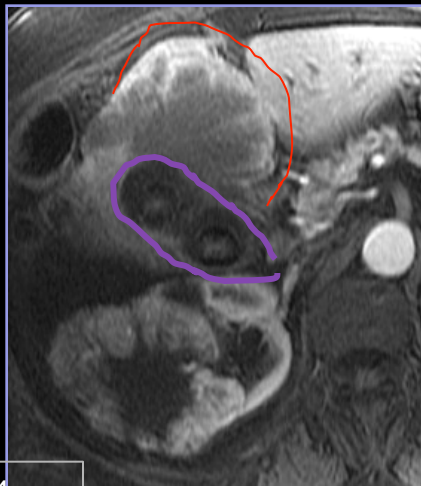
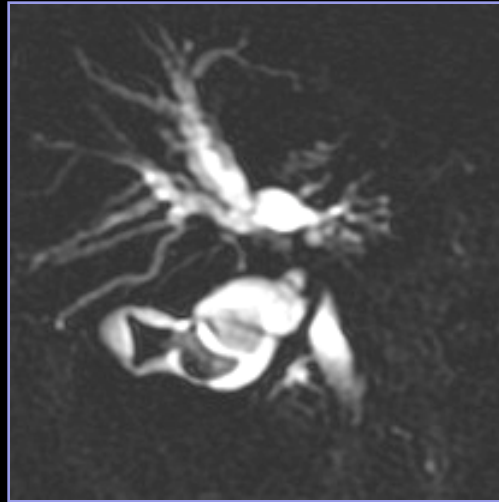
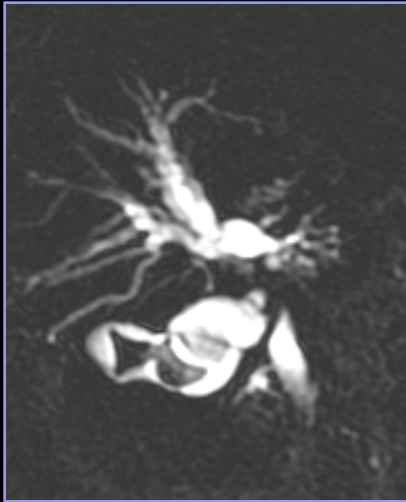
**Facteurs de risque**

-Calculs

-Long common channel

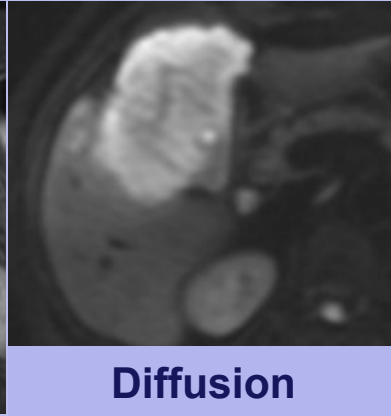
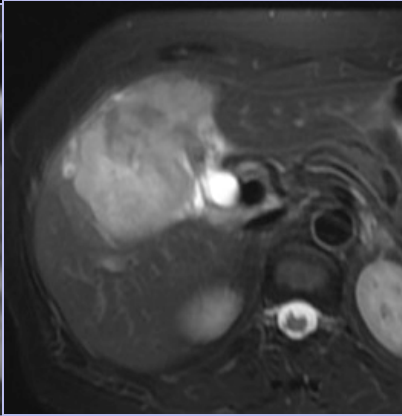
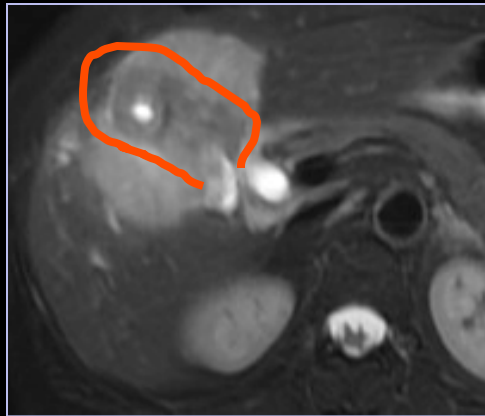
# I. Tumeurs de la vésicule biliaire

## 1. Masse hépatique centrée sur la vésicule

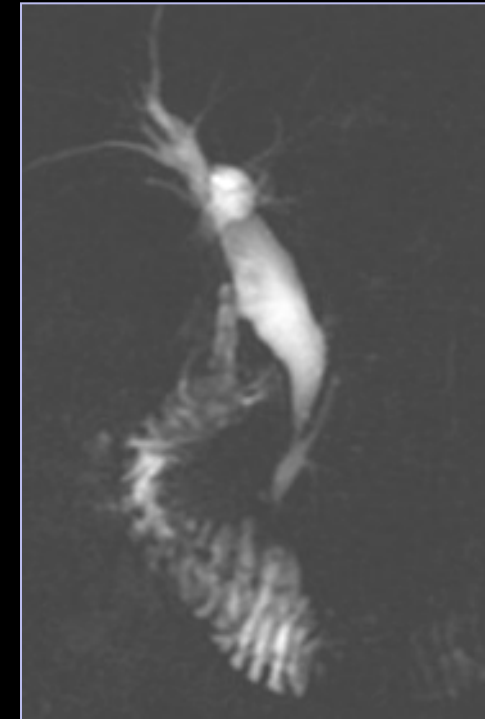
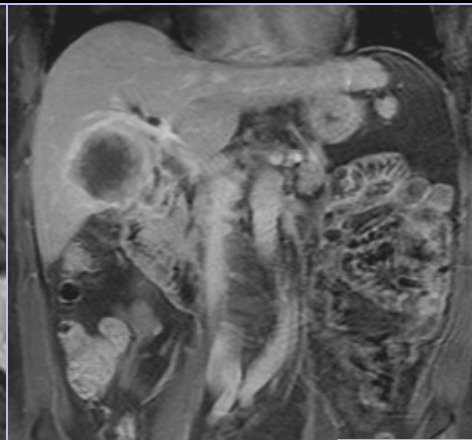
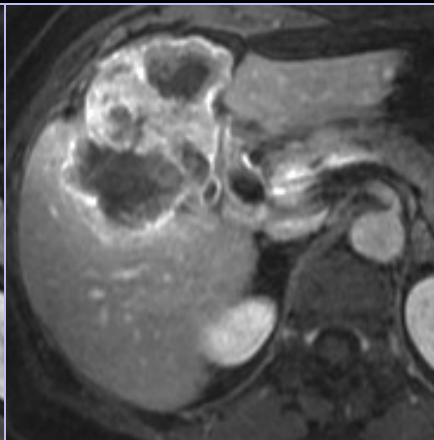
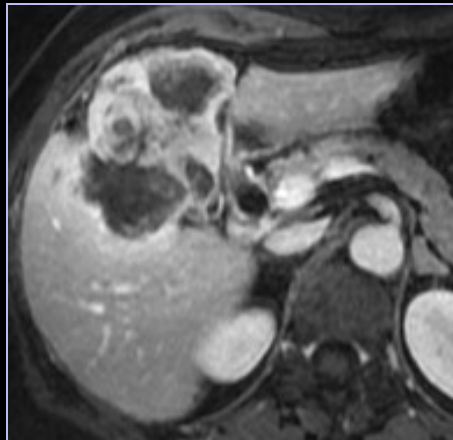


# I. Tumeurs de la vésicule biliaire

## 1. Masse hépatique centrée sur la vésicule



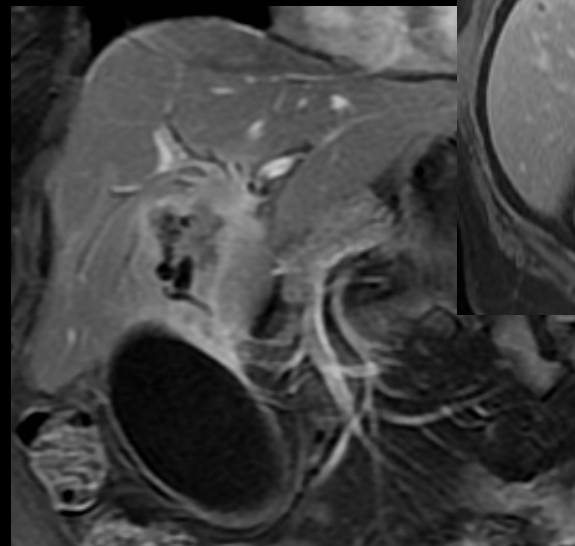
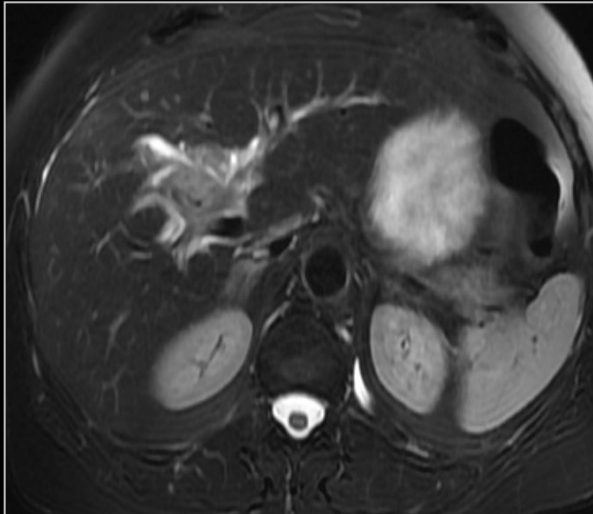
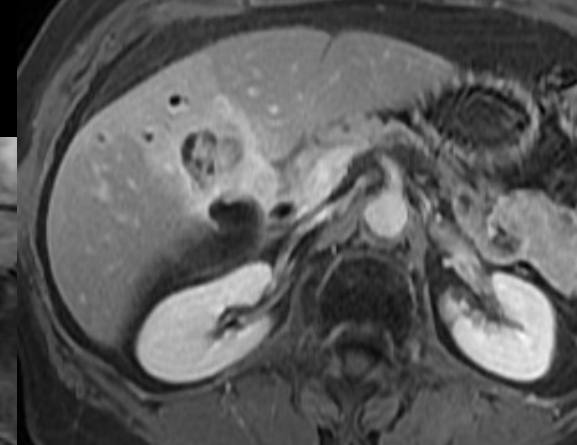
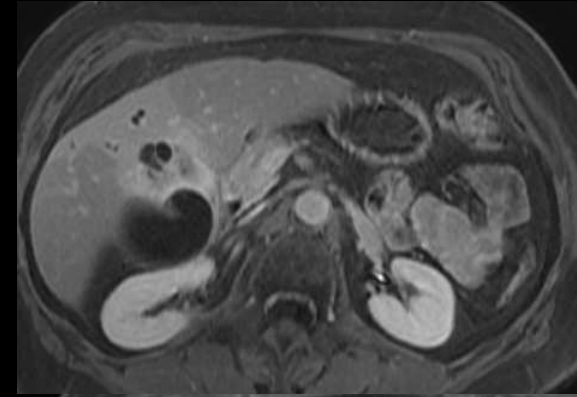
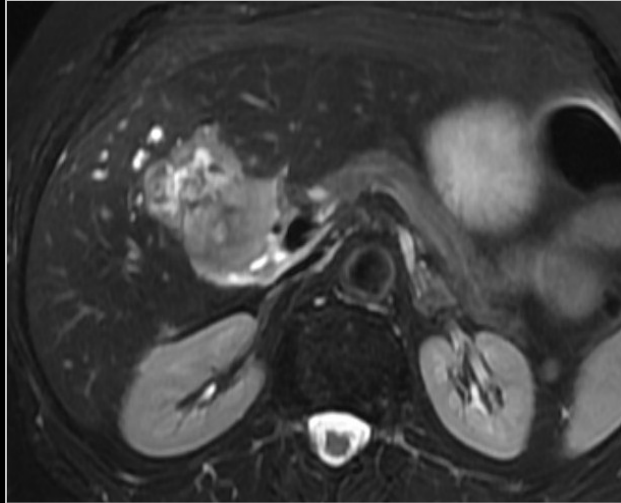
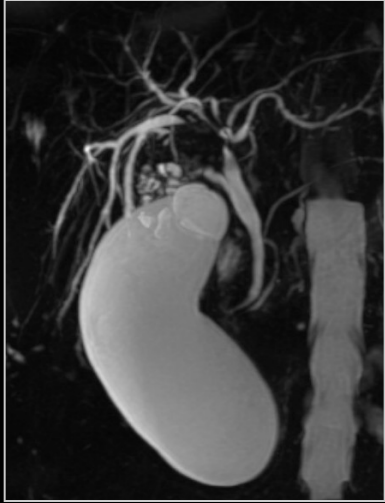
Diffusion



Long common

# I. Tumeurs de la vésicule biliaire

## 2. Sténose hilaire et masse

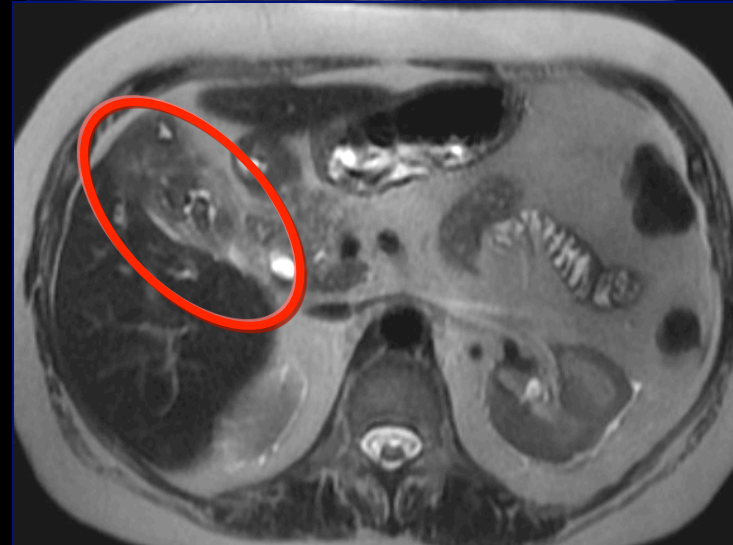
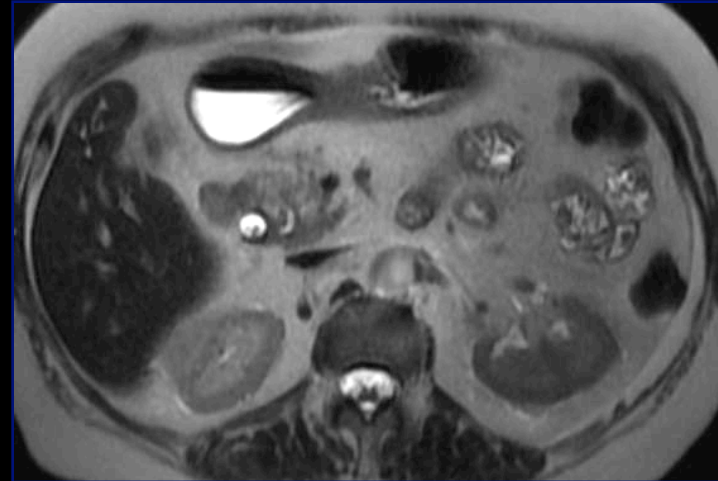
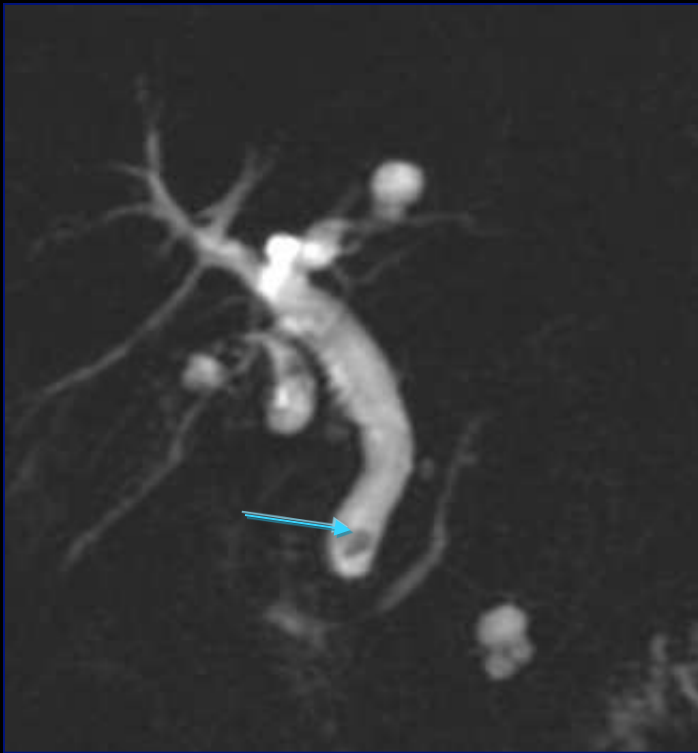


# I. Tumeurs de la vésicule biliaire

## 3. Epaissement irrégulier diffus parois vésiculaires

Femme, 82 ans

Ictère, Cholestase biologique



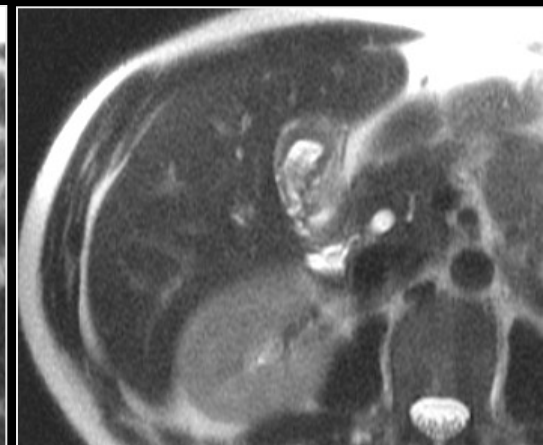
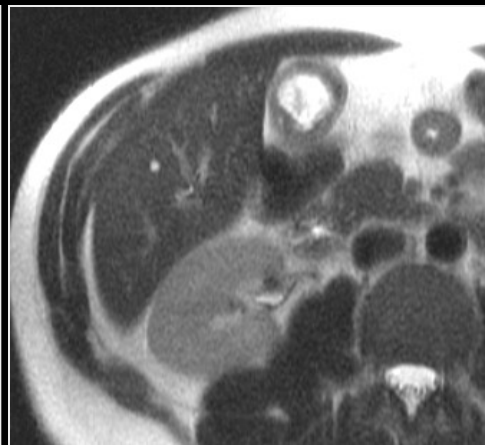
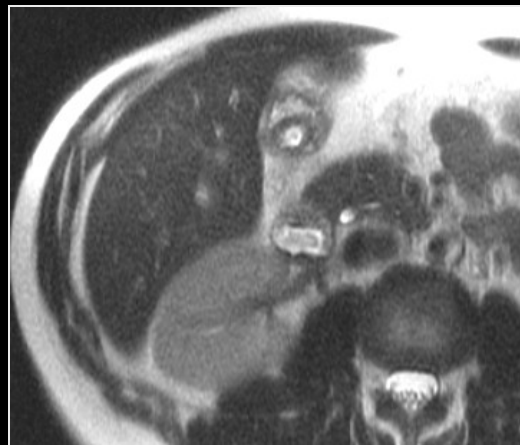
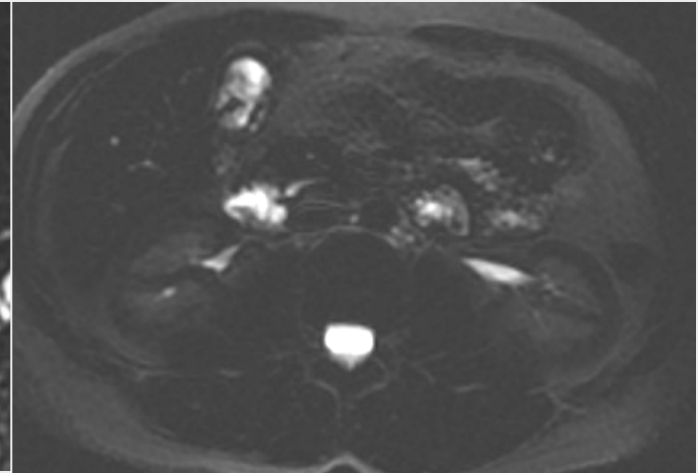
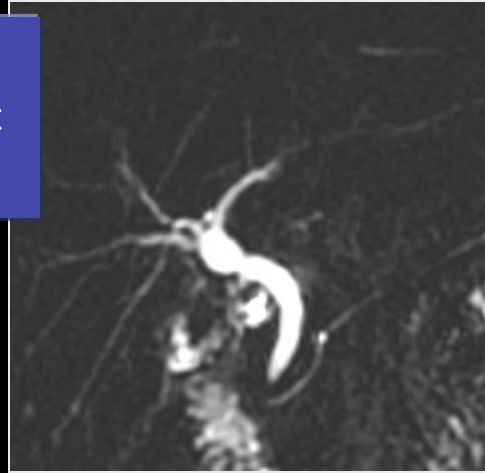
# I. Tumeurs de la vésicule biliaire

## 3. Epaissement irrégulier diffus parois vésiculaires

**Homme, 38 ans**

Douleurs de l'hypochondre droit

Recherche de calculs VBP

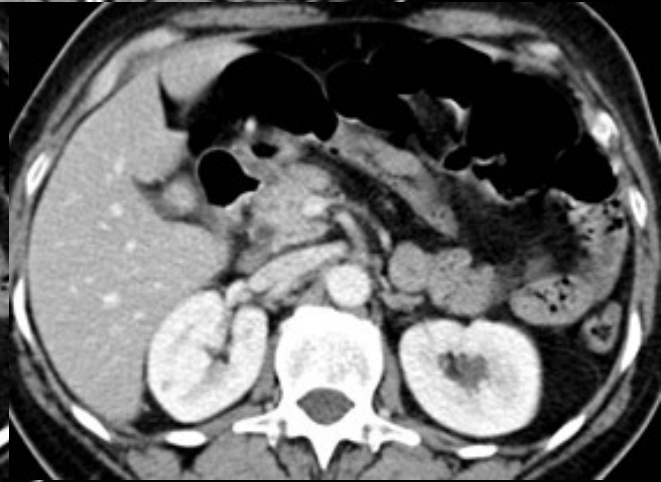
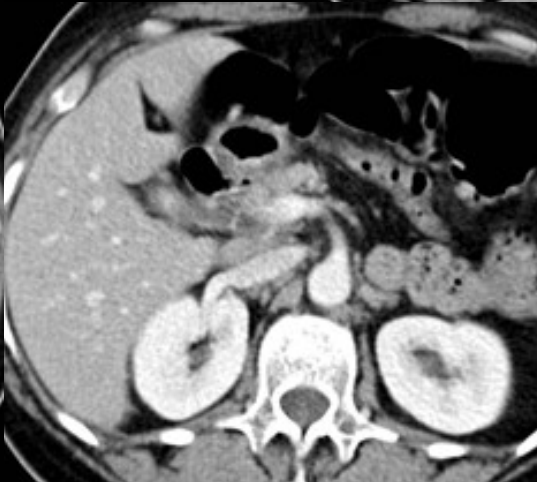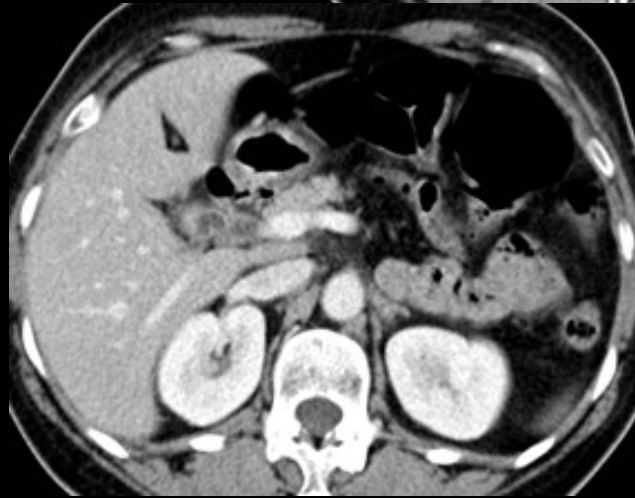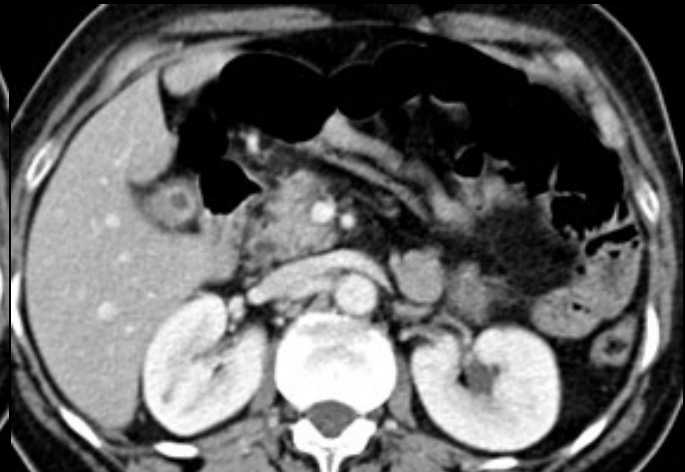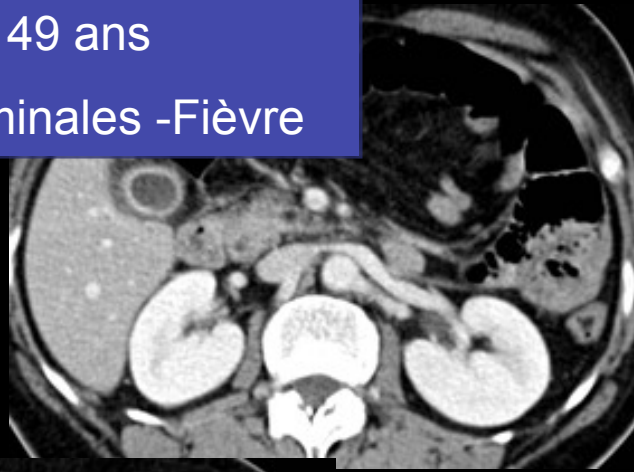


# I. Tumeurs de la vésicule biliaire

## 3. Epaissement irrégulier focal parois vésiculaires

Femme, 49 ans

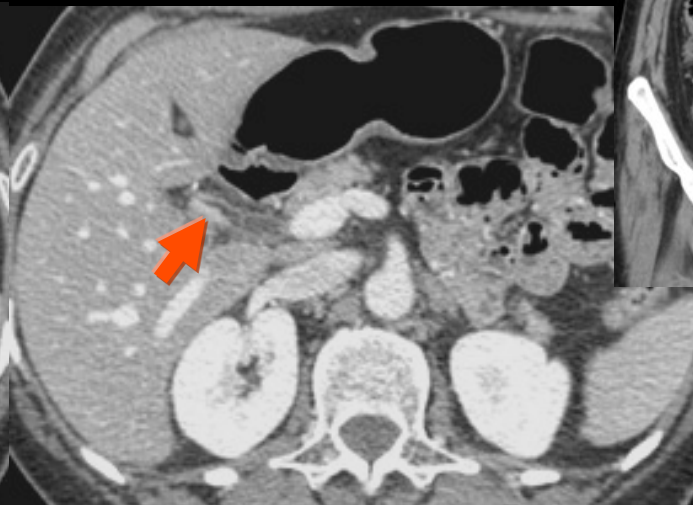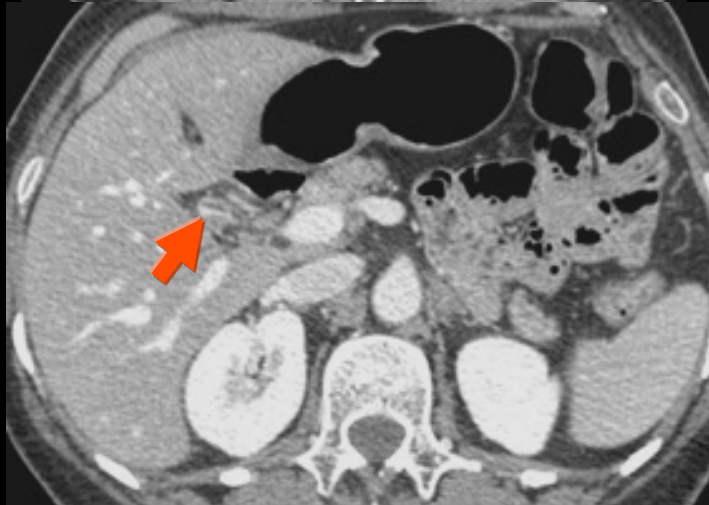
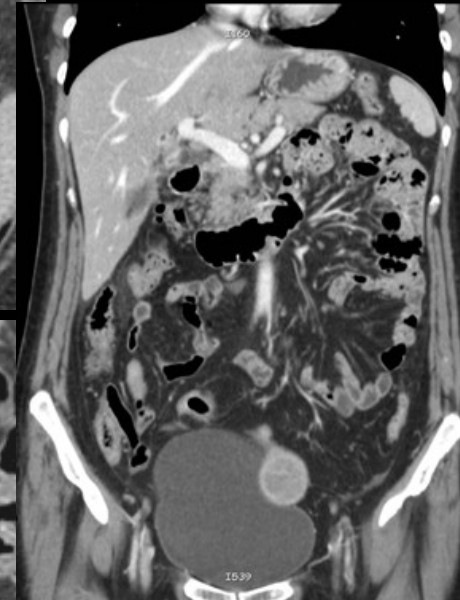
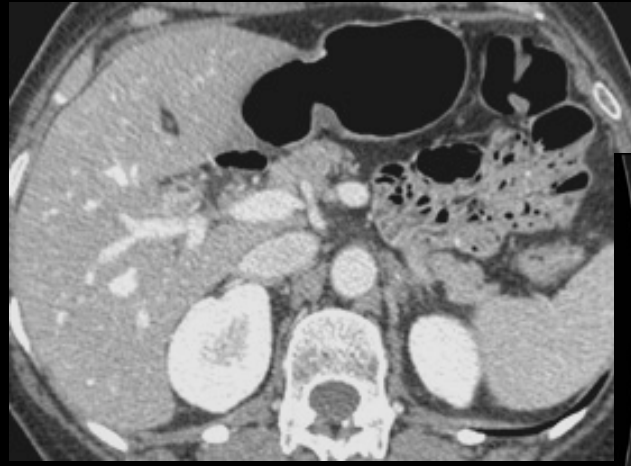
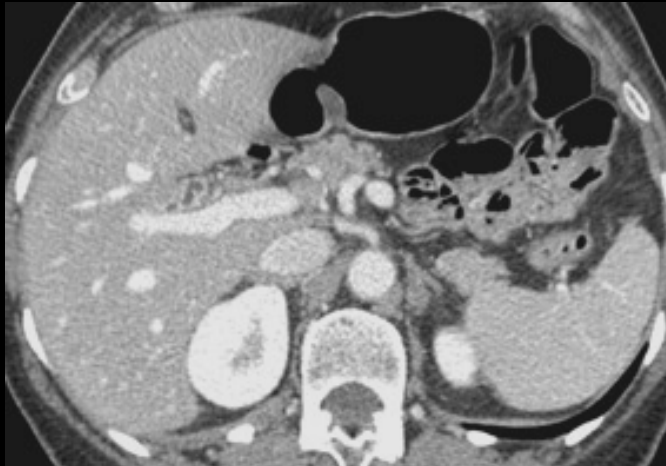
Douleurs abdominales - Fièvre



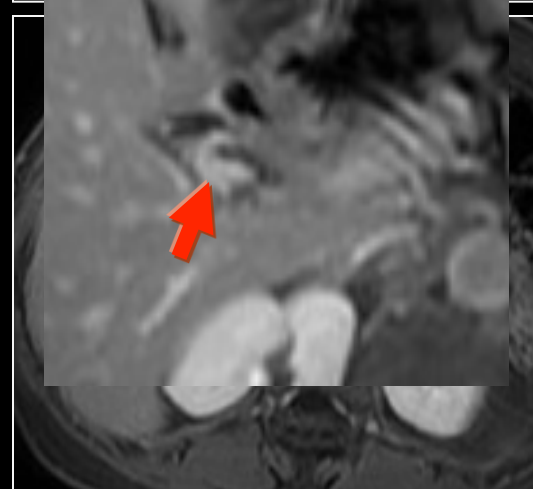
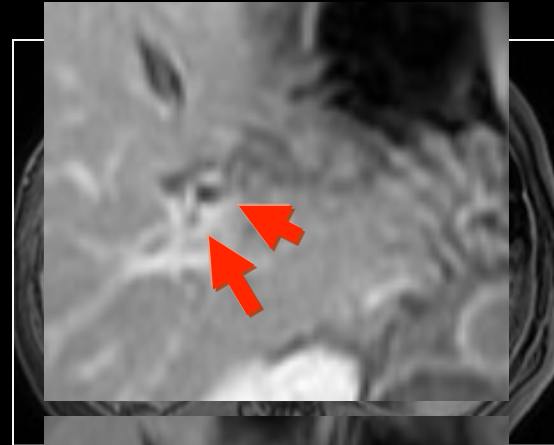
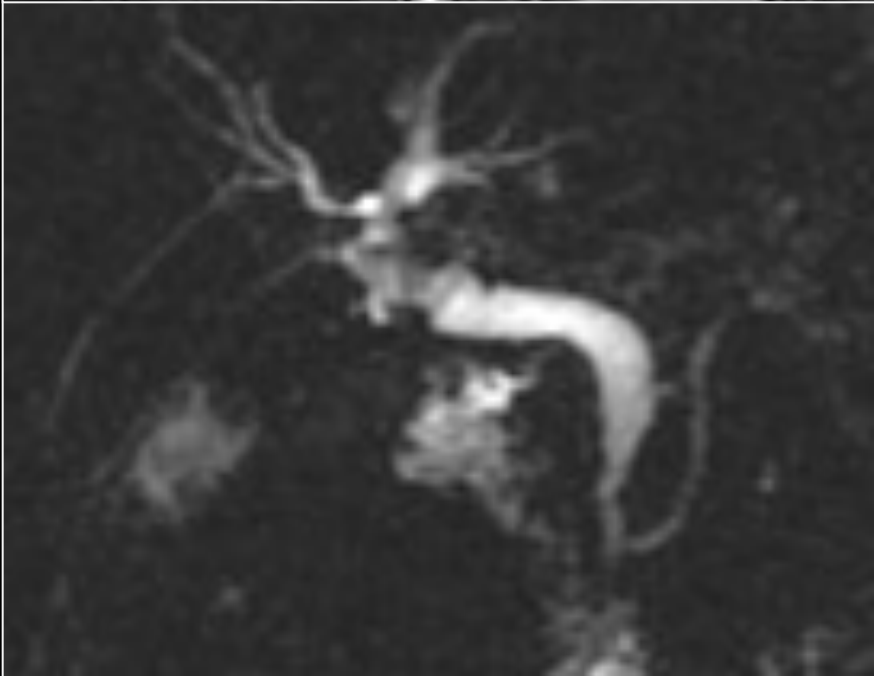
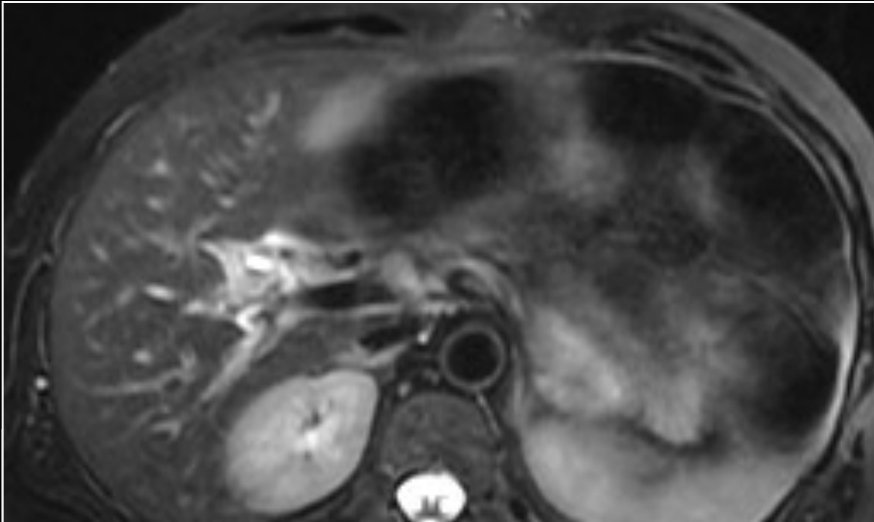
# I. Tumeurs de la vésicule biliaire

Femme, 49 ans

Cholécystectomie-Anapath: adénocarcinome sur les zones de recoupe chirurgicale



# Tumeurs de la vésicule biliaire



# Plan

- Tumeurs de la vésicule biliaire
- **CCK IH**
- CCK hilaires
  - Diagnostic positif
  - Bilan d'extirpabilité
- Tumeurs du bas cholédoque

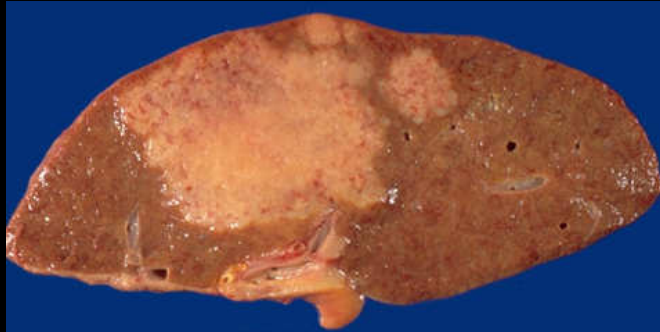## II. Cholangiocarcinomes intrahépatiques

- **Masse parenchymateuse intrahépatique (MF)**

- Masse contours réguliers
- Diagn. différentiels :
  - Lésion focale hépatique

**Fibrose**

**Temps tardifs**



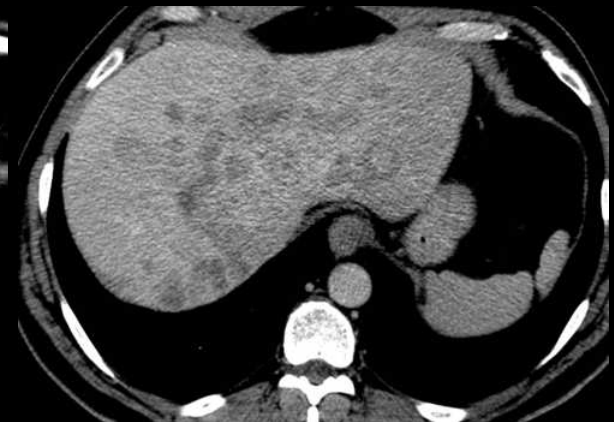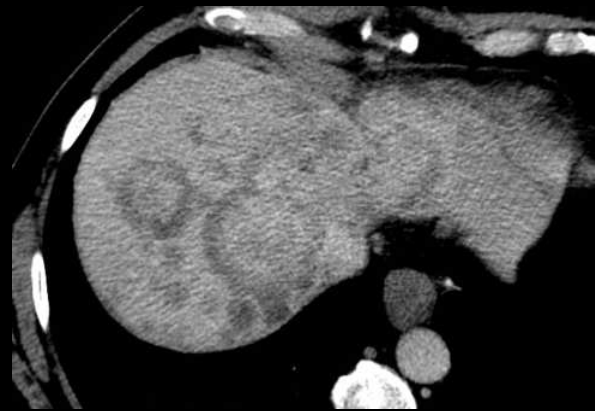
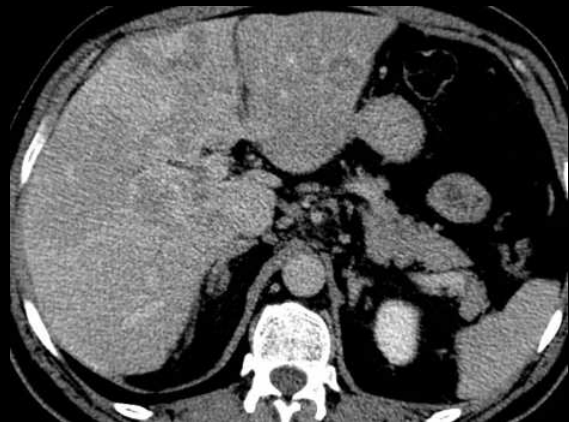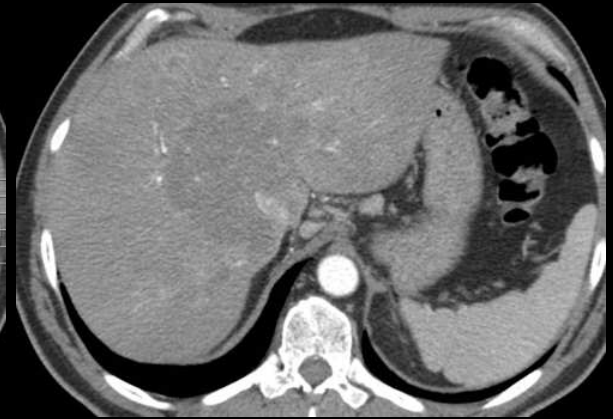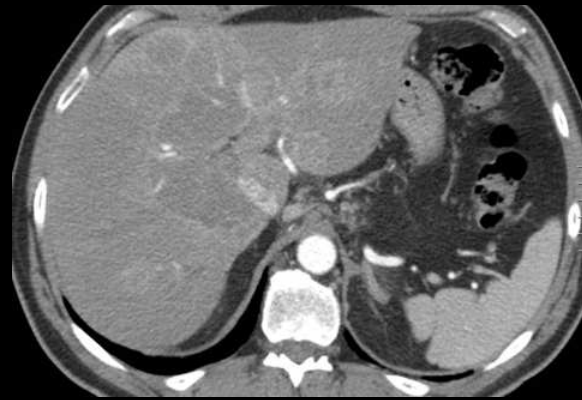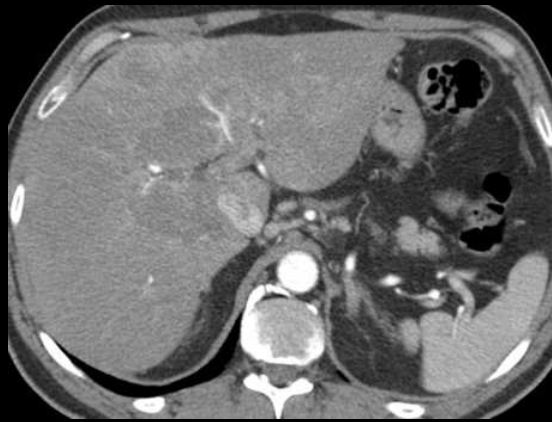### **Facteurs de risque**

- Cholangite sclérosante primitive
- Hépatites virales
- Maladies biliaires congénitales

- **Dilatation segmentaire des VBIH en amont obstacle**

- Diagn. différentiels :
  - Calculs
  - Métastase endobiliaire
  - CHC endobiliaire
  - CSP

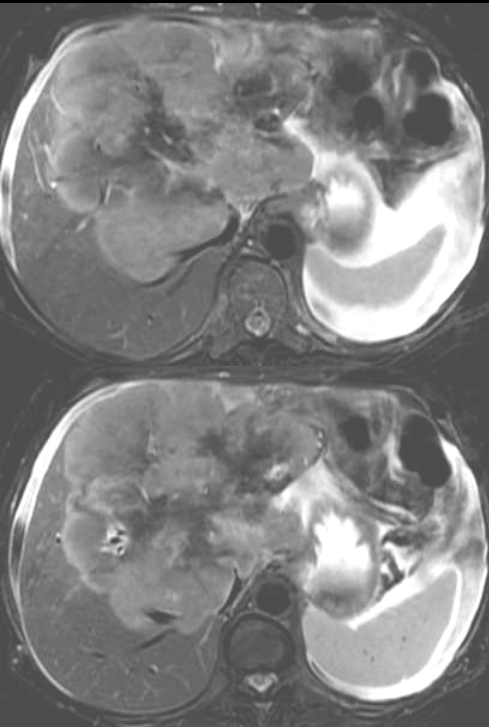
## II. Cholangiocarcinomes intrahépatiques



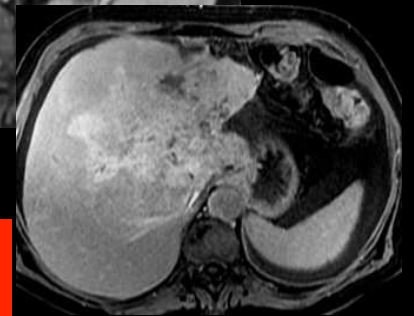
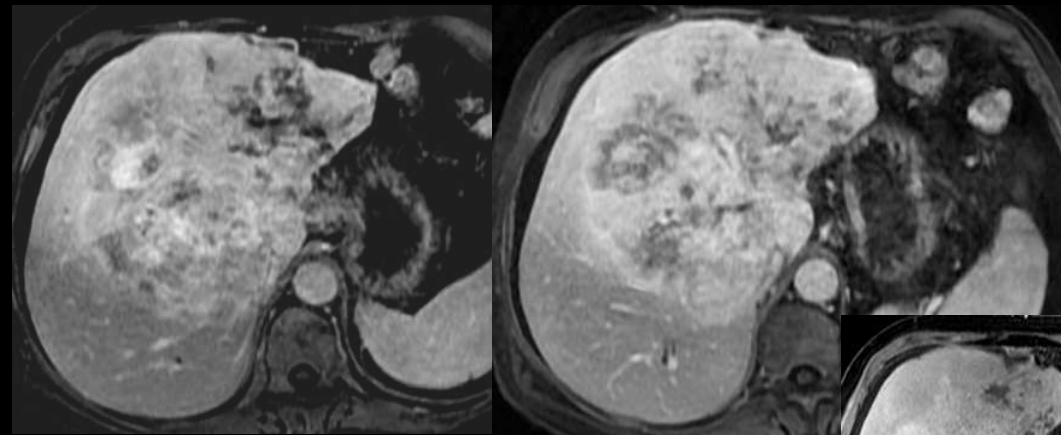
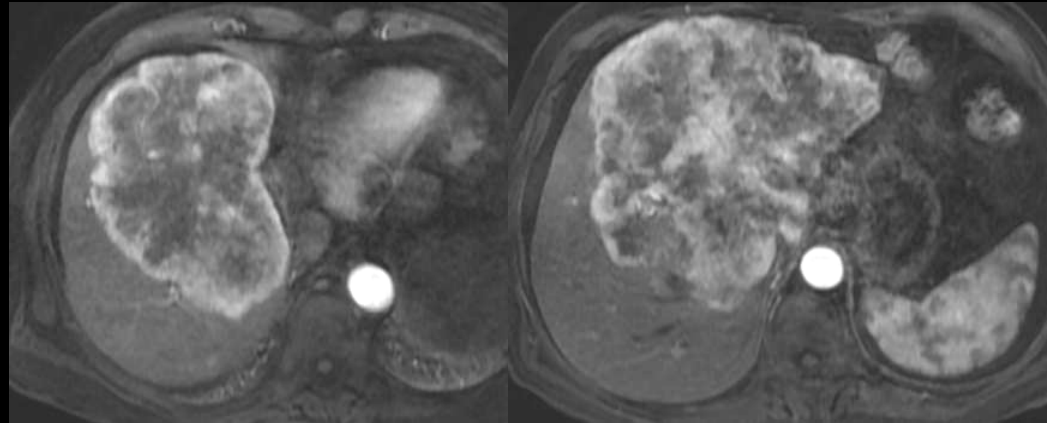
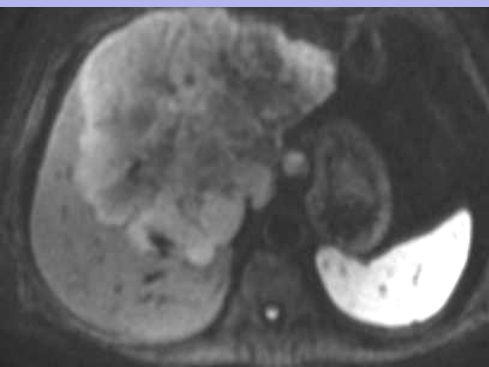
**Temps tardifs**

Maetani et al. AJR 2001  
Manfredi et al. Semin Liver Dis 2004  
Rimola et al. Hepatology 2009

## II. Cholangiocarcinomes intrahépatiques

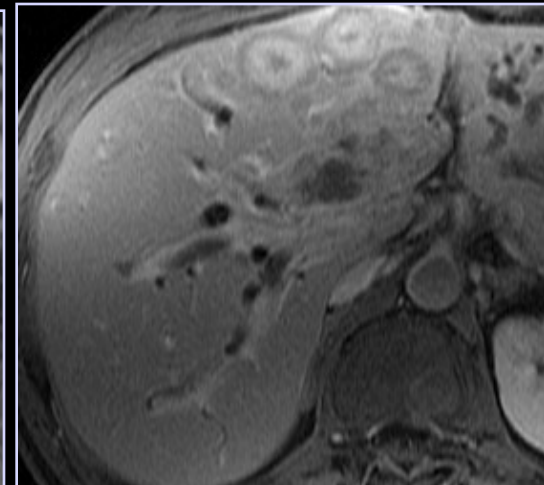
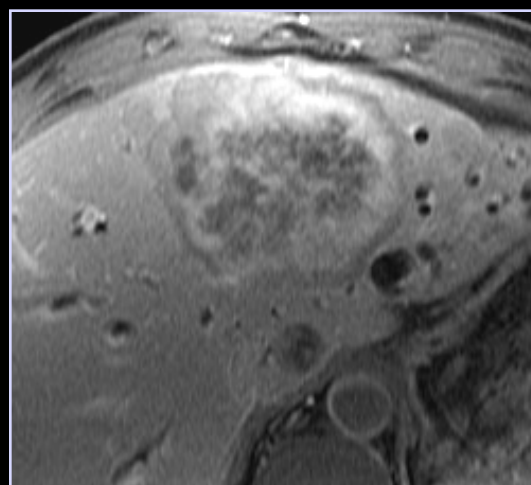
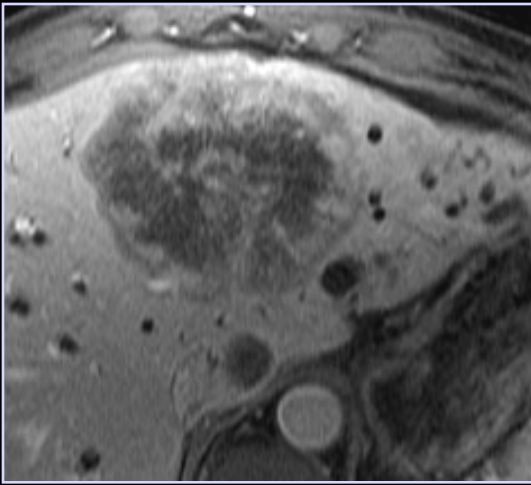
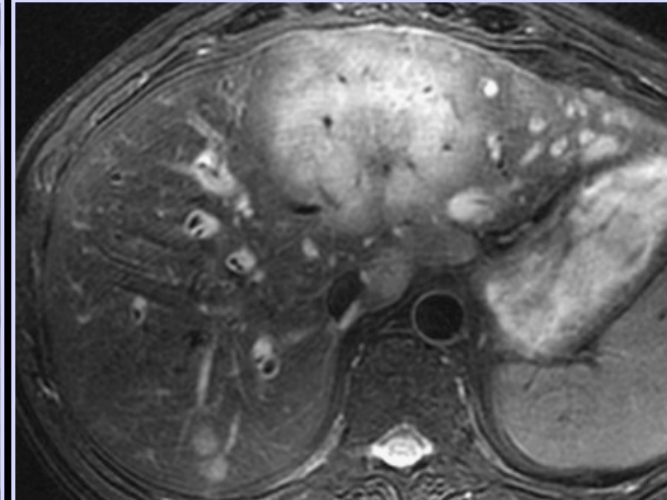
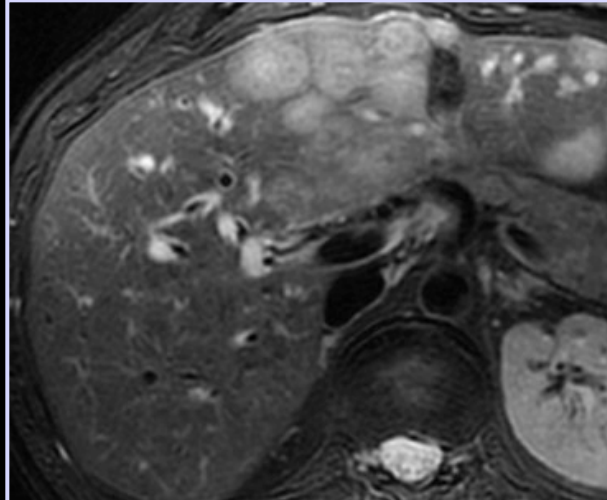
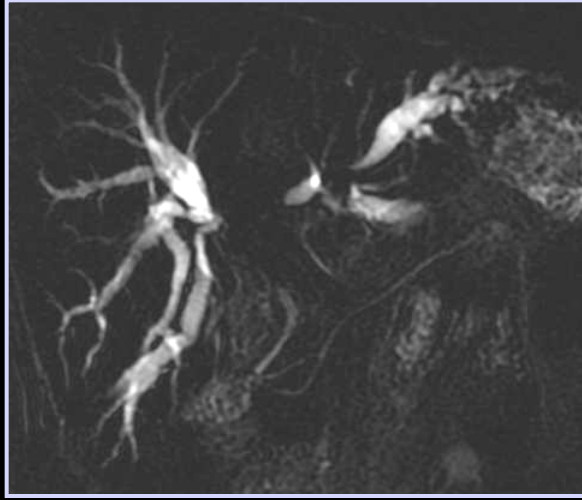


Diffusion



Temps tardifs

## II. Cholangiocarcinomes intrahépatiques

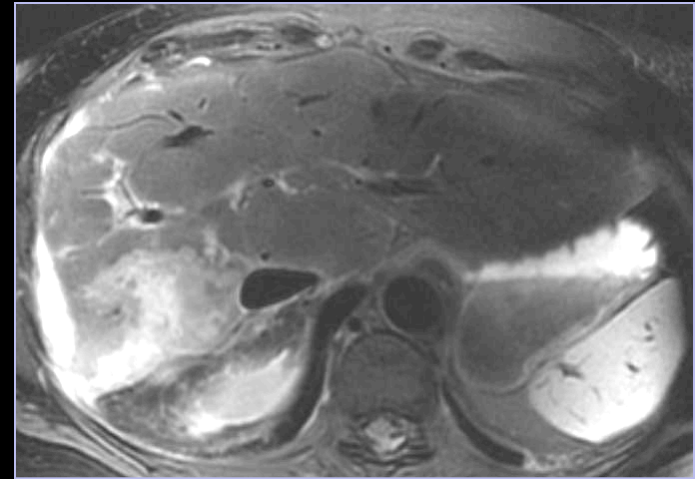
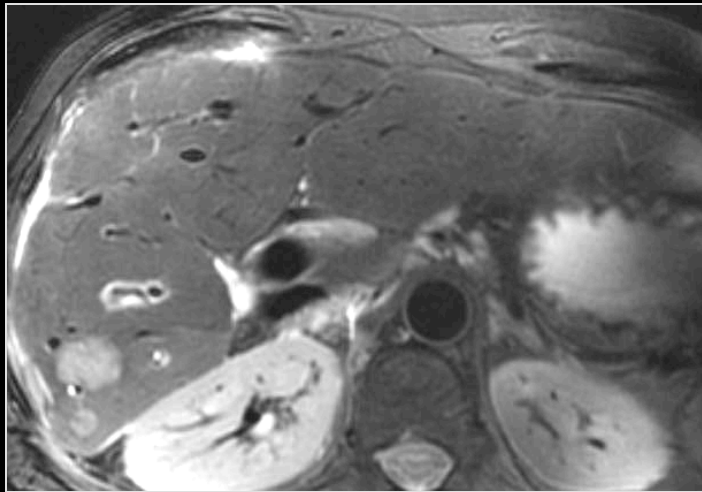


## II. Cholangiocarcinomes intrahépatiques

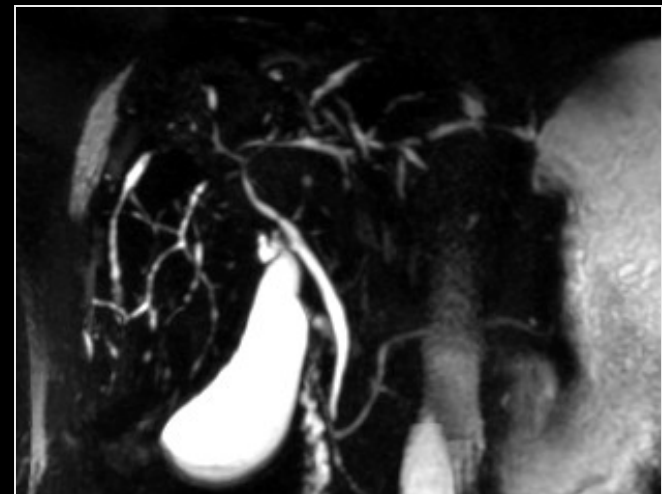
Femme, 52 ans

Perturbations mineures du bilan biologique hépatique depuis 10 ans

Découverte lésions focales hépatiques du foie droit



**Facteur de risque**  
-Cholangite sclérosante primitive



## II. Cholangiocarcinomes intrahépatiques

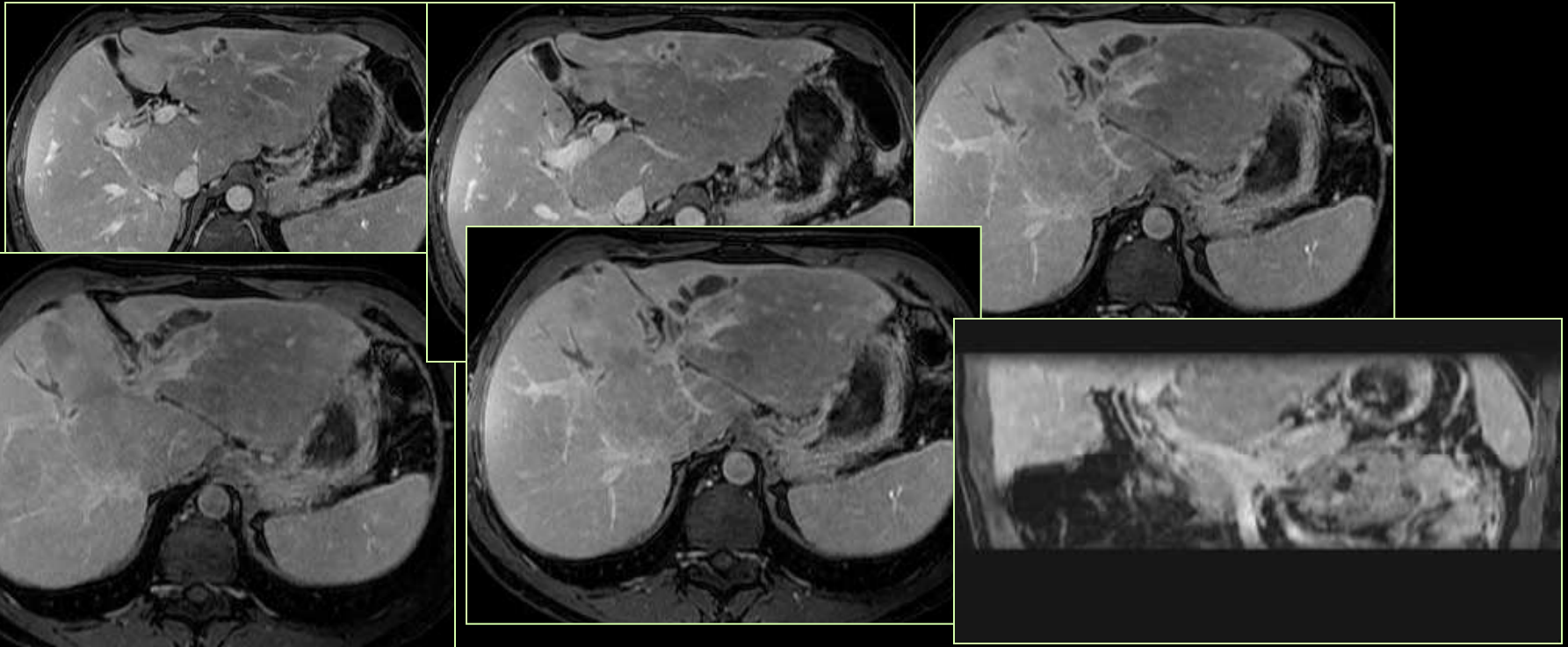
### Dilatation segmentaire des VBIH

– Diagn. différentiels :

Calculs

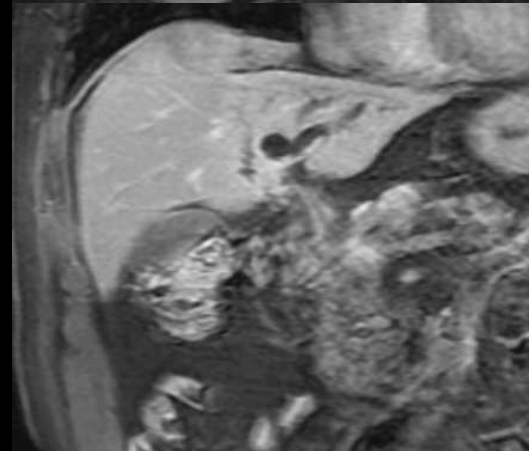
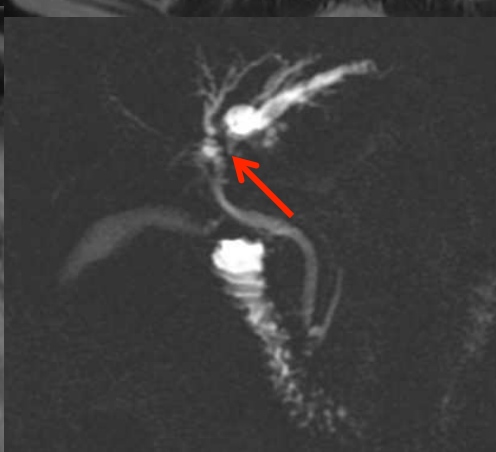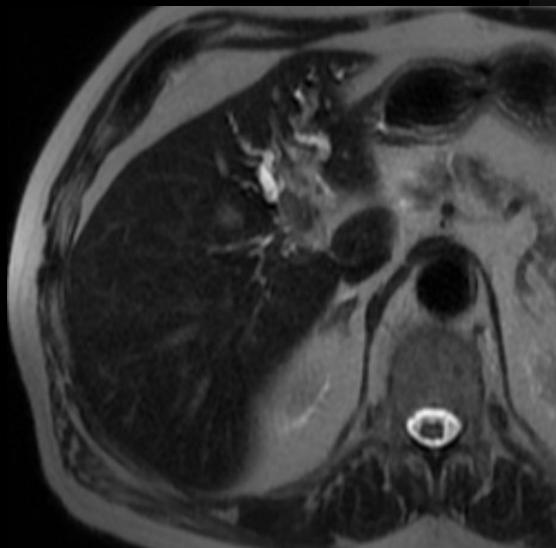
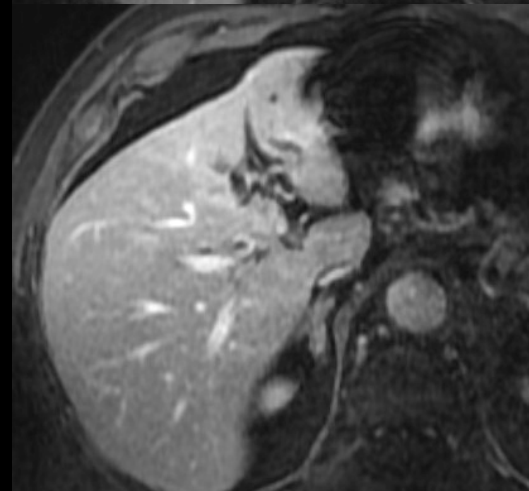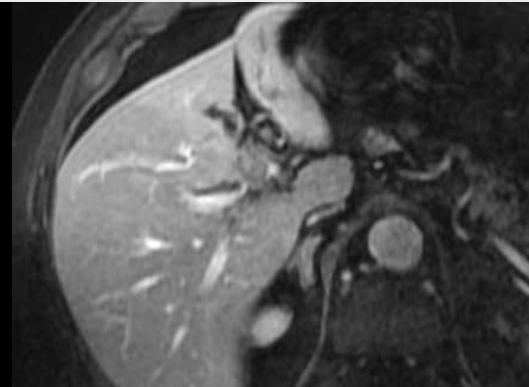
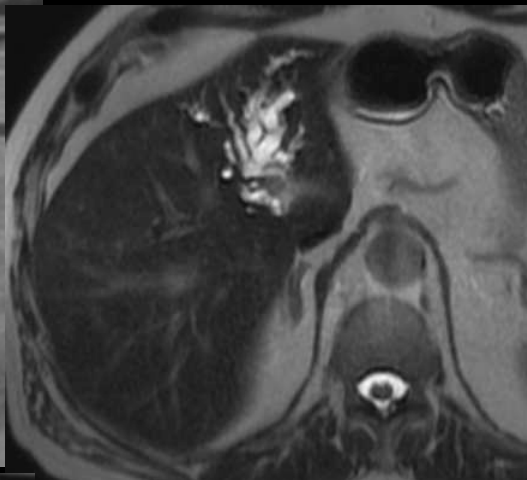
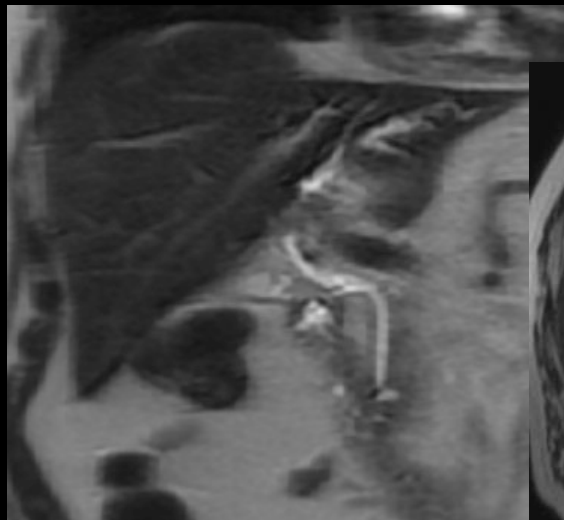
CHC à développement endobiliaire

Métastases à développement endobiliaire (cancers colo rectaux, sein)



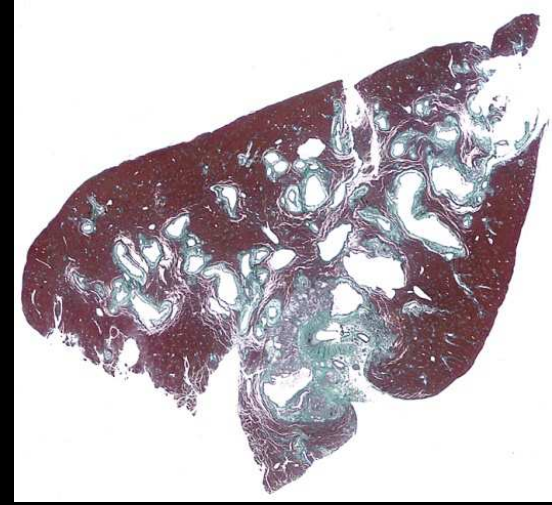
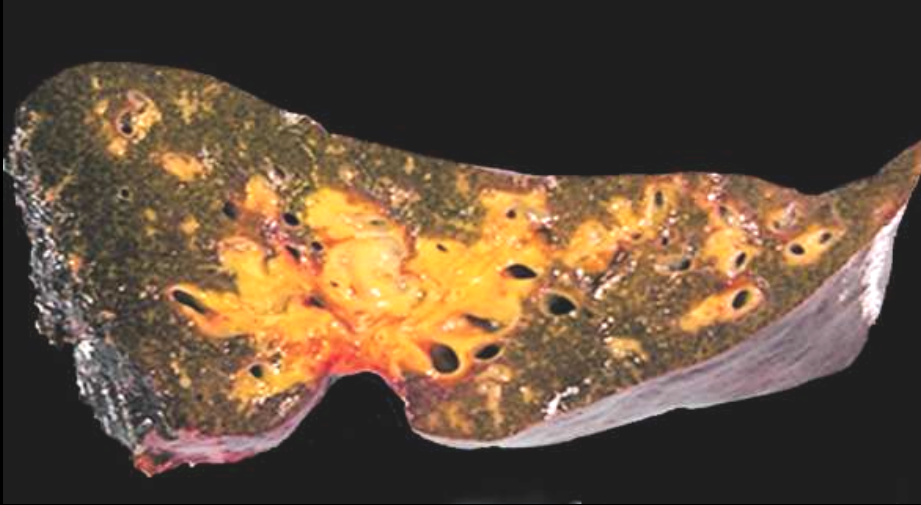
## II. Cholangiocarcinomes intra hépatiques

### Dilatation segmentaire des VBIH



Couple échographie  
IRM

# III. Cholangiocarcinomes hilaires



**Infiltration pariétale**  
**Prolifération endocanalaire**

**Diagn. différentiels :**

Obstacles de la convergence

**Particularités :**

- Extension longitudinale
- Extension circonférentielle

**Facteurs de risque**

- Cholangite sclérosante primitive

# Plan

- Tumeurs de la vésicule biliaire
- CCK IH
- **CCK hilaires**
  - Diagnostic positif
  - Bilan d'extirpabilité
- Tumeurs du bas cholédoque

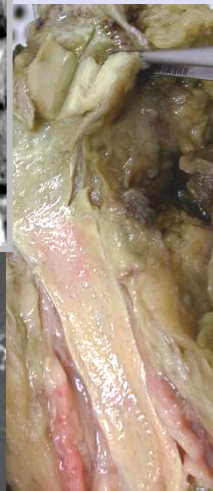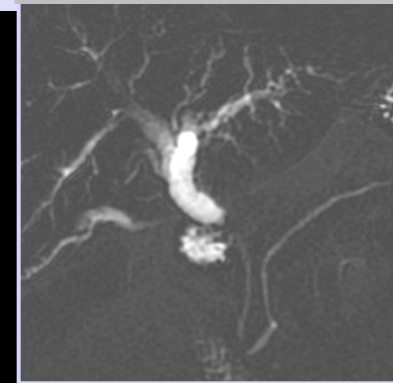
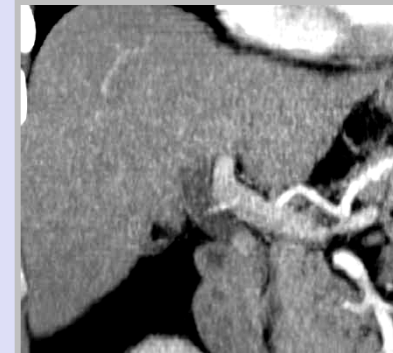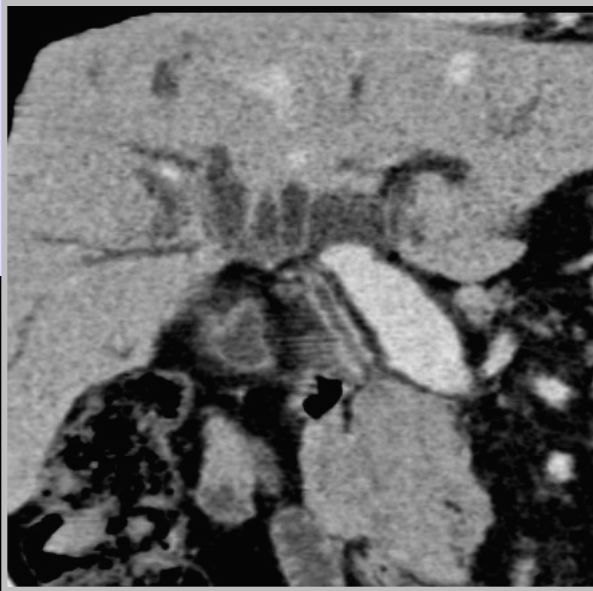# III. Cholangiocarcinomes hilaires

## Macroscopie

Infiltration canalaire  
(« Periductal infiltrating »)

Prolifération tumorale  
endocanalaire  
(« Intraductal growth »)

## Aspects en Imagerie



# III. Cholangiocarcinomes hilaires

Obstacles Hilaires :

Est-ce que c' est un cancer ???

Obstacles Hilaires :

Existe il une possibilité curative ???

Dans quelles conditions ???

# III. Cholangiocarcinomes hilaires

## Place de l'imagerie : Rôle majeur ++++

- Diagnostic positif:
  - Niveau lésionnel
  - Différentiel malin/bénin
  
- Evaluation de l'extirpabilité :
  - Biliaire
  - Vasculaire : artériel et veineux
  - Loco-régional parenchymateuse hépatique, organes de voisinage et à distance
  
- Place de la radiologie interventionnelle
  - Si chirurgie à visée curative : préparation à l'intervention
    - Volumétrie hépatique, évaluation du foie restant après intervention
    - Drainage biliaire
    - Embolisation portale
  - Si traitement palliatif
    - Drainage interne, externe
    - Type de stents, nombre de stents etc...

**Obstacle biliaire mécanique : échographie**



**Explorations radiologiques non invasives**

Scanner abdomino-pelvien

IRM : cholangio et séquences injectées

Nature  
de l'obstacle +++

Bilan  
d'extirpabilité



**Avis chirurgical ++++**

- Kim MJ et al. *Radiology* 2000, 214: 173-181.

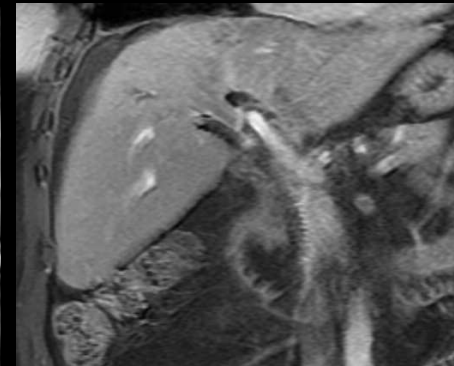
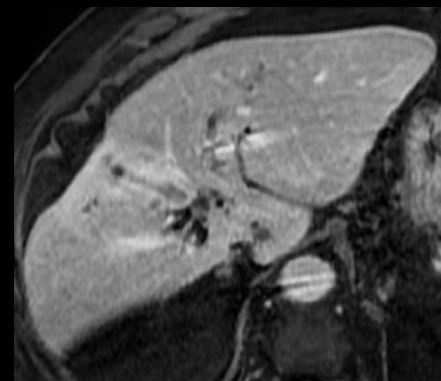
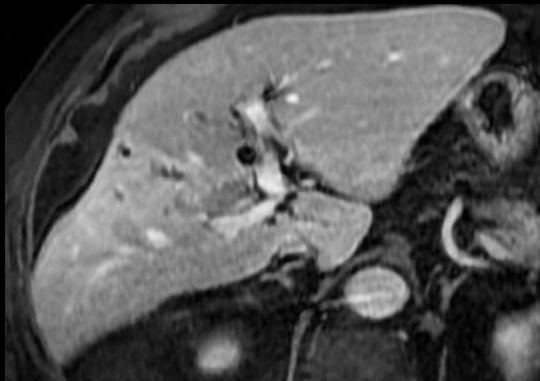
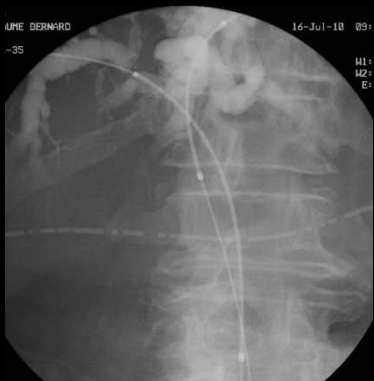# Explorations radiologiques non invasives

Scanner abdomino-pelvien

IRM : cholangio et séquences injectées

**Si** opacifications et prothèse mise en place avant tte exploration radiologique non invasive

- Pas d'analyse des voies biliaires sus jacentes à la sténose
- Pas de bilan d'extirpabilité adéquat pour juger de la résecabilité ou non, et donc du choix de la prothèse ....
- Csq en imagerie
  - Aspect inflammatoire marqué de l'ensemble de la VBP
  - Aérobilie
  - Pas d'analyse possible de la sémiologie de la sténose



Obstacles Hilaires :

Est-ce un cancer ???

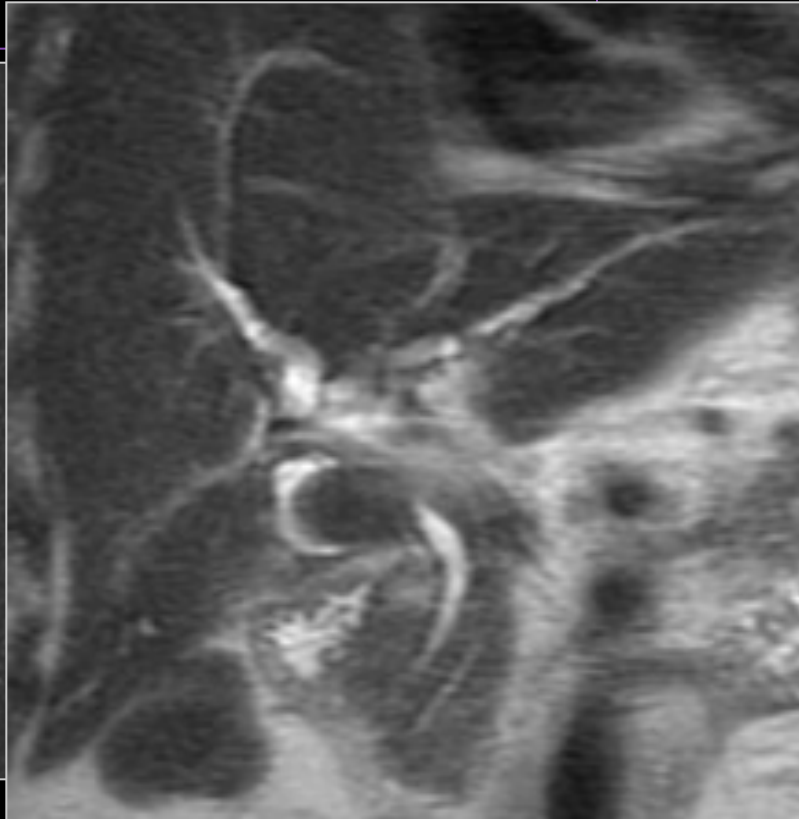
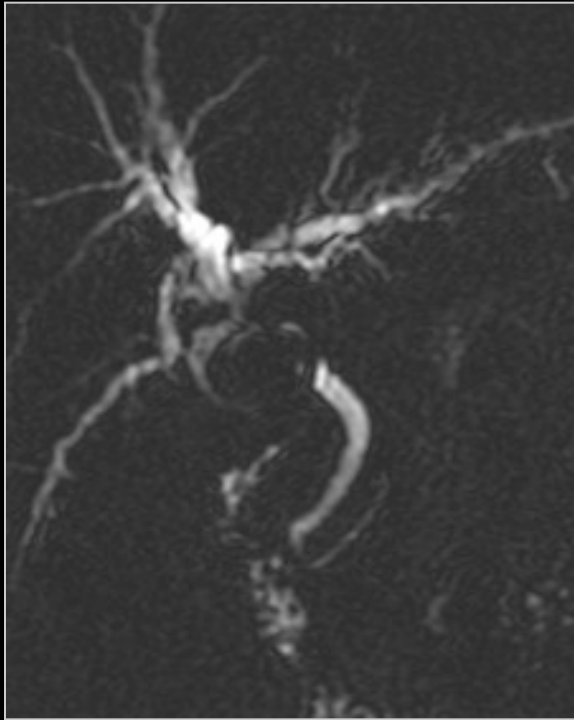
## Etiologies bénignes

Syndrome de Mirizzi

Calculs de la convergence

Cavernome pseudo tumoral

Faux kystes

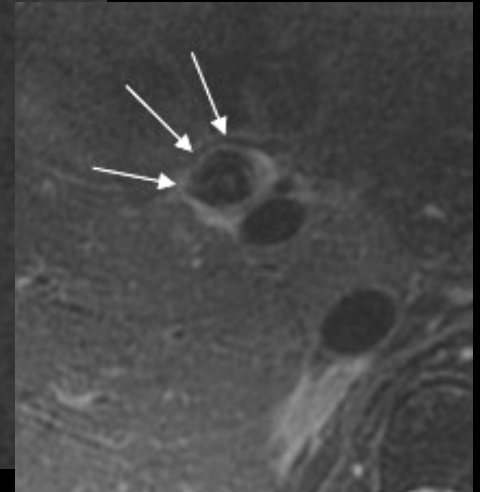
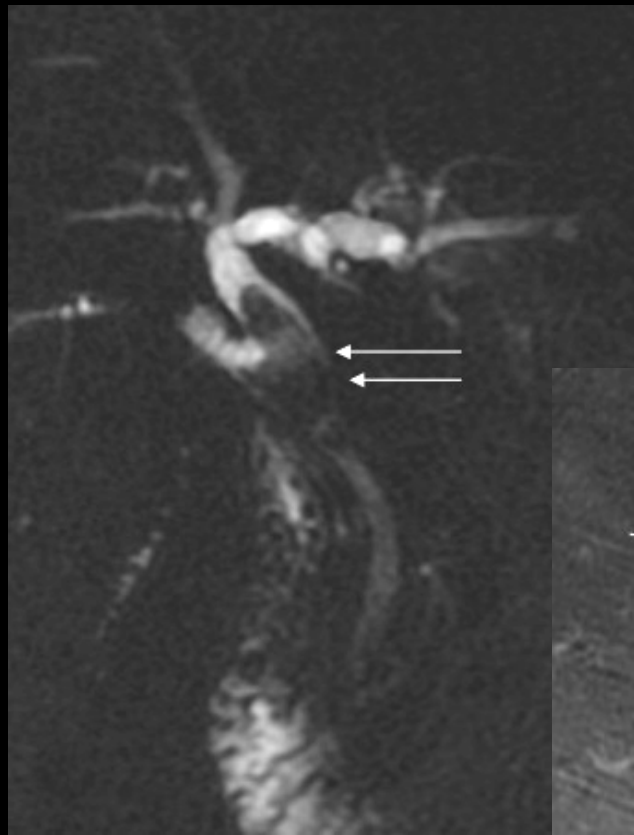
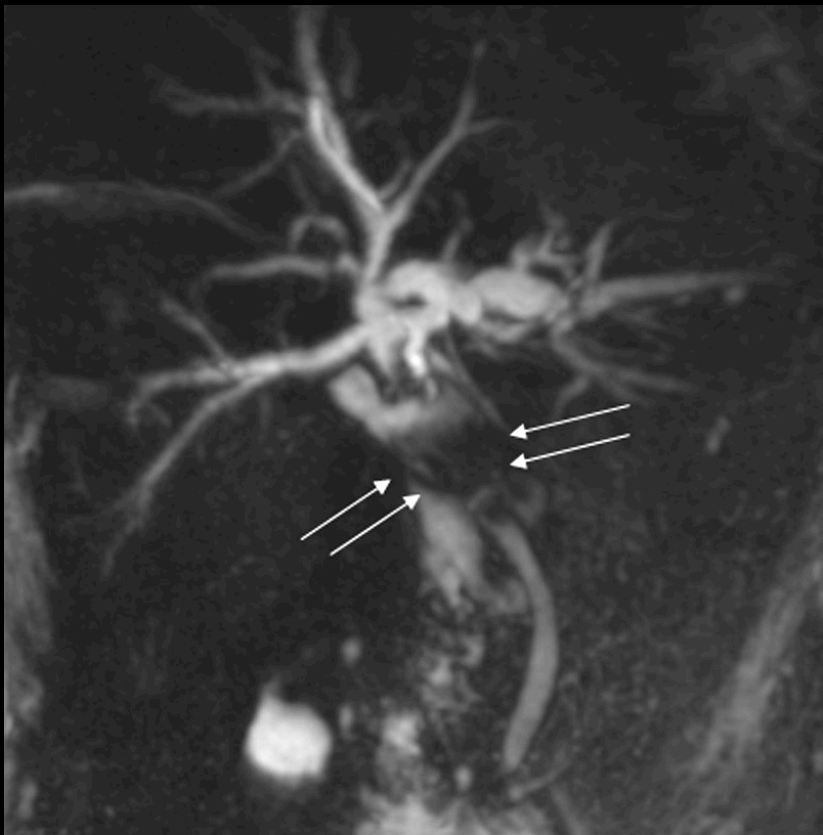


**Syndrome de Mirizzi**

# Obstacle hilaire : est ce un cancer ?

## Etiologies bénignes

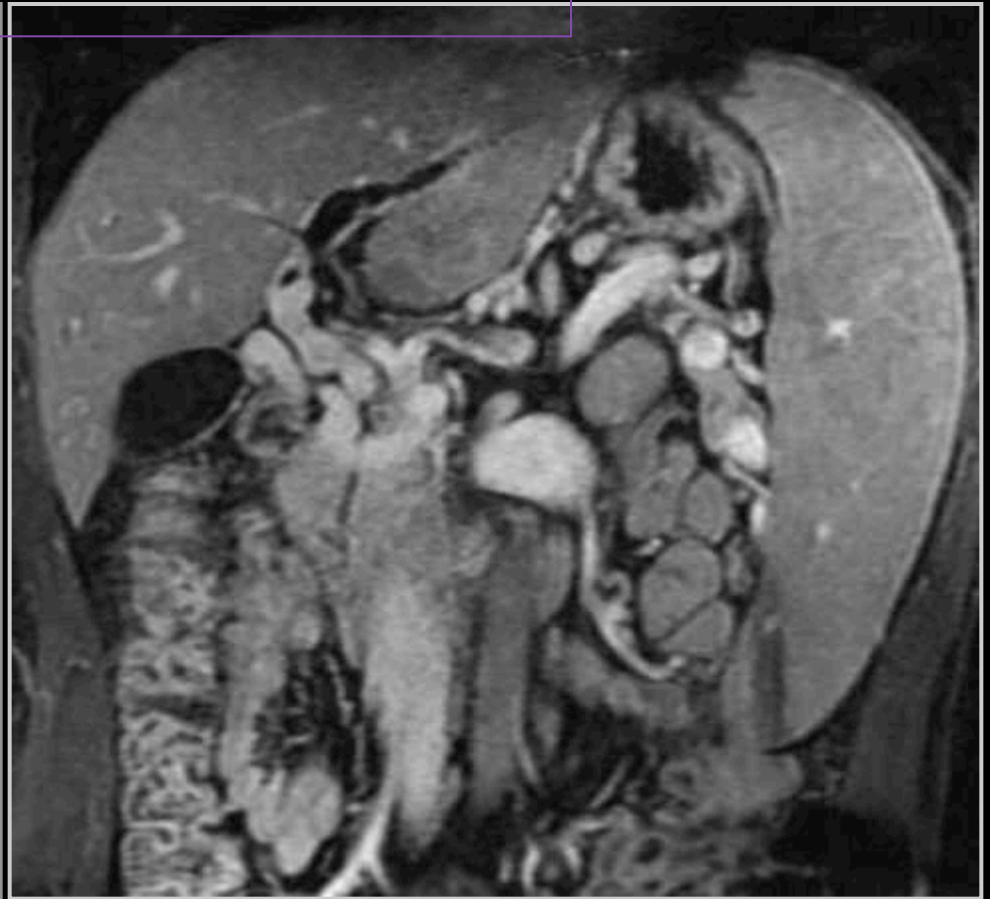
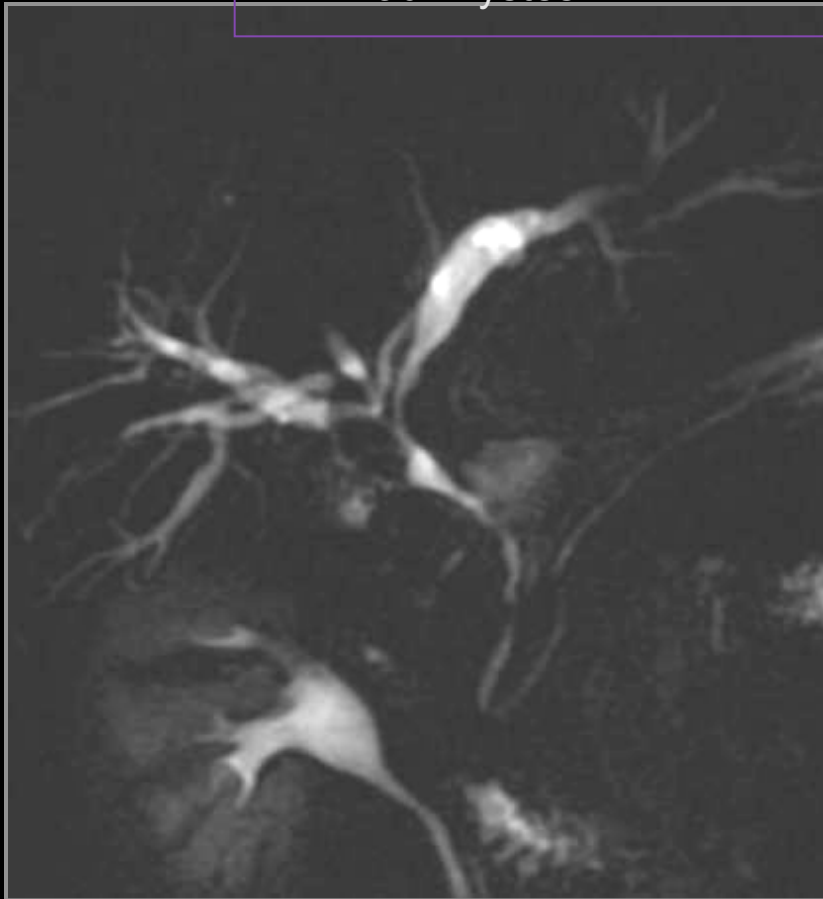
Syndrome de Mirizzi  
Calculs de la convergence  
Cavernome pseudo tumoral  
Faux kystes



# Obstacle hilaire : est ce un cancer ?

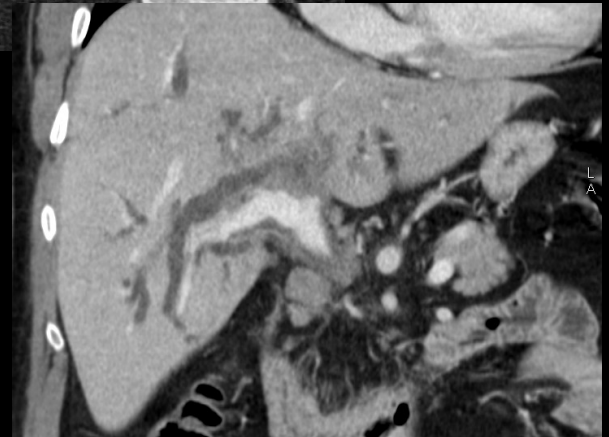
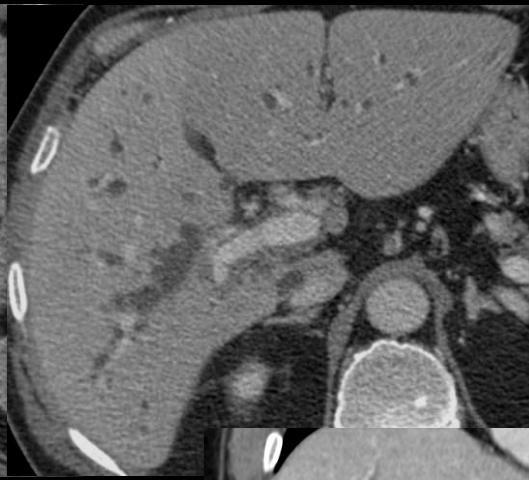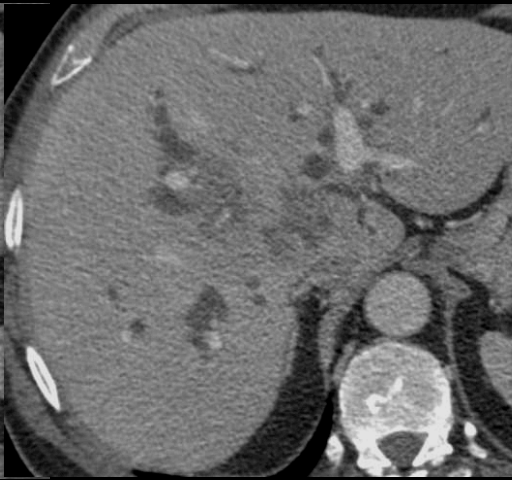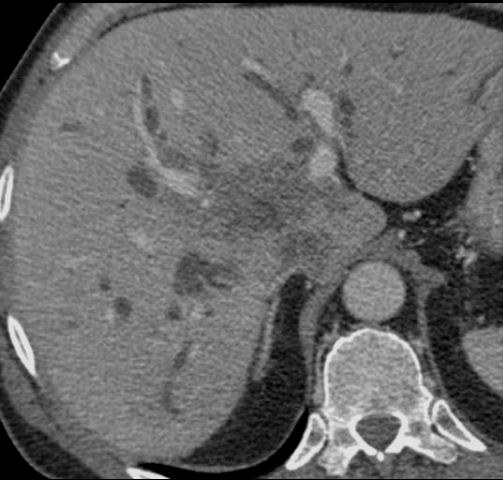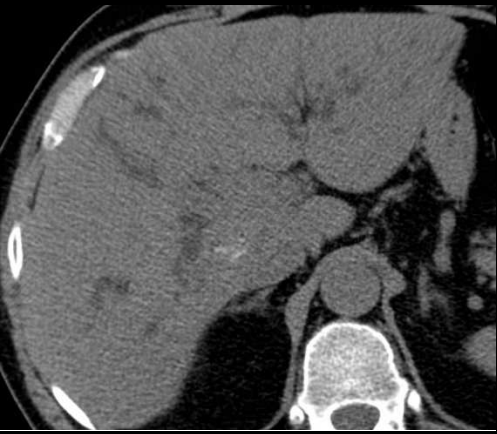
## Etiologies bénignes

Syndrome de Mirizzi  
Calculs de la convergence  
Cavernome pseudo tumoral  
Faux kystes



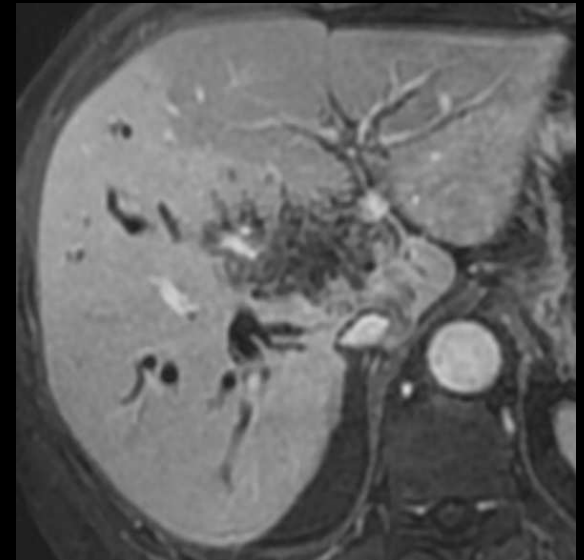
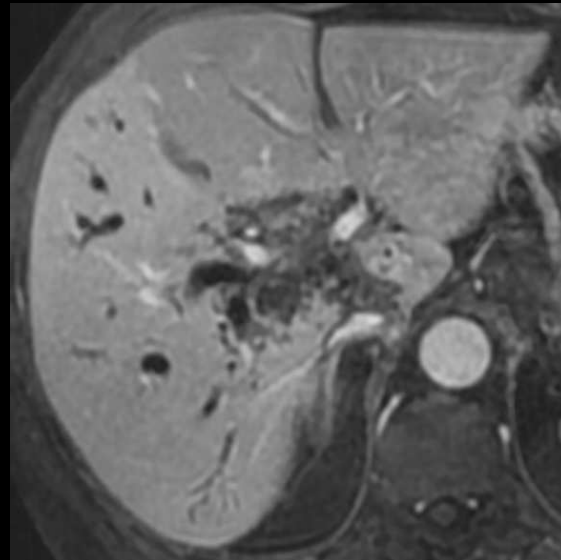
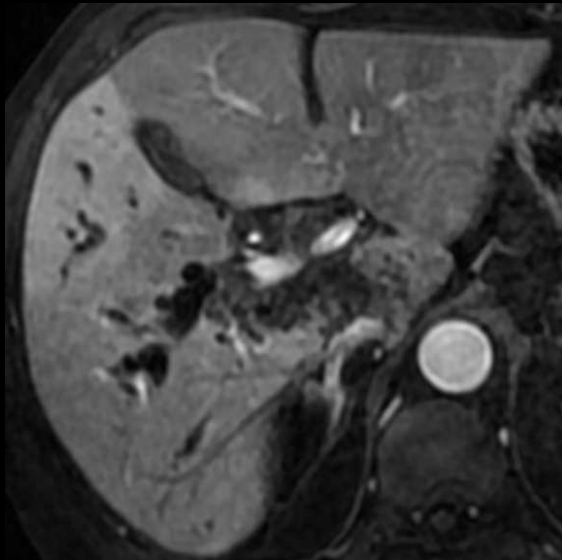
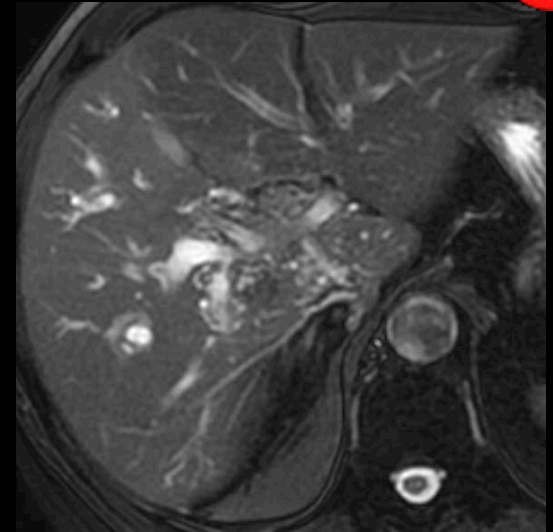
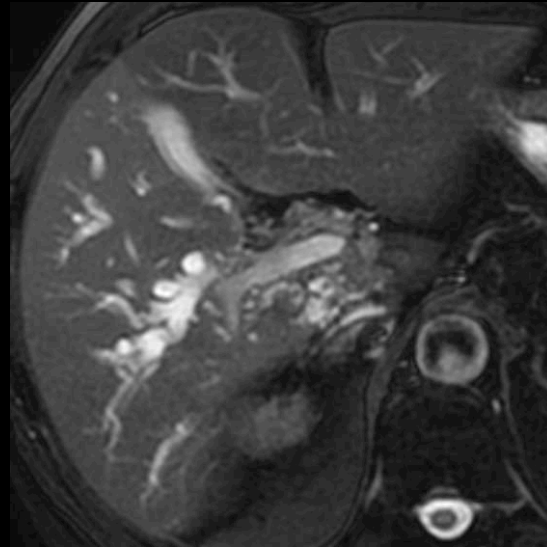
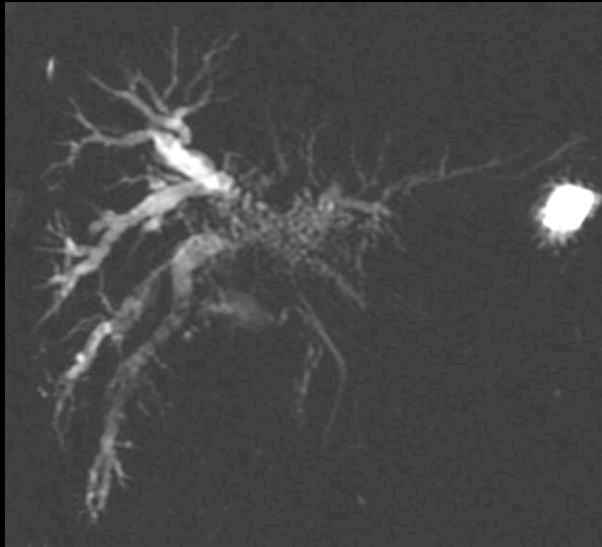**Cholangiopathie portale**

# Obstacle hilaire : est ce un cancer ?



**Patient ictère  
Vosgien**

# Obstacle hilaire : est ce un cancer ?

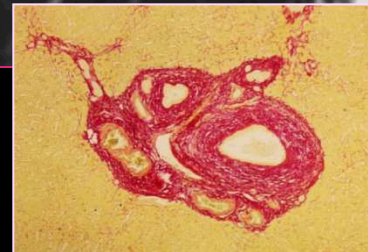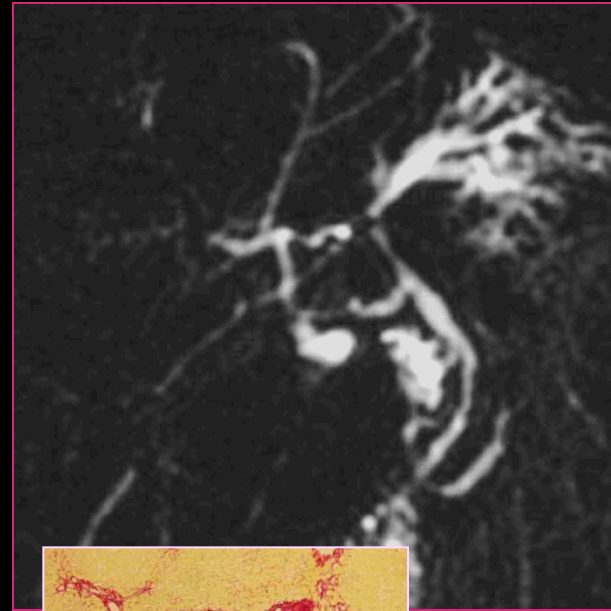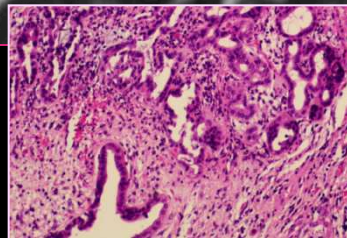
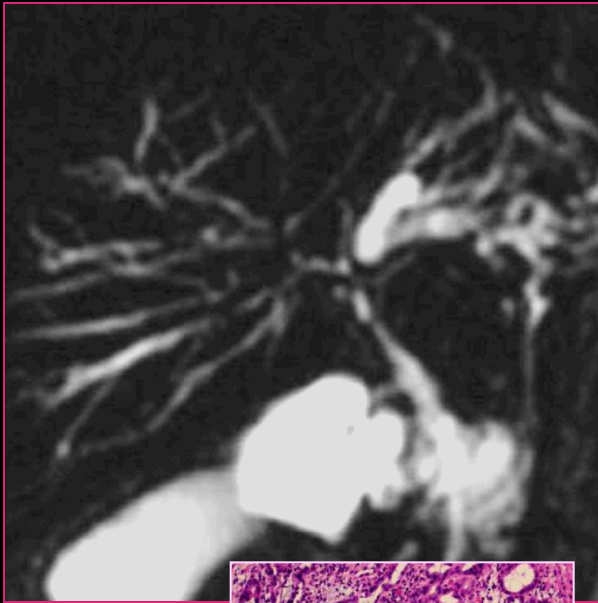


## Processus infiltrant pariétal

### Cholangite sclérosante primitive

Anomalies conjointes des VBIH  
RCH , pancréatite auto immune

Cholangite auto-immune



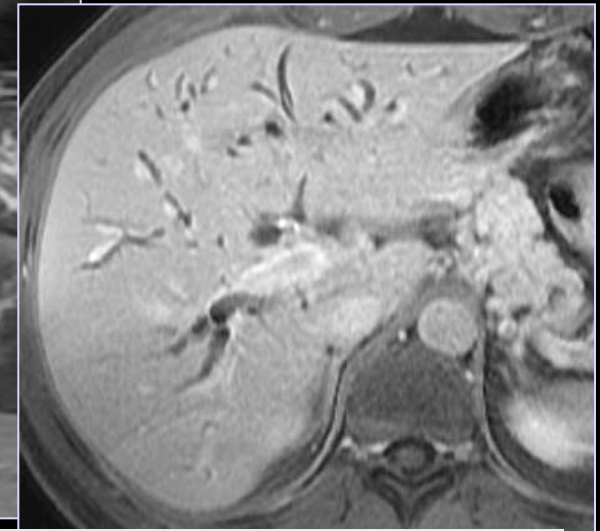
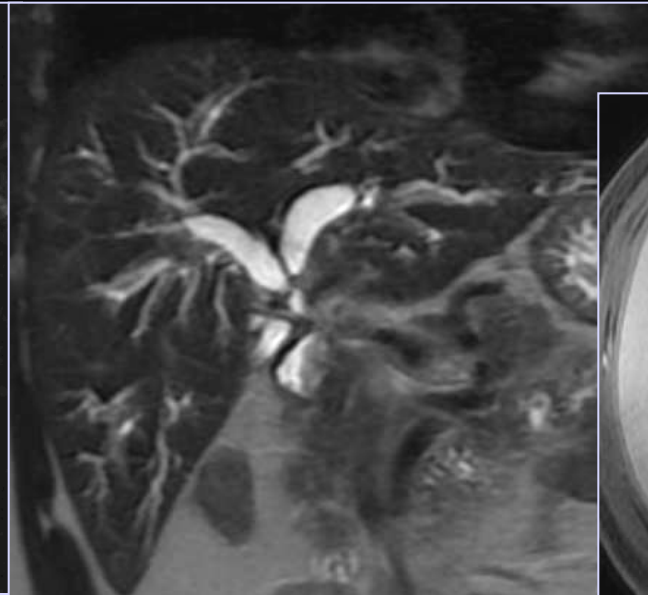
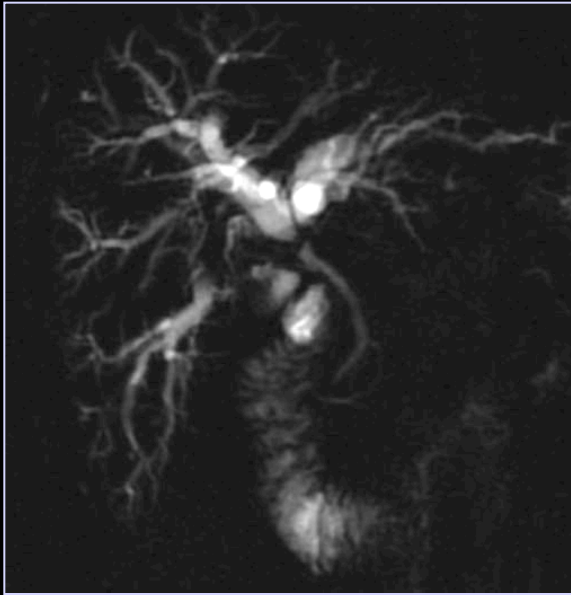## Processus infiltrant pariétal

### Cholangite sclérosante primitive

Anomalies conjointes des VBIH  
RCH , pancréatite auto immune

### Cholangite auto-immune

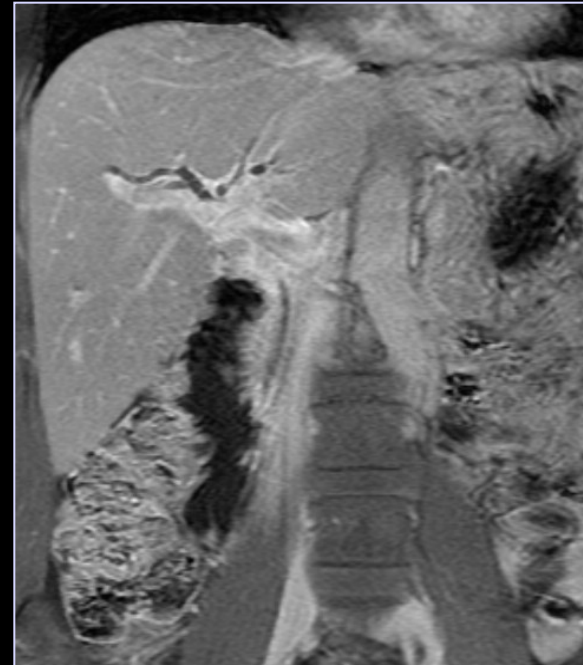
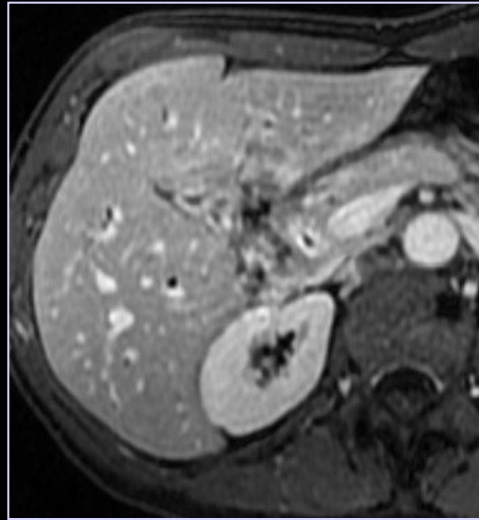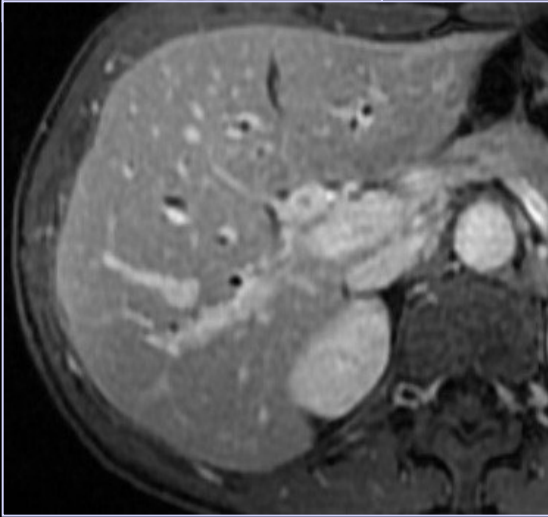
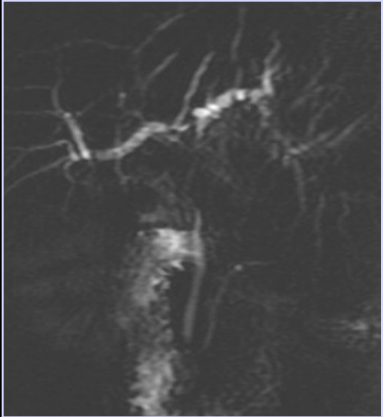
Koea et al. World J Surg 2004  
Rosch et al. Gastrointest Endosc  
2002  
Gerhards et al. Br J Sur 2001



**14% des obstacles hilaires considérés comme des CCK périhilaires sont des cholangites**

# Obstacle hilaire : est ce un cancer ?

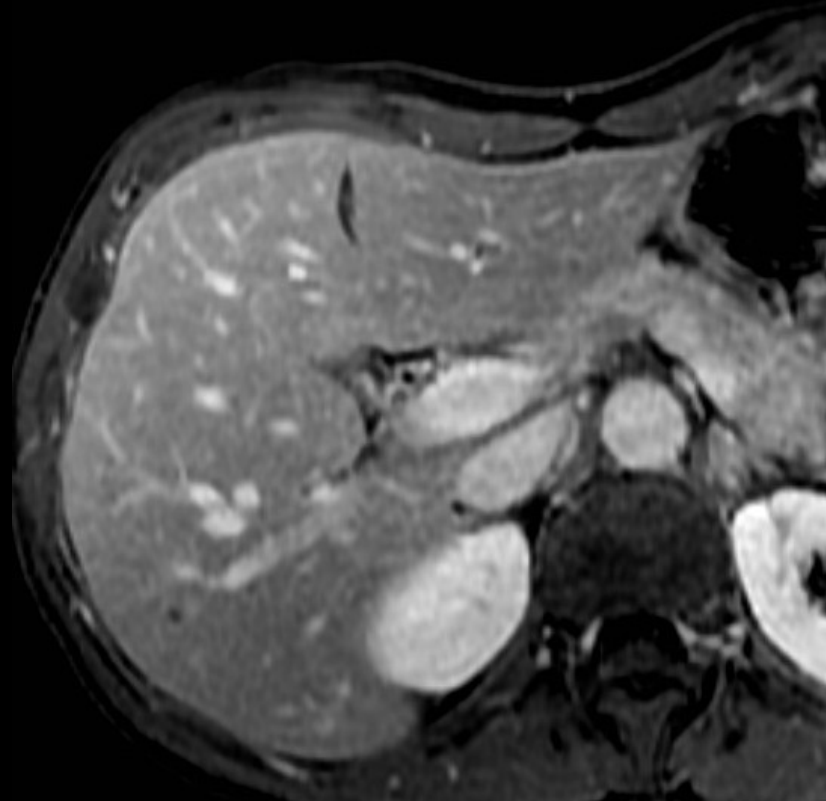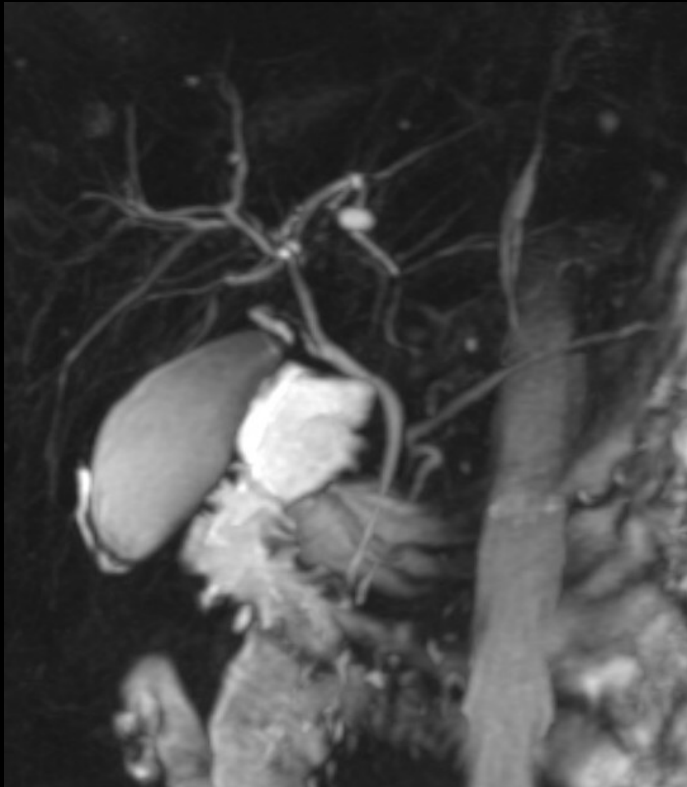## Processus infiltrant pariétal



Koea et al. World J Surg 2004  
Rosch et al. Gastrointest Endosc 2002  
Gerhards et al. Br J Sur 2001

# Obstacle hilaire : est ce un cancer ?

## Processus infiltrant pariétal



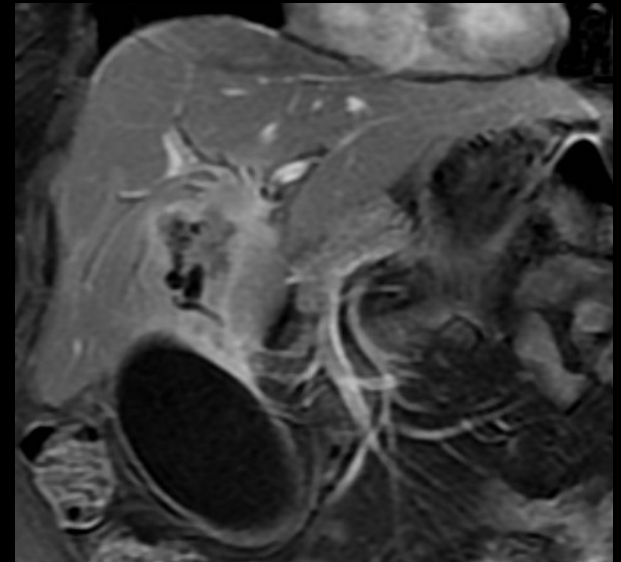
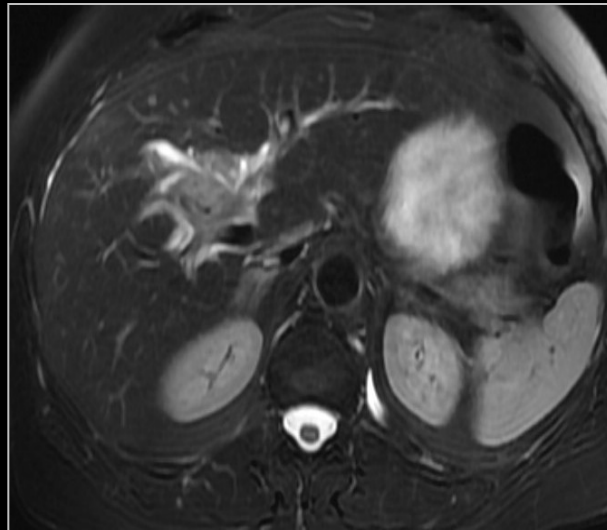
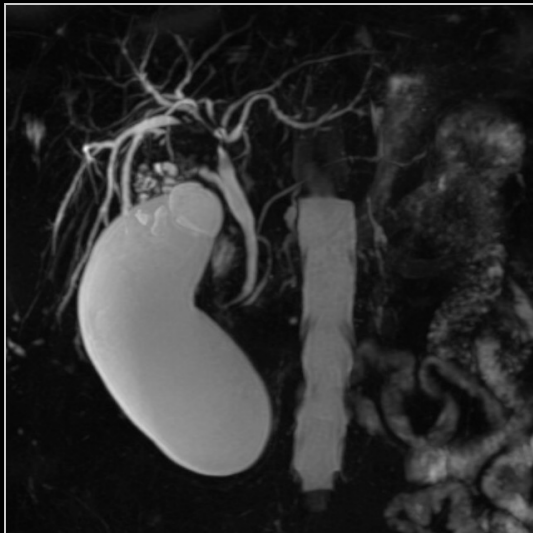
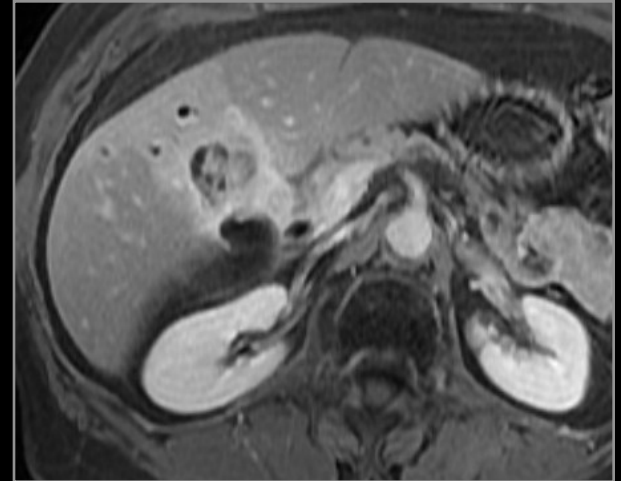
## Processus infiltrant pariétal

- Knoefel WT et al. *Eur Surg Oncol* 2003; 29 : 658-61
  - 33 patients
  - Echo, CT, ERCP, angiography
  - 27 lésions malignes / 6 patients porteurs d'une cholangite fibrosante
- Uhlmann D et al. *J Gastrointest Surg* 2006; 10 : 1144-50
  - 49 patients / diagnostic radiologique de tumeur de Klatskin
  - **14% (7) : pathologie bénigne.**
  - 6 considérés comme malins à la laparotomie
  - Anapath : cholangite sévère avec une fibrose extensive périductale

# Obstacle hilaire : est ce un cancer d'une autre origine ?

Malins

- ADK pancréas
- ADK sillon
- ADK vésiculaire étendu au hile
- Carcinomatose péritonéale
- ADP métastatiques



# Obstacle hilaire : est ce un cancer d'une autre origine ?

Malins

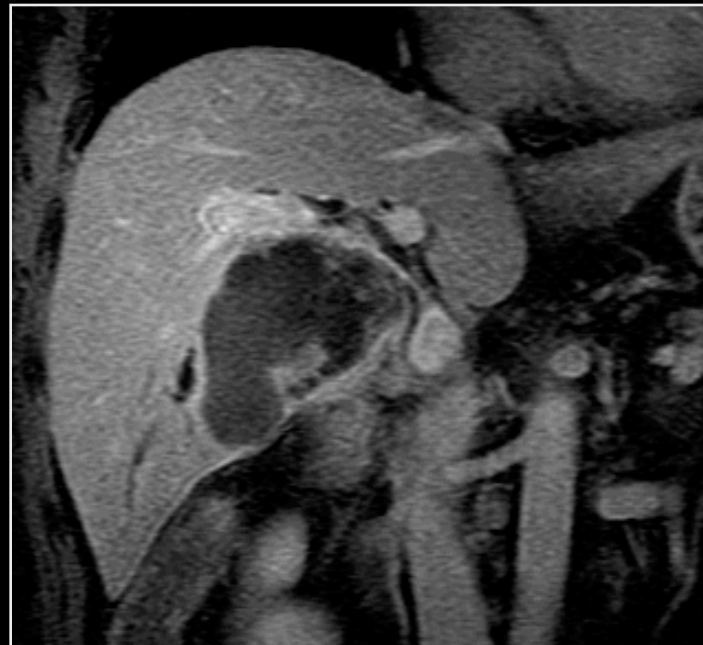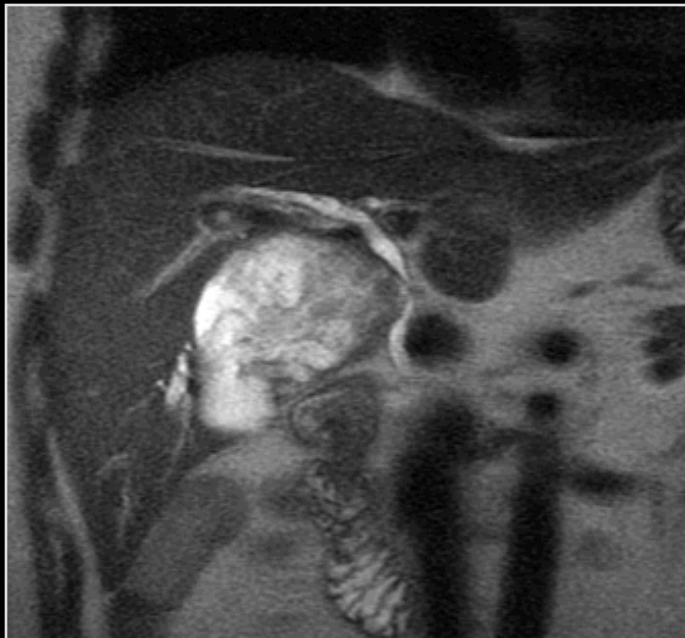
ADK pancréas

ADK sillon

ADK vésiculaire étendu au hile

Carcinomatose péritonéale

**ADP métastatiques**



# Obstacle hilaire : est ce un cancer d'une autre origine ?

Malins

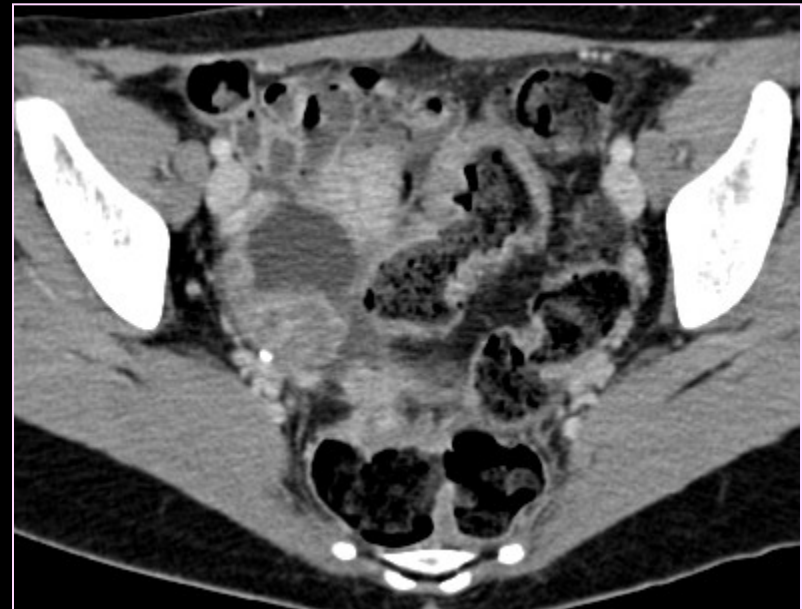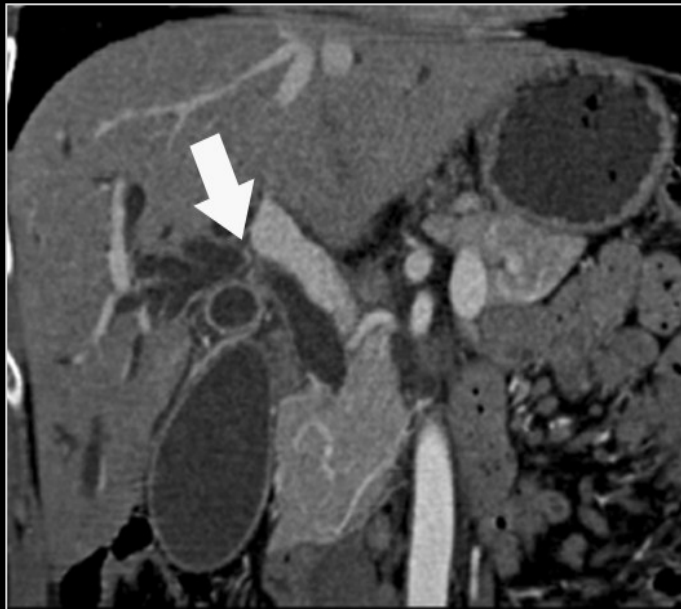ADK pancréas

ADK sillon

ADK vésiculaire étendu au hile

**Carcinomatose péritonéale**

ADP métastatiques



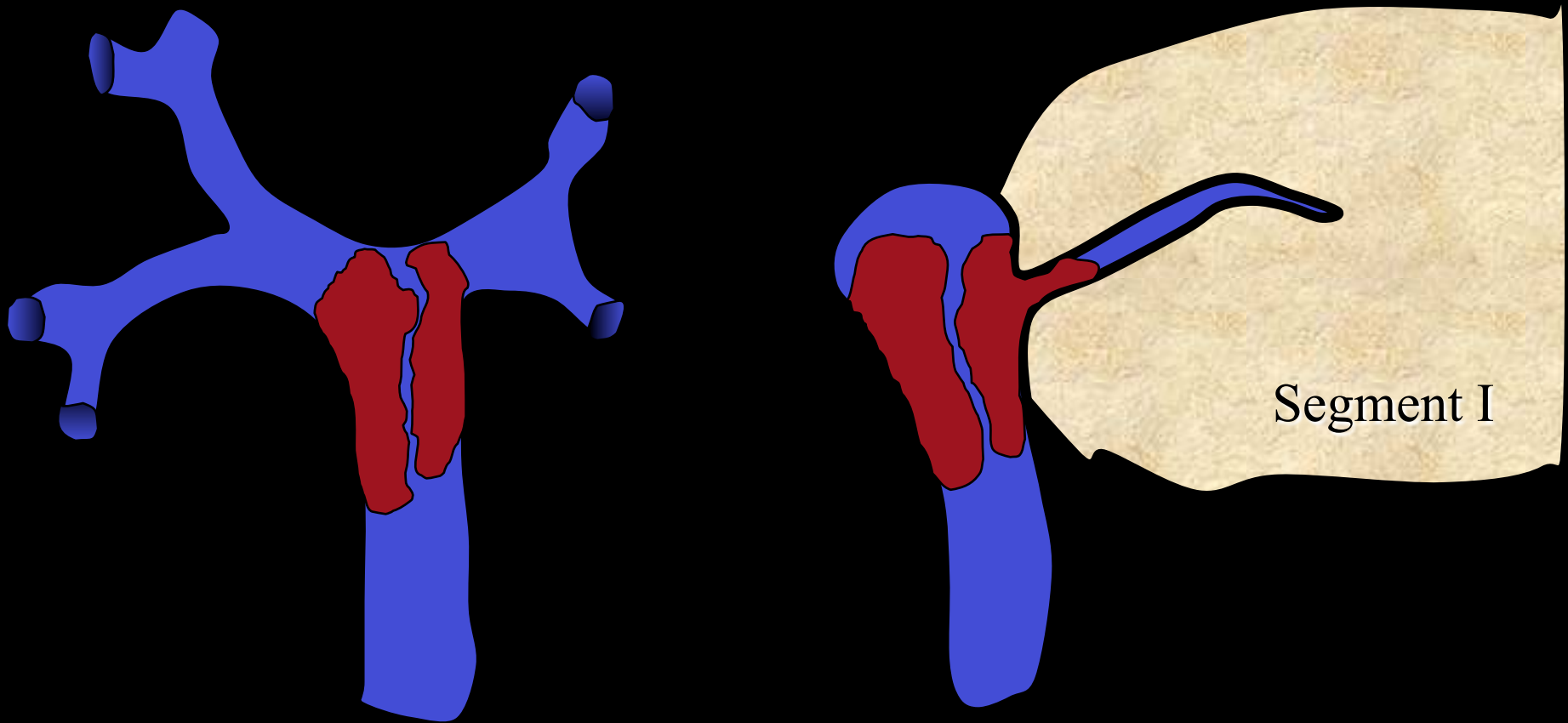
Obstacles Hilaires, c' est un cholangiocarcinome :  
Existe il une possibilité curative ???

Dans quelles conditions ???

### Critères d'irrésécabilité chirurgicale

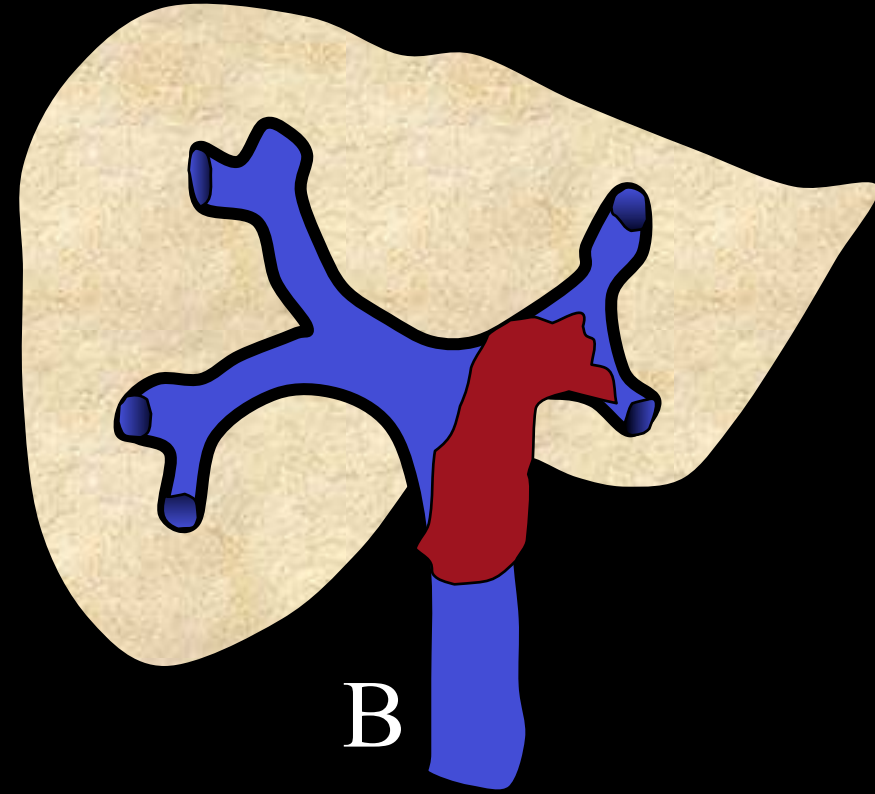
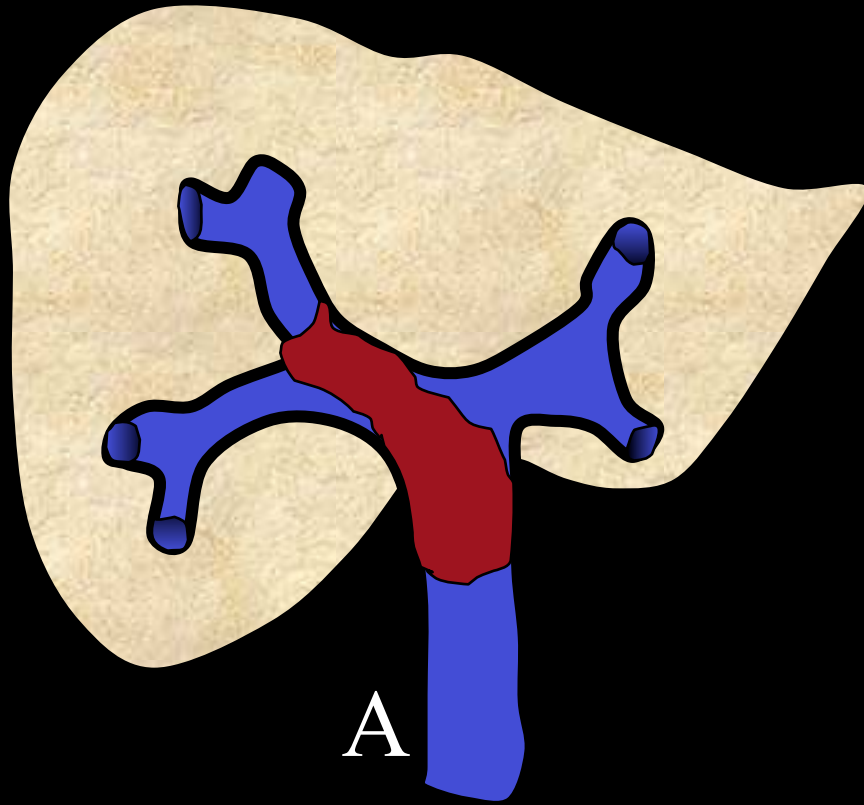
- Volumineuse masse hilaire
- Critères biliaires
  - Pôle supérieur atteignant les convergences secondaires de façon bilatérale
- Critères vasculaires
  - Atteinte des trois veines sus hépatiques
  - Atteinte artérielle bilatérale
  - Atteinte vasculaire unilatérale associée à une atrophie controlatérale
- Critères parenchymateux hépatiques
- Extension extra hépatique

**Une seule vraie question:  
La convergence est-elle atteinte ?**



**Type II: la convergence est atteinte. Le segment I doit être enlevé**

**La convergence est-elle atteinte ?  
Si oui: reste-il un canal dérivable ?**



**Type III** : Extension dans 1 seul des deux canaux hépatiques.

Droit (III A) ou gauche (IIIB)

Une hépatectomie homolatérale à l'atteinte, élargie au I, est nécessaire

## Extension biliaire

### Classification de Bismuth et Corlette

#### Cholangiogramme :

coupes épaisses 20 mm

#### Limites :

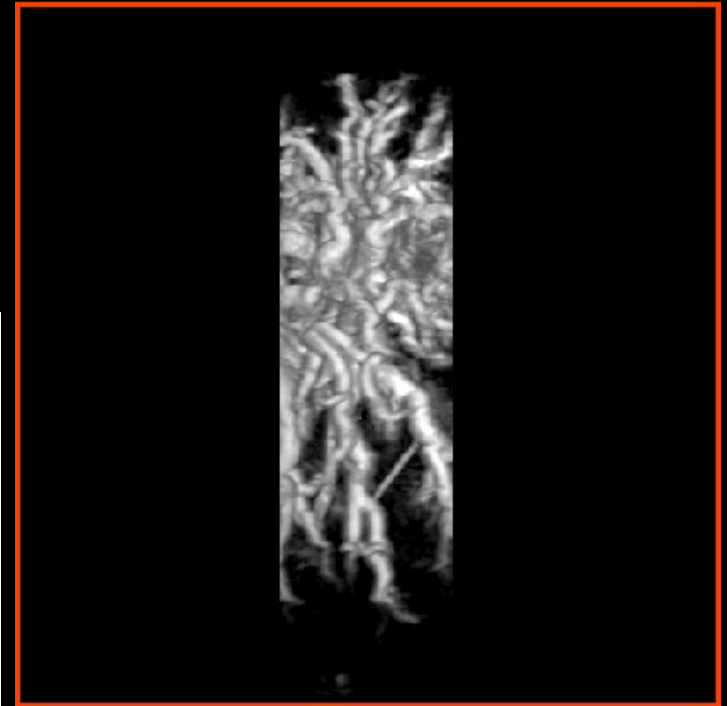
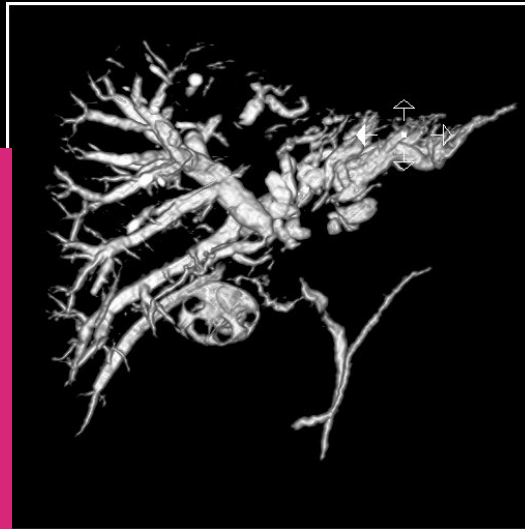- superpositions ++
- Pas de coupes fines
- Difficulté d'analyse de la zone pathologique



#### Cholangiogramme en 3D

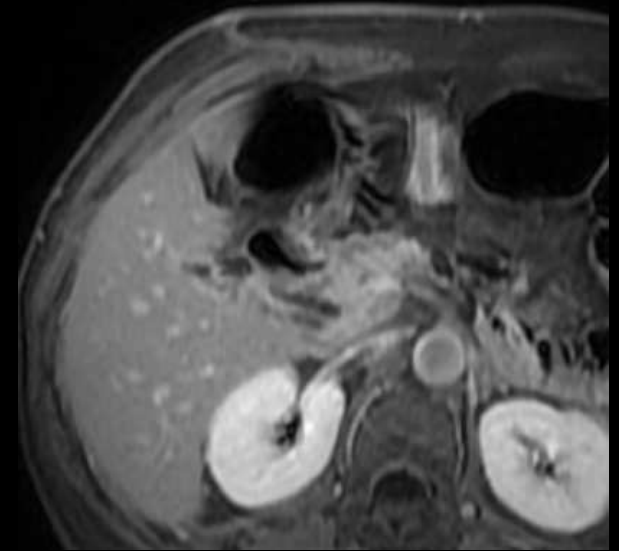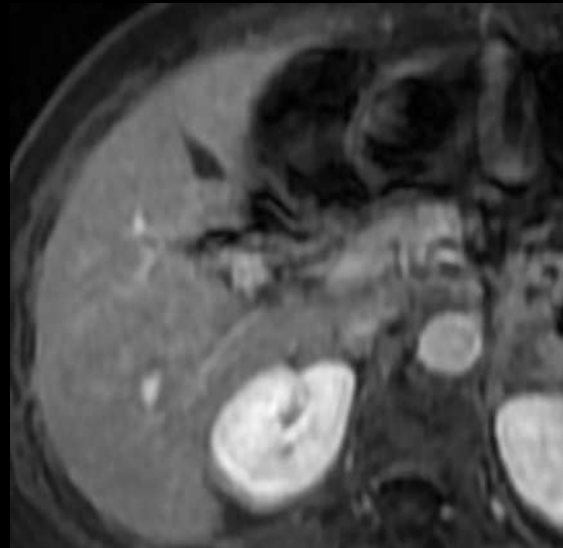
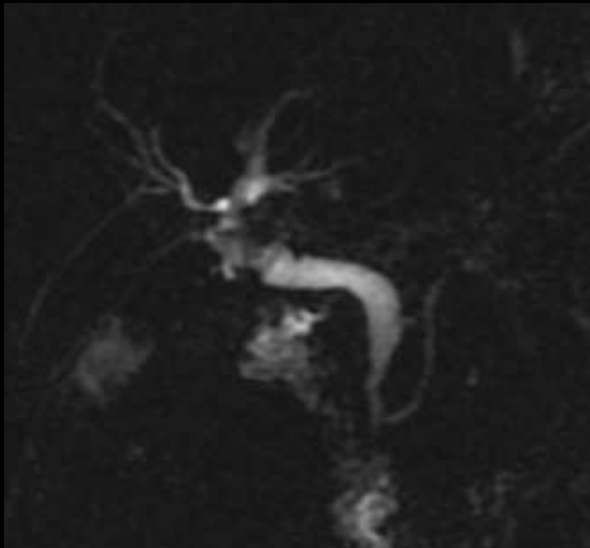
#### Intérêts :

- Pas de superpositions ++
- Coupes fines ++++
- Reformations multiplanaires sur la zone intéressante



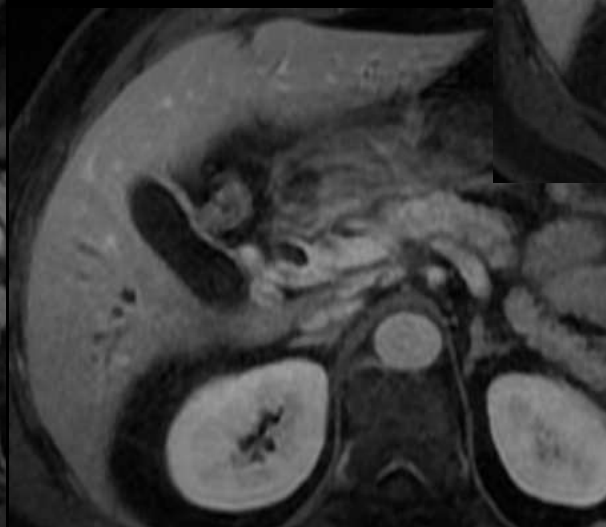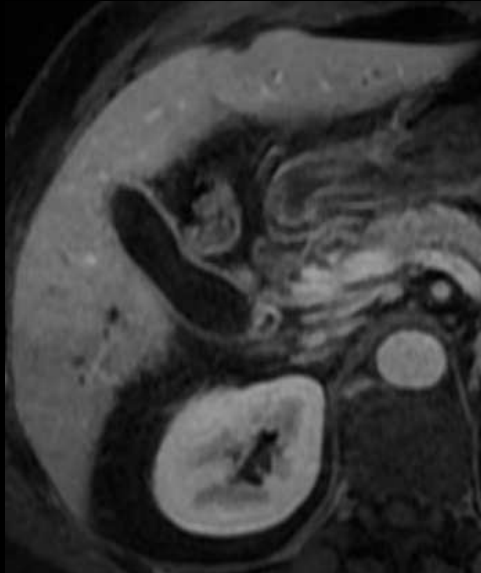
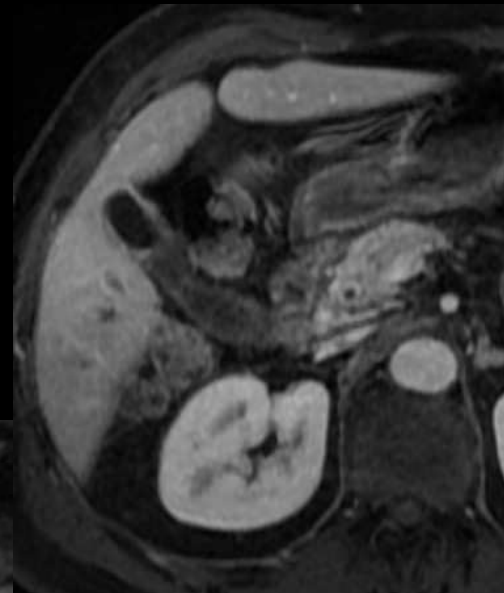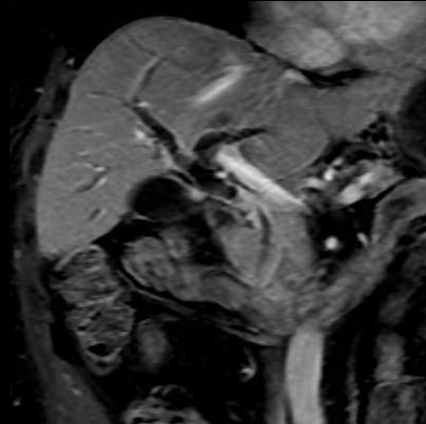
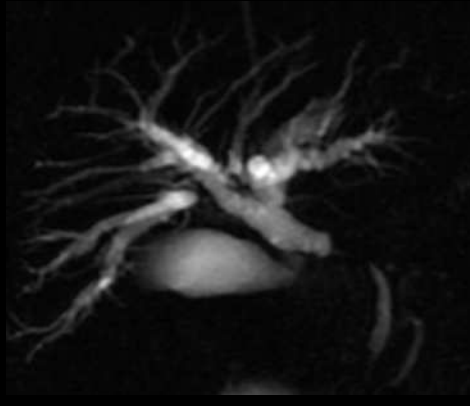
## Extension biliaire

### Classification de Bismuth et Cornette



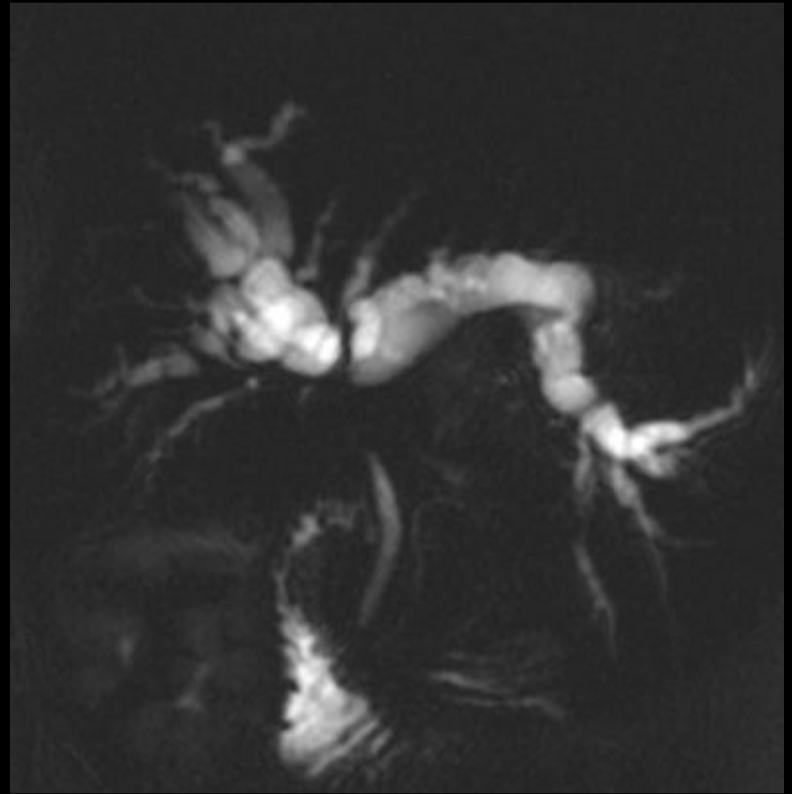
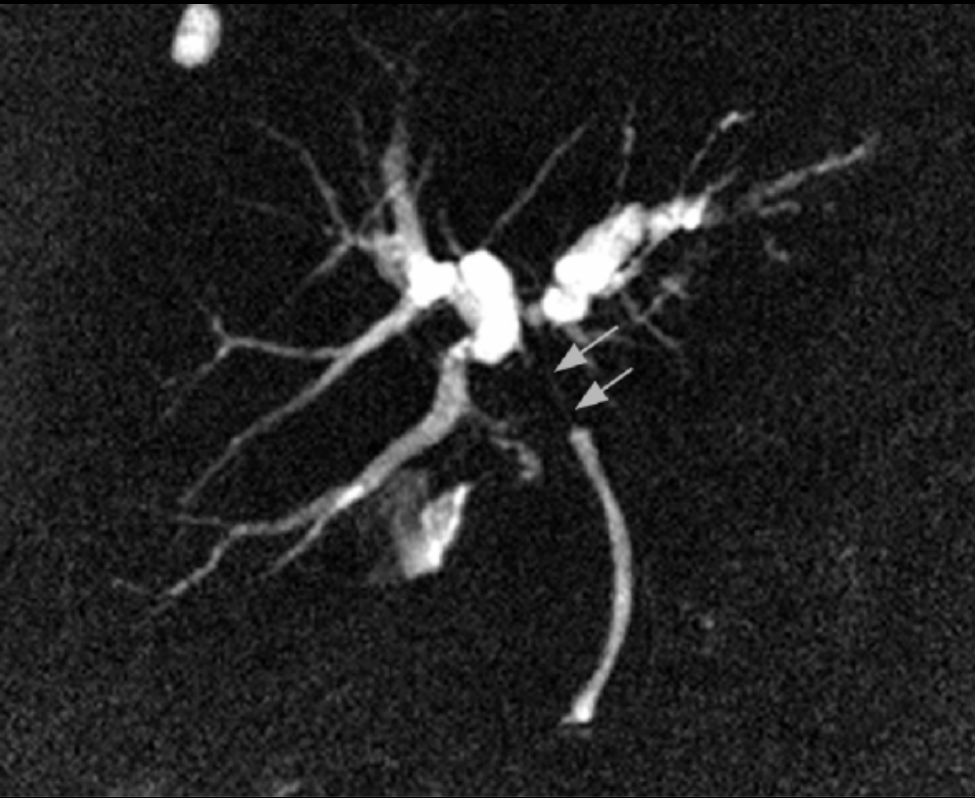
## Extension biliaire

### Classification de Bismuth et Cornette

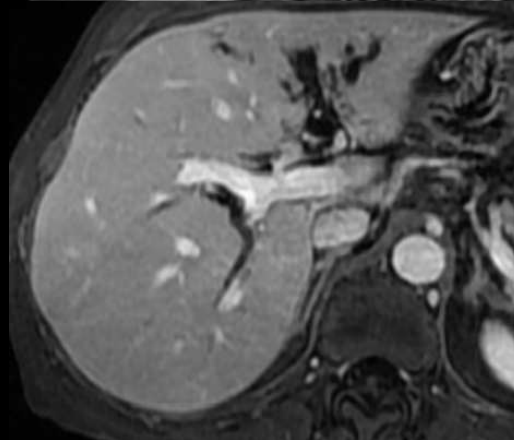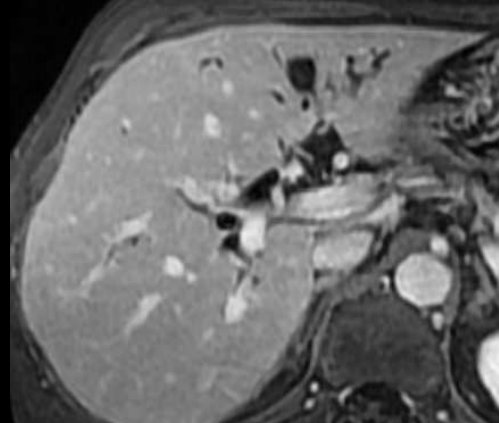
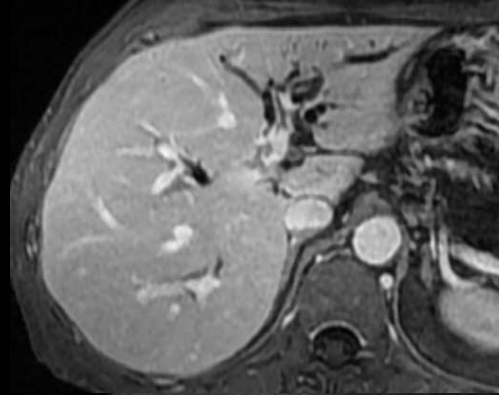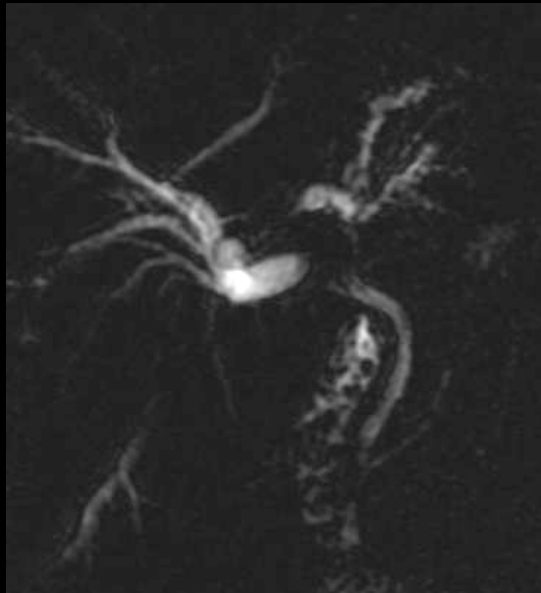


## Extension biliaire

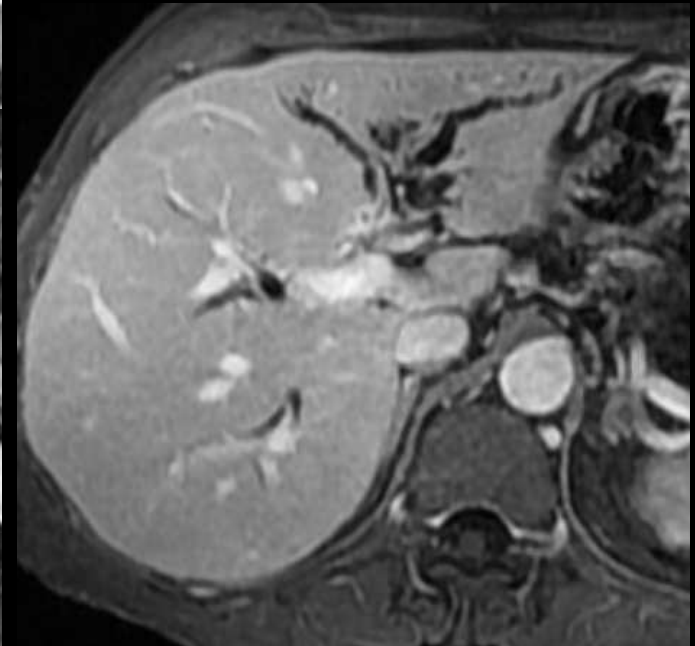
### Classification de Bismuth et Cornette



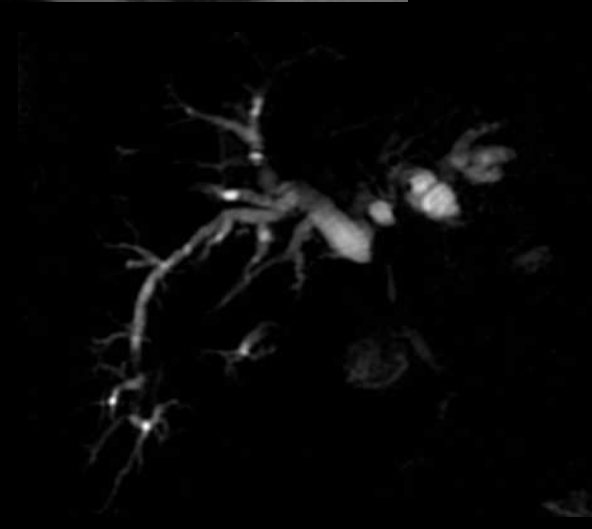
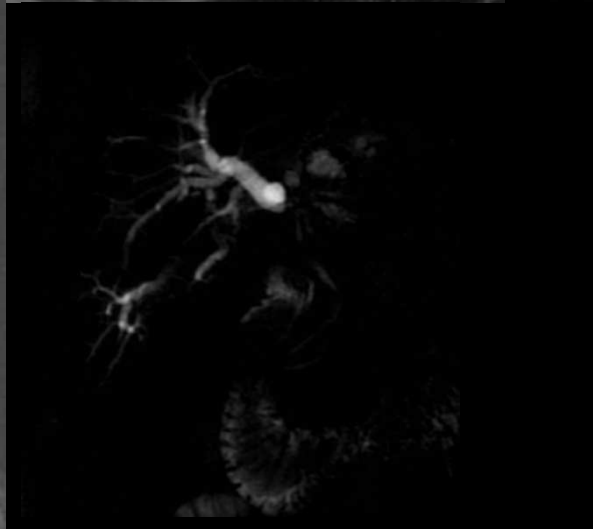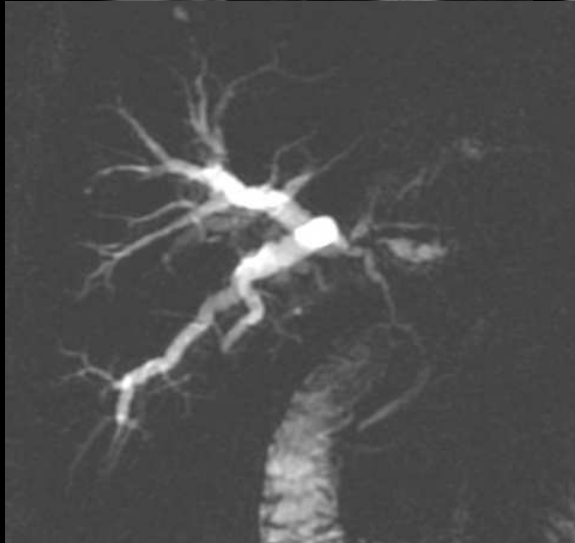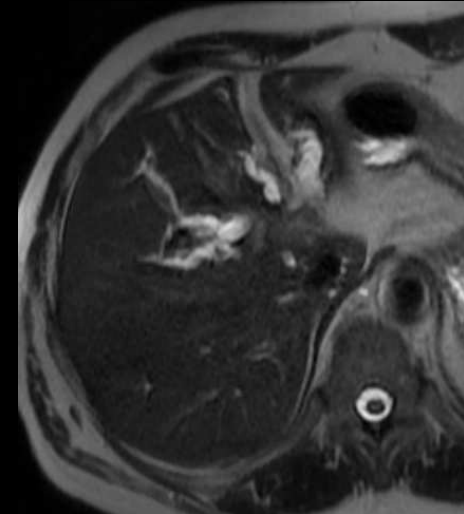
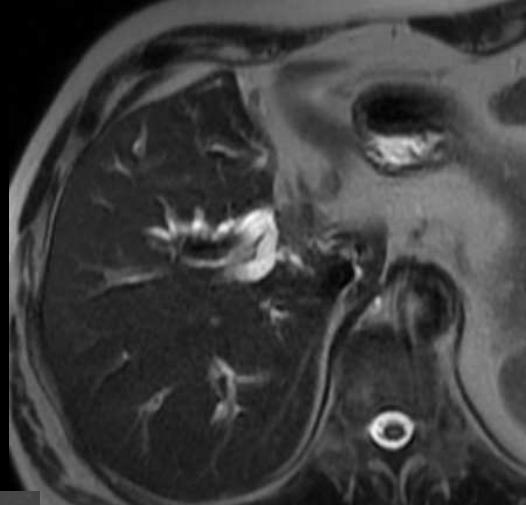
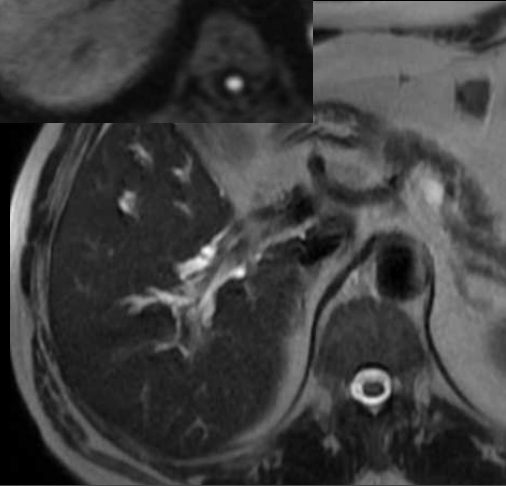
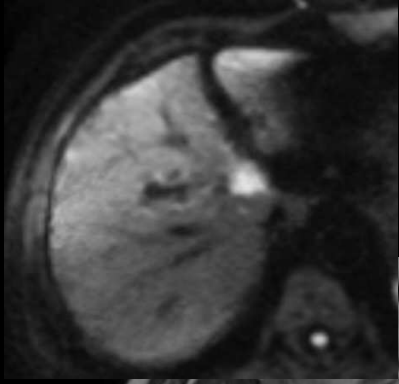
# Evaluation de l'extirpabilité



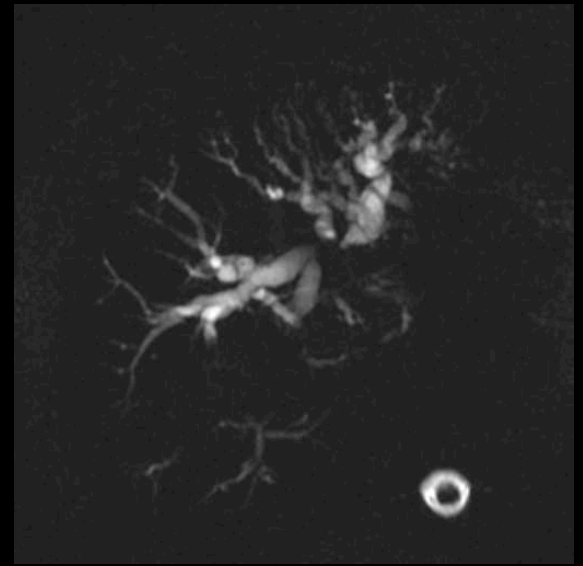
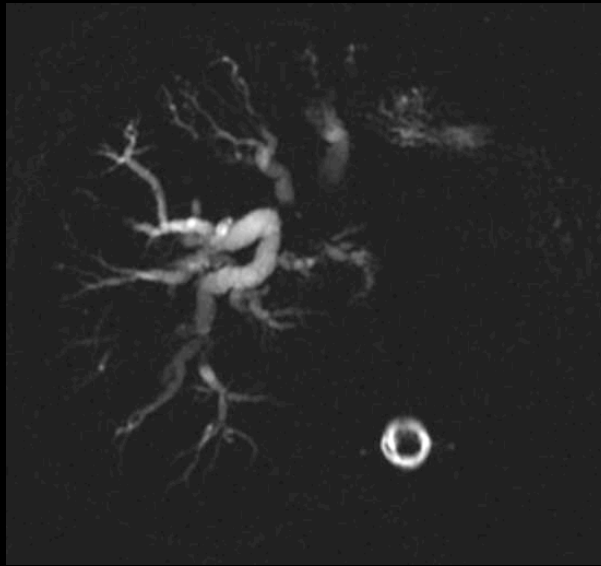
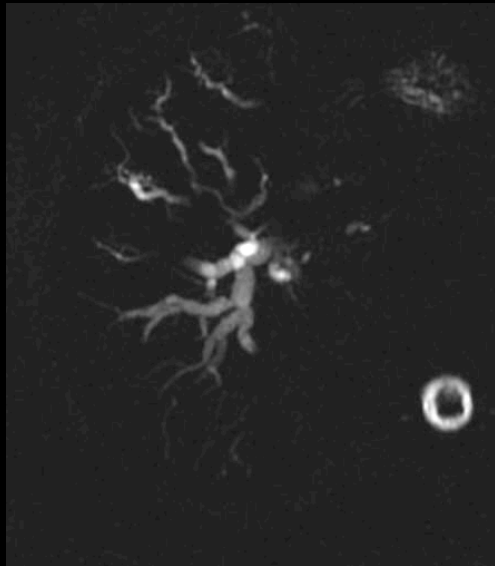
**Extension biliaire**



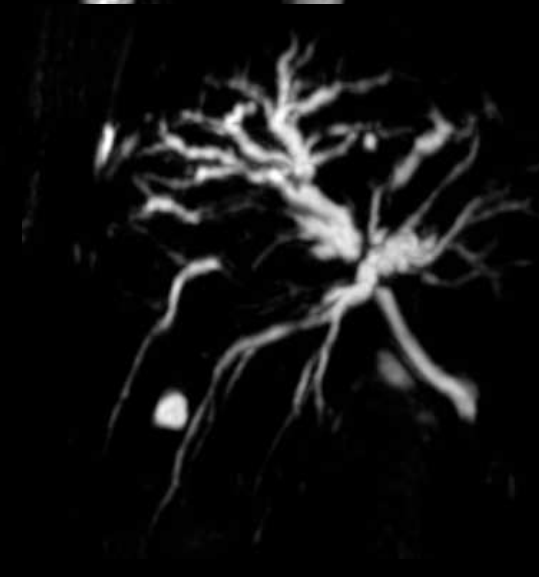
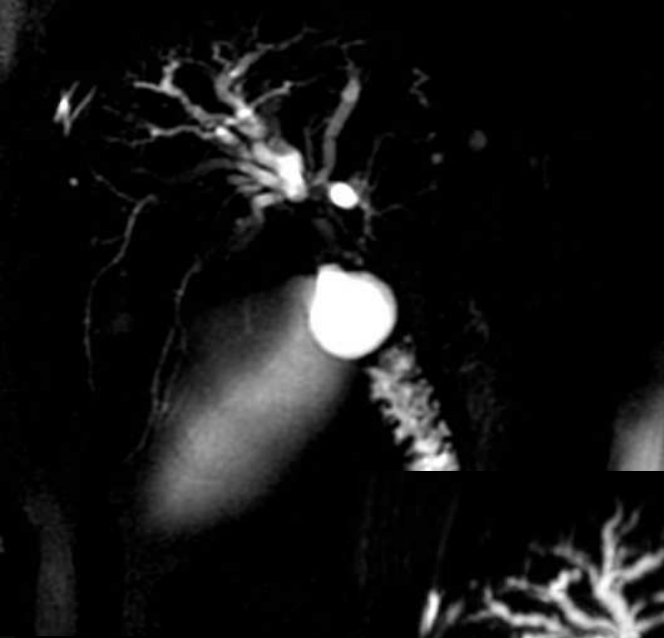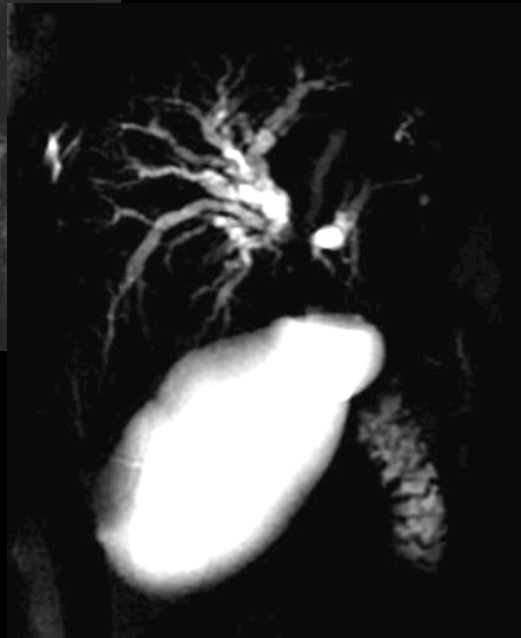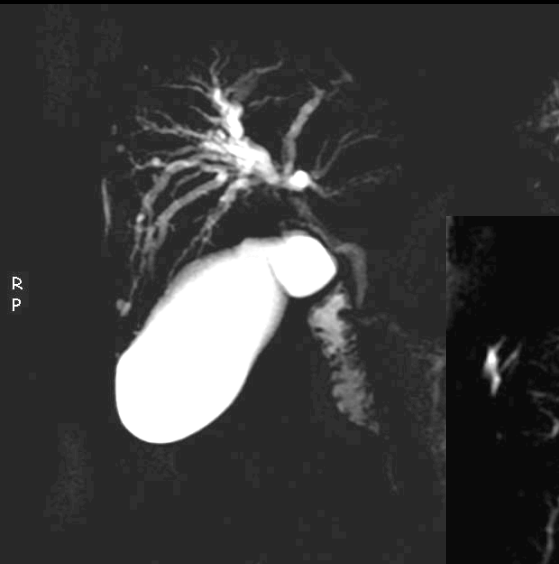
## Extension biliaire



## Extension biliaire



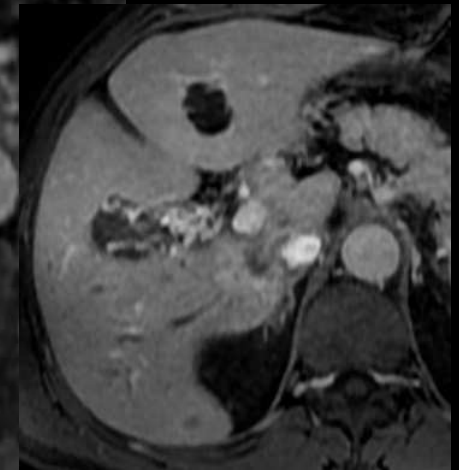
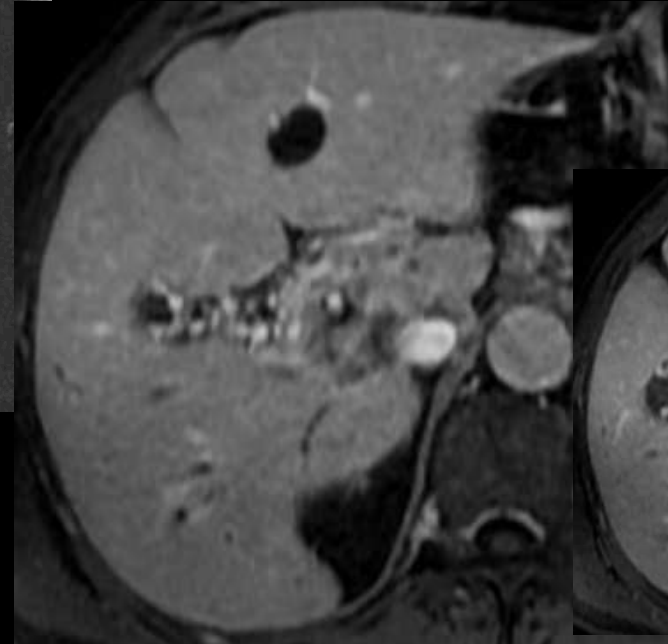
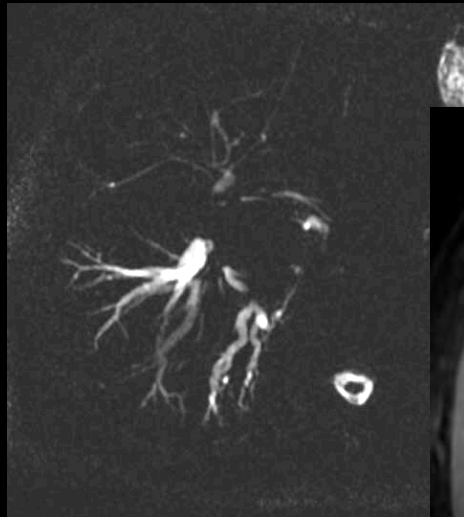
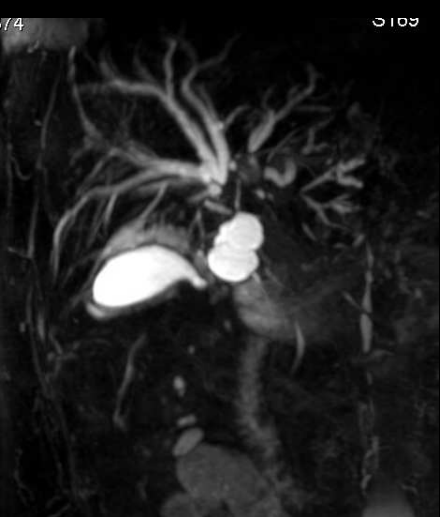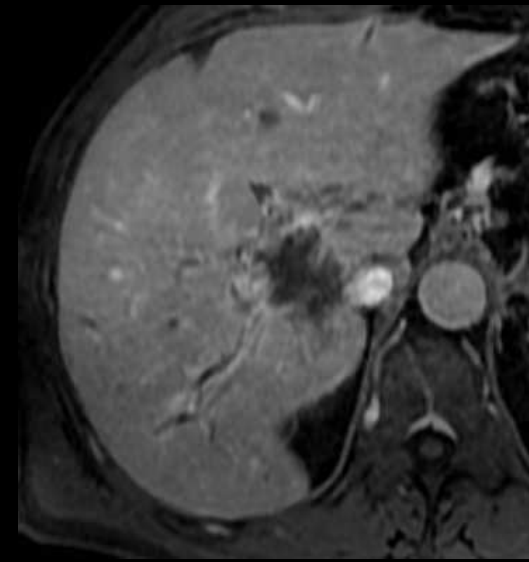## Extension biliaire



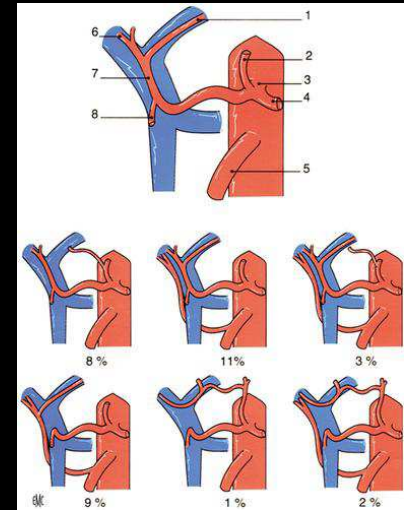
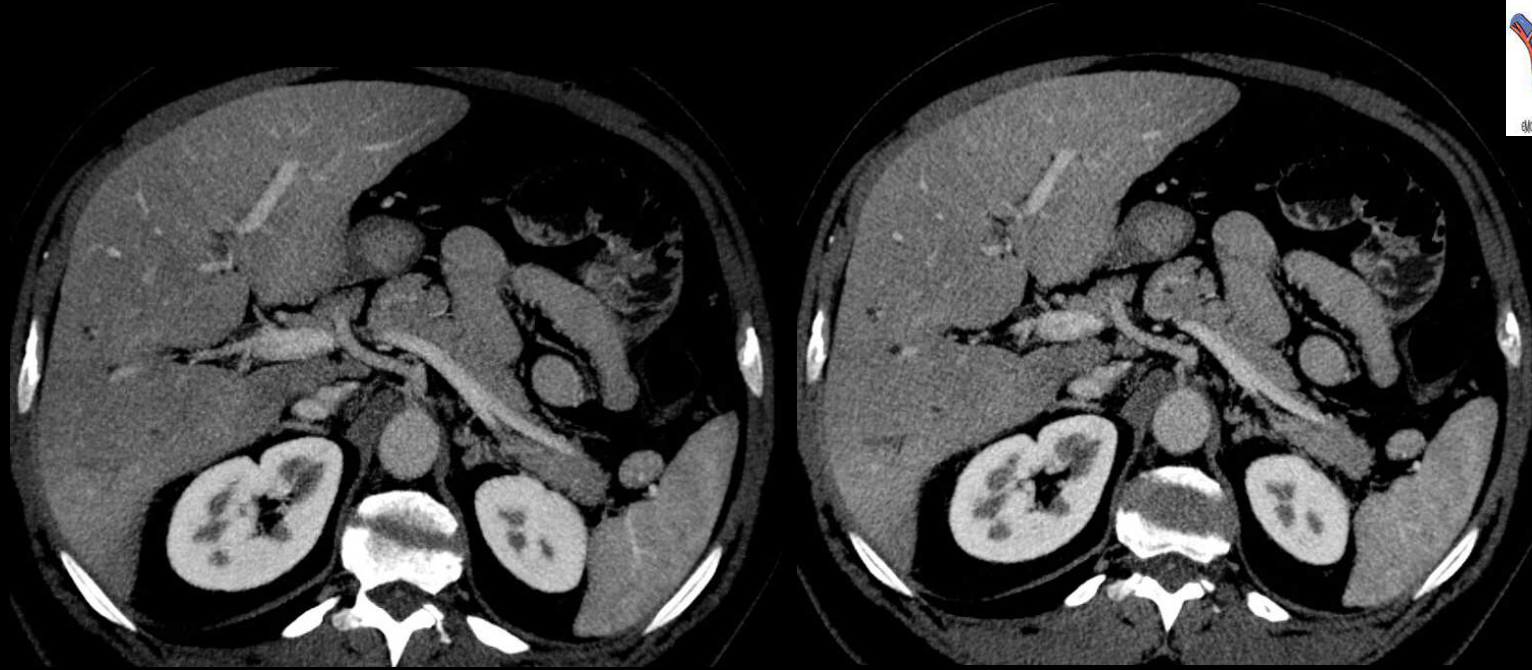## Extension artérielle

### Bilan artériel :

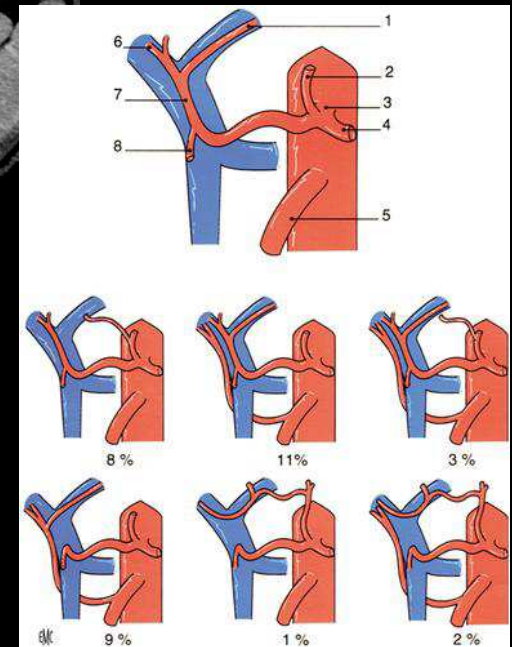
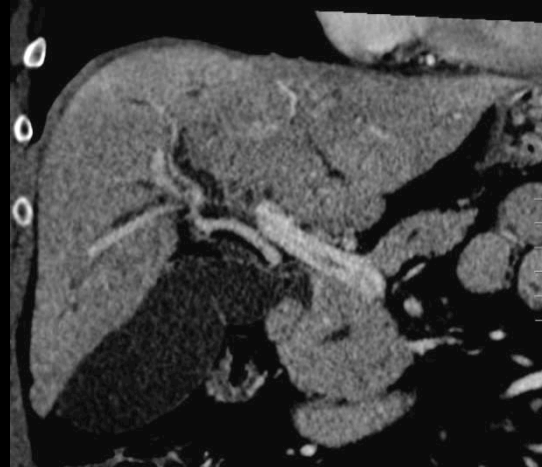
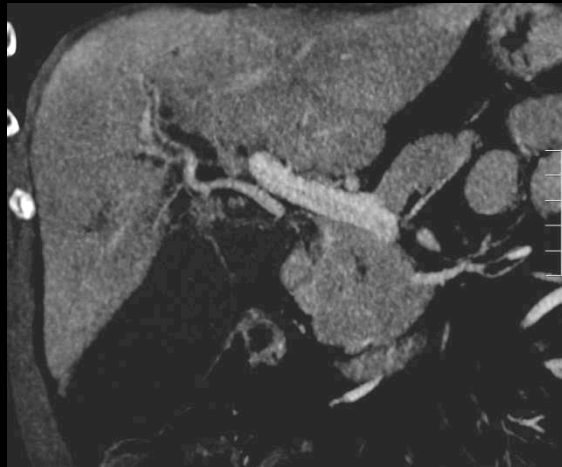
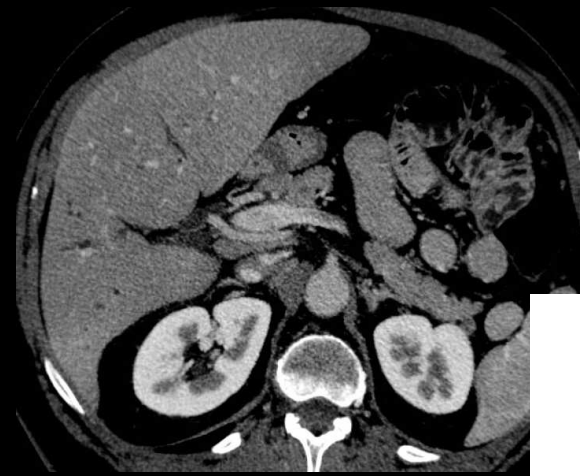
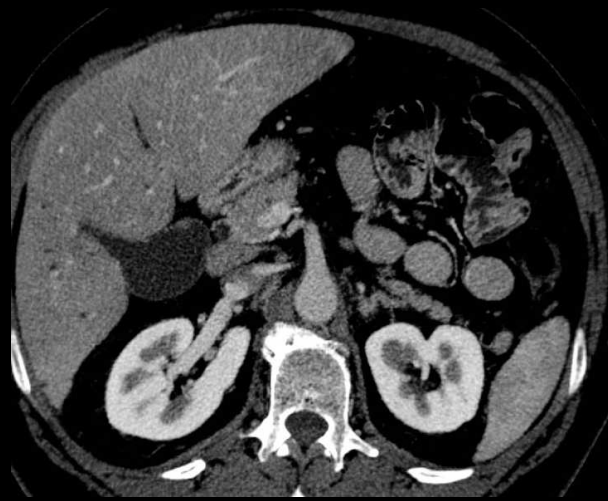
- Siège de la lésion/artère hépatique commune et aux branches de l'artère hépatique
- Préciser si engainement (en degrés), sténose ou thrombose
- Préciser si distribution normale ou si présence de variantes anatomiques



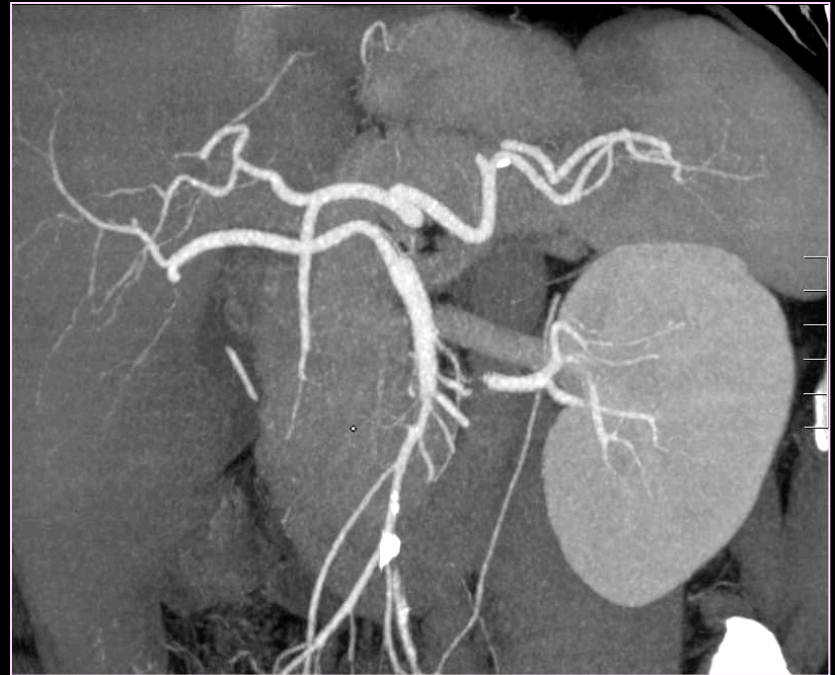
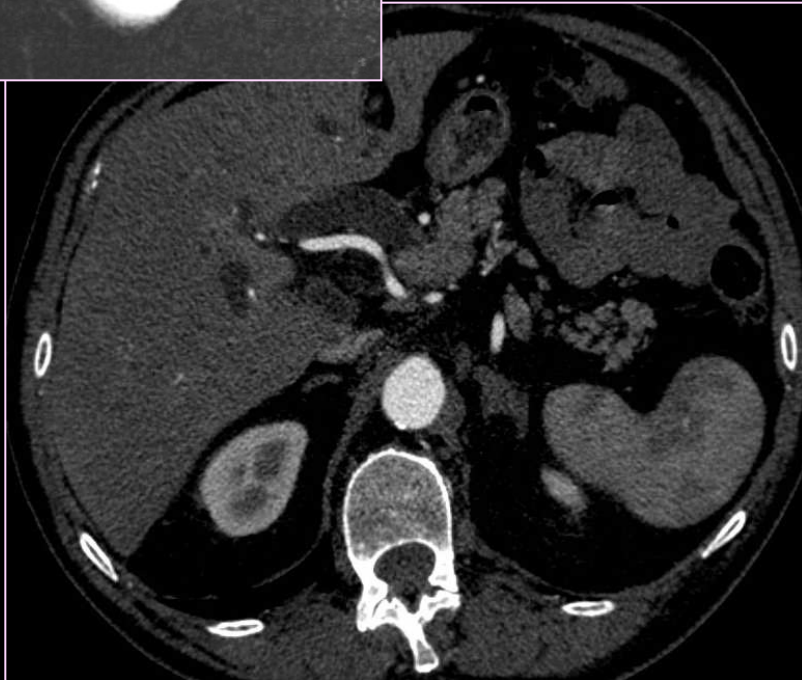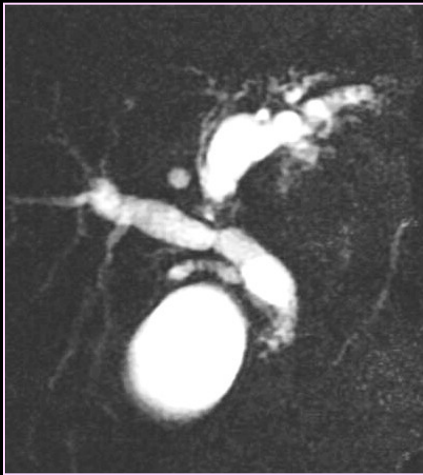
## Extension artérielle



## Extension artérielle

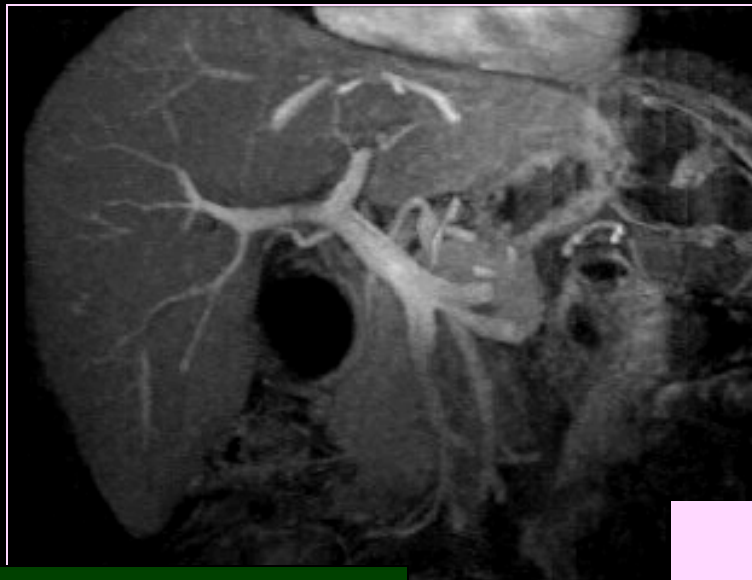
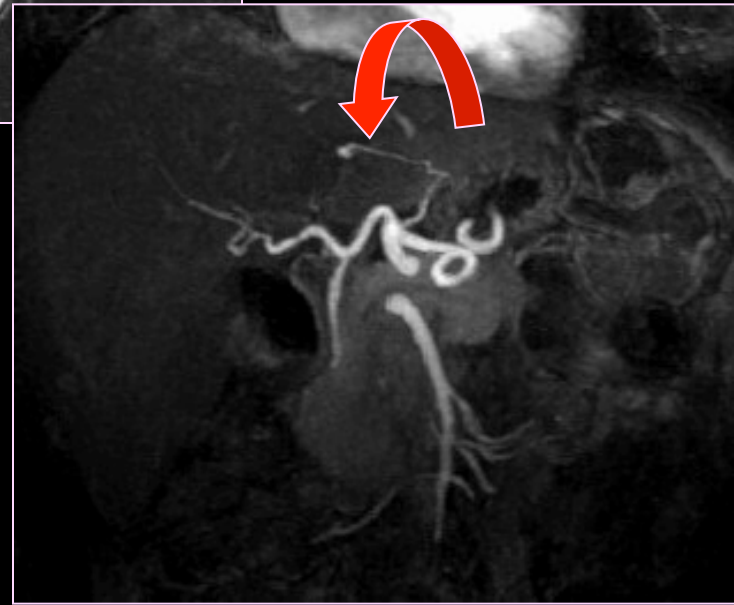
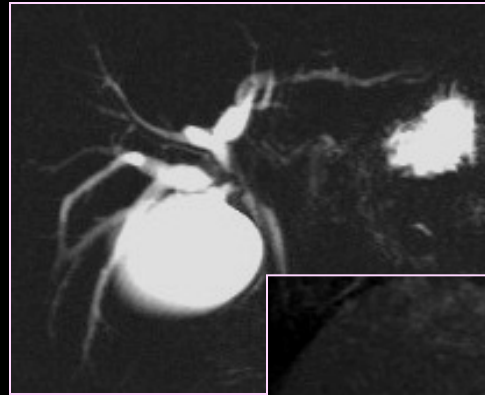
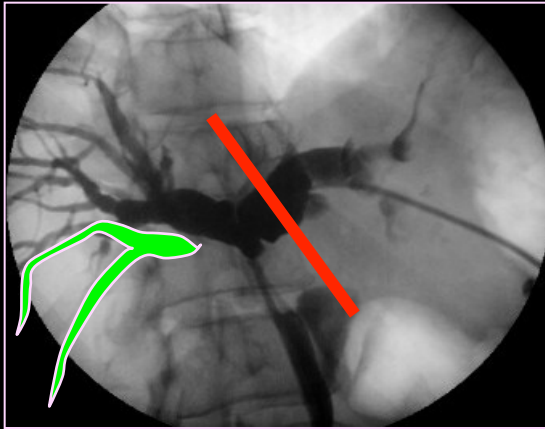


Extension artérielle



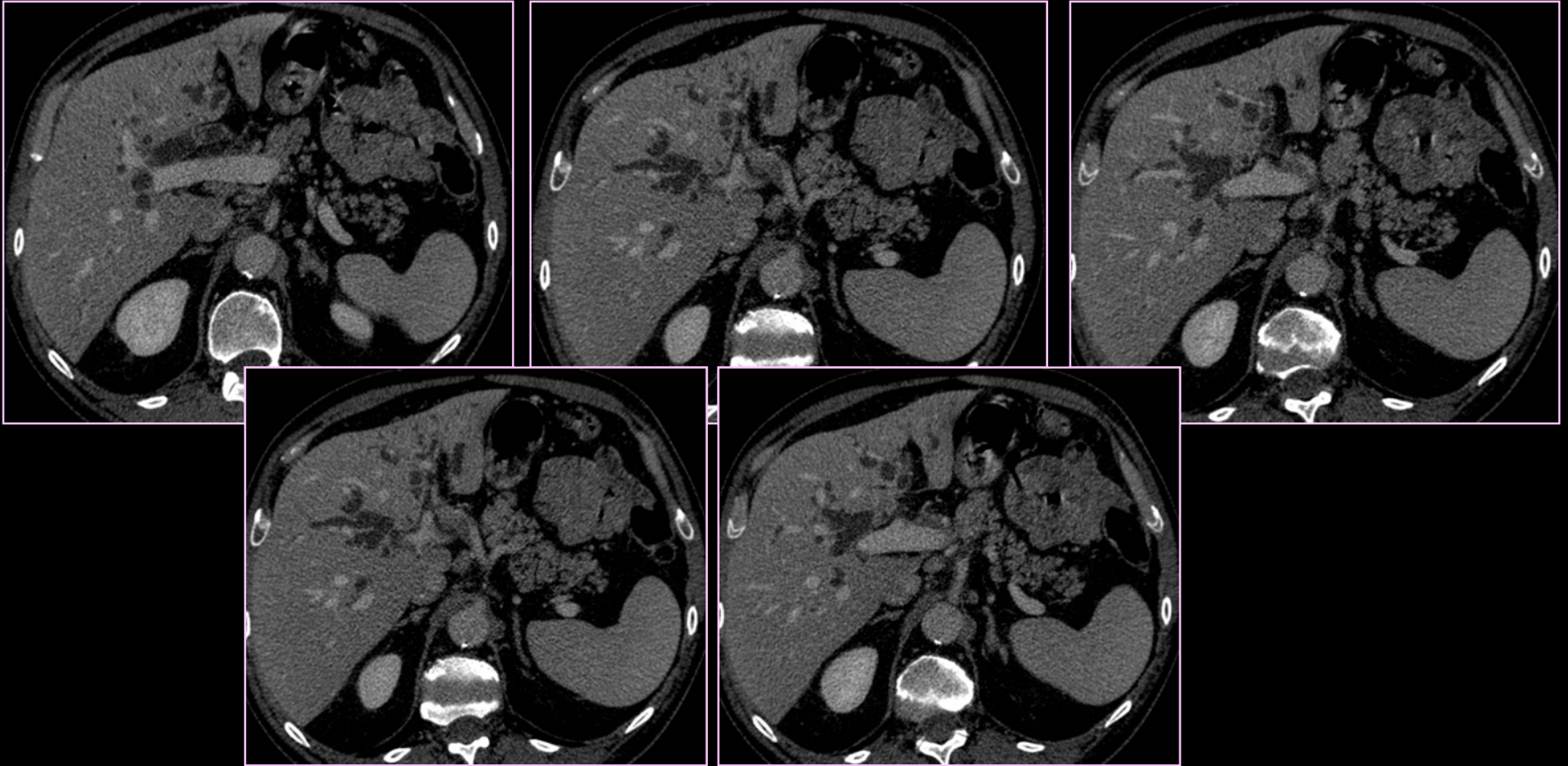
Artère hépatique droite naissant de l'AMS

## Extension artérielle



Artère hépatique gauche naissant de l'artère coronaire stomacachique

## Extension portale

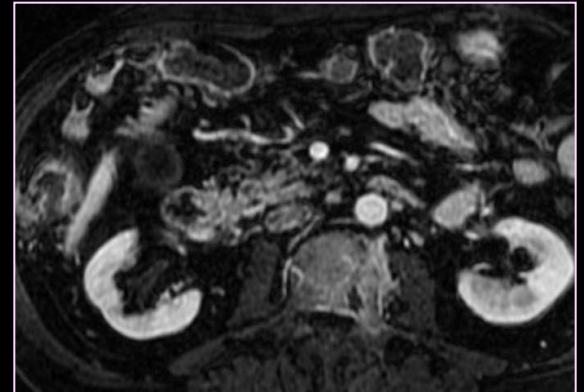
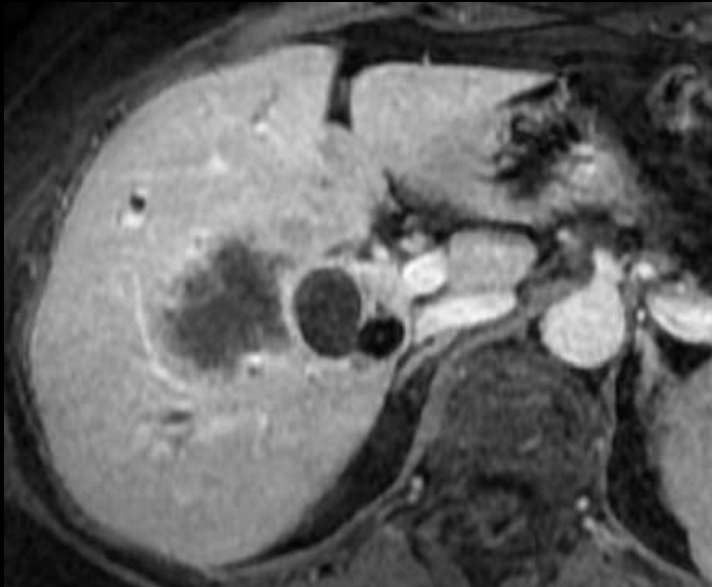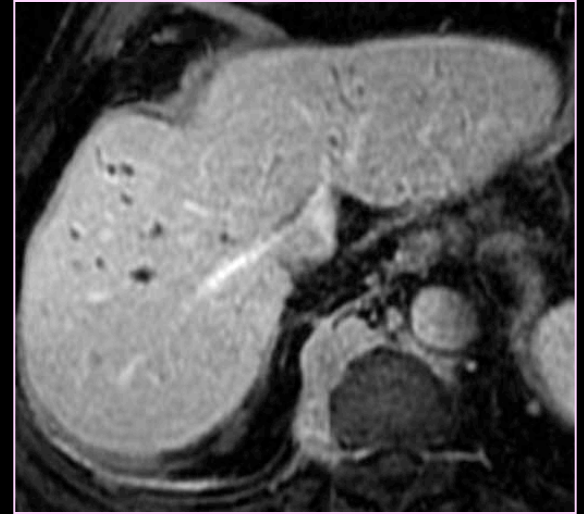
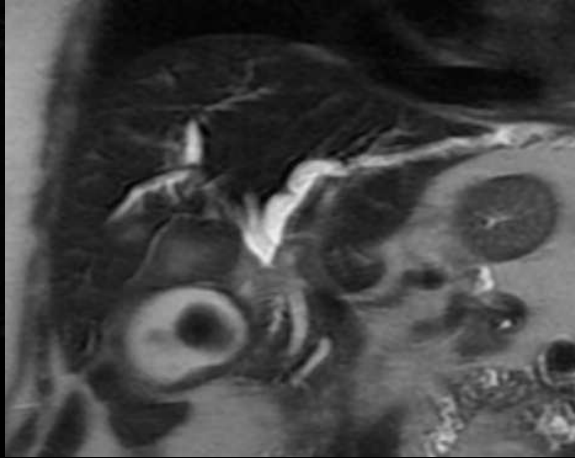
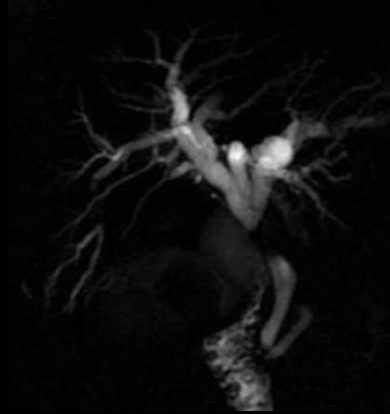


## Critères d'irrésécabilité chirurgicale

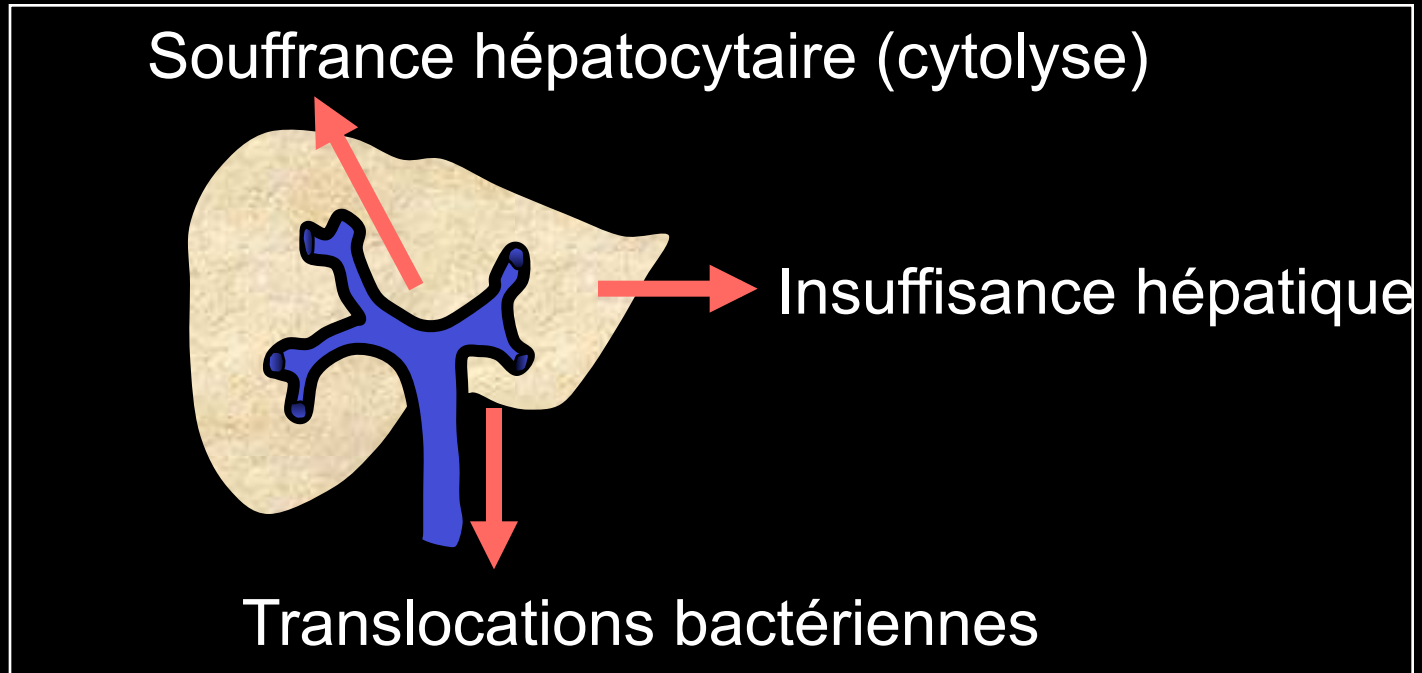
- Soriano et al. Am J Gastroenterol 2004, 99 : 492-501.
  - Comparaison scanner,echoendoscopie, IRM ,angiographie
  - Atteinte vasculaire : **scanner hélicoidal >> autres techniques**
- Comparaisons angio scanner/Chir.
  - Envahissement portal
    - Diag.+ : 85,5 % - 94,4%
  - Envahissement artère hépatique
    - Diag.+ : 88,9% - 92,7%

**Lee, Radiology 2006**

## Extension à distance



# Comment le radiologue peut-il participer à l'« optimisation » hépatique ?

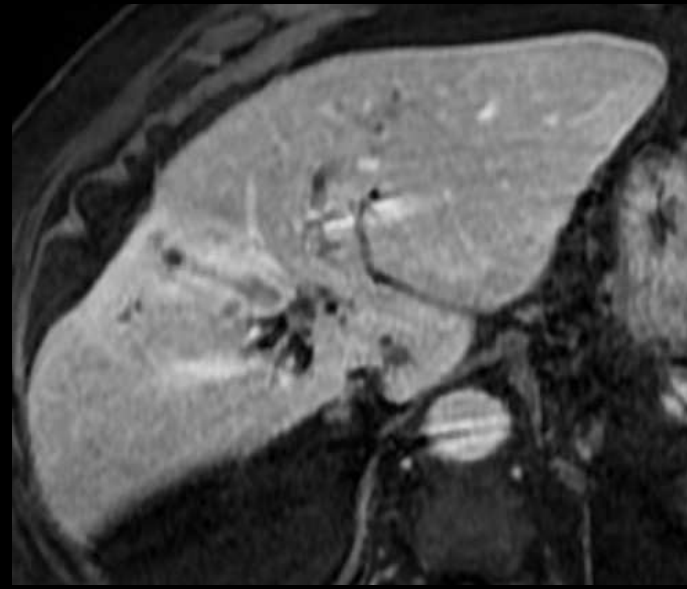
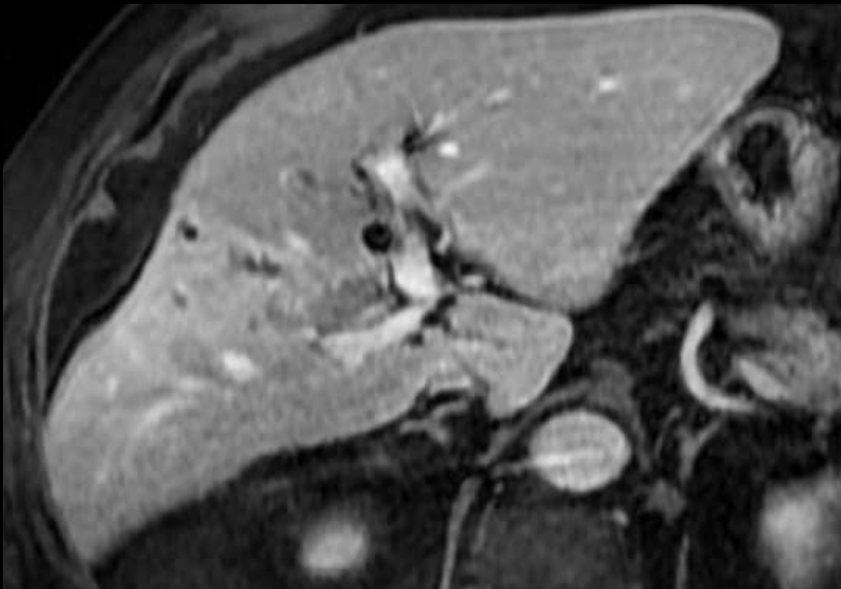


- Drainage biliaire
- Embolisation portale

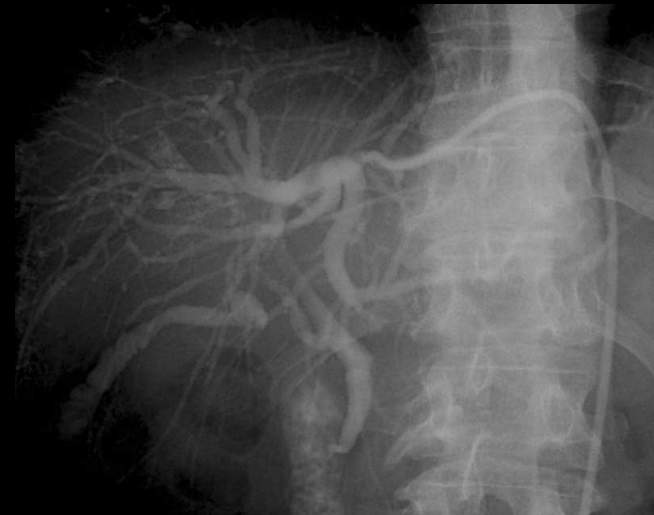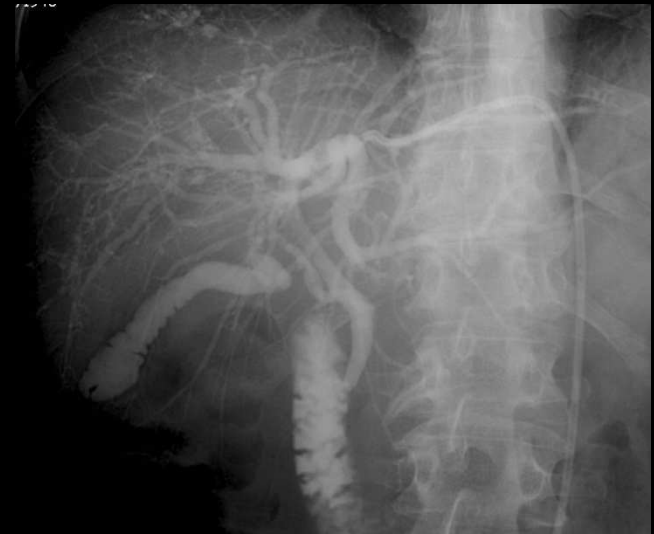## Etat du parenchyme hépatique sous jacent

Morphologie

Volumétrie du parenchyme hépatique restant



Drainage  
Embolisation portale



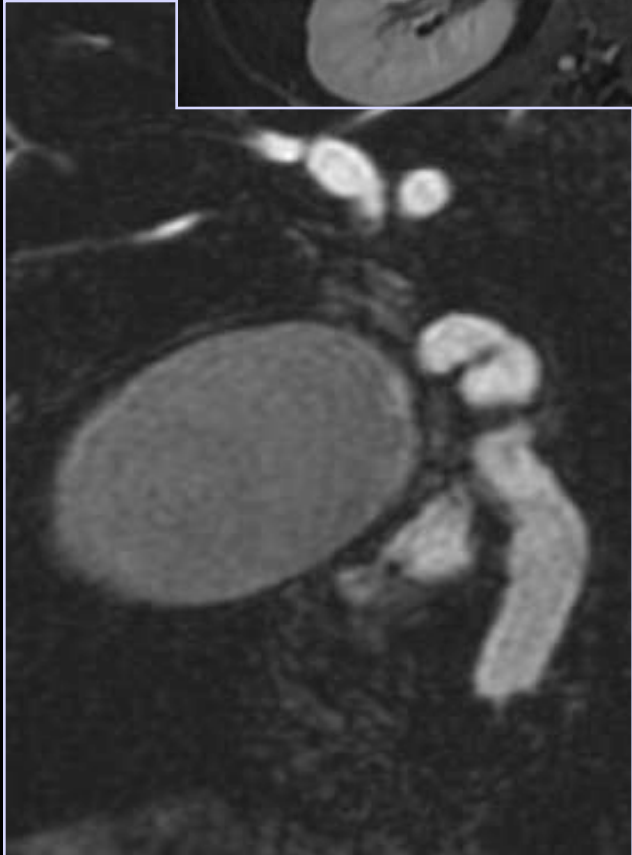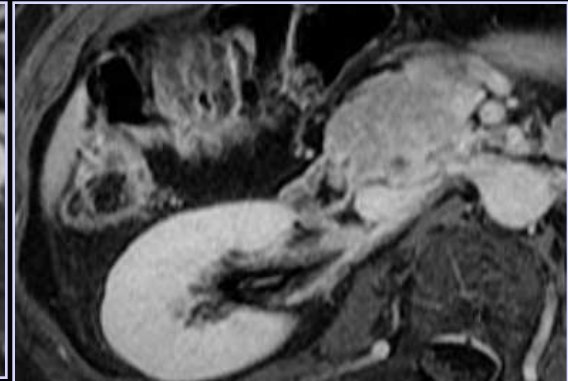
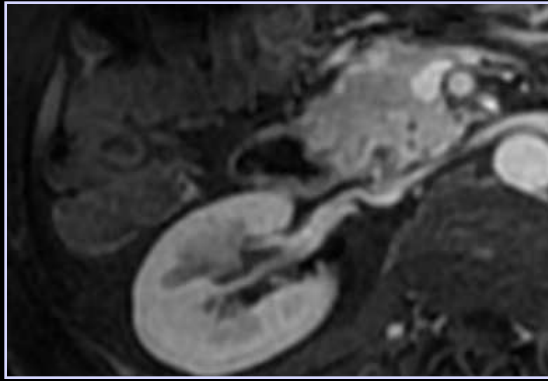
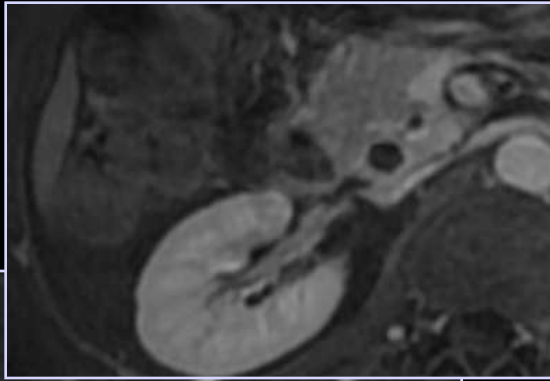
# Plan

- **Tumeurs de la vésicule biliaire**
- **CCK IH**
- **CCK hilaires**
  - Diagnostic positif
  - Bilan d'extirpabilité
- **Tumeurs du bas cholédoque**

# Cholangiocarcinomes du bas cholédoque

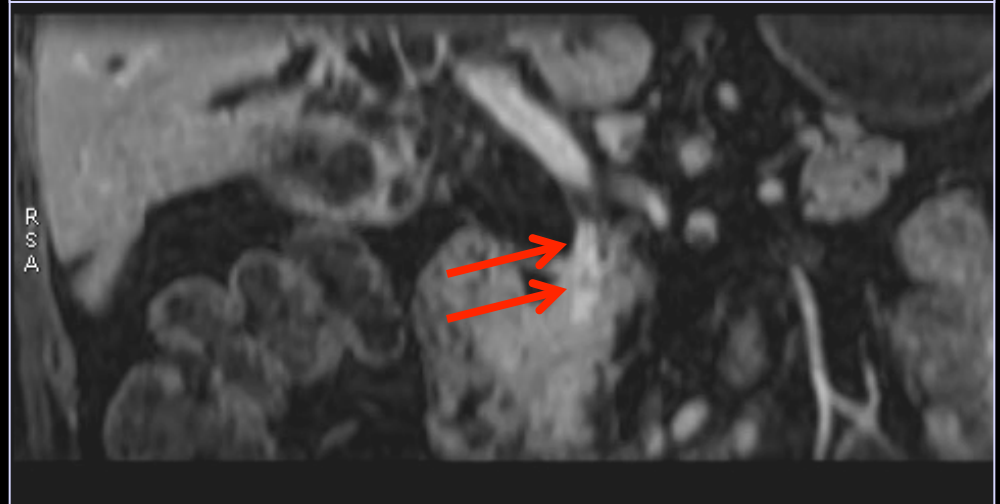
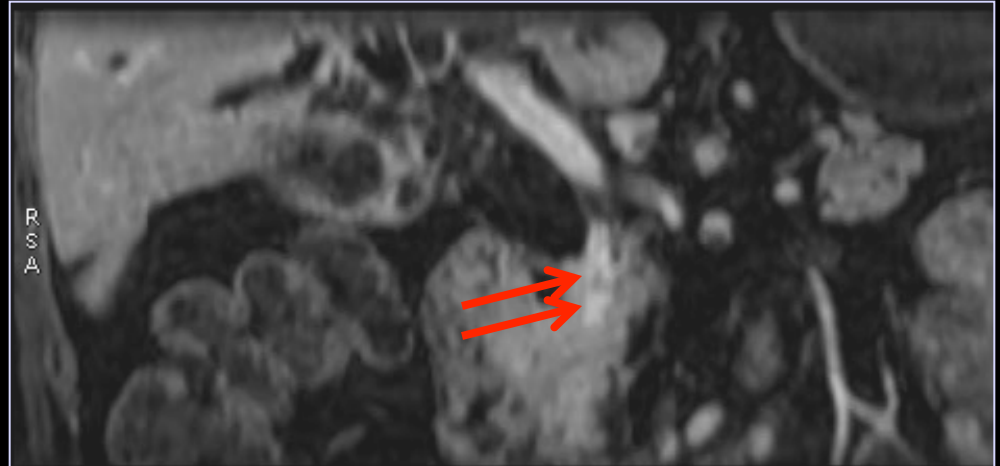
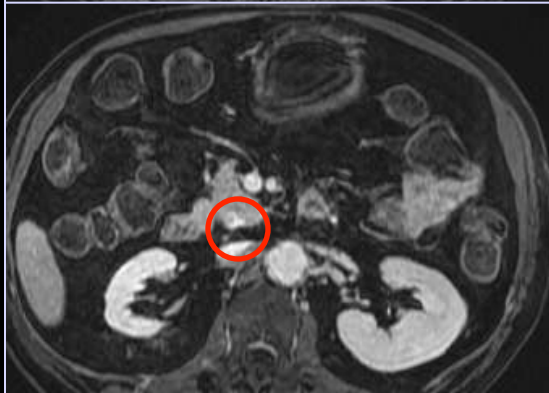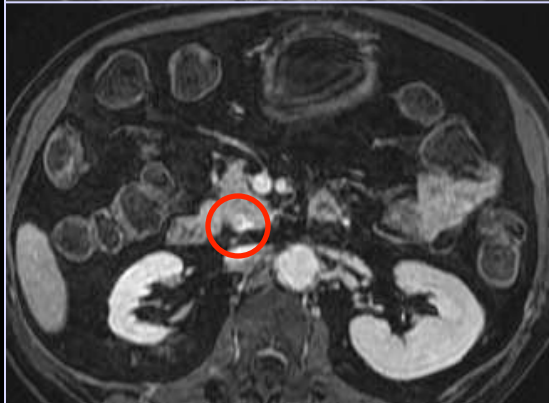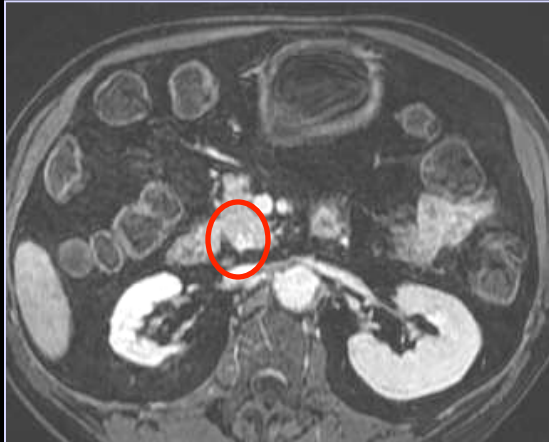# IV. Cholangiocarcinomes du bas cholédoque

## Forme infiltrative



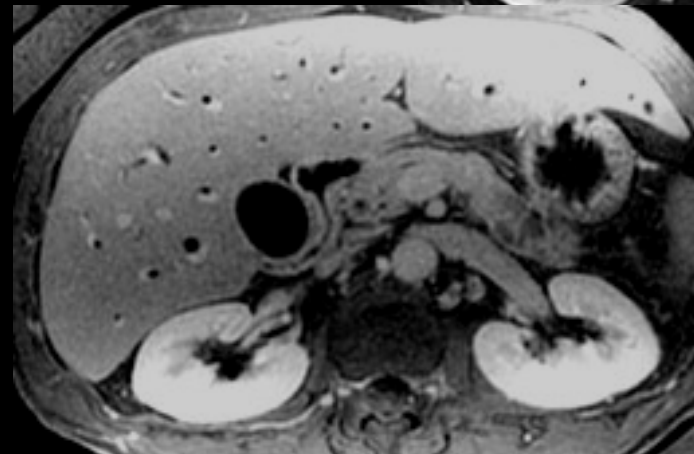
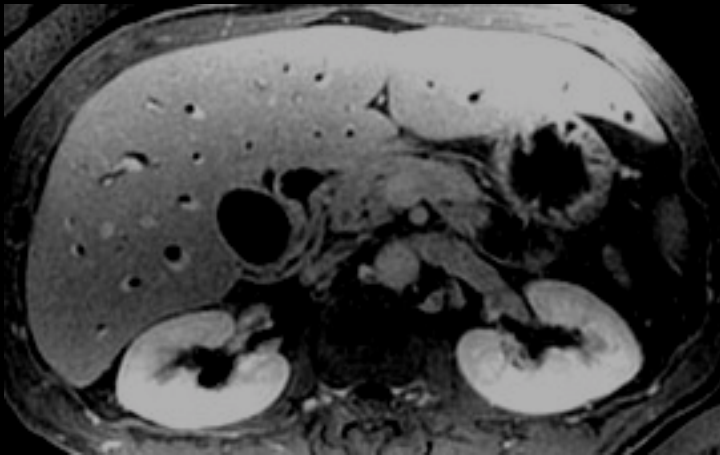
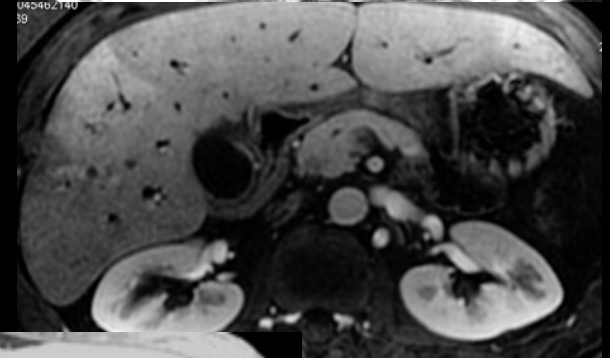
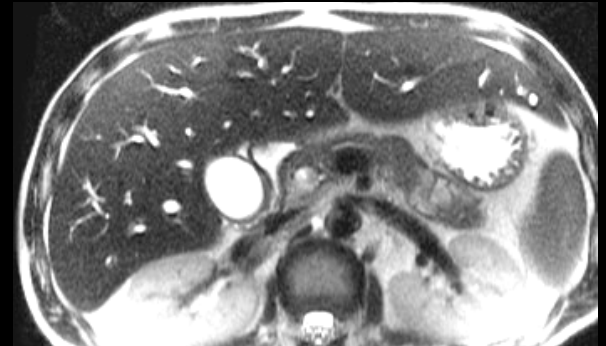
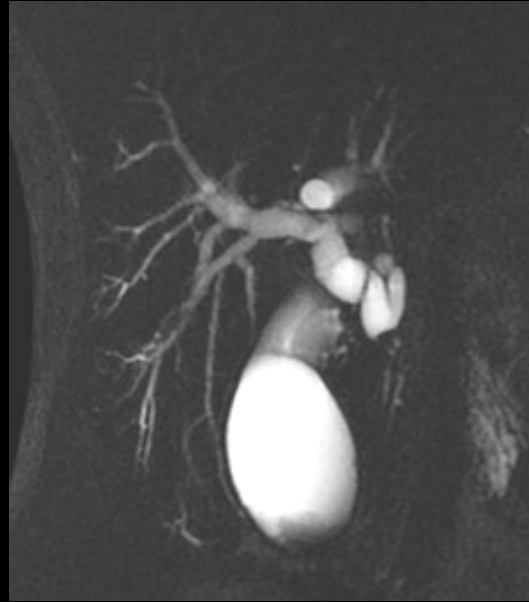
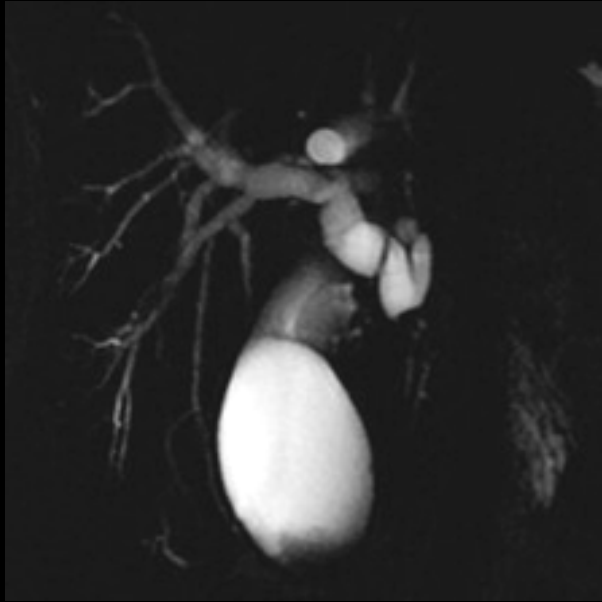
# Cholangiocarcinomes du bas cholédoque

## Forme infiltrative

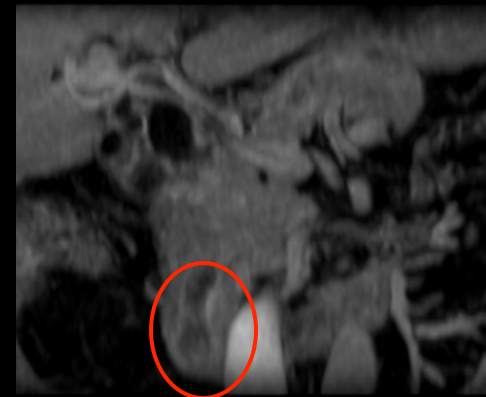
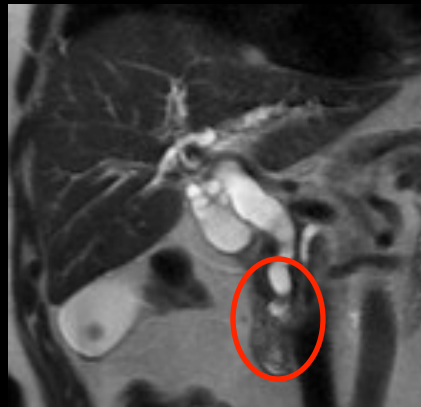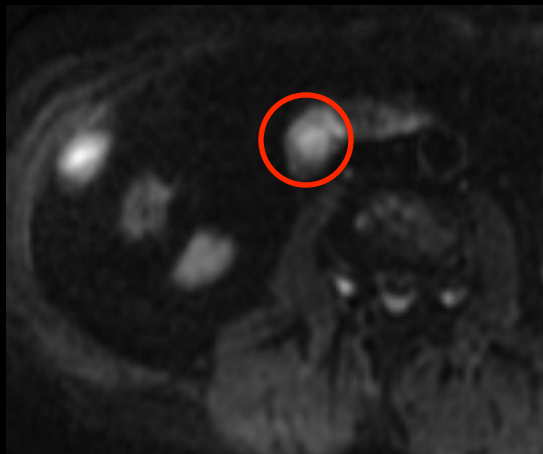
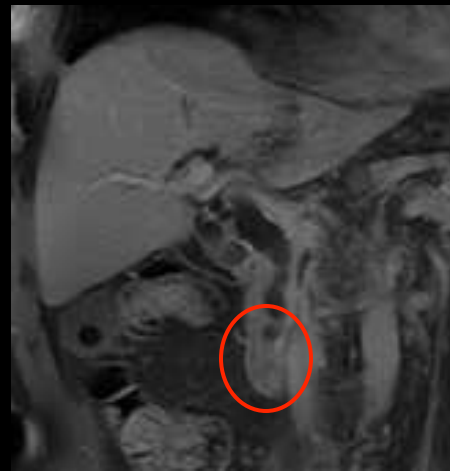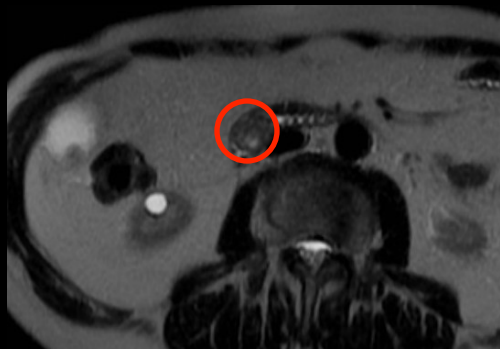
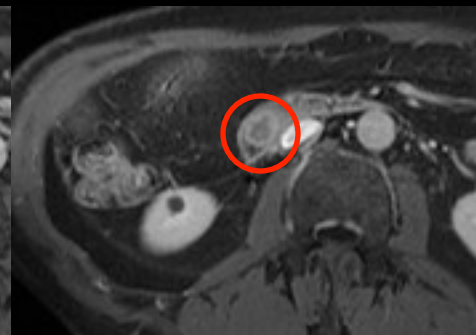


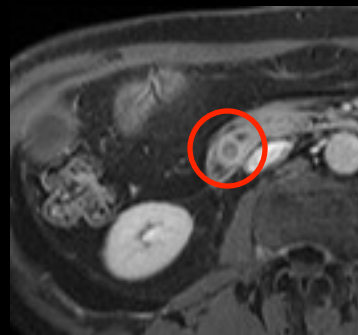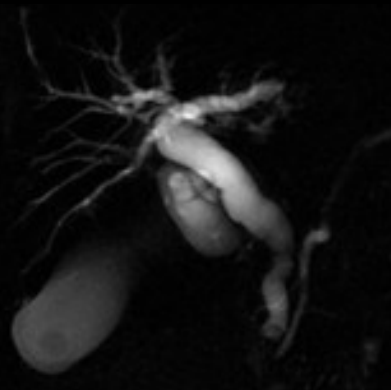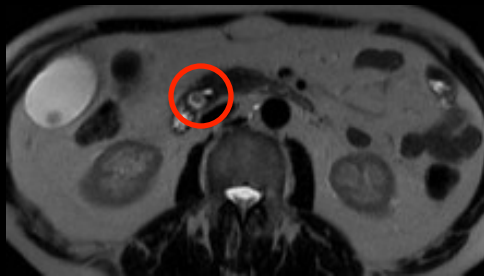# Cholangiocarcinomes du bas cholédoque

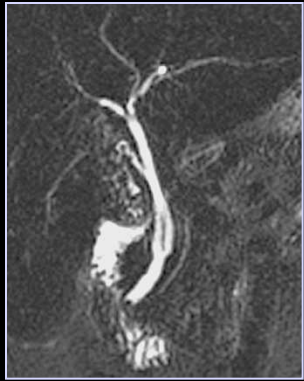## Diagnostic différentiel ADK pancréas



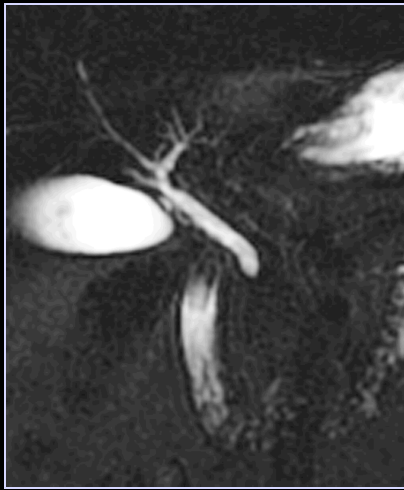
# Ampullomes



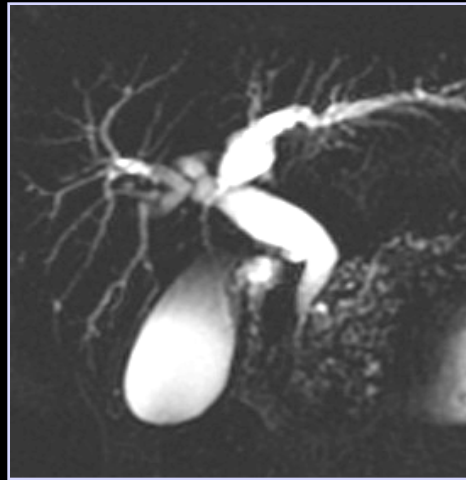
# Sténoses bénignes



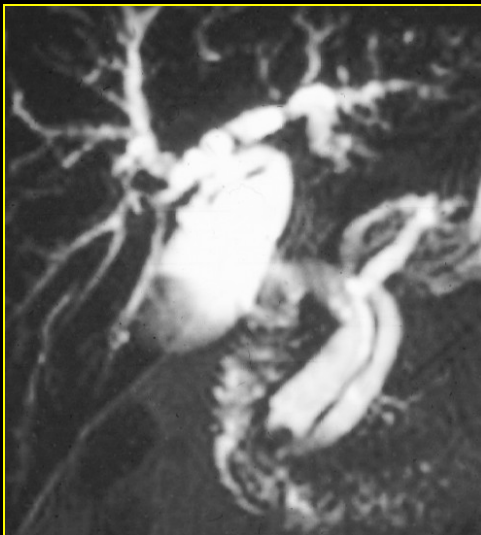
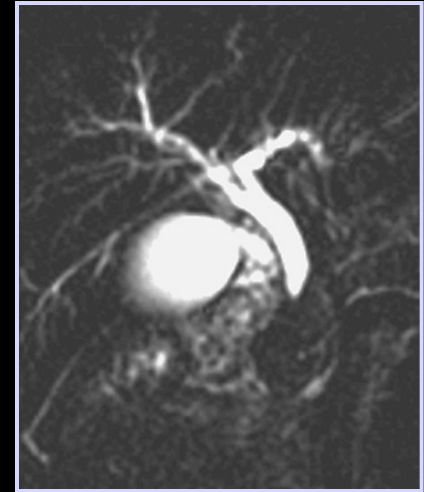
Lithiasique



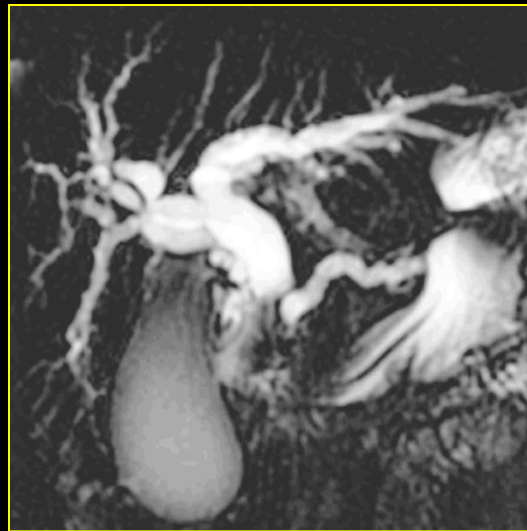
Oddite



Pancréatites



Ampullome



ADK

# Sténoses malignes

# Conclusion

- **Masse hép centrée par la vésicule avec extension hilare**
  - CCK vésiculaire
  - FDR : Long common channel
- **Epaississement irrégulier de la paroi vésiculaire**
  - CCK vésiculaire infiltrant
- **Masse IH : CCK IH**
  - Fibrose : temps tardifs +++
  - FDR : CSP
- **Obstacles de la VBP (hilaires et en dessous)**
  - Eliminer Causes extrinsèques bénignes et malignes
  - Sténose hilare infiltration pariétale VB : CCK

**Tout n' est pas du cancer !!!!! .....**

## **Tumeurs endobiliaires rares**

**Papillomatose**

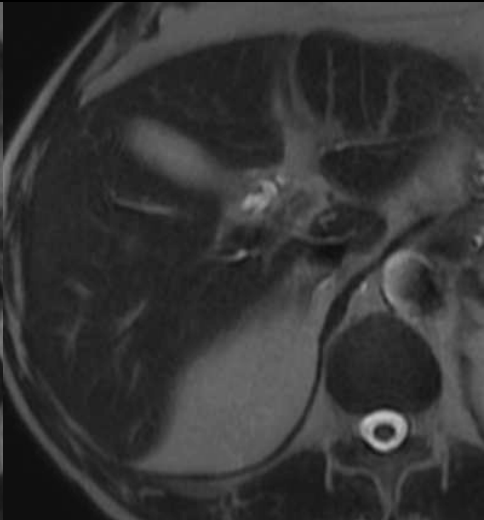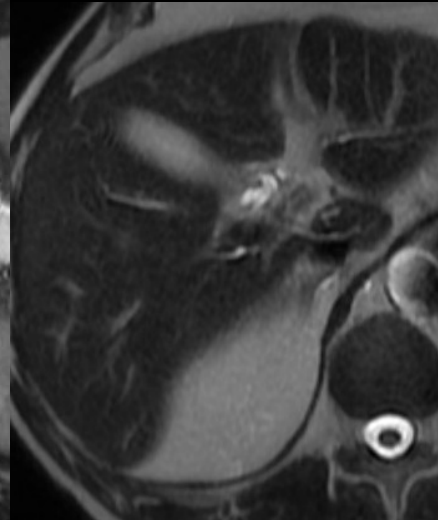
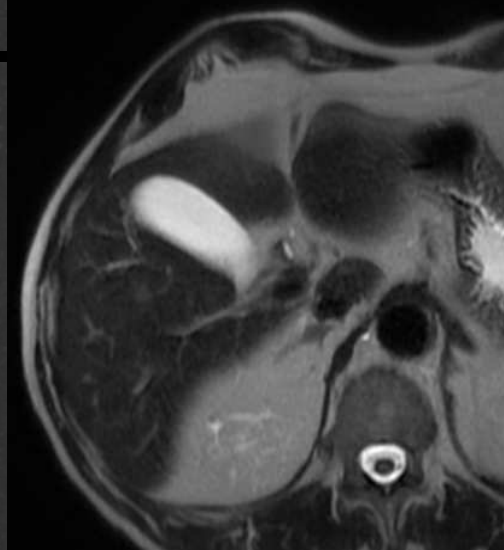
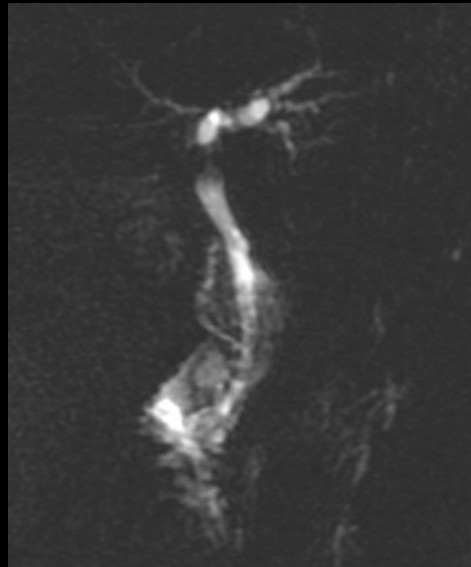
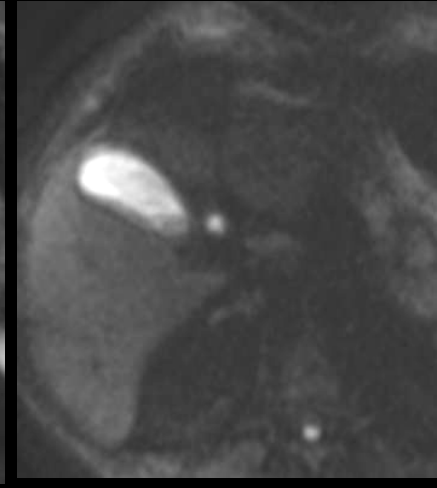
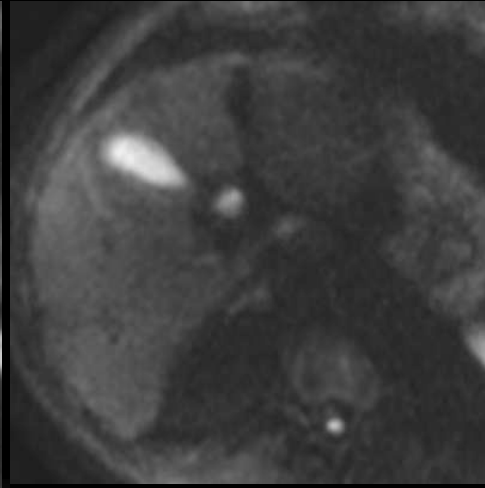
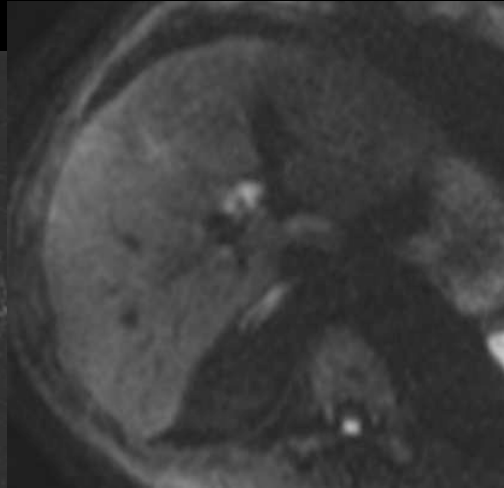
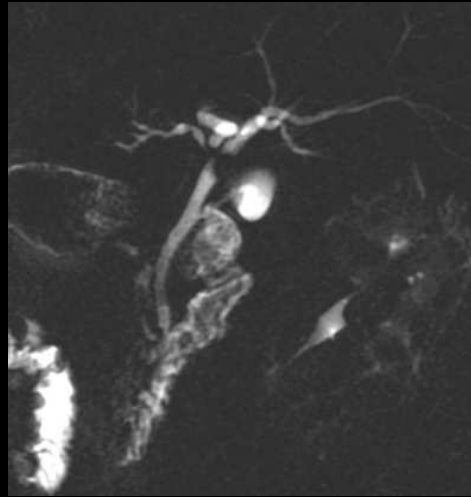
**CHC à développement endobiliaire**

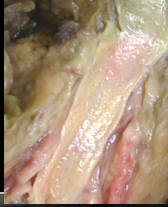**Métastases à développement endobiliaire**

## Papillomatose

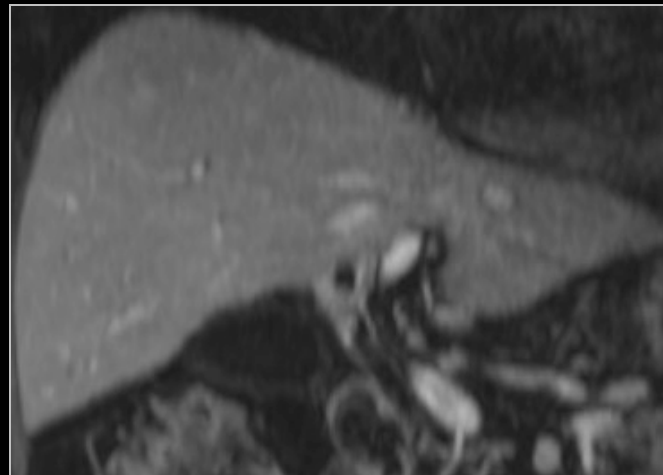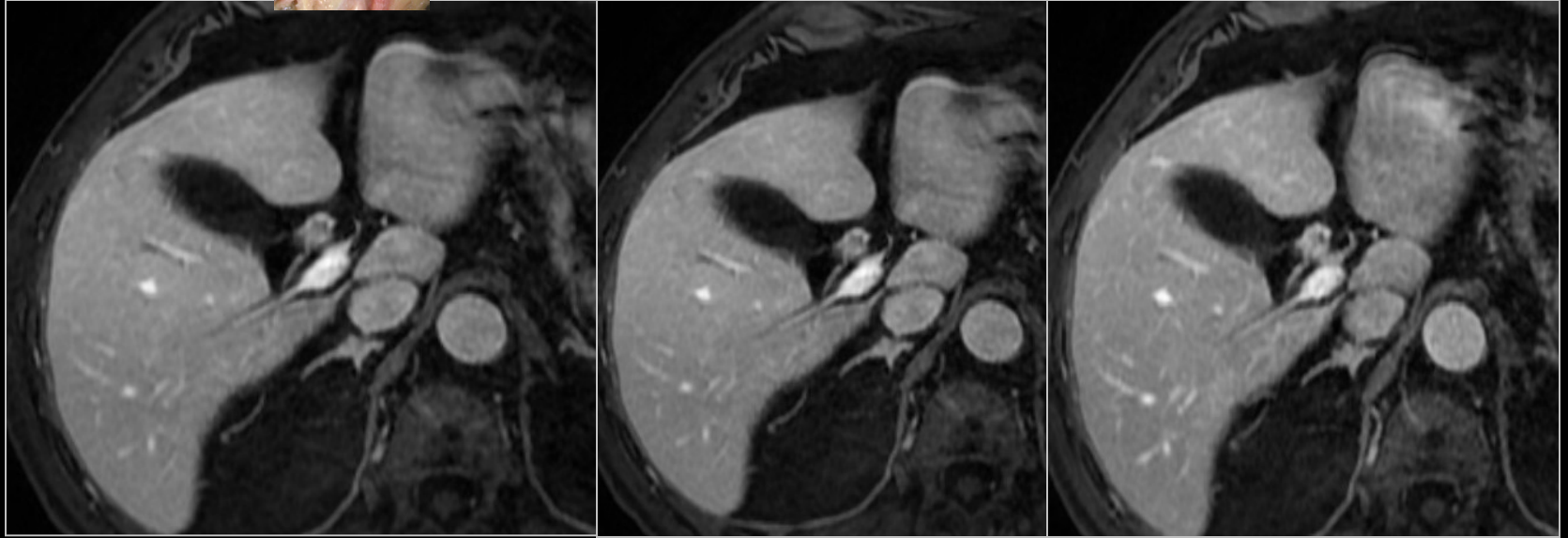
- Papillome biliaire : prolifération papillaire d'un épithélium biliaire atypique autour d'un axe fibro vasculaire
- Papillomatose : > 3 papillomes sur les VBIH ou EH, continue ou discontinue
- Degrés variables de dysplasie : de dysplasiques jusqu'à dégénérées
- 5 classes (différentes classes peuvent coexister)
  - Classes 1 et 2 : dysplasies de bas et de haut grade
  - Classes 3 : carcinome in situ
  - Classes 4 et 5 : invasion micro et macro du parenchyme hépatique et ou des couches fibro musculaires de la paroi biliaire
- Papillomatoses sécrétantes (dilatations en amont et en aval de l'obstacle) et non sécrétantes
- TTT chirurgical , transplantation hépatique envisageable pour les classes 1 et 2 voire 3

Papillome

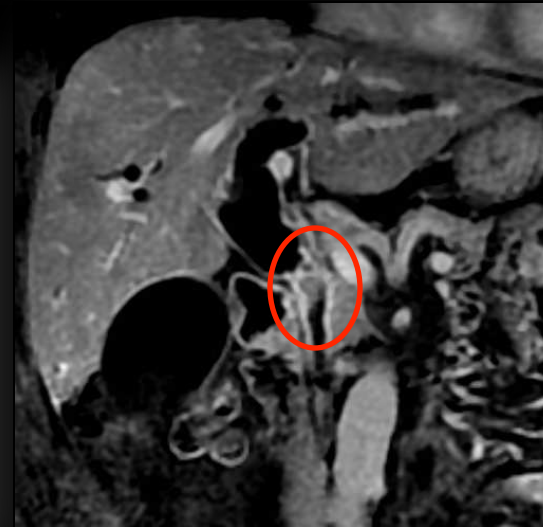
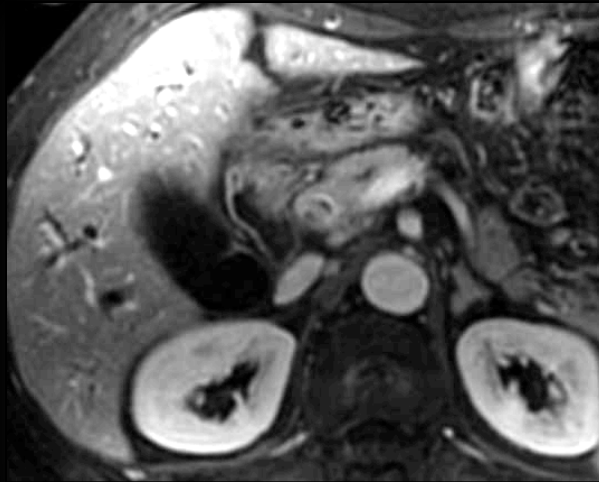
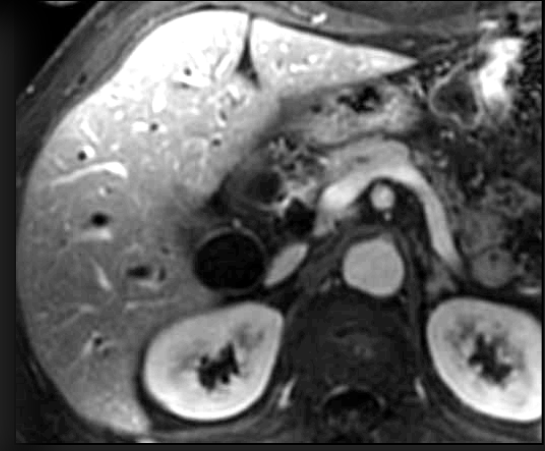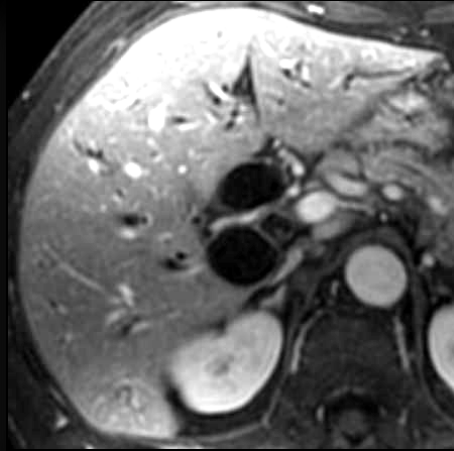
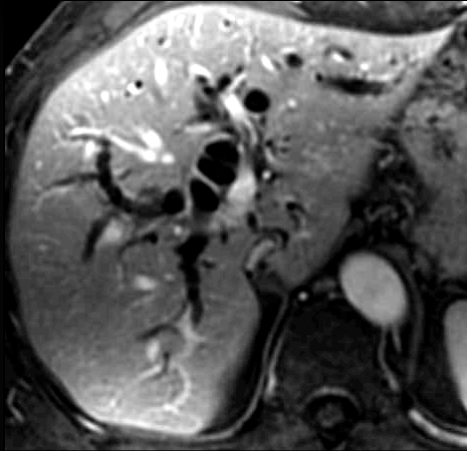




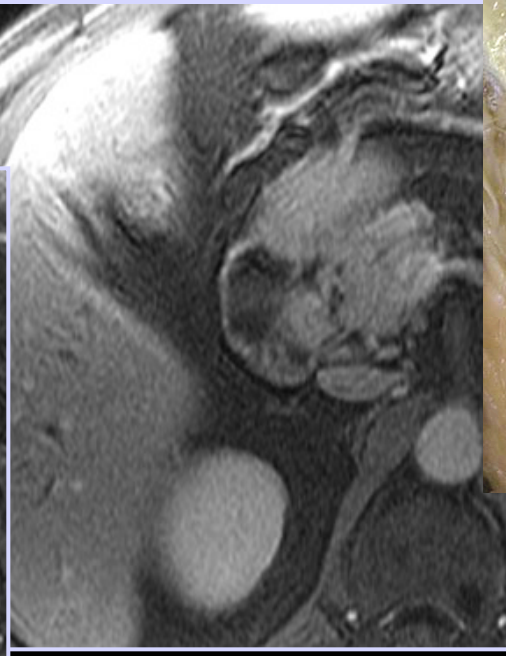
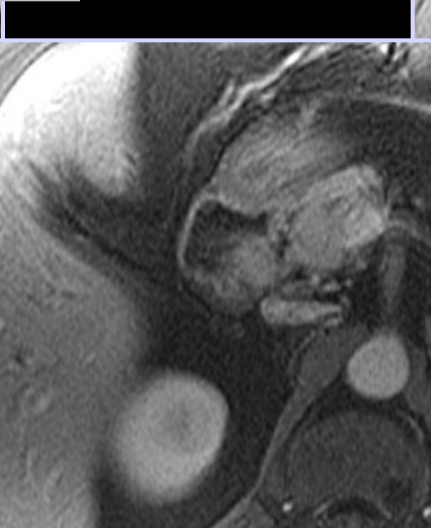
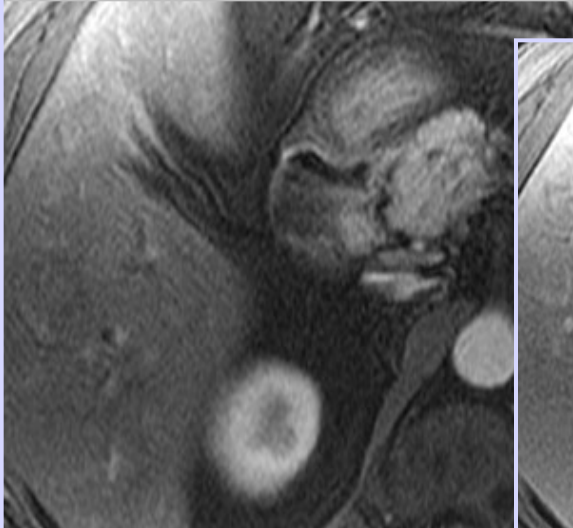
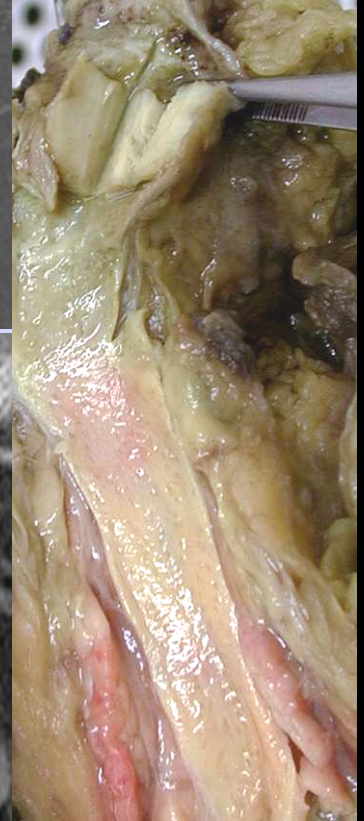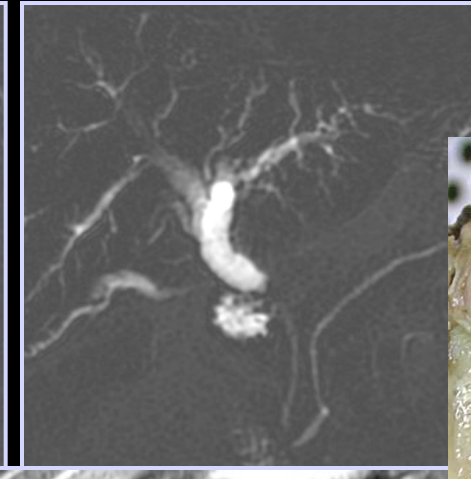
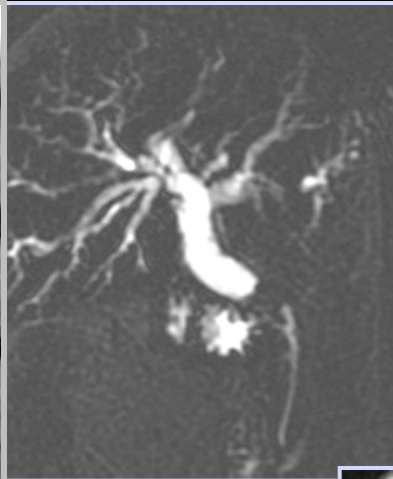
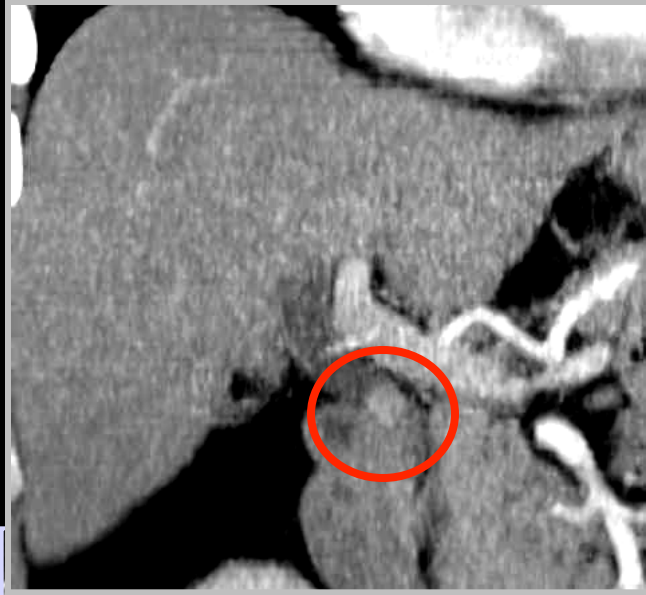
Papillome



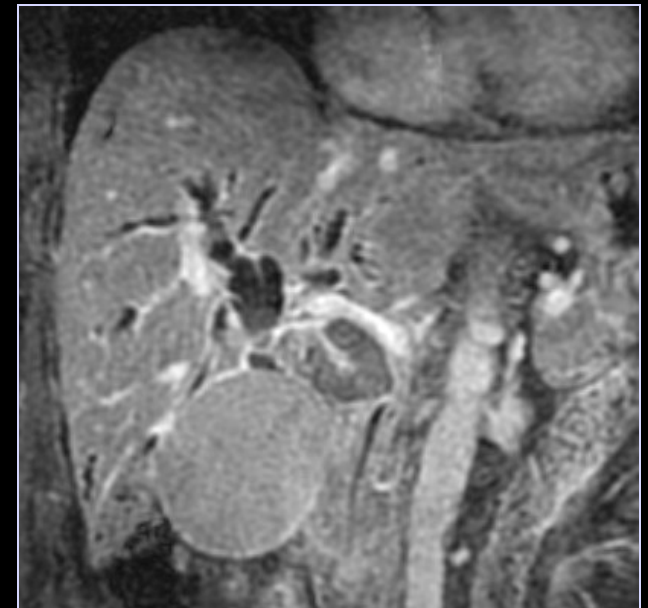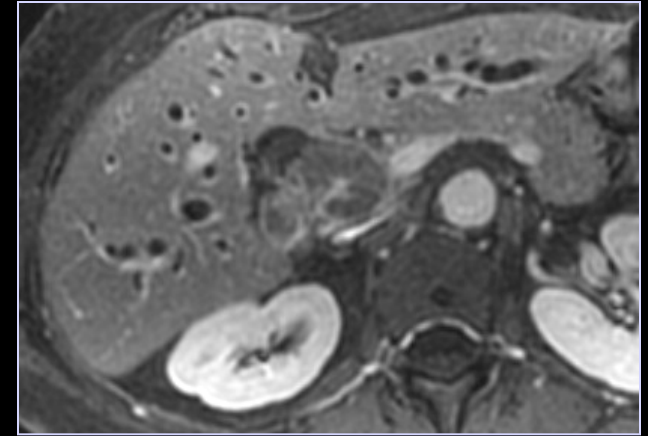
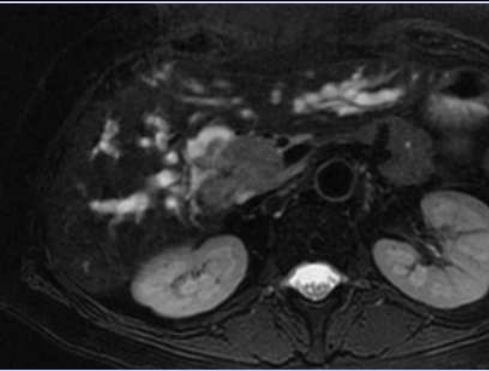
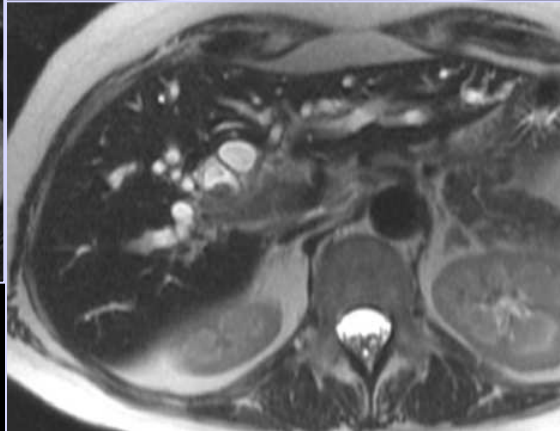
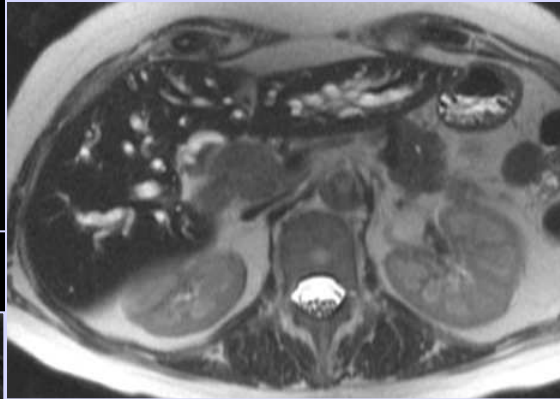
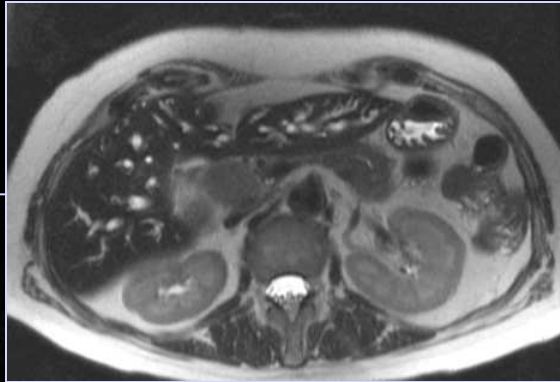
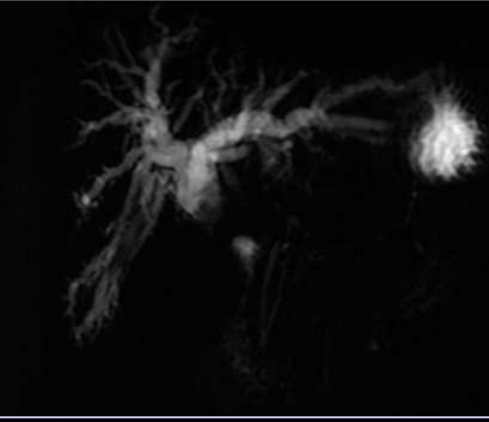
## Papillome



# Tumeurs endobiliaires rares



## Papillomatose

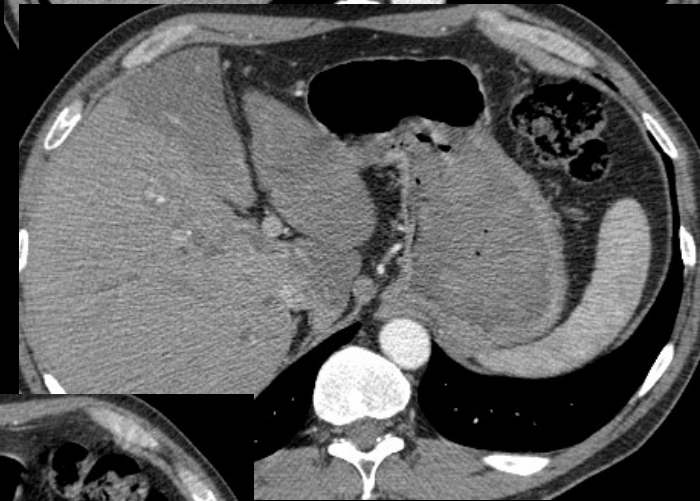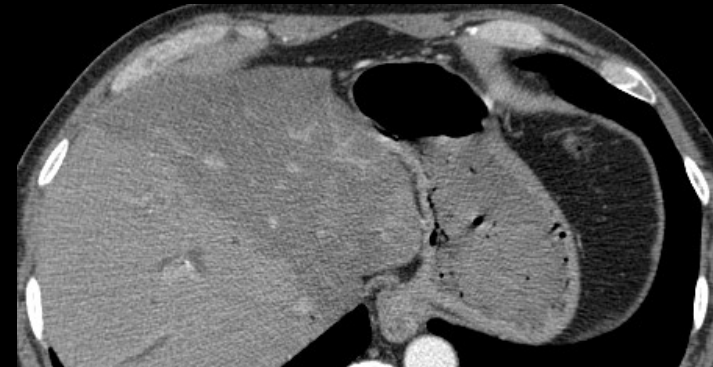
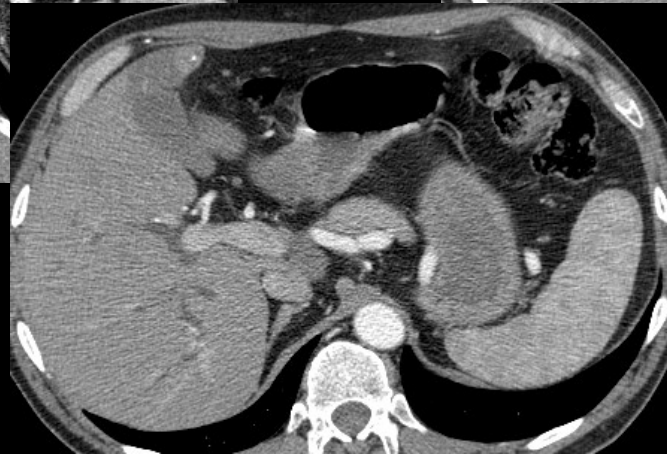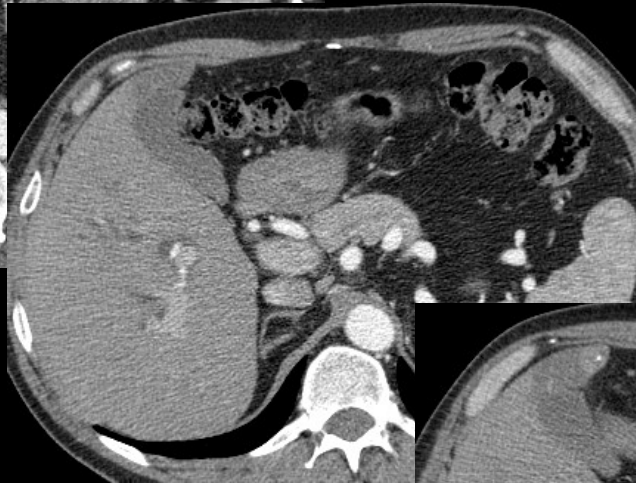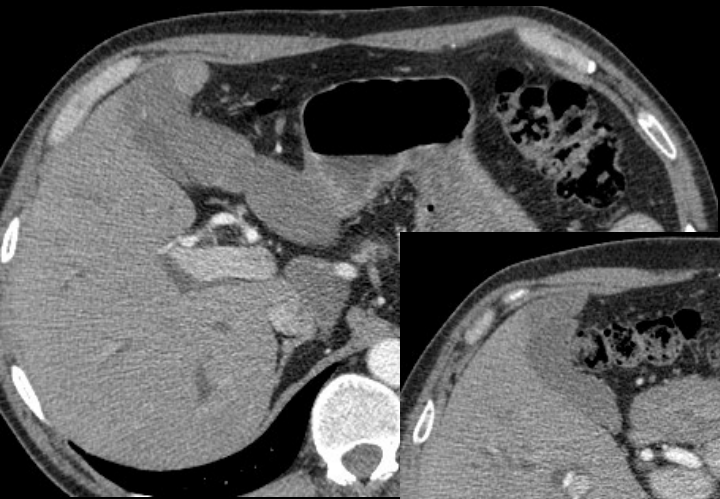


Homme 56 ans

Ictère associé à un prurit majeur

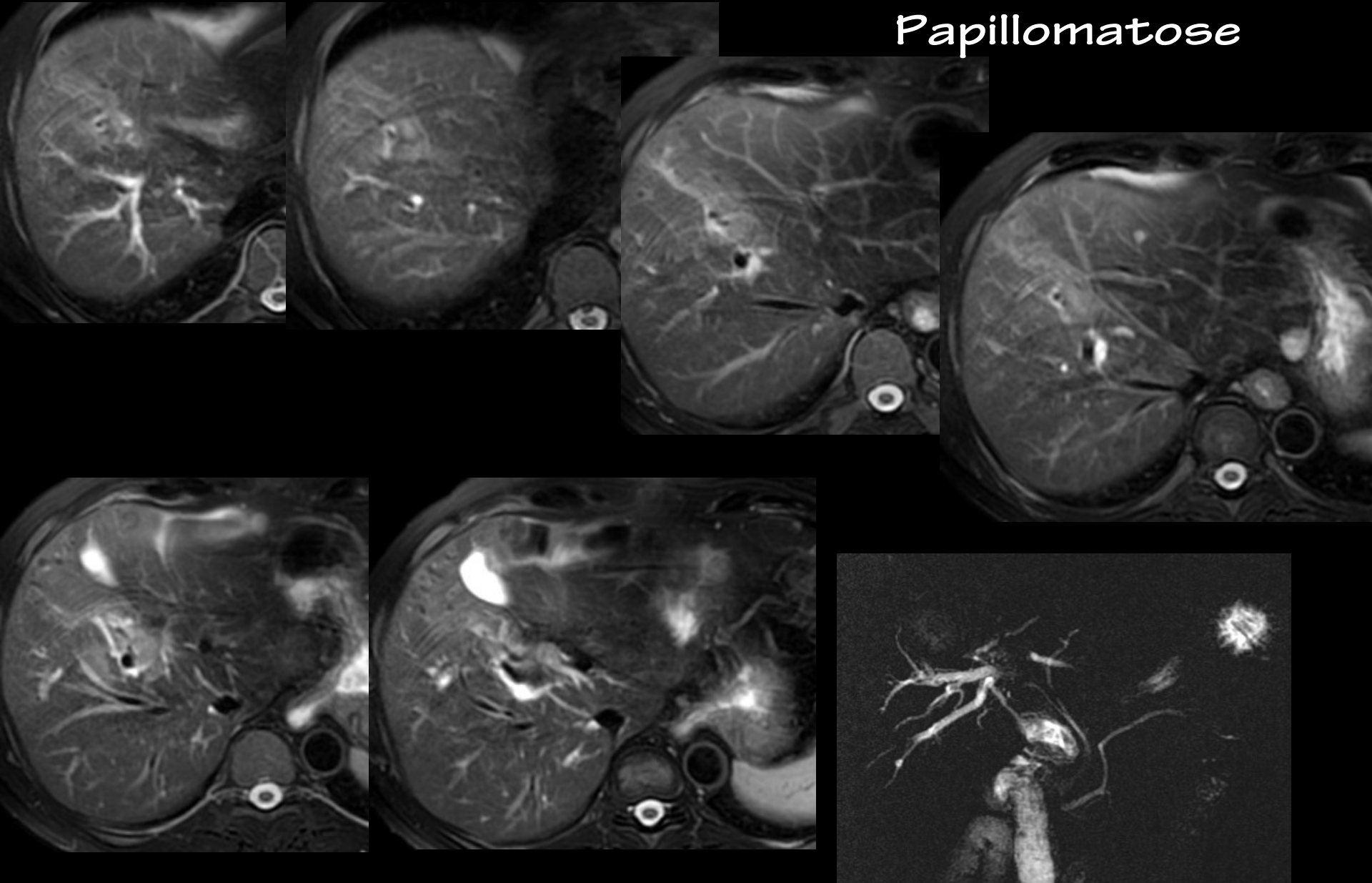
Topographie obstacle ? Nature ?

*Papillomatose*

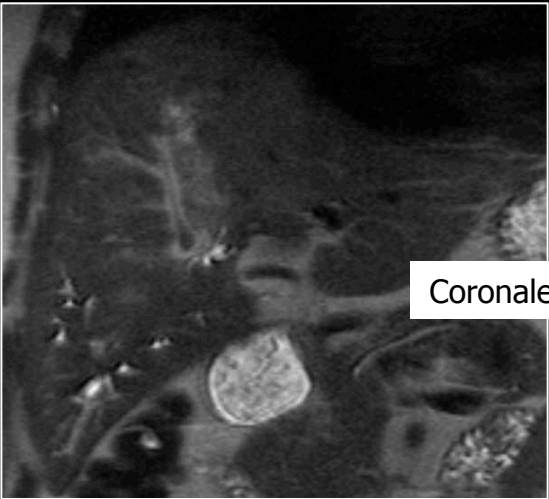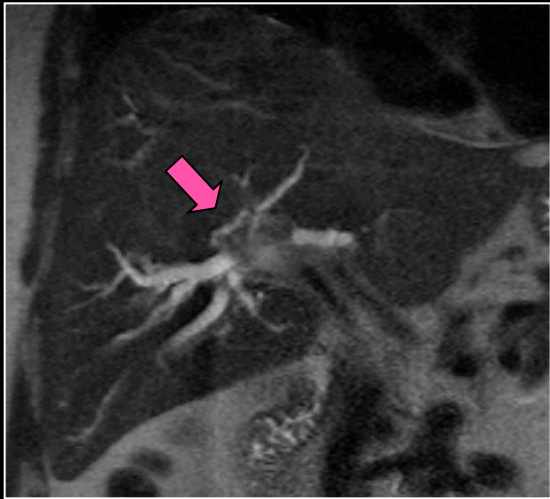


# Tumeurs endobiliaires rares

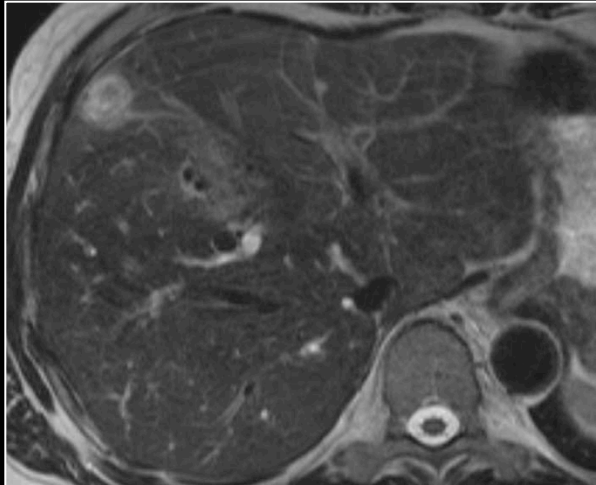
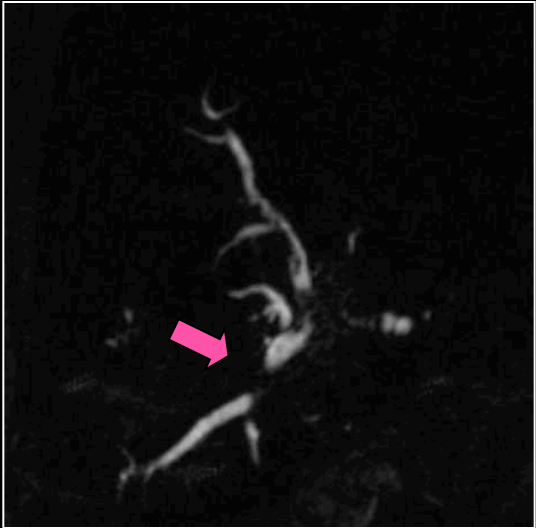
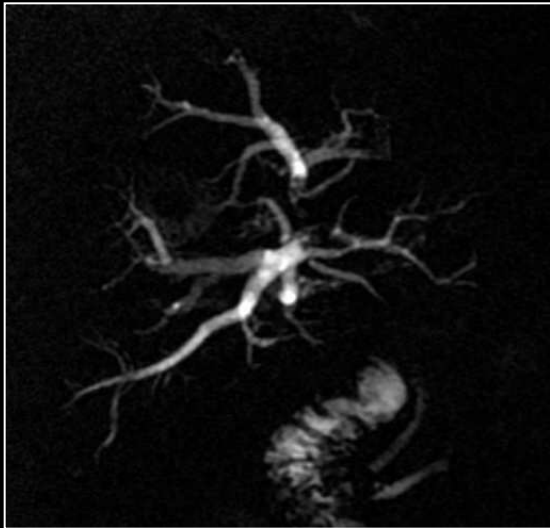
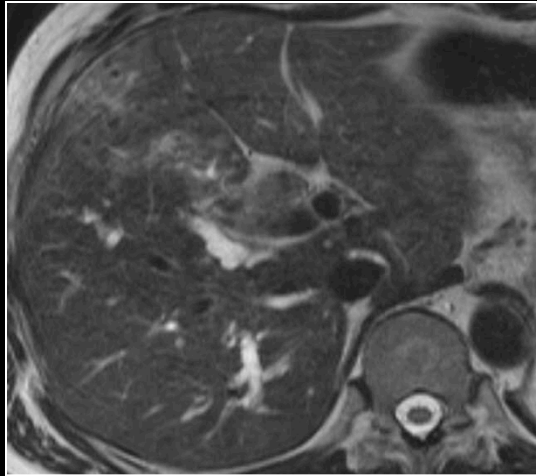
## Papillomatose



## Papillomatose

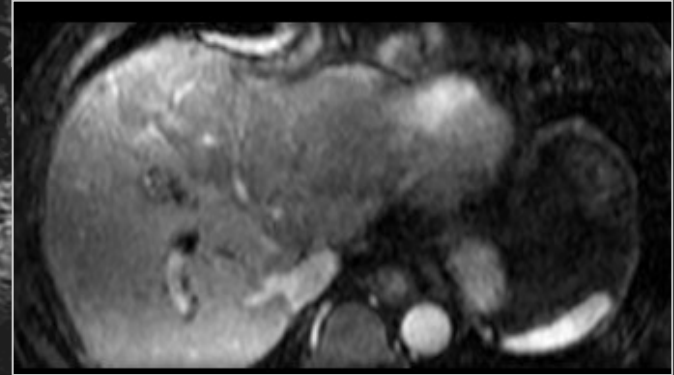
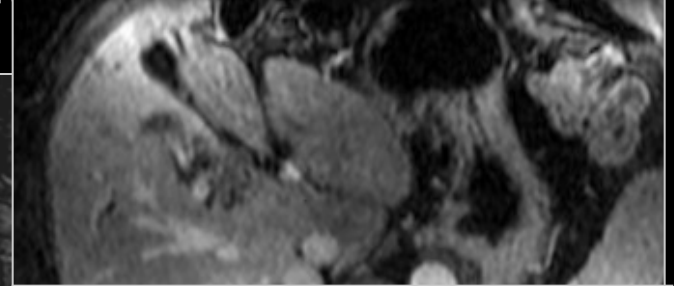
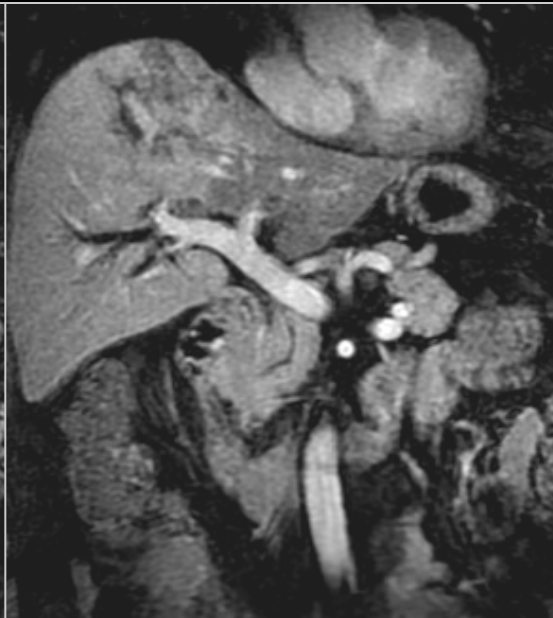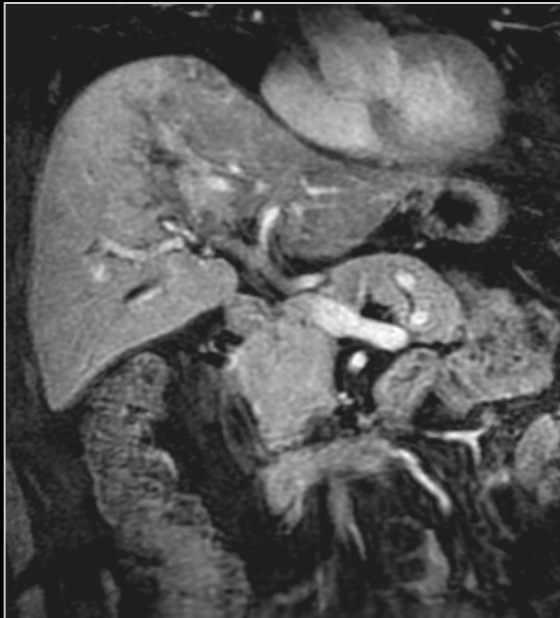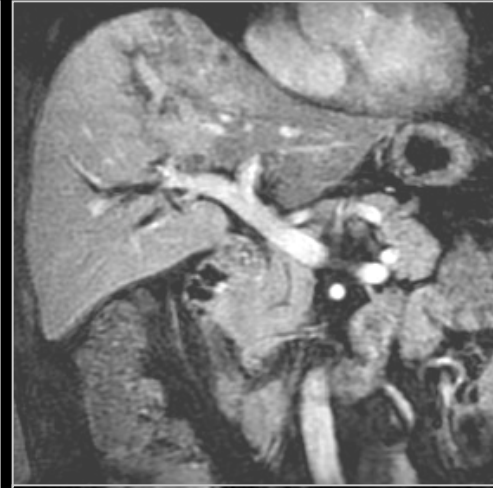


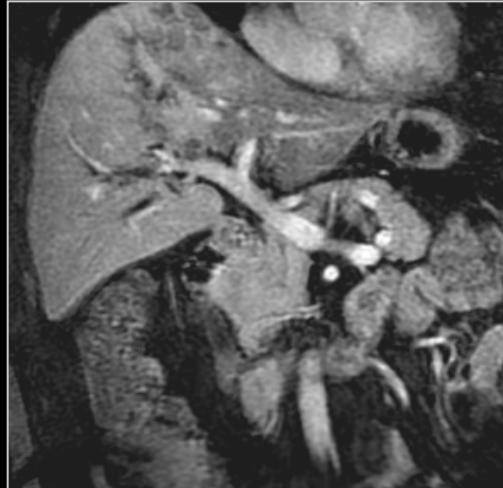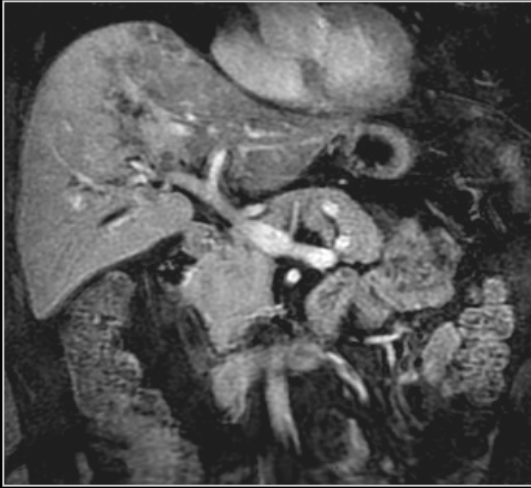Coronales T2

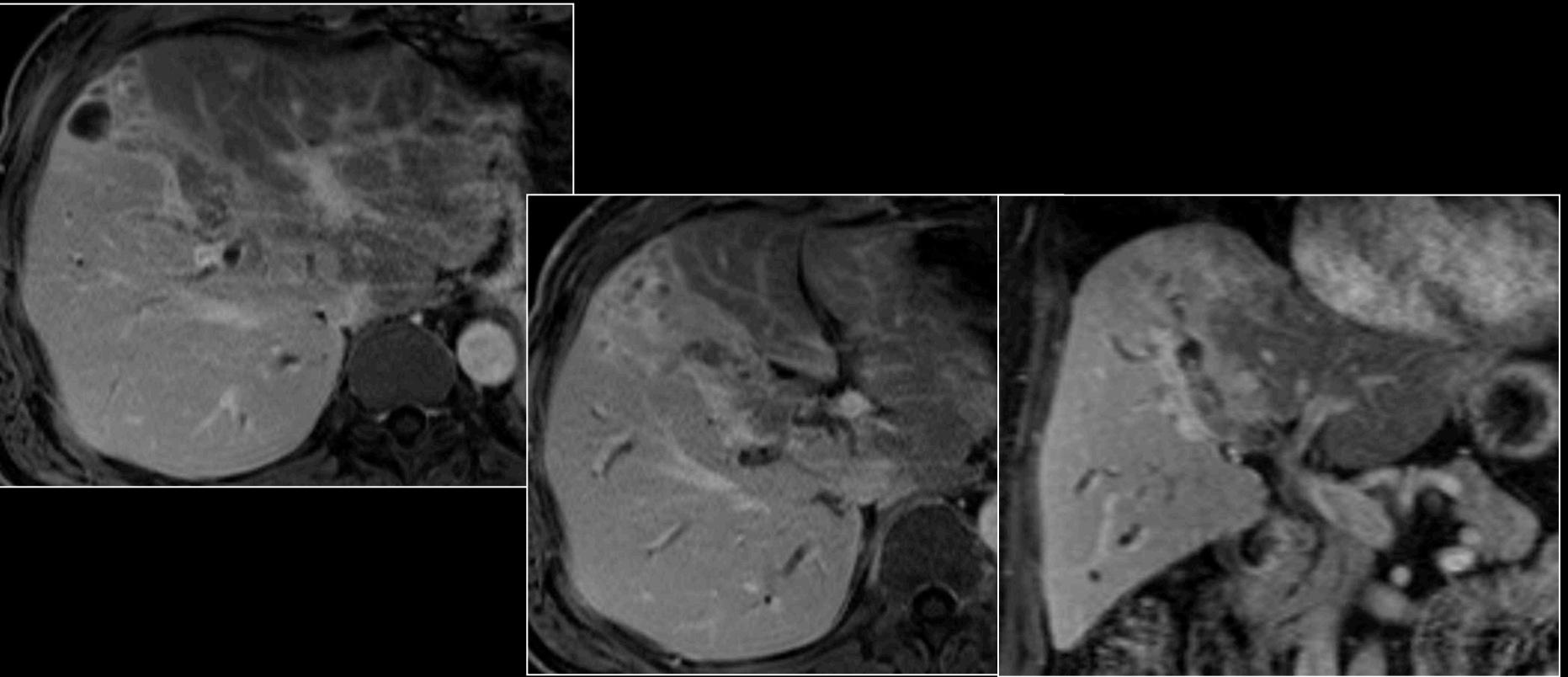


Radiaires SSFSE T2 TE long

# Tumeurs endobiliaires rares



## Tumeurs endobiliaires rares



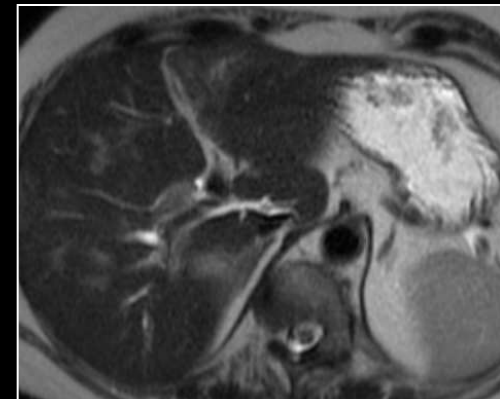
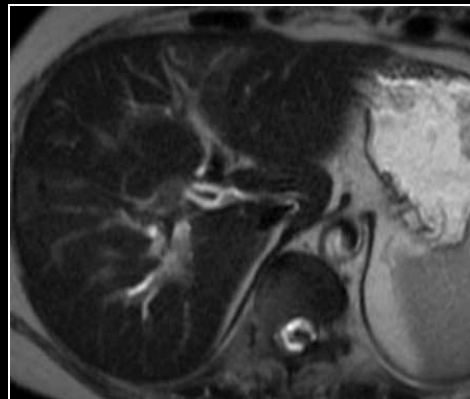
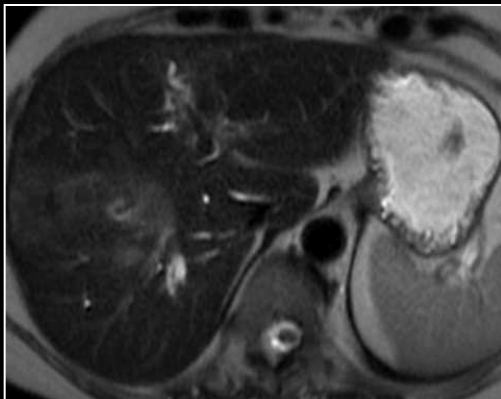
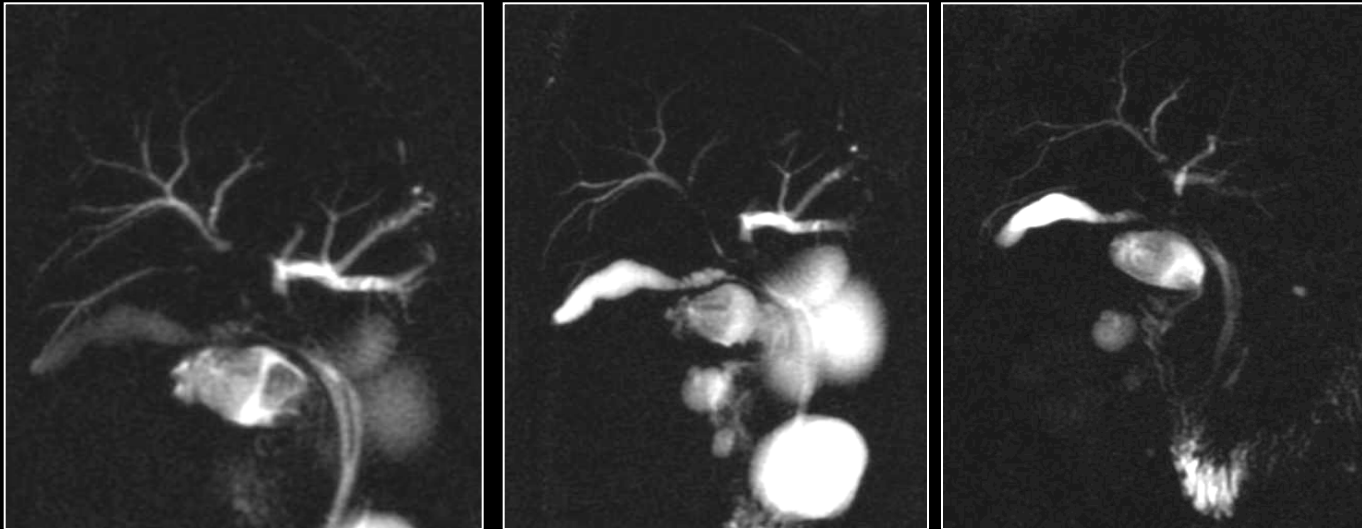
*Papillomatose avec foyers de carcinome in situ*

Le patient a bénéficié d'une transplantation hépatique

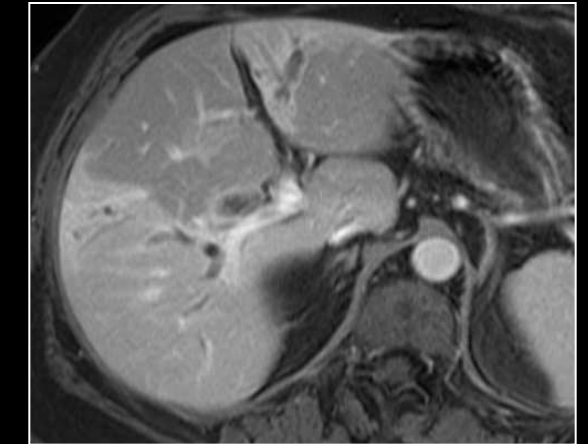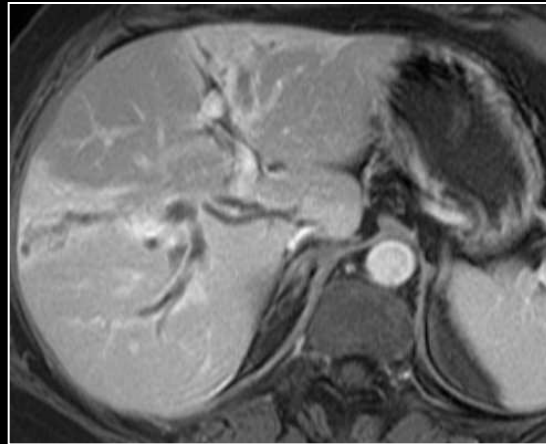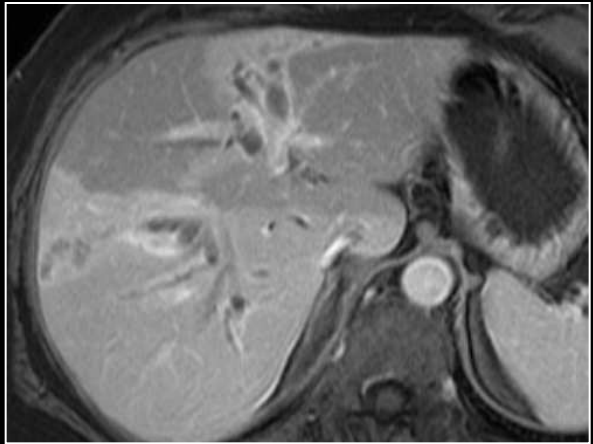
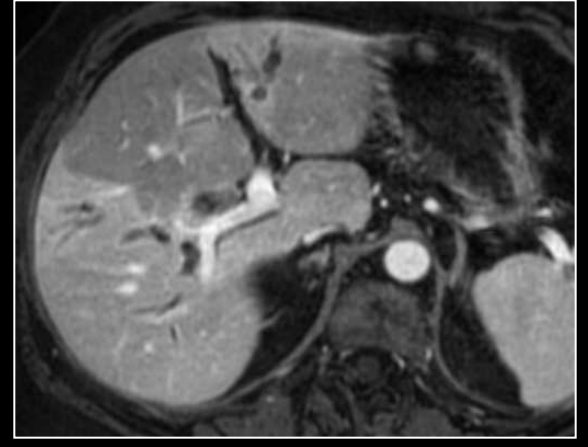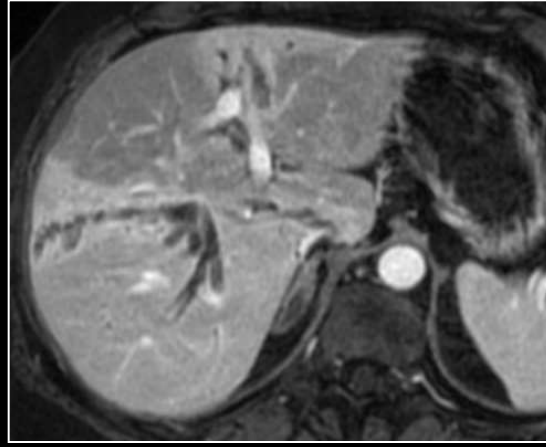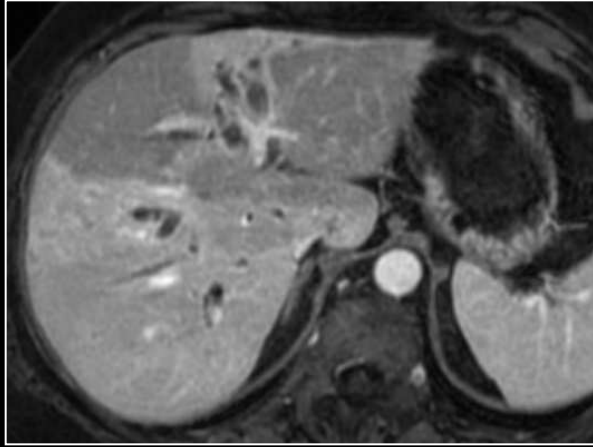
# Tumeurs endobiliaires rares

Altération de l'état général et cholestase biologique chez une patiente opérée 3 ans auparavant d'un adénocarcinome colique.

La coloscopie est normale.

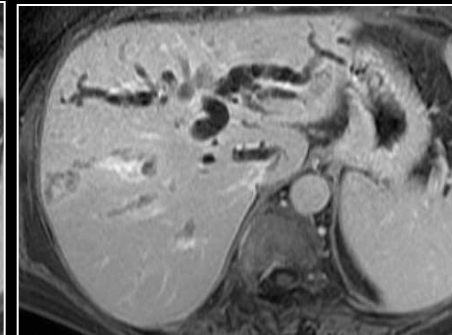
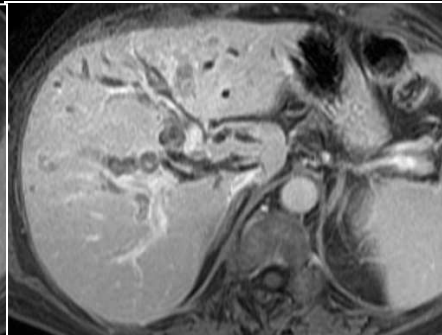
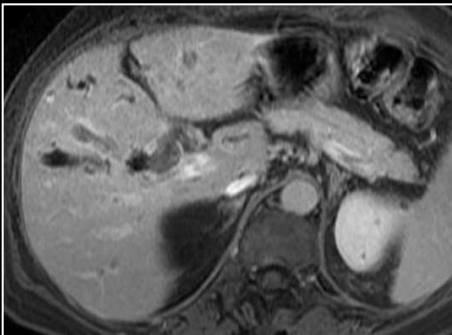
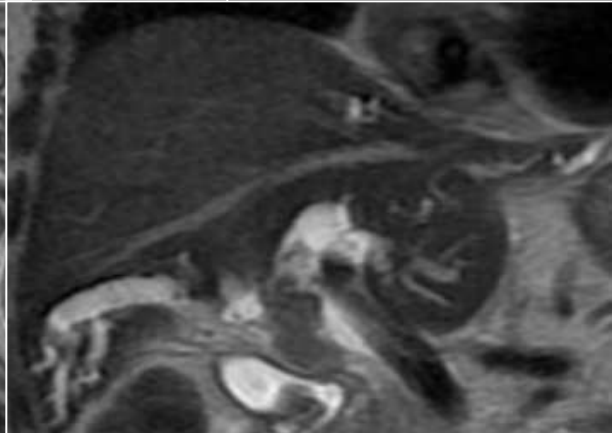
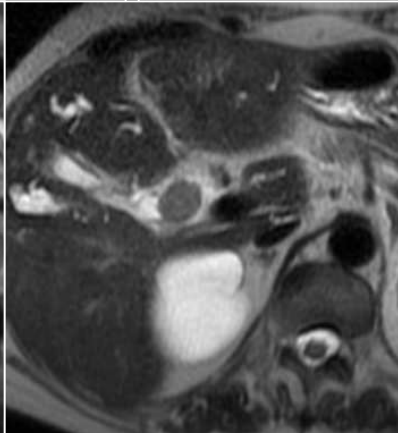
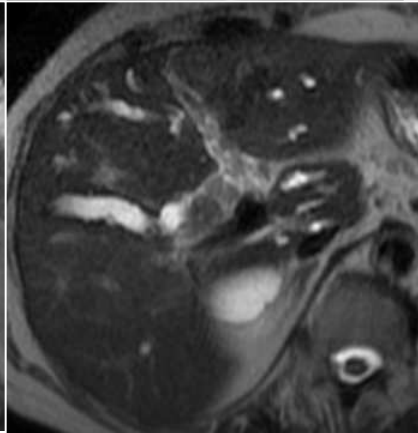
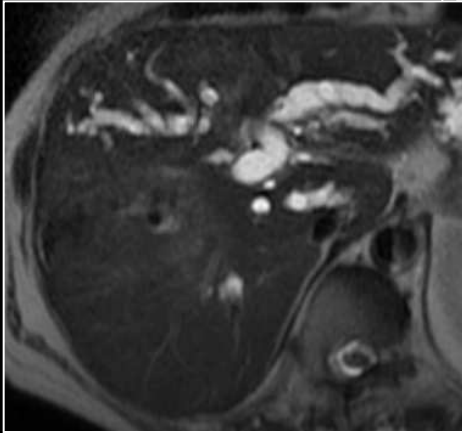
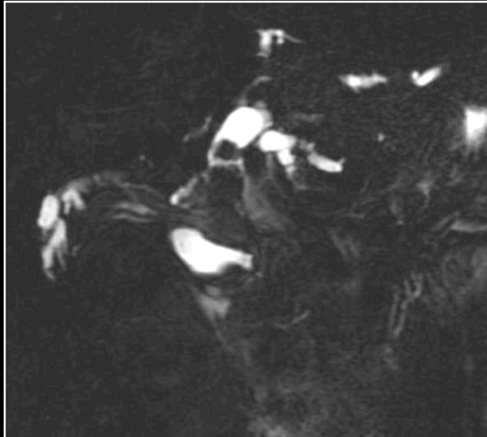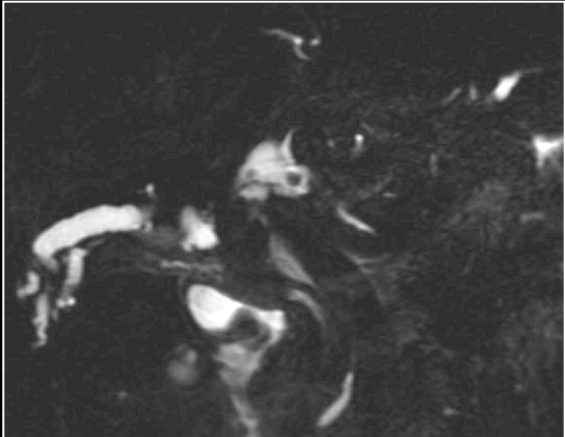
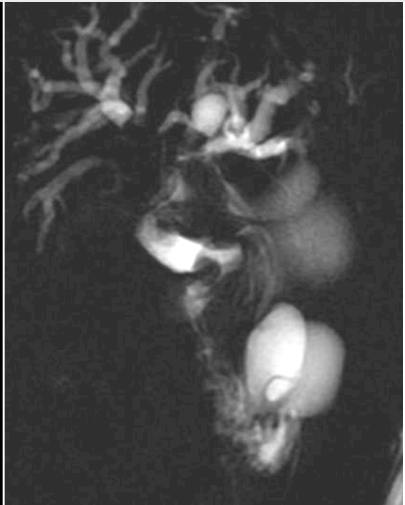


# Tumeurs endobiliaires rares



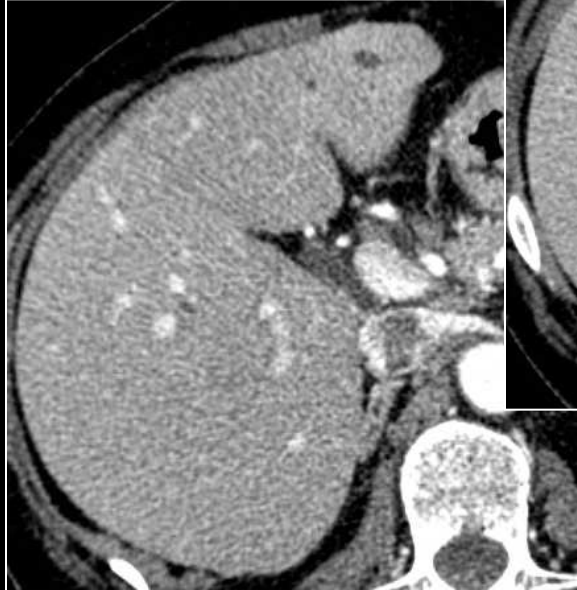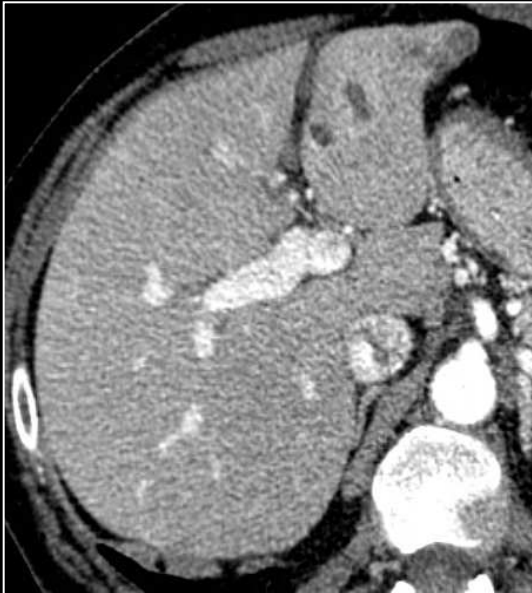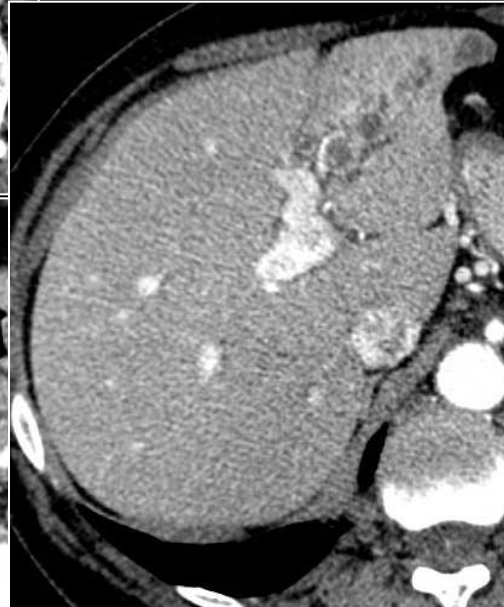
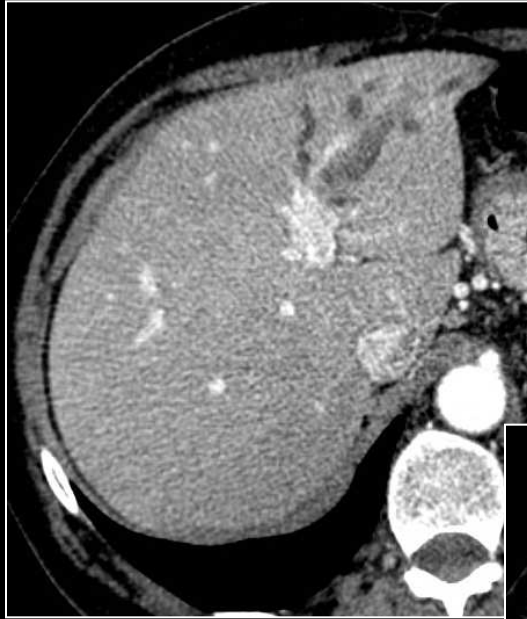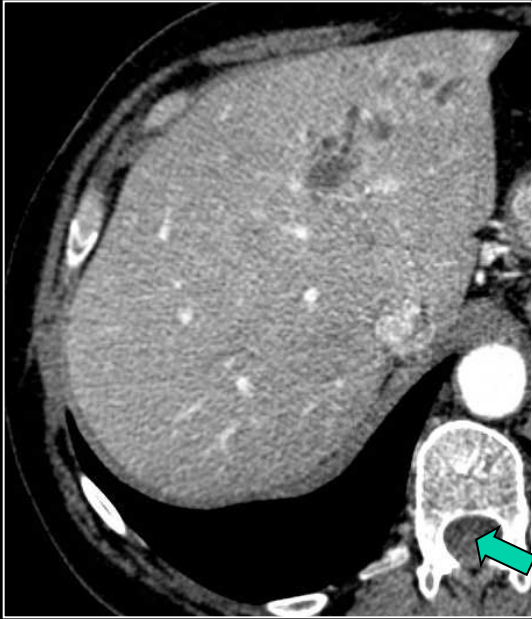Métastases endobiliaires

## Métastases endobiliaires

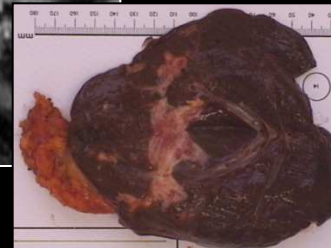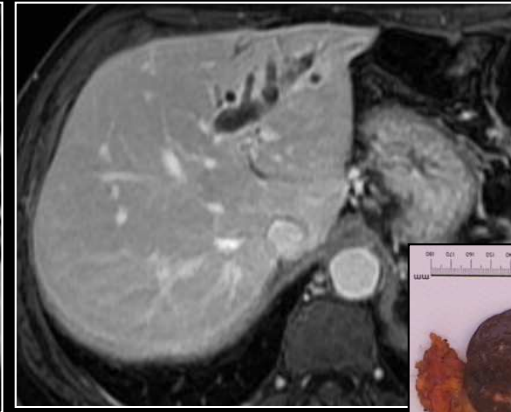
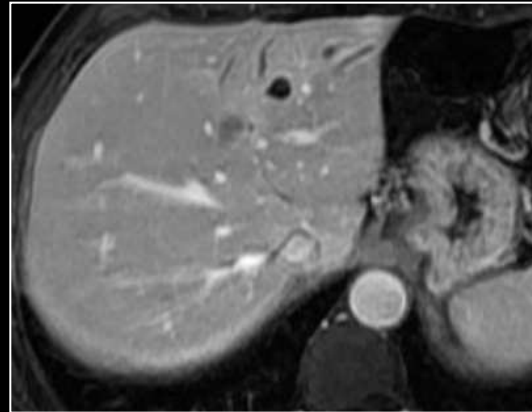
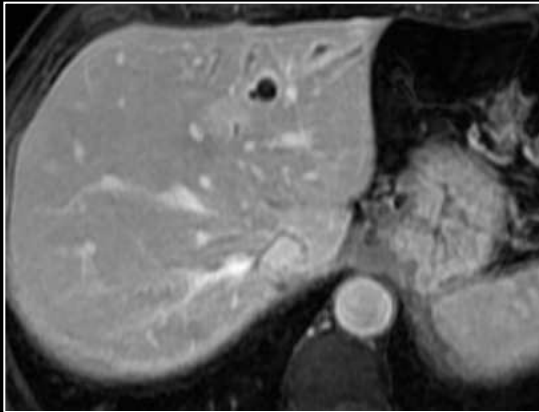
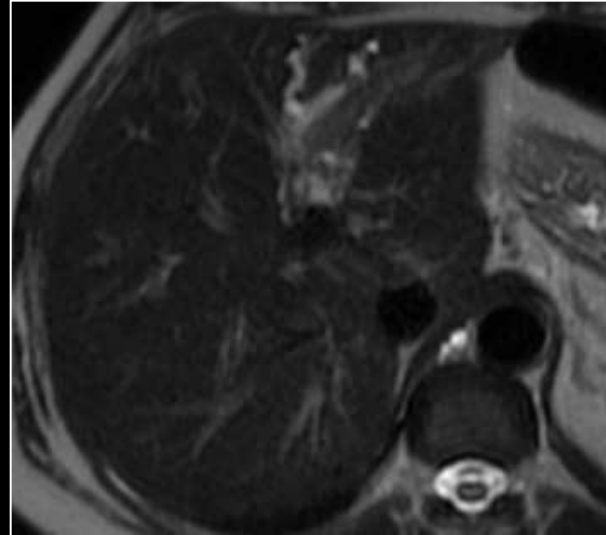
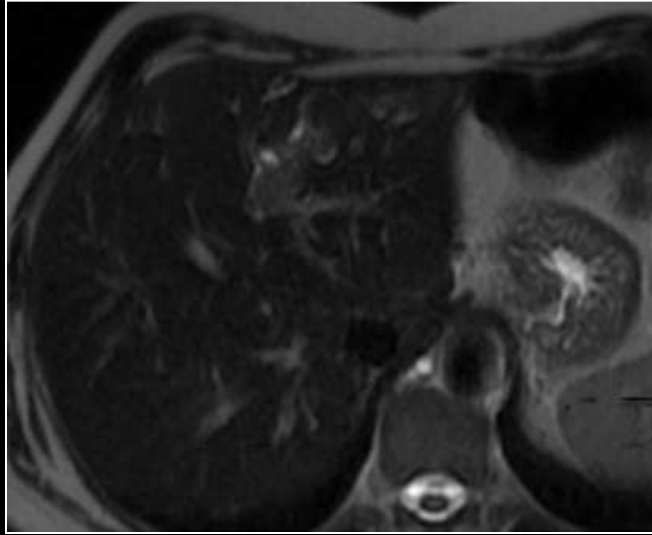


# Tumeurs endobiliaires rares

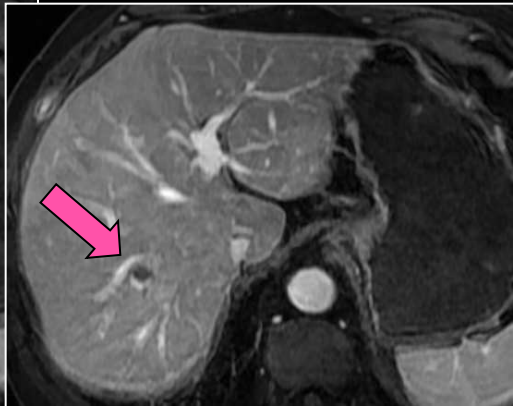
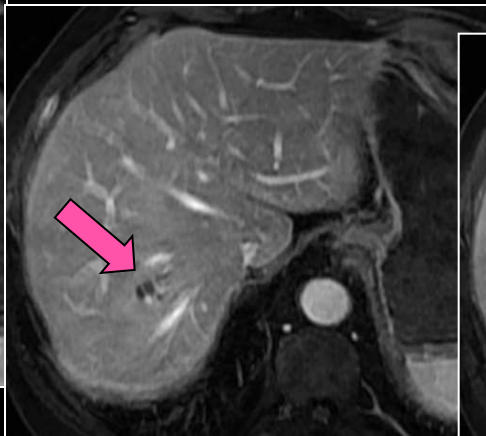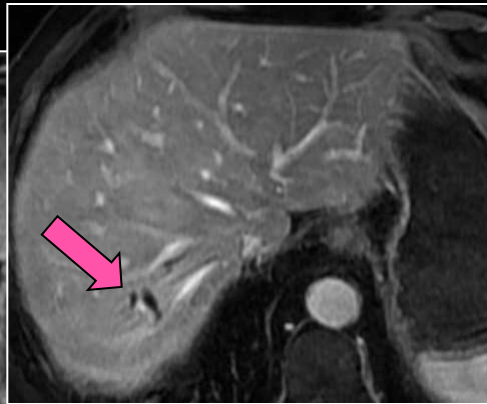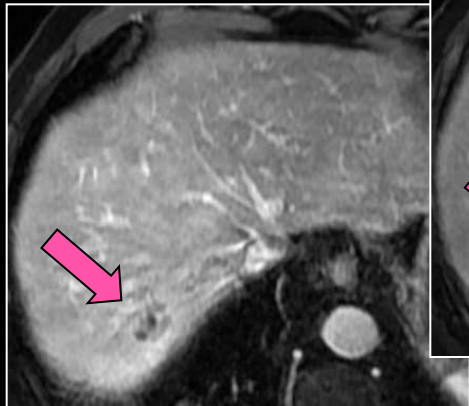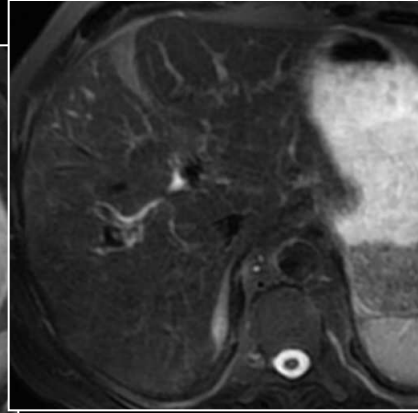
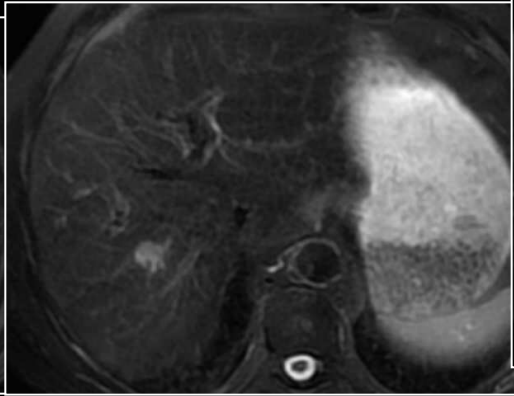
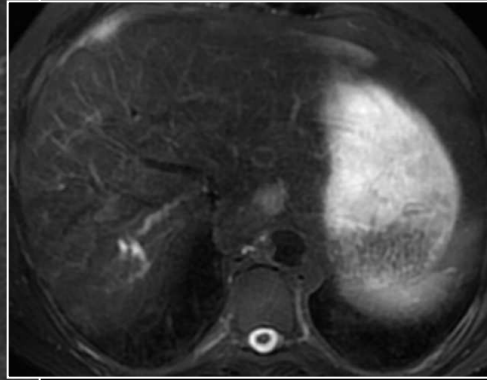
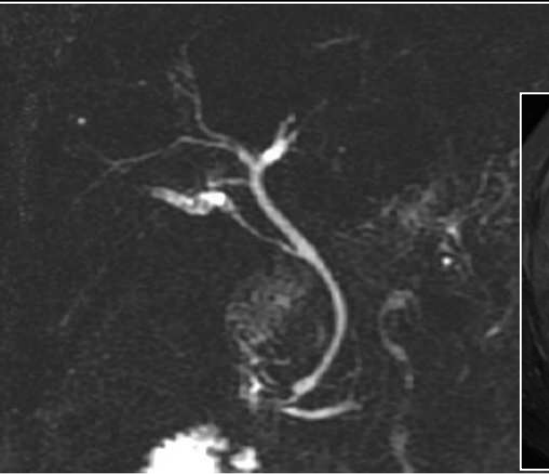
Altération de l'état général et cholestase biologique chez une patiente opérée 5 ans auparavant d'un ADK rectum



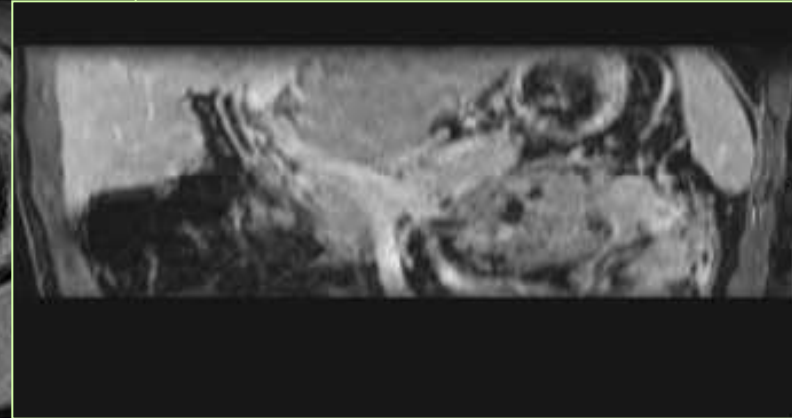
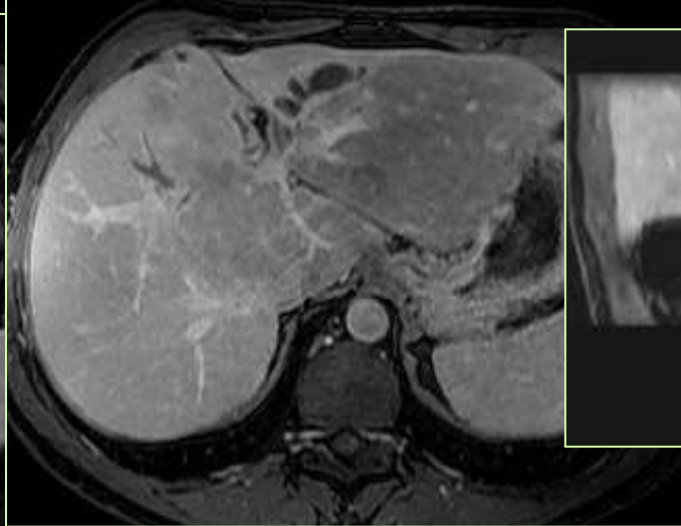
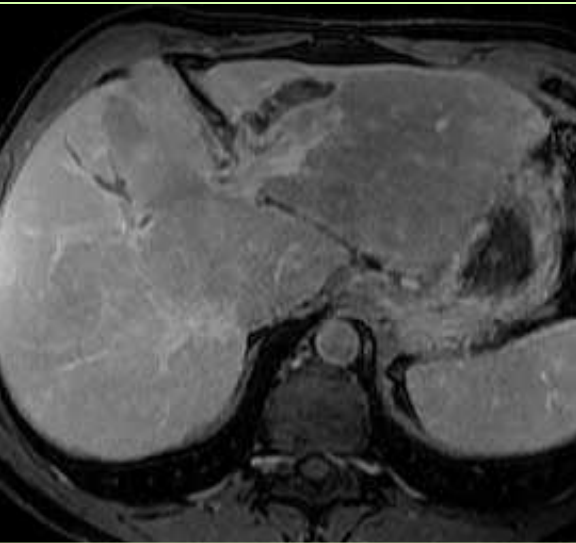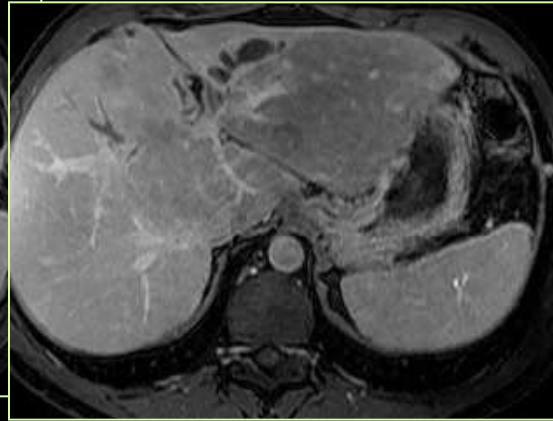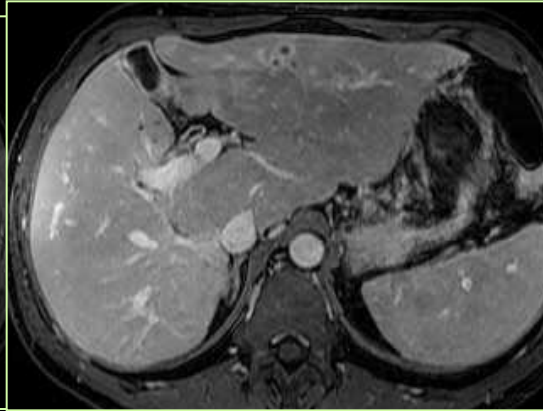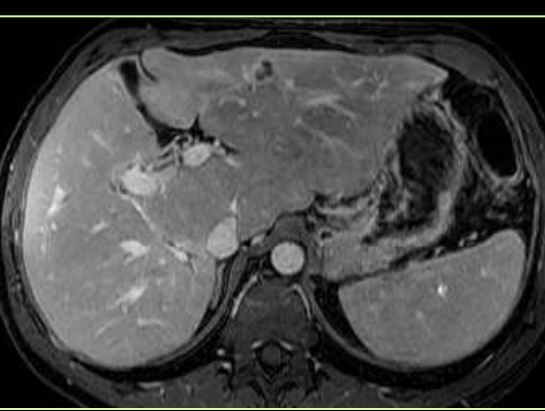
## Métastases endobiliaires



## Métastases endobiliaires



Métastases endobiliaires



# Conclusion

- **Masse hép centrée par la vésicule avec extension hilare**
  - CCK vésiculaire
  - FDR : Long common channel
- **Epaississement irrégulier de la paroi vésiculaire**
  - CCK vésiculaire infiltrant
- **Masse IH : CCK IH**
  - Fibrose : temps tardifs +++
  - FDR : CSP
- **Obstacles de la VBP (hilaires et en dessous)**
  - Eliminer Causes extrinsèques bénignes et malignes
  - Sténose hilare infiltration pariétale VB : CCK

**Tout n' est pas du cancer !!!!! .....**