

Tumeurs malignes des Voies Biliaires

Valérie CROISE-LAURENT

Plan

- **Tumeurs de la vésicule biliaire**
- **CCK IH**
- **CCK hilaires**
 - Diagnostic positif
 - Bilan d'extirpabilité
- **Tumeurs du bas cholédoque**

Points Clés

- Incidence : 2000 nvx cas/an (3% des cancers digestifs)
- Augmentation cste dans les pays occidentaux
- **Classification :**
 - Tumeurs de la vésicule biliaire
 - Cholangiocarcinomes intra-hépatiques
 - Cholangiocarcinomes extra-hépatiques
 - Hilaires : Tumeur de Klatskin (60%)
 - De la voie biliaire principale (25%)

Macroscopie

Masse Intraparenchymateuse
(« Mass forming »)

Infiltration canalaire
(« Periductal infiltrating »)

Prolifération tumorale
endocanalaire
(« Intraductal growth »)

Aspects en Imagerie

Cholangiocarcinome
intrahépatique

Cholangiocarcinome hilaire

Cholangiocarcinome EH

Microscopie

– ADK glandulaires

– ADK glandulaires

– ADK papillaires

Une dénomination commune mais

	Tumeurs de la vésicule	CCK IH	CCK hilaires	CCK de la VBP
FDR	Calculs Long common channel	CSP Hépatopathies Maladies biliaires congénitales	CSP	
Circonstances de découverte	Fortuite Masse segment V	Masse	Ictère	Ictère
Aspects en imagerie	Infiltration diffuse paroi Masse	Masse parenchymateuse	Infiltrante Polypoïde	Infiltrante Polypoïde
Diagnostics différentiels	CCK IH Métastase	LFH	Mirizzi, CSP, cholangite Causes néoplasiques extrinsèques	ADK pancréas...
Preuve du cancer	Possible	Possible	Non (Cytologie sur brossage)	Echoendo.
Stratégie thérapeutique	Cholécystectomie +/- bi ou trisegmentectomie Ou hépatectomie drte élargie au V	Réséction segments hép	Réséction biliaire et hépatique	DPC

Rôle majeur de

l'imagerie

Plan

- **Tumeurs de la vésicule biliaire**
- **CCK IH**
- **CCK hilaires**
 - Diagnostic positif
 - Bilan d'extirpabilité
- **Tumeurs du bas cholédoque**

I. Tumeurs de la vésicule biliaire

- **Masse intrahépatique centrée sur la vésicule**
 - Masse contours irréguliers
 - **Diagn. différentiels** :
 - CCK IH
- **Sténose hilaire avec masse, épicode collet vésiculaire**
 - Masse hilaire et dilatation VBIH ++++++
 - **Diagn. différentiels** :
 - CCK hilaire, obstacles hilaires
- **Infiltration diffuse ou localisée de la paroi vésiculaire**
 - Epaissement irrégulier diffus ou focal
 - **Diagn. Différentiels** :
 - Cholécystite chronique
 - Cholécystite xantho granulomateuse

Facteurs de risque

-Calculs

-Long common

Uchiyama et al. J Hepatobiliary
Pancreas Surg 2009

Yun EJ et al. Abdom Imaging 2004

Kim et al. AJR 2008

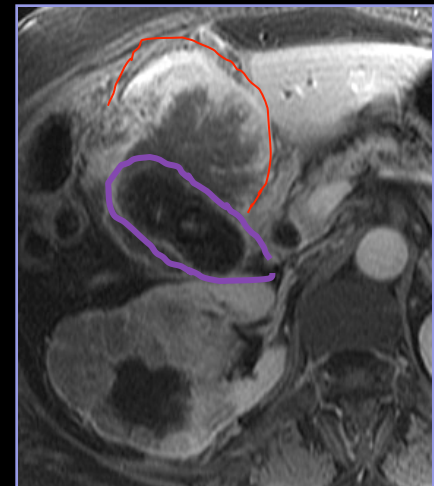
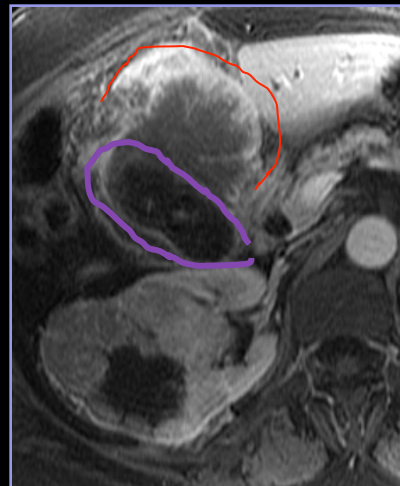
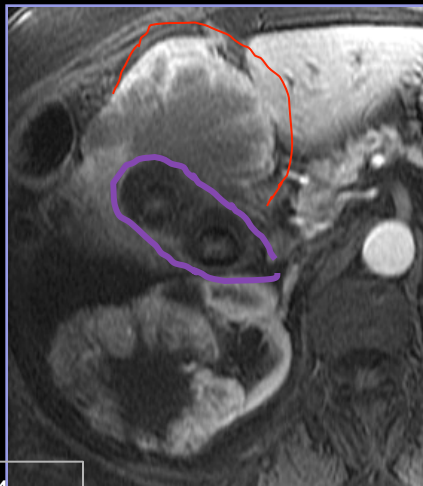
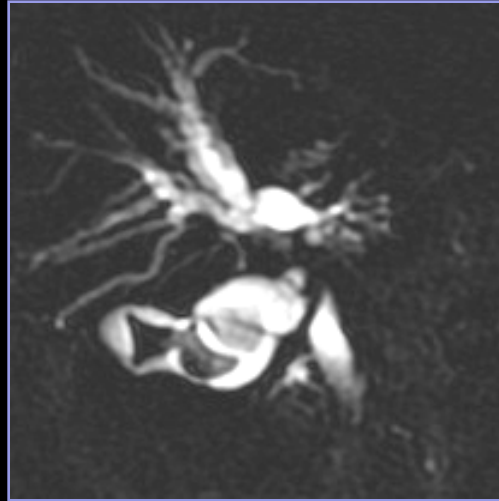
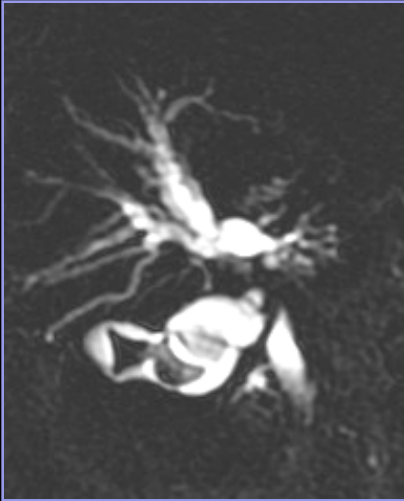
Lane et al. Radiographics 1989

Jung et al. Eur Radiol 2005

Choi et al. Abdom Imaging 2004

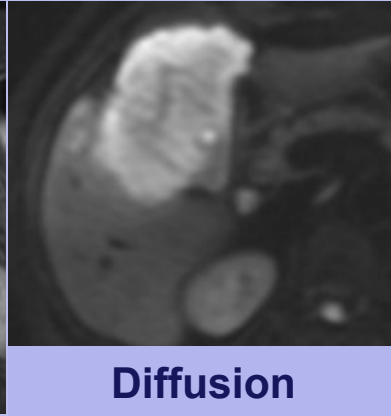
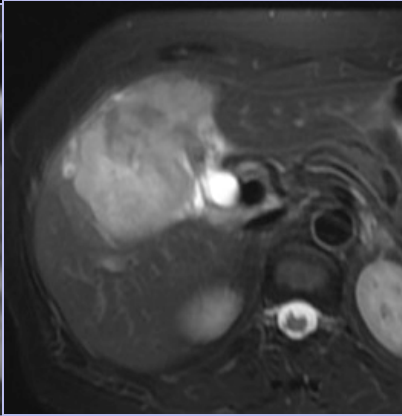
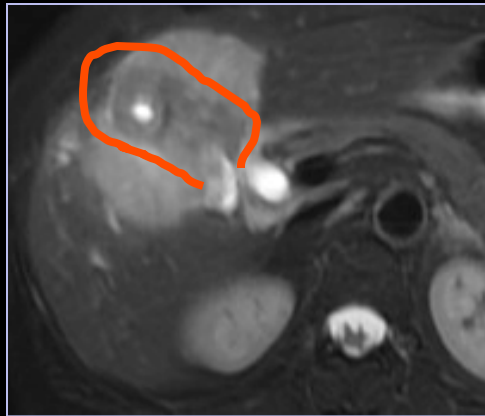
I. Tumeurs de la vésicule biliaire

1. Masse hépatique centrée sur la vésicule

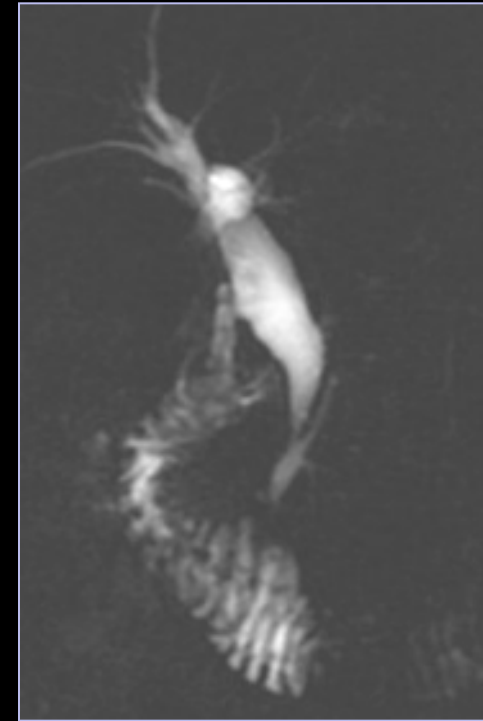
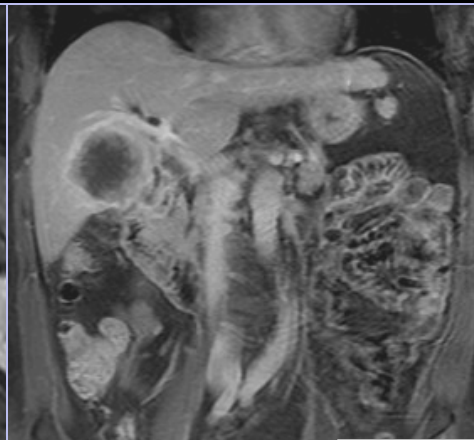
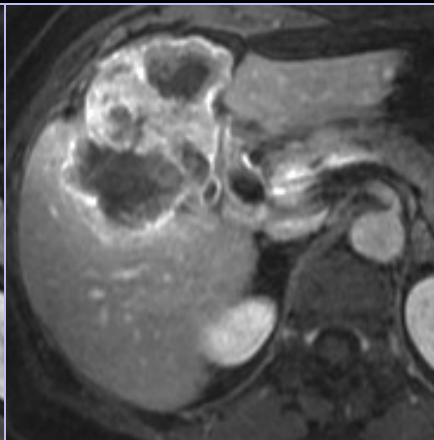
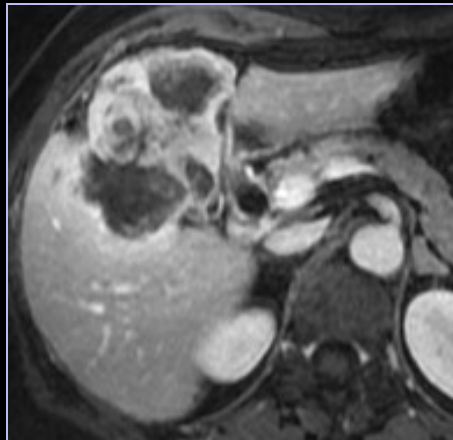


I. Tumeurs de la vésicule biliaire

1. Masse hépatique centrée sur la vésicule



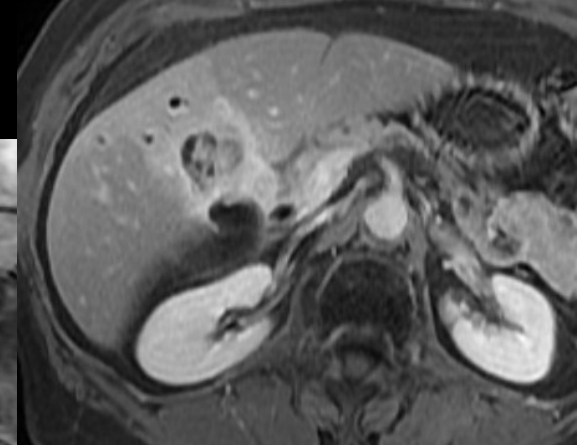
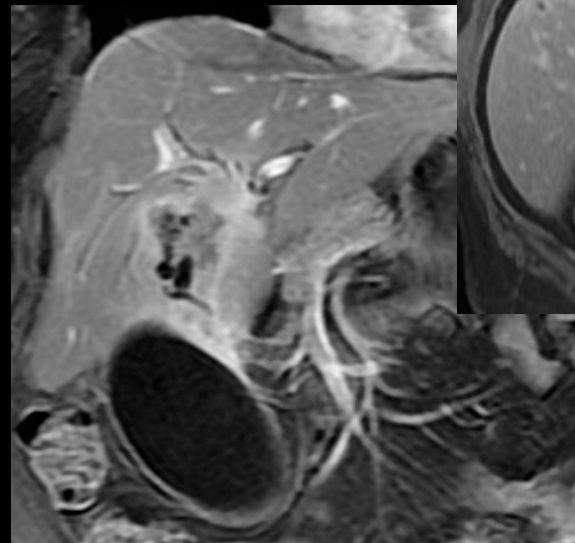
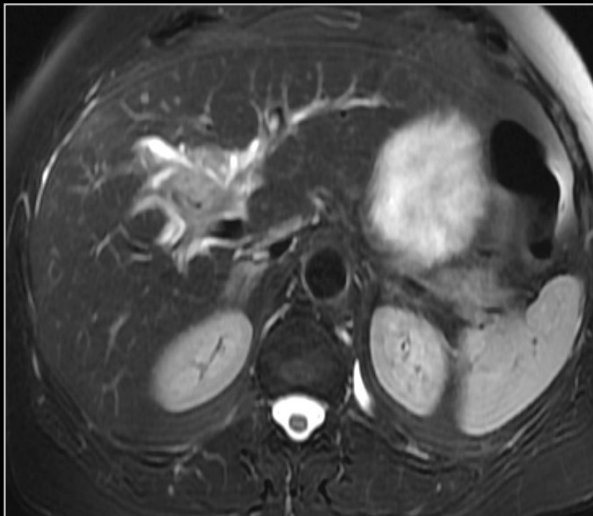
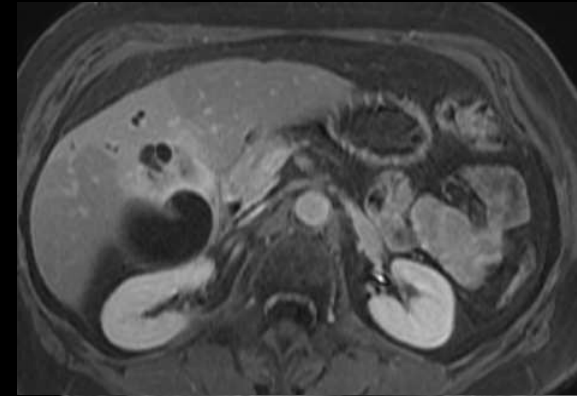
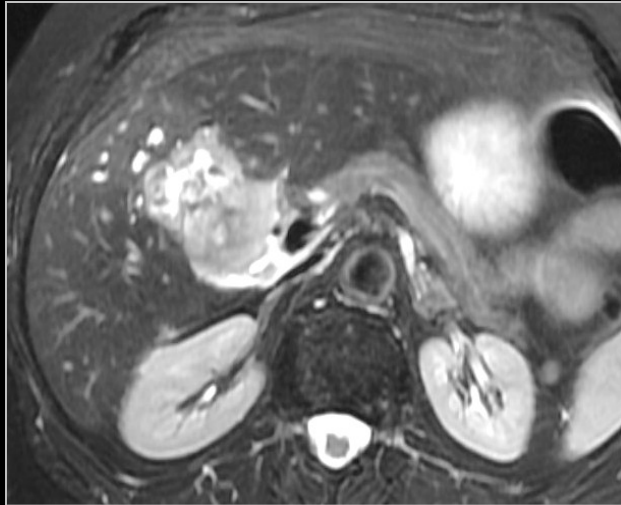
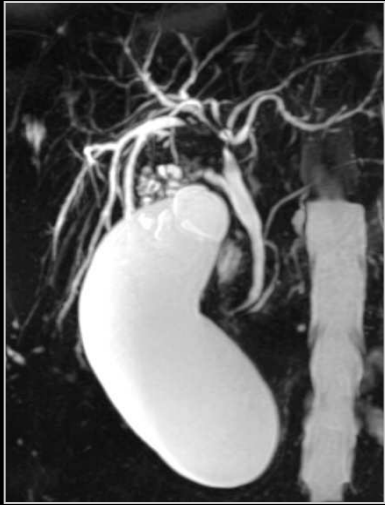Diffusion



Long common

I. Tumeurs de la vésicule biliaire

2. Sténose hilaire et masse

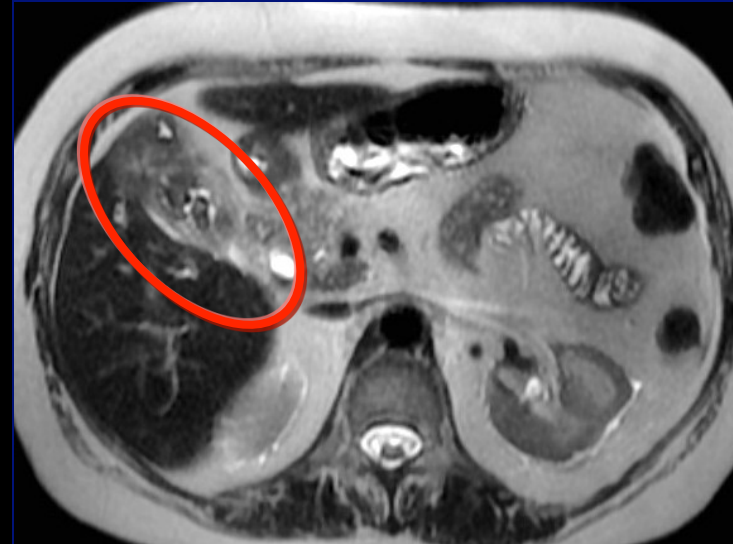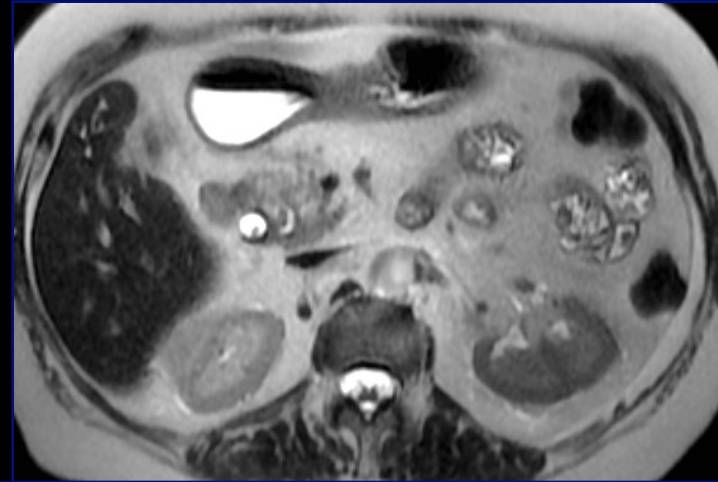
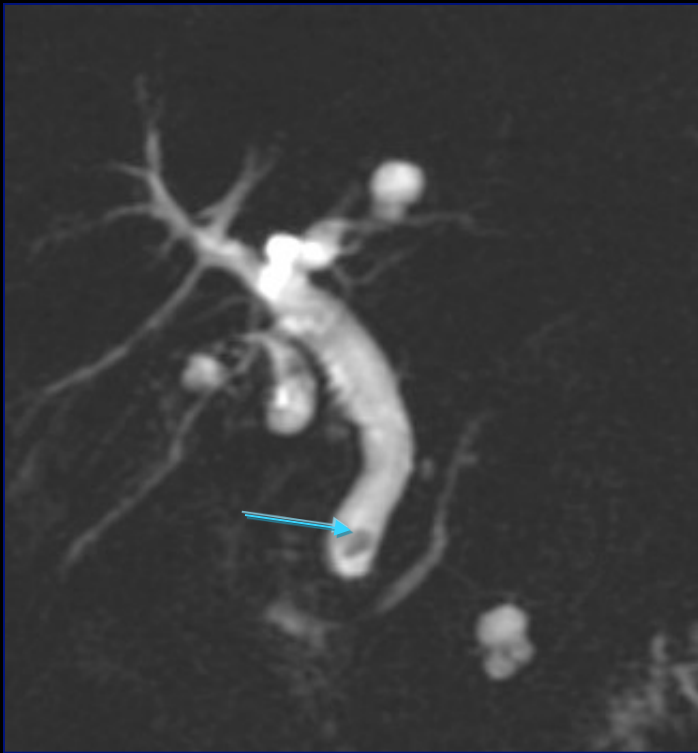


I. Tumeurs de la vésicule biliaire

3. Epaissement irrégulier diffus parois vésiculaires

Femme, 82 ans

Ictère, Cholestase biologique



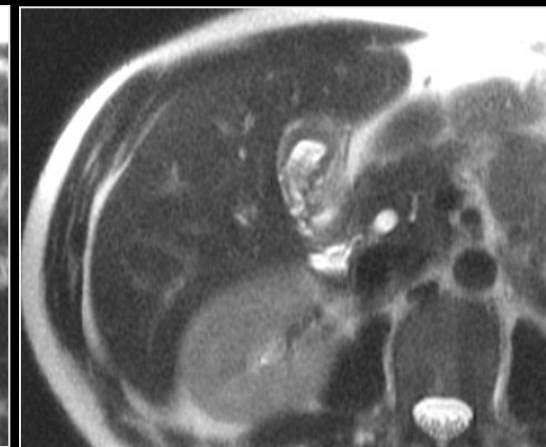
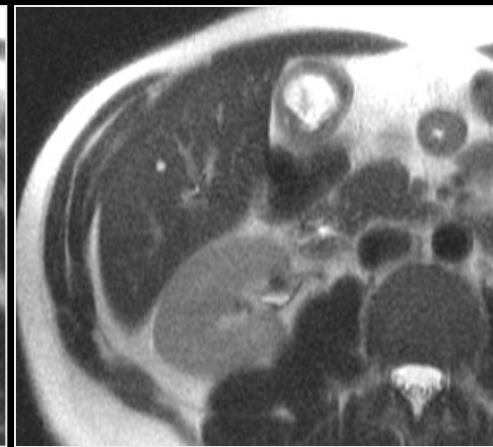
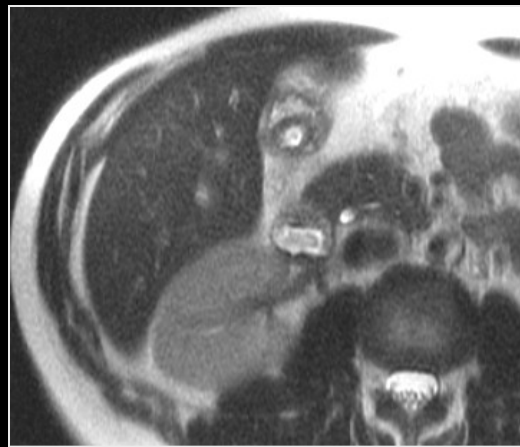
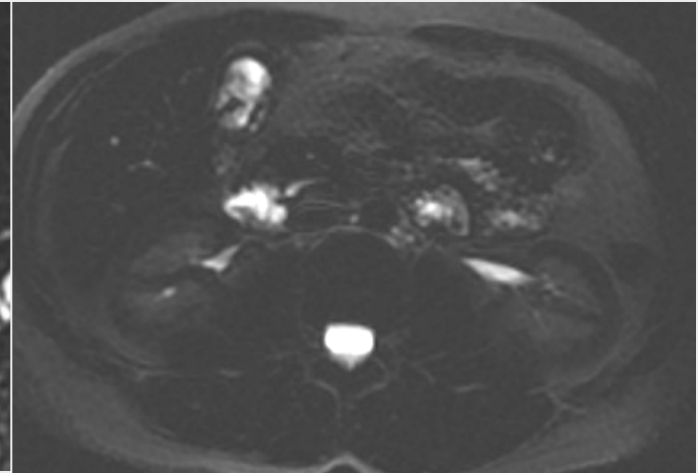
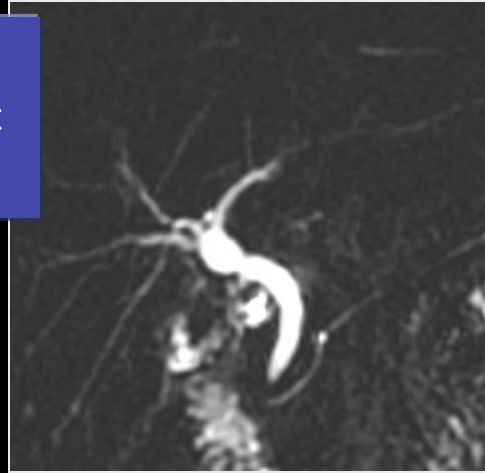
I. Tumeurs de la vésicule biliaire

3. Epaissement irrégulier diffus parois vésiculaires

Homme, 38 ans

Douleurs de l'hypochondre droit

Recherche de calculs VBP

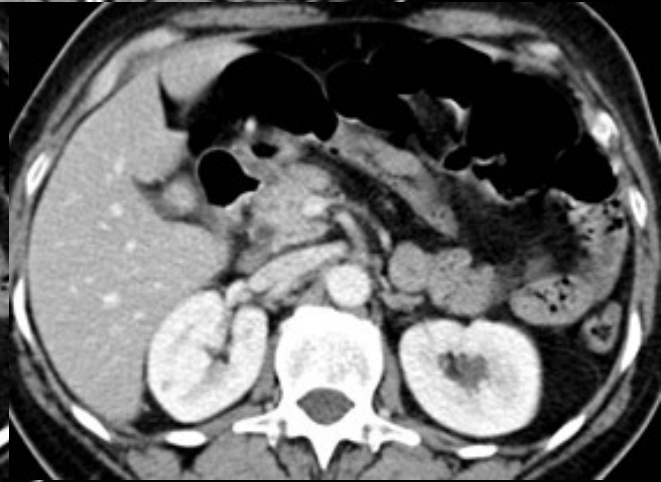
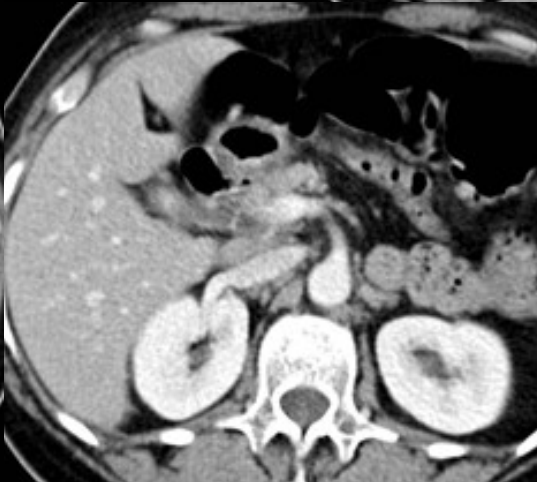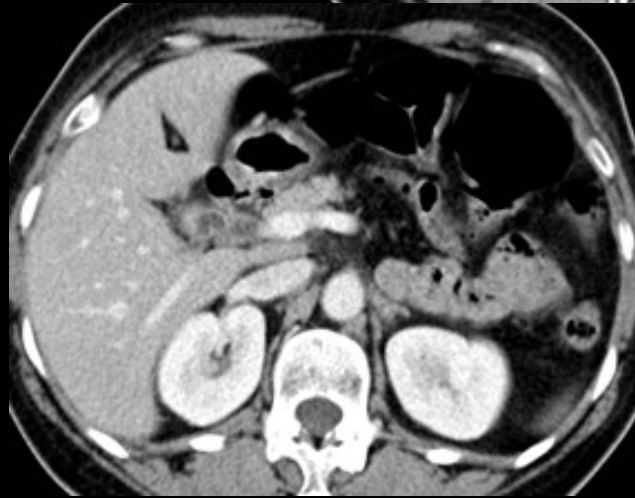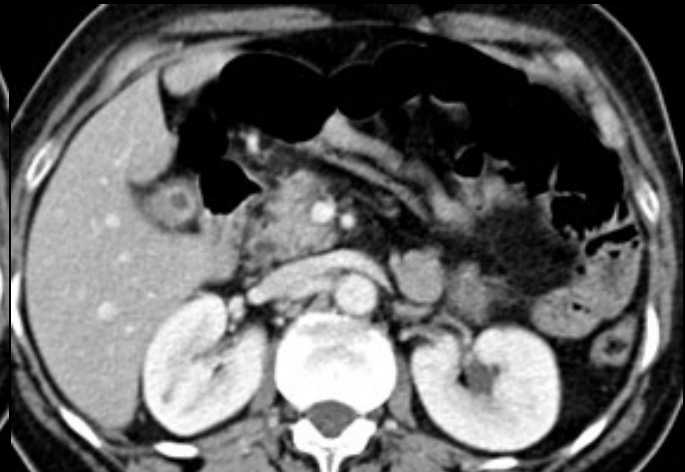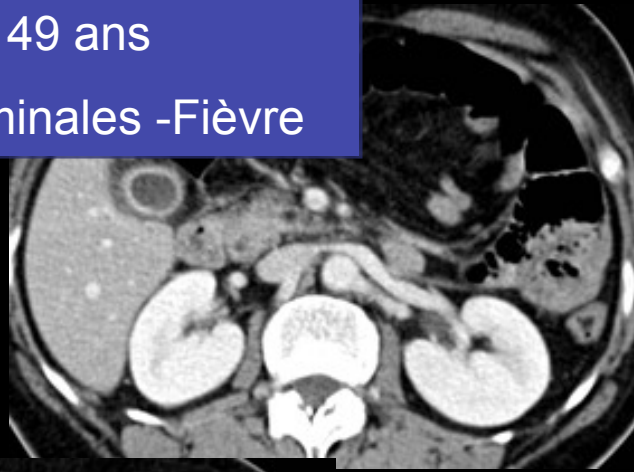


I. Tumeurs de la vésicule biliaire

3. Epaissement irrégulier focal parois vésiculaires

Femme, 49 ans

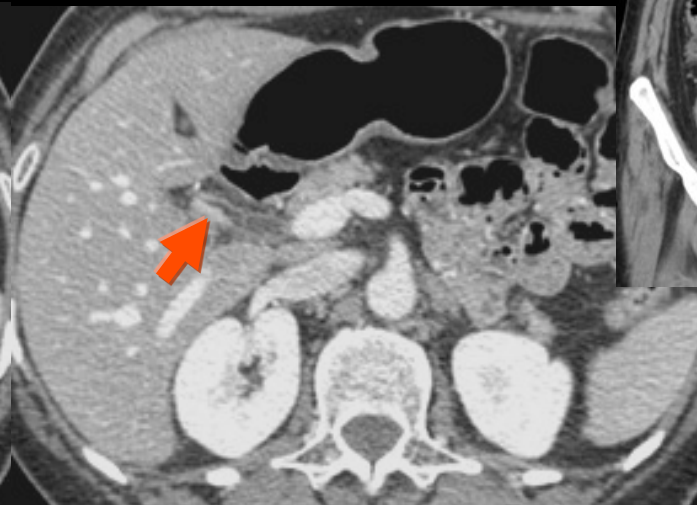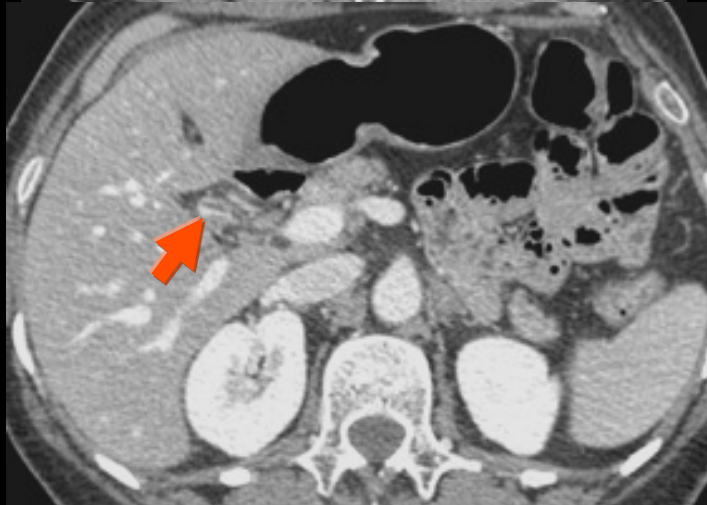
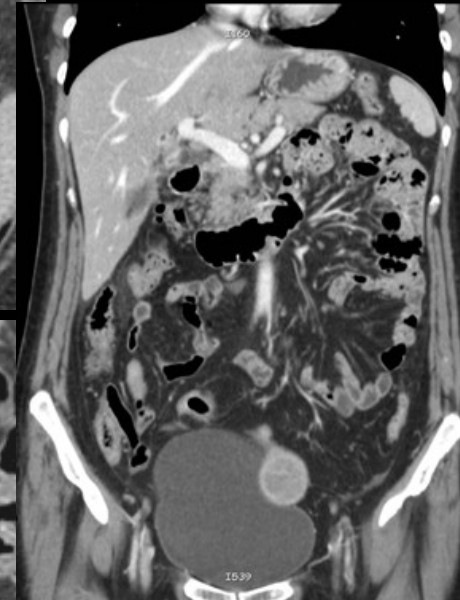
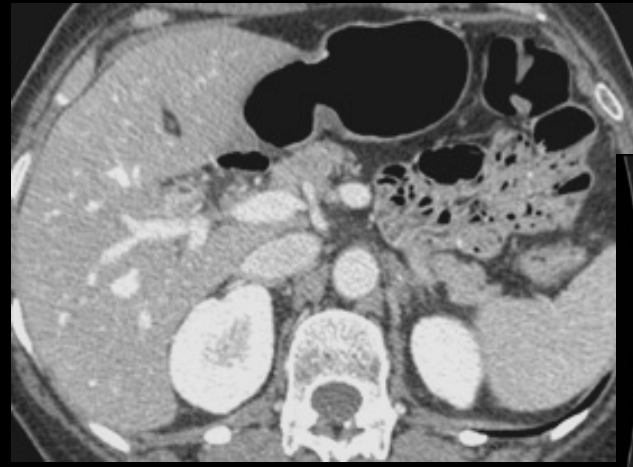
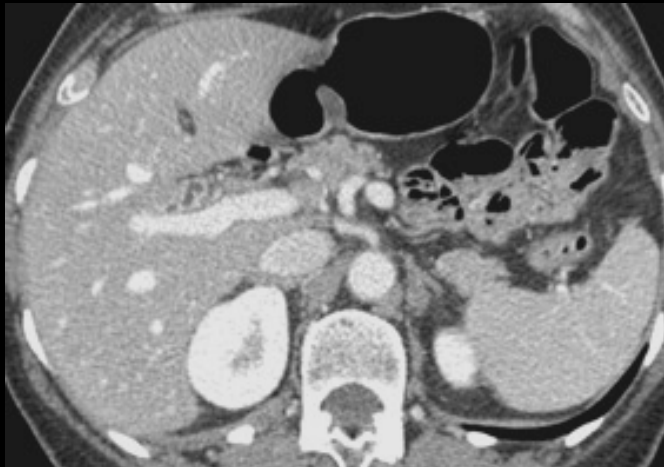
Douleurs abdominales - Fièvre



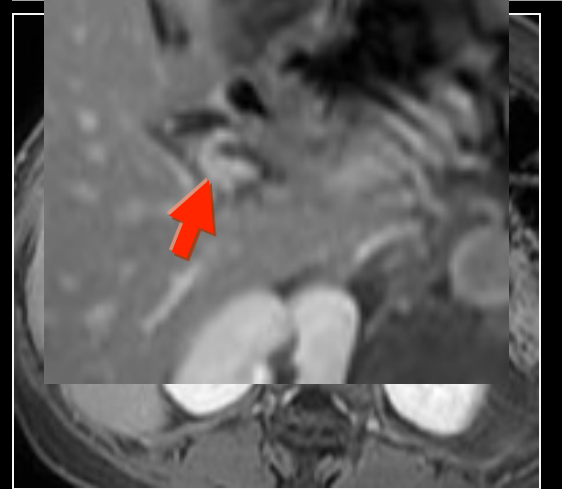
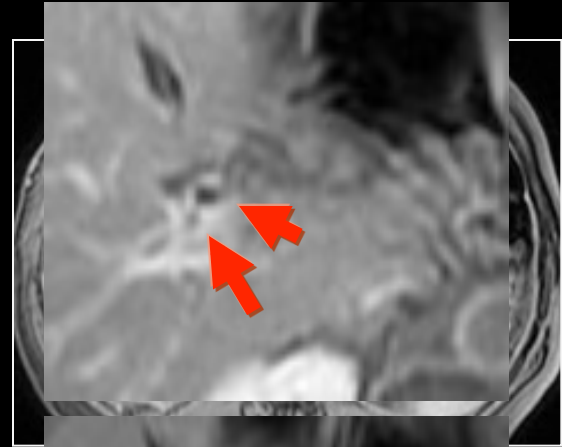
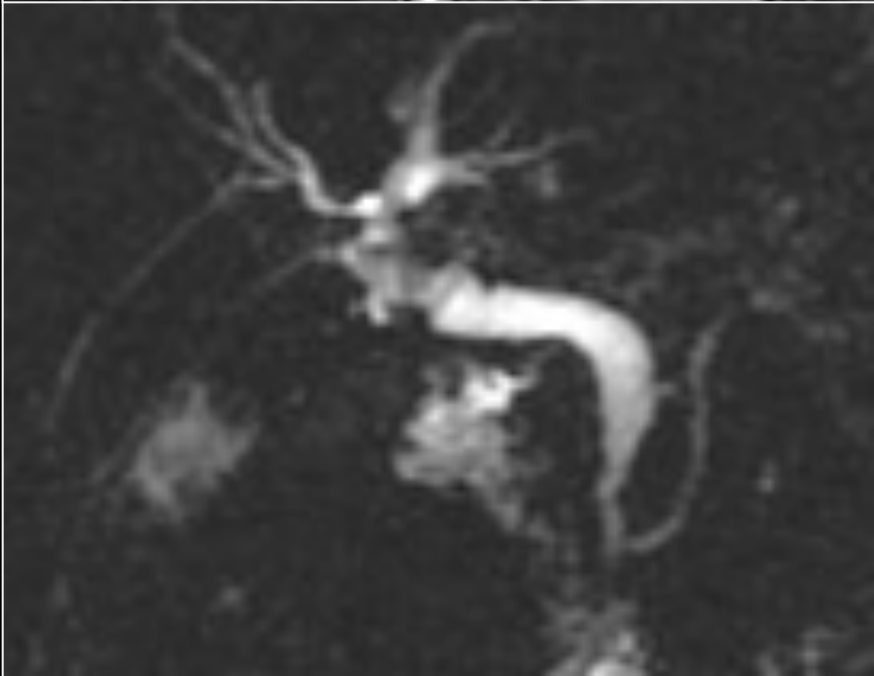
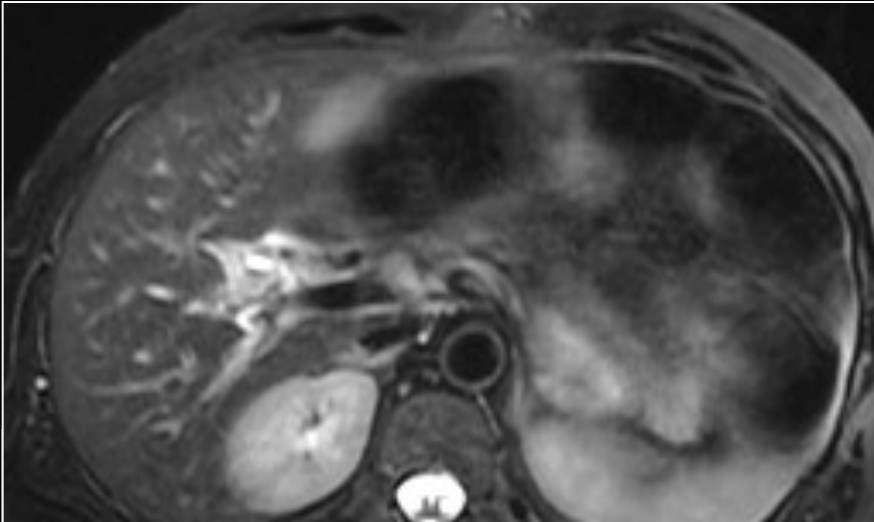
I. Tumeurs de la vésicule biliaire

Femme, 49 ans

Cholécystectomie-Anapath: adénocarcinome sur les zones de recoupe chirurgicale



Tumeurs de la vésicule biliaire



Plan

- Tumeurs de la vésicule biliaire
- **CCK IH**
- CCK hilaires
 - Diagnostic positif
 - Bilan d'extirpabilité
- Tumeurs du bas cholédoque

II. Cholangiocarcinomes intrahépatiques

- **Masse parenchymateuse intrahépatique (MF)**

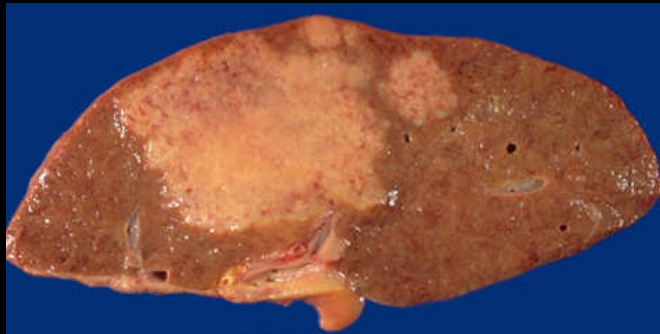- Masse contours réguliers

- Diagn. différentiels :

- Lésion focale hépatique

Fibrose

Temps tardifs



Facteurs de risque

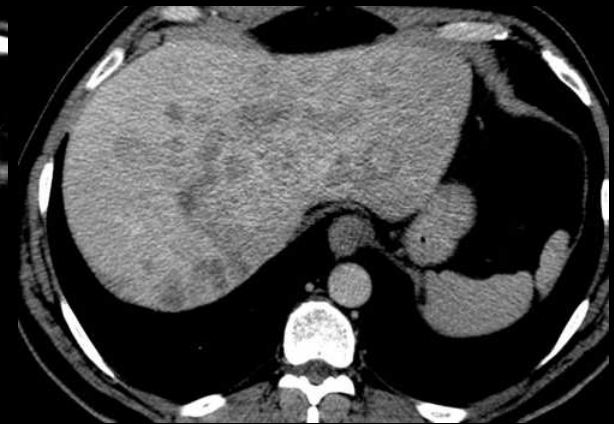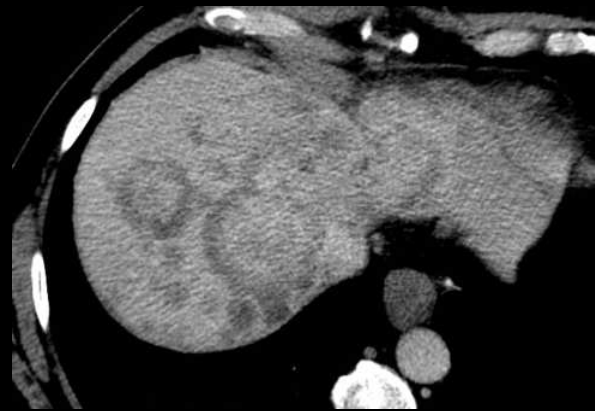
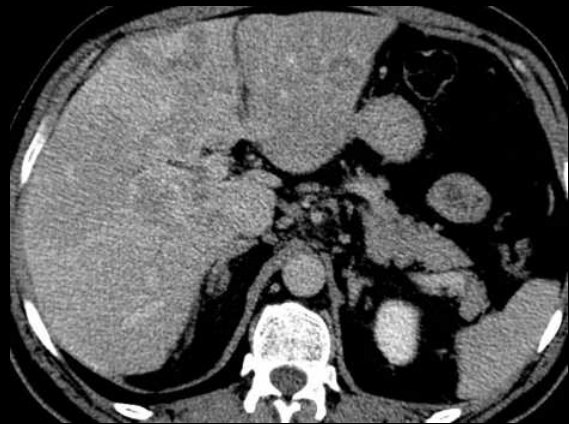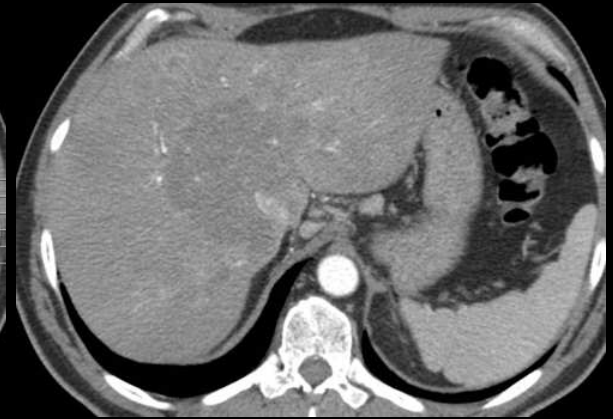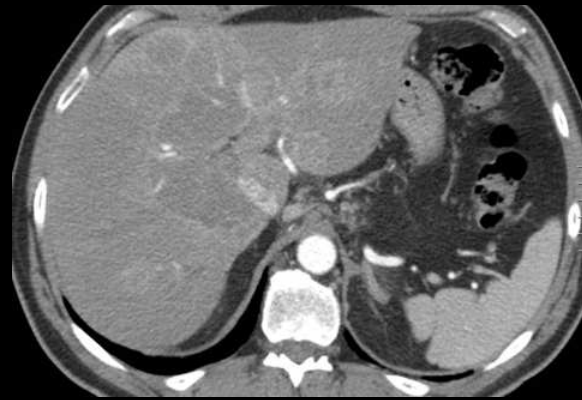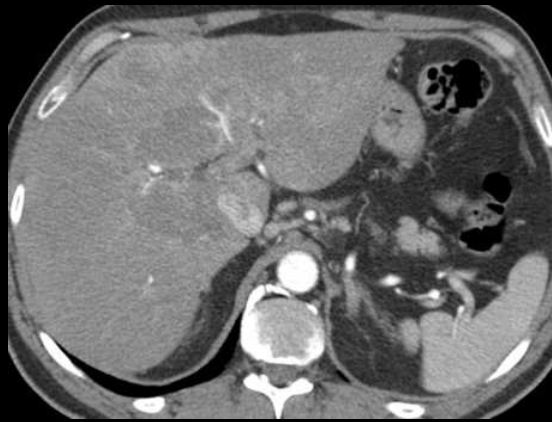- Cholangite sclérosante primitive
- Hépatites virales
- Maladies biliaires congénitales

- **Dilatation segmentaire des VBIH en amont obstacle**

- Diagn. différentiels :

- Calculs
- Métastase endobiliaire
- CHC endobiliaire
- CSP

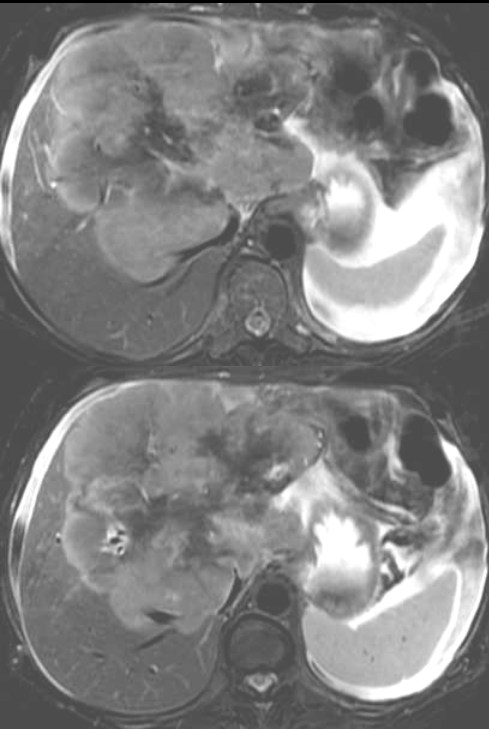
II. Cholangiocarcinomes intrahépatiques



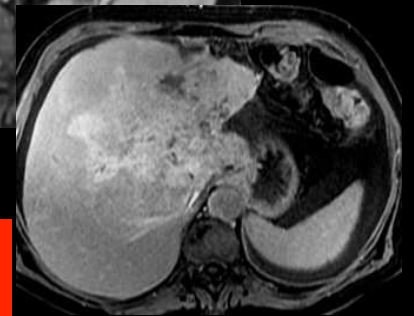
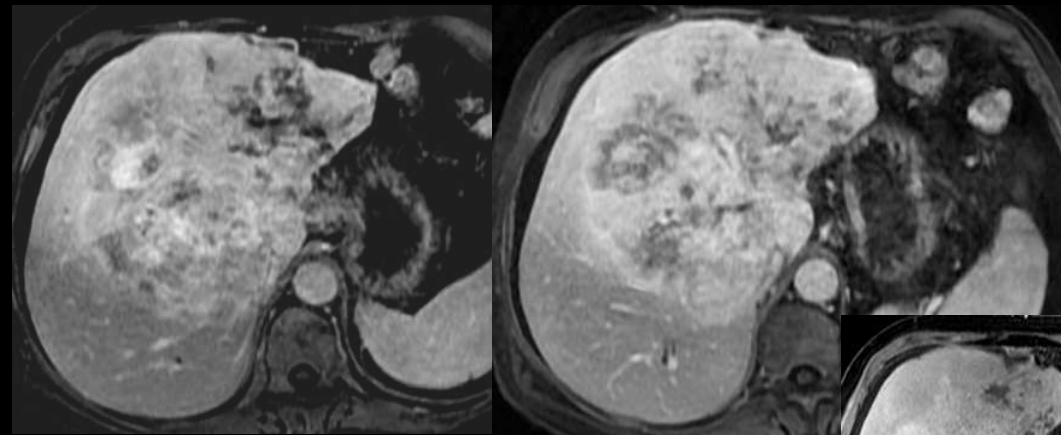
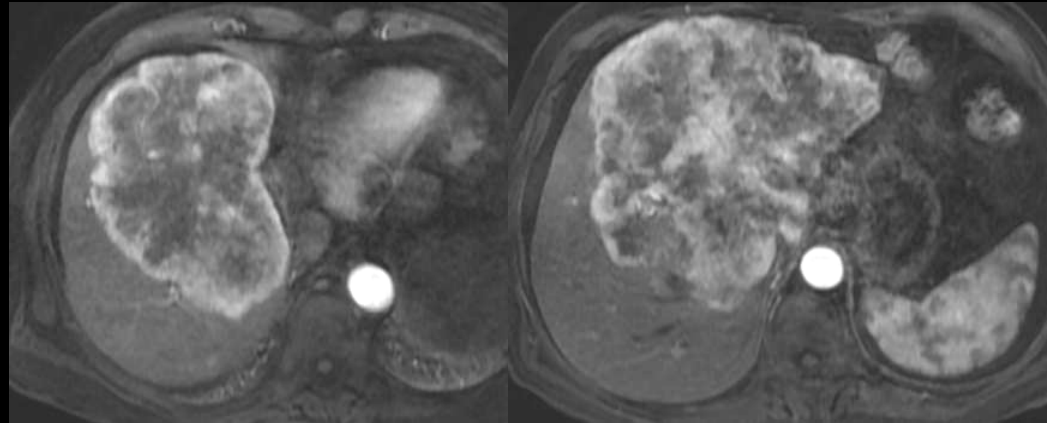
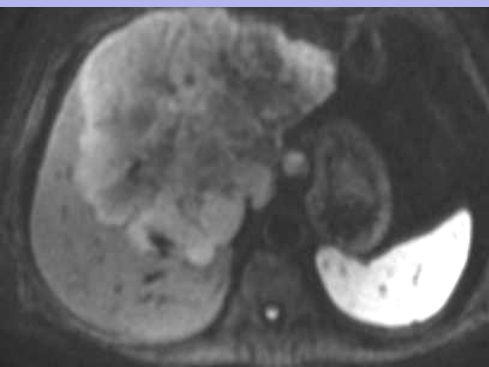
Temps tardifs

Maetani et al. AJR 2001
Manfredi et al. Semin Liver Dis 2004
Rimola et al. Hepatology 2009

II. Cholangiocarcinomes intrahépatiques

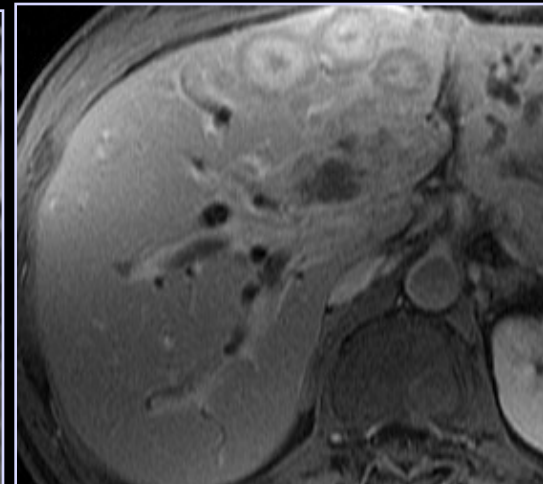
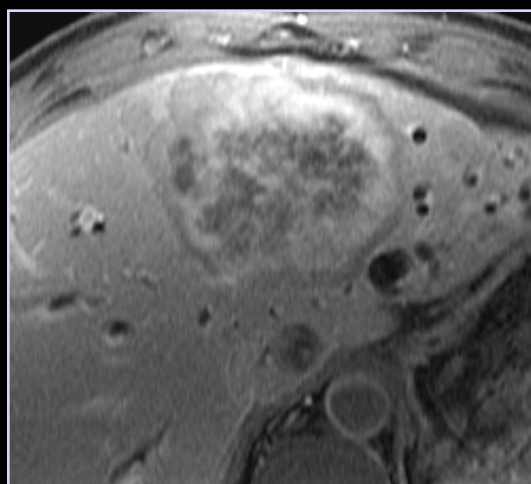
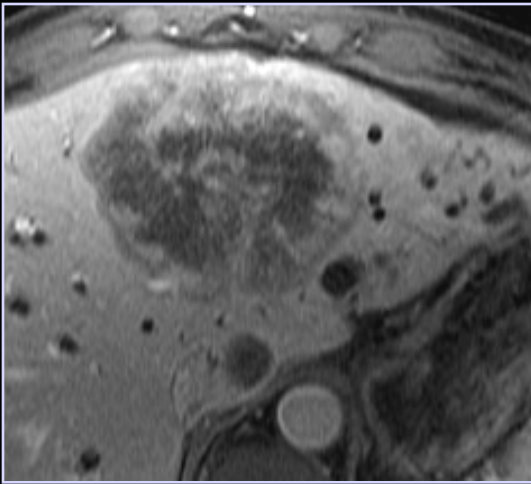
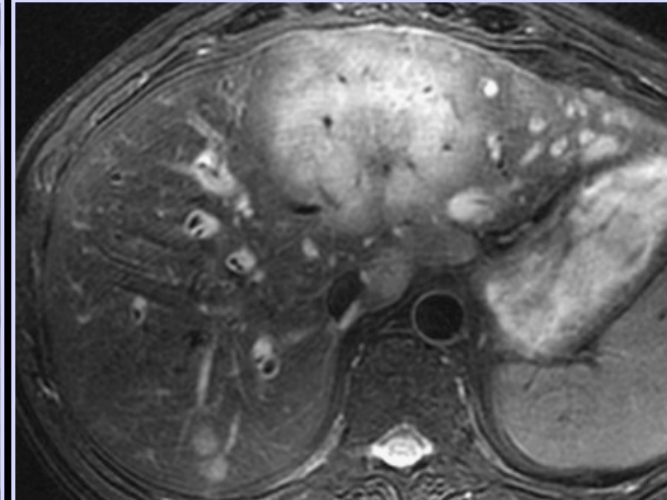
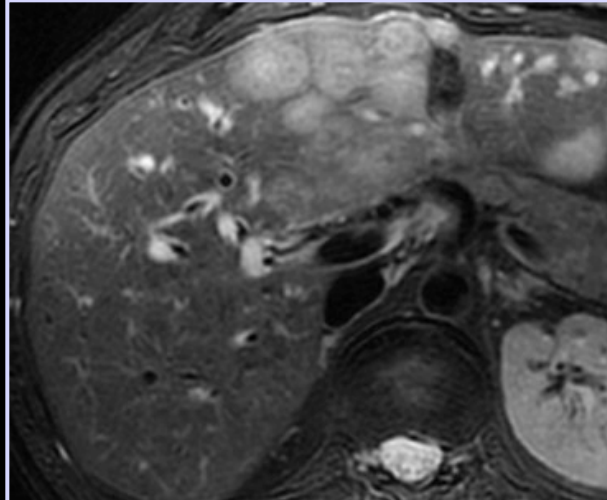
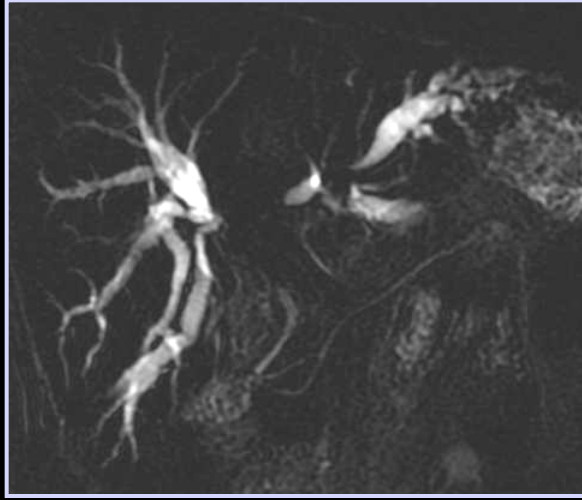


Diffusion



Temps tardifs

II. Cholangiocarcinomes intrahépatiques

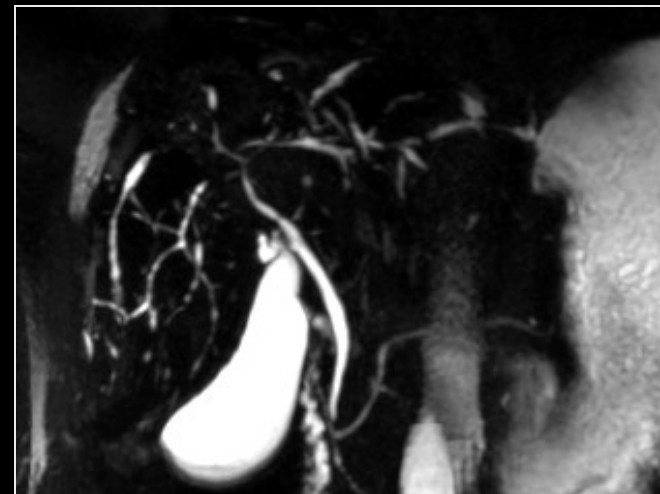
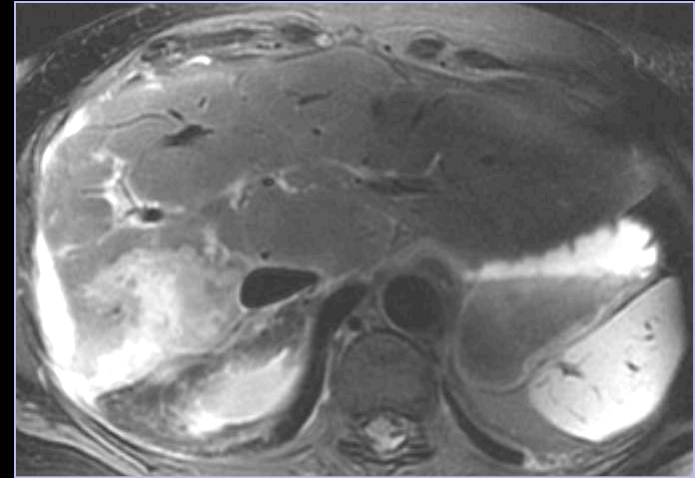
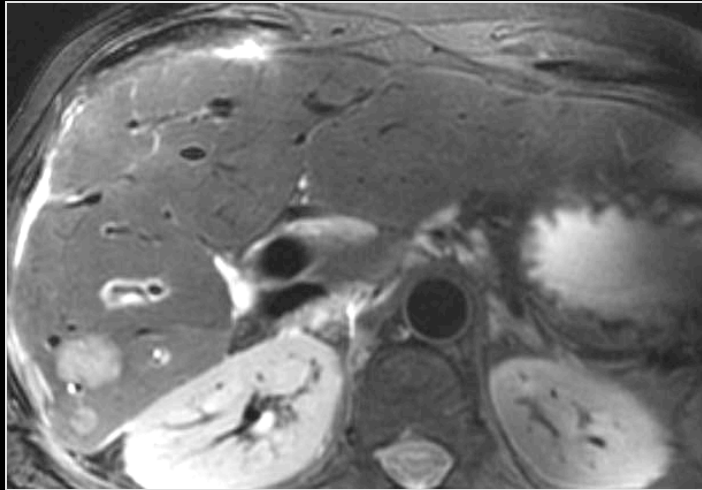


II. Cholangiocarcinomes intrahépatiques

Femme, 52 ans

Perturbations mineures du bilan biologique hépatique depuis 10 ans

Découverte lésions focales hépatiques du foie droit



Facteur de risque

-Cholangite sclérosante primitive

II. Cholangiocarcinomes intrahépatiques

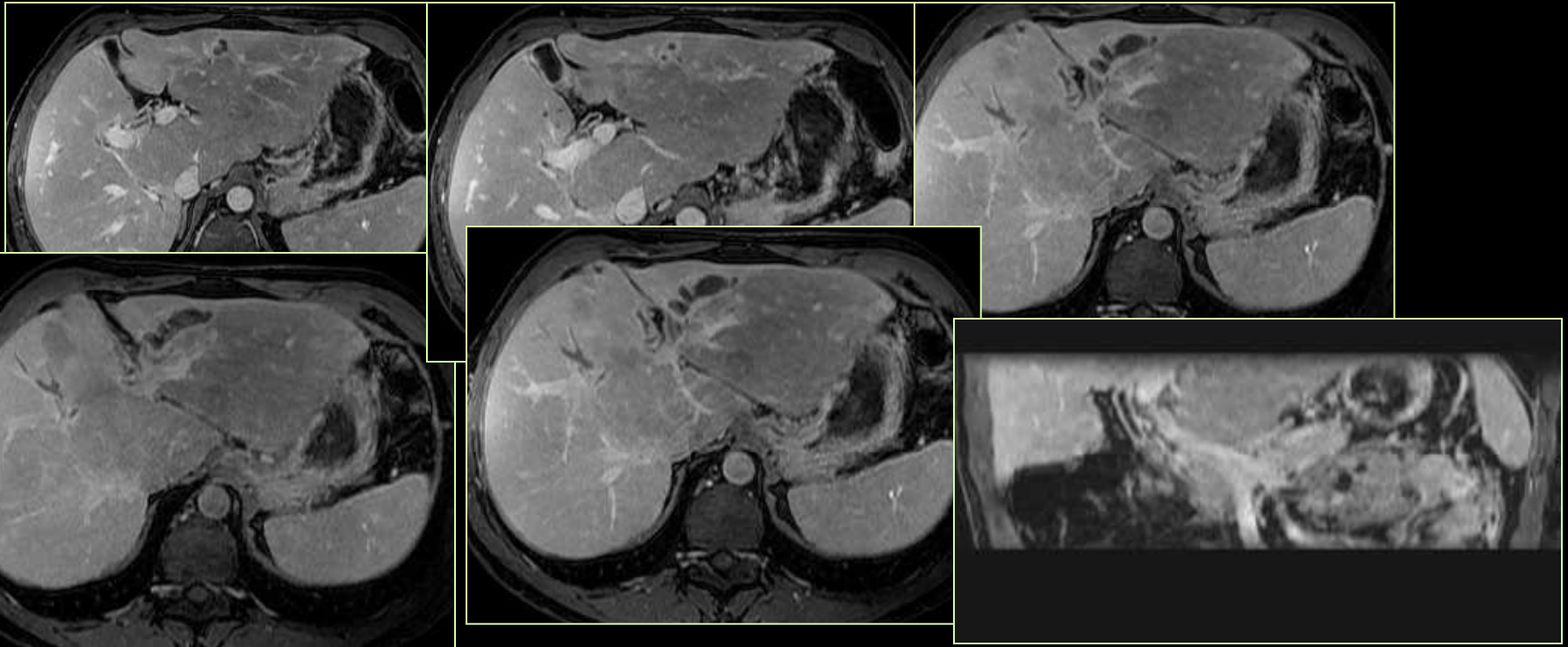
Dilatation segmentaire des VBIH

– Diagn. différentiels :

Calculs

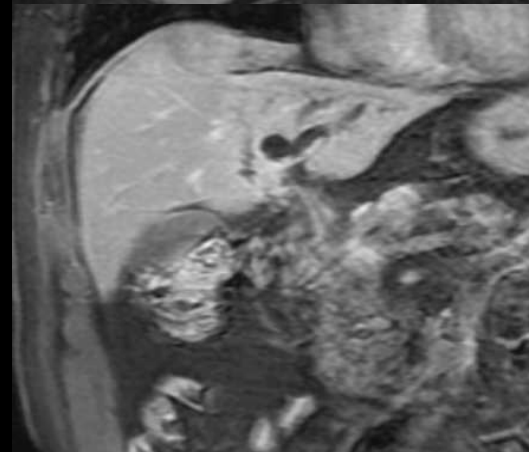
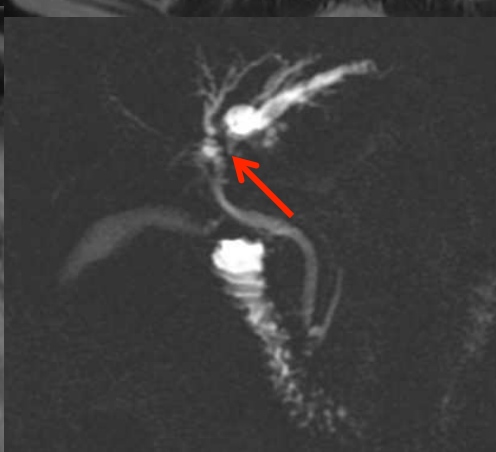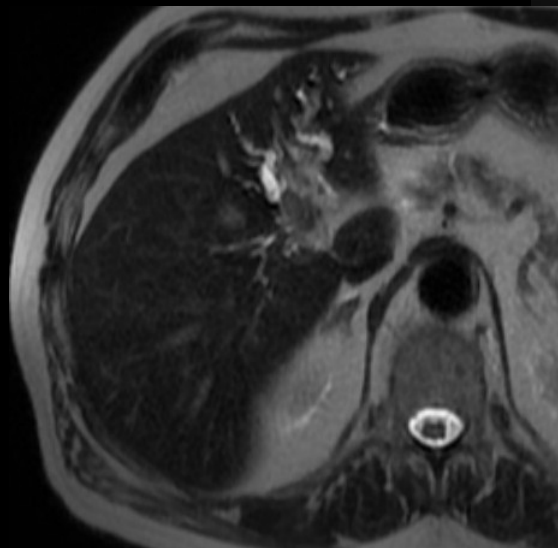
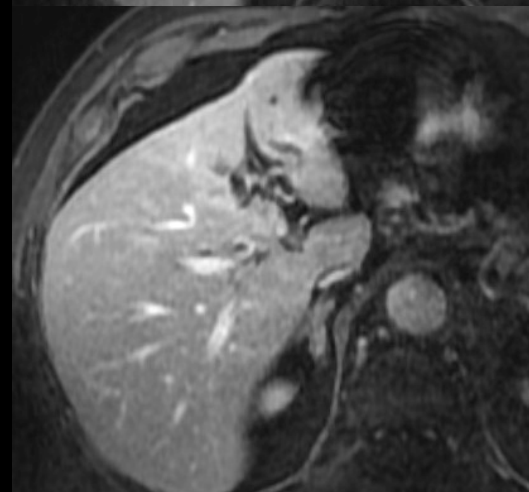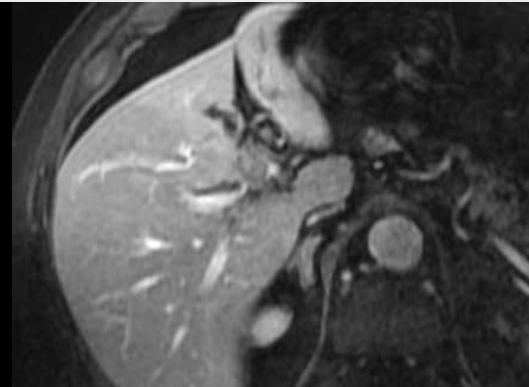
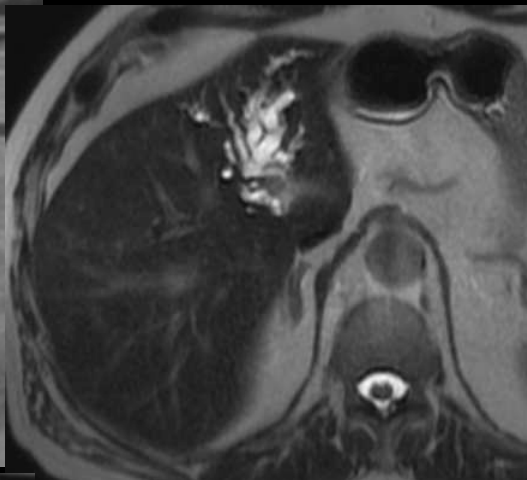
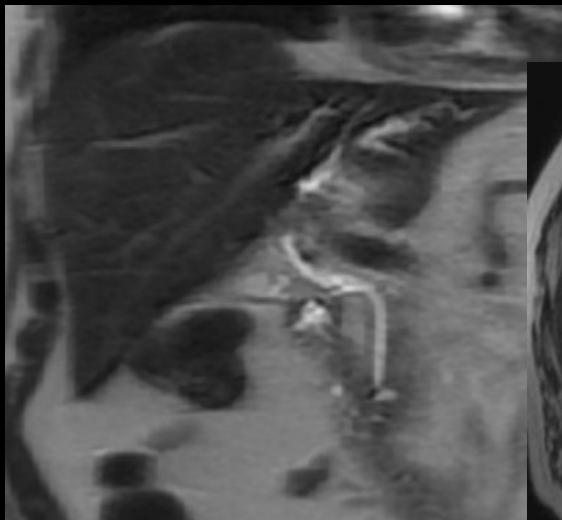
CHC à développement endobiliaire

Métastases à développement endobiliaire (cancers colo rectaux, sein)



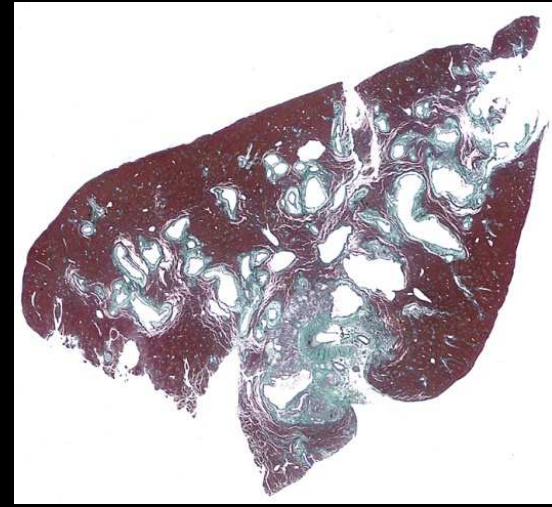
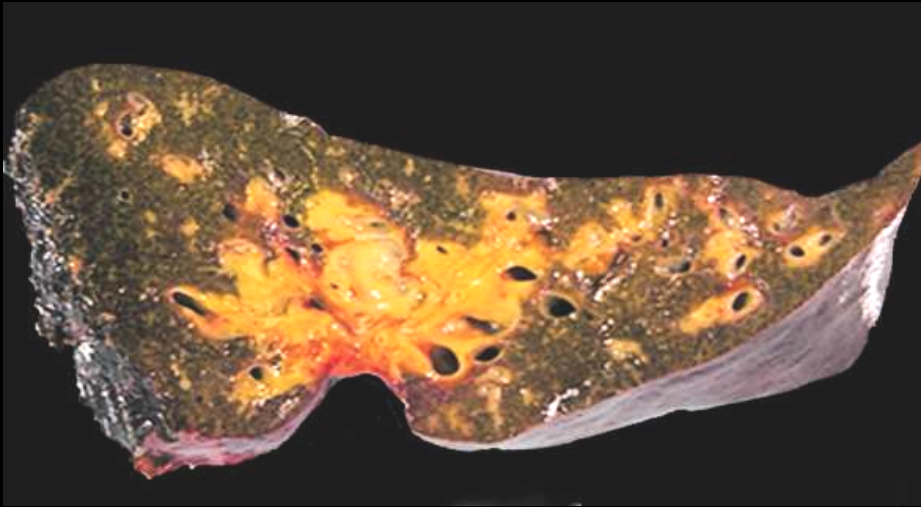
II. Cholangiocarcinomes intra hépatiques

Dilatation segmentaire des VBIH



Couple échographie
IRM

III. Cholangiocarcinomes hilaires



Infiltration pariétale
Prolifération endocanalaire

Diagn. différentiels :

Obstacles de la convergence

Particularités :

- Extension longitudinale
- Extension circonférentielle

Facteurs de risque

- Cholangite sclérosante primitive

Plan

- Tumeurs de la vésicule biliaire
- CCK IH
- **CCK hilaires**
 - Diagnostic positif
 - Bilan d'extirpabilité
- Tumeurs du bas cholédoque

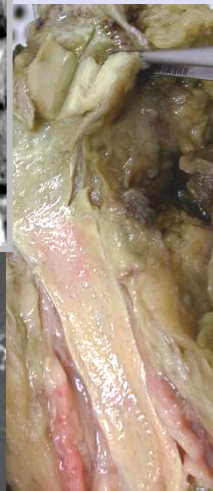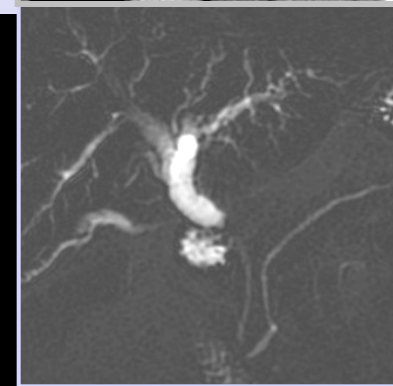
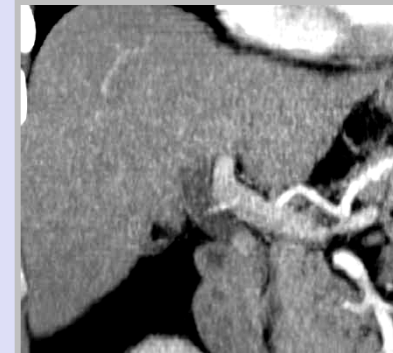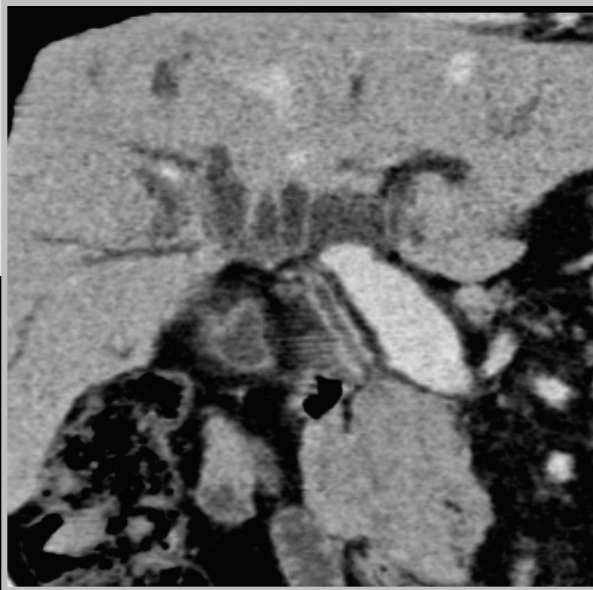III. Cholangiocarcinomes hilaires

Macroscopie

Infiltration canalaire
(« Periductal infiltrating »)

Prolifération tumorale
endocanalaire
(« Intraductal growth »)

Aspects en Imagerie



III. Cholangiocarcinomes hilaires

Obstacles Hilaires :

Est-ce que c' est un cancer ???

Obstacles Hilaires :

Existe il une possibilité curative ???

Dans quelles conditions ???

III. Cholangiocarcinomes hilaires

Place de l'imagerie : Rôle majeur ++++

- Diagnostic positif:
 - Niveau lésionnel
 - Différentiel malin/bénin

- Evaluation de l'extirpabilité :
 - Biliaire
 - Vasculaire : artériel et veineux
 - Loco-régional parenchymateuse hépatique, organes de voisinage et à distance

- Place de la radiologie interventionnelle
 - Si chirurgie à visée curative : préparation à l'intervention
 - Volumétrie hépatique, évaluation du foie restant après intervention
 - Drainage biliaire
 - Embolisation portale
 - Si traitement palliatif
 - Drainage interne, externe
 - Type de stents, nombre de stents etc...

Obstacle biliaire mécanique : échographie



Explorations radiologiques non invasives

Scanner abdomino-pelvien

IRM : cholangio et séquences injectées

Nature
de l'obstacle +++

Bilan
d'extirpabilité



Avis chirurgical ++++

- Kim MJ et al. *Radiology* 2000, 214: 173-181.

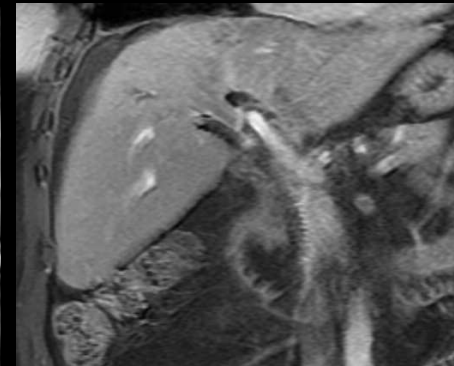
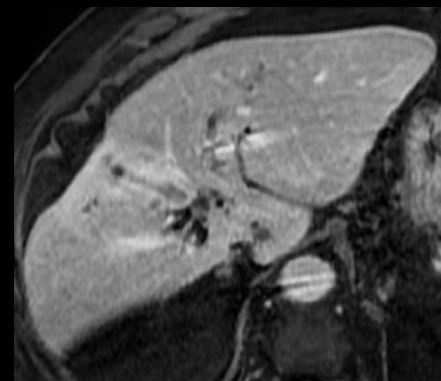
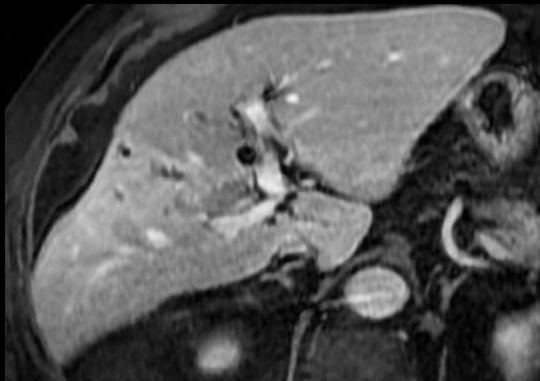
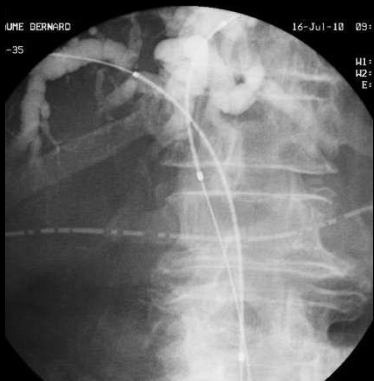Explorations radiologiques non invasives

Scanner abdomino-pelvien

IRM : cholangio et séquences injectées

Si opacifications et prothèse mise en place avant tte exploration radiologique non invasive

- Pas d'analyse des voies biliaires sus jacentes à la sténose
- Pas de bilan d'extirpabilité adéquat pour juger de la résécabilité ou non, et donc du choix de la prothèse
- Csq en imagerie
 - Aspect inflammatoire marqué de l'ensemble de la VBP
 - Aérobilie
 - Pas d'analyse possible de la sémiologie de la sténose



Obstacles Hilaires :

Est-ce un cancer ???

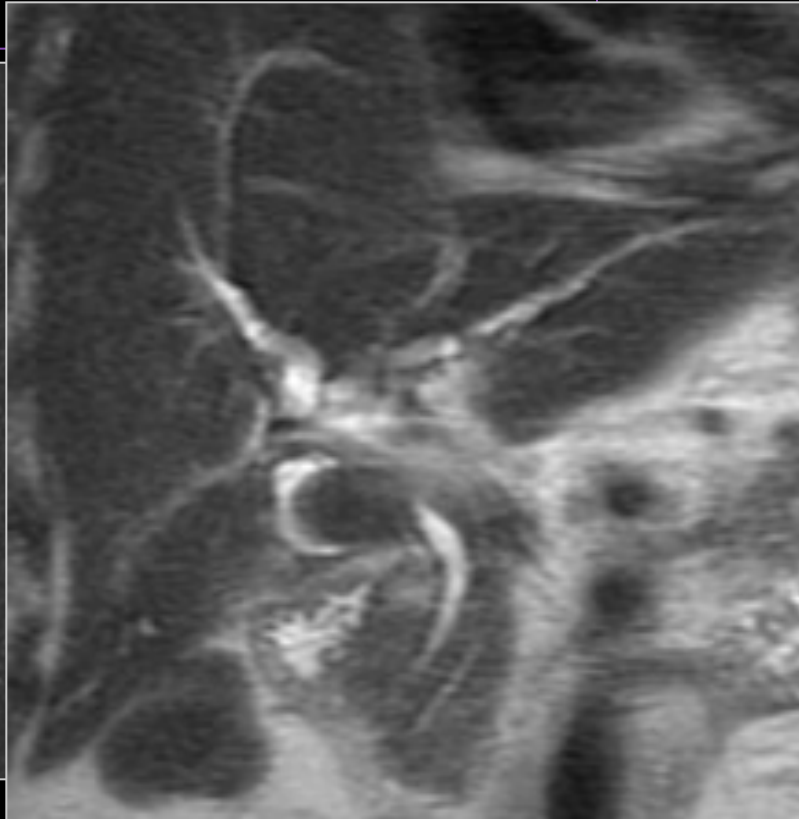
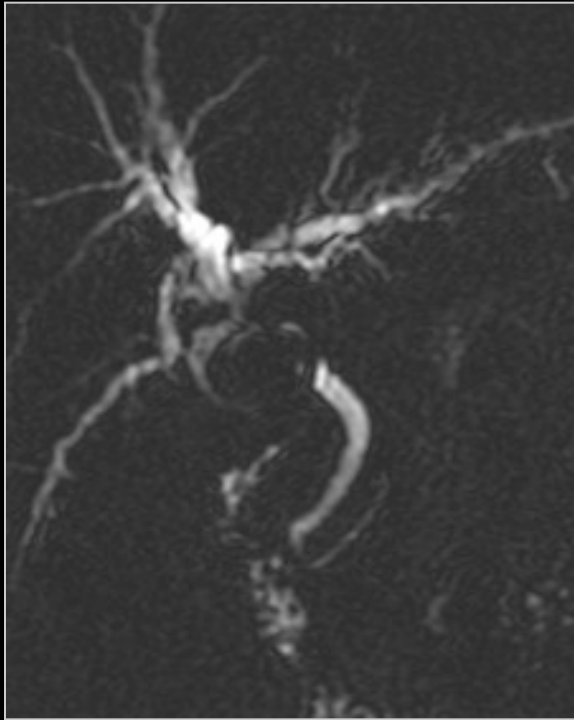
Etiologies bénignes

Syndrome de Mirizzi

Calculs de la convergence

Cavernome pseudo tumoral

Faux kystes

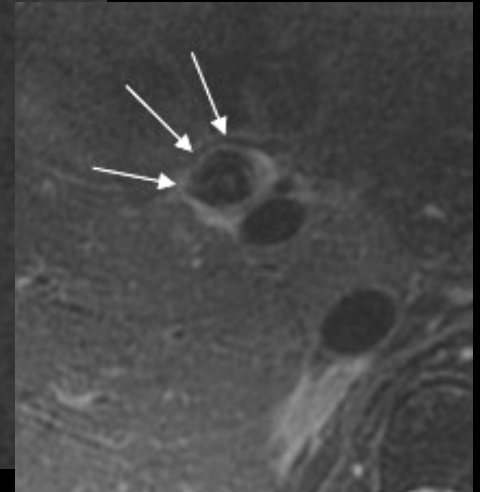
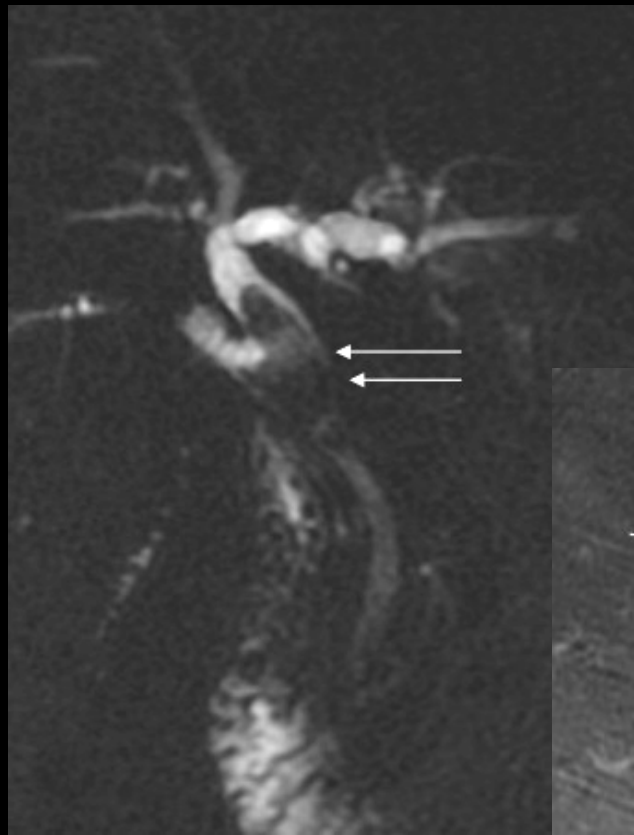
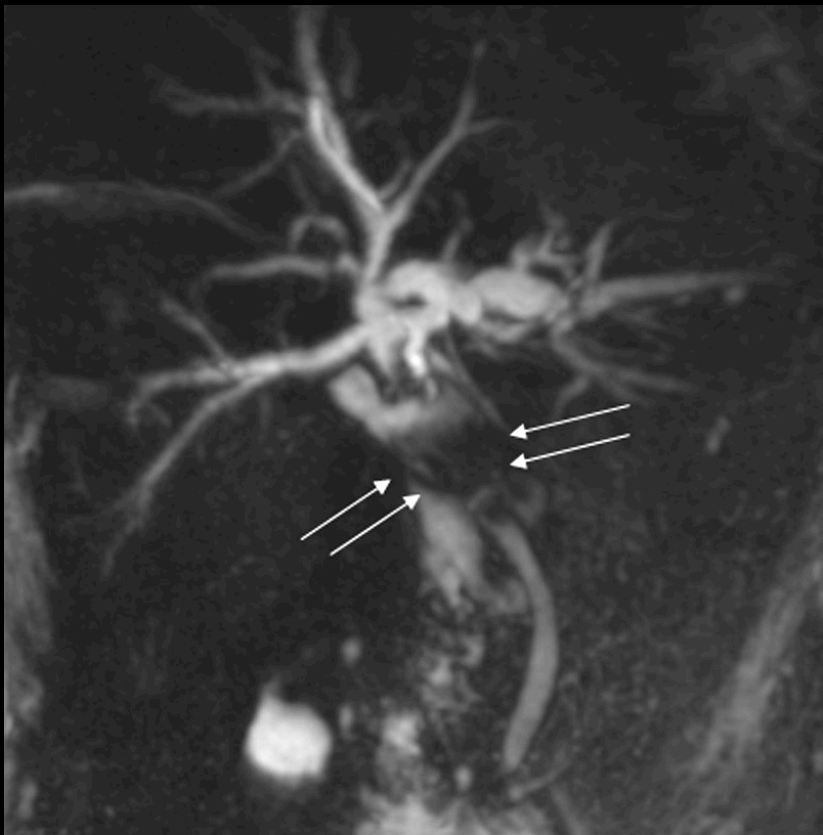


Syndrome de Mirizzi

Obstacle hilaire : est ce un cancer ?

Etiologies bénignes

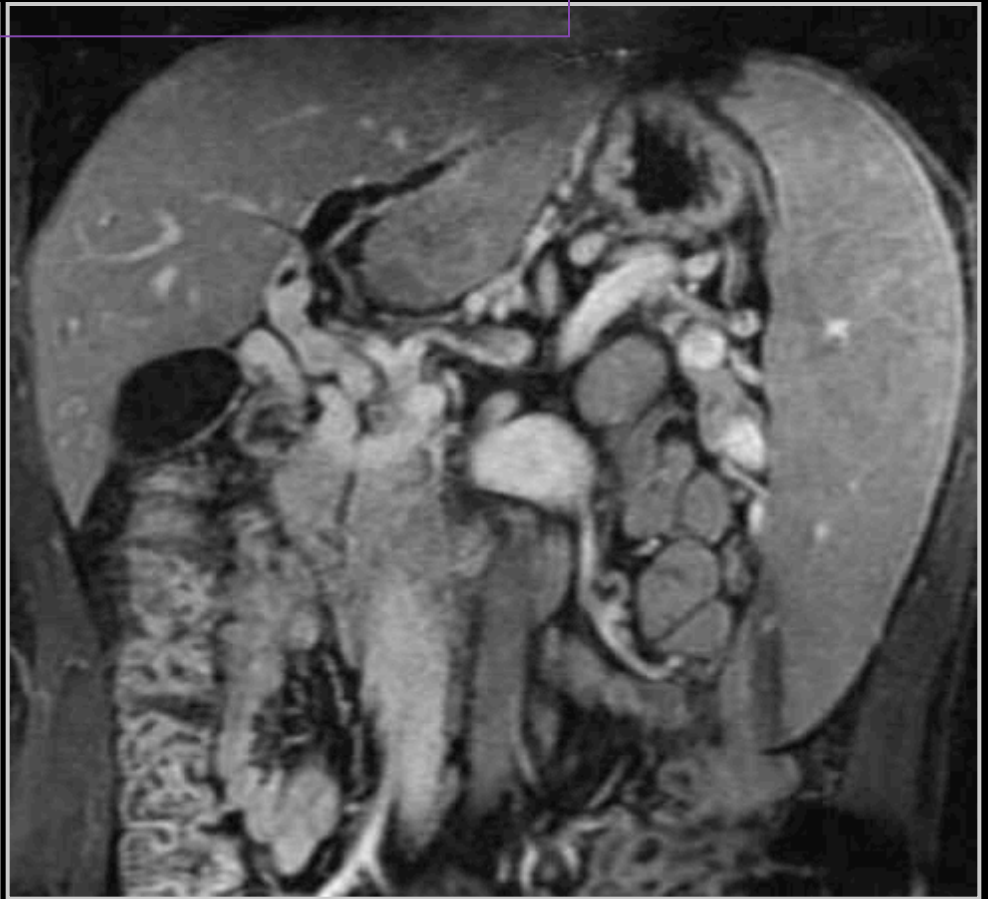
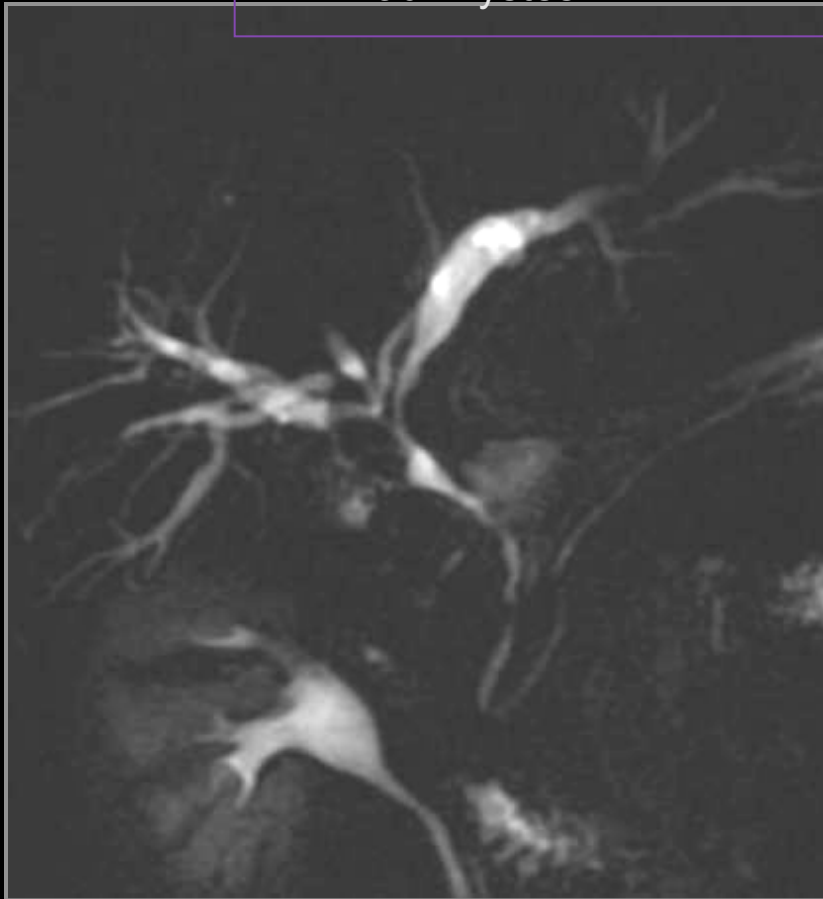
Syndrome de Mirizzi
Calculs de la convergence
Cavernome pseudo tumoral
Faux kystes



Obstacle hilaire : est ce un cancer ?

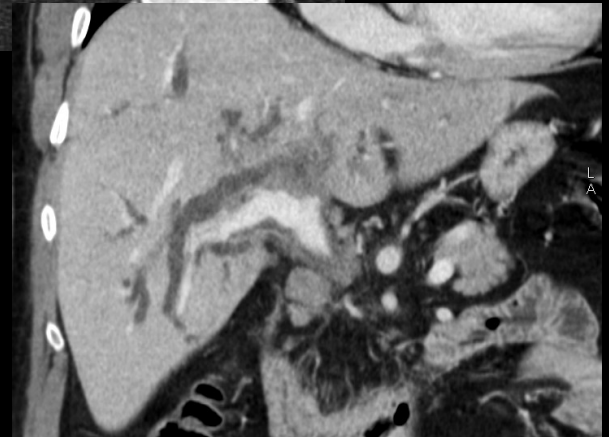
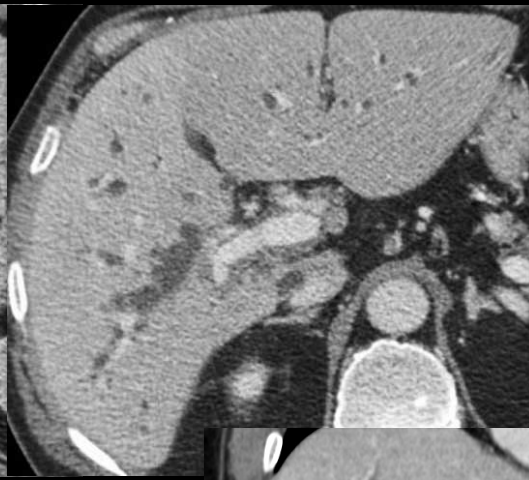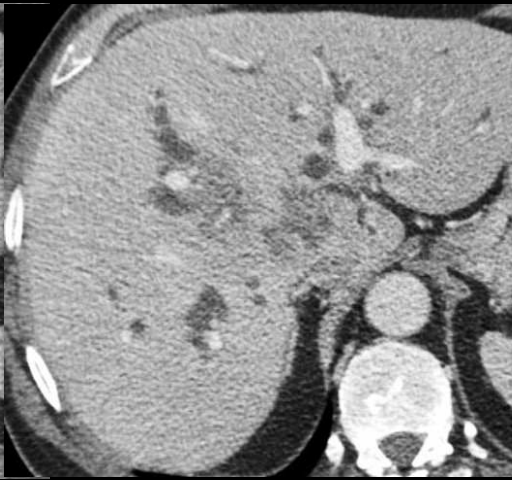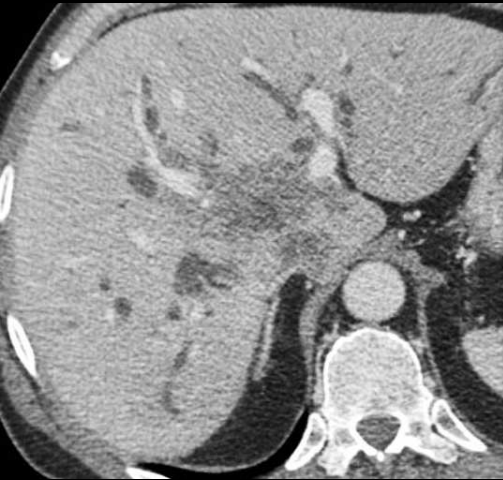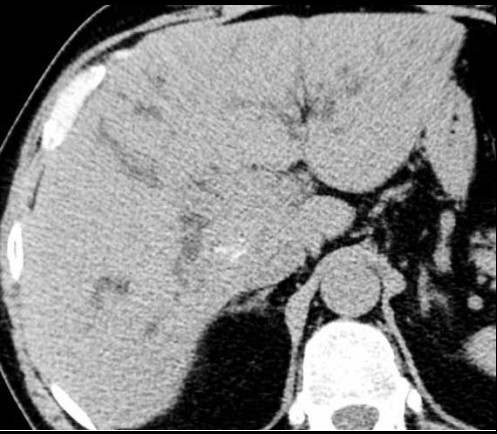
Etiologies bénignes

Syndrome de Mirizzi
Calculs de la convergence
Cavernome pseudo tumoral
Faux kystes



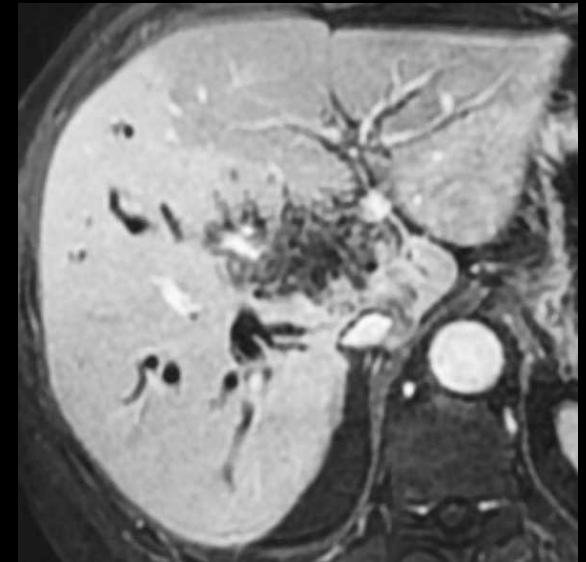
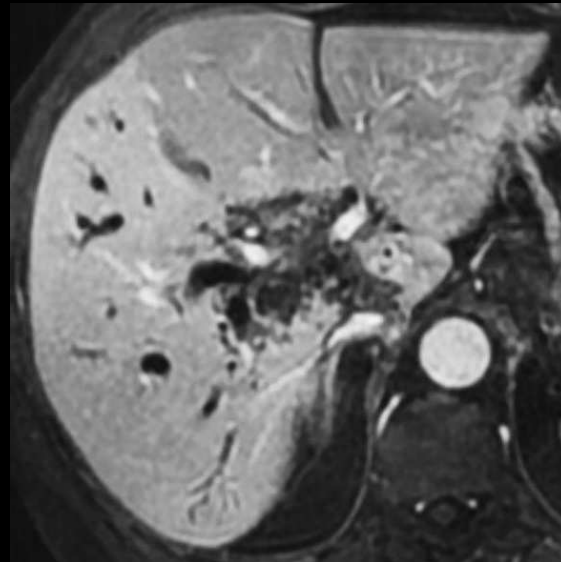
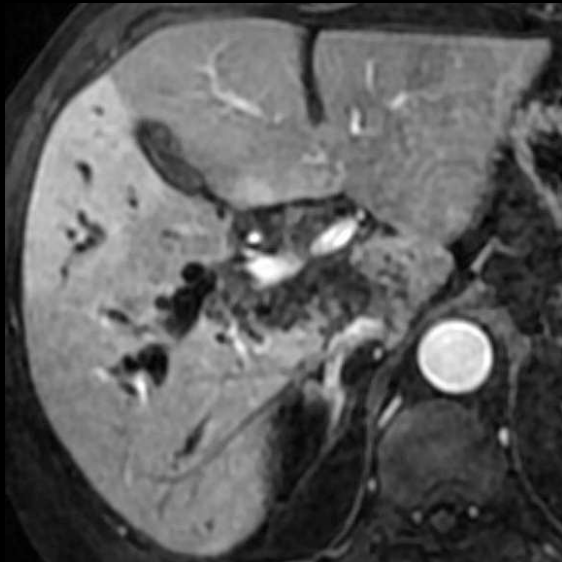
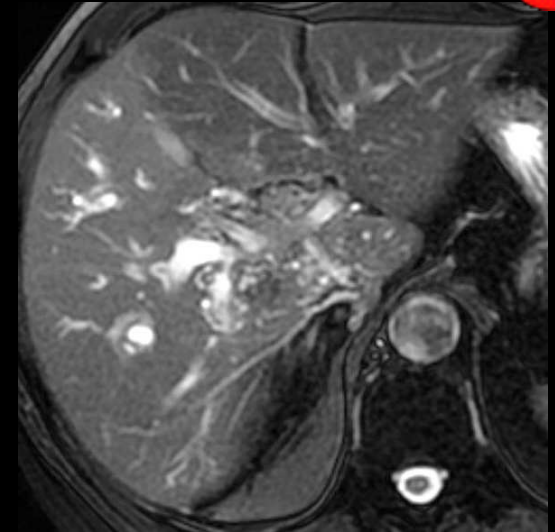
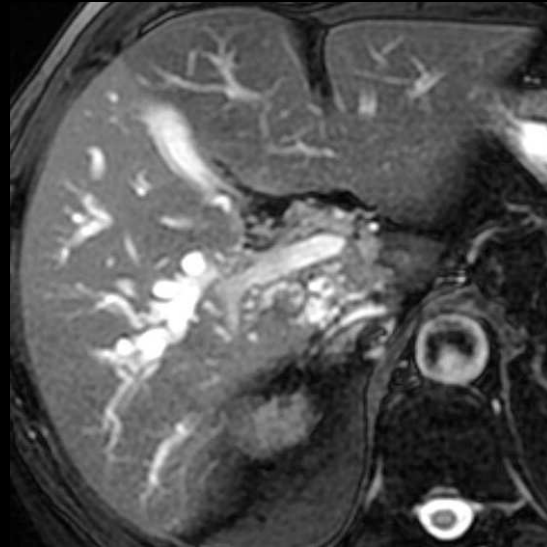
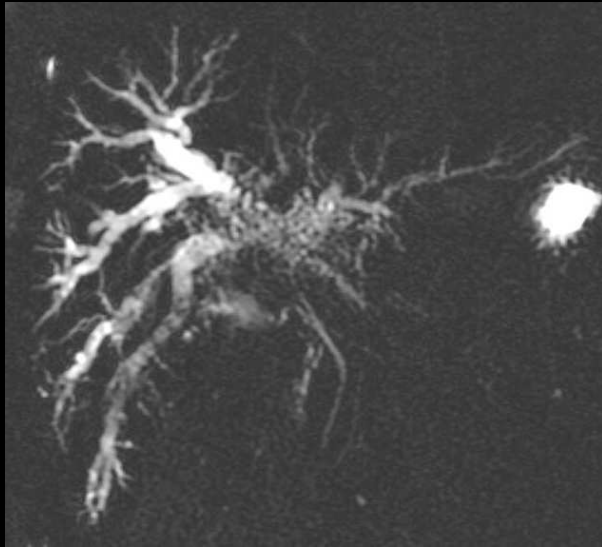Cholangiopathie portale

Obstacle hilaire : est ce un cancer ?



**Patient ictère
Vosgien**

Obstacle hilaire : est ce un cancer ?



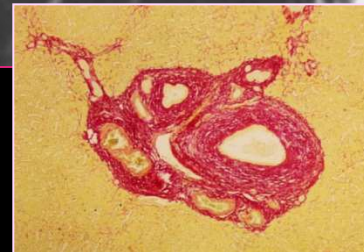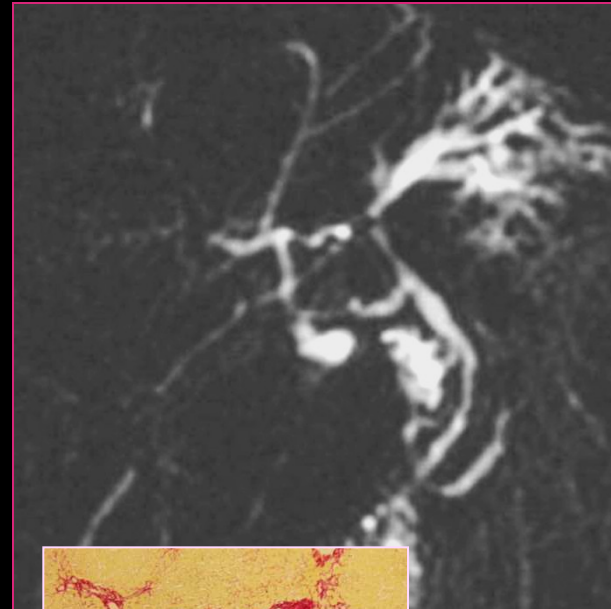
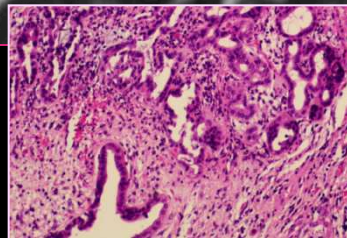
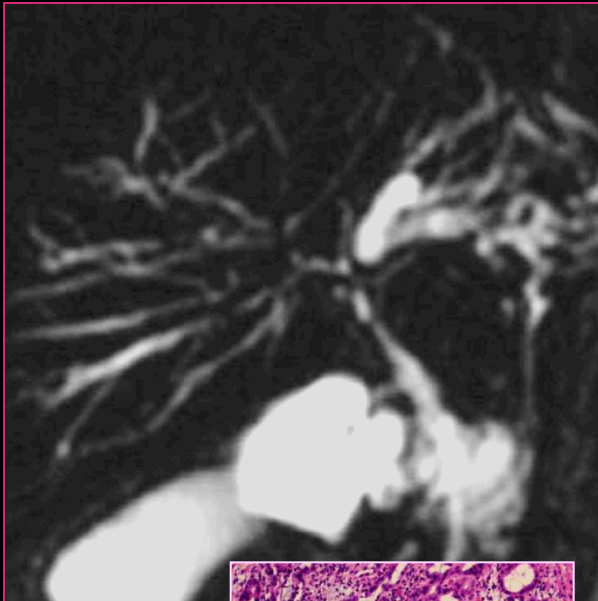
Obstacle hilaire : est ce un cancer ?

Processus infiltrant pariétal

Cholangite sclérosante primitive

Anomalies conjointes des VBIH
RCH , pancréatite auto immune

Cholangite auto-immune



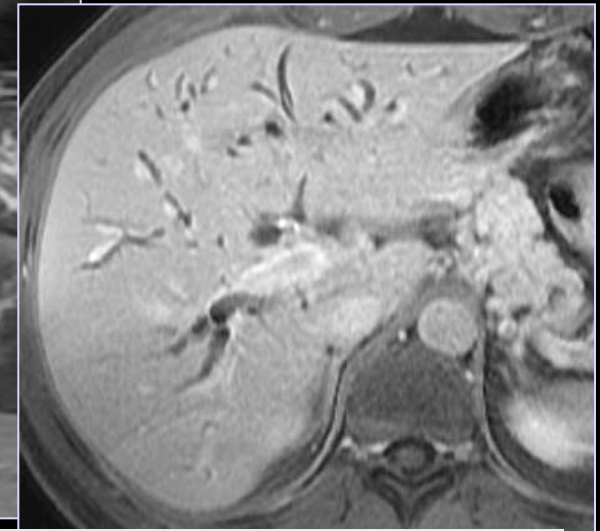
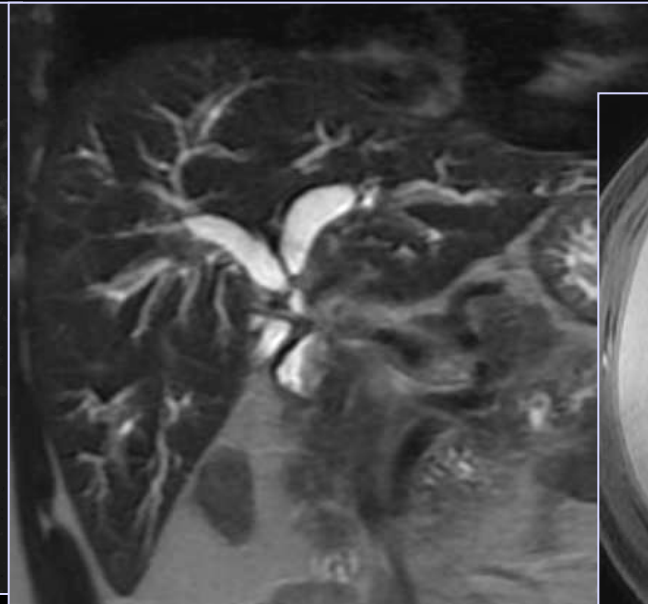
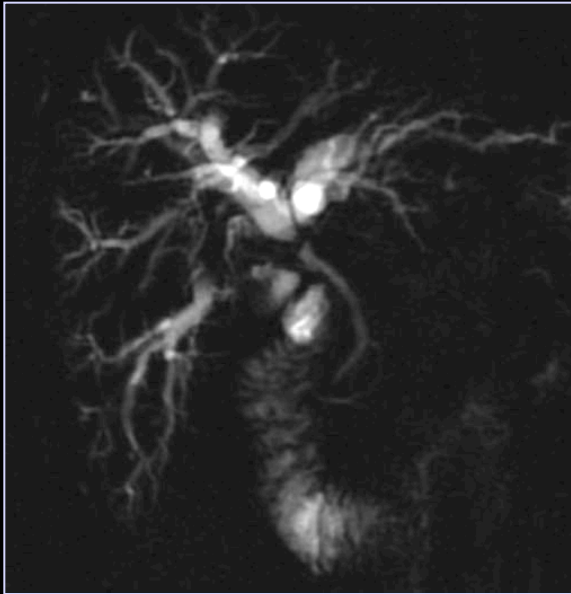Processus infiltrant pariétal

Cholangite sclérosante primitive

Anomalies conjointes des VBIH
RCH , pancréatite auto immune

Cholangite auto-immune

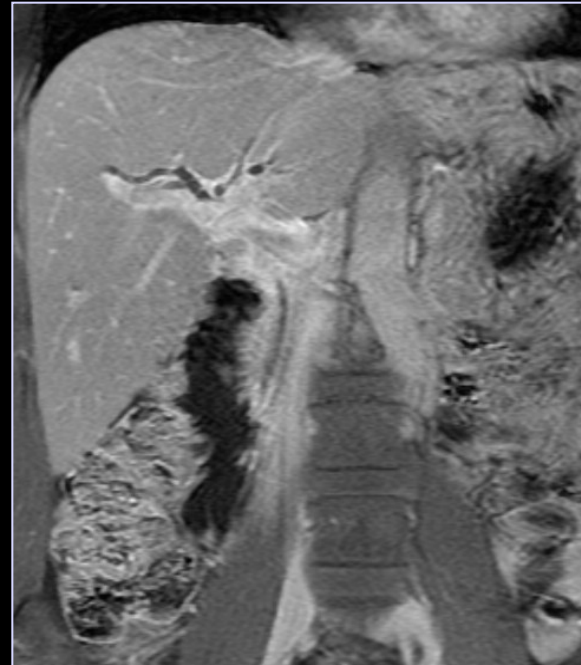
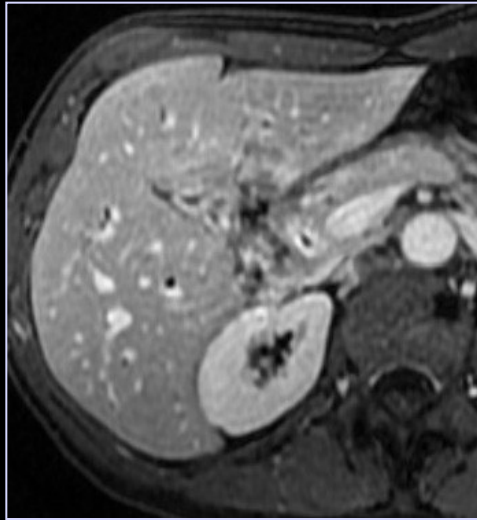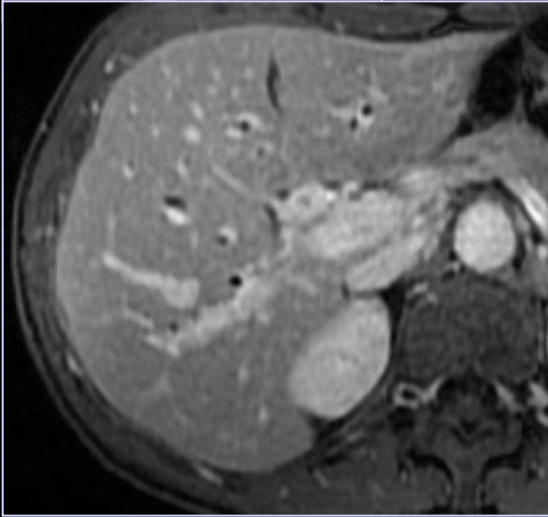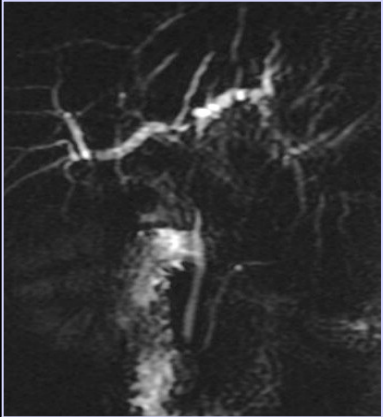
Koea et al. World J Surg 2004
Rosch et al. Gastrointest Endosc
2002
Gerhards et al. Br J Sur 2001



14% des obstacles hilaires considérés comme des CCK périhilaires sont des cholangites

Obstacle hilaire : est ce un cancer ?

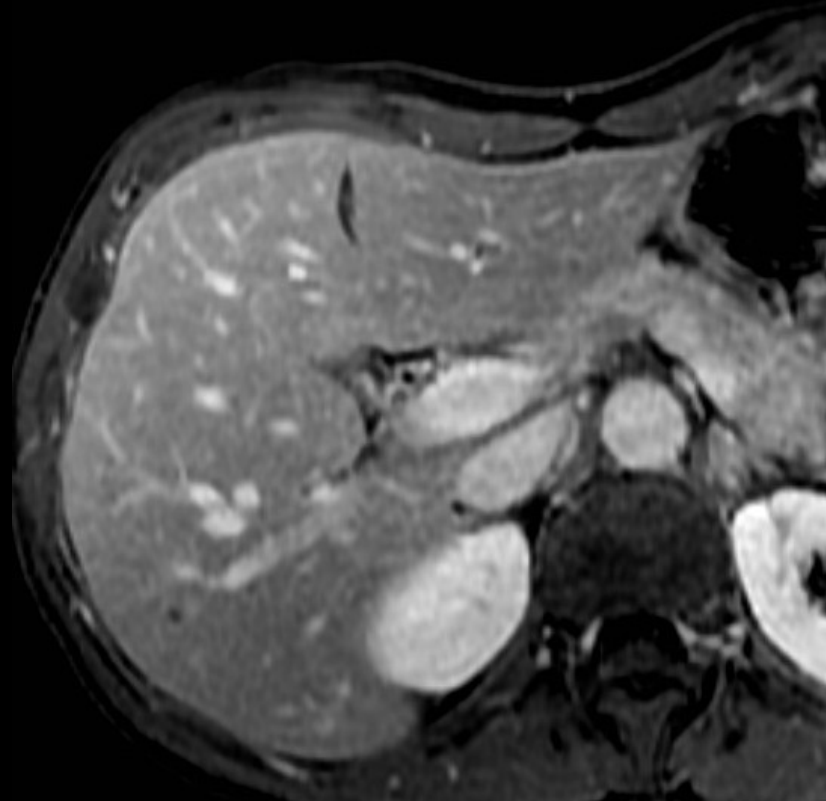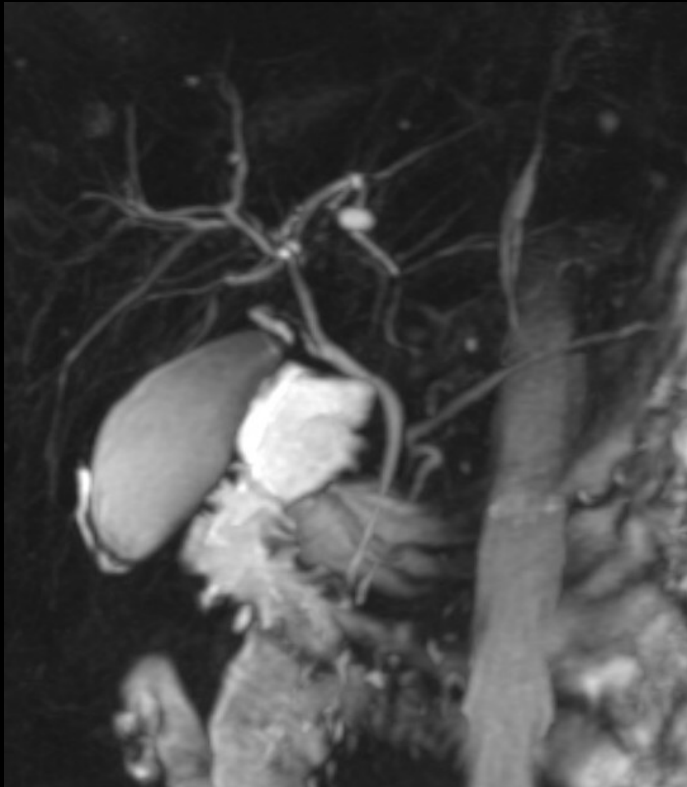Processus infiltrant pariétal



Koea et al. World J Surg 2004
Rosch et al. Gastrointest Endosc 2002
Gerhards et al. Br J Sur 2001

Obstacle hilaire : est ce un cancer ?

Processus infiltrant pariétal



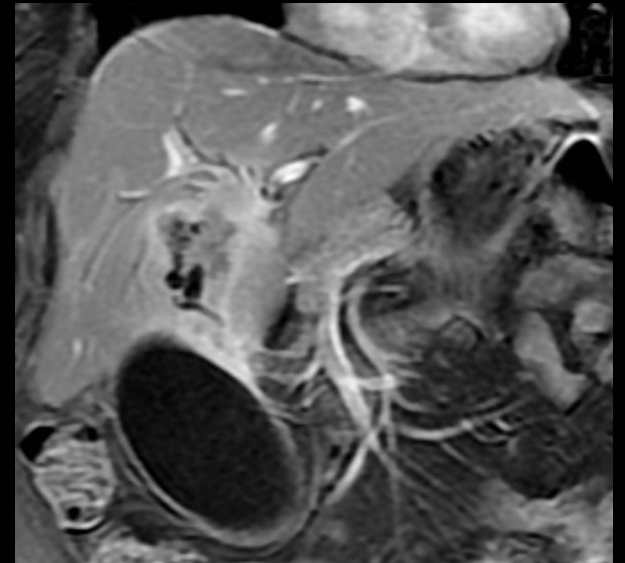
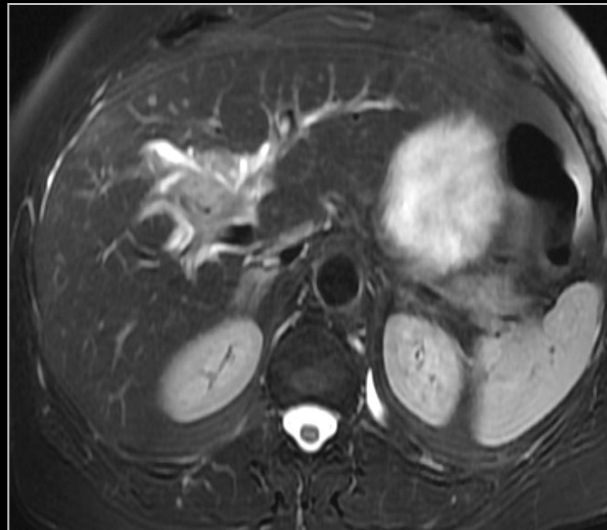
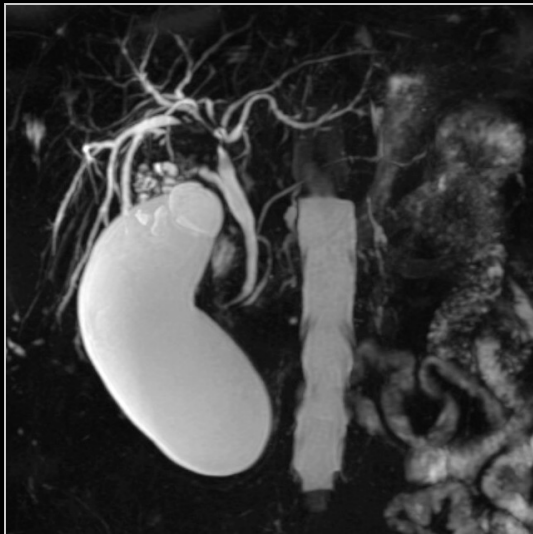
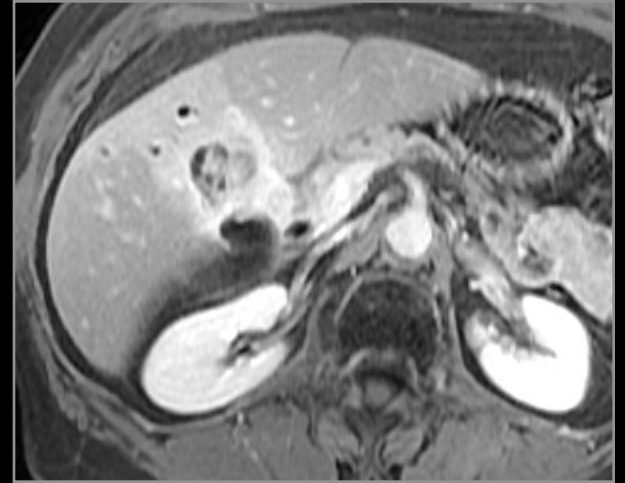
Processus infiltrant pariétal

- Knoefel WT et al. *Eur Surg Oncol* 2003; 29 : 658-61
 - 33 patients
 - Echo, CT, ERCP, angiography
 - 27 lésions malignes / 6 patients porteurs d'une cholangite fibrosante
- Uhlmann D et al. *J Gastrointest Surg* 2006; 10 : 1144-50
 - 49 patients / diagnostic radiologique de tumeur de Klatskin
 - **14% (7) : pathologie bénigne.**
 - 6 considérés comme malins à la laparotomie
 - Anapath : cholangite sévère avec une fibrose extensive périductale

Obstacle hilaire : est ce un cancer d'une autre origine ?

Malins

- ADK pancréas
- ADK sillon
- ADK vésiculaire étendu au hile
- Carcinomatose péritonéale
- ADP métastatiques



Obstacle hilaire : est ce un cancer d'une autre origine ?

Malins

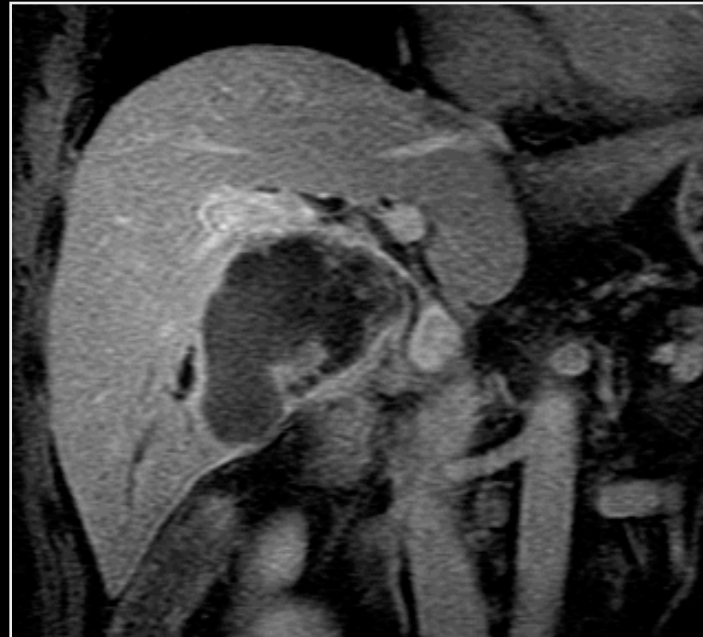
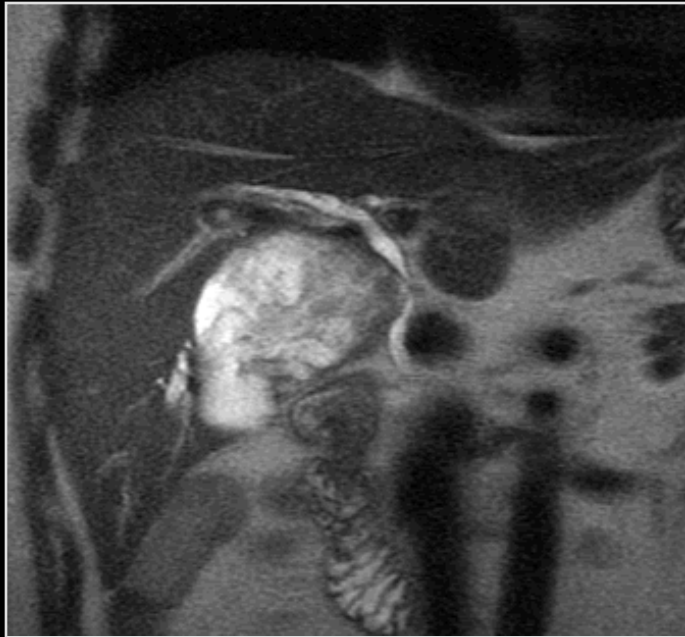
ADK pancréas

ADK sillon

ADK vésiculaire étendu au hile

Carcinomatose péritonéale

ADP métastatiques



Obstacle hilaire : est ce un cancer d'une autre origine ?

Malins

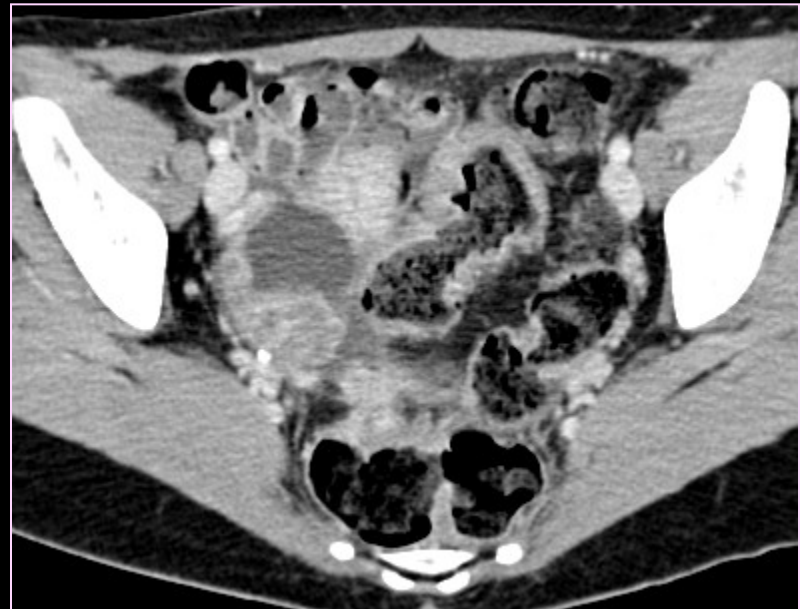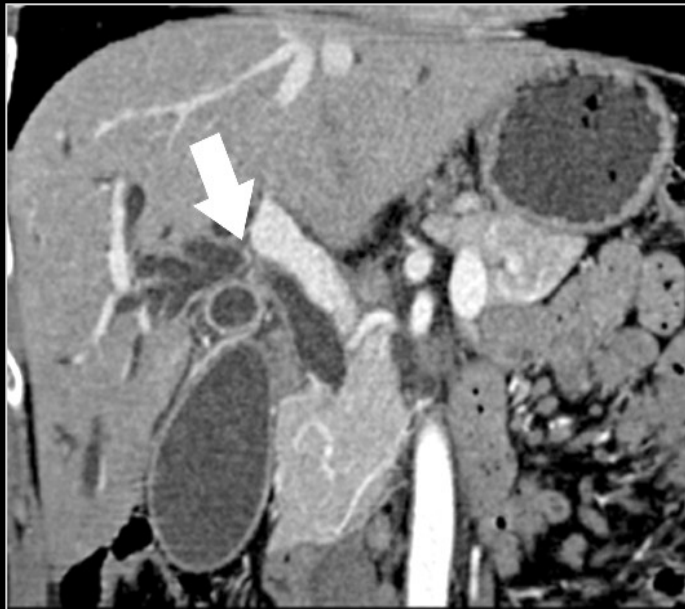ADK pancréas

ADK sillon

ADK vésiculaire étendu au hile

Carcinomatose péritonéale

ADP métastatiques



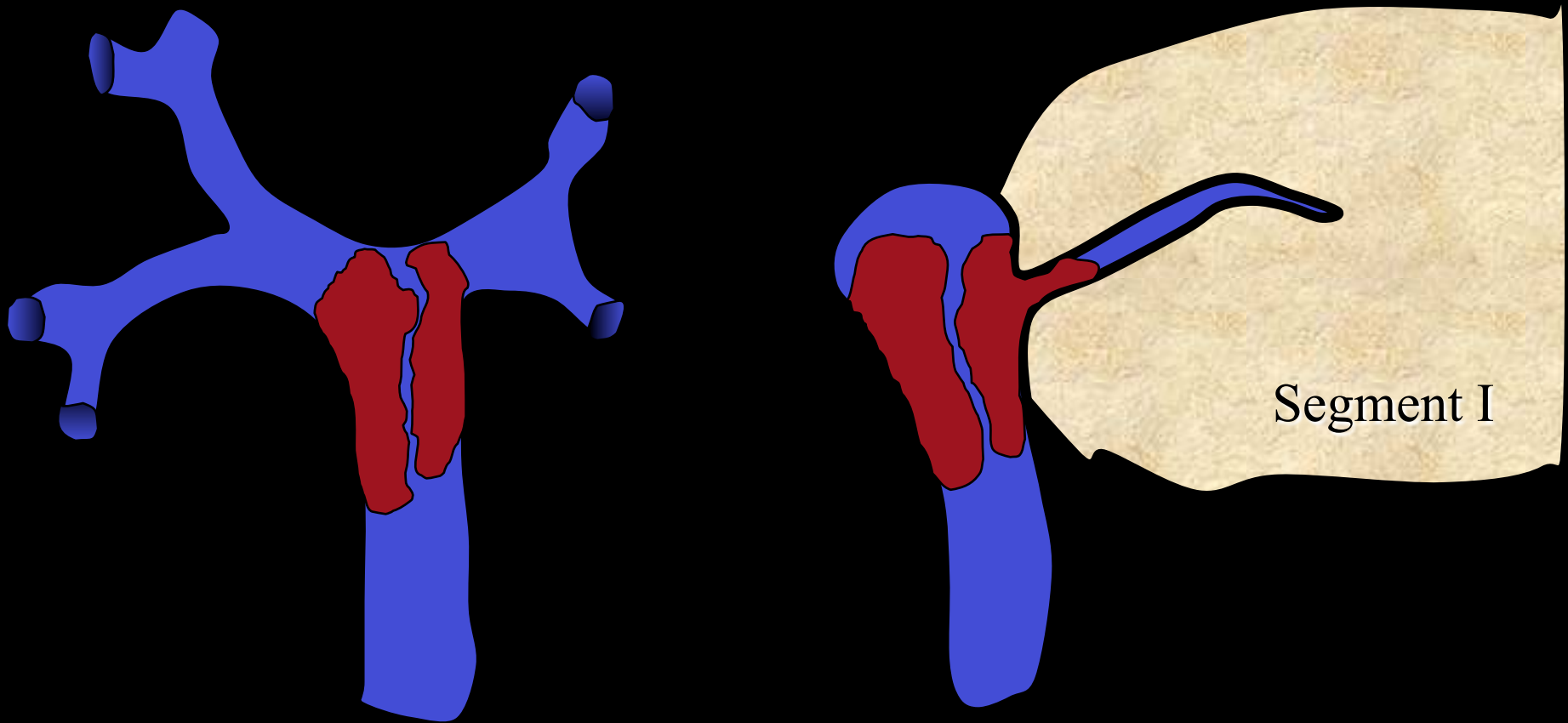
Obstacles Hilaires, c' est un cholangiocarcinome :
Existe il une possibilité curative ???

Dans quelles conditions ???

Critères d'irrésécabilité chirurgicale

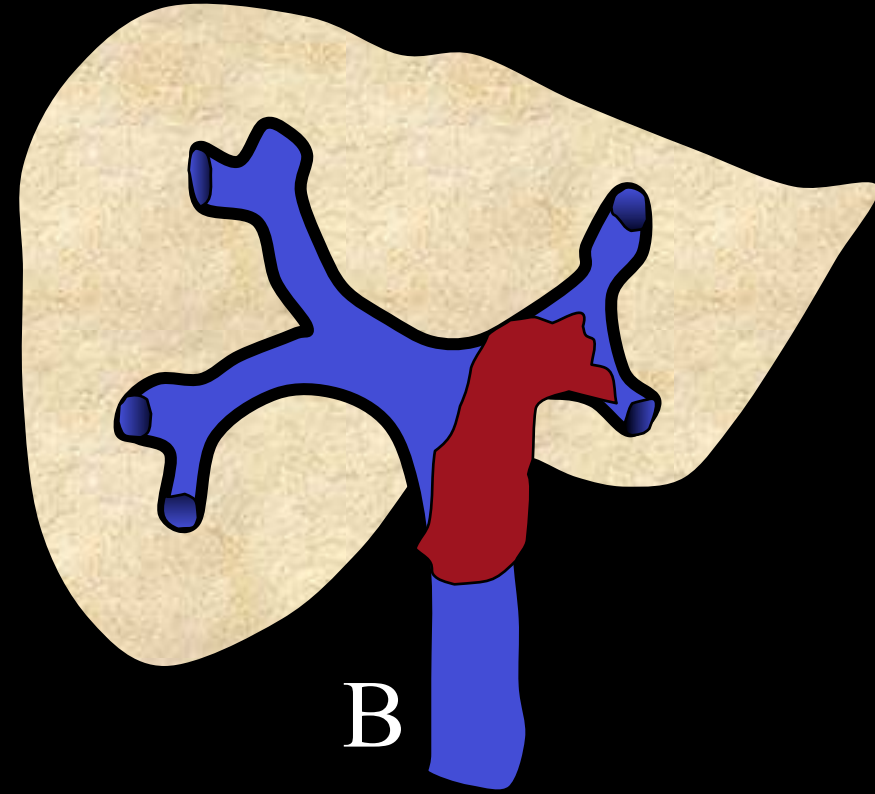
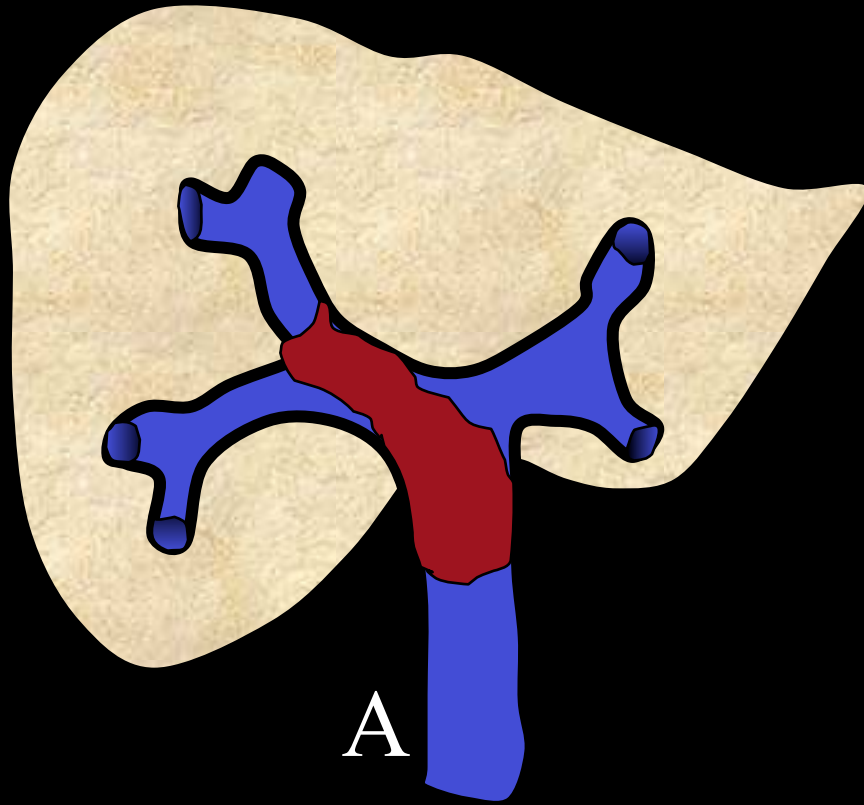
- Volumineuse masse hilaire
- Critères biliaires
 - Pôle supérieur atteignant les convergences secondaires de façon bilatérale
- Critères vasculaires
 - Atteinte des trois veines sus hépatiques
 - Atteinte artérielle bilatérale
 - Atteinte vasculaire unilatérale associée à une atrophie controlatérale
- Critères parenchymateux hépatiques
- Extension extra hépatique

**Une seule vraie question:
La convergence est-elle atteinte ?**



Type II: la convergence est atteinte. Le segment I doit être enlevé

**La convergence est-elle atteinte ?
Si oui: reste-il un canal dérivable ?**



Type III : Extension dans 1 seul des deux canaux hépatiques.

Droit (III A) ou gauche (IIIB)

Une hépatectomie homolatérale à l'atteinte, élargie au I, est nécessaire

Extension biliaire

Classification de Bismuth et Corlette

Cholangiogramme :

coupes épaisses 20 mm

Limites :

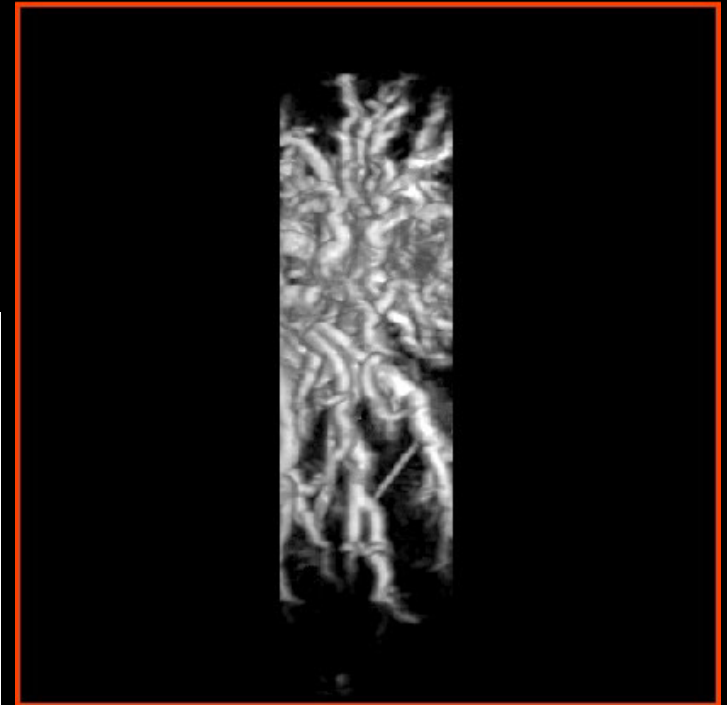
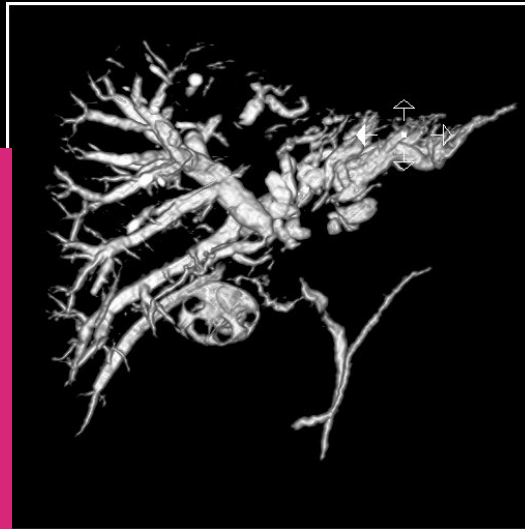- superpositions ++
- Pas de coupes fines
- Difficulté d'analyse de la zone pathologique



Cholangiogramme en 3D

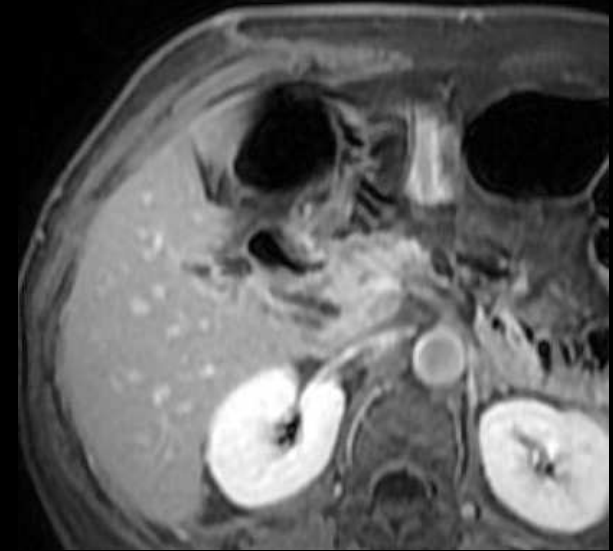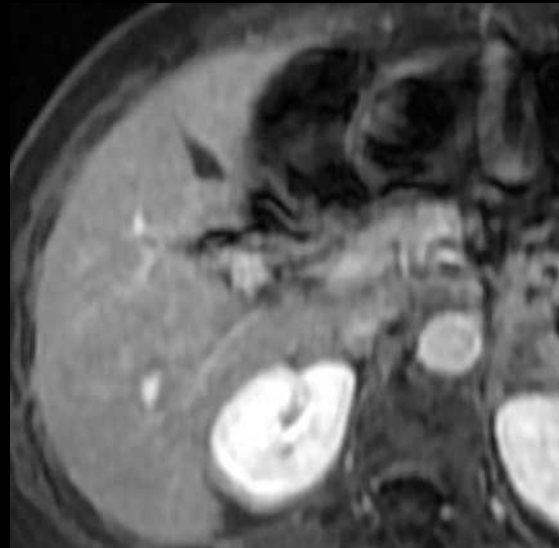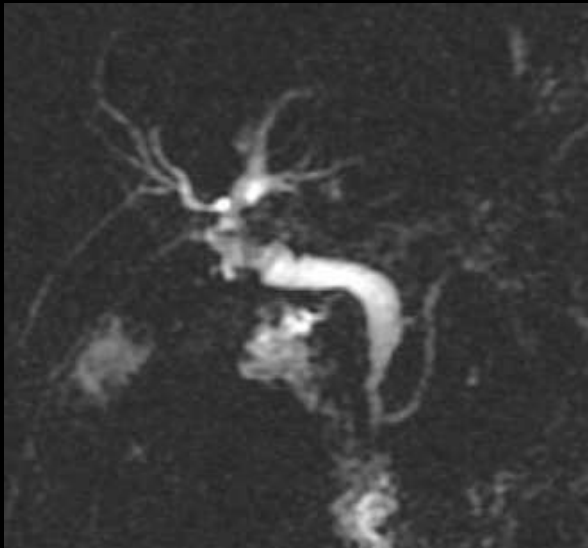
Intérêts :

- Pas de superpositions ++
- Coupes fines ++++
- Reformations multiplanaires sur la zone intéressante



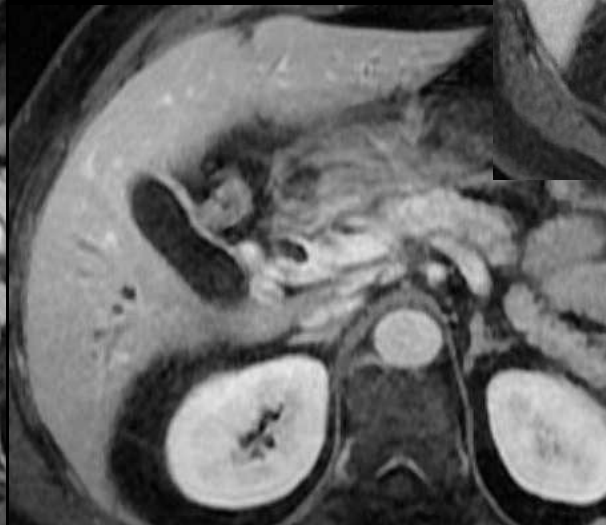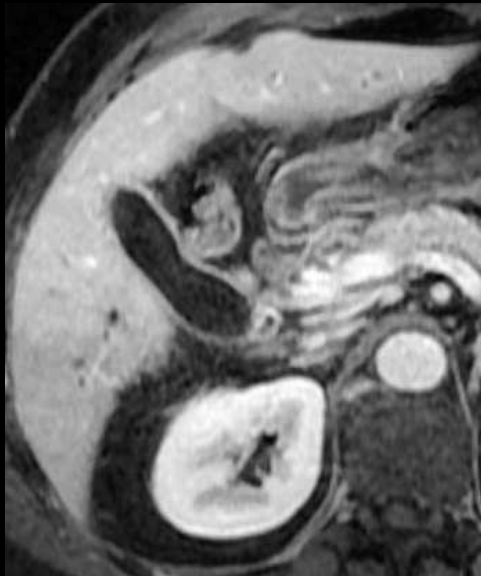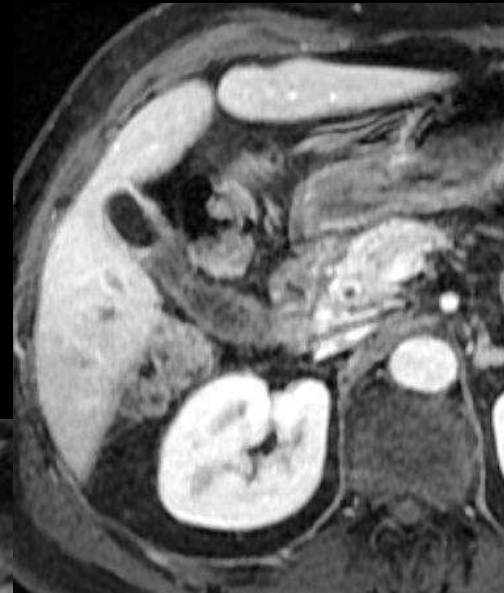
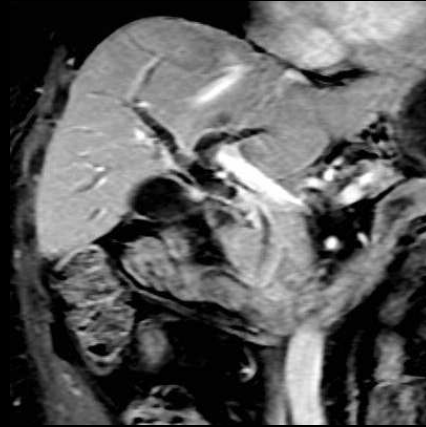
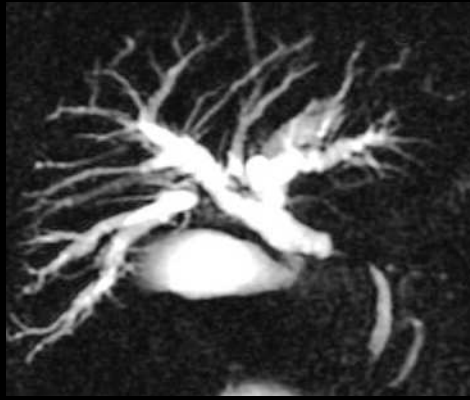Extension biliaire

Classification de Bismuth et Cornette



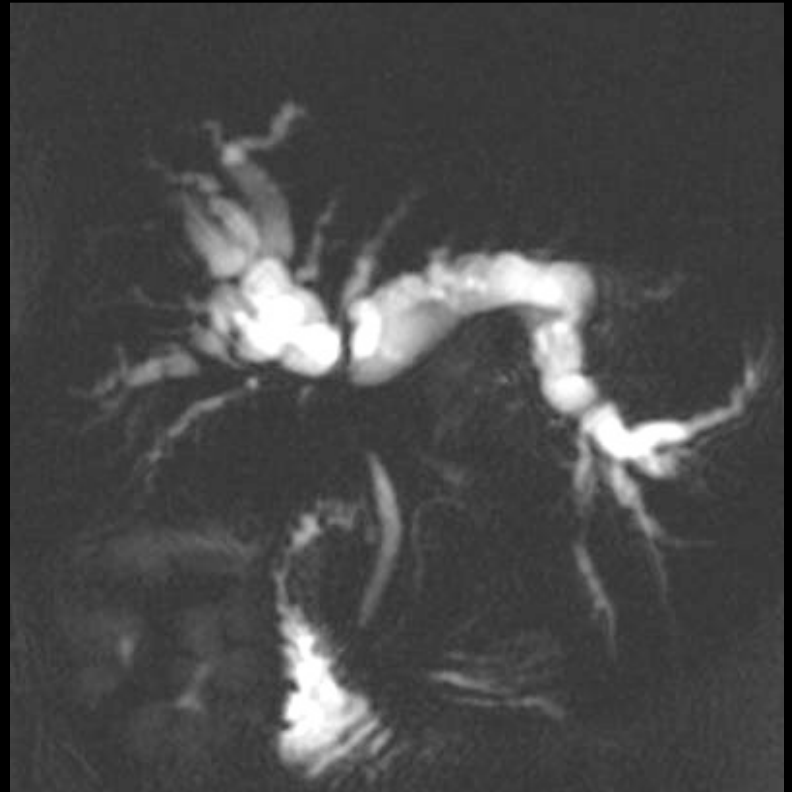
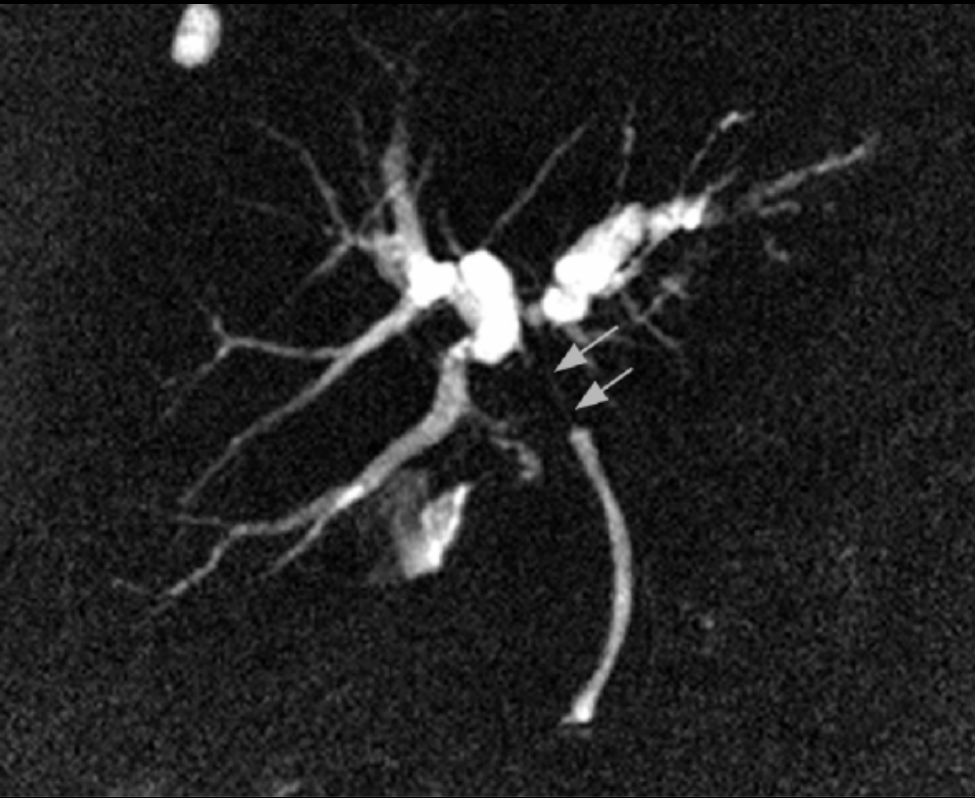
Extension biliaire

Classification de Bismuth et Cornette

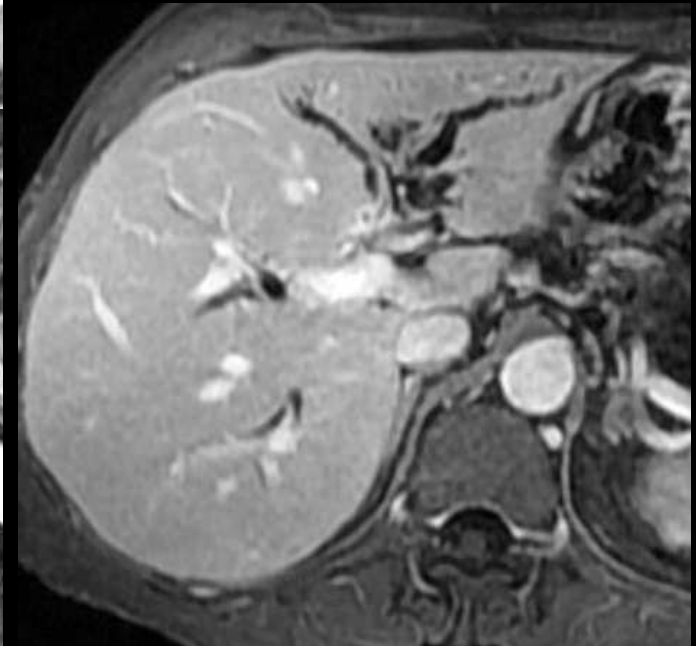
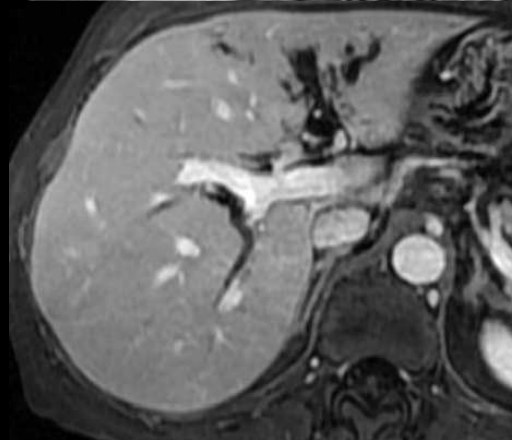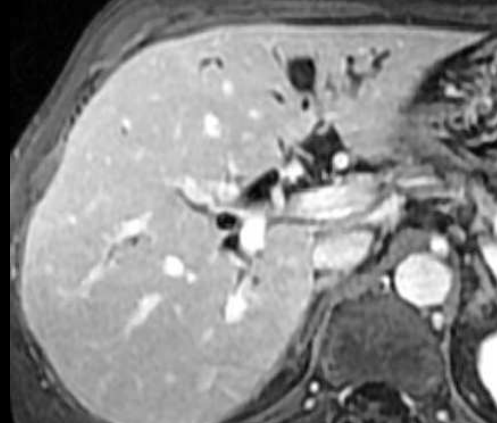
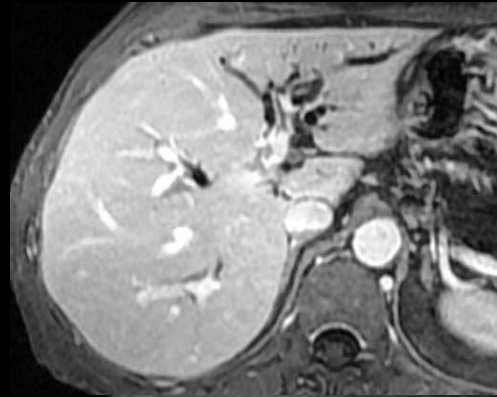
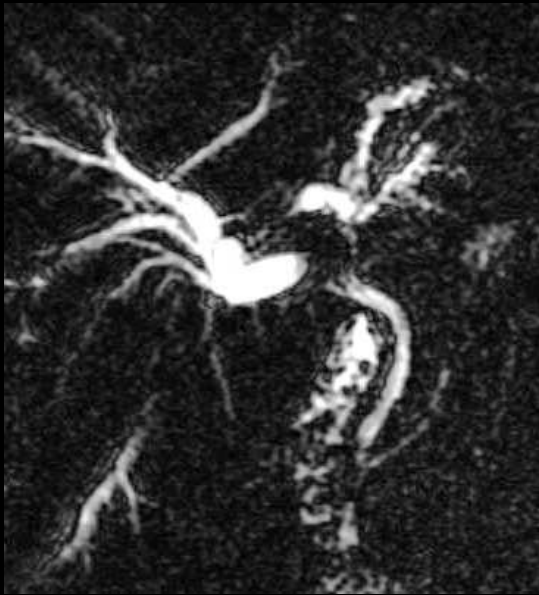


Extension biliaire

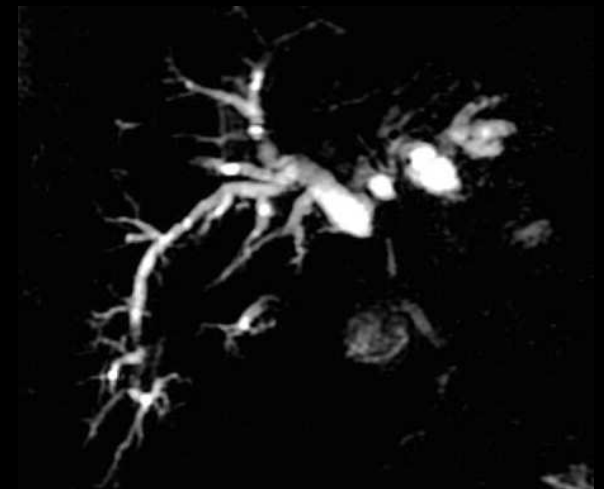
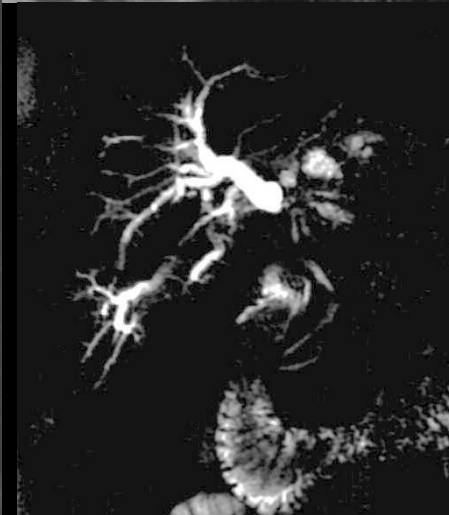
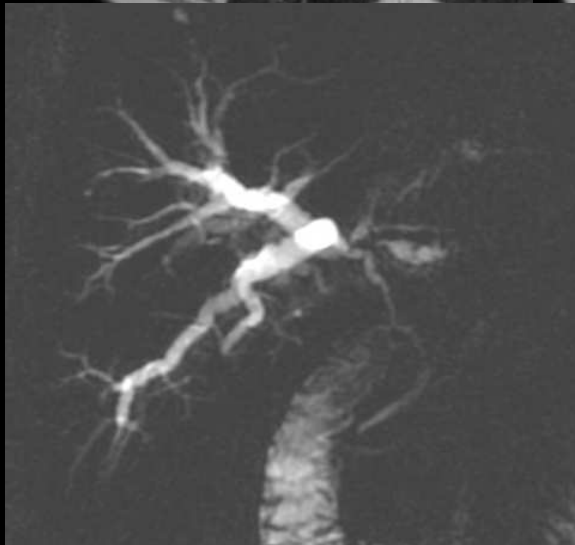
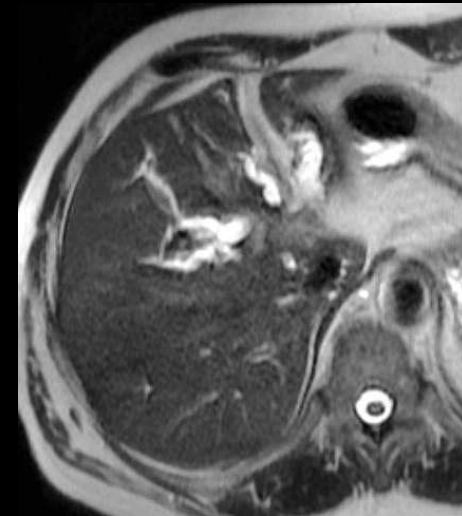
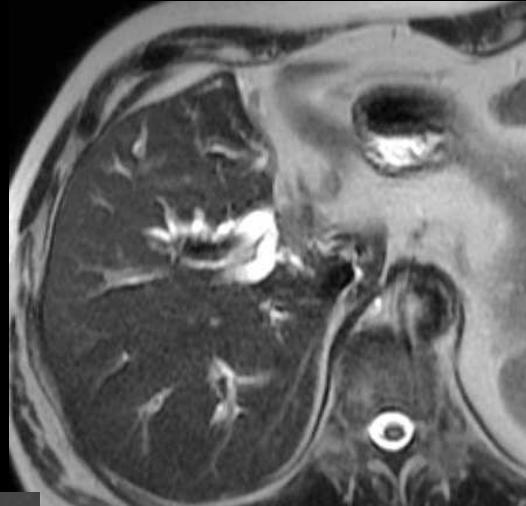
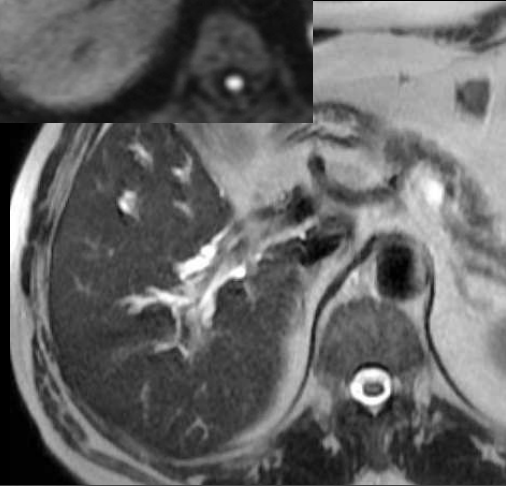
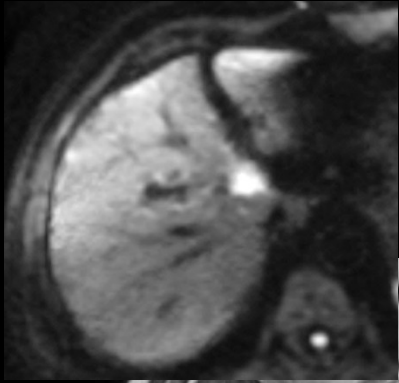
Classification de Bismuth et Cornette



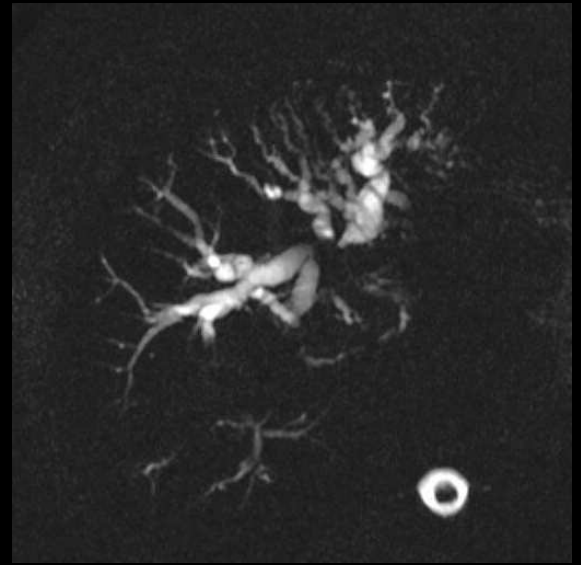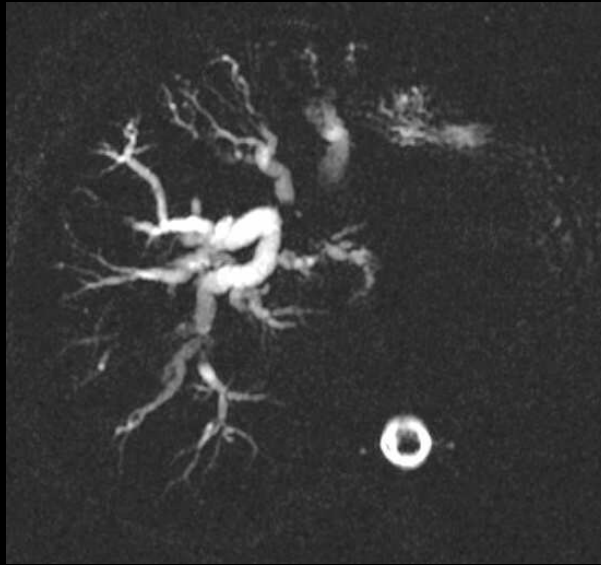
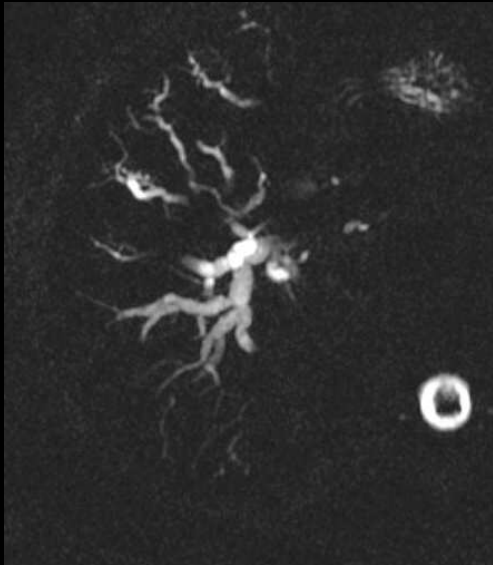
Extension biliaire



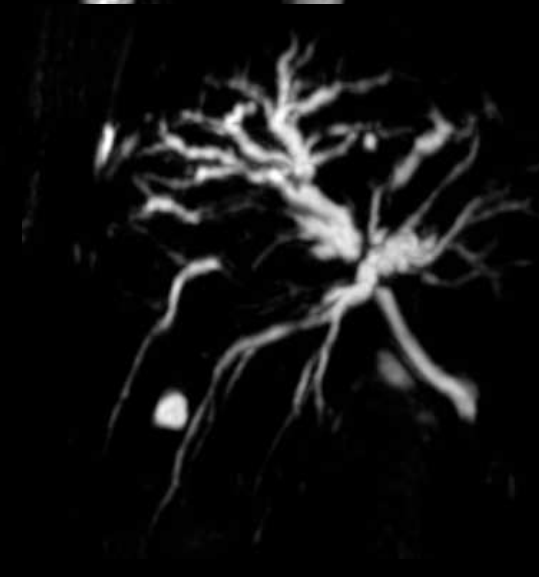
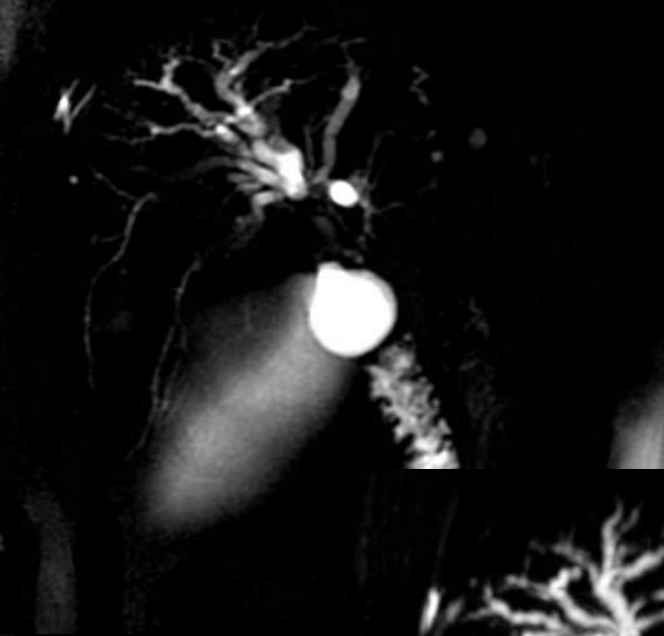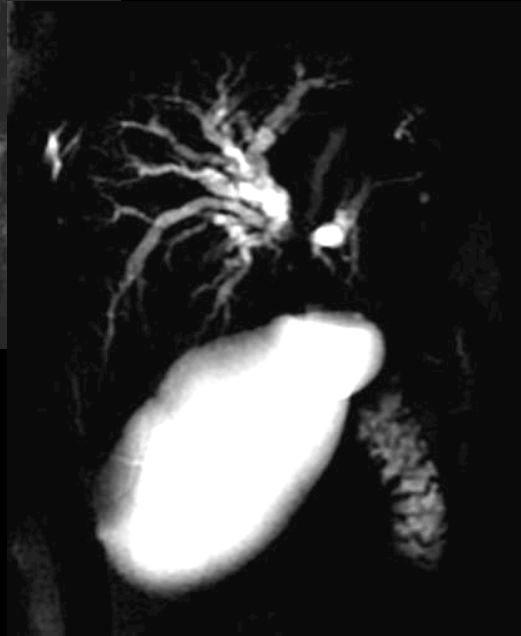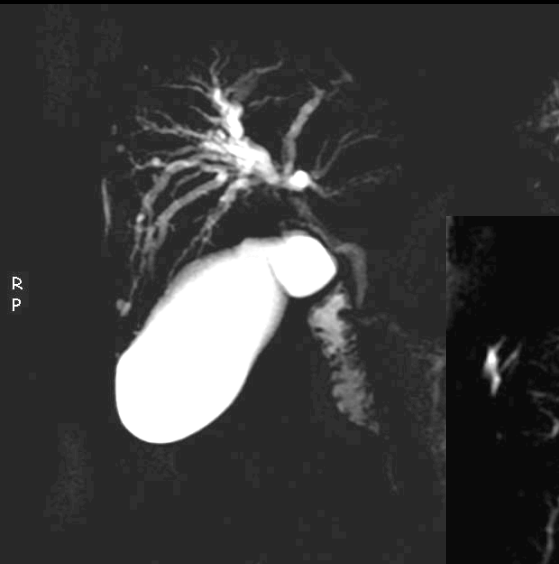
Extension biliaire



Extension biliaire



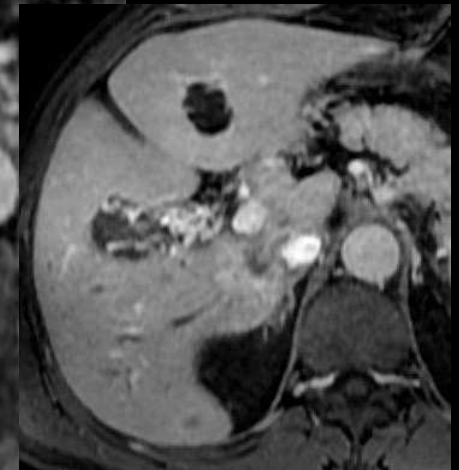
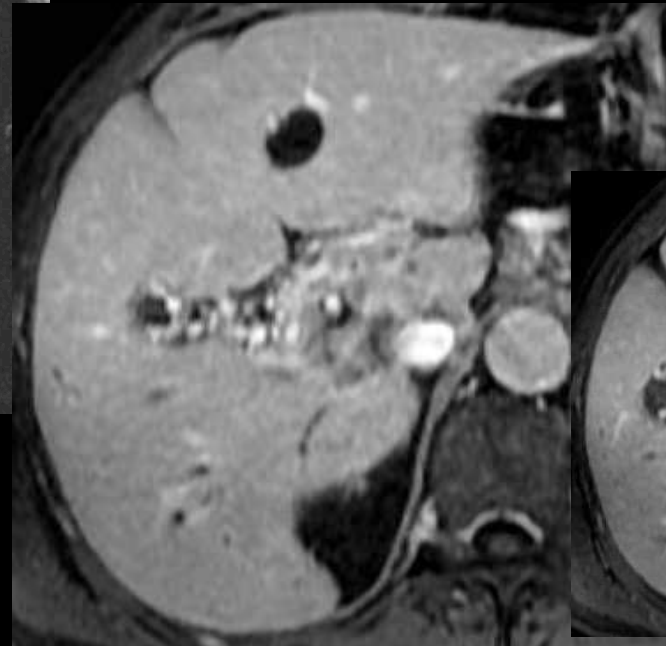
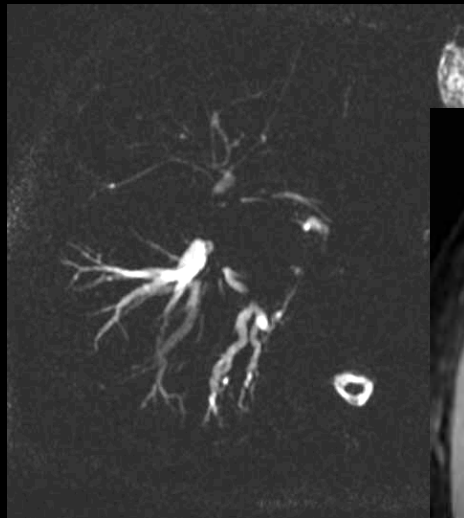
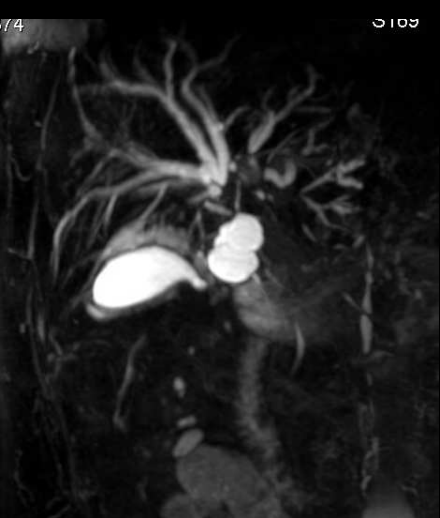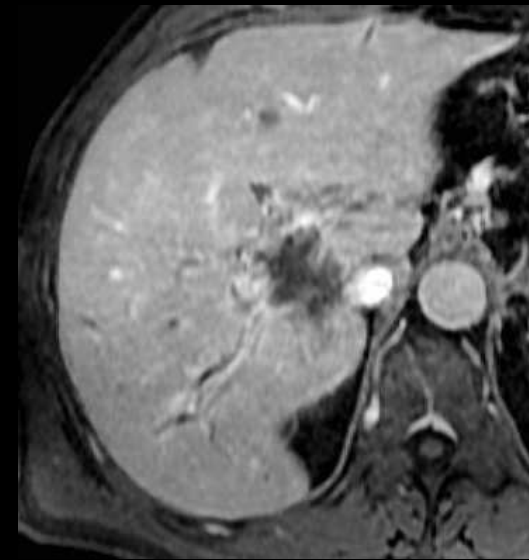Extension biliaire



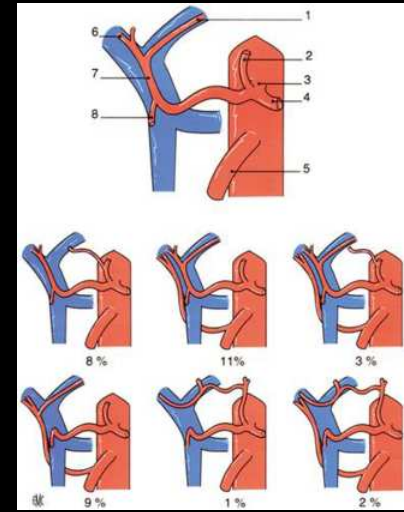
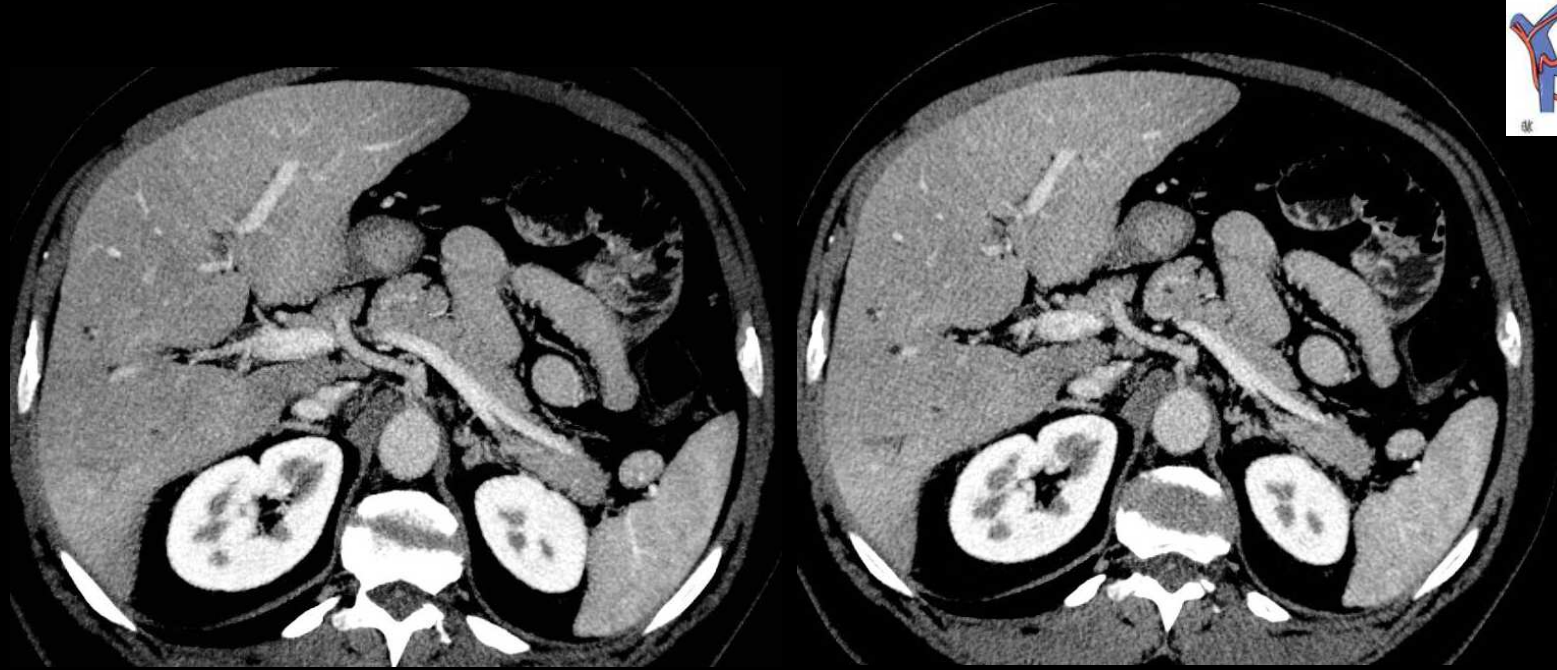
Extension artérielle

Bilan artériel :

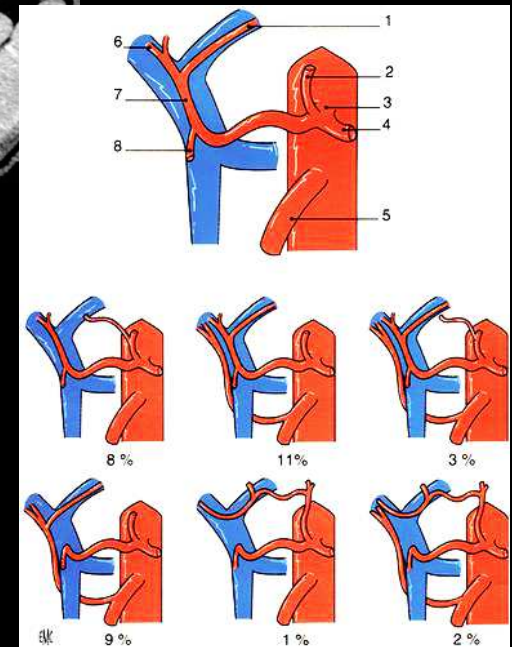
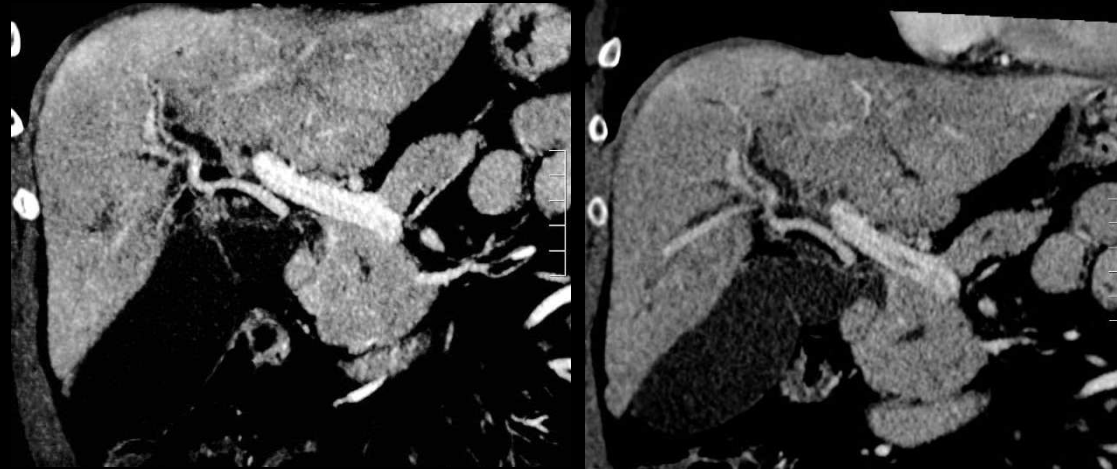
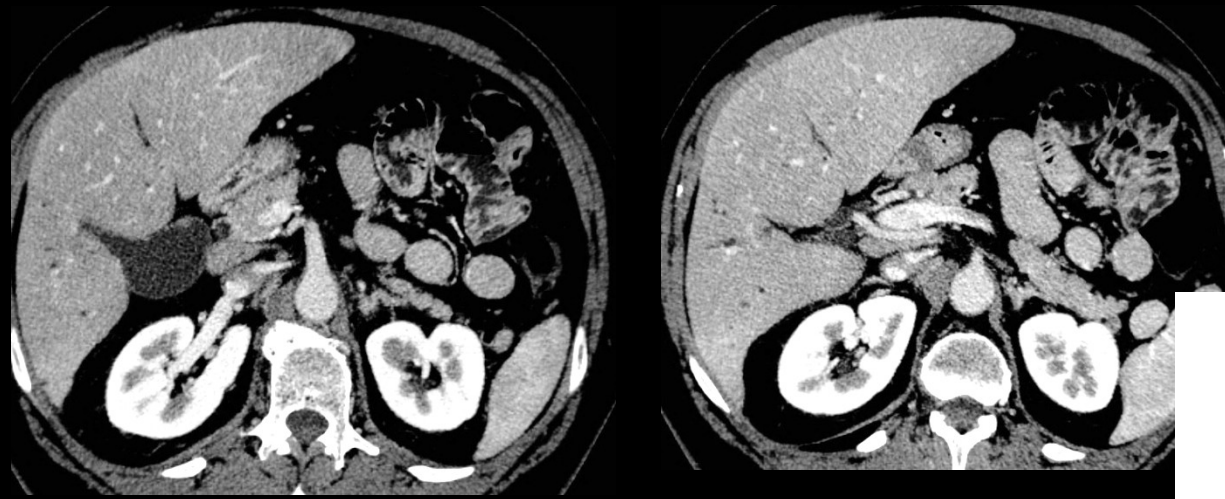- Siège de la lésion/artère hépatique commune et aux branches de l'artère hépatique
- Préciser si engainement (en degrés), sténose ou thrombose
- Préciser si distribution normale ou si présence de variantes anatomiques



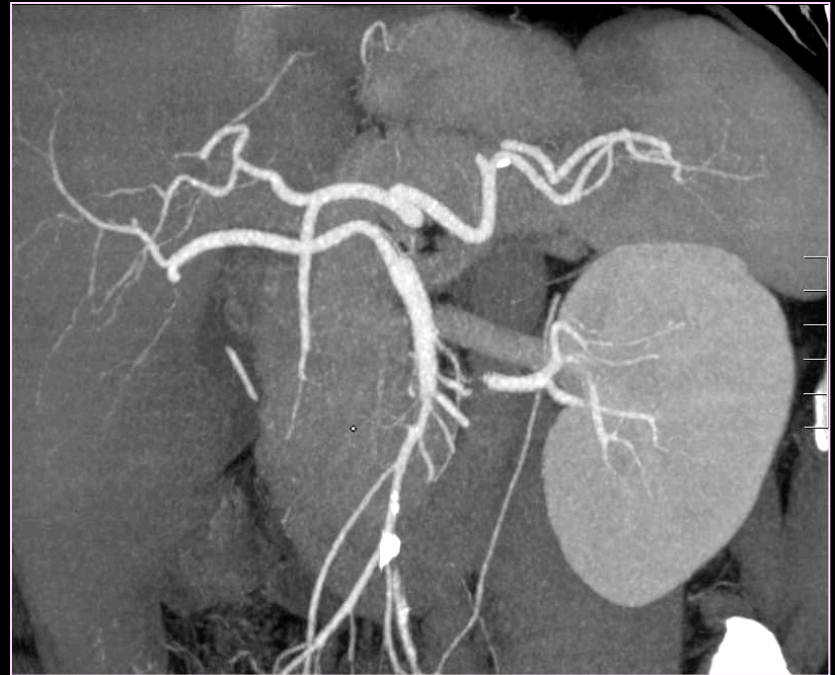
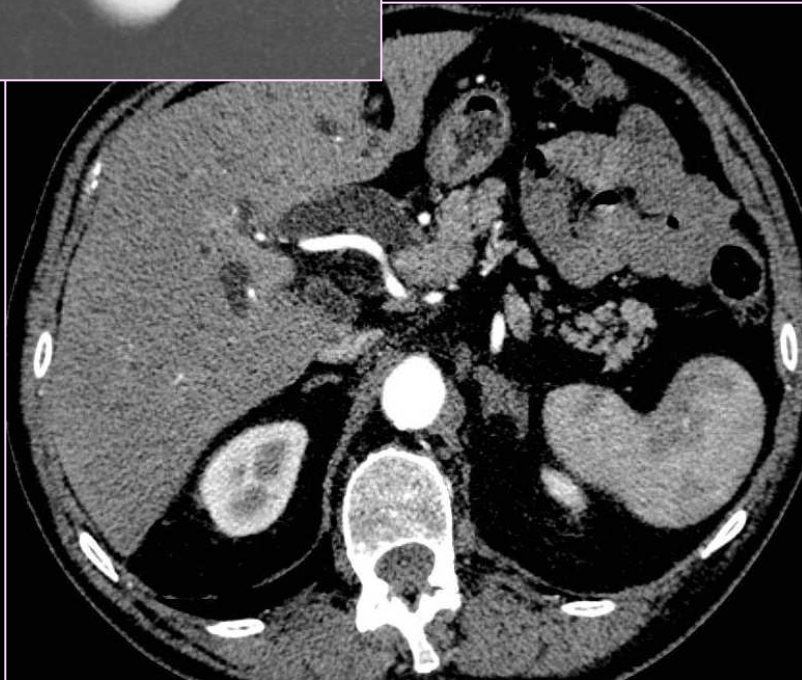
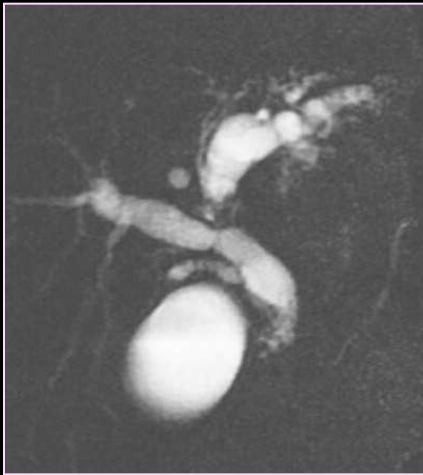
Extension artérielle



Extension artérielle

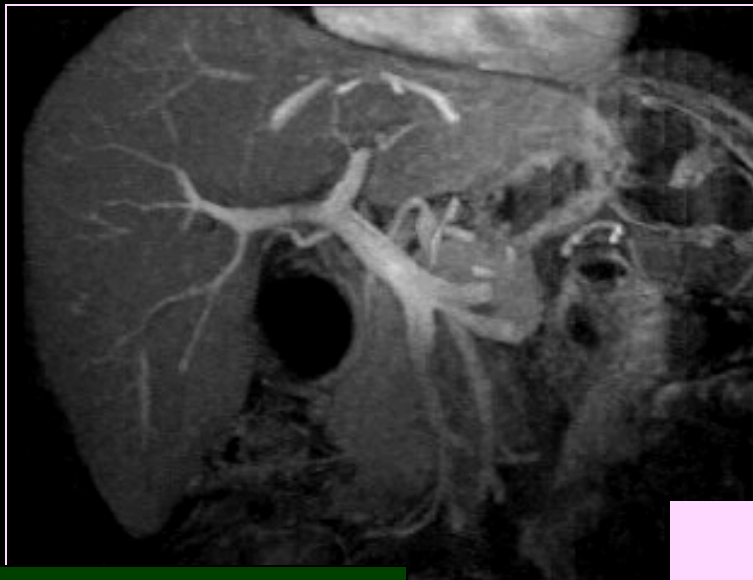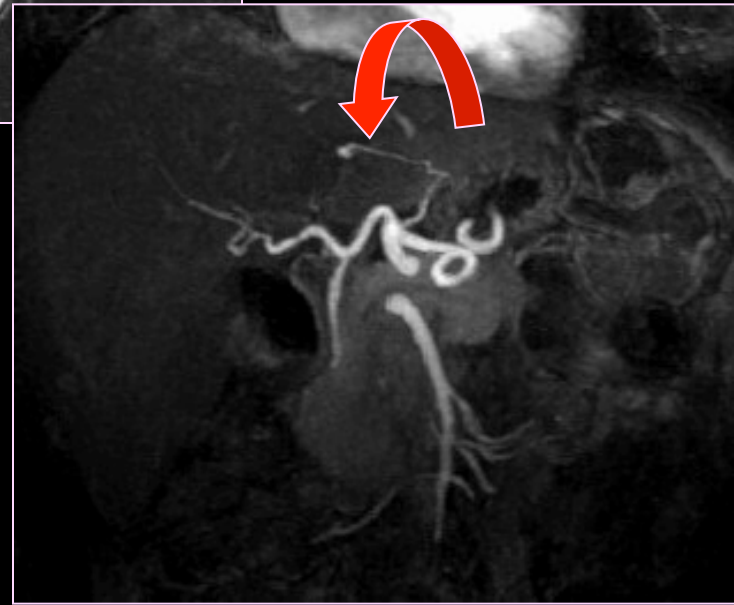
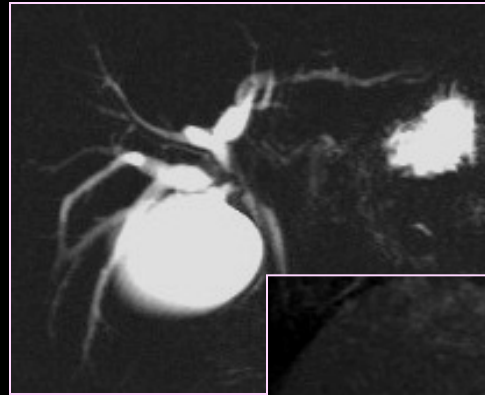
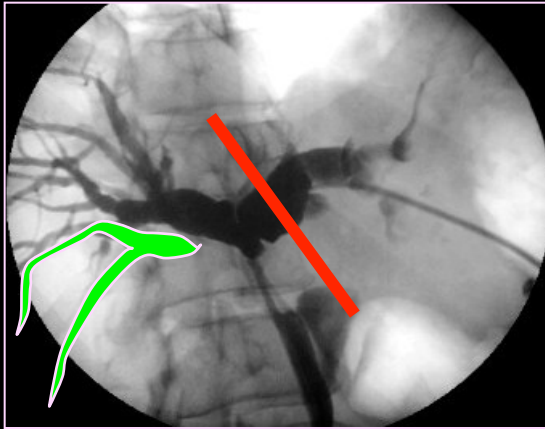


Extension artérielle



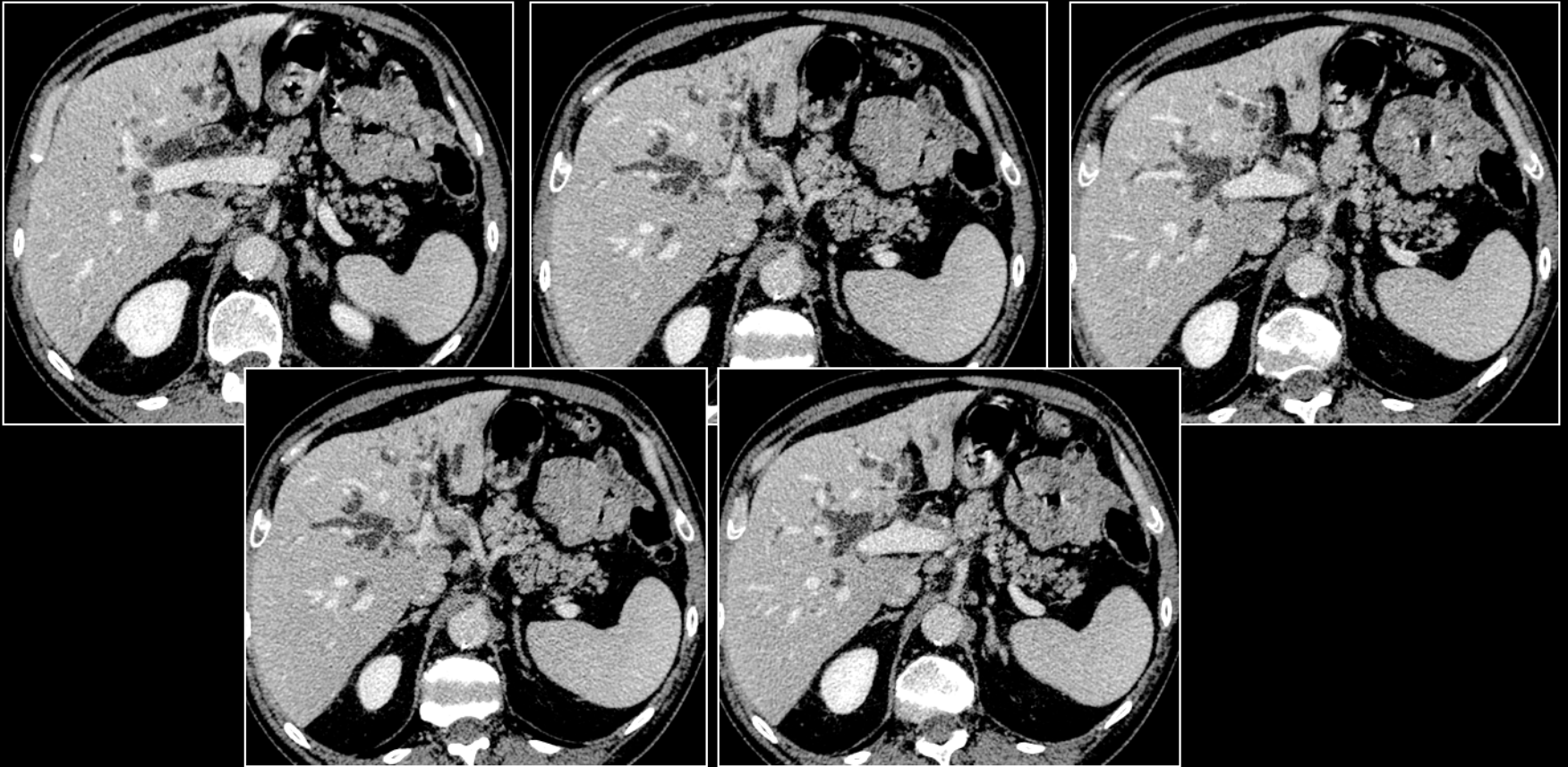
Artère hépatique droite naissant de l'AMS

Extension artérielle



Artère hépatique gauche naissant de l'artère coronaire stomacachique

Extension portale

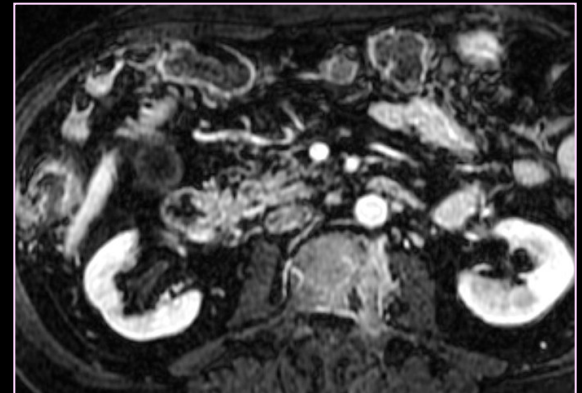
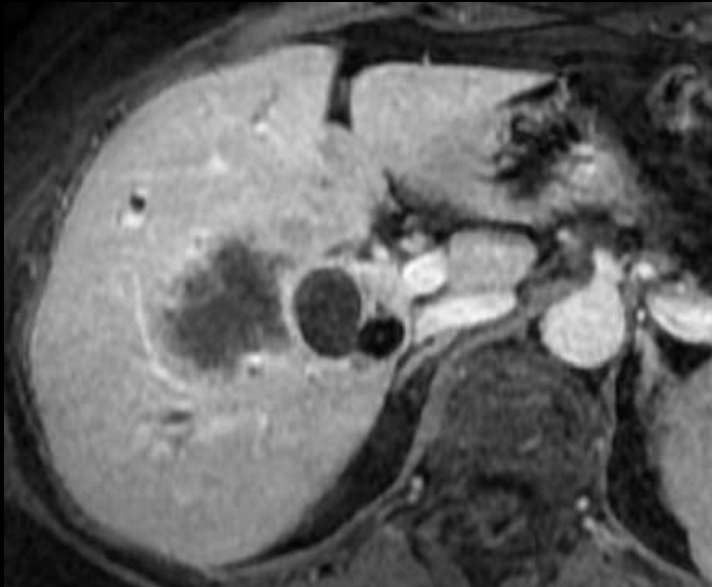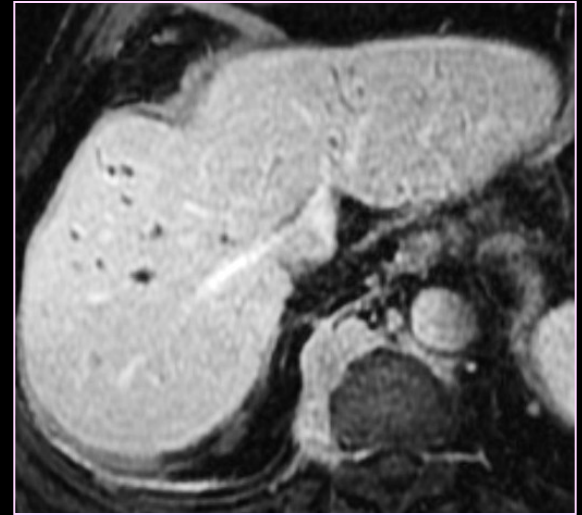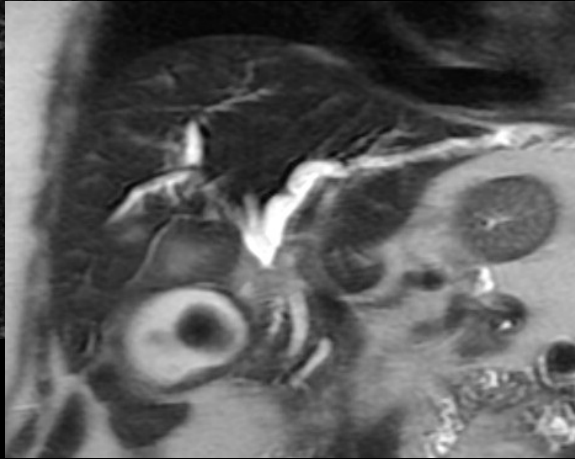
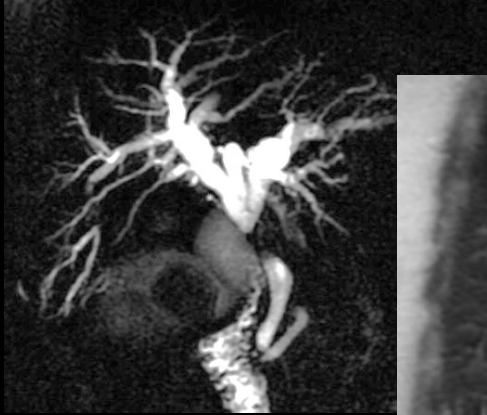


Critères d'irrésécabilité chirurgicale

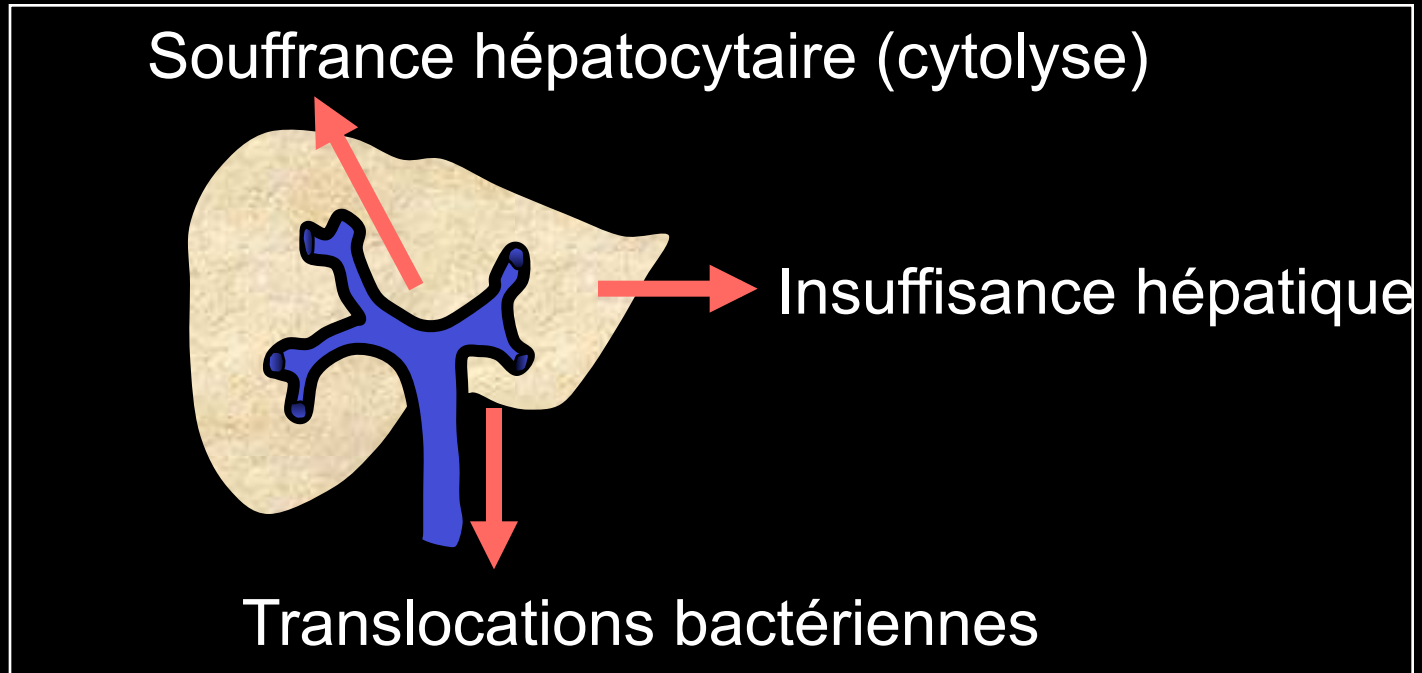
- Soriano et al. Am J Gastroenterol 2004, 99 : 492-501.
 - Comparaison scanner,echoendoscopie, IRM ,angiographie
 - Atteinte vasculaire : **scanner hélicoidal >> autres techniques**
- Comparaisons angio scanner/Chir.
 - Envahissement portal
 - Diag.+ : 85,5 % - 94,4%
 - Envahissement artère hépatique
 - Diag.+ : 88,9% - 92,7%

Lee, Radiology 2006

Extension à distance



Comment le radiologue peut-il participer à l'« optimisation » hépatique ?

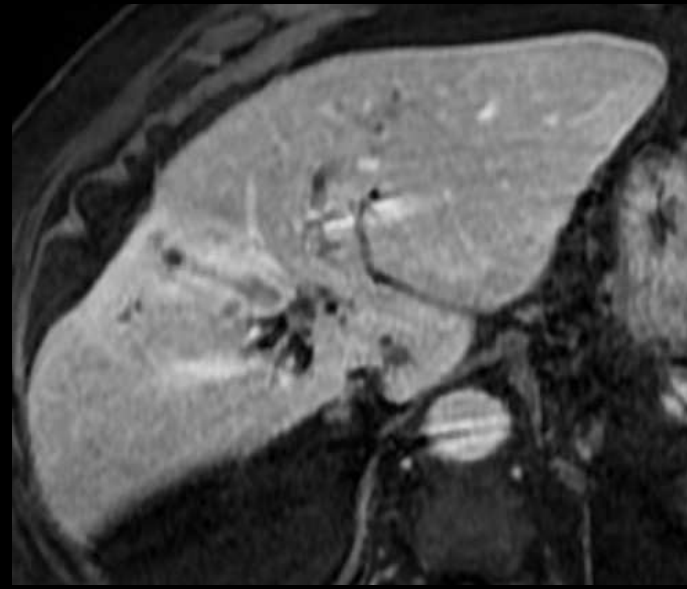
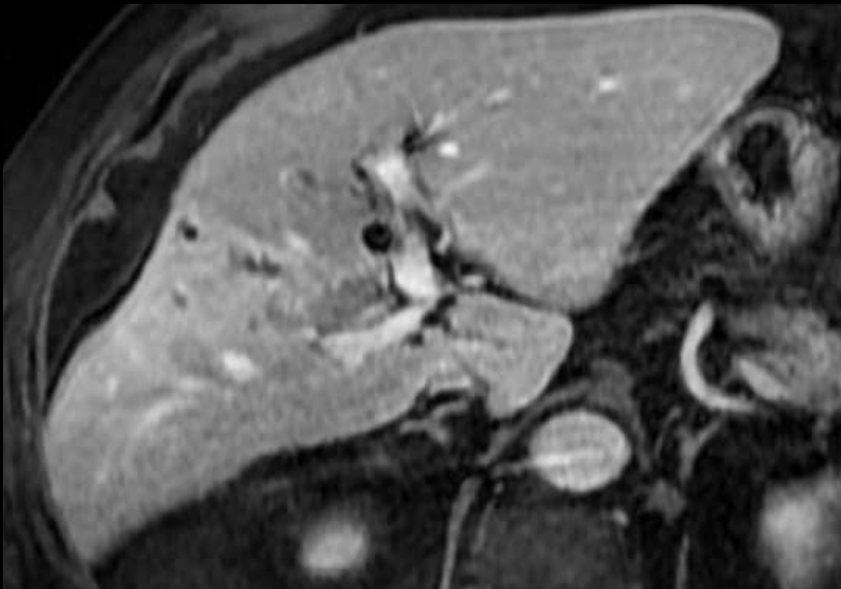


- Drainage biliaire
- Embolisation portale

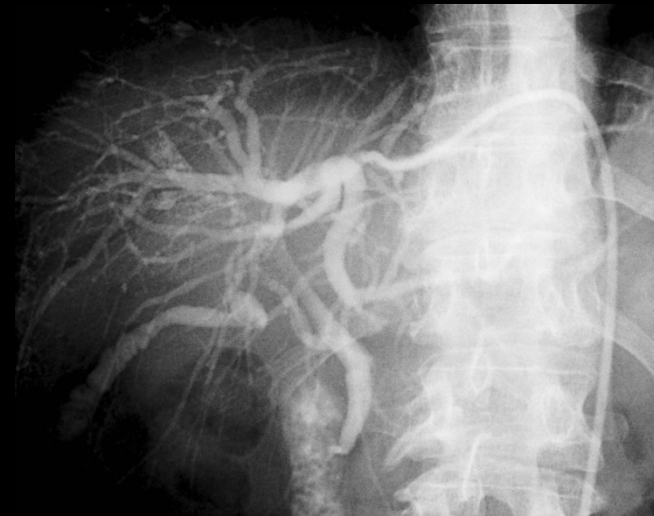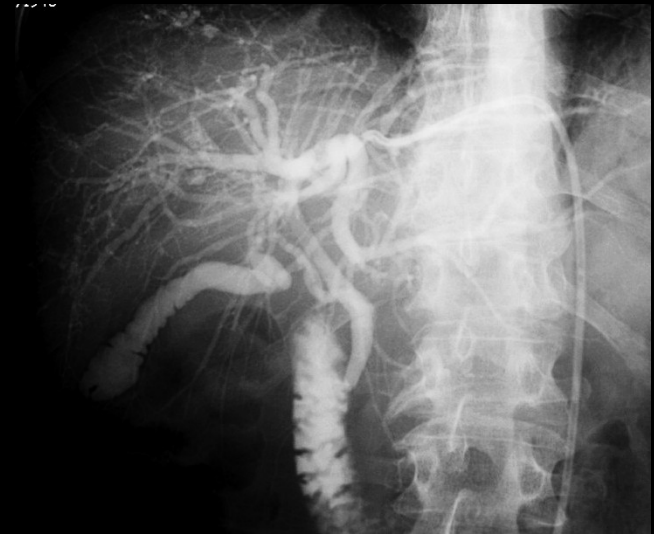Etat du parenchyme hépatique sous jacent

Morphologie

Volumétrie du parenchyme hépatique restant



Drainage
Embolisation portale



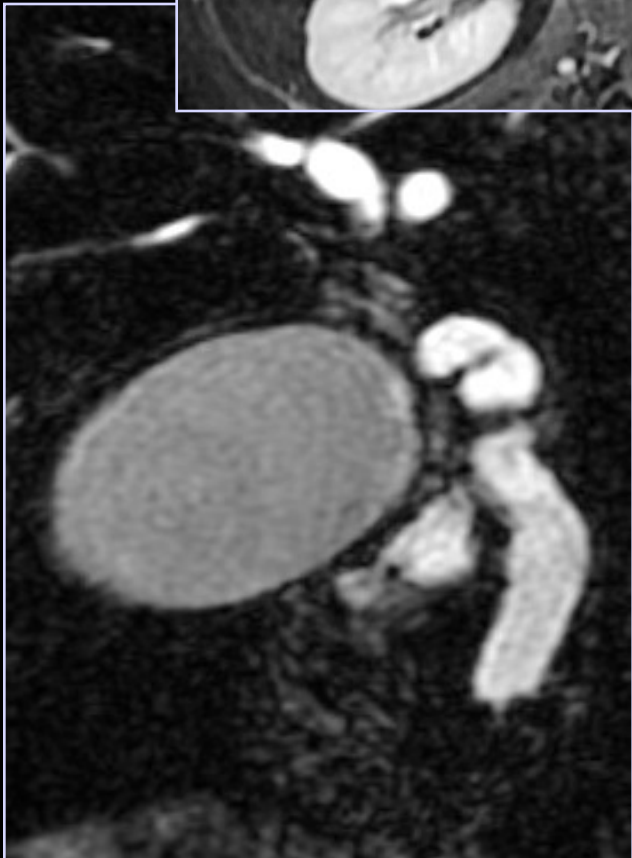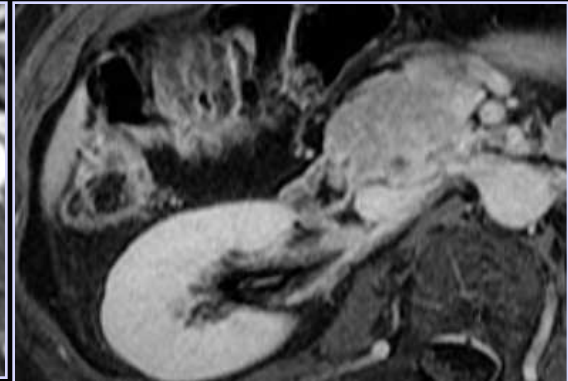
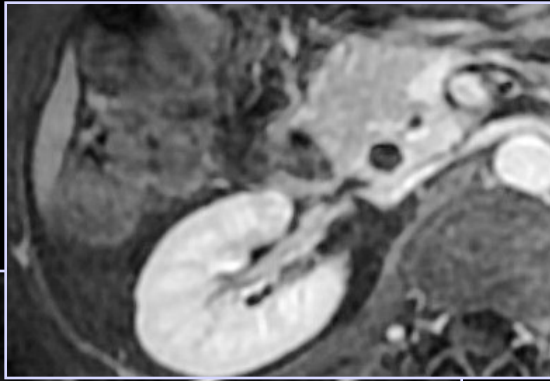
Plan

- **Tumeurs de la vésicule biliaire**
- **CCK IH**
- **CCK hilaires**
 - Diagnostic positif
 - Bilan d'extirpabilité
- **Tumeurs du bas cholédoque**

Cholangiocarcinomes du bas cholédoque

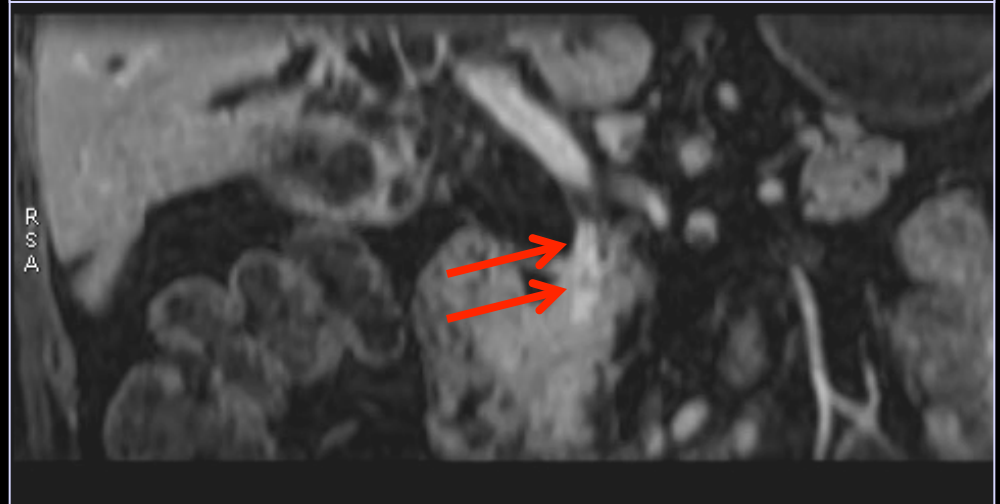
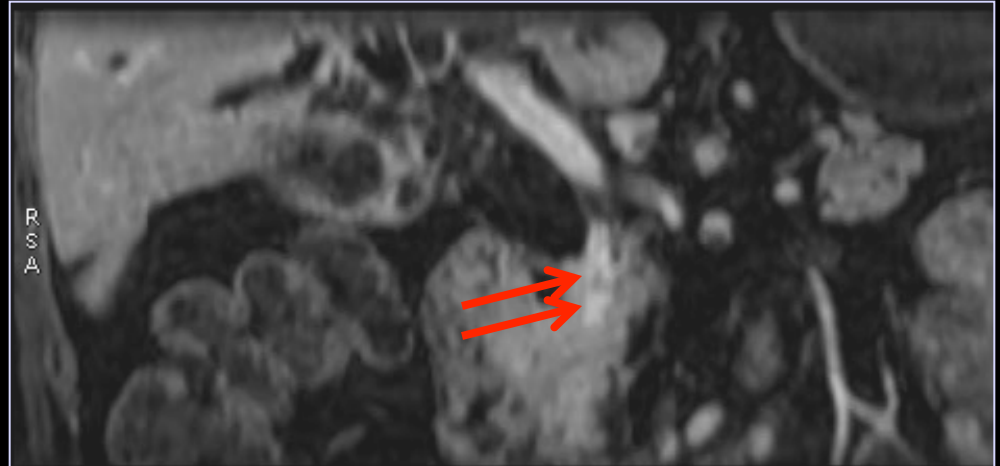
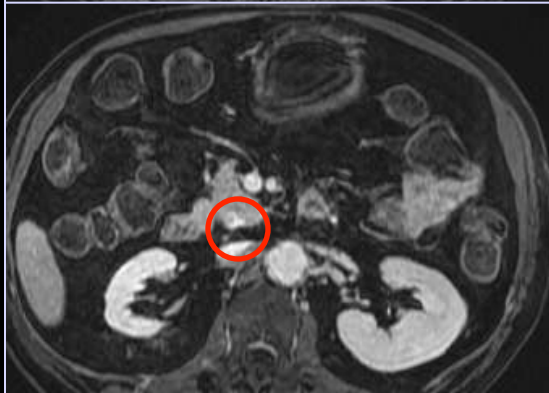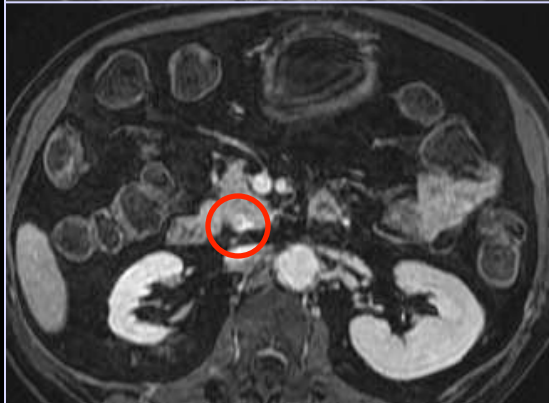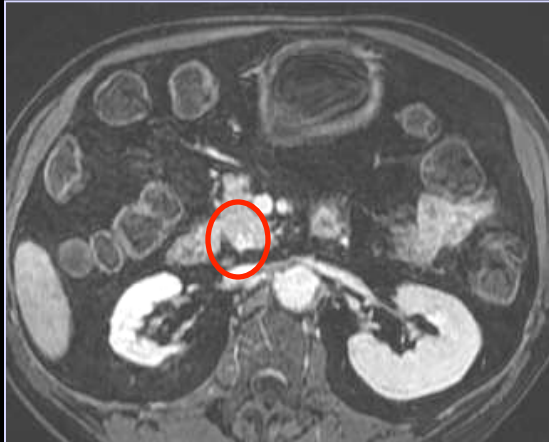IV. Cholangiocarcinomes du bas cholédoque

Forme infiltrative



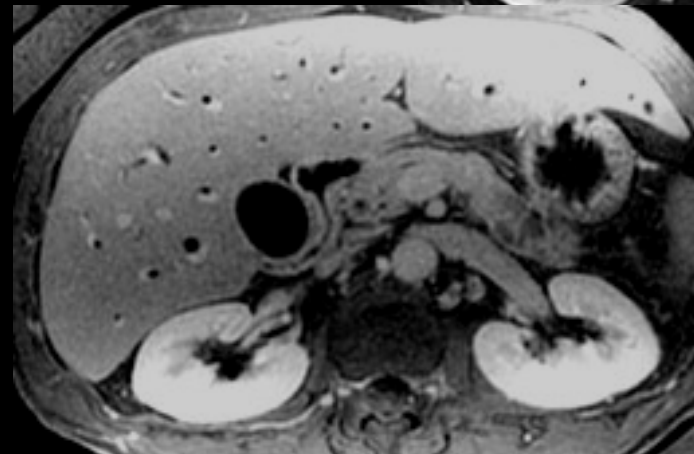
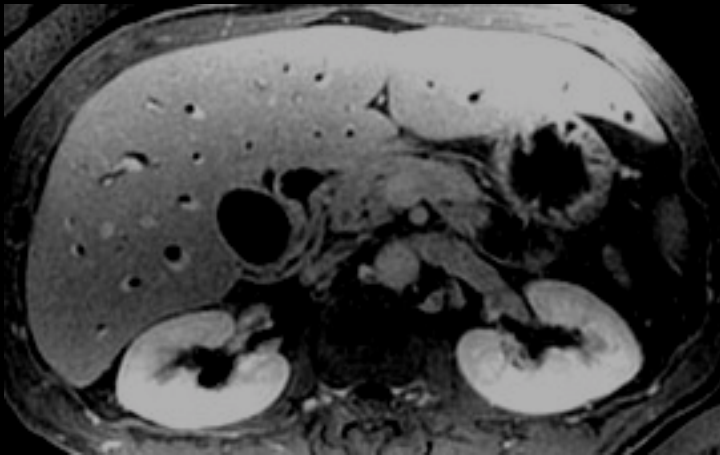
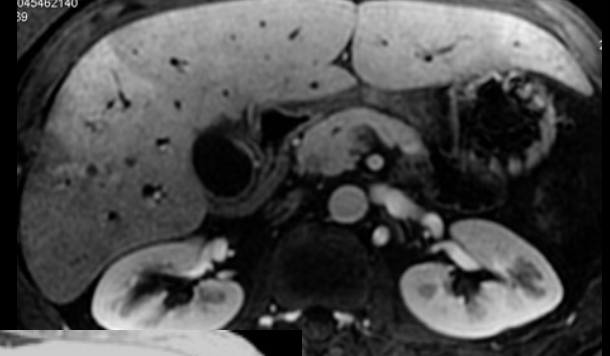
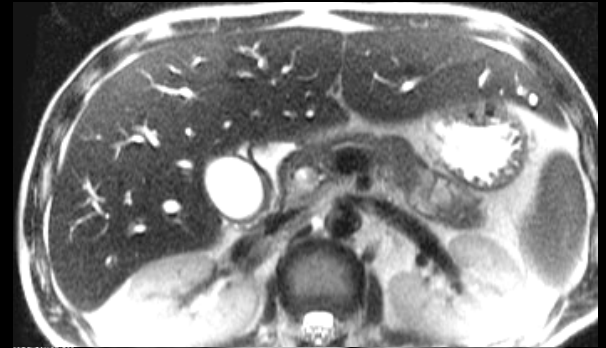
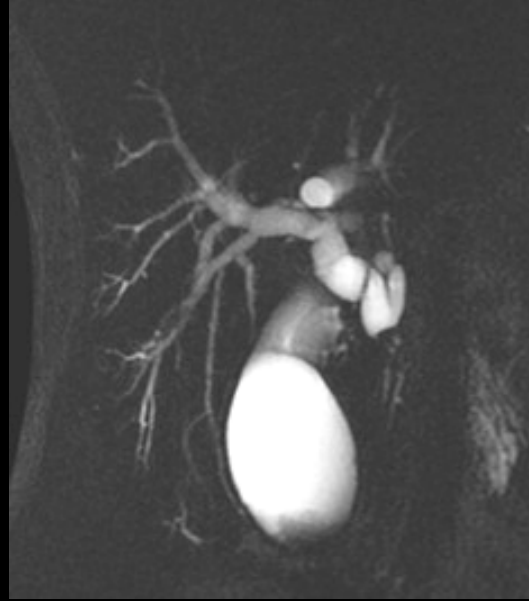
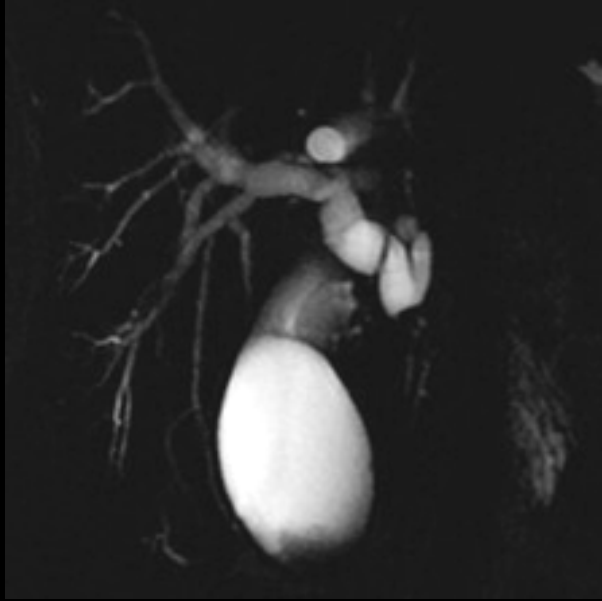
Cholangiocarcinomes du bas cholédoque

Forme infiltrative

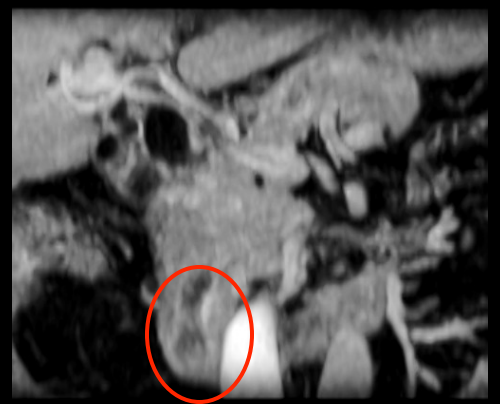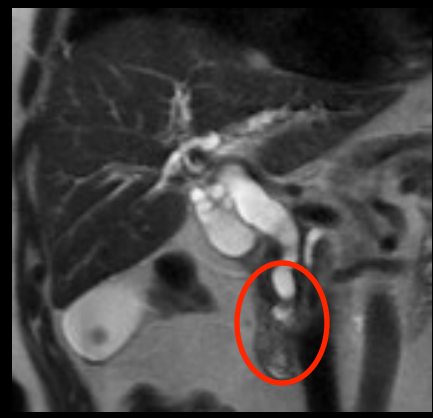
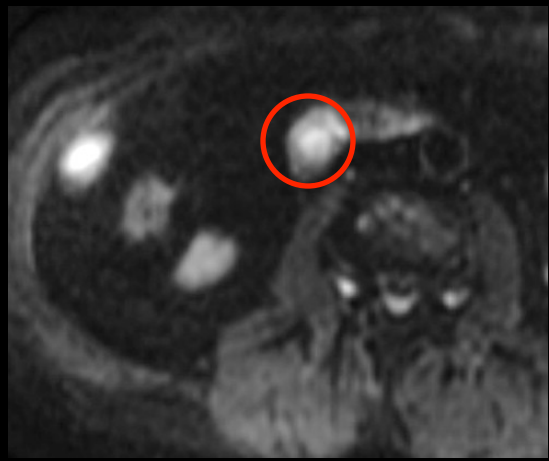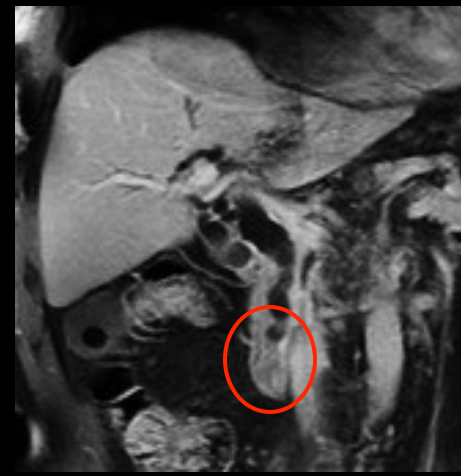
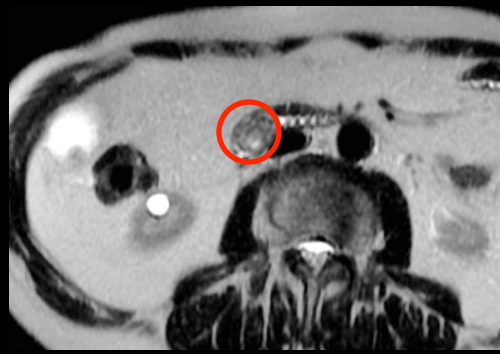
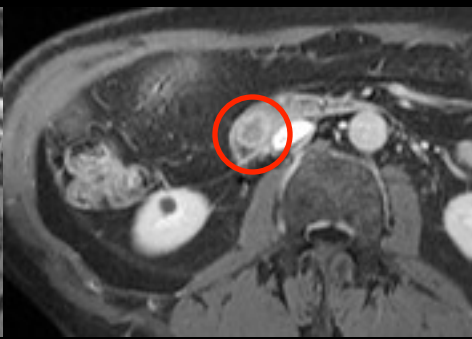


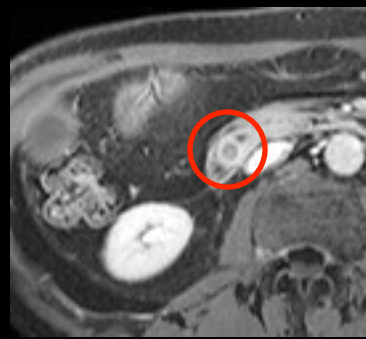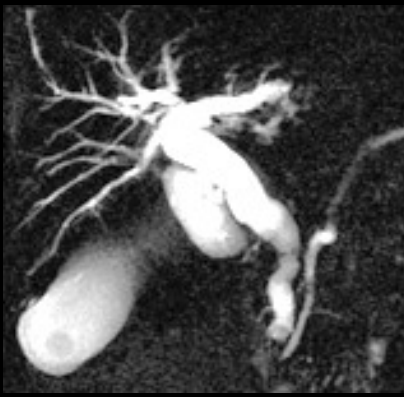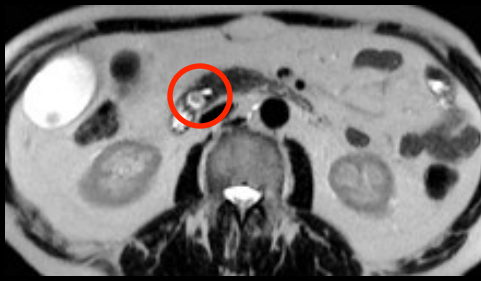Cholangiocarcinomes du bas cholédoque

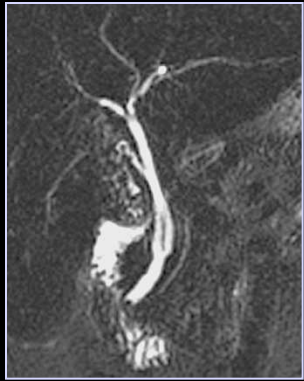Diagnostic différentiel ADK pancréas



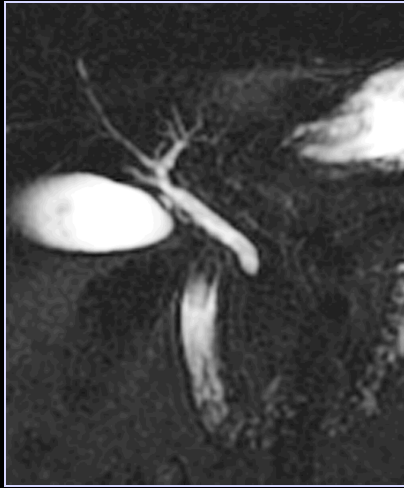
Ampullomes



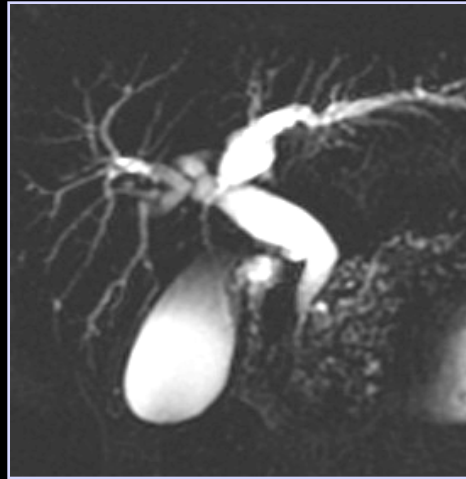
Sténoses bénignes



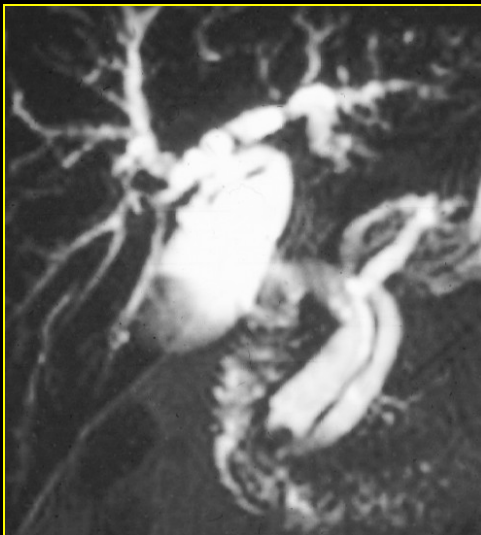
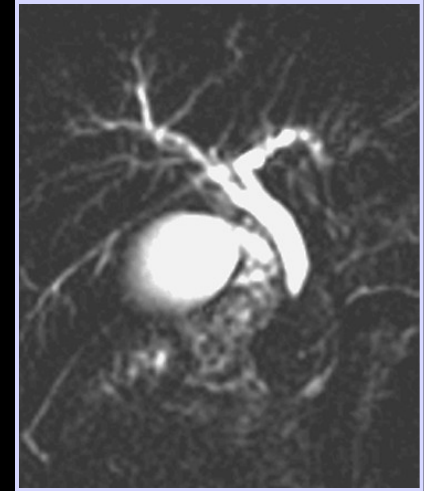
Lithiasique



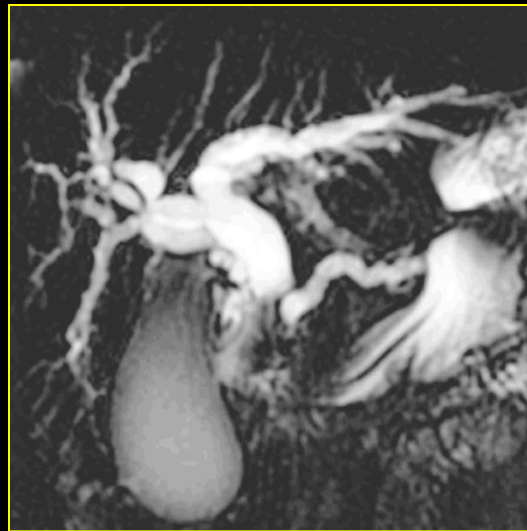
Oddite



Pancréatites



Ampullome



ADK

Sténoses malignes

Conclusion

- **Masse hép centrée par la vésicule avec extension hilare**
 - CCK vésiculaire
 - FDR : Long common channel
- **Epaississement irrégulier de la paroi vésiculaire**
 - CCK vésiculaire infiltrant
- **Masse IH : CCK IH**
 - Fibrose : temps tardifs +++
 - FDR : CSP
- **Obstacles de la VBP (hilaires et en dessous)**
 - Eliminer Causes extrinsèques bénignes et malignes
 - Sténose hilare infiltration pariétale VB : CCK

Tout n' est pas du cancer !!!!!

Tumeurs endobiliaires rares

Papillomatose

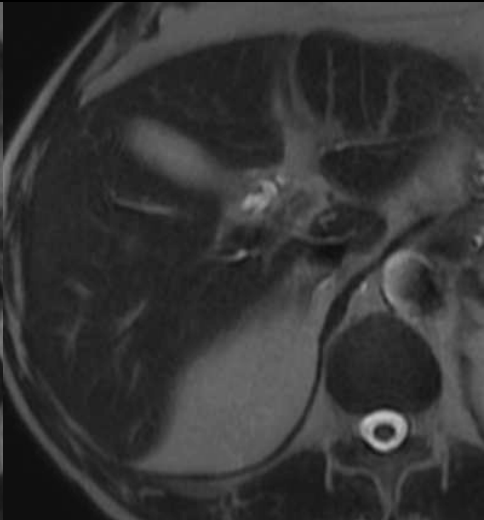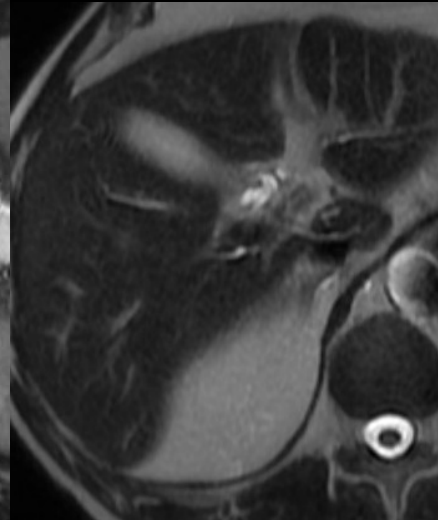
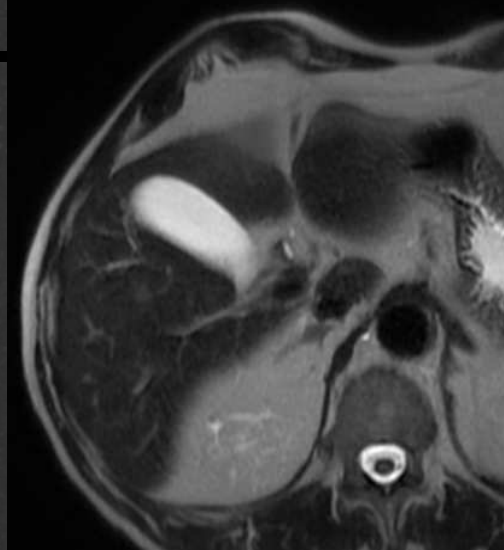
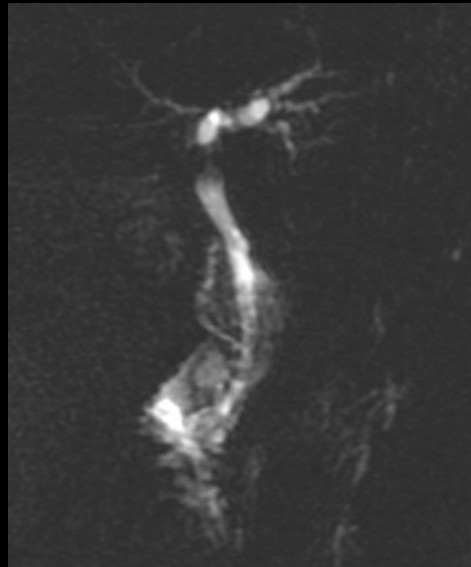
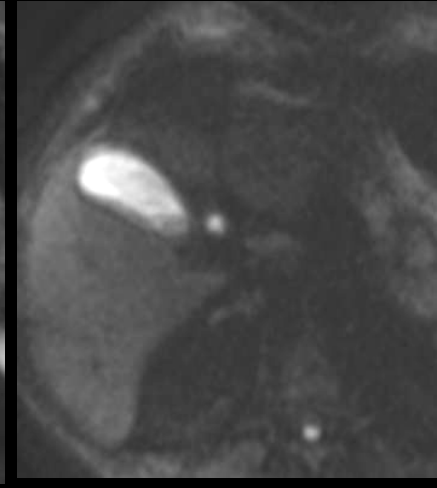
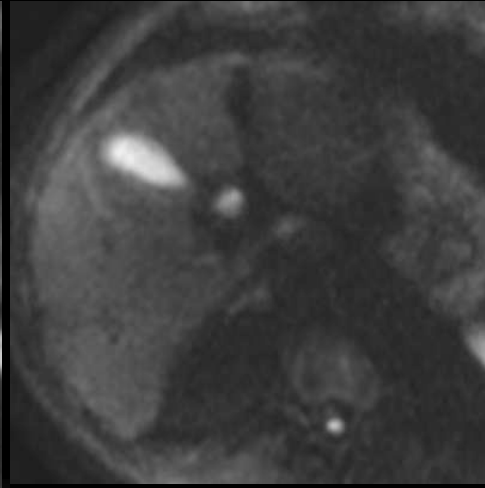
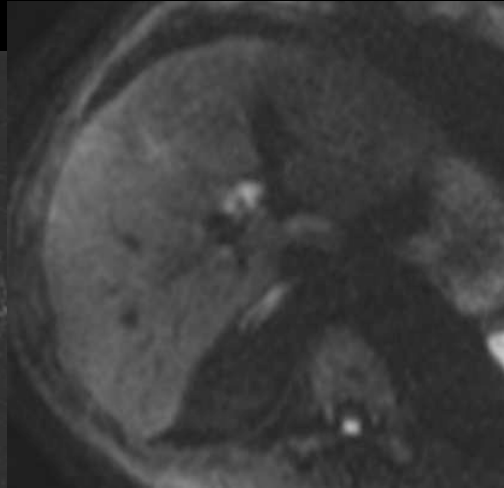
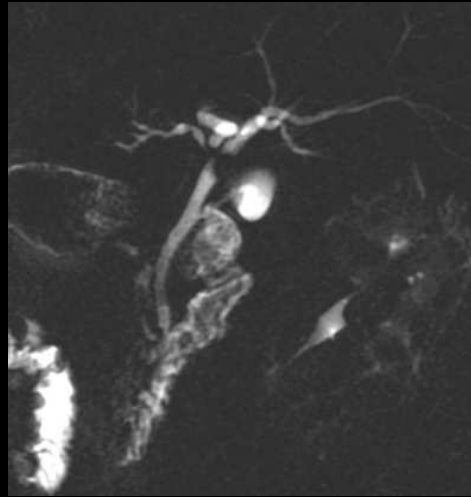
CHC à développement endobiliaire

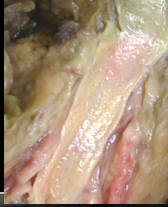Métastases à développement endobiliaire

Papillomatose

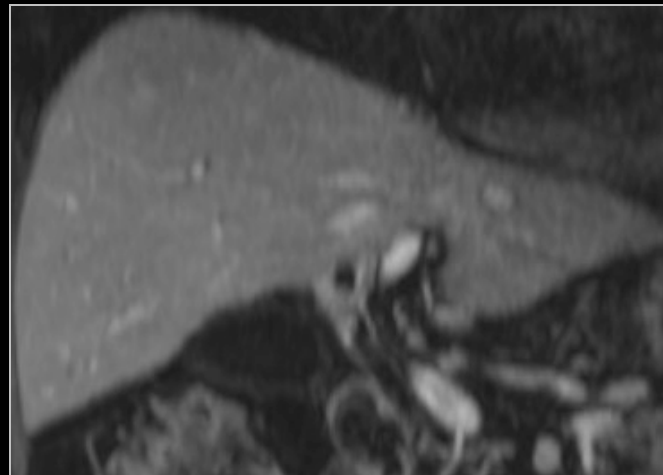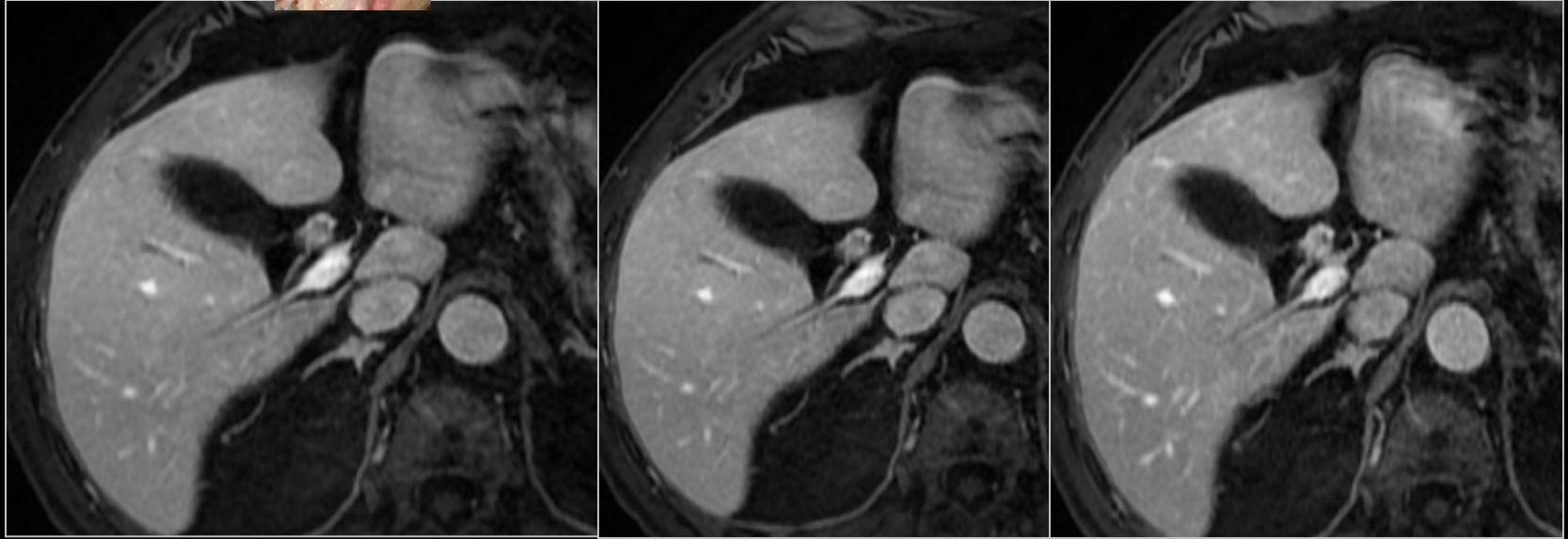
- Papillome biliaire : prolifération papillaire d'un épithélium biliaire atypique autour d'un axe fibro vasculaire
- Papillomatose : > 3 papillomes sur les VBIH ou EH, continue ou discontinue
- Degrés variables de dysplasie : de dysplasiques jusqu'à dégénérées
- 5 classes (différentes classes peuvent coexister)
 - Classes 1 et 2 : dysplasies de bas et de haut grade
 - Classes 3 : carcinome in situ
 - Classes 4 et 5 : invasion micro et macro du parenchyme hépatique et ou des couches fibro musculaires de la paroi biliaire
- Papillomatoses sécrétantes (dilatations en amont et en aval de l'obstacle) et non sécrétantes
- TTT chirurgical , transplantation hépatique envisageable pour les classes 1 et 2 voire 3

Papillome

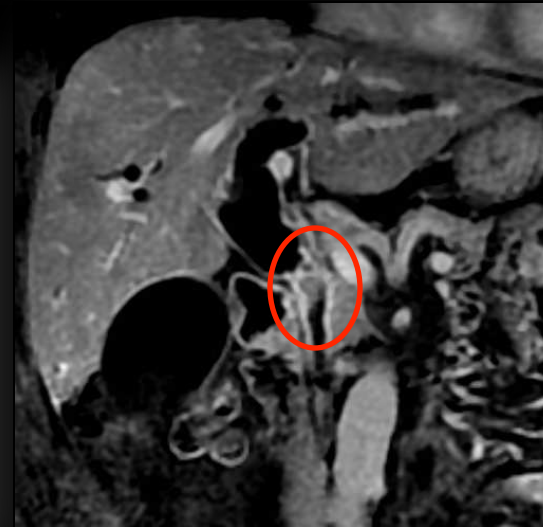
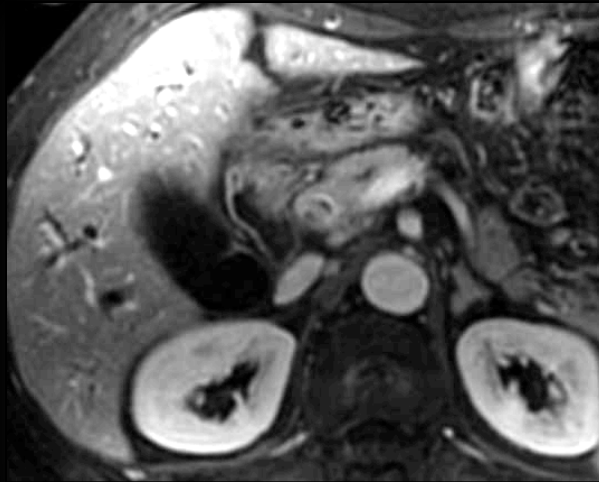
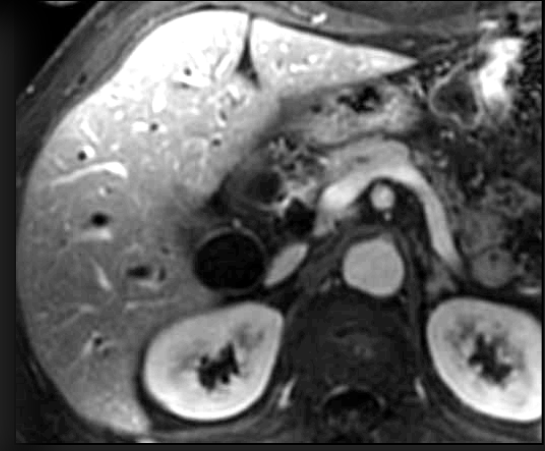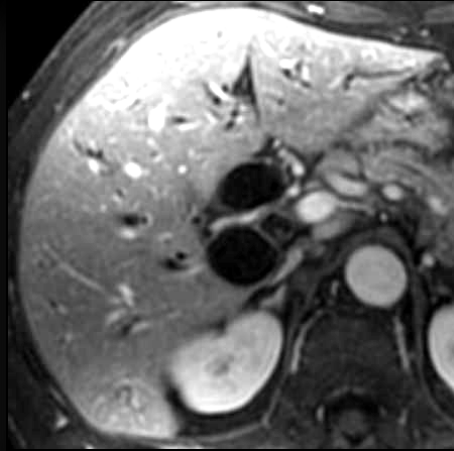
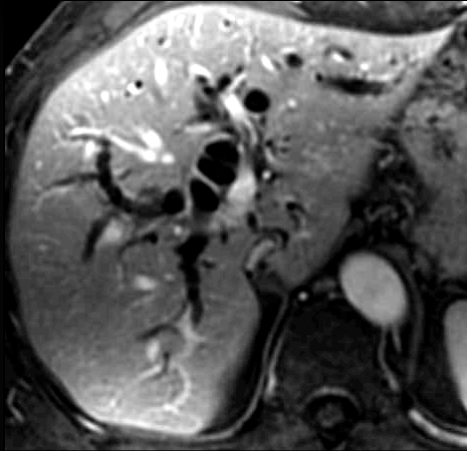




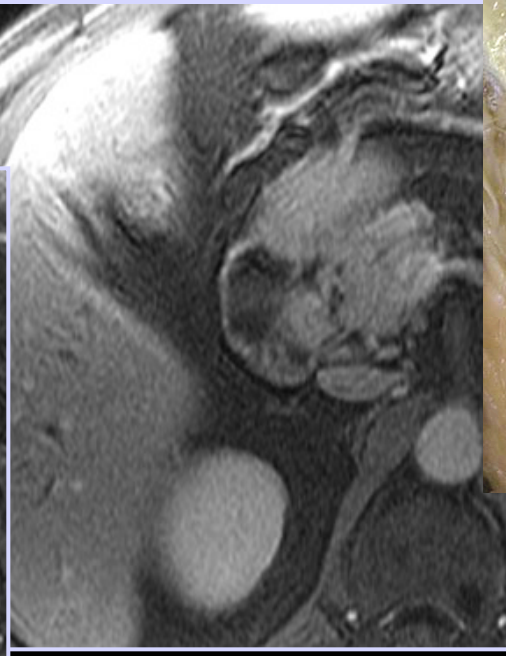
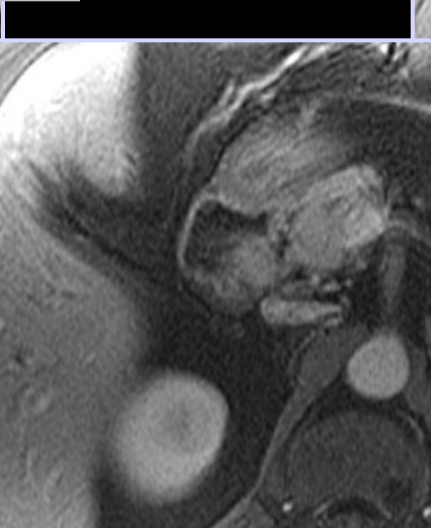
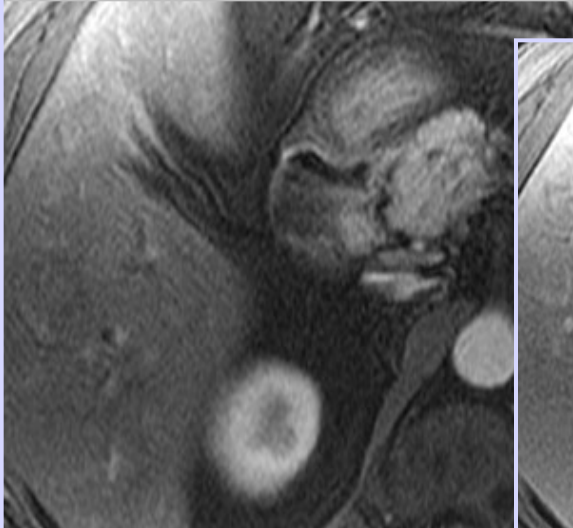
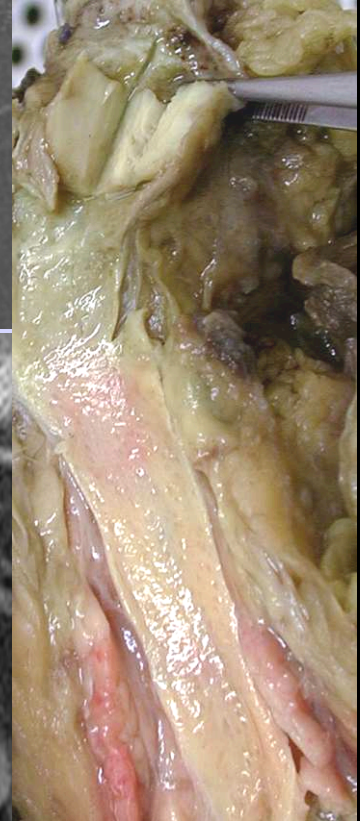
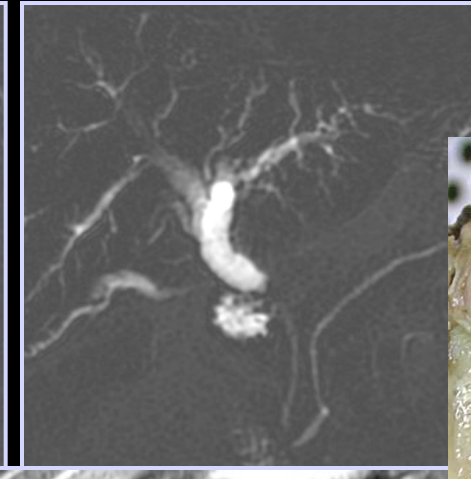
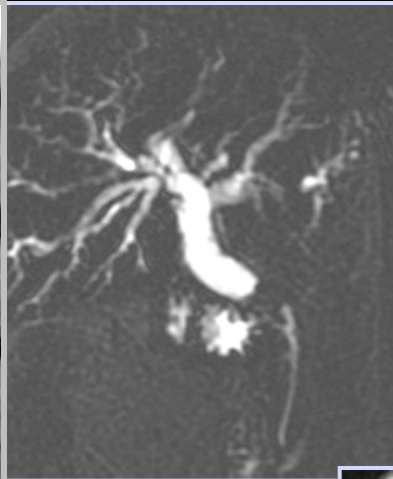
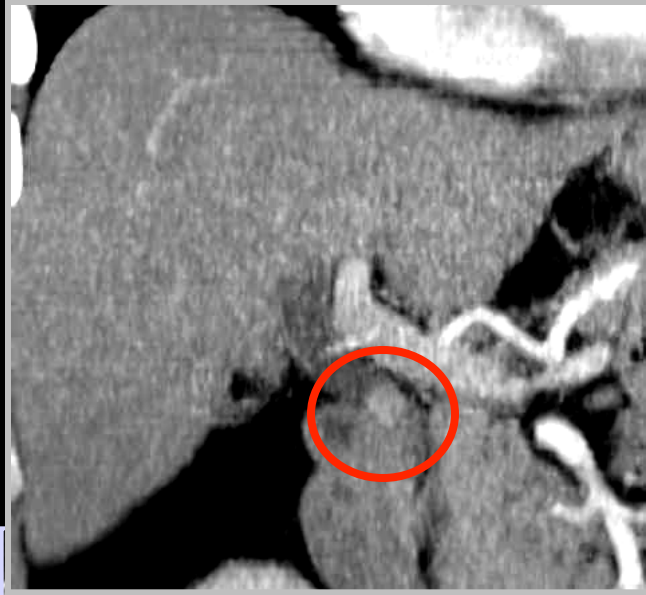
Papillome



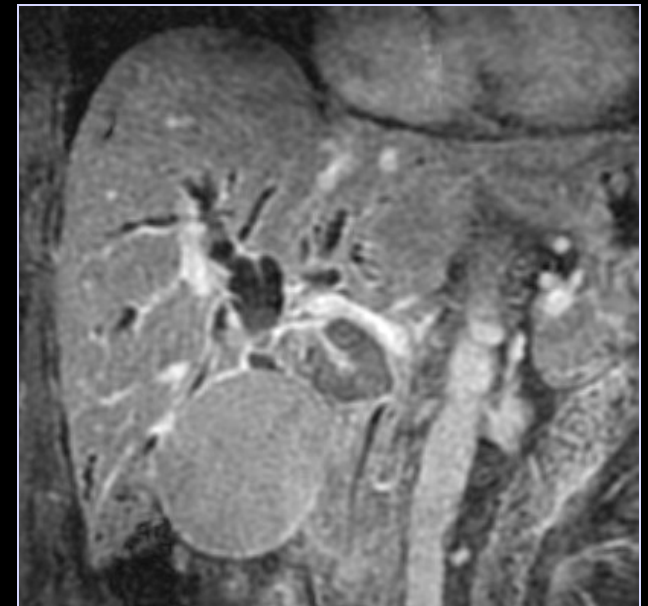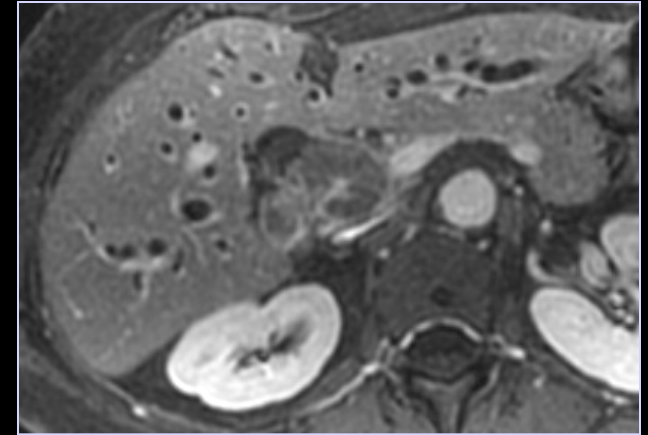
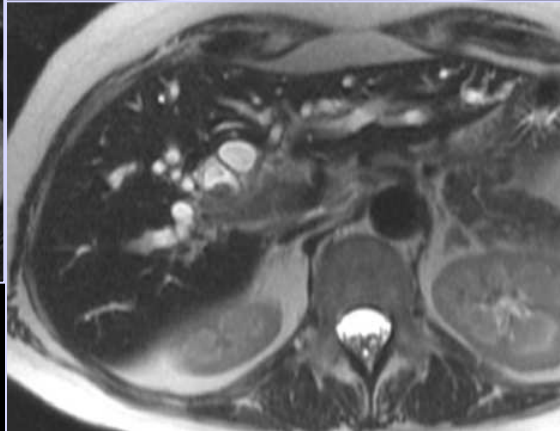
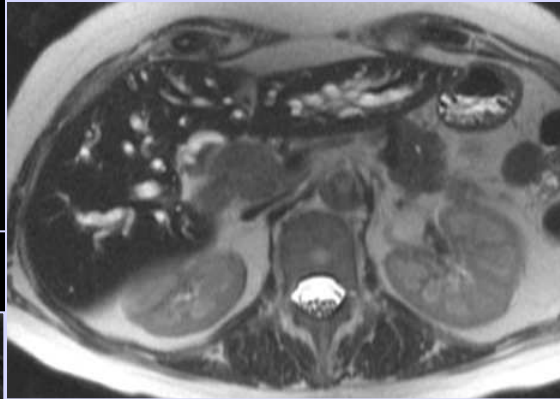
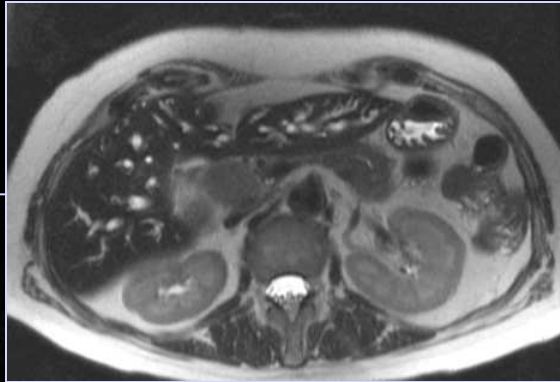
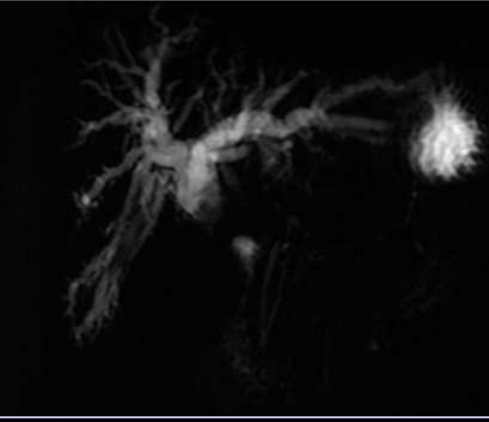
Papillome



Tumeurs endobiliaires rares



Papillomatose

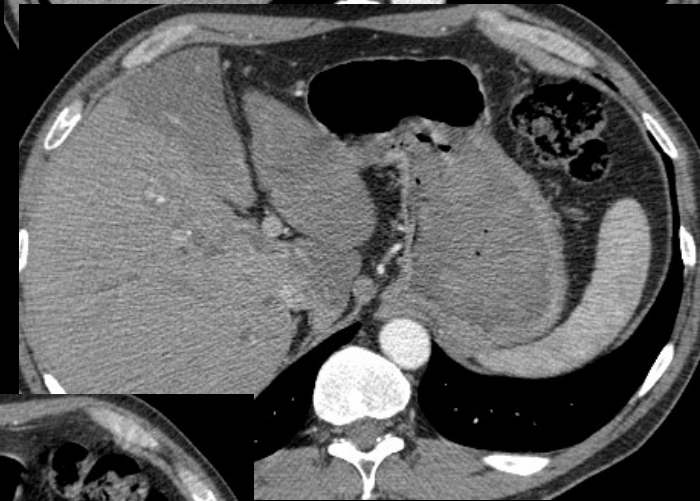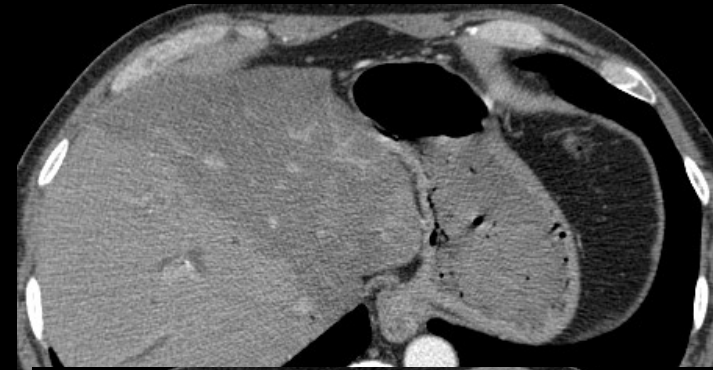
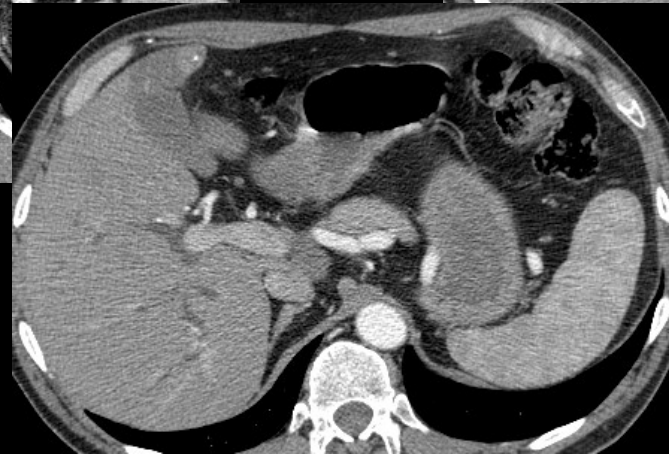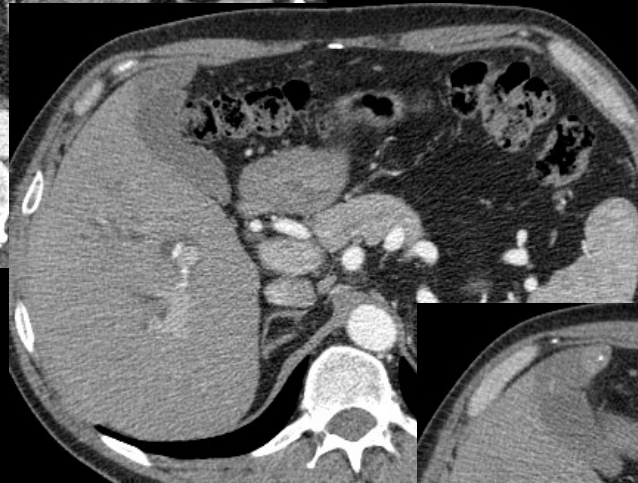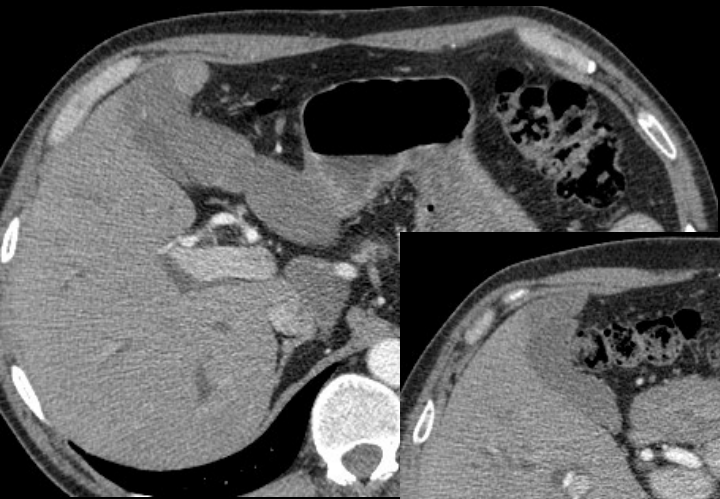


Homme 56 ans

Ictère associé à un prurit majeur

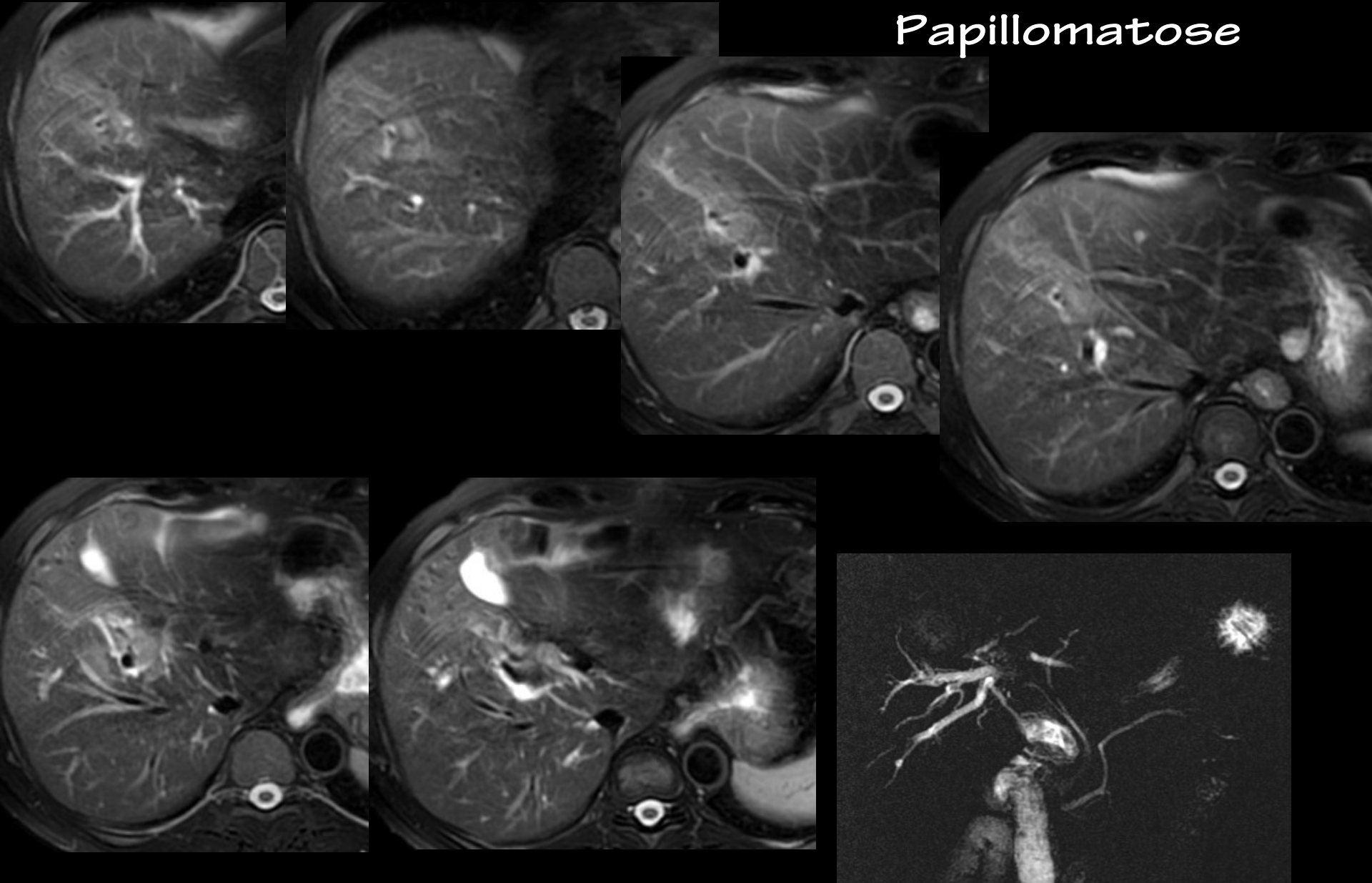
Topographie obstacle ? Nature ?

Papillomatose

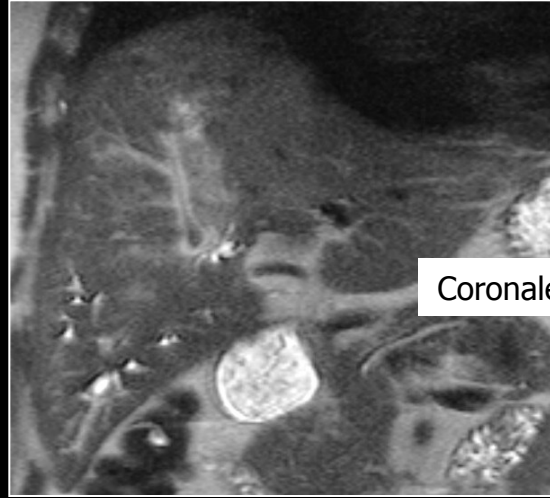
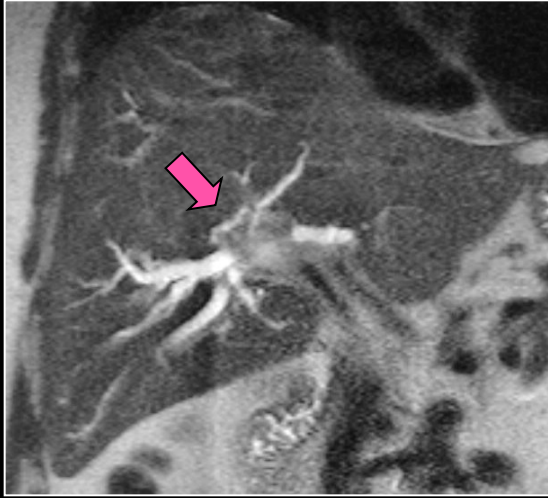


Tumeurs endobiliaires rares

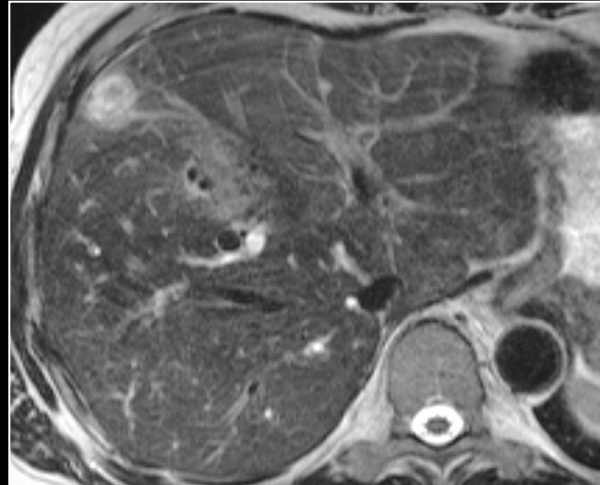
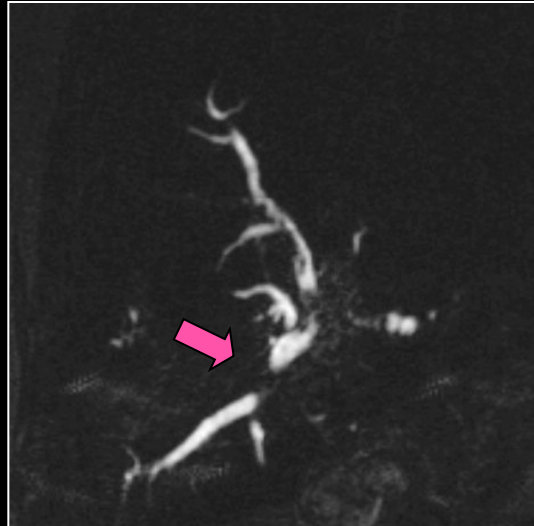
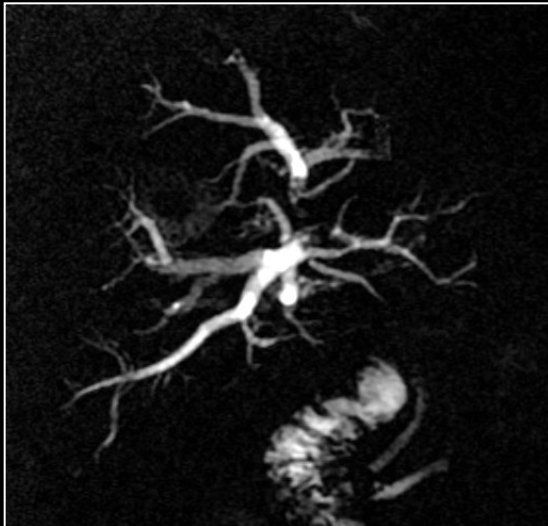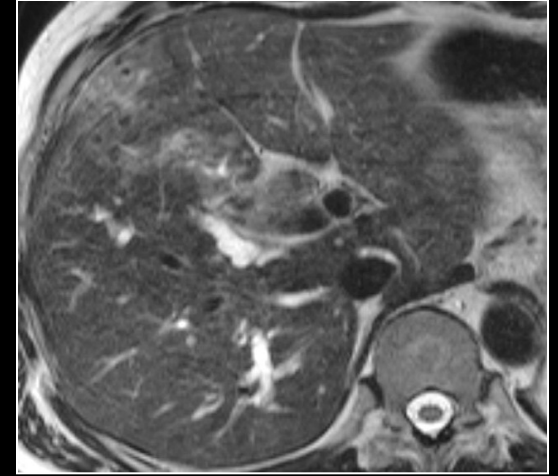
Papillomatose



Papillomatose

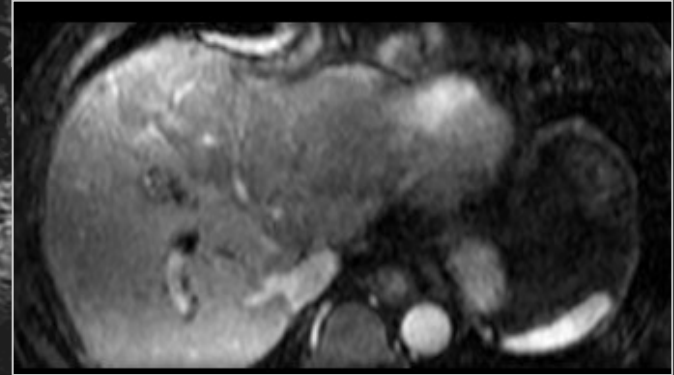
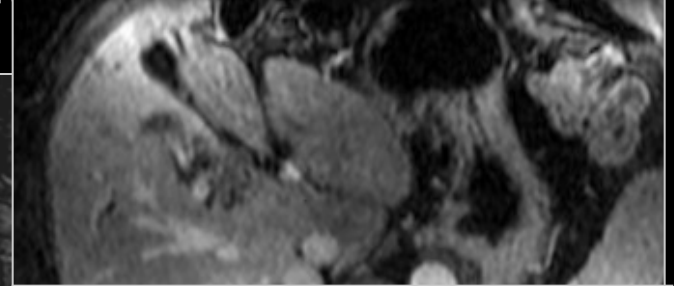
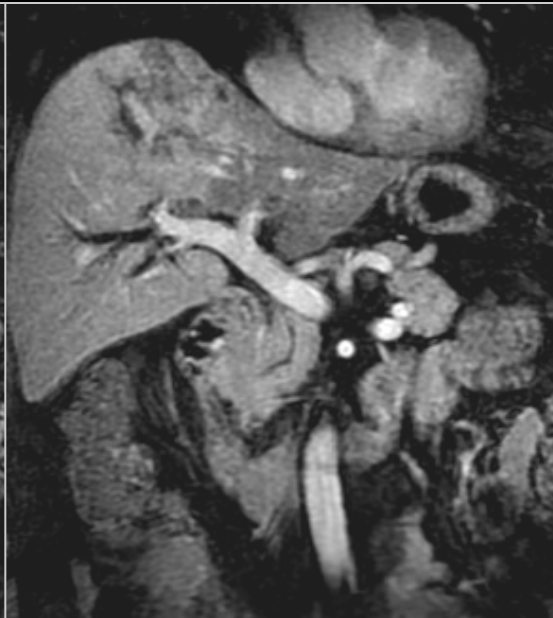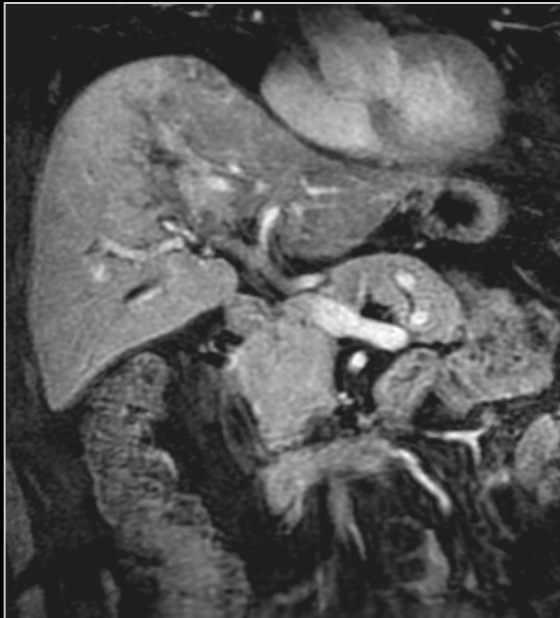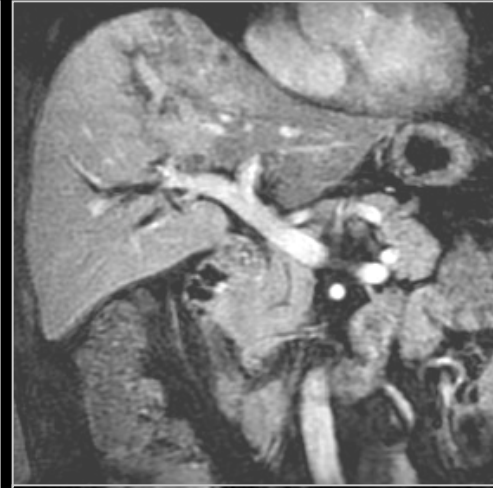


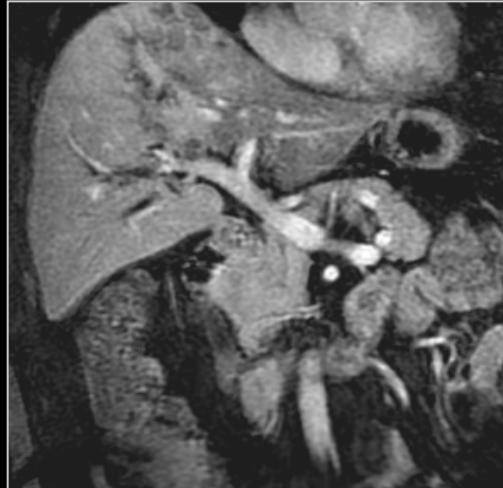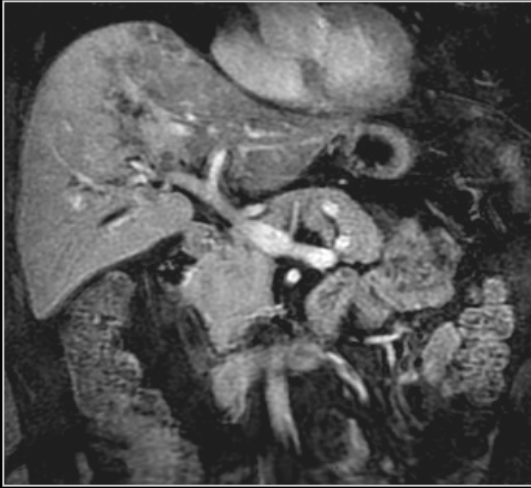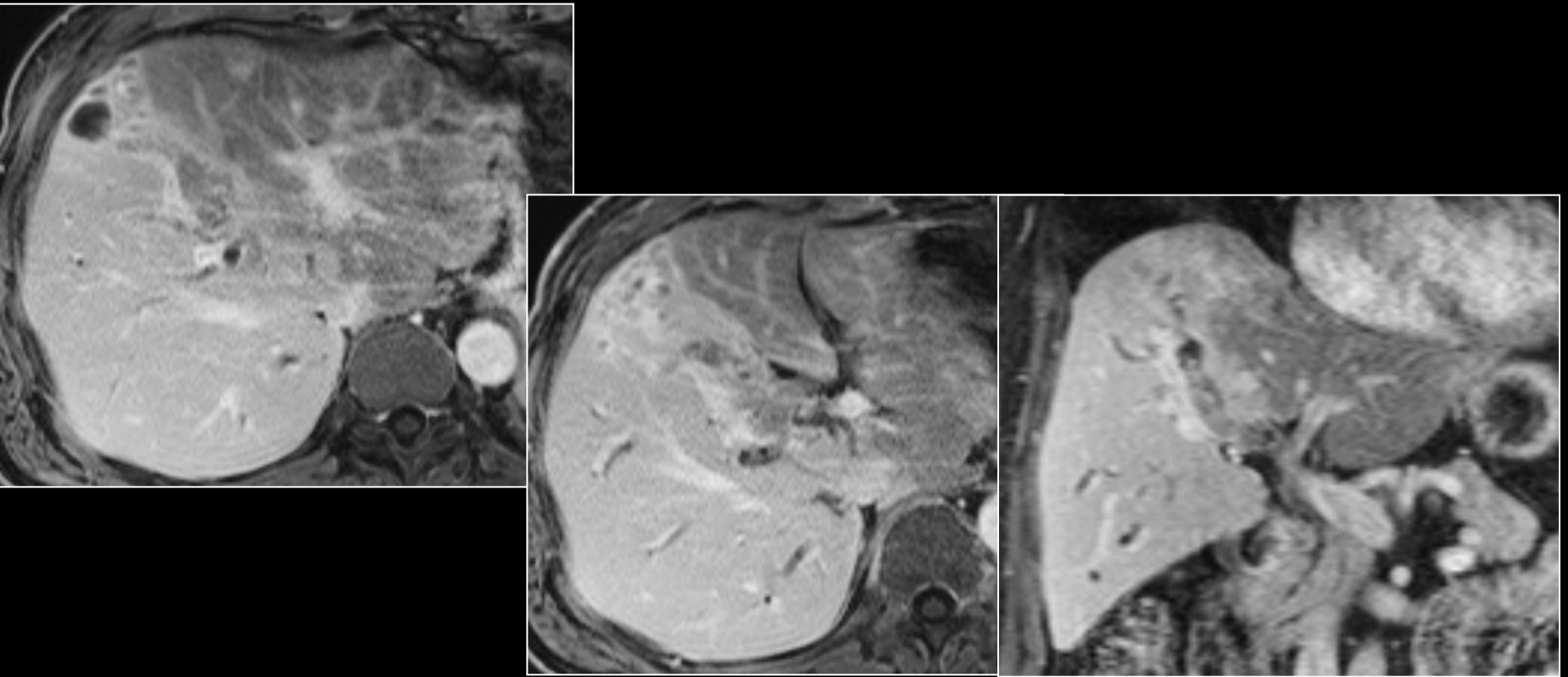
Coronales T2



Radiaires SSFSE T2 TE long

Tumeurs endobiliaires rares





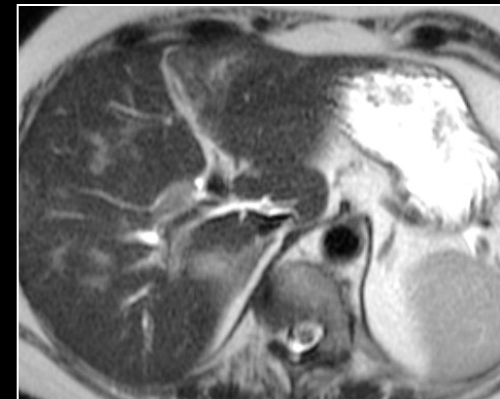
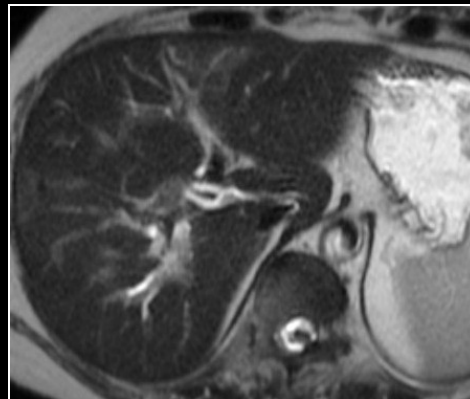
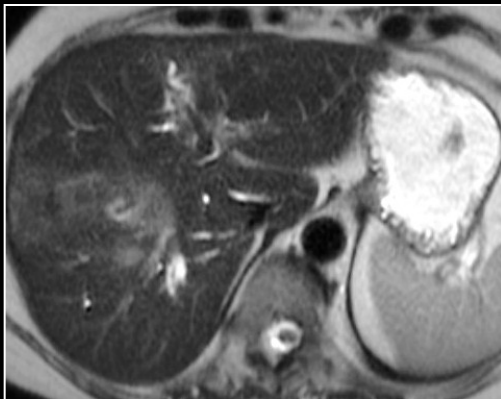
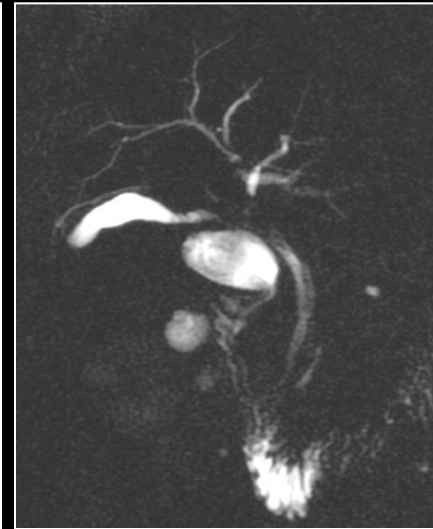
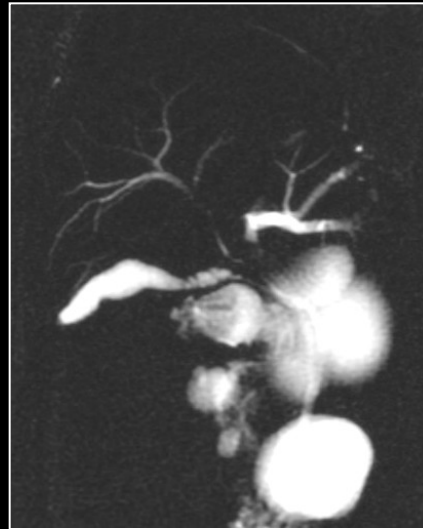
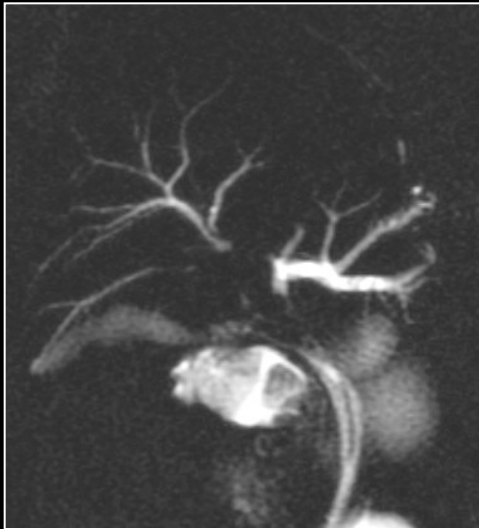
Papillomatose avec foyers de carcinome in situ

Le patient a bénéficié d'une transplantation hépatique

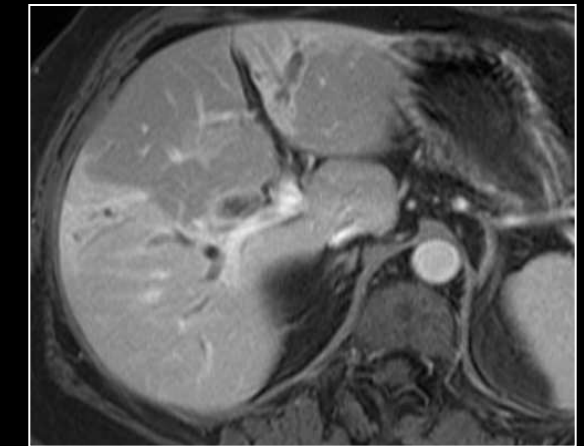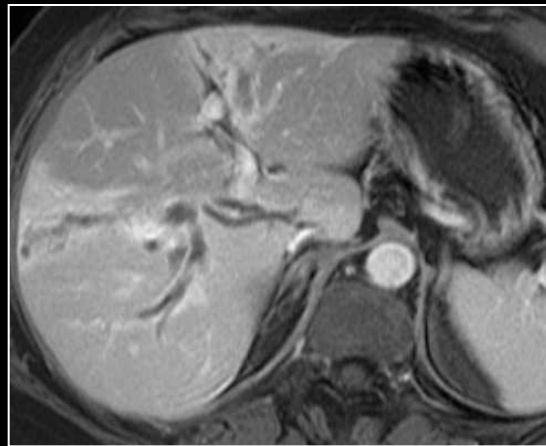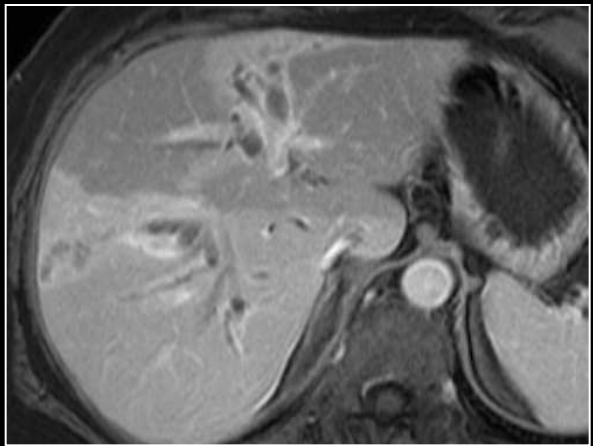
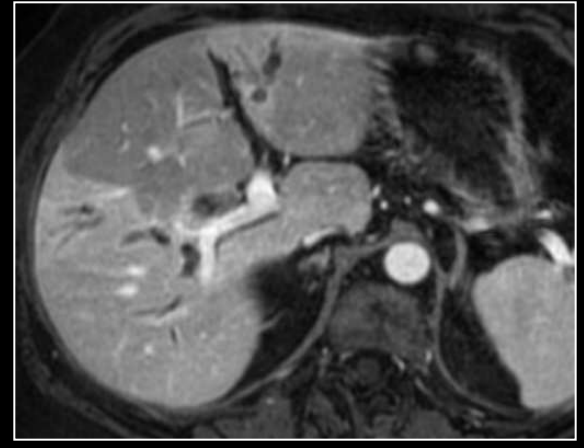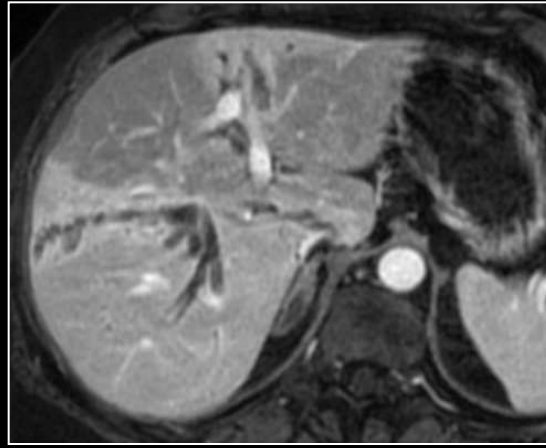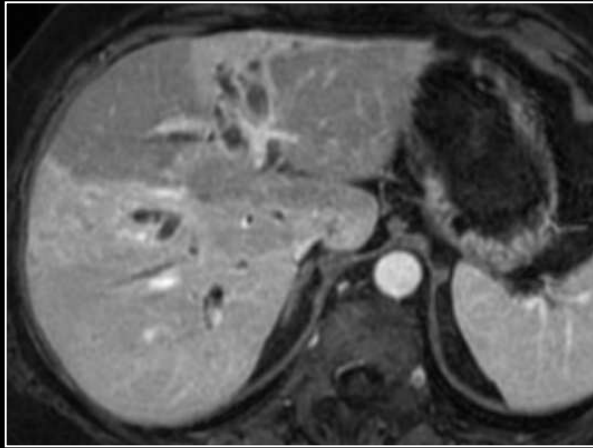
Tumeurs endobiliaires rares

Altération de l'état général et cholestase biologique chez une patiente opérée 3 ans auparavant d'un adénocarcinome colique.

La coloscopie est normale.

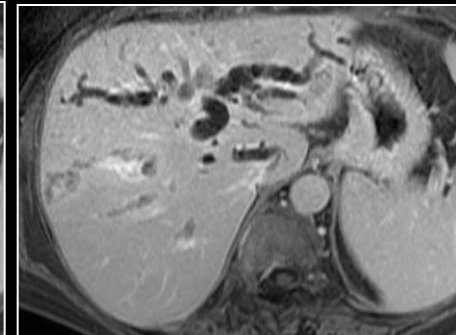
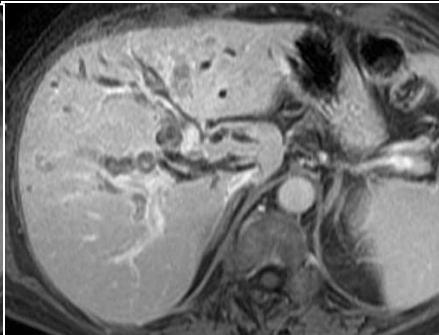
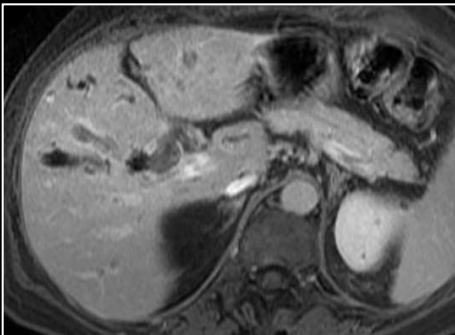
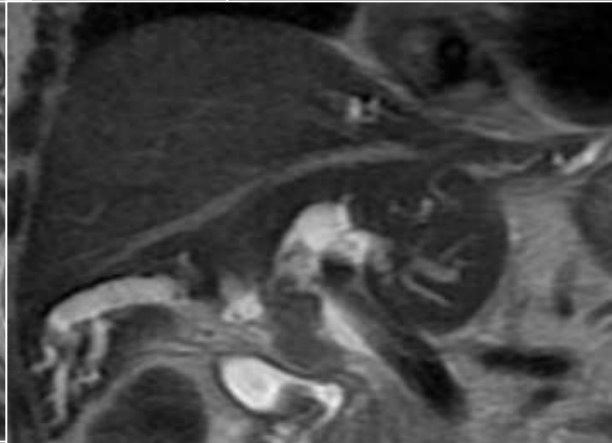
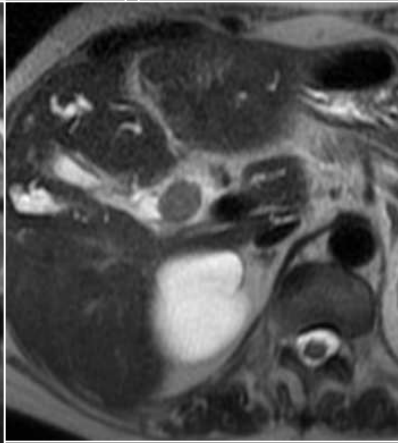
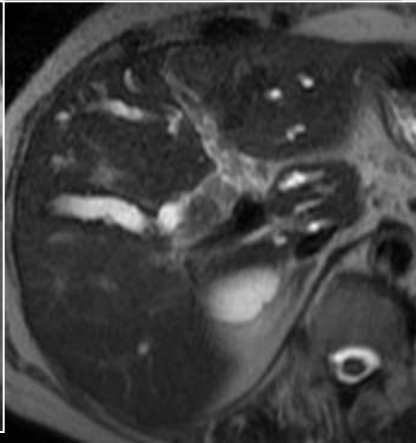
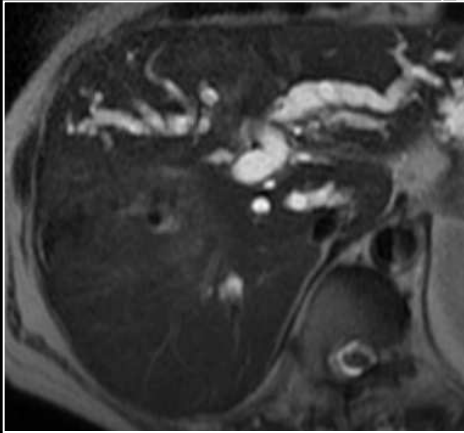
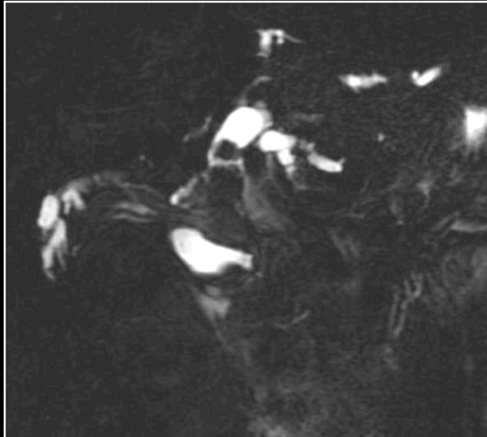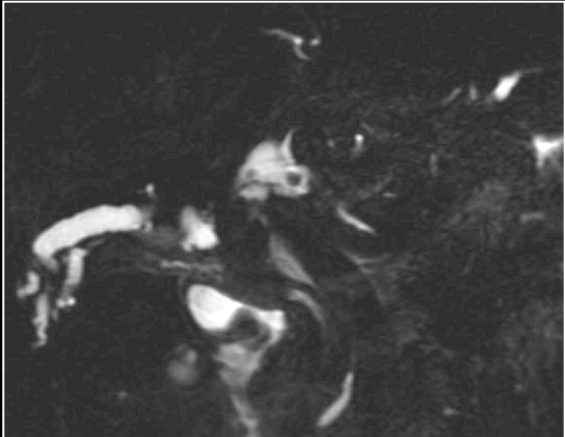
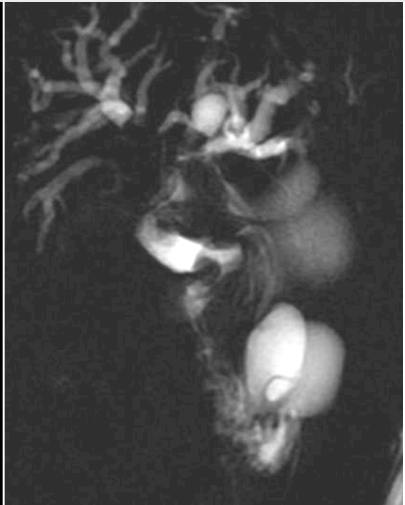


Tumeurs endobiliaires rares



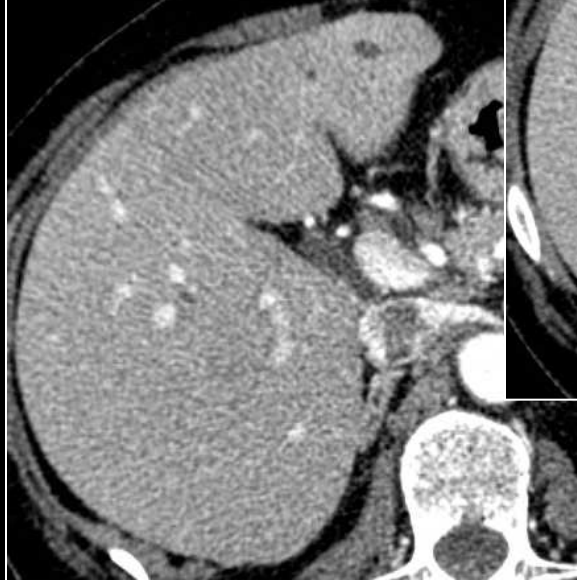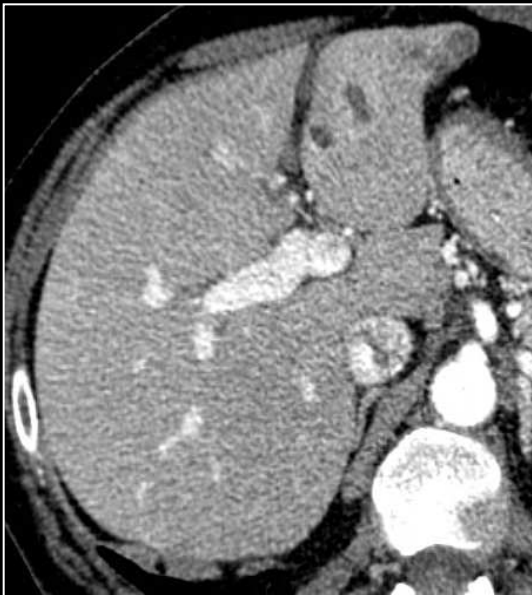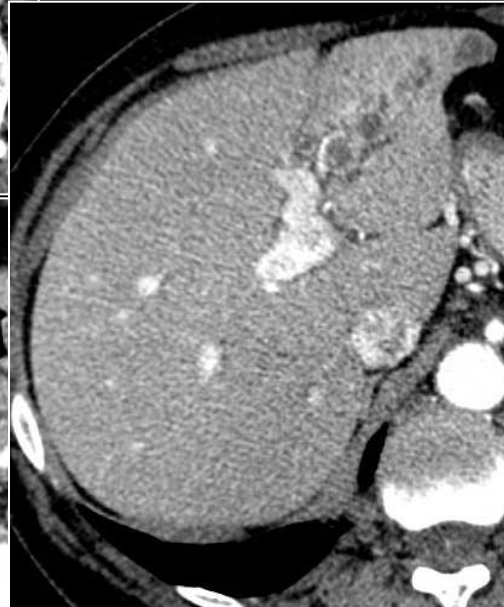
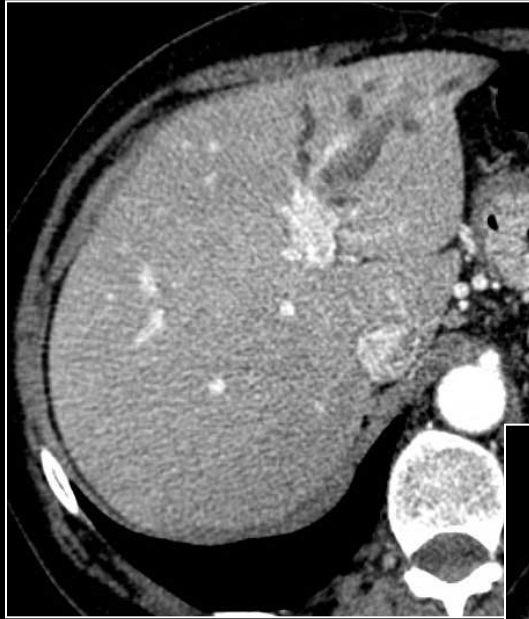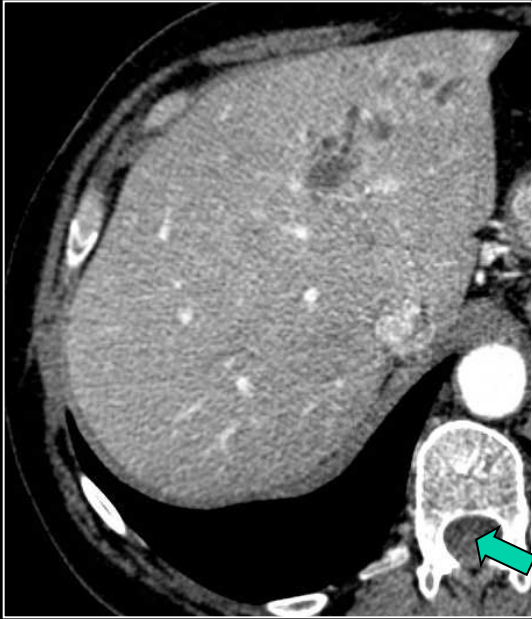Métastases endobiliaires

Métastases endobiliaires

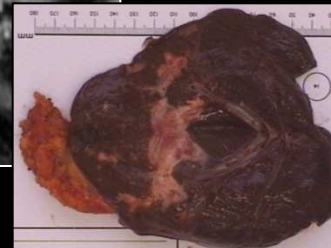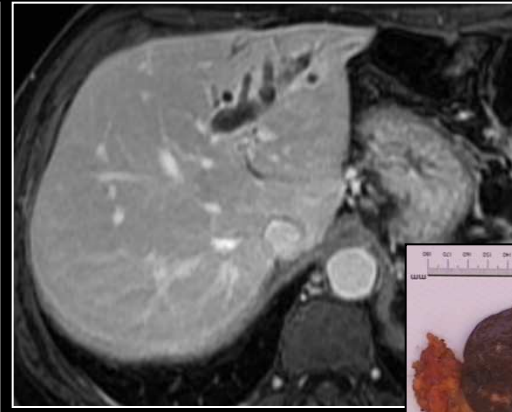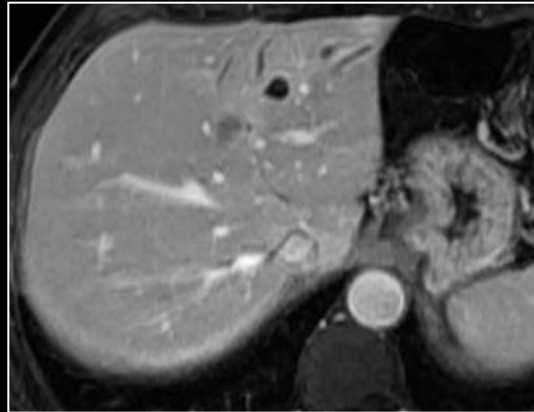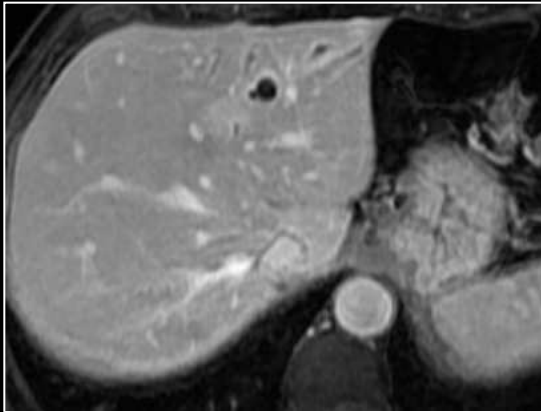
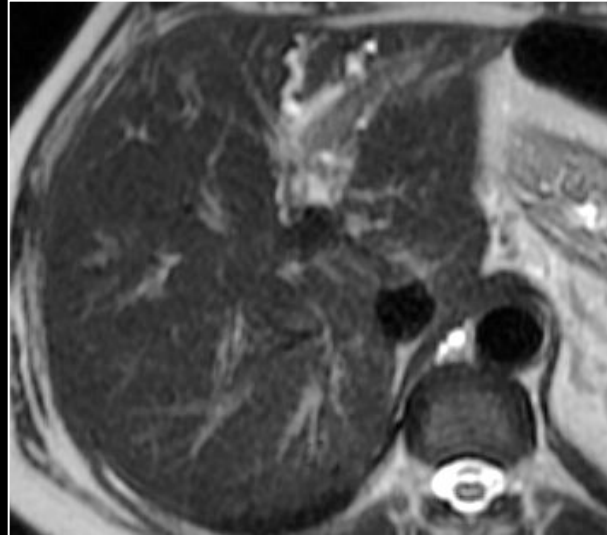


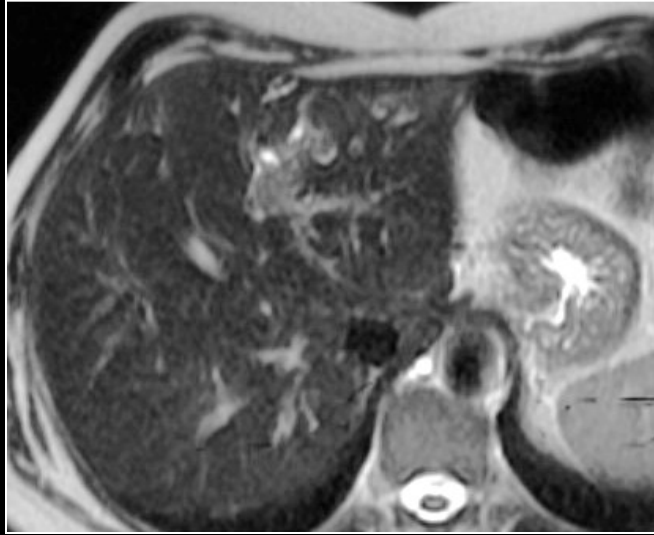Tumeurs endobiliaires rares

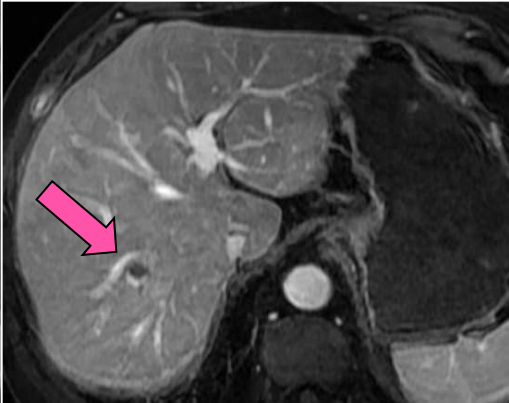
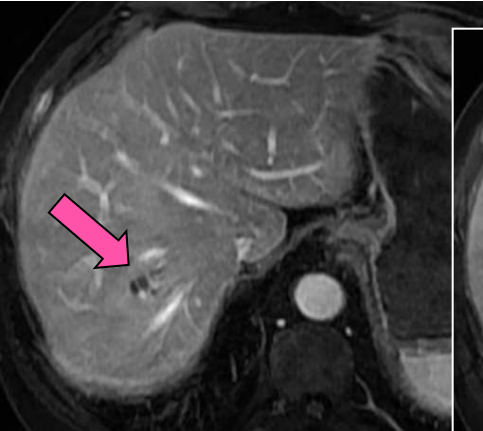
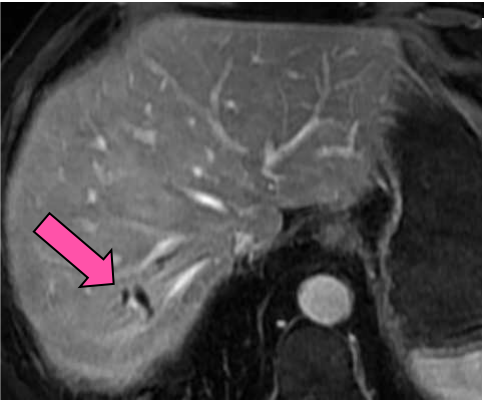
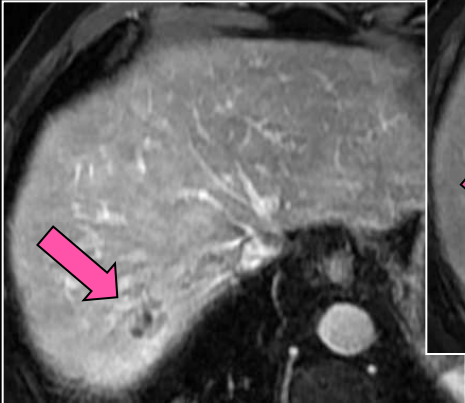
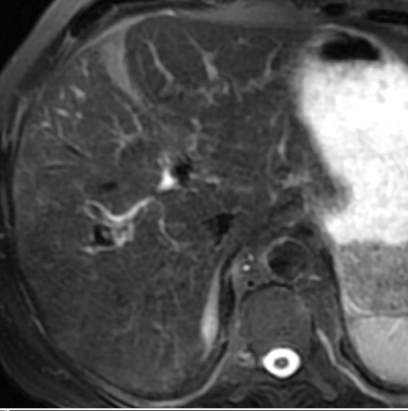
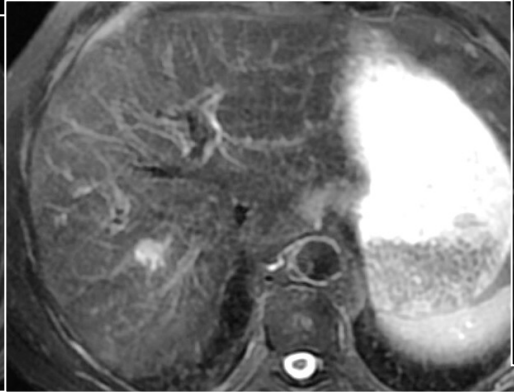
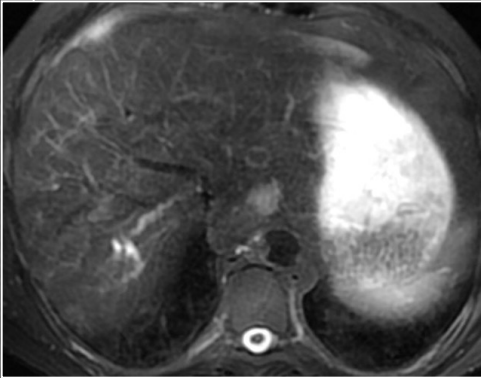
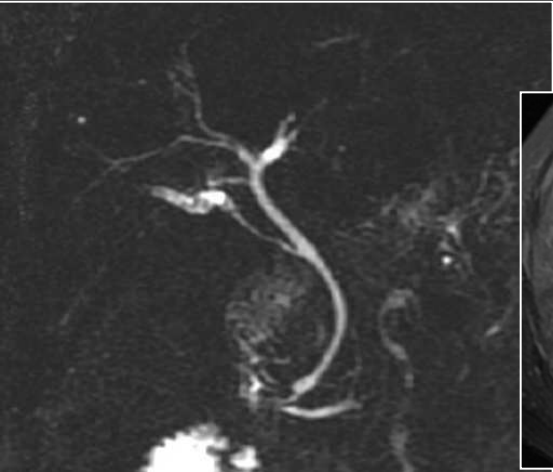
Altération de l'état général et cholestase biologique chez une patiente opérée 5 ans auparavant d'un ADK rectum



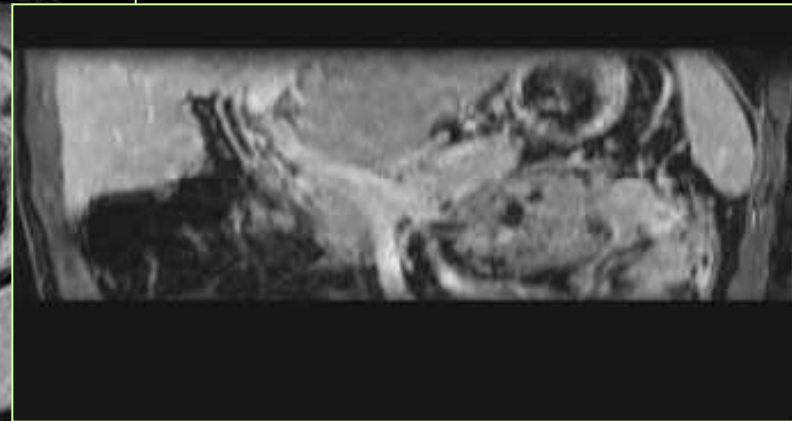
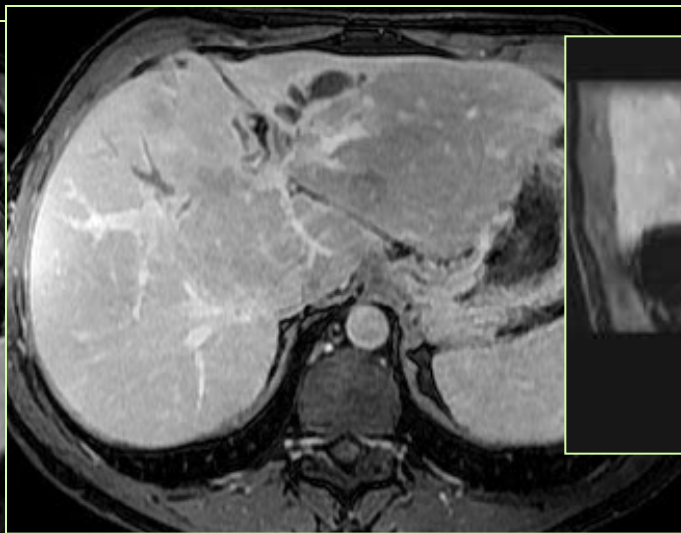
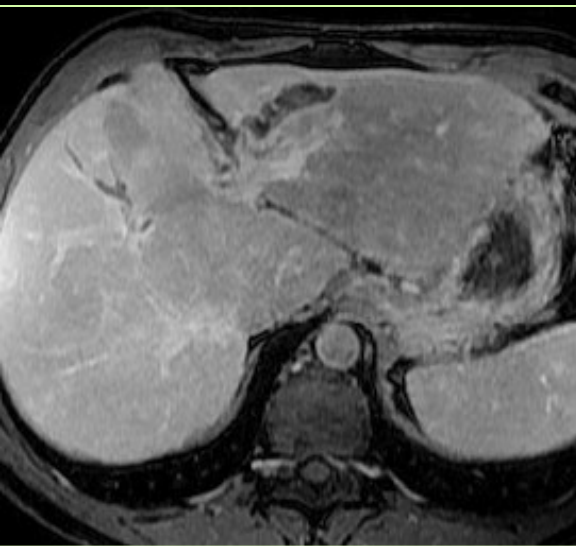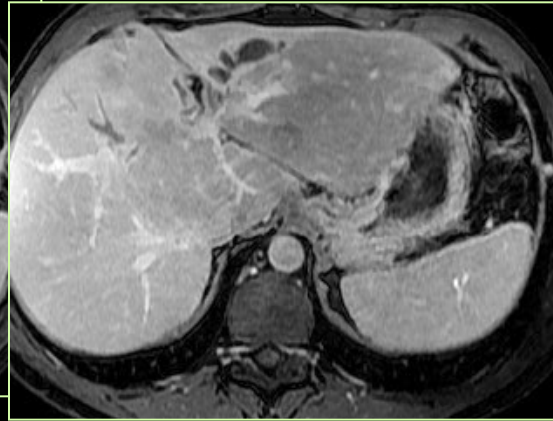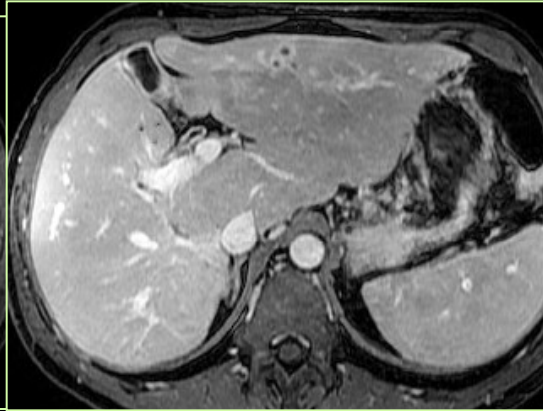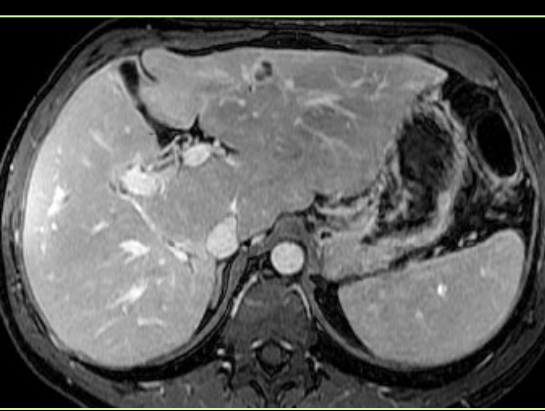Métastases endobiliaires



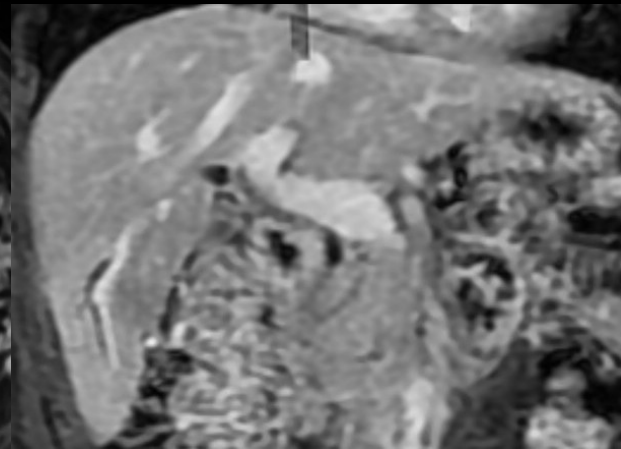
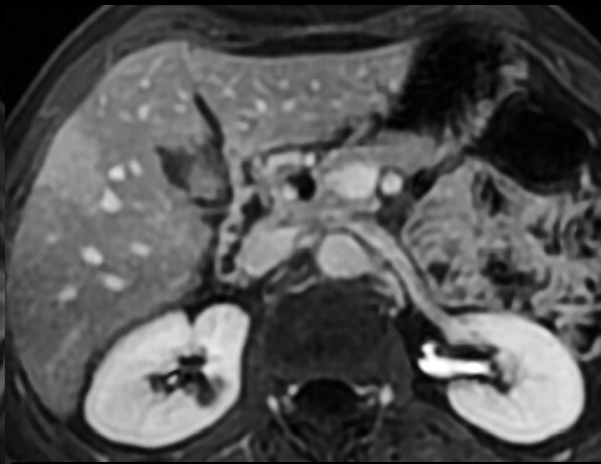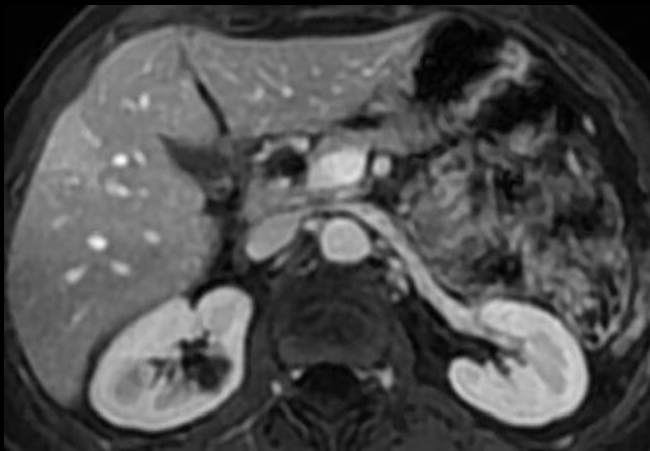
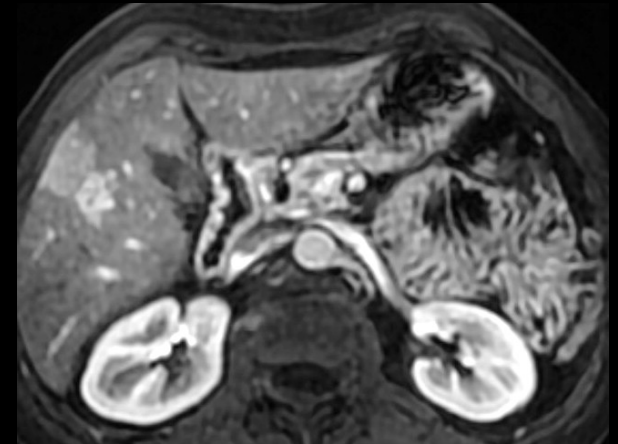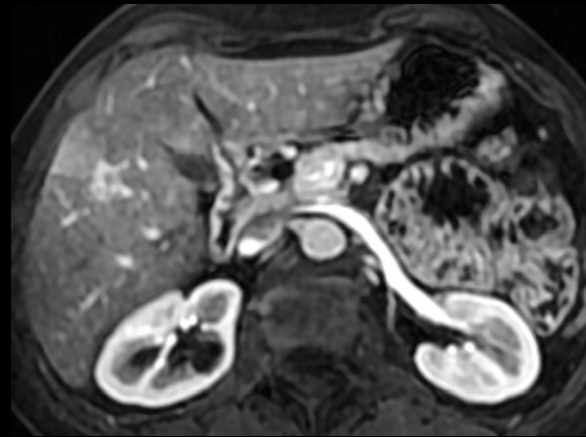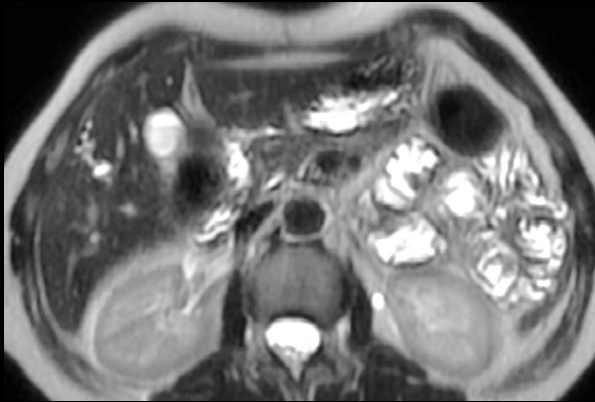
Métastases endobiliaires



Métastases endobiliaires



Métastases endobiliaires



Conclusion

- **Masse hép centrée par la vésicule avec extension hilare**
 - CCK vésiculaire
 - FDR : Long common channel
- **Epaississement irrégulier de la paroi vésiculaire**
 - CCK vésiculaire infiltrant
- **Masse IH : CCK IH**
 - Fibrose : temps tardifs +++
 - FDR : CSP
- **Obstacles de la VBP (hilaires et en dessous)**
 - Eliminer Causes extrinsèques bénignes et malignes
 - Sténose hilare infiltration pariétale VB : CCK

Tout n' est pas du cancer !!!!!