

Radioanatomie du thorax

www.e-anatomy.org

C.PROUST

Mai 2010

THORAX

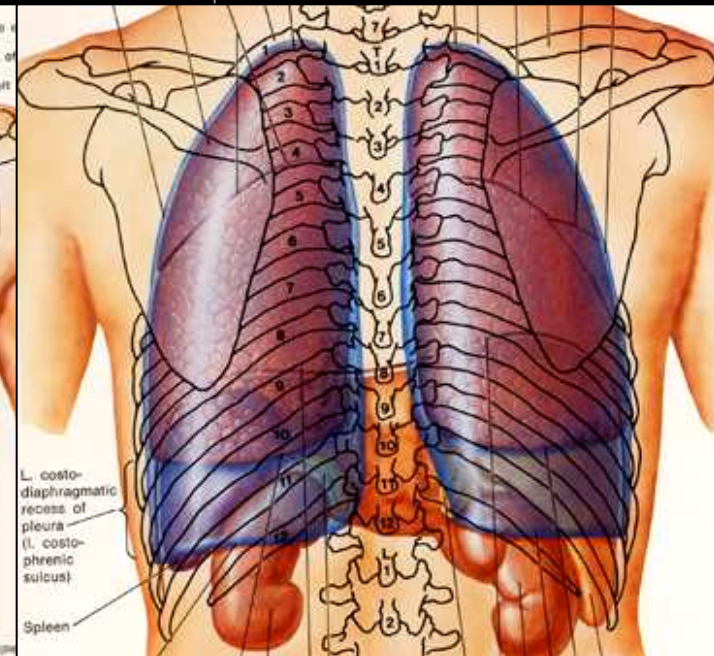
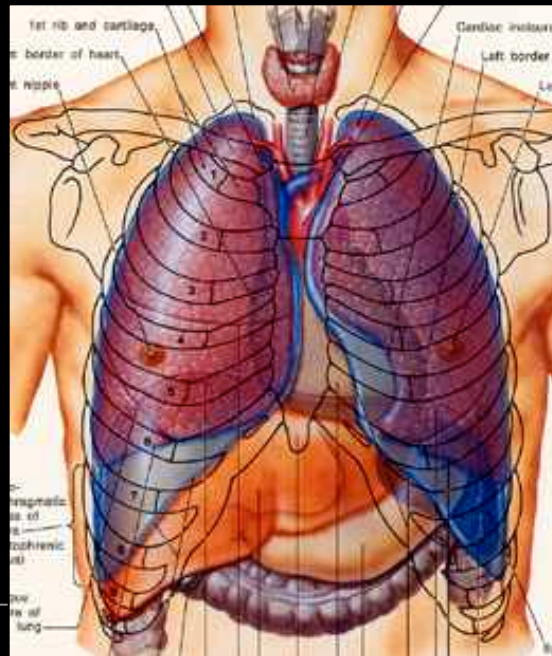
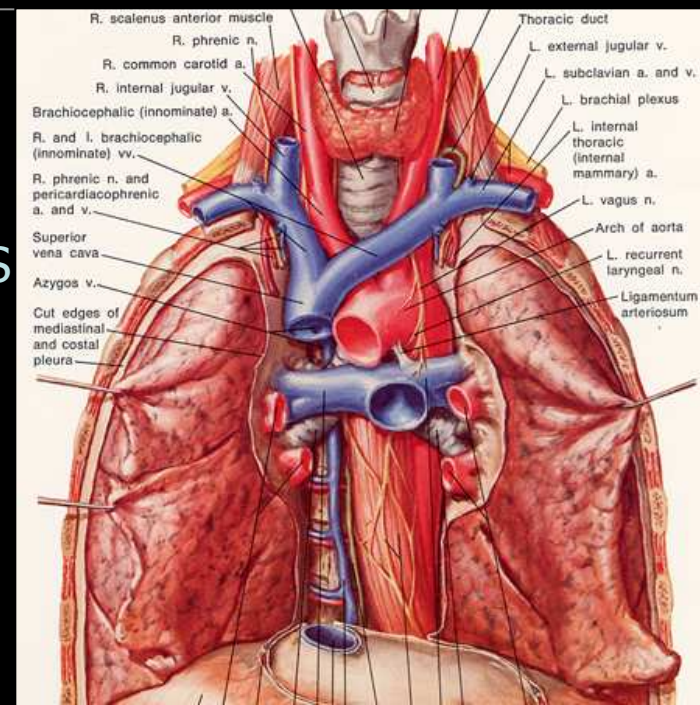
1/ RADIOANATOMIE PULMONAIRE ET DES BRONCHES

2/ RADIOANATOMIE DU MEDIASTIN

- VAISSEAUX
- CŒUR
- ŒSOPHAGE
- CHAINES GANGLIONNAIRES

3/ PAROI THORACIQUE

- PLEVRE
- COTES





1/ RADIOANATOMIE PULMONAIRE ET DES BRONCHES

ANATOMIE de l' ARBRE TRACHEO-BRONCHIQUE

Trachée conduit semi rigide anneaux cartilagineux en avant

membrane fibreuse postérieure

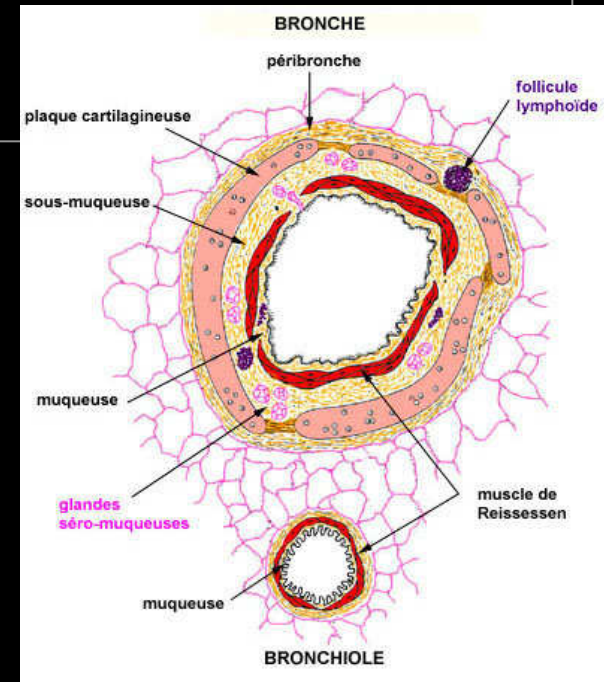
sous glottique à carène

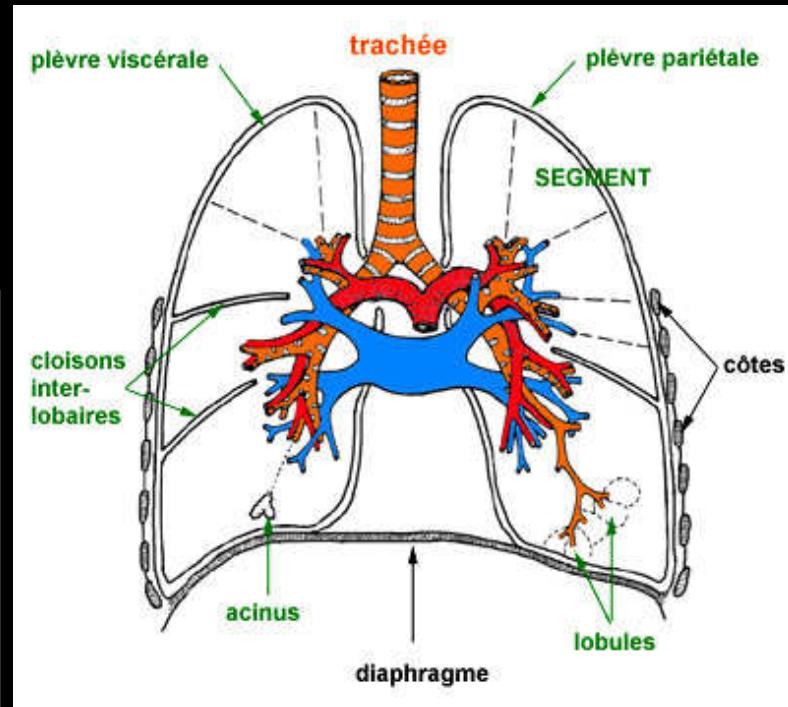
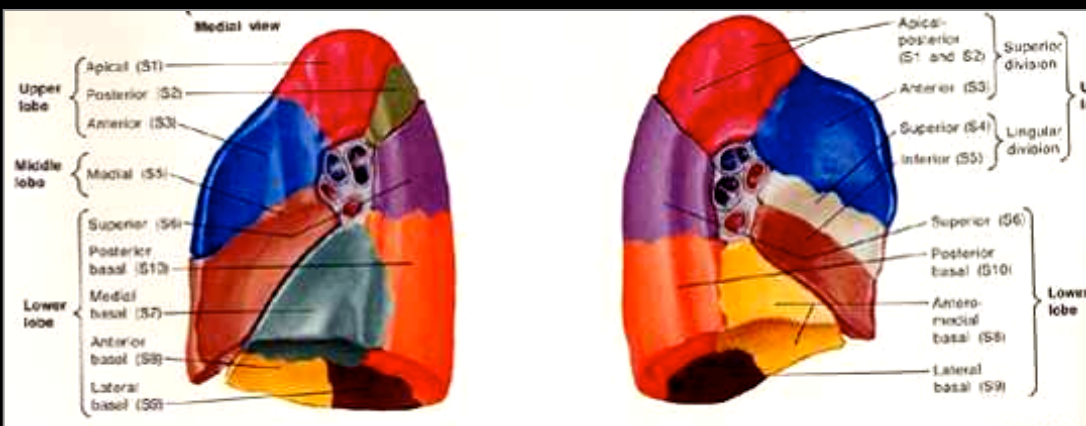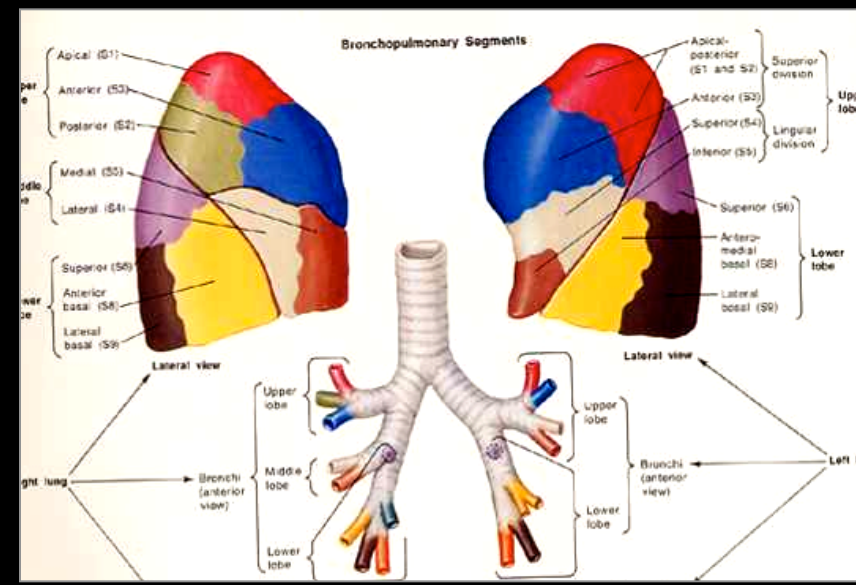
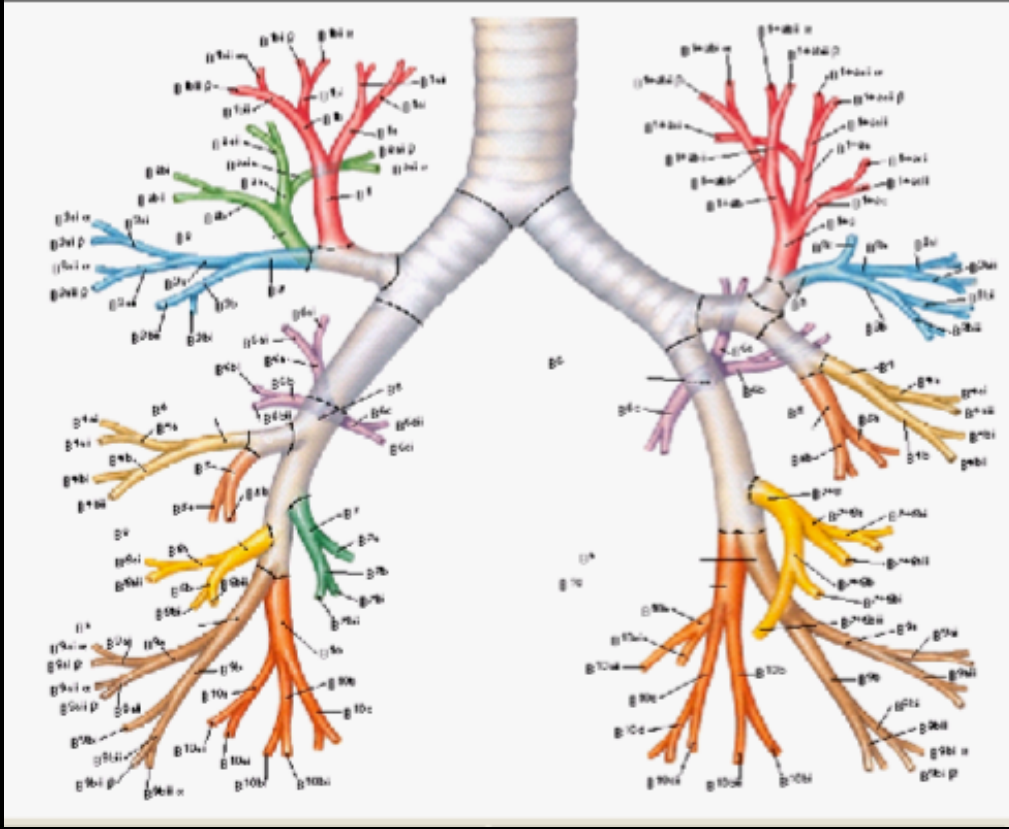
diamètre inférieur à 30 mm

Bronches

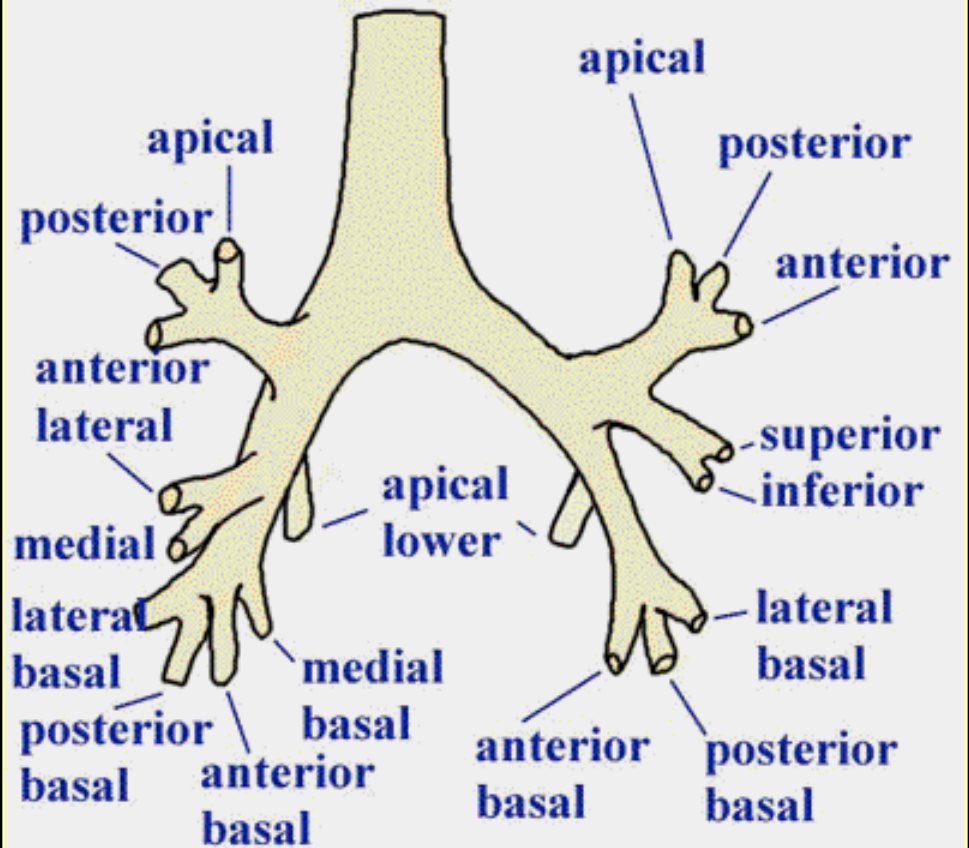
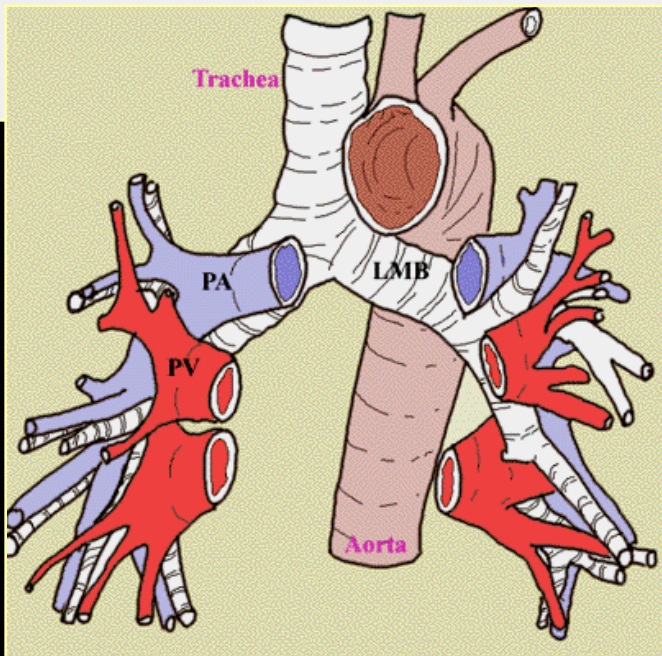
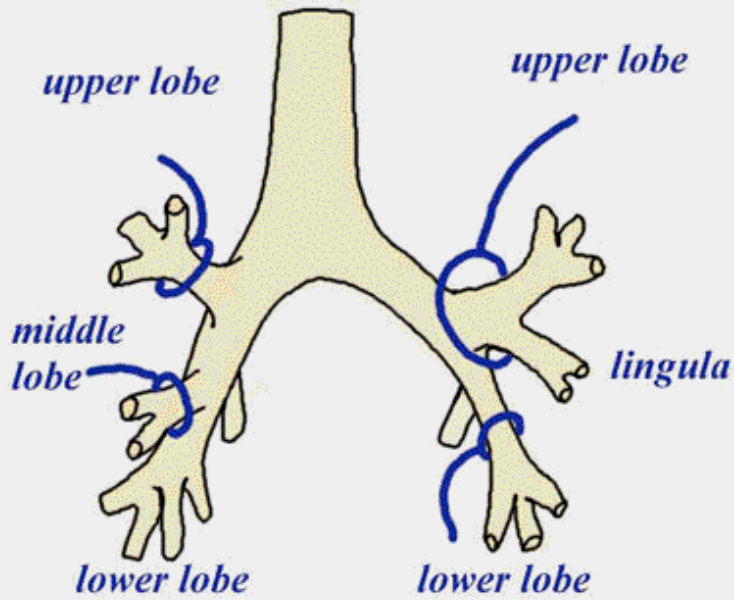
cartilage + m. lisse + fibres élastiques

élastine et collagène alvéoles

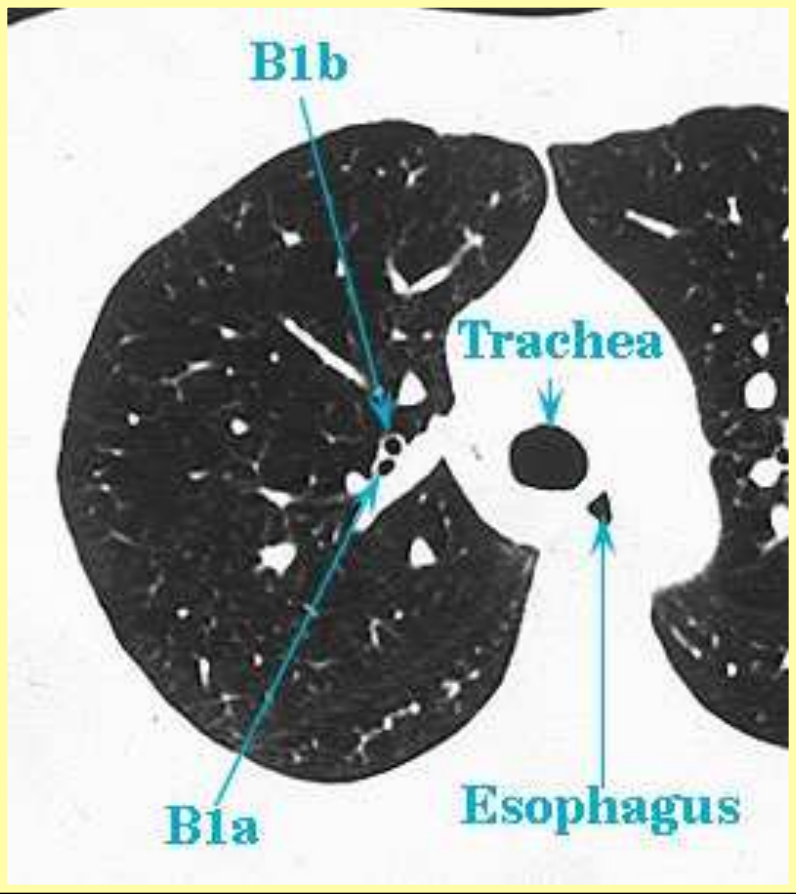
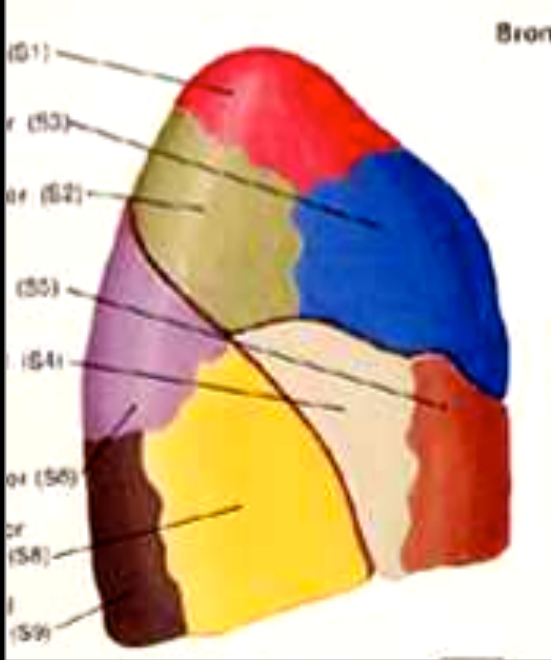




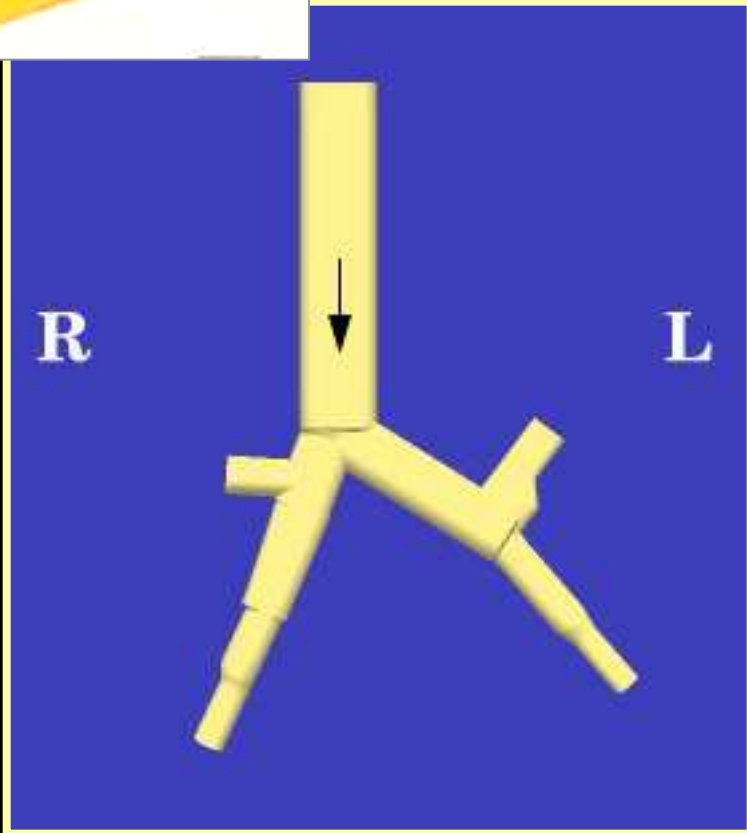
Systeme bronchique



POUMON DROIT

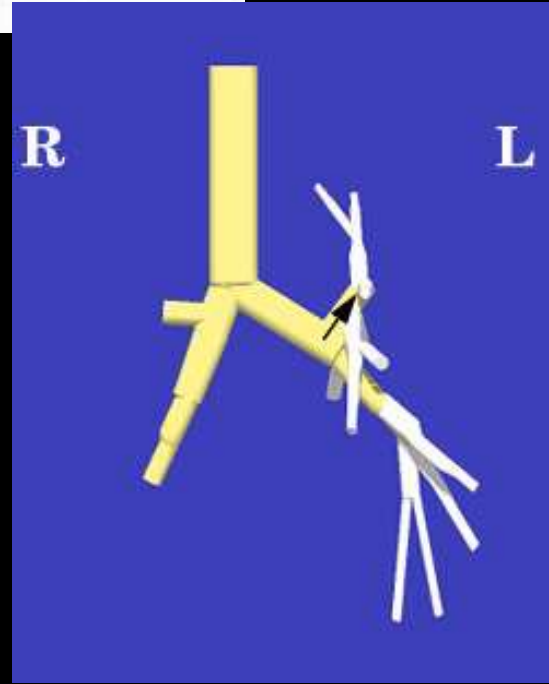
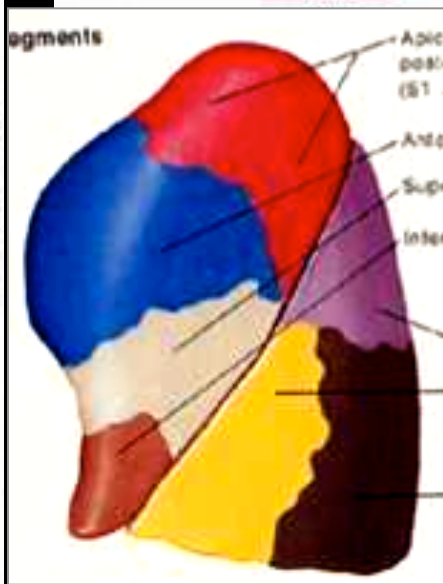
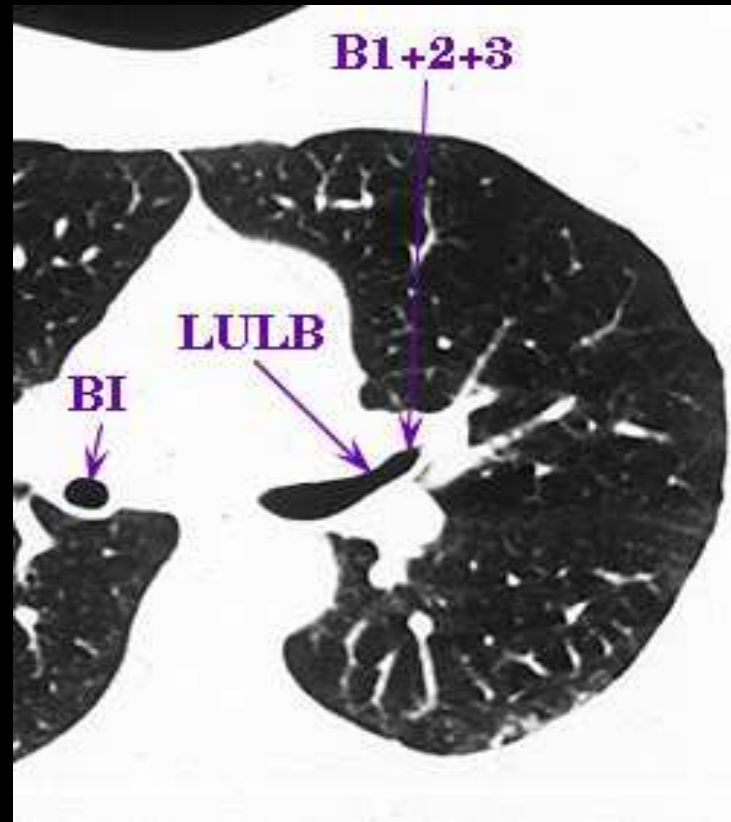
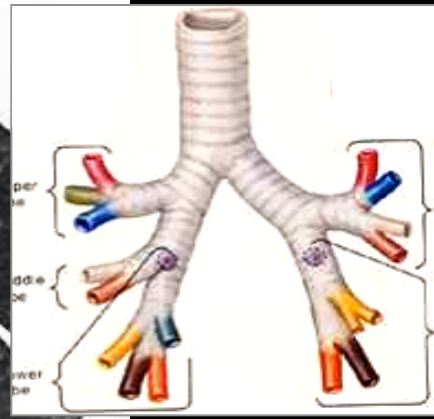
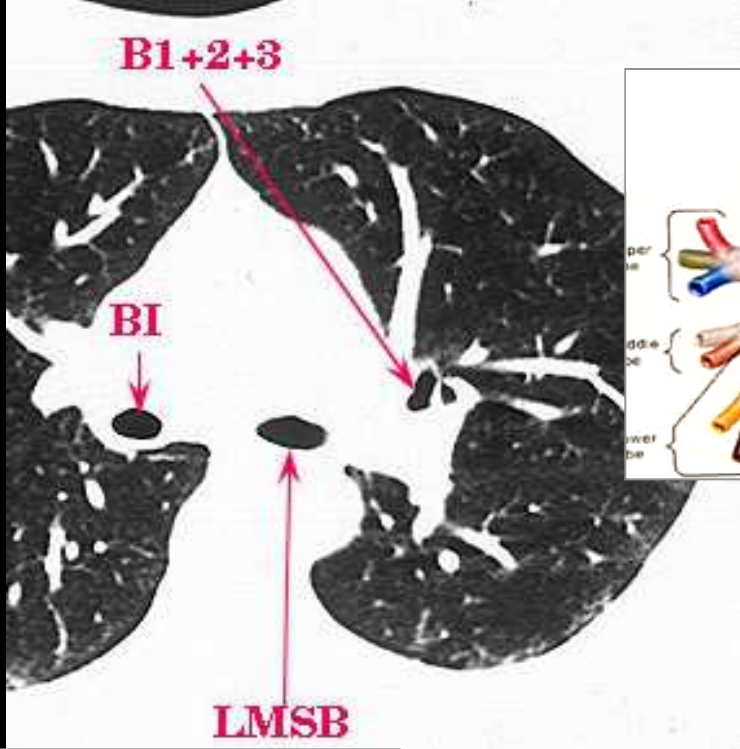


B1 apical

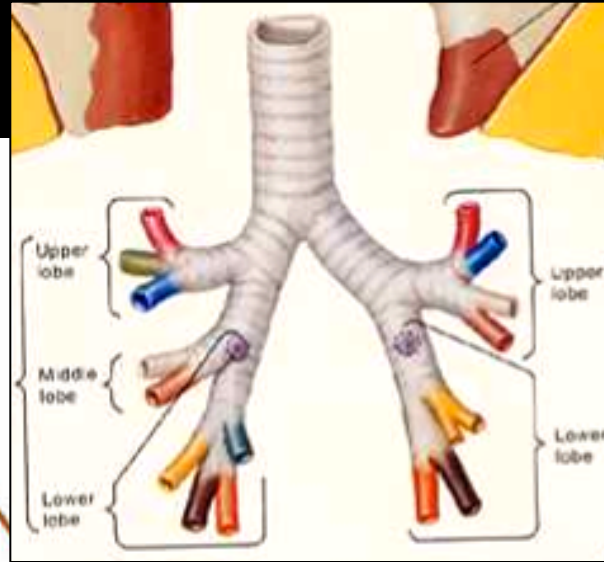


POUMON GAUCHE

Bronche Lobaire Supérieure
B1+2 apical postérieur
B3 antérieur
= culmen

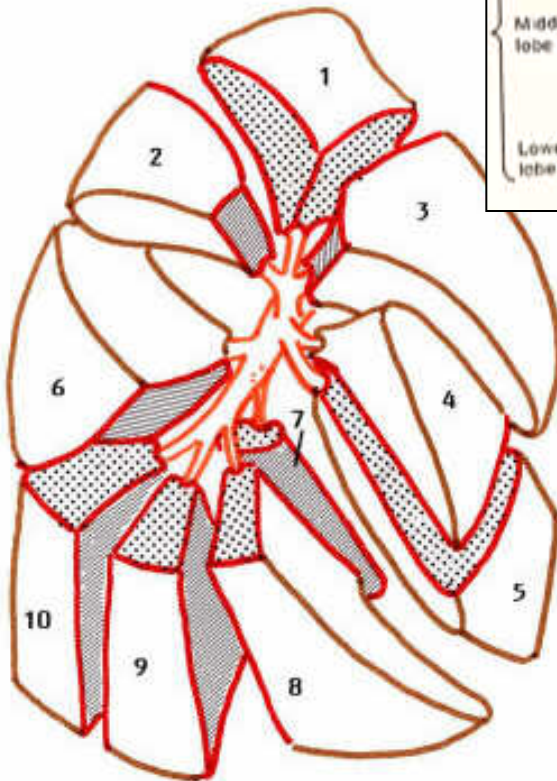


SEGMENTATION PULMONAIRE



POUMON DROIT

AV
BS



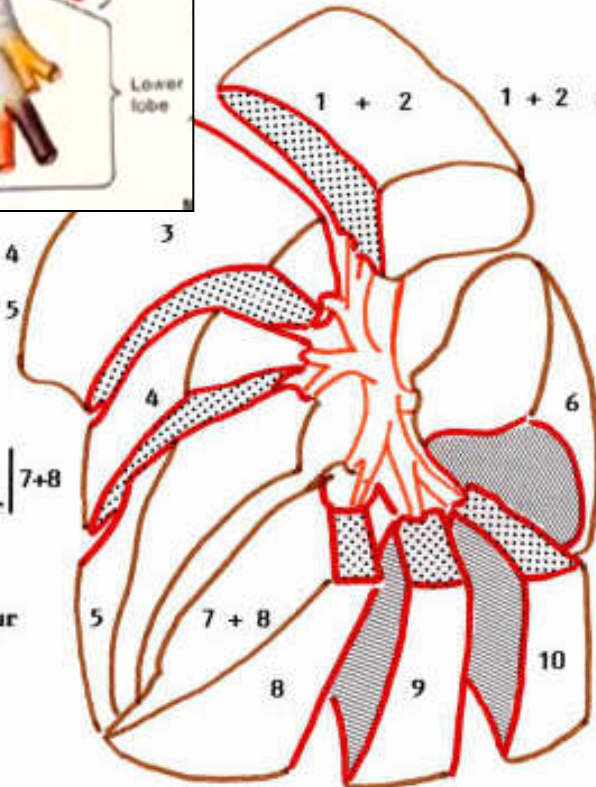
1, 2....., 10 : Nomenclature chiffrée de Boyden

- 4. Latéral Super 4
- 5. Médial Infér 5
- 6. Supérieur (apical du LI)
- 7. Basal médial
- 8. Basal antérieur
- 9. Basal latéral
- 10. Basal postérieur

7+8

POUMON GAUCHE

AV
BS

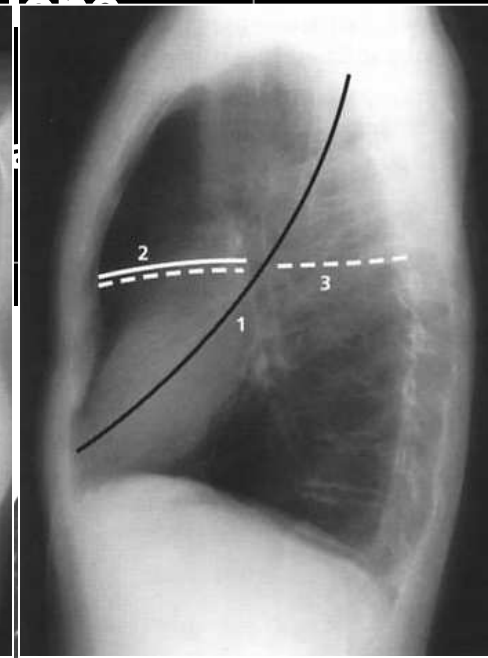
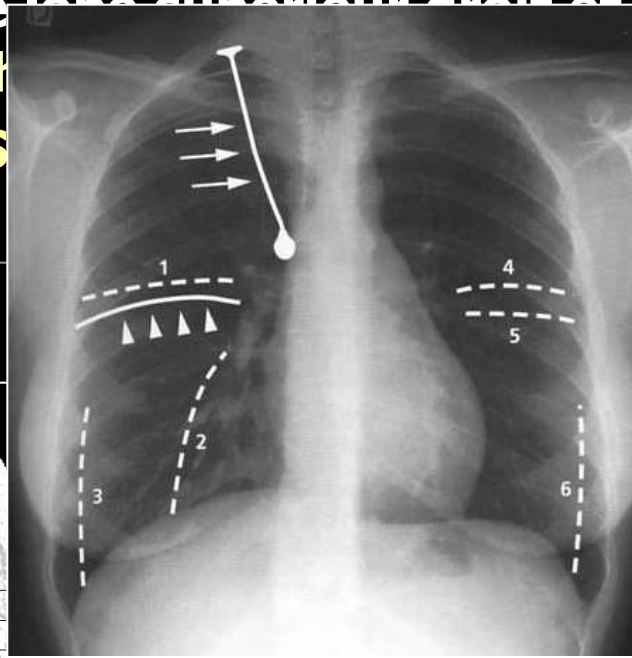
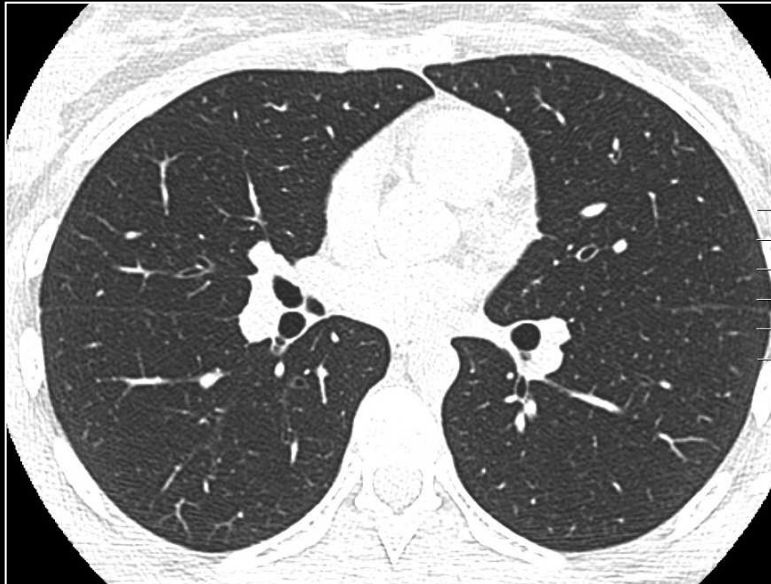

7 + 8 basal antéro-médial

1 + 2 Apico-postérieur

LES SCISSURES

- La plèvre viscérale s'insinue dans les scissures
- **GRANDES SCISSURES** entre les lobes supérieur et inférieur et sont obliques
- **PETITE SCISSURE** entre le lobe supérieur droit et lobe moyen et est proche de l'arc costal
- **SCISSURES ACCESSOIRES** la scissure verticale externe et la scissure para-cardiaque



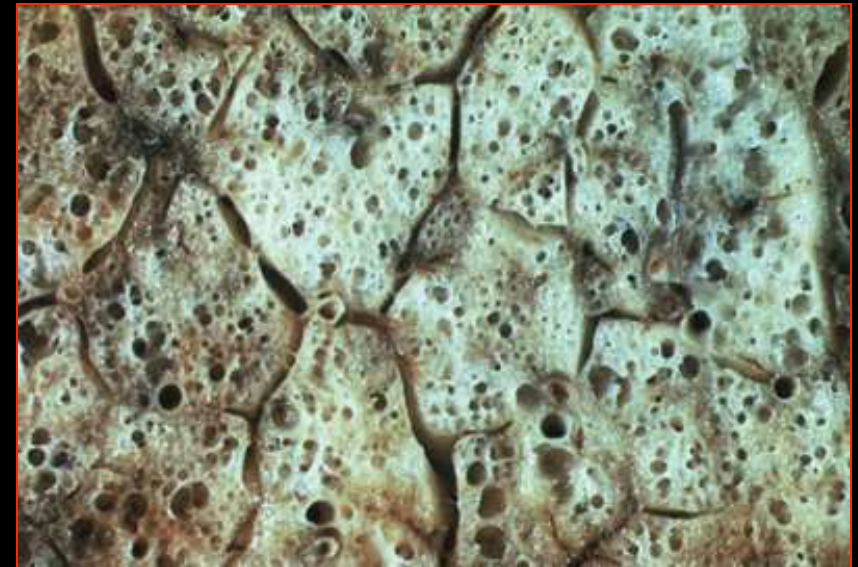
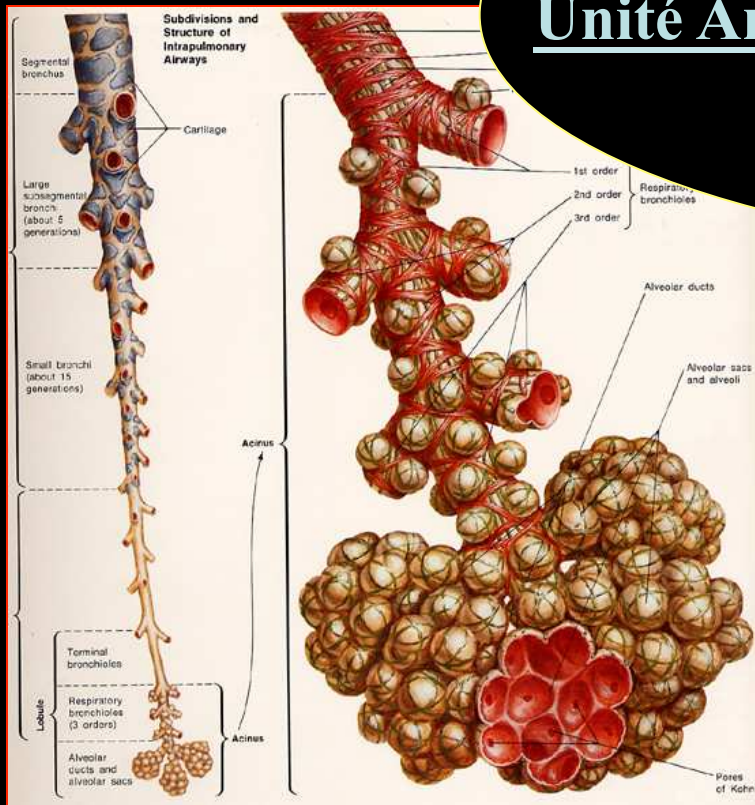
- 1.Scissure du segment S6 droit
- 2.Scissure para-cardiaque droite
- 3.Scissure verticale externe gauche
- 4.Scissure linguale
- 5.Scissure du segment S6 gauche
- 6.Scissure verticale externe gauche

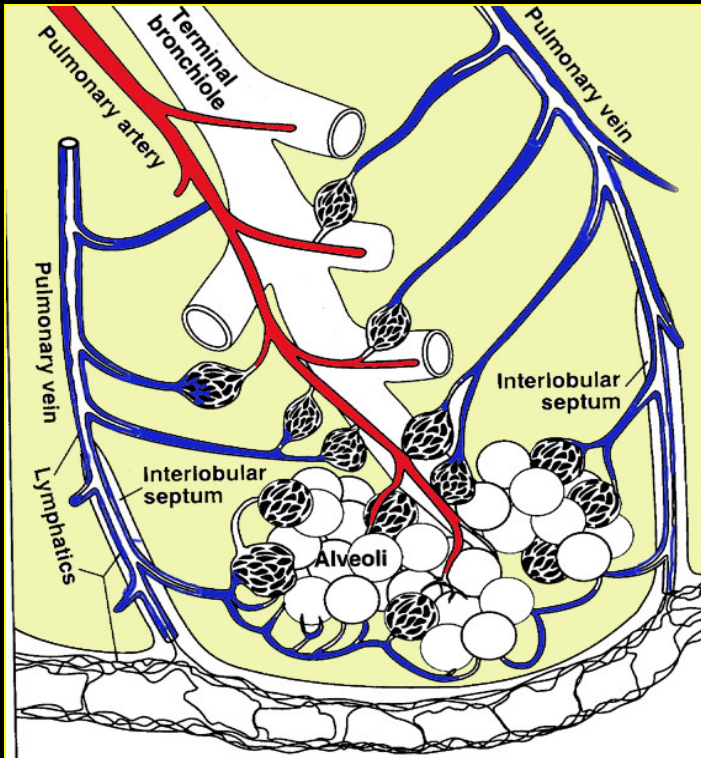
Imagerie du Lobule Secondaire

- grâce au **Scanner Haute Résolution** (coupes millimétriques)

Lobule II de Miller

Unité Anatomique et Fonctionnelle du poumon
Polyédrique, 1 à 1,5 cm
Contient 3 à 5 acini





Bronchiole centrolobulaire

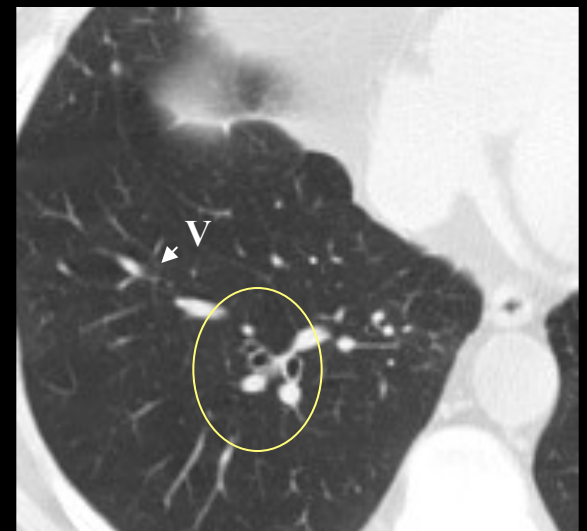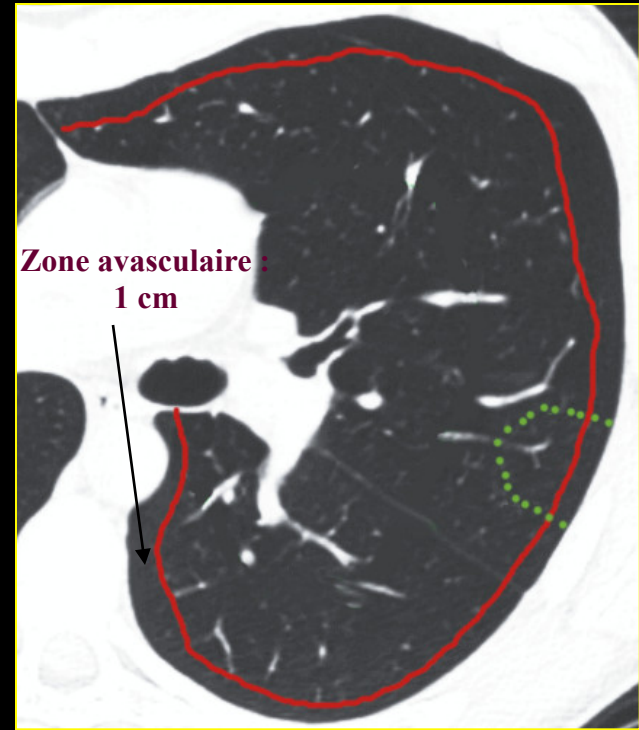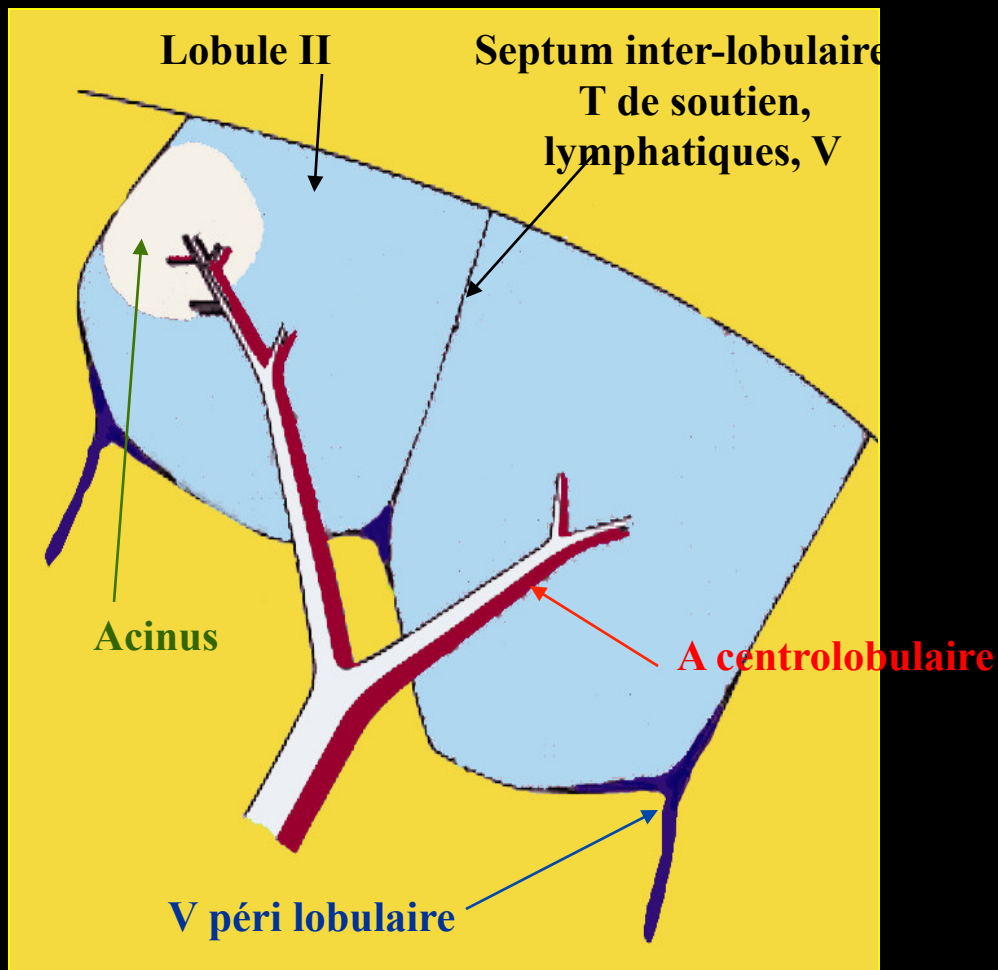


Bronchioles terminales



**Bronchioles respiratoires/ bordées
d'alvéoles (=acinus ou lobule primaire
de Miller)**

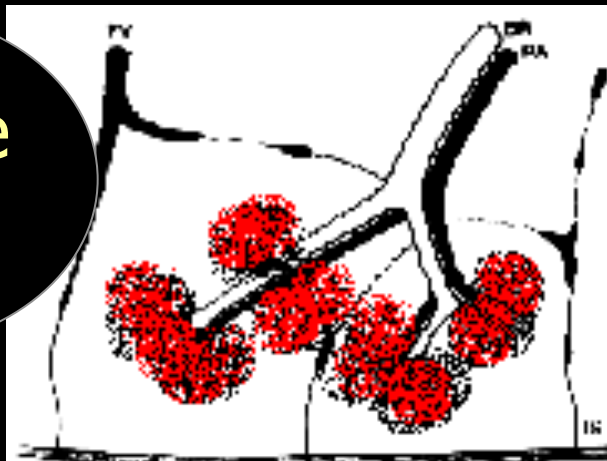- ✓ **Membrane Air/Sang** : Échanges gazeux alvéolo-capillaires
- ✓ **Secteur Interstitiel** (de soutien) :
 - Inter et péri lobulaire (V et lymphatiques)
 - Sous pleural
 - Péri Bronchovasculaire (jusqu' au hile)
- ✓ **Secteur aérique** : alvéolaire, bronchique



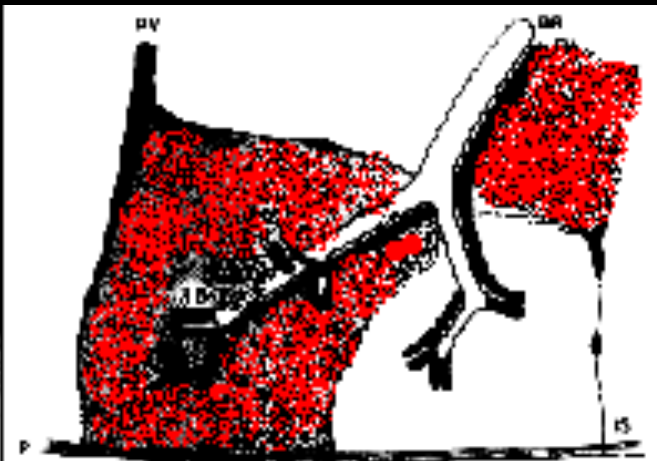A l'état normal :
Bronchioles et septa non vus, en périphérie
A. visualisées plus loin que V.

Différentes atteintes pulmonaires

Aérique
Alvéoles,
Bronches

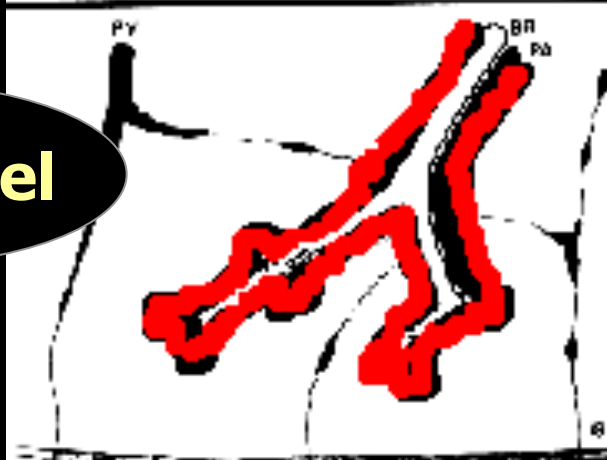

Centilobular

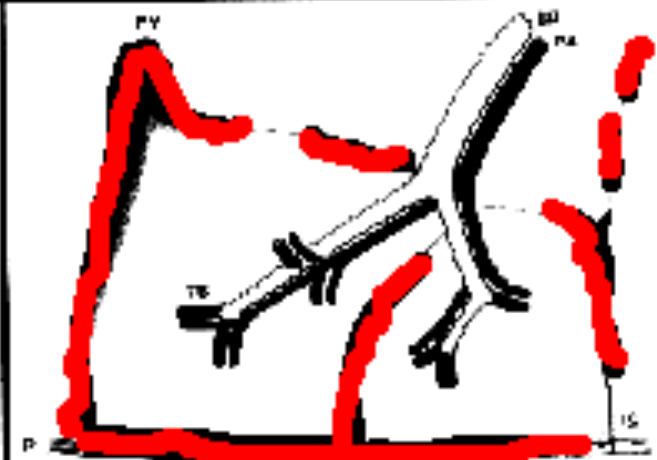

Panlobular

Interstitiel

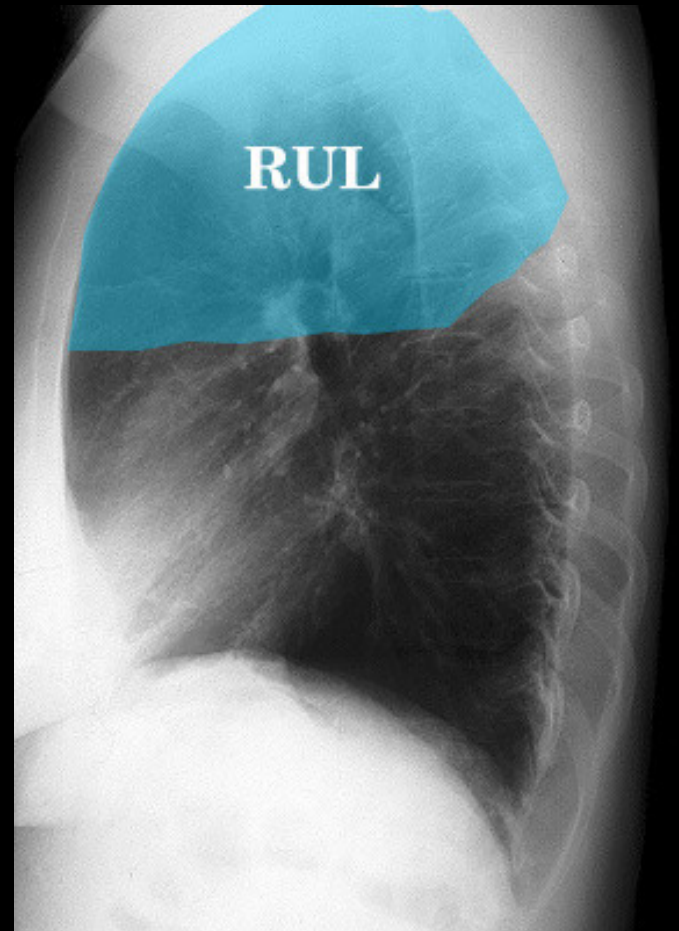
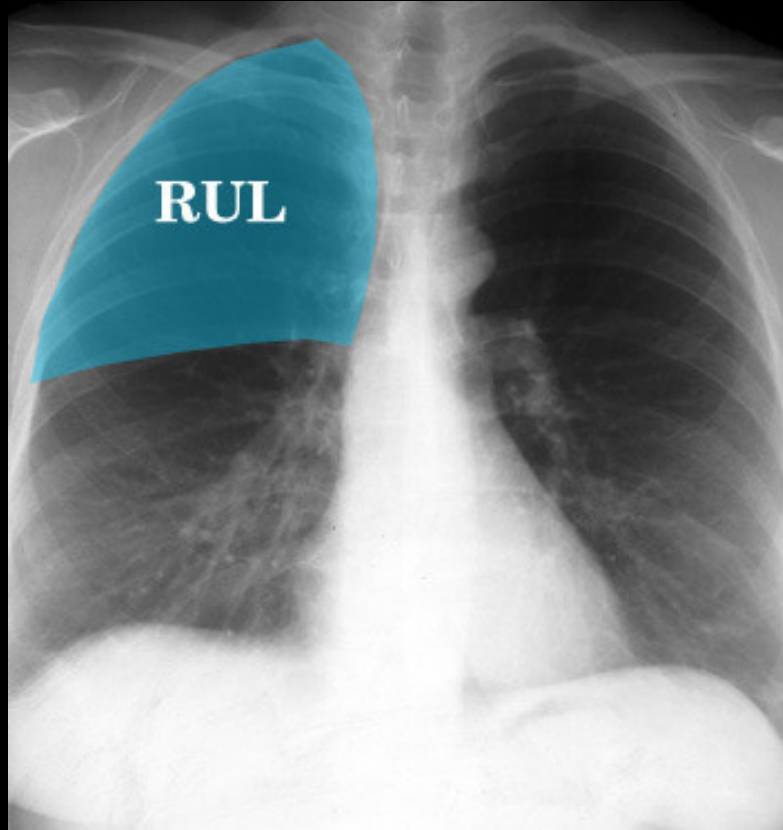


T. Soutien péri-broncho-vascul

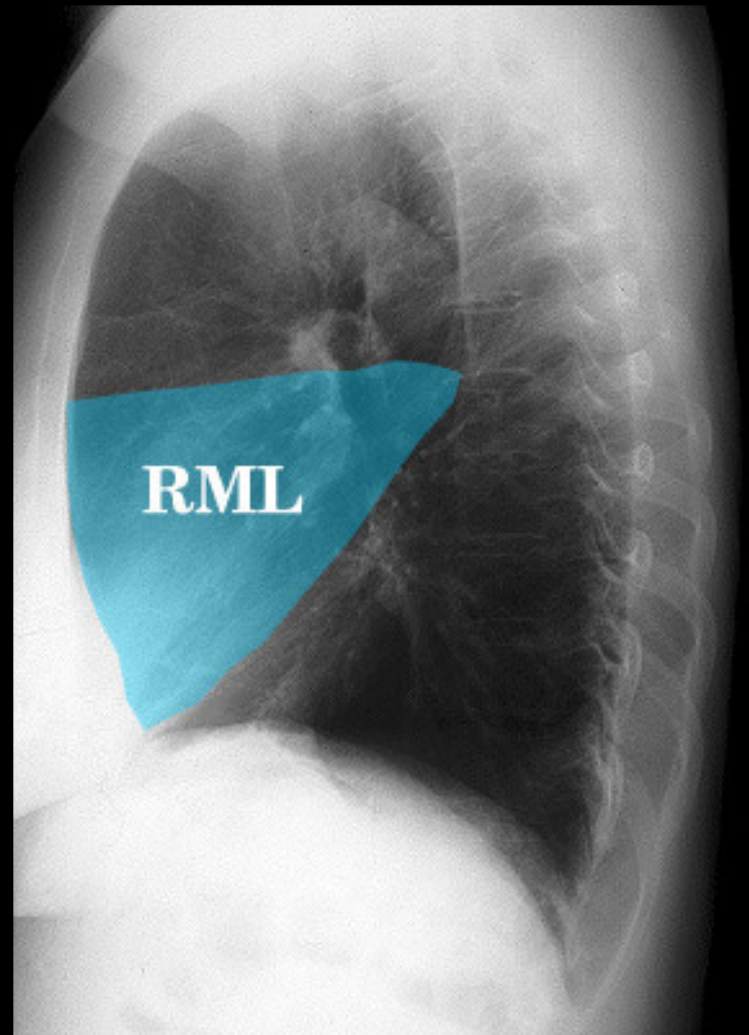
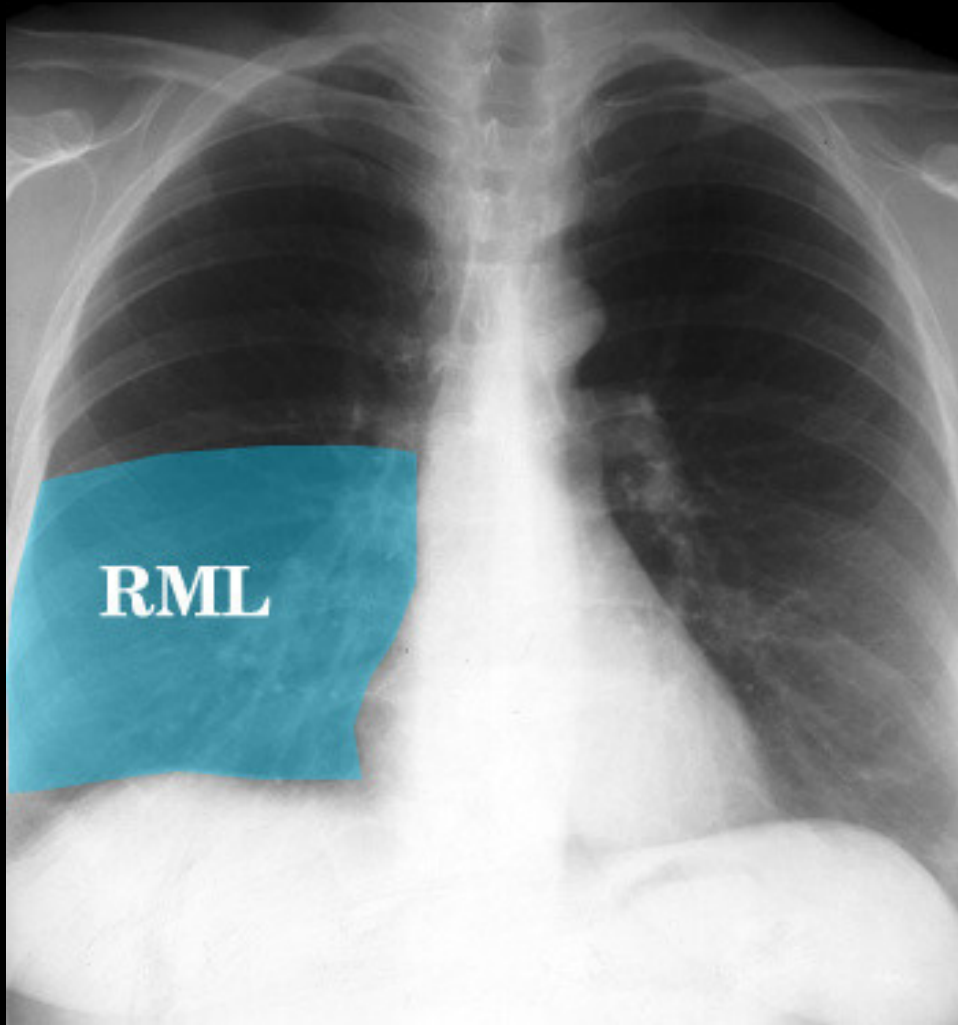


Septal (Perilobular)

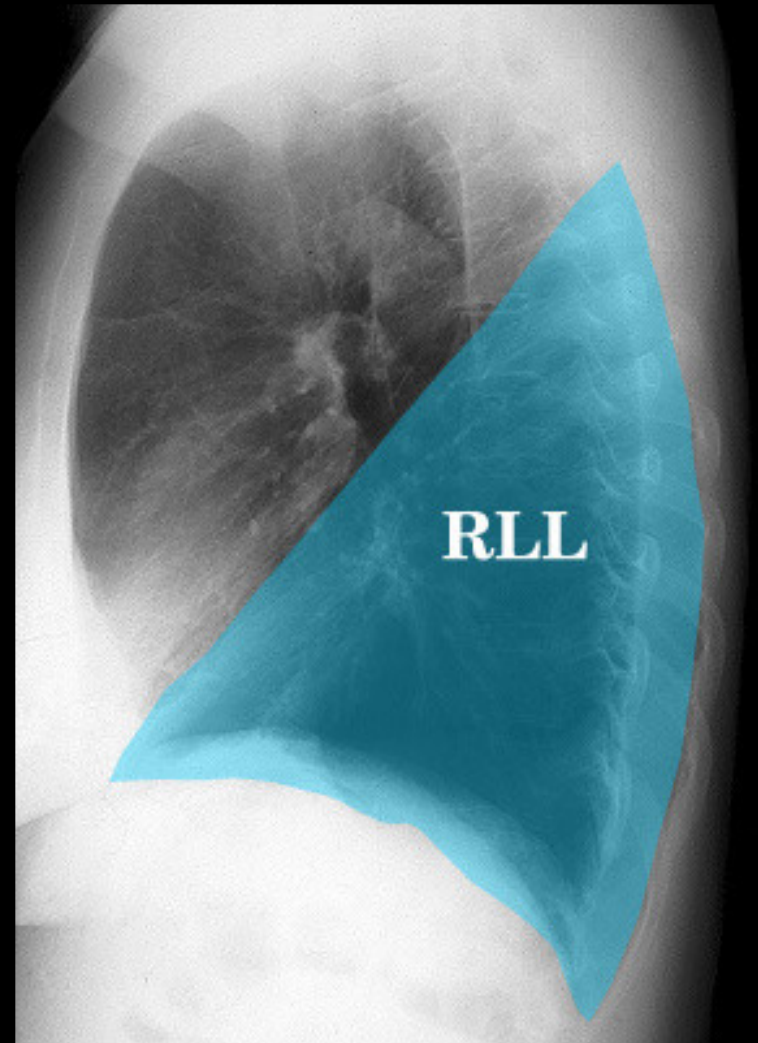
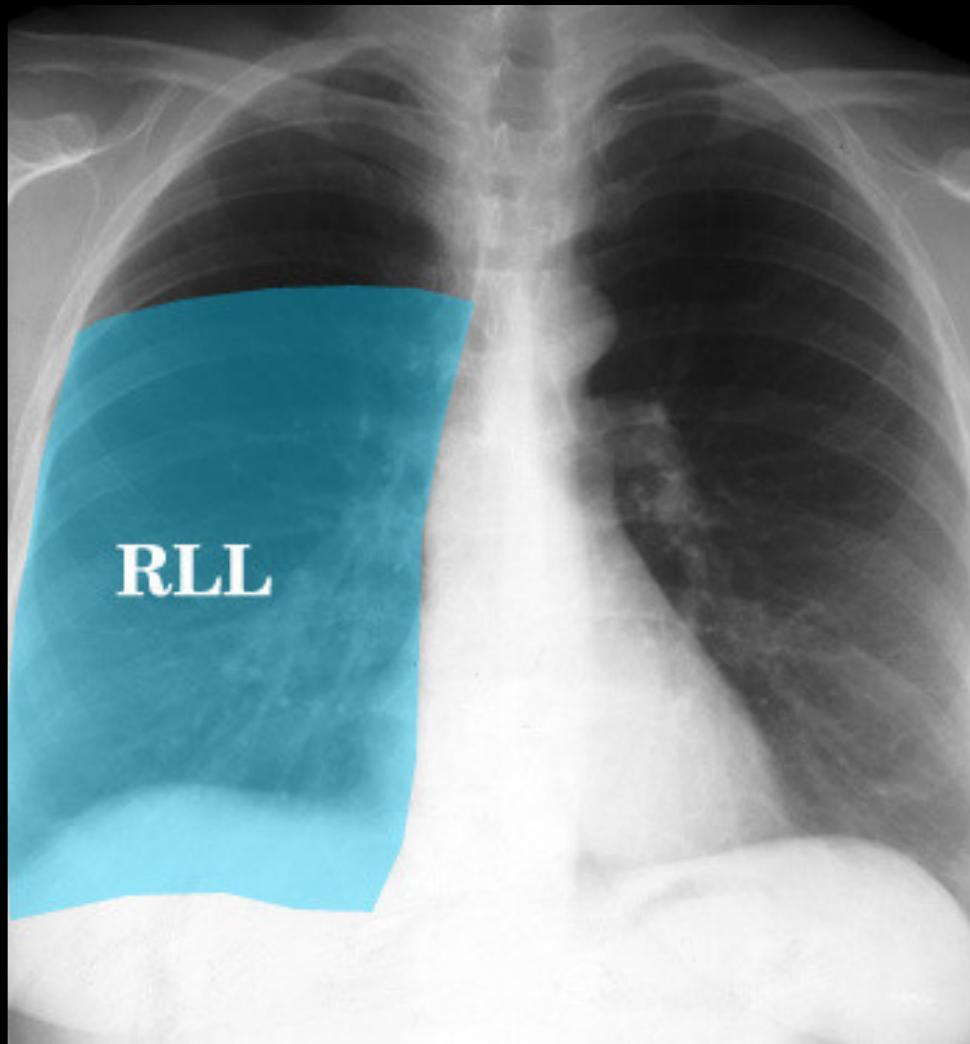
Radiographie standard



Lobe supérieur droit

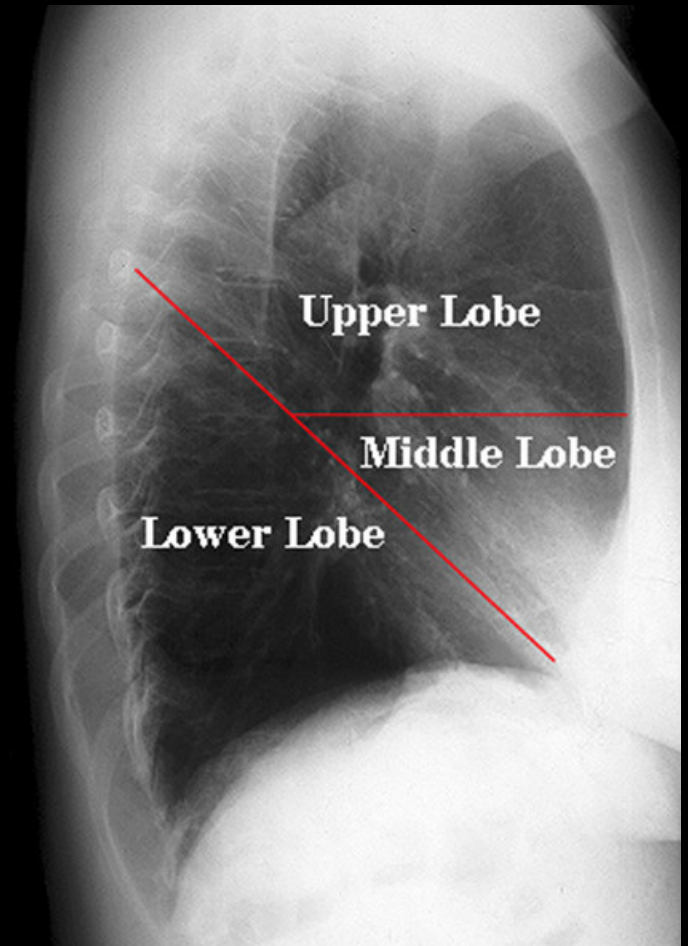
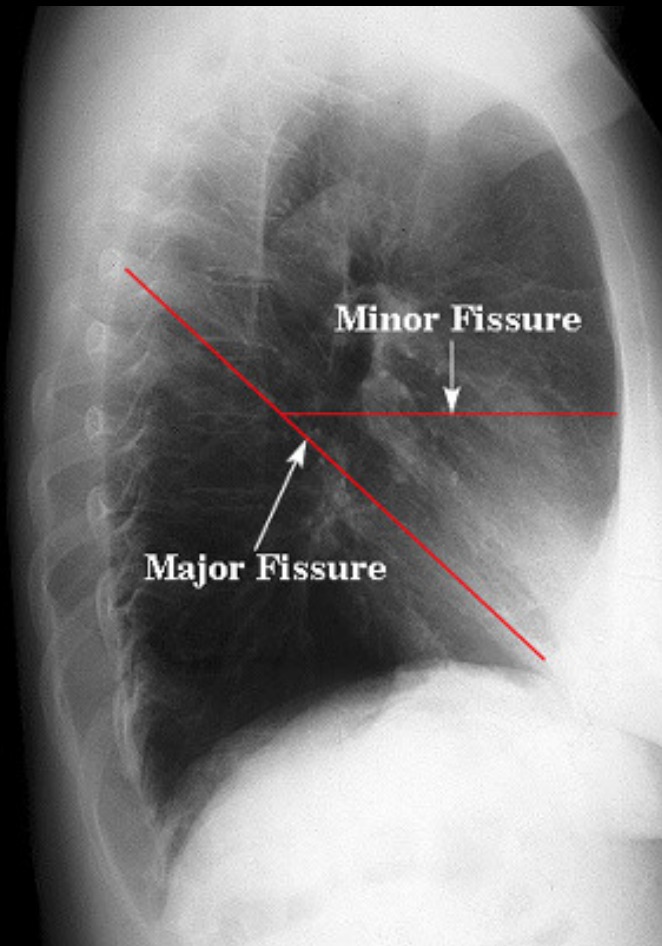


Lobe moyen



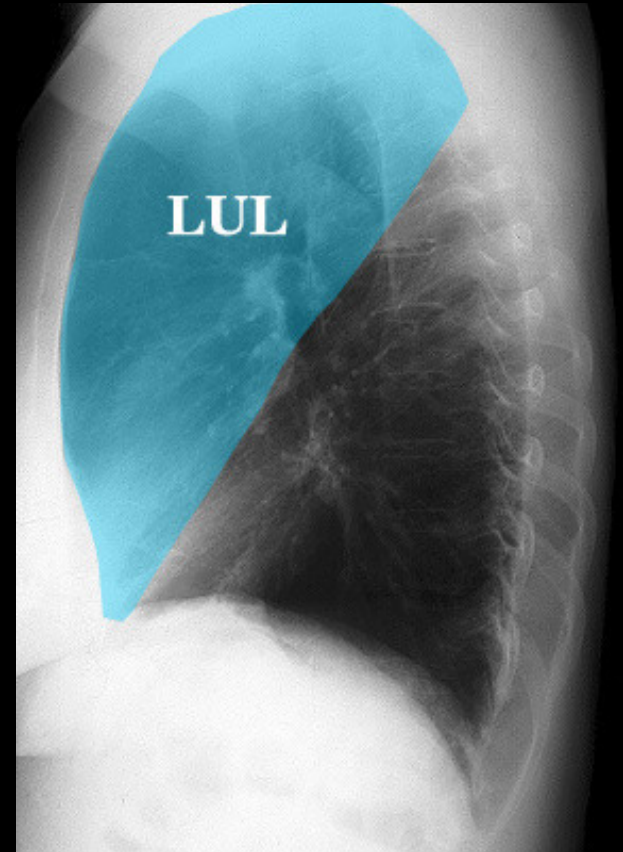
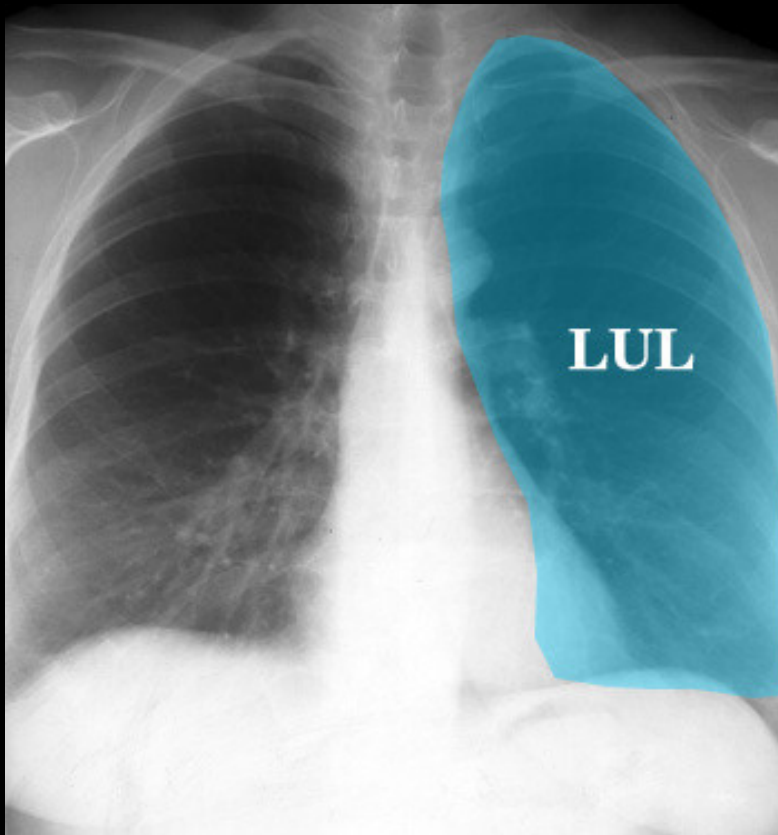
Lobe inférieur droit

A droite: les scissures

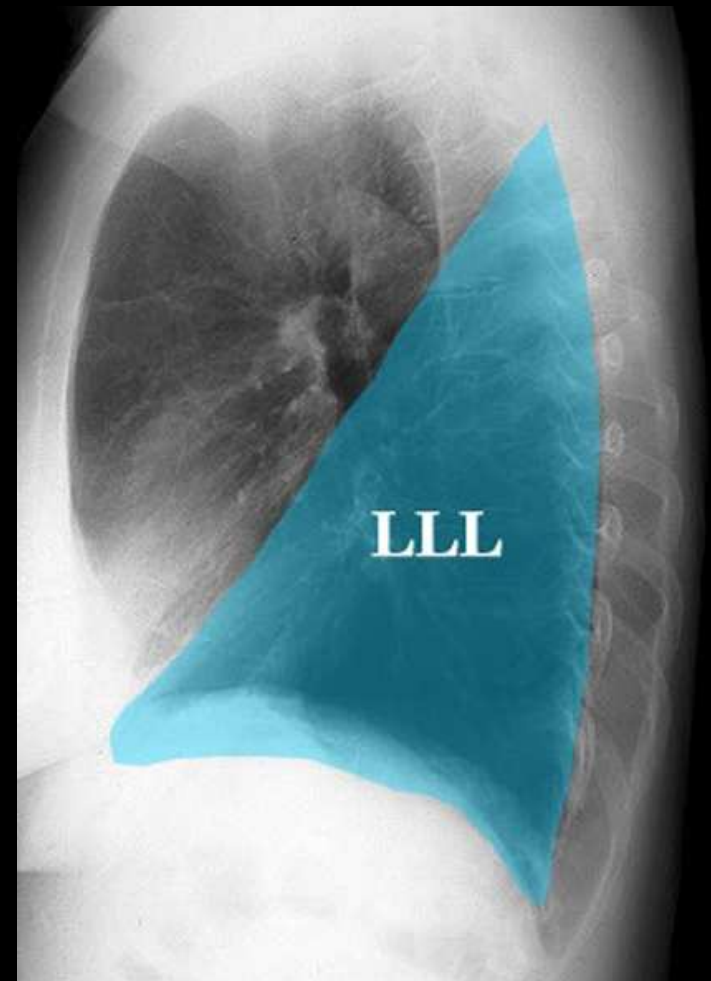
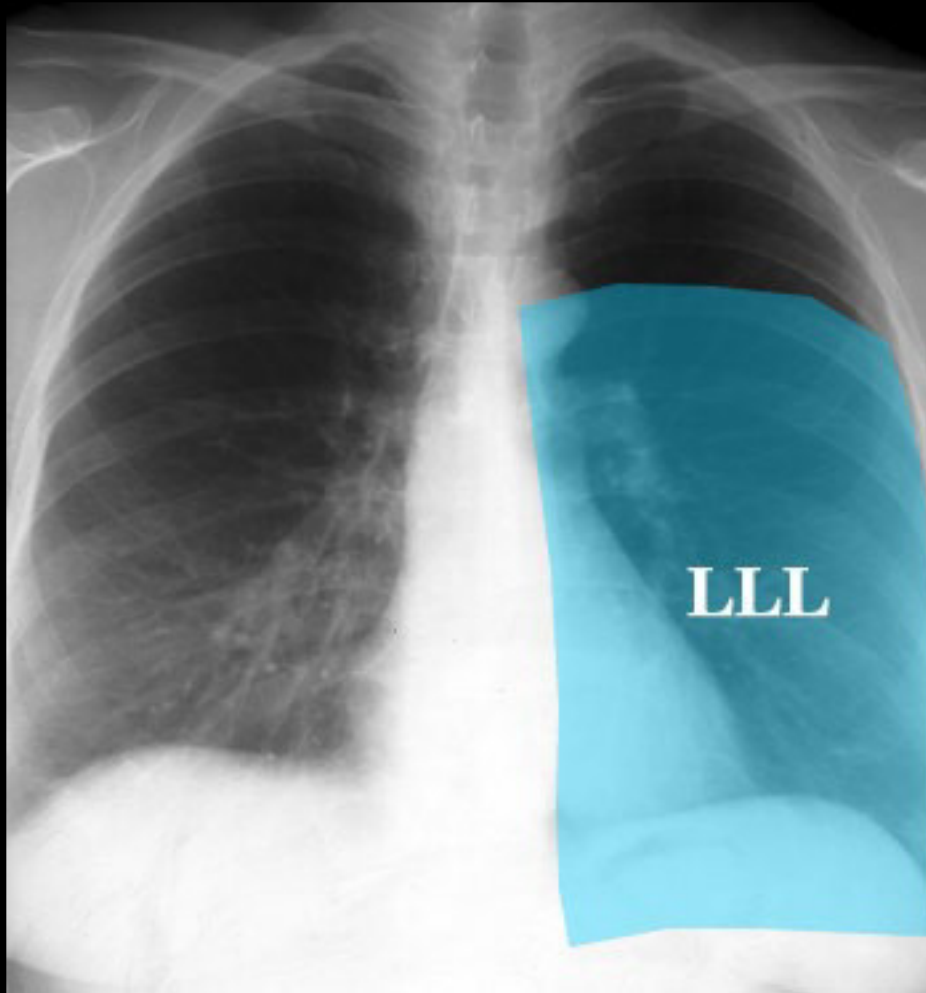


Application : Le signe de la silhouette de Felson

- 2 structures de tonalité hydrique se confondent si elles sont situées dans le même plan
- De grande valeur pour la détermination topographique d'une opacité intra thoracique qu'elle soit médiastinale ou pulmonaire : en effet deux opacités qui se silhouettent (en effaçant leur bord) se trouvent sur un même plan.
- ex : opacité dans le lobe moyen effaçant le bord droit du coeur.

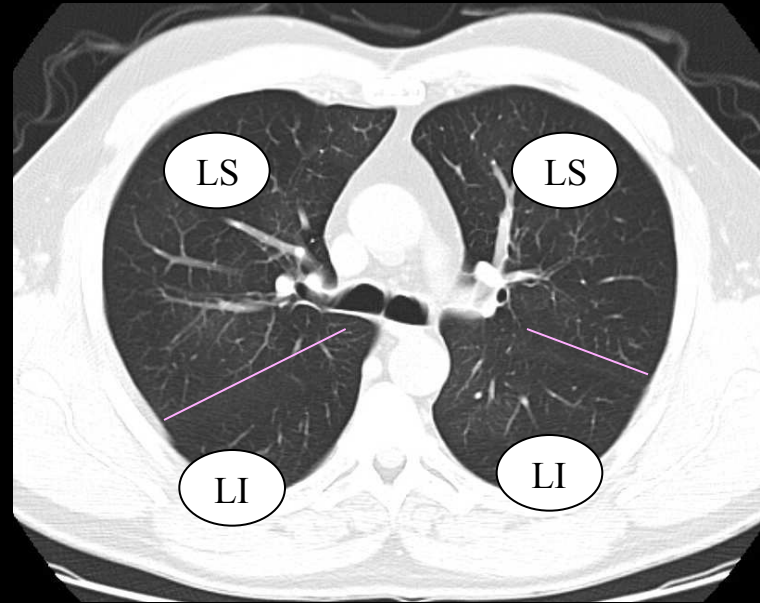
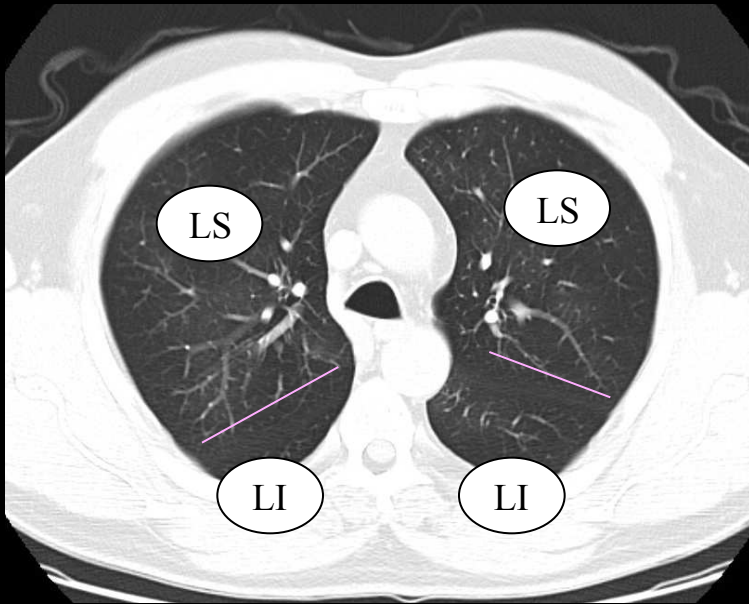
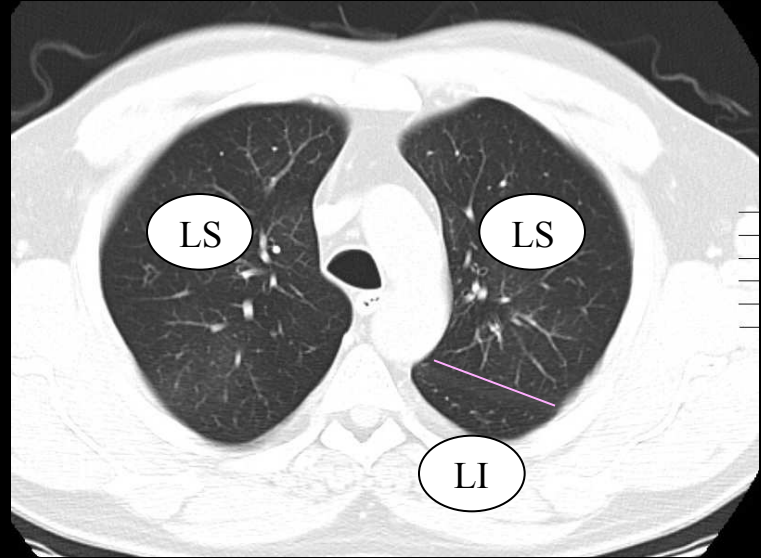
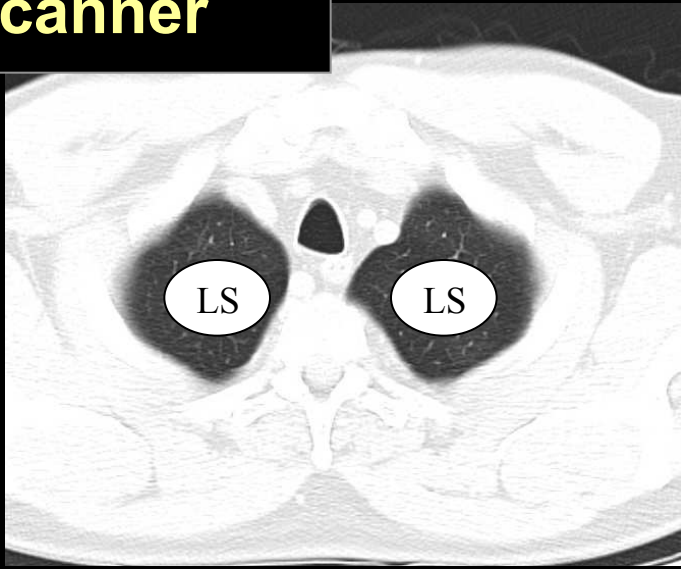


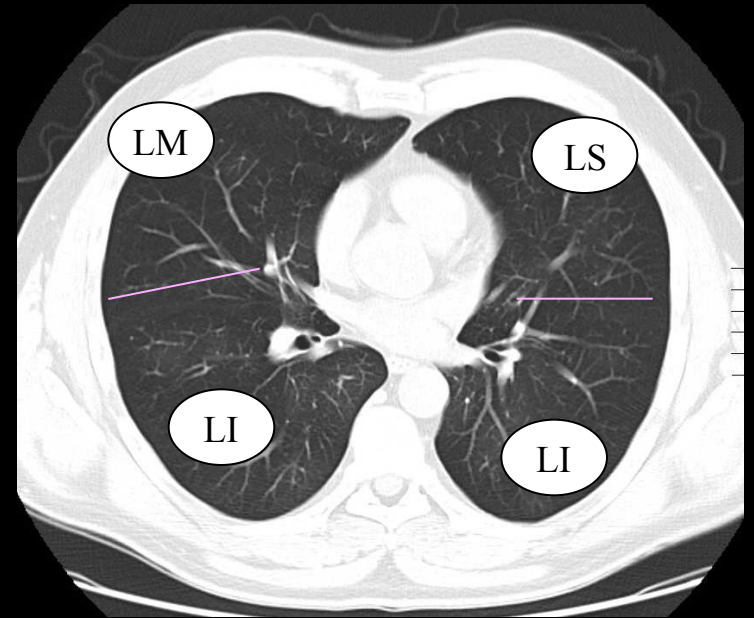
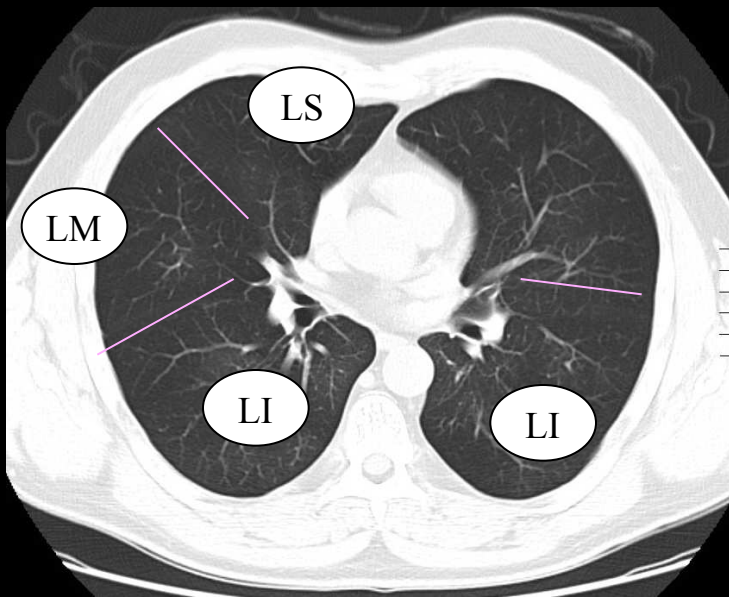
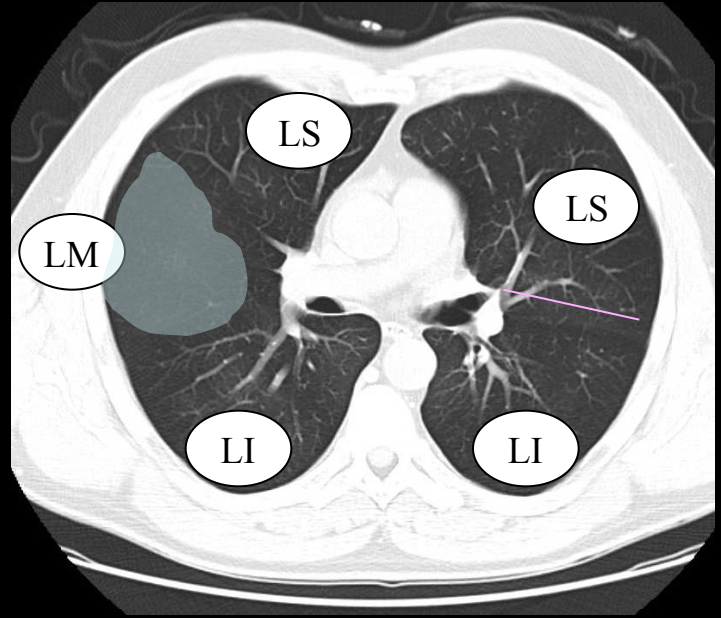
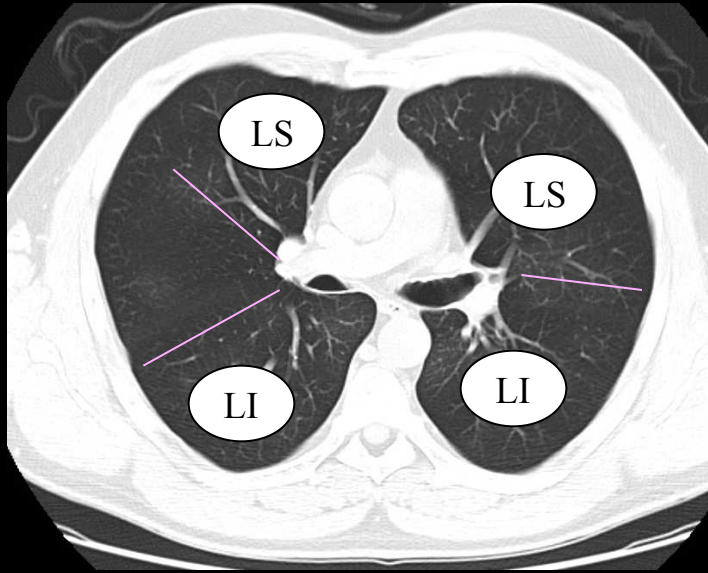
Lobe supérieur gauche

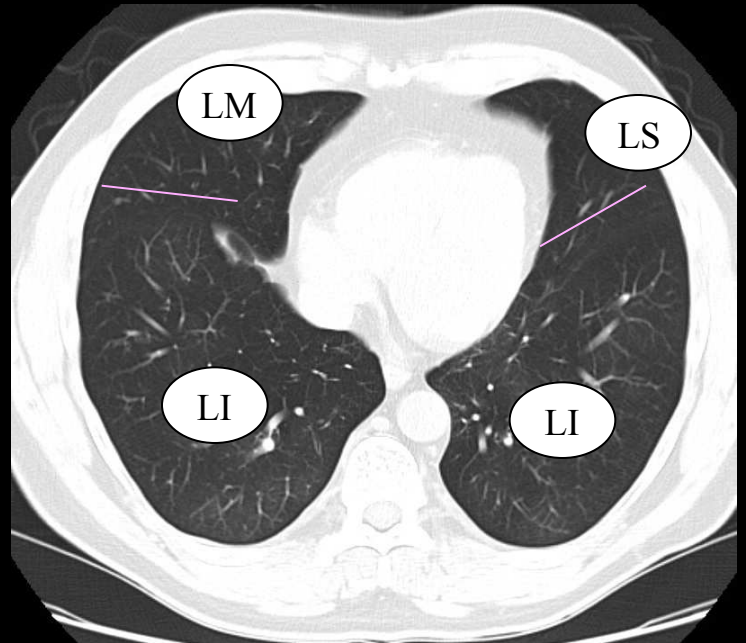
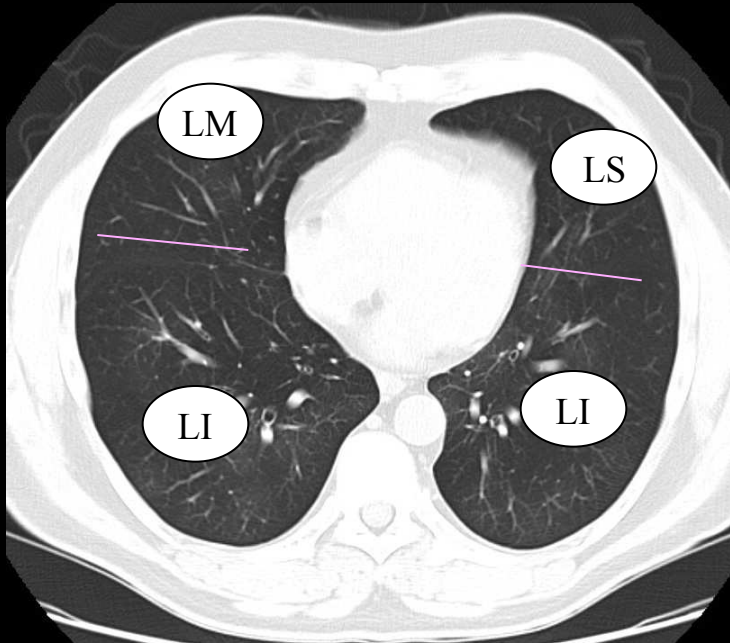
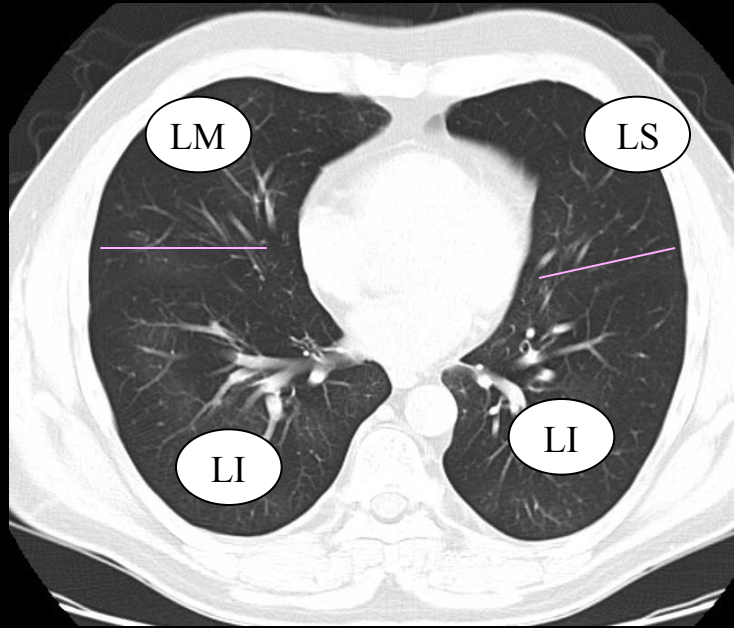
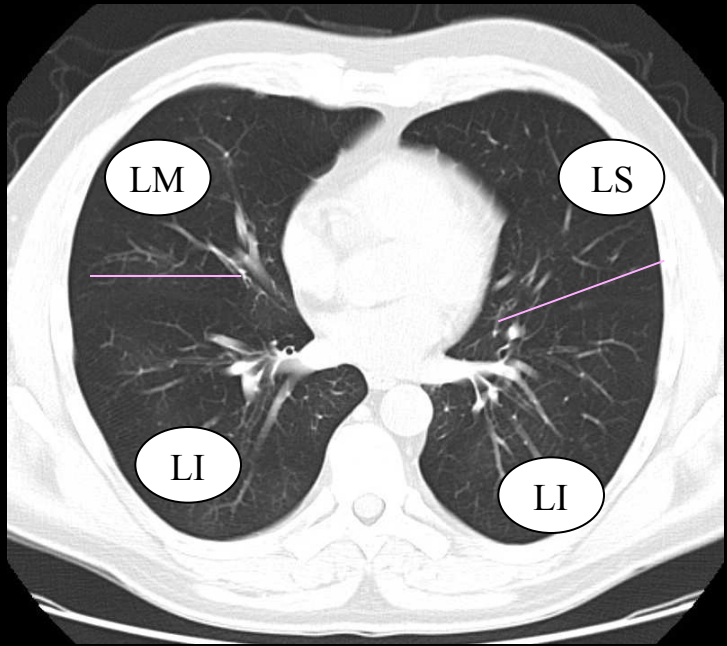


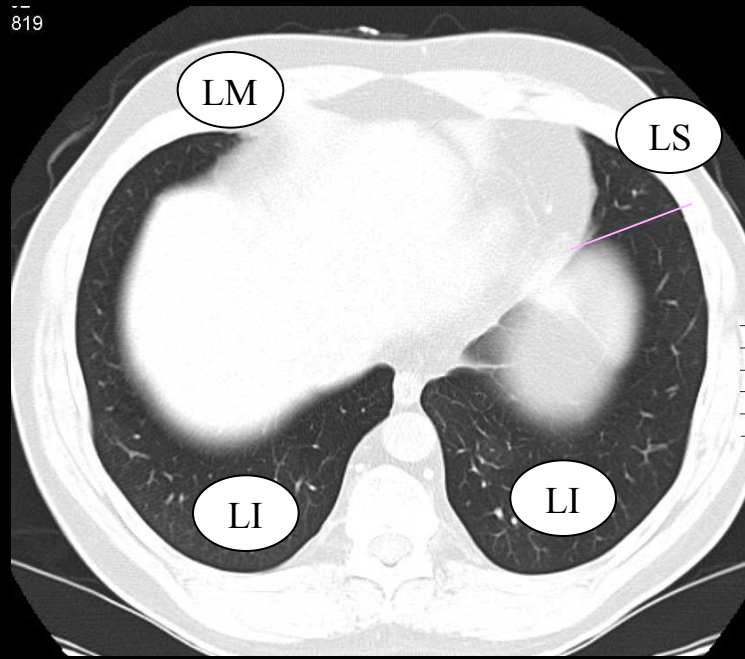
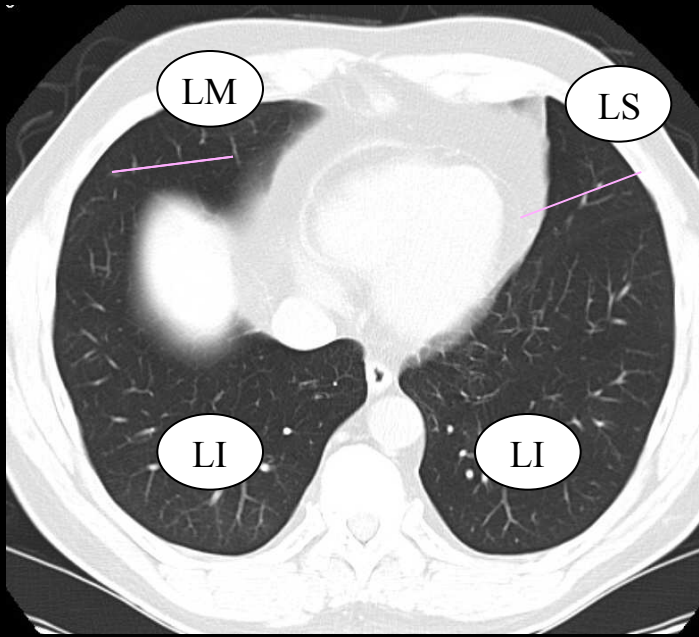
Lobe inférieur gauche

Scanner

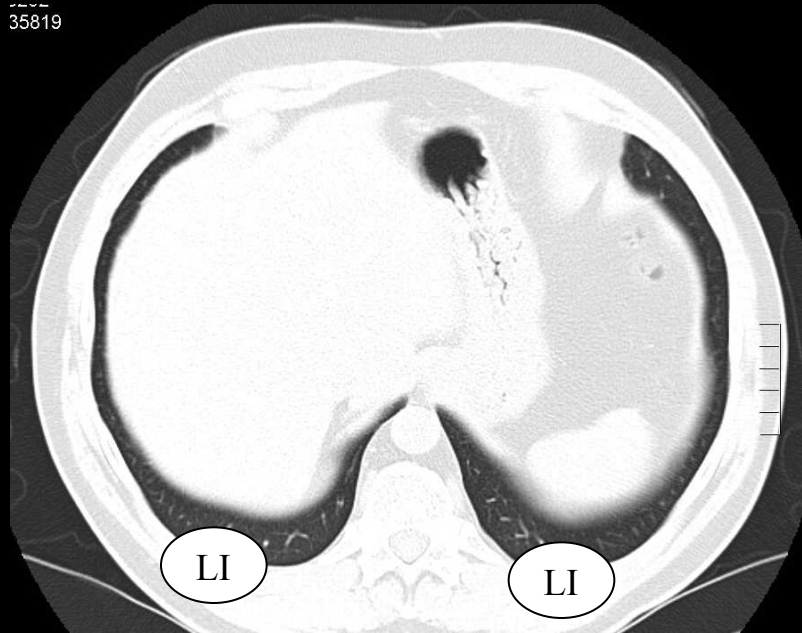


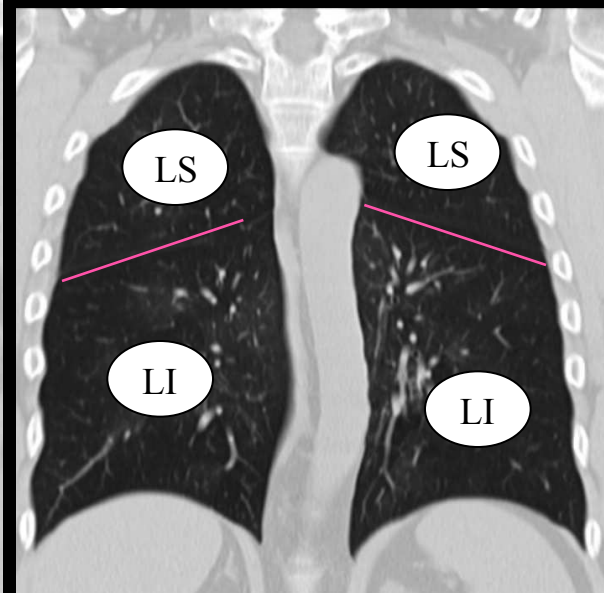
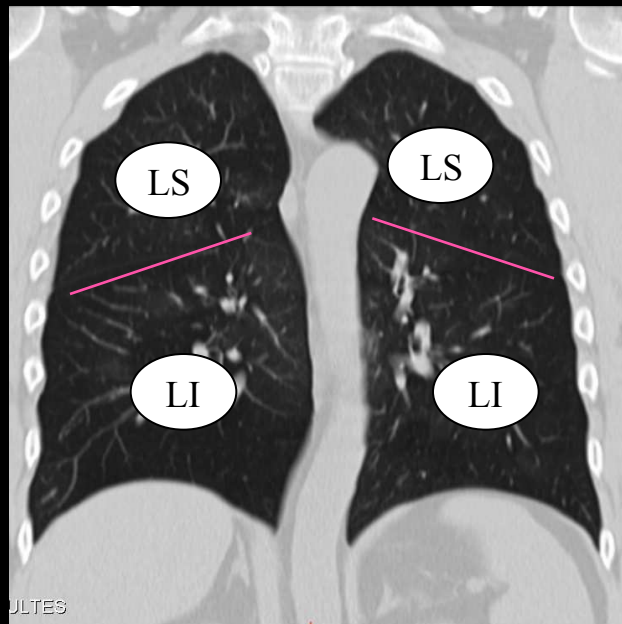
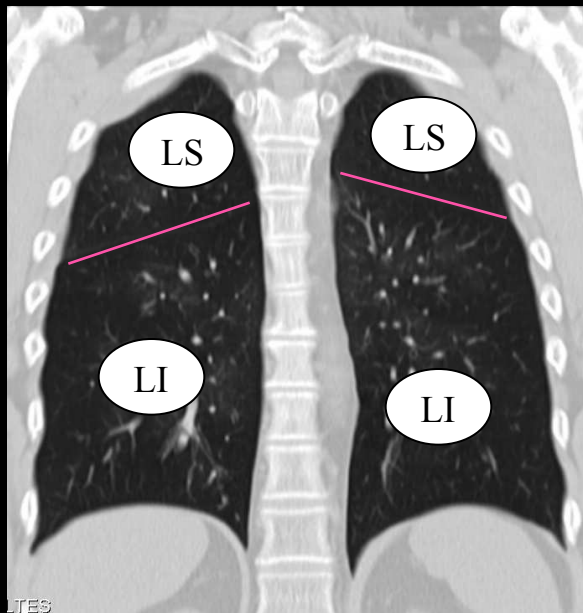
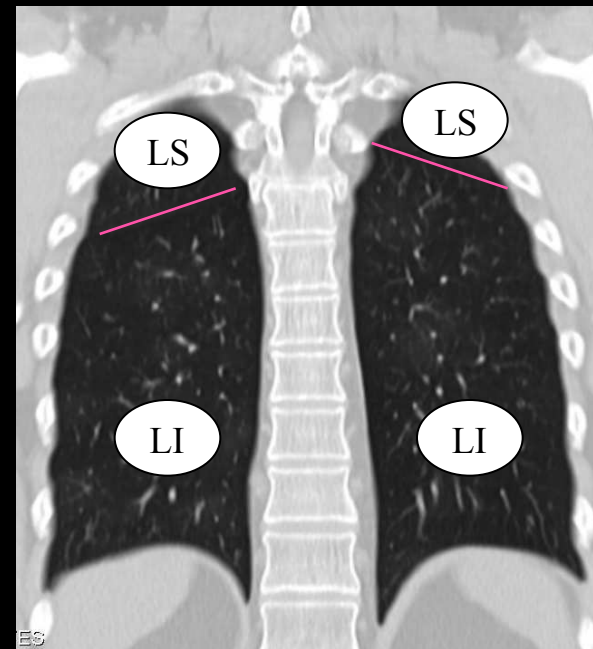
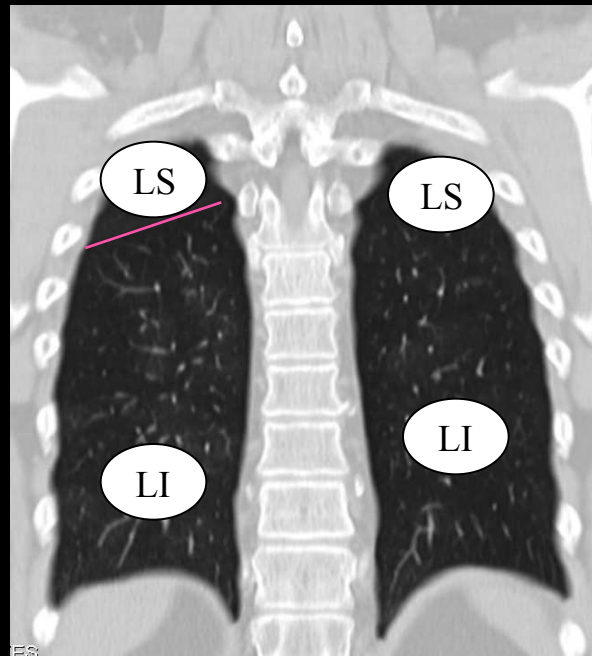
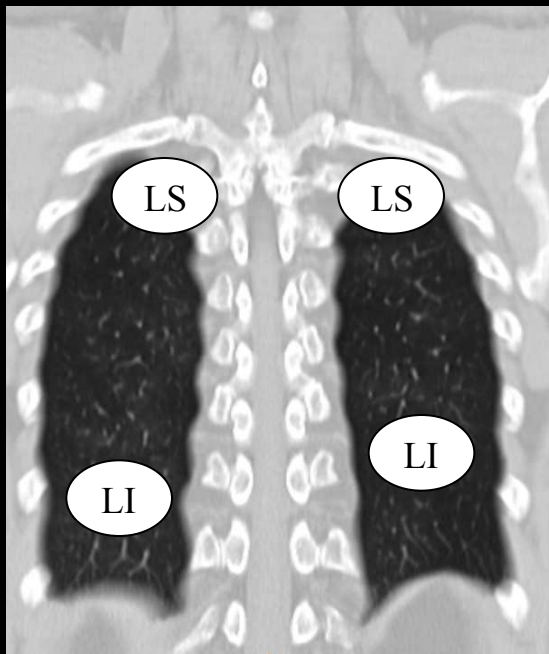


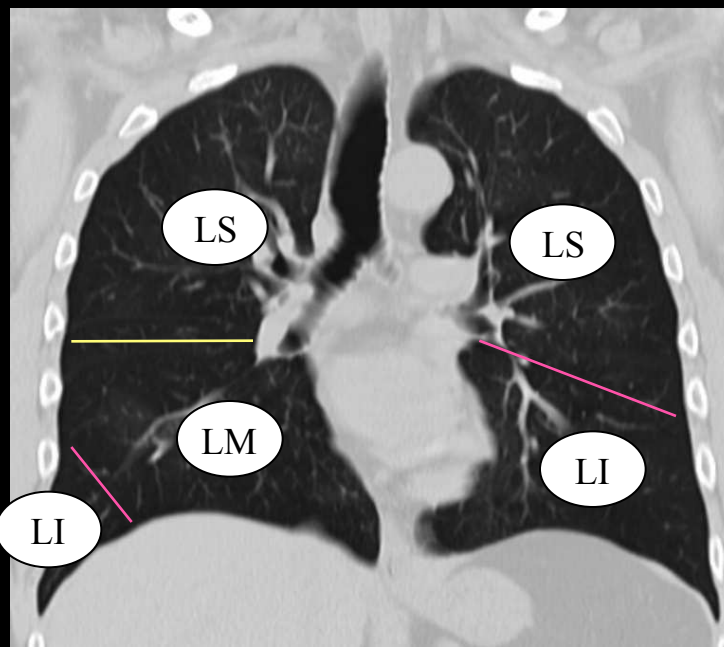
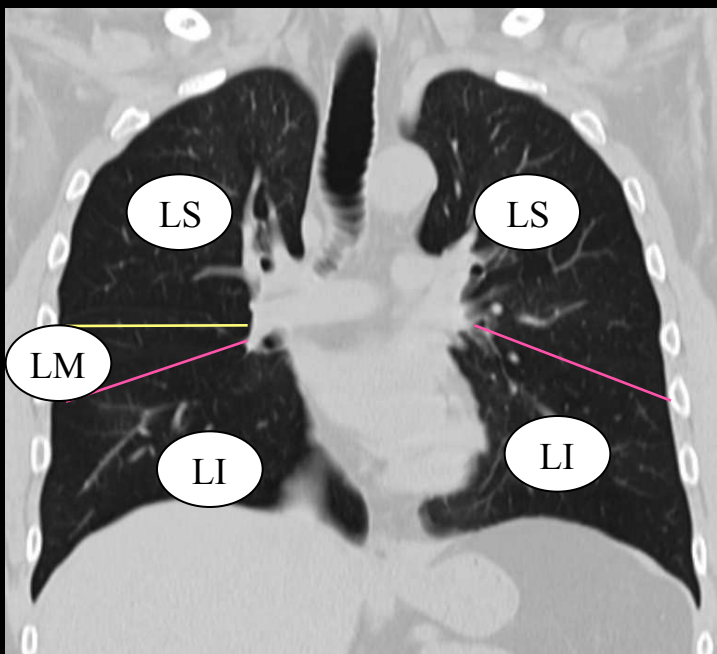
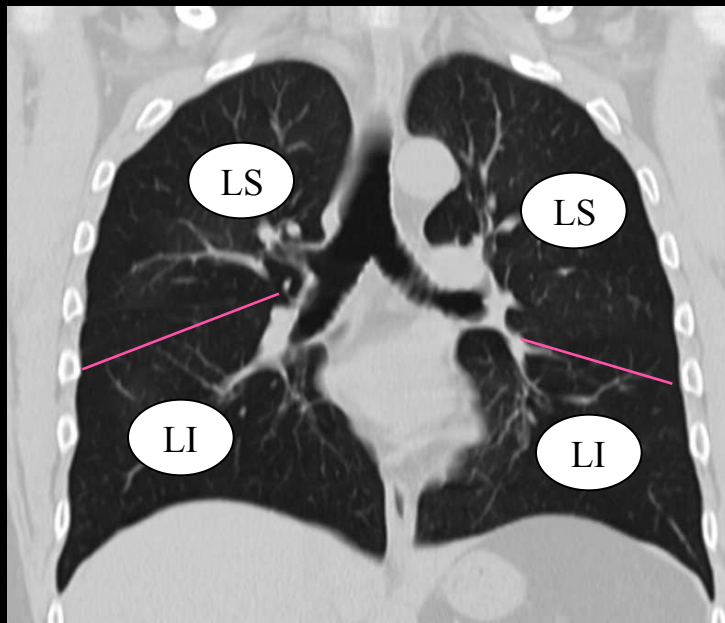
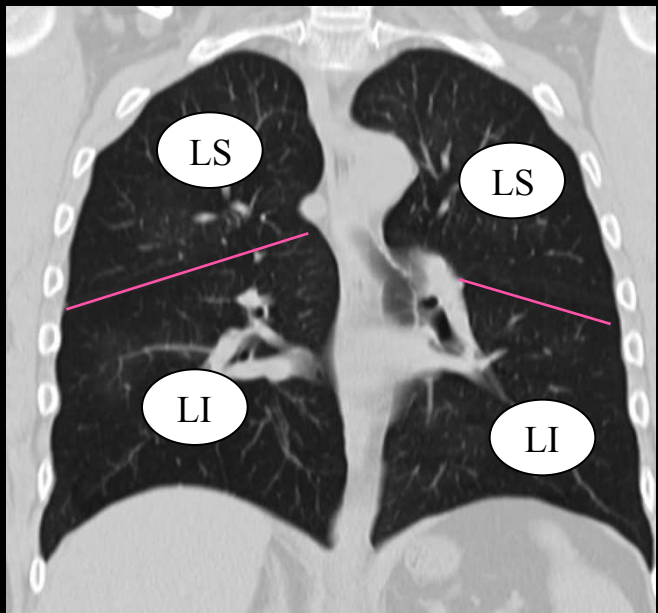


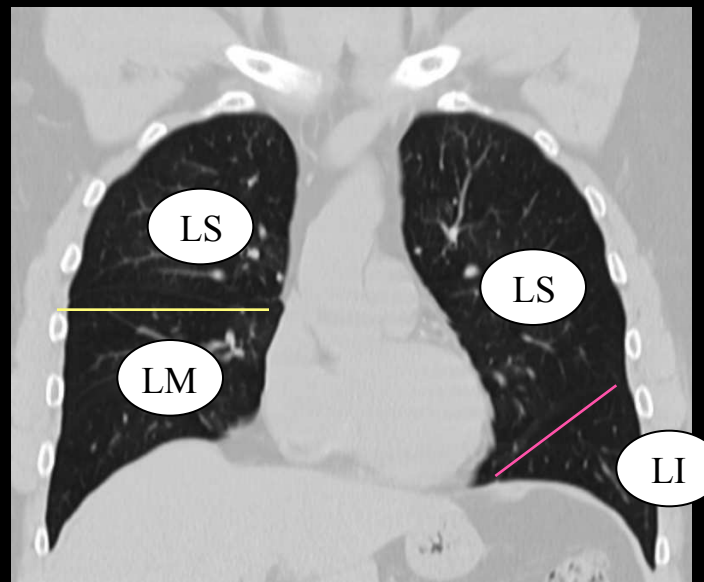
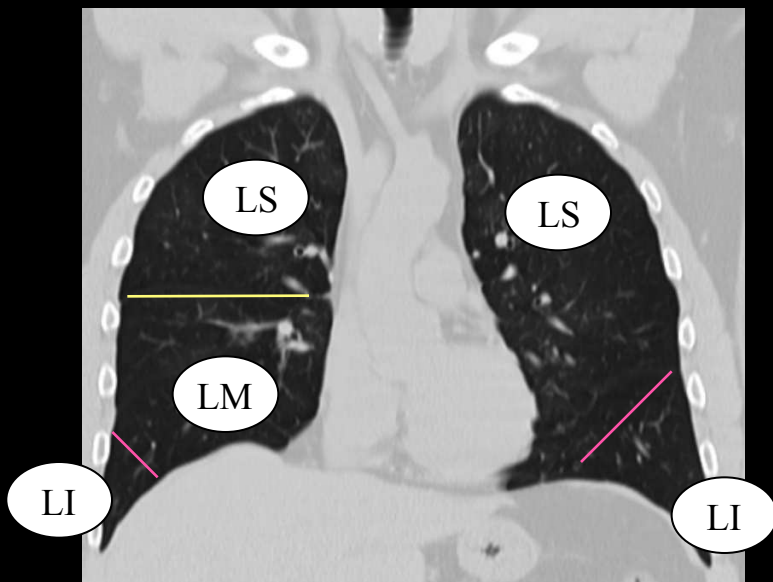
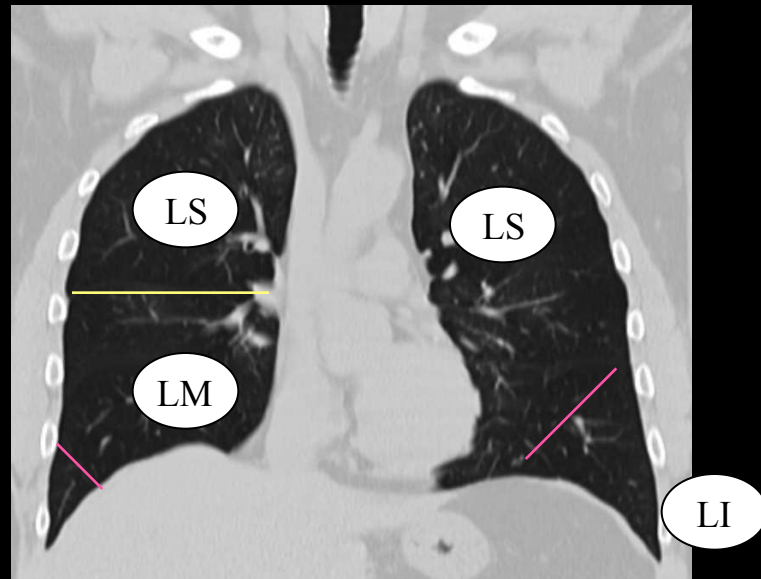
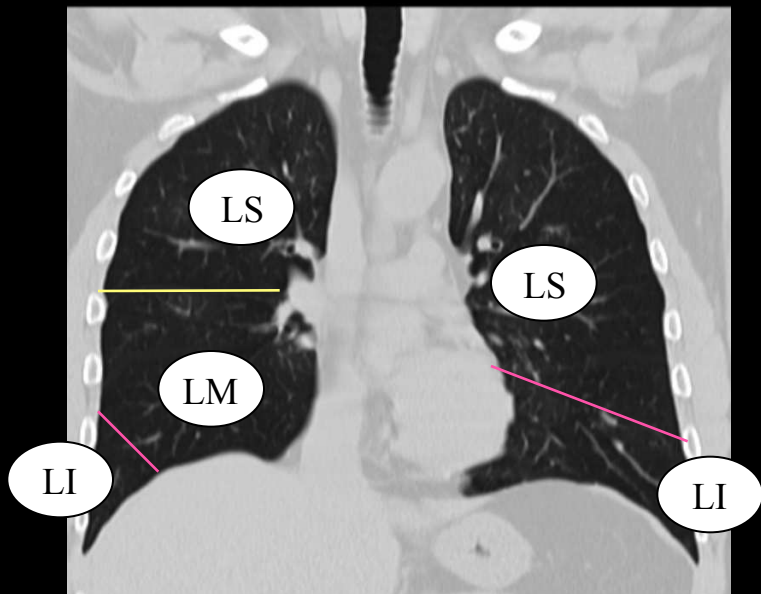


35819





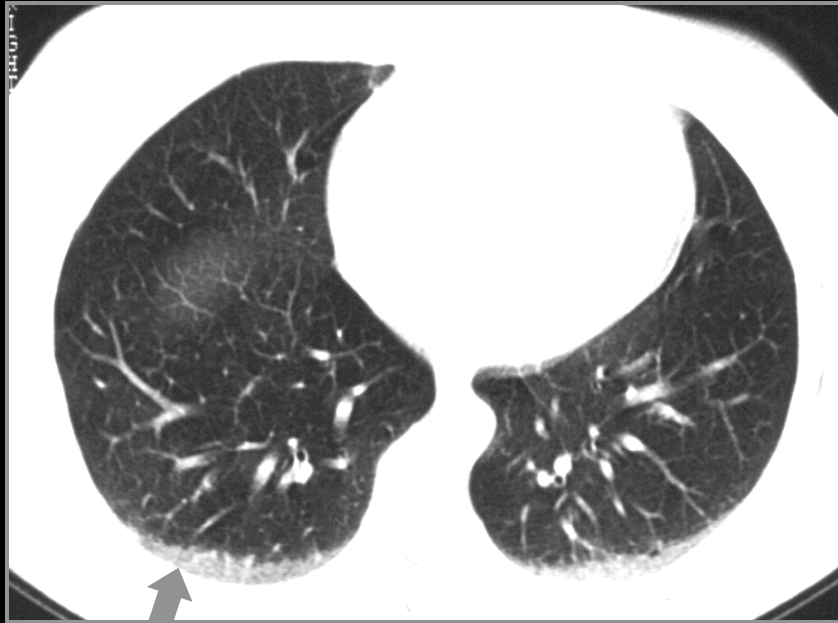






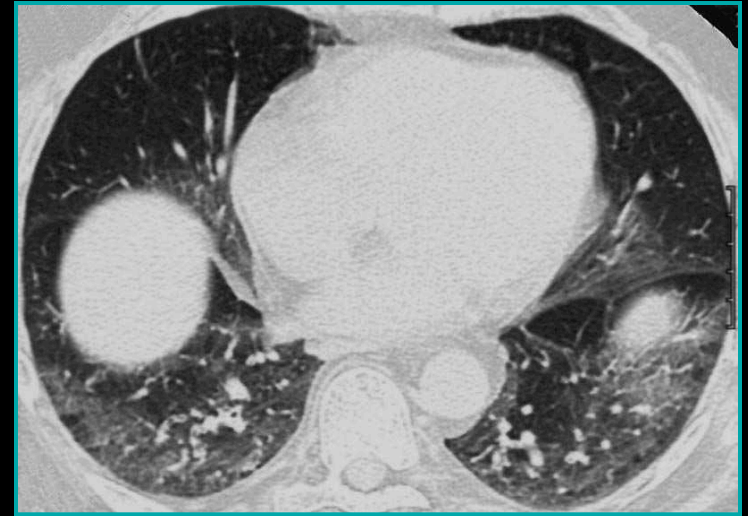
**UN PEU DE PATHOLOGIE ET
VARIATIONS ANATOMIQUES...**

Stase Physiologique

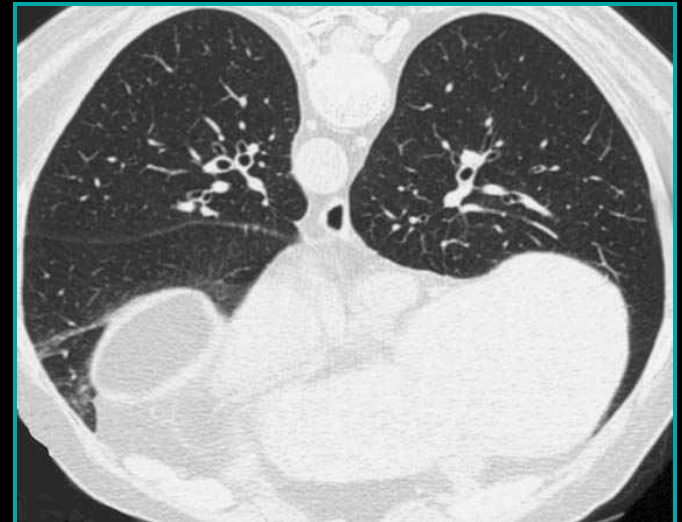


Territoires
Déclives

inspiration



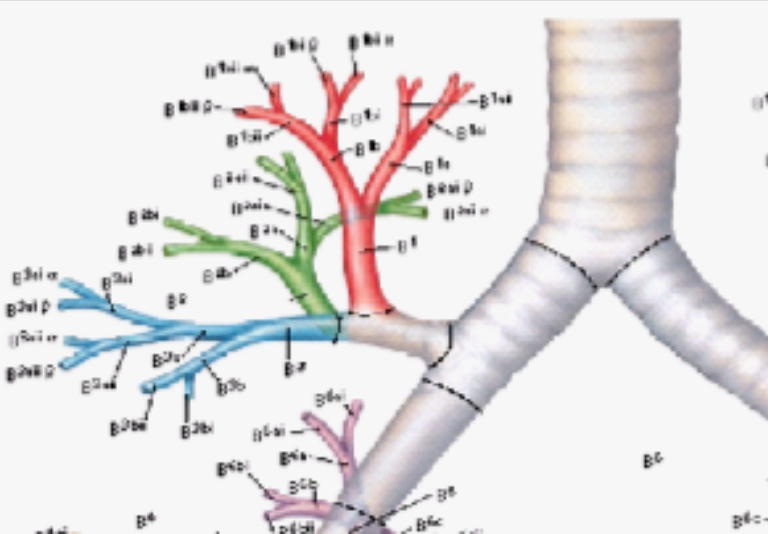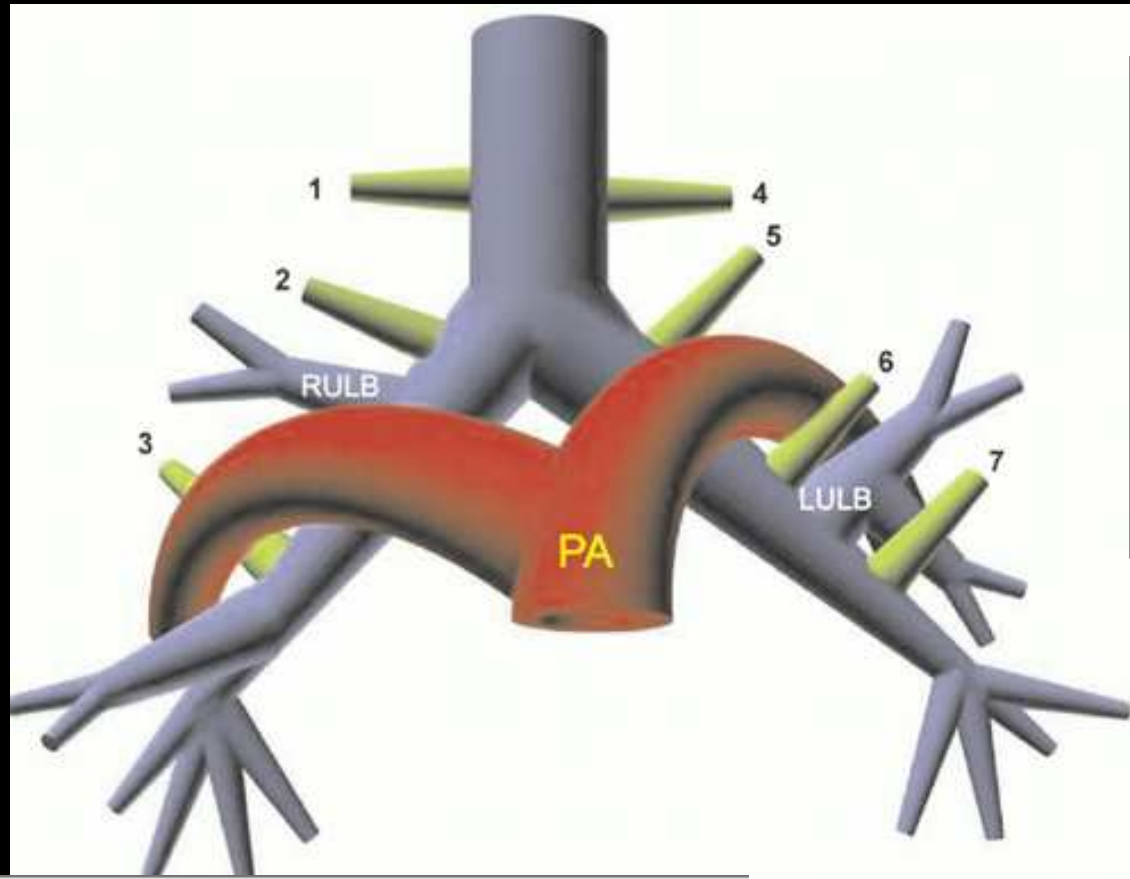
procubitus

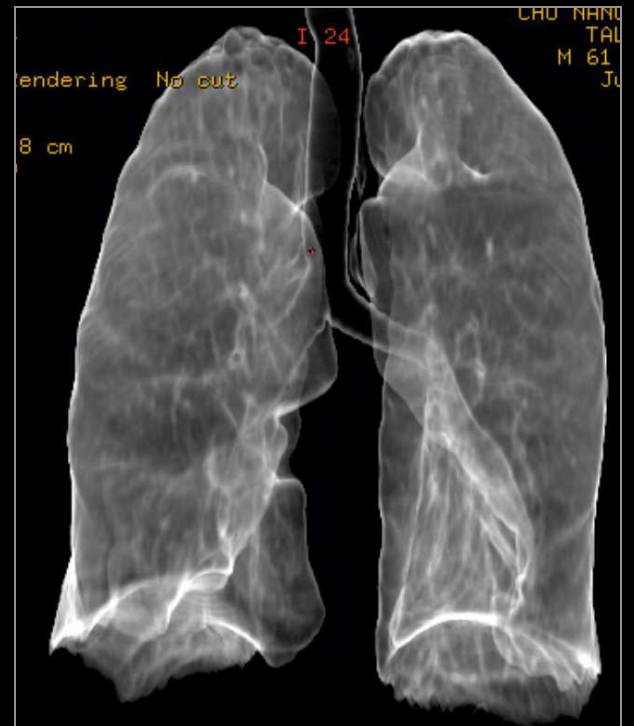
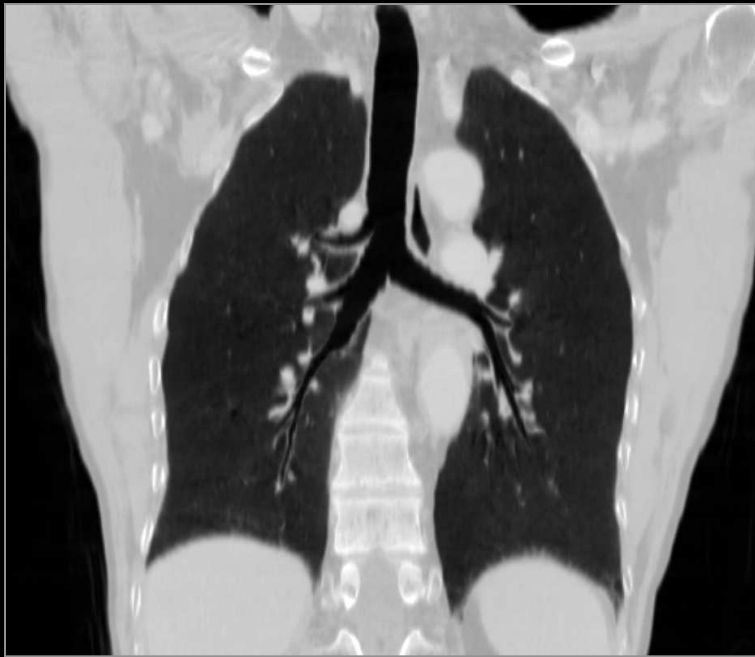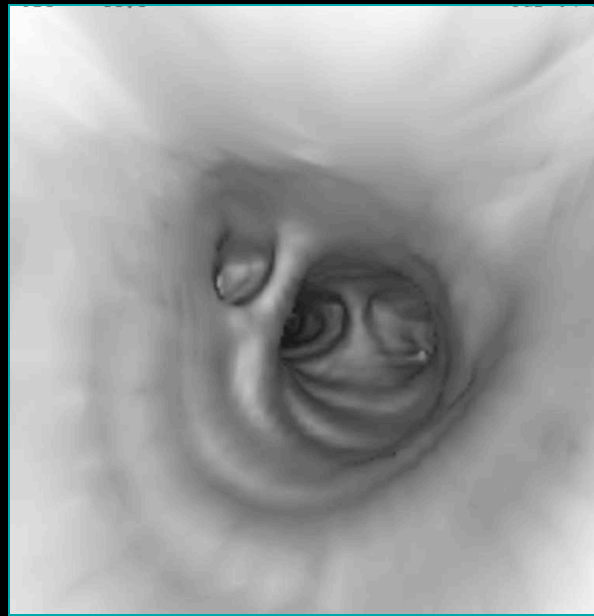
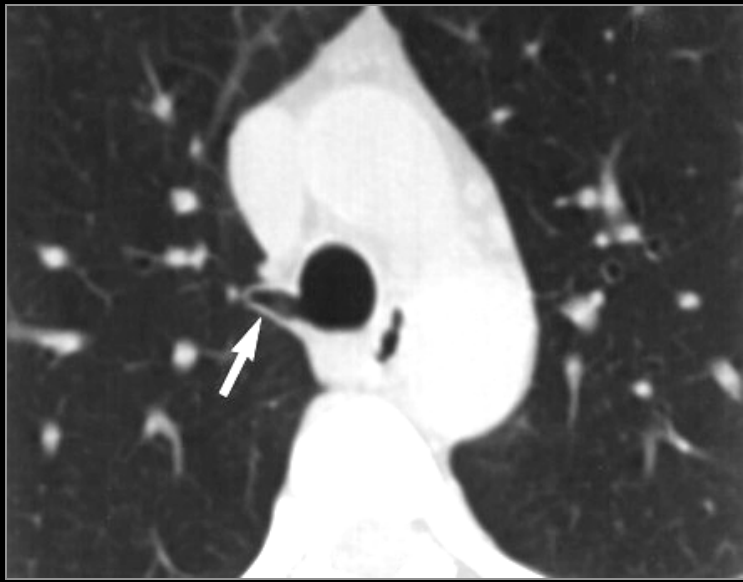


Bronche ectopique

Les plus fréquentes 2%

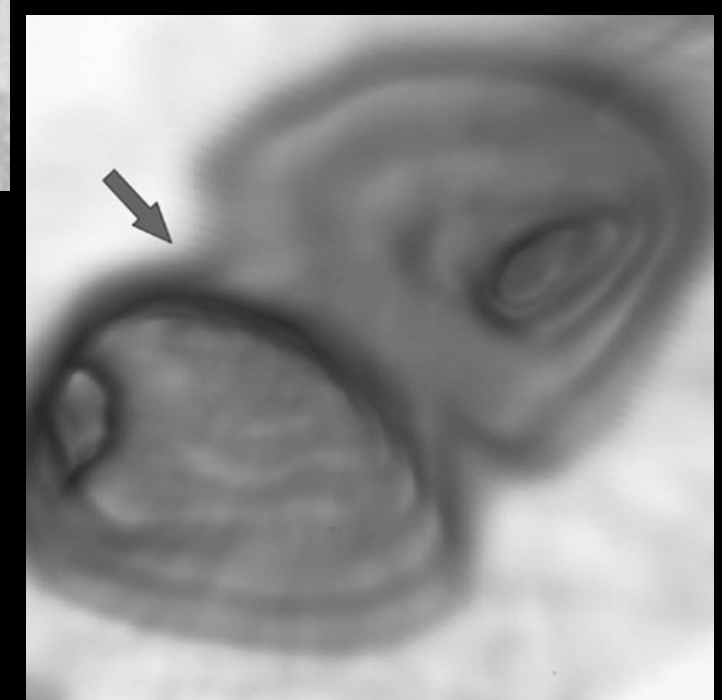
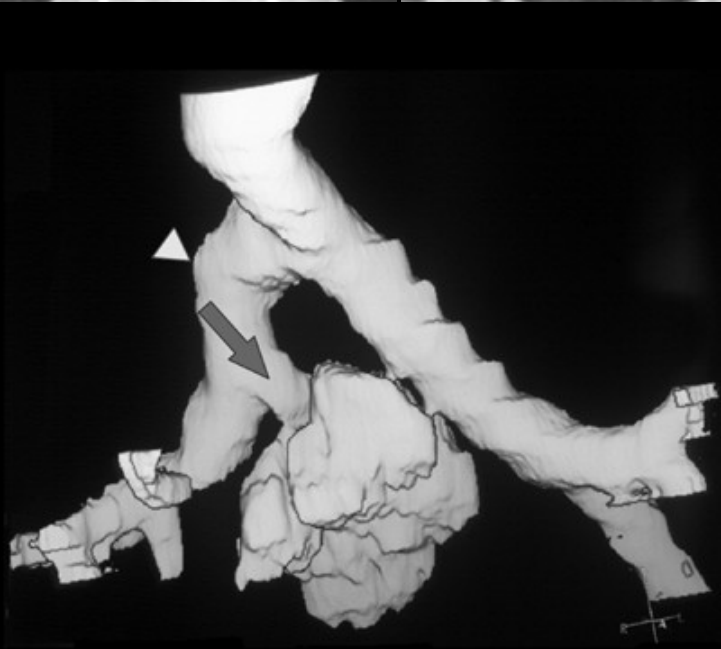
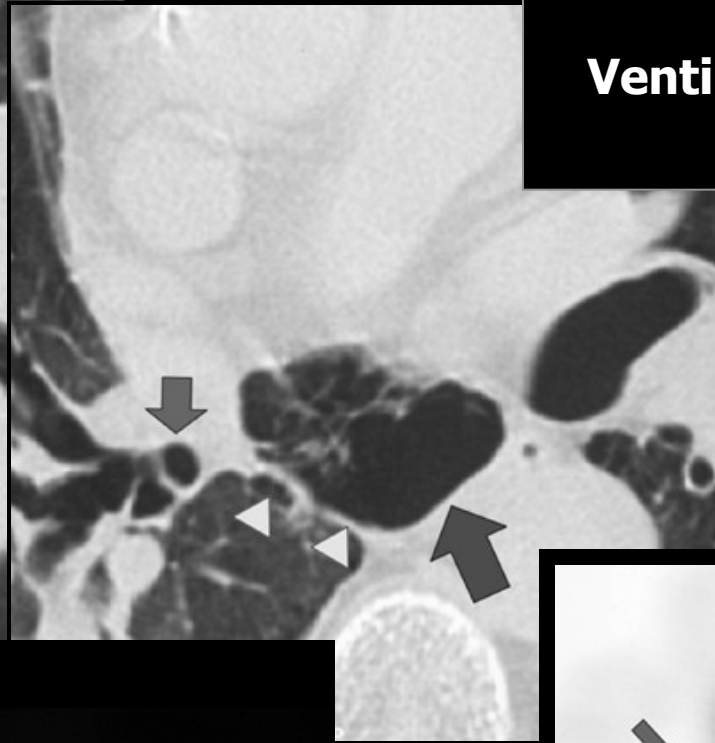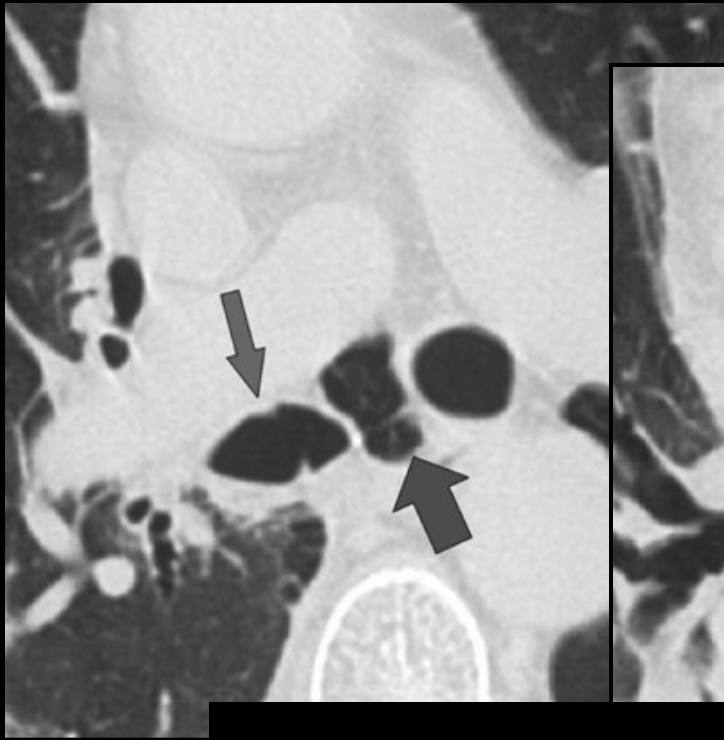Origine déplacée
drainage territoire normal
anatomiquement





Bronche surnuméraire

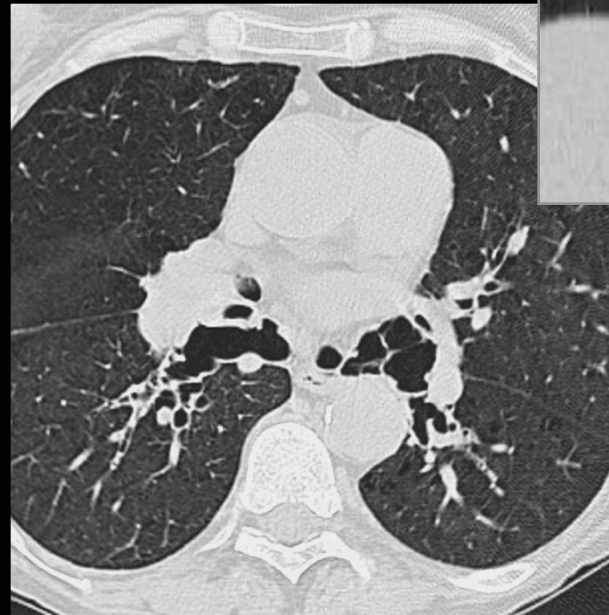
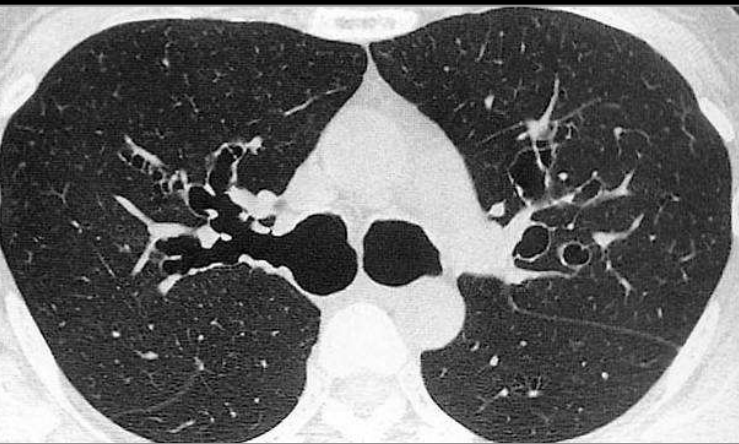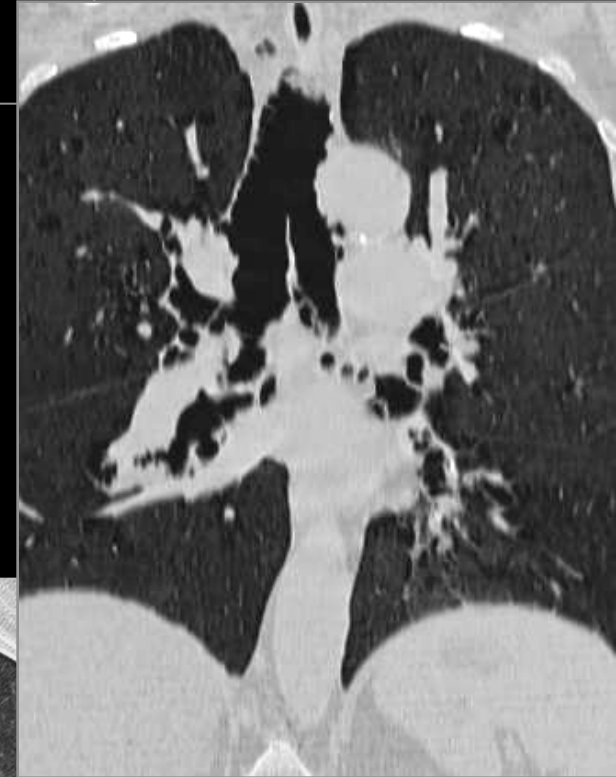
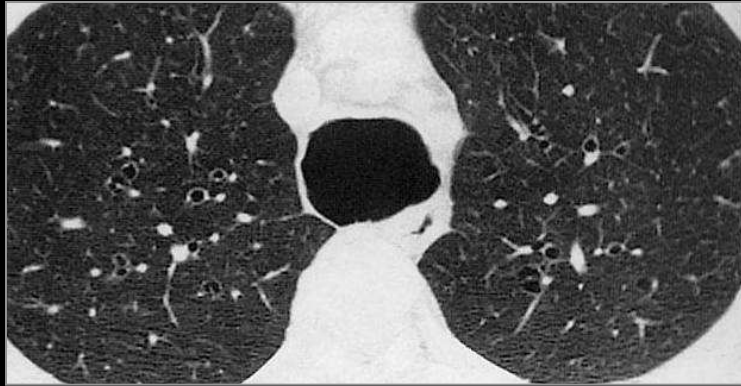Ventilation d'un territoire supplémentaire



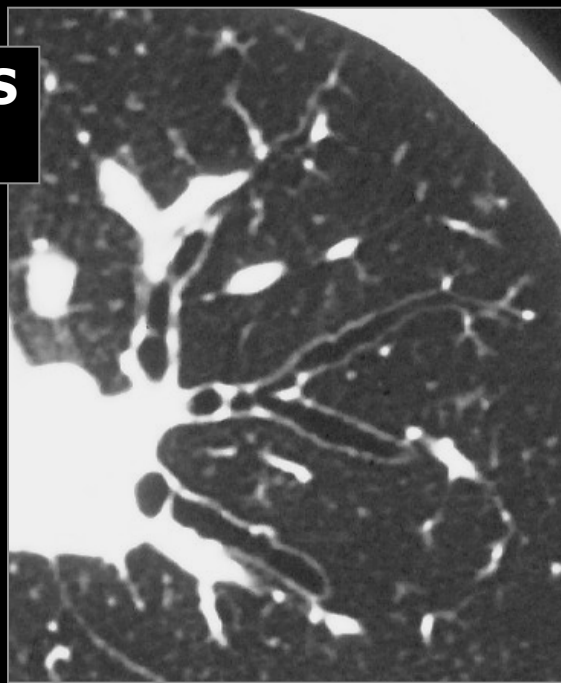
Trachéobronchomégalie (maladie de Mounier-Kuhn)

Maladie des tissus musc. et élastiques

Maladie intrinsèque VA ou associée à maladie Ehler Danlos



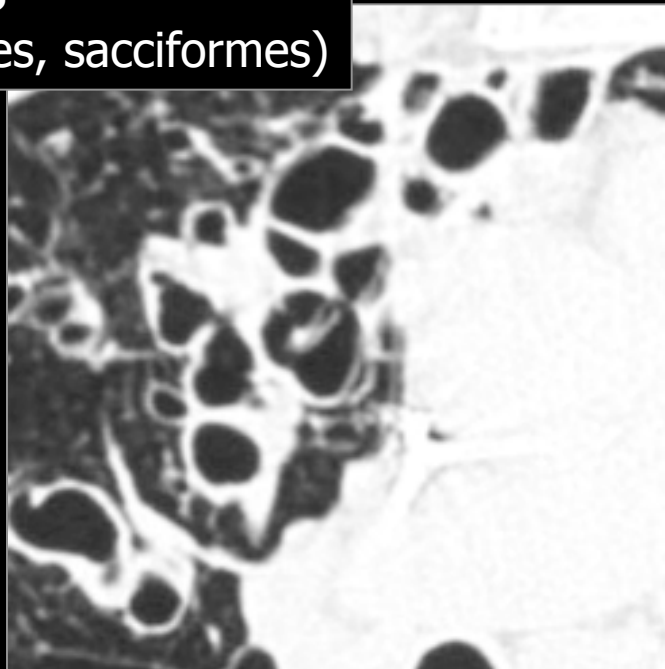
CYLINDRIQUES
(= fusiformes)



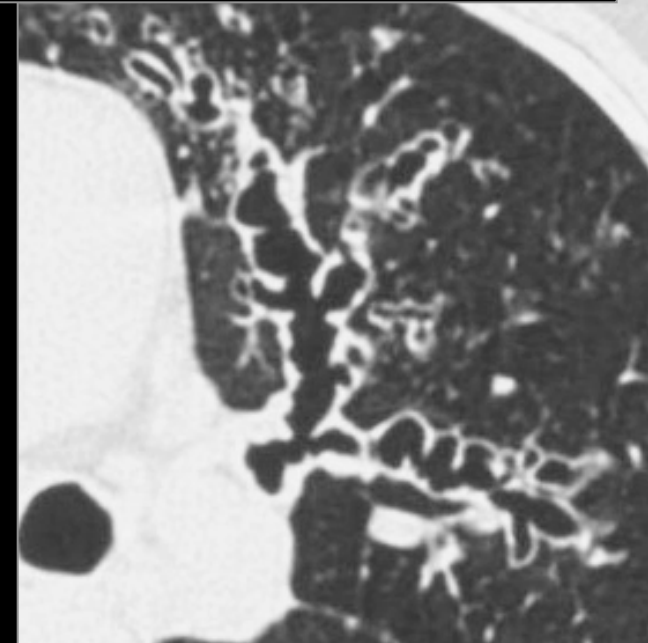
Bronchiectasies
Classification de Reid
(1950)

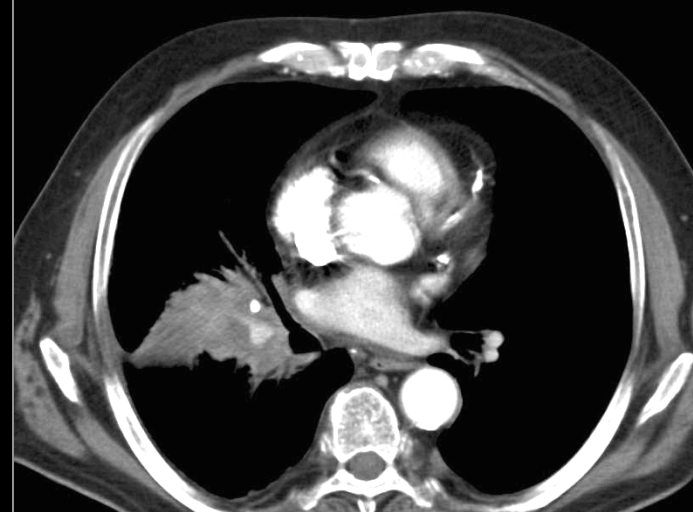
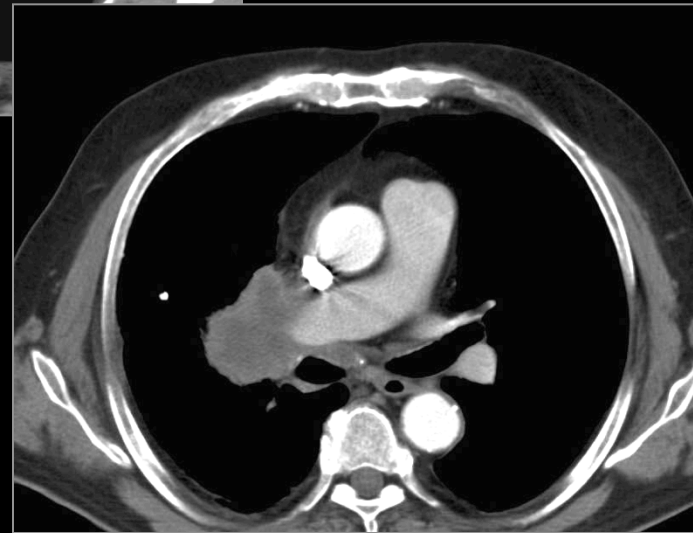
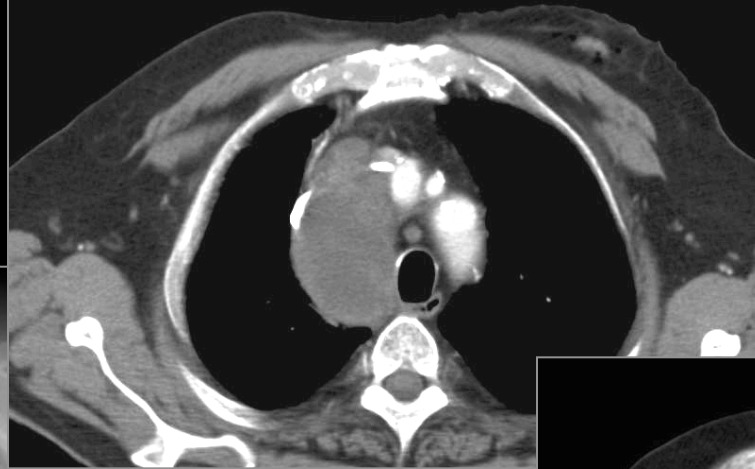
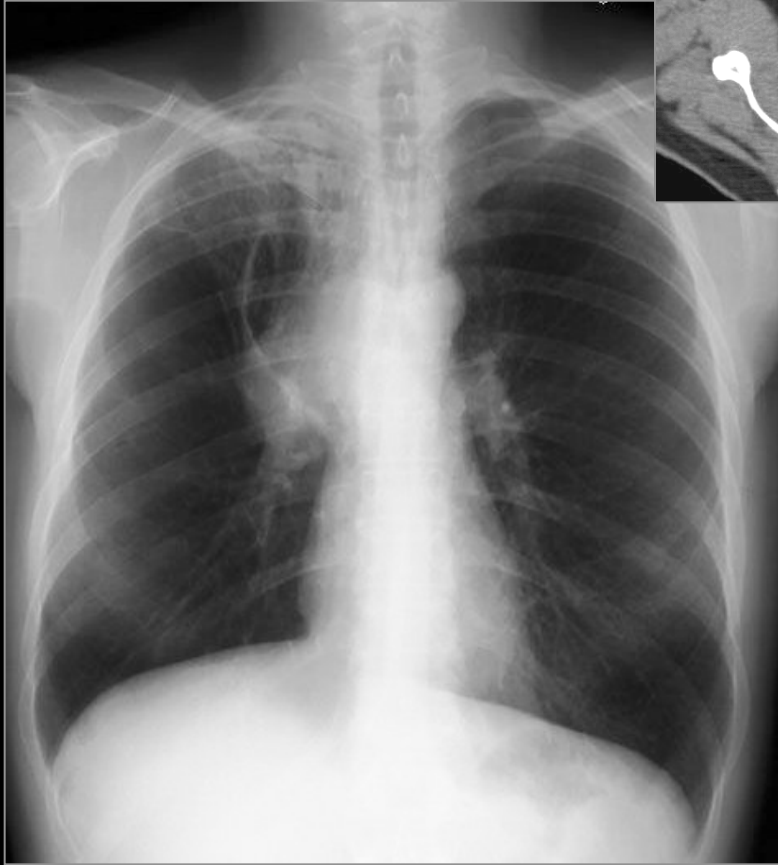


KYSTIQUES
(= ampullaires, sacciformes)

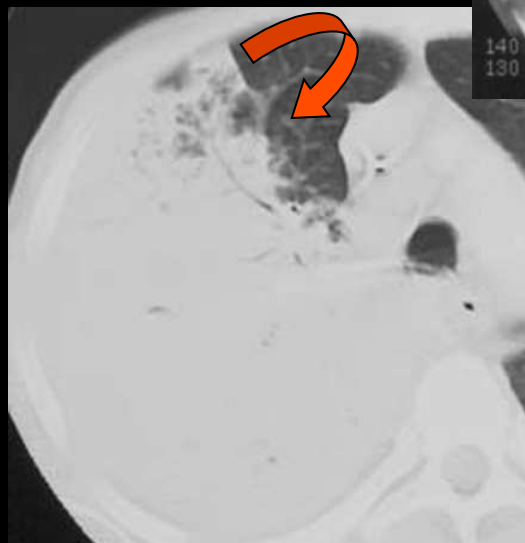
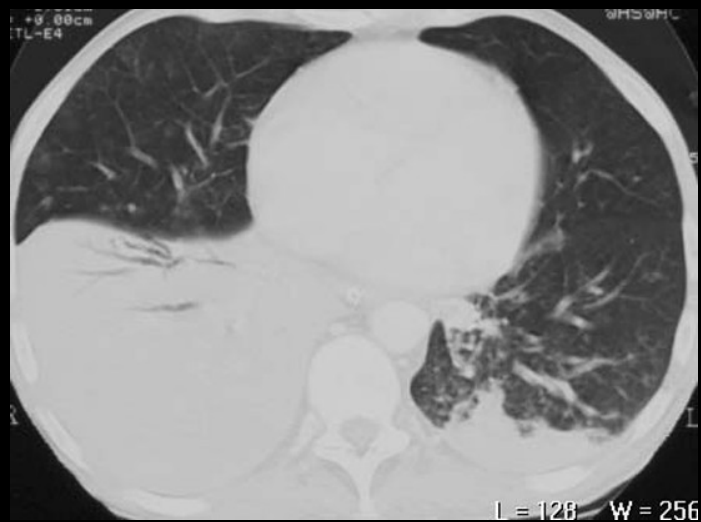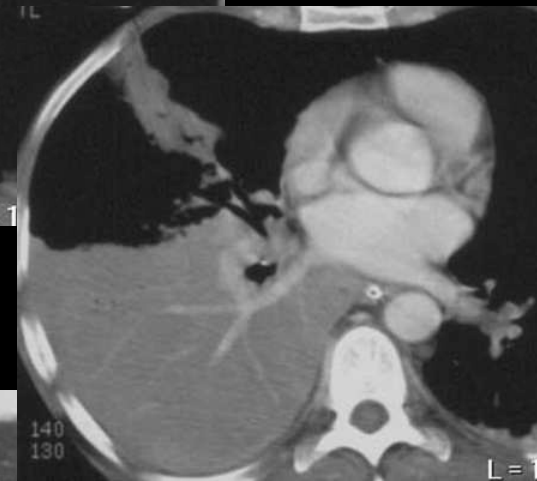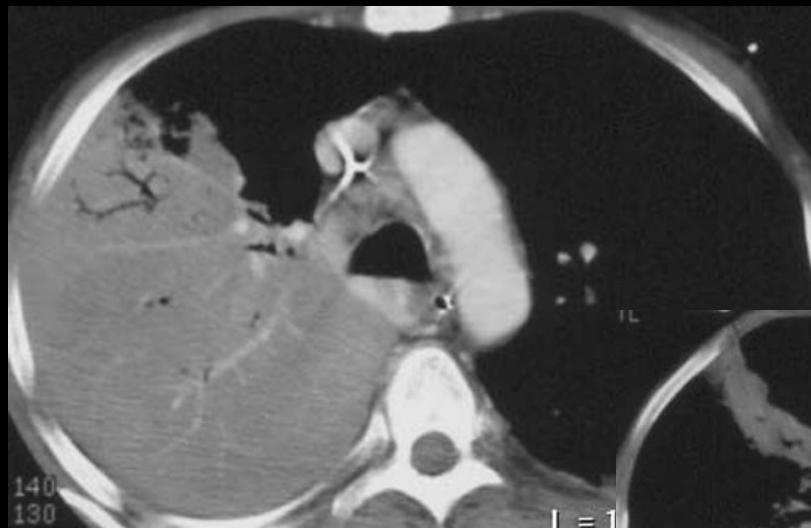


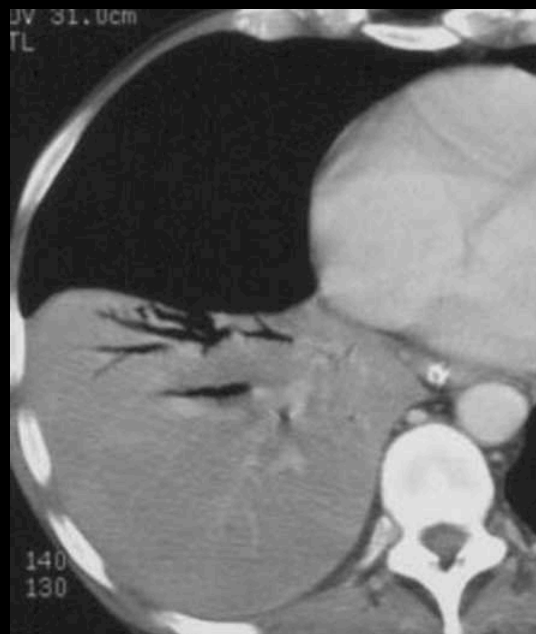VARIQUEUSES
(= moniliformes, en grappe)

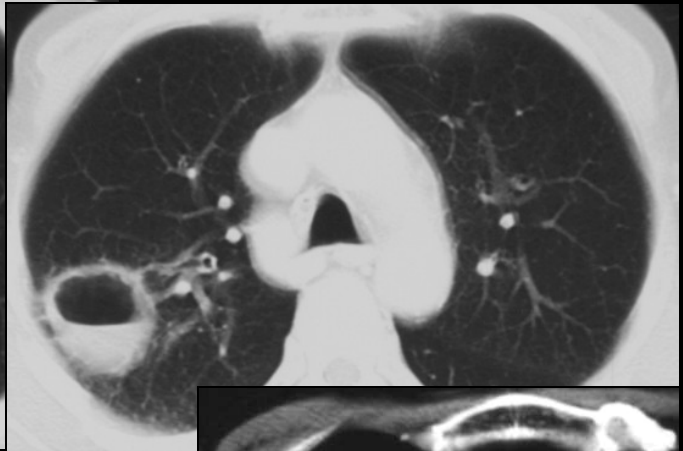
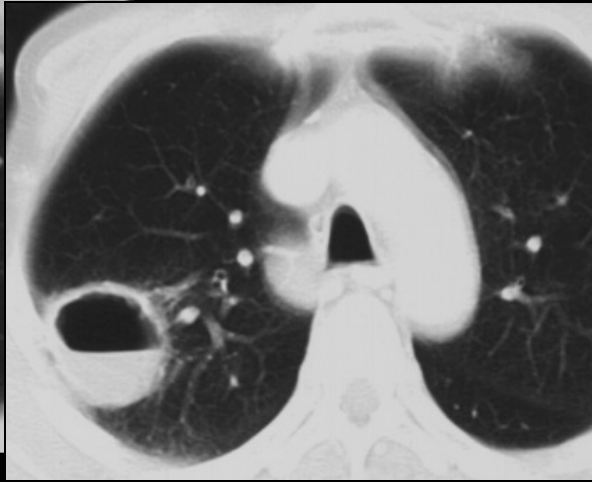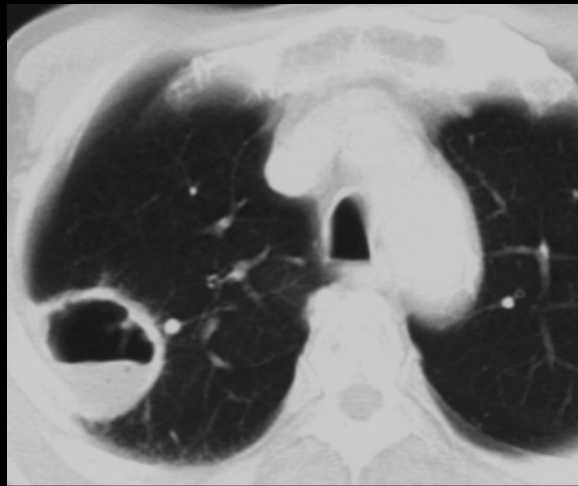




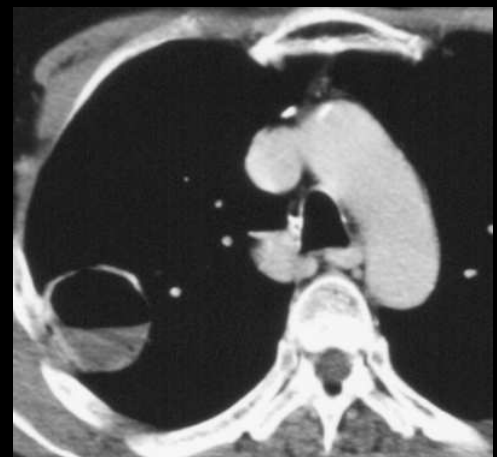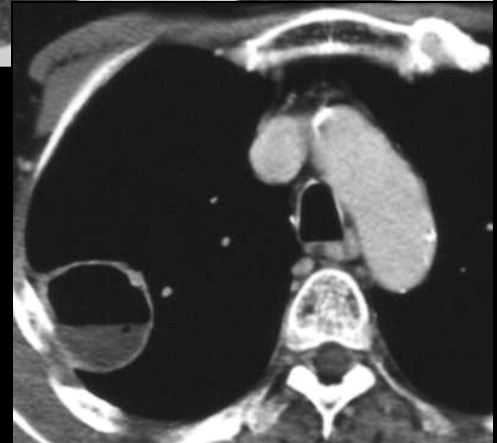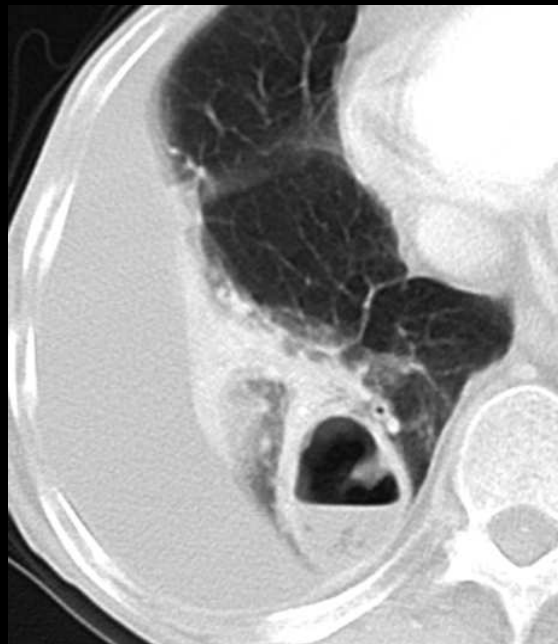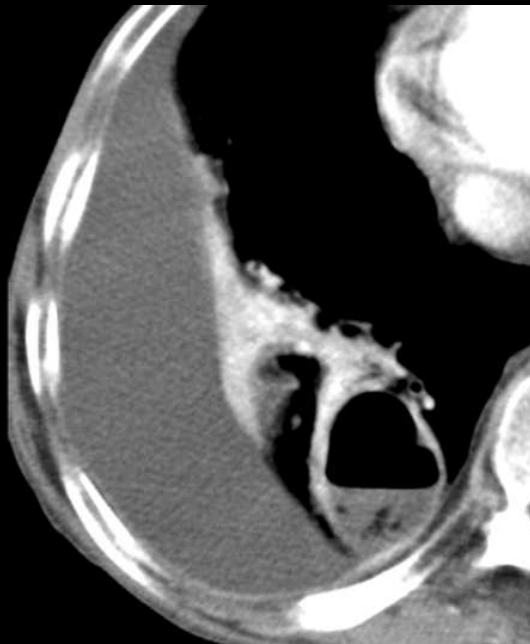Scissure azygos et carcinome à petites cellules

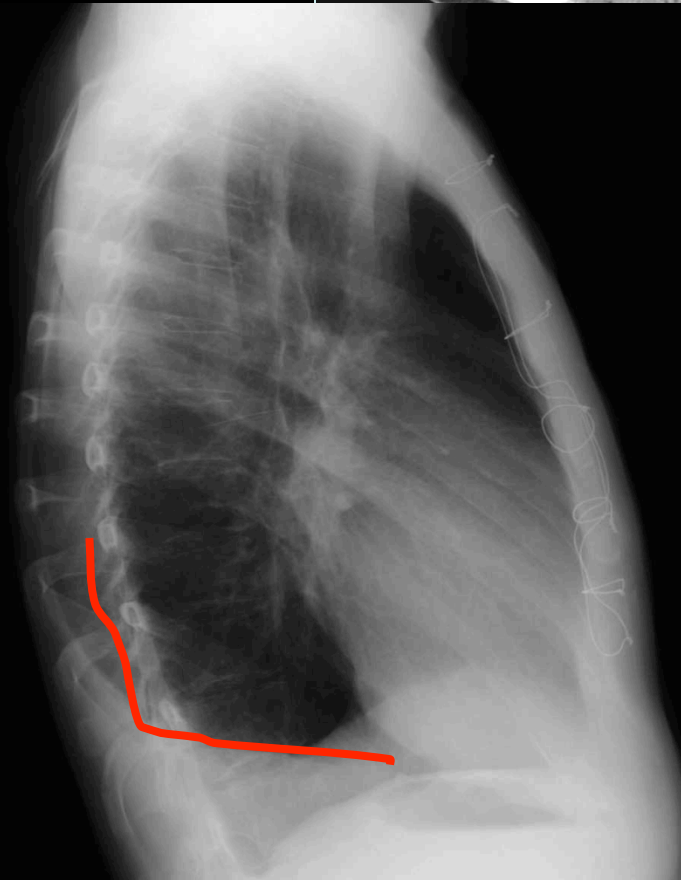
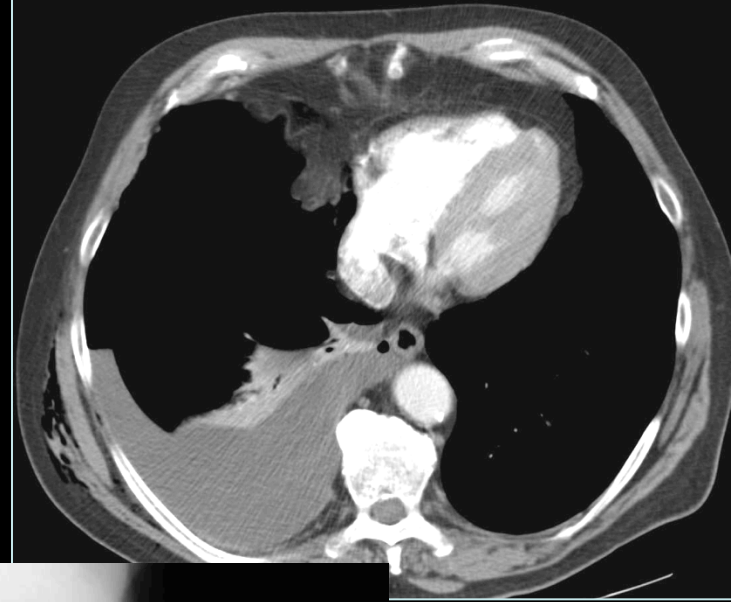
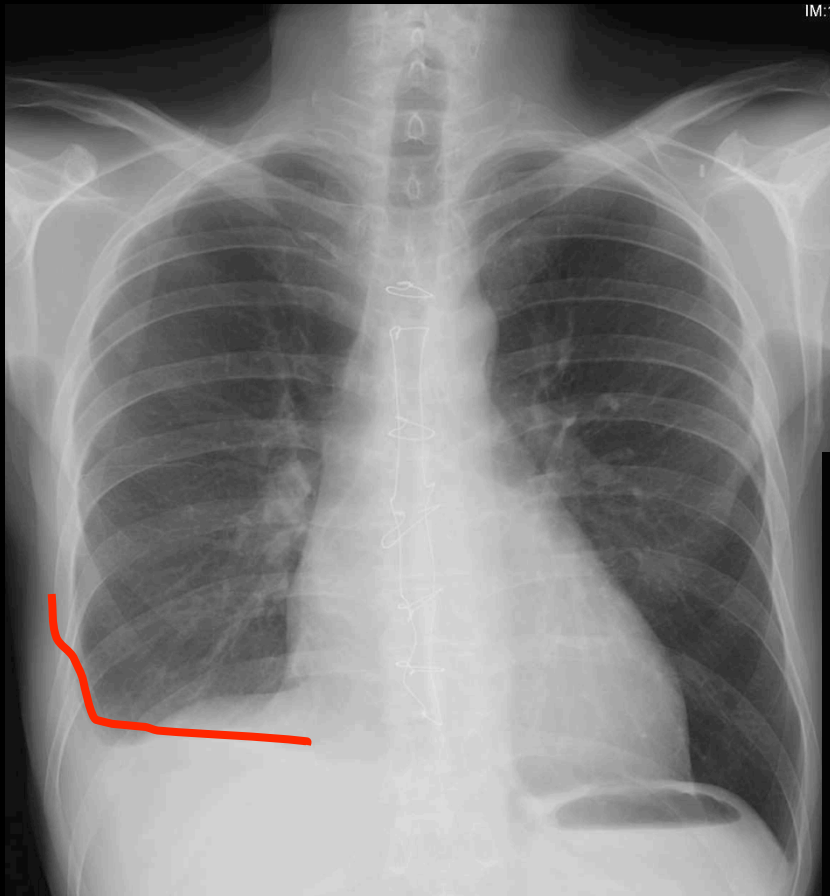


PFLA du lobe inférieur (hépatisation)

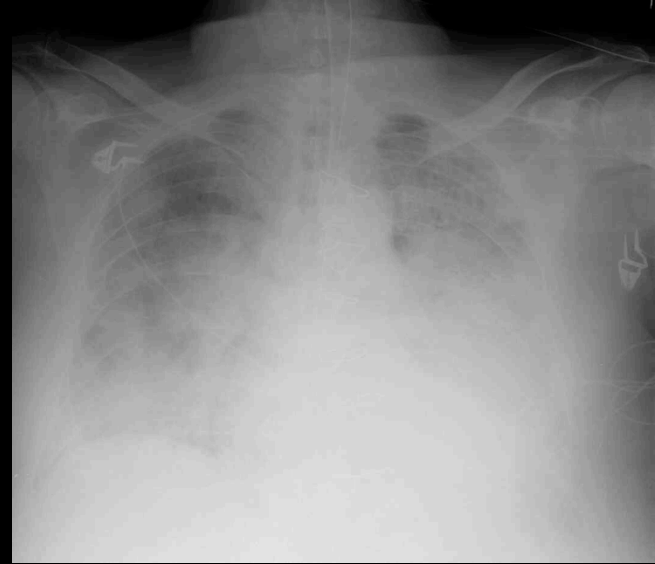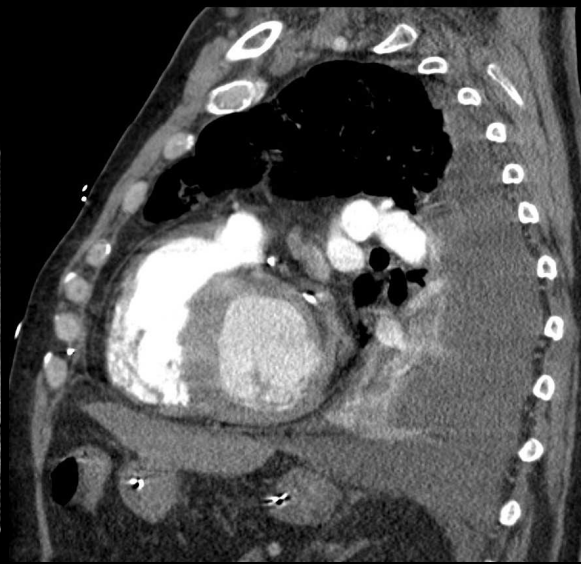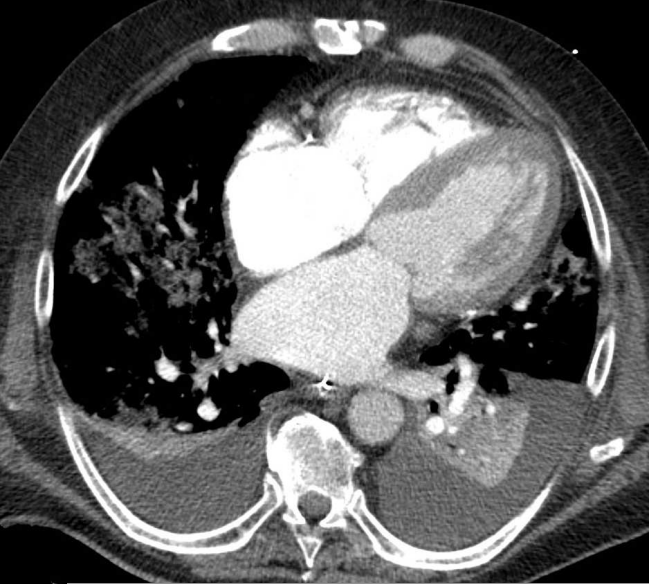


abcès du poumon

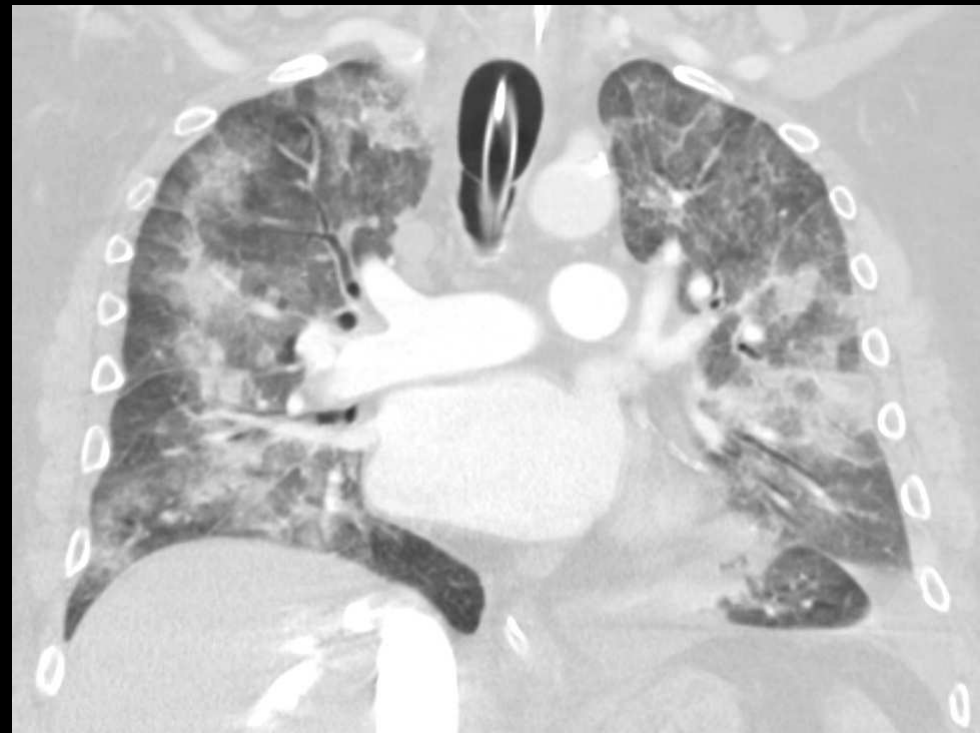
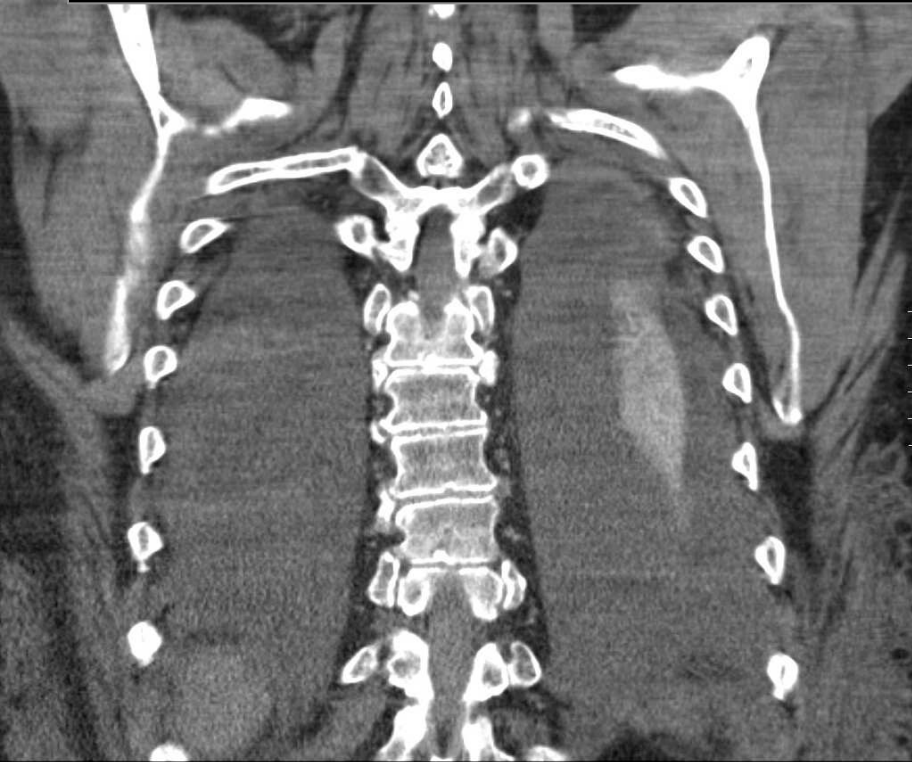


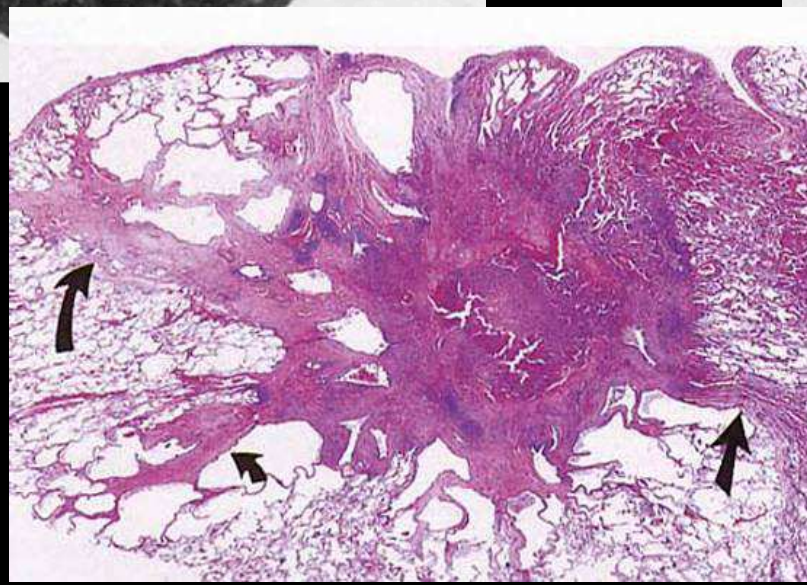
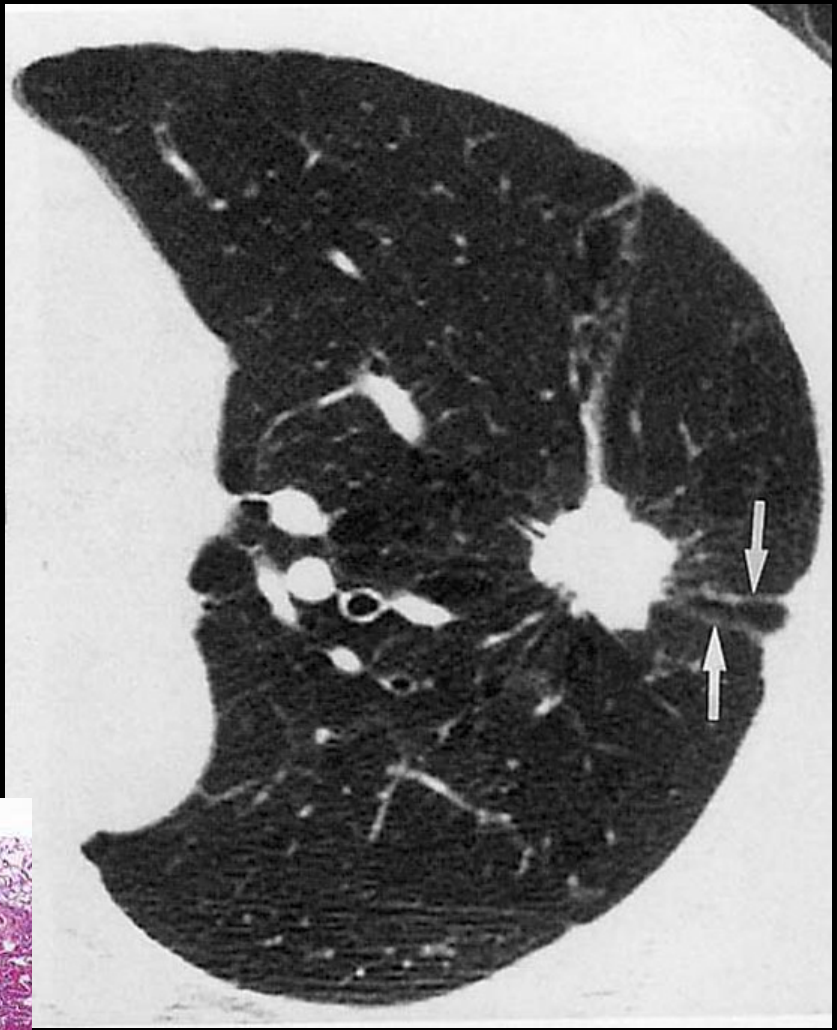
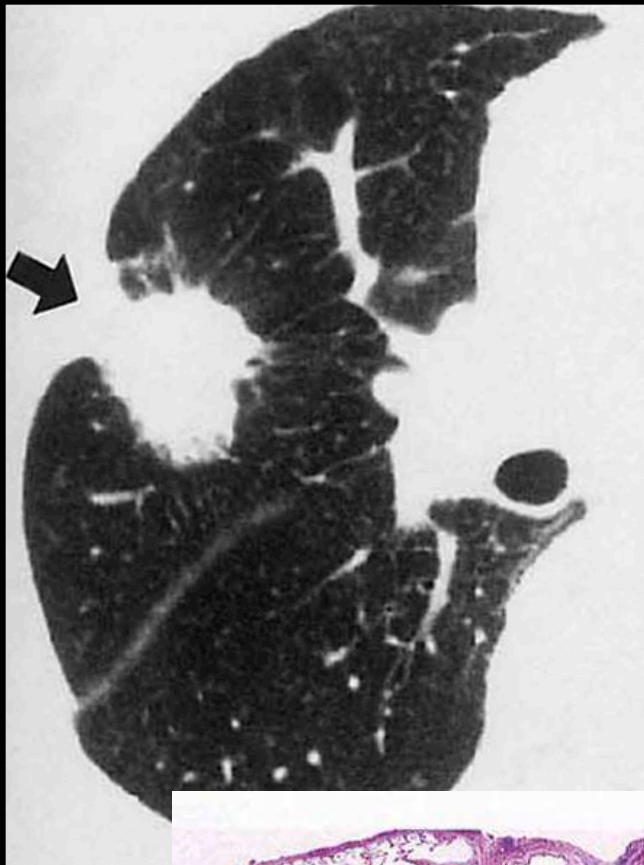
**Épanchement pleural
droit**



Pleurésie bilatérale décompensation cardiaque

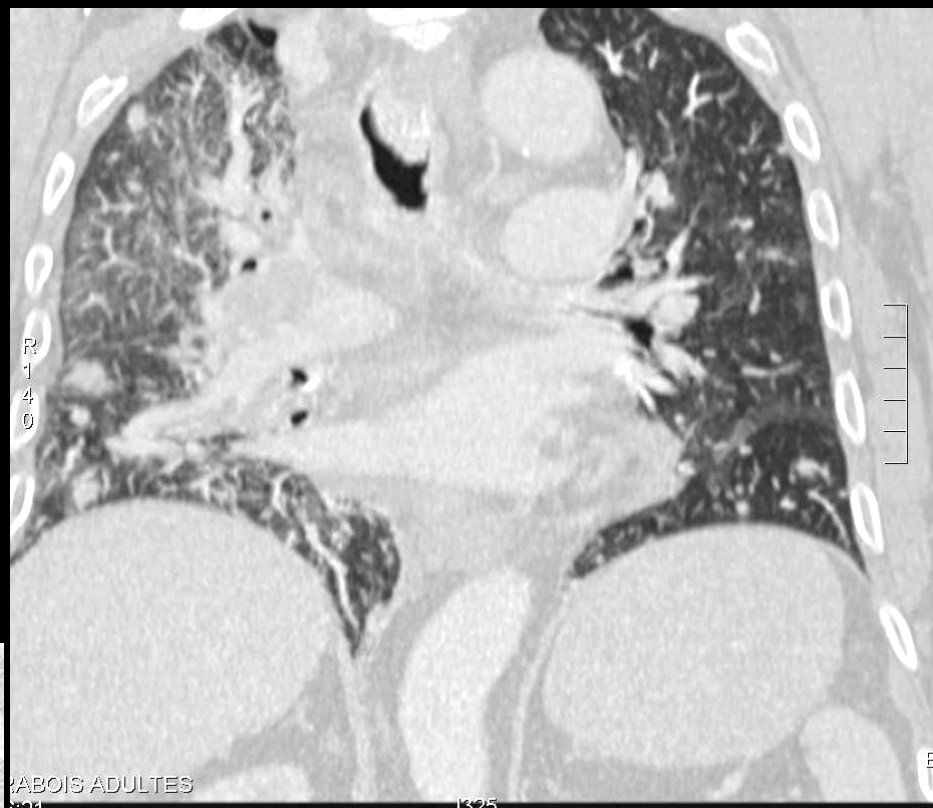
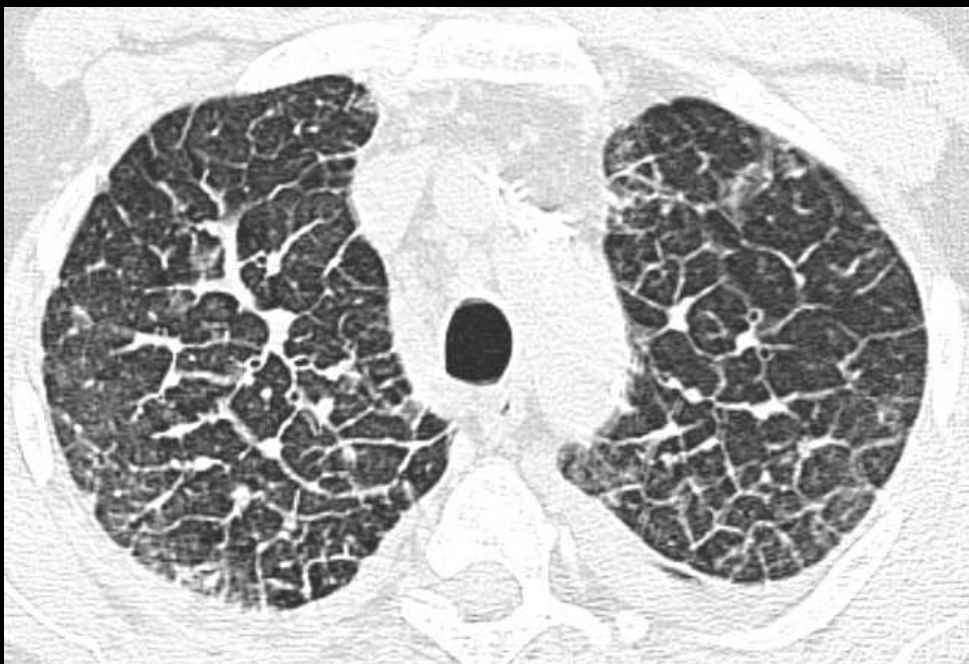
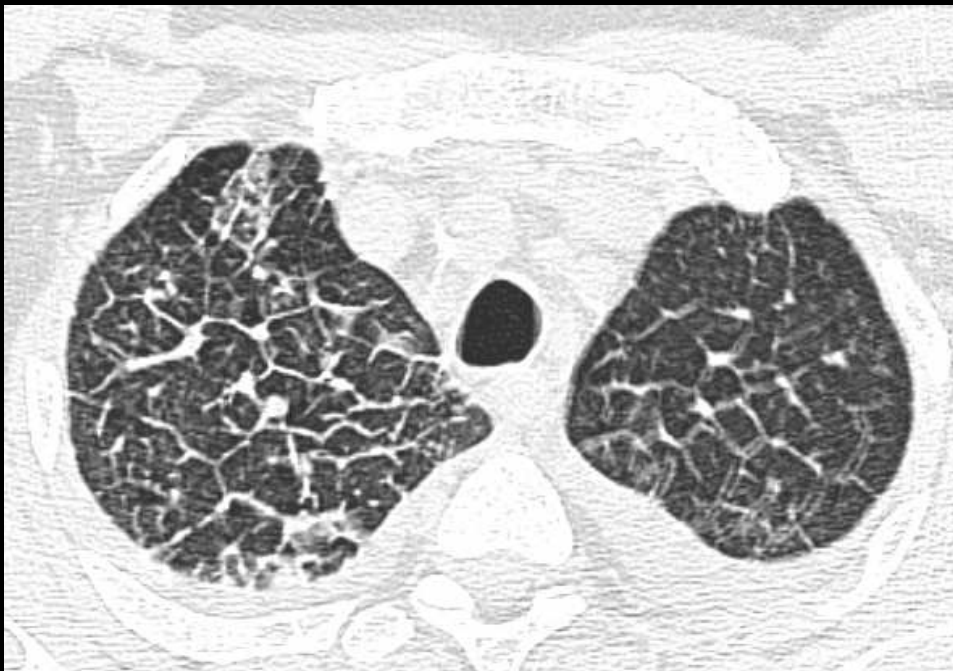



**adénocarcinomes
infiltration et rétraction de
la plèvre**



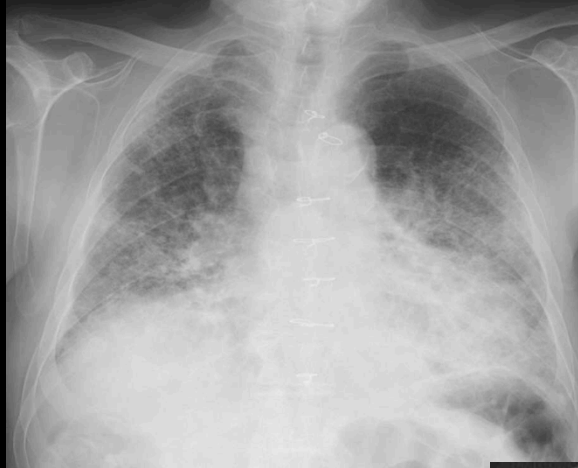Atteinte parenchymateuse interstitielle...



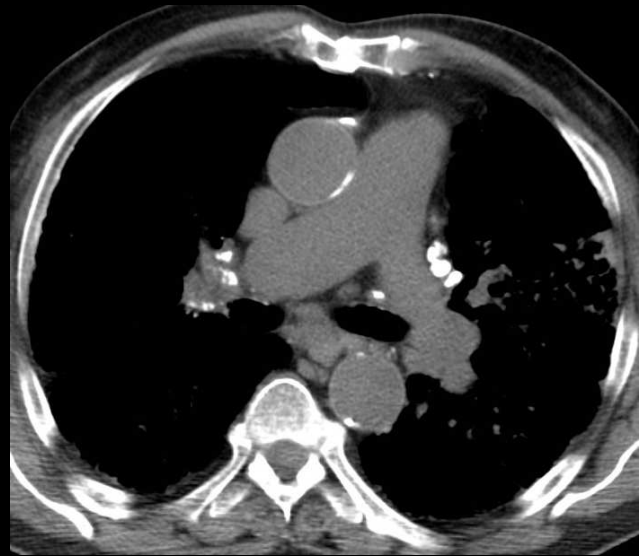
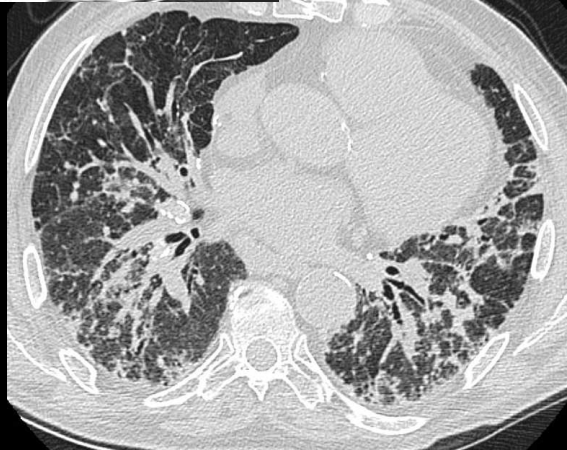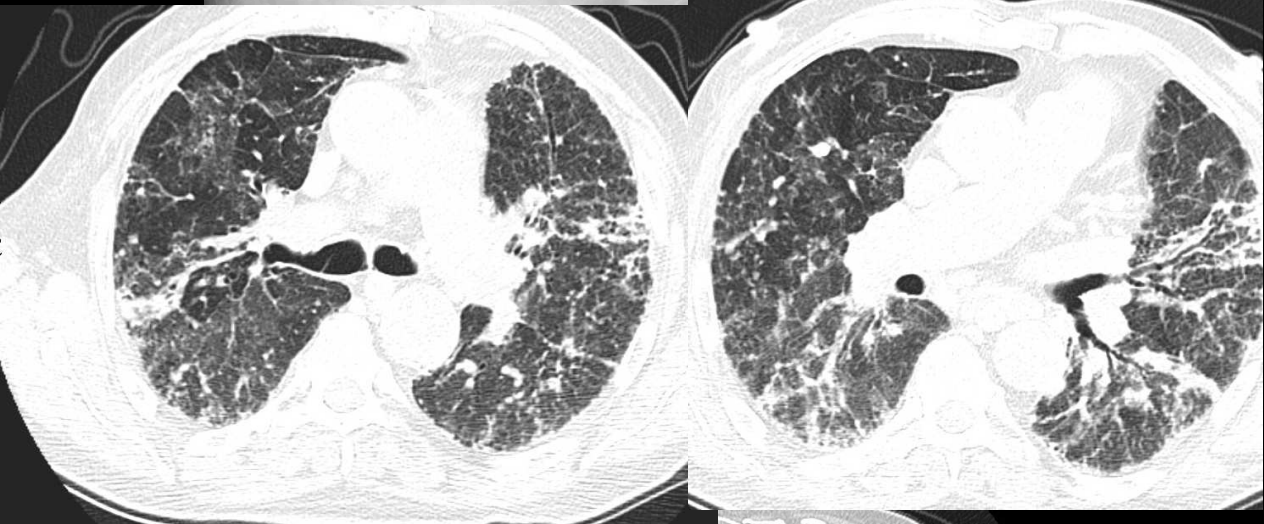
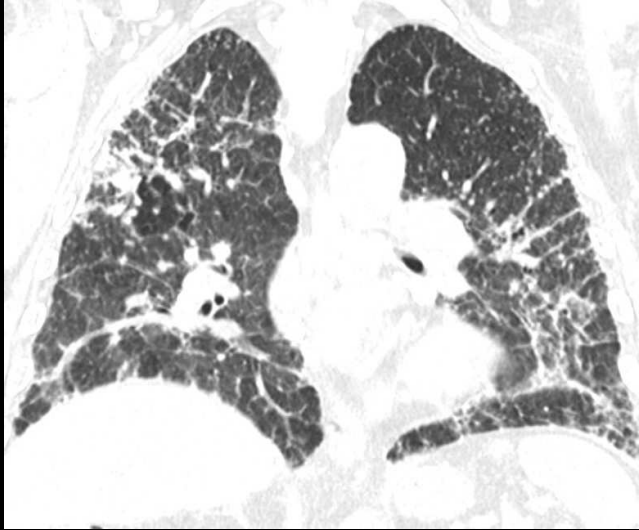
LABOIS ADULTES
3:21

1325

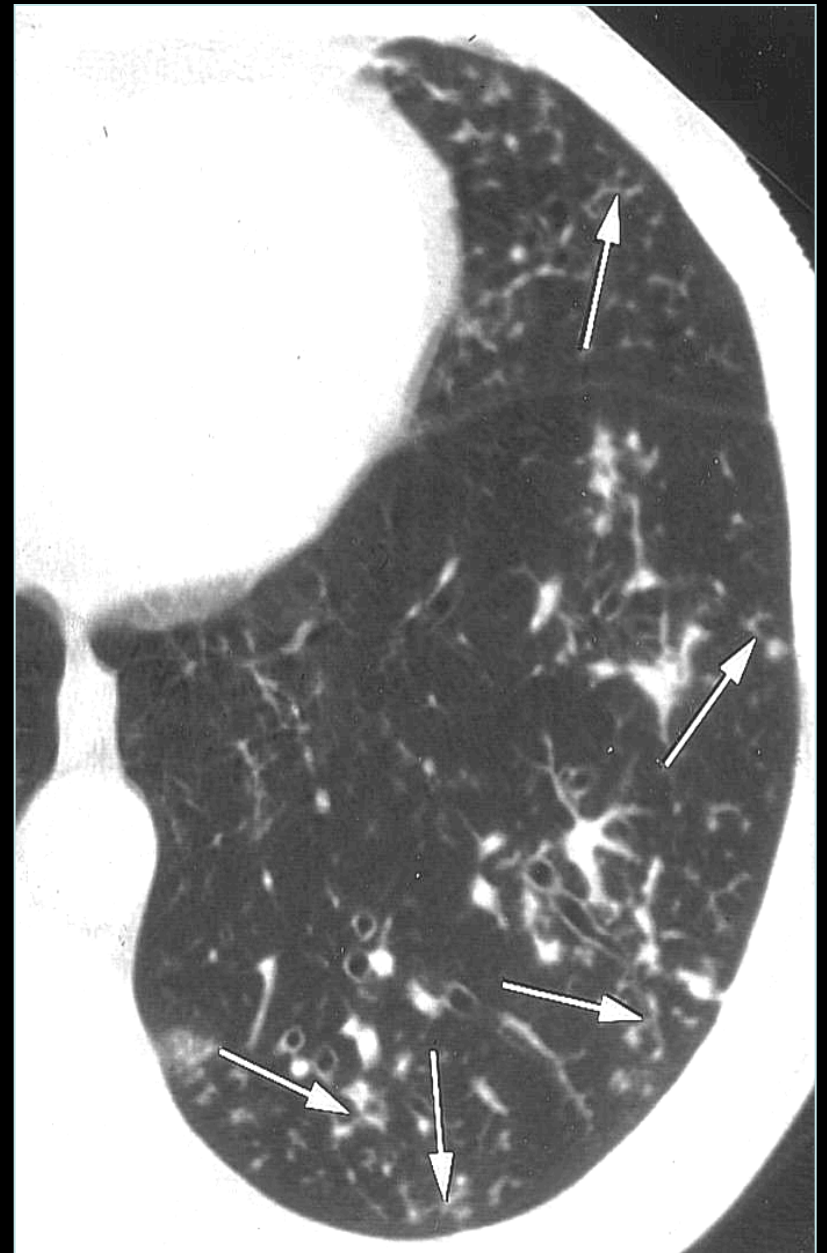
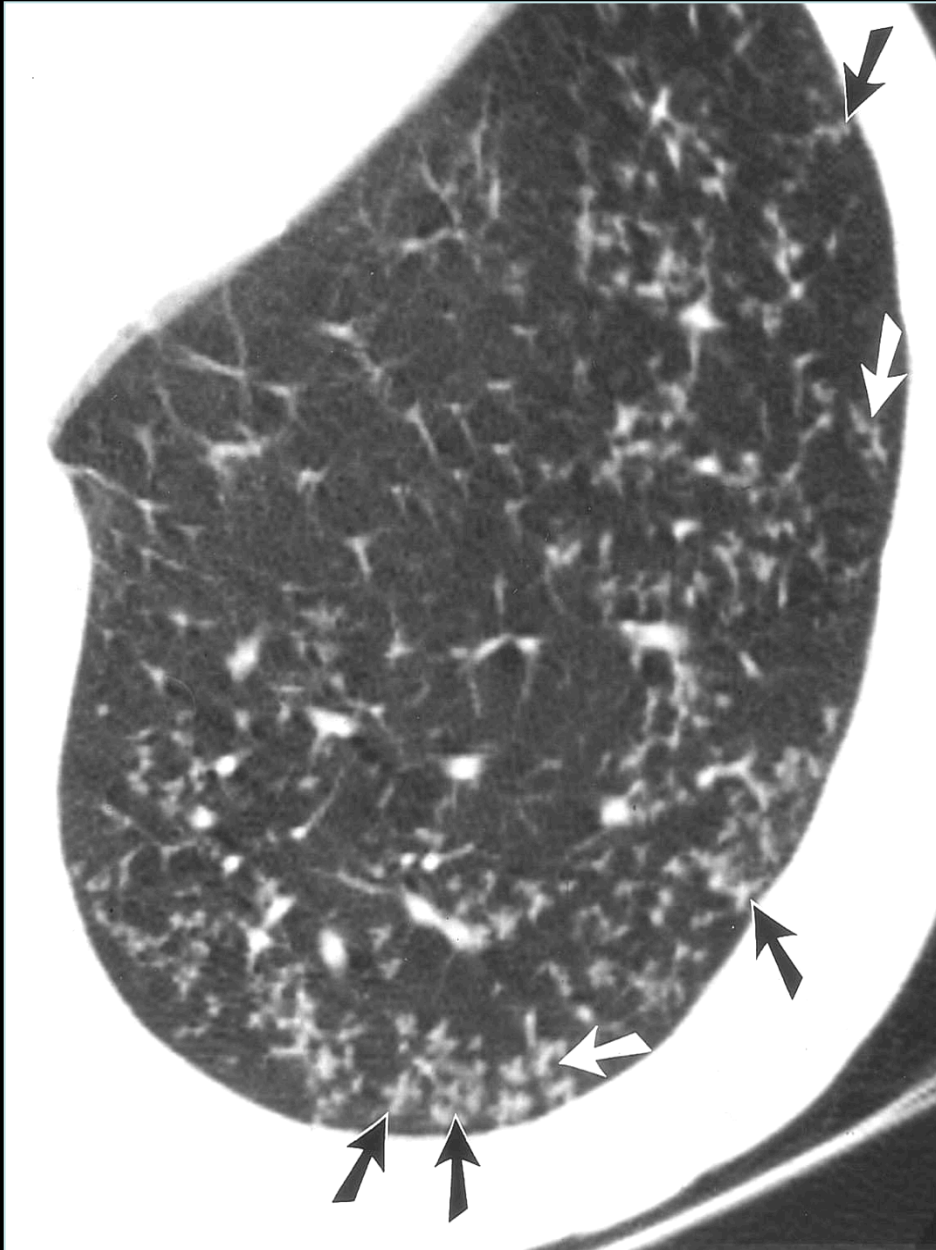
**Épaississements des
septas et
micronodules :
lymphangite**



silicose

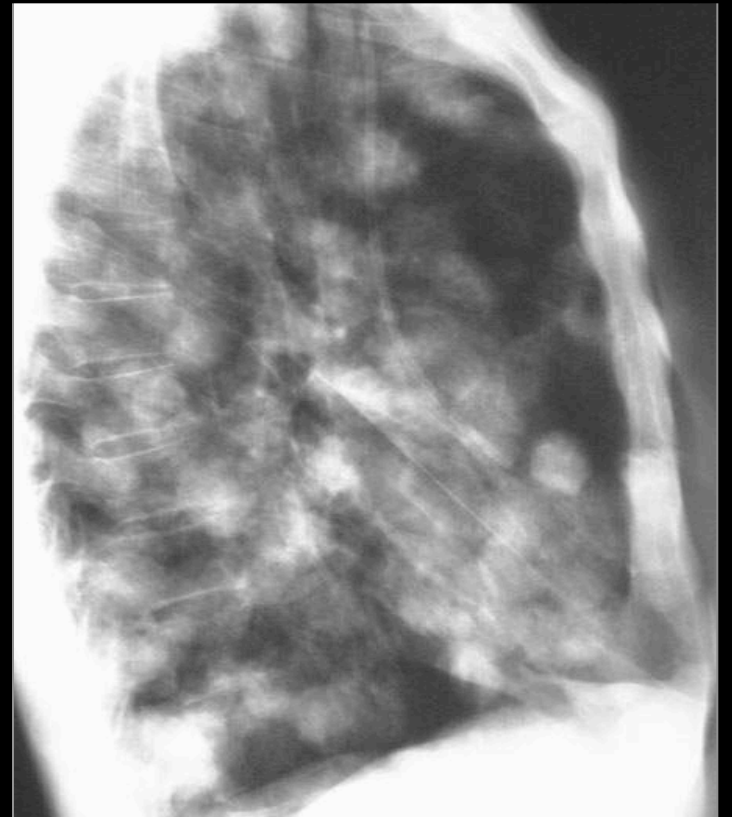
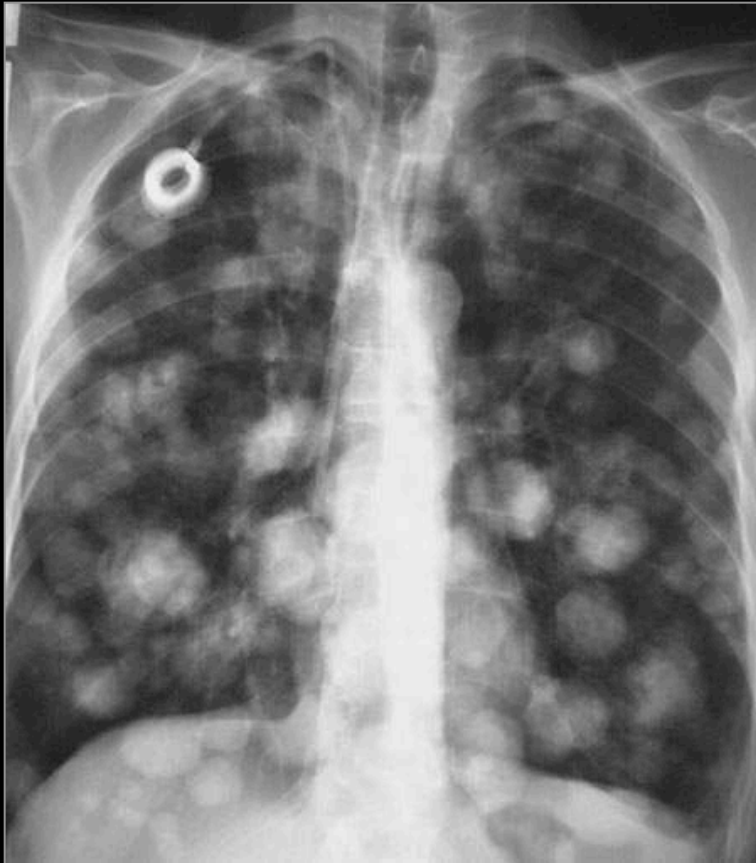
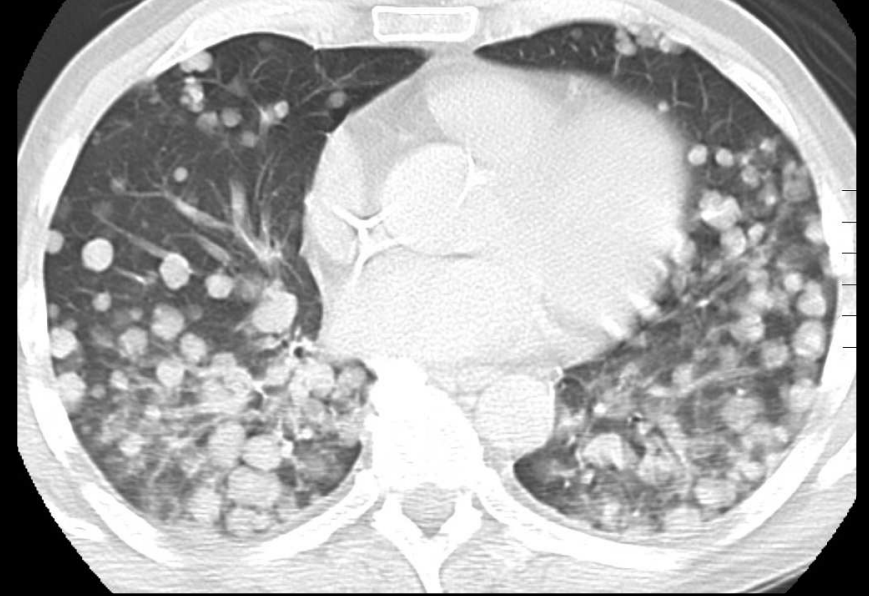


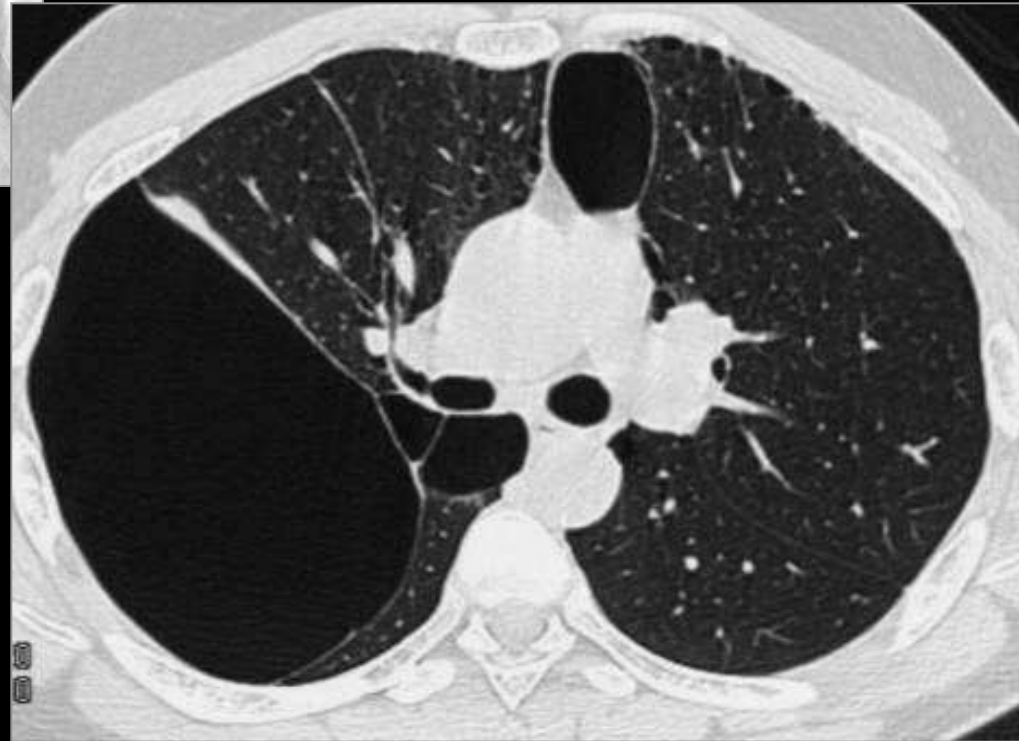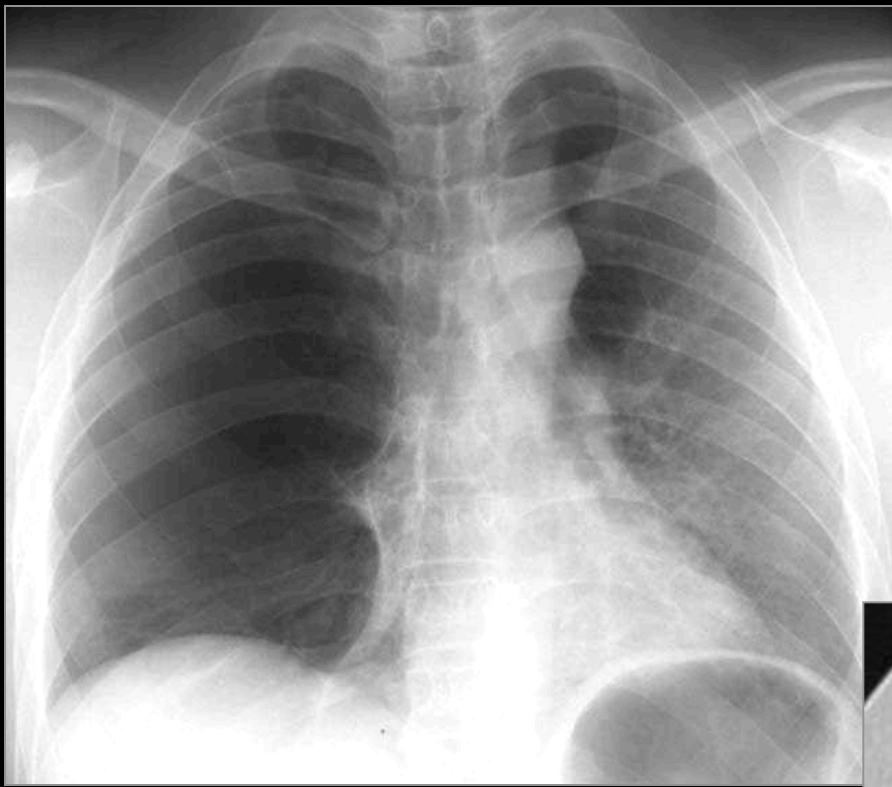
Bronchiolite bactérienne



Opacités macro nodulaires

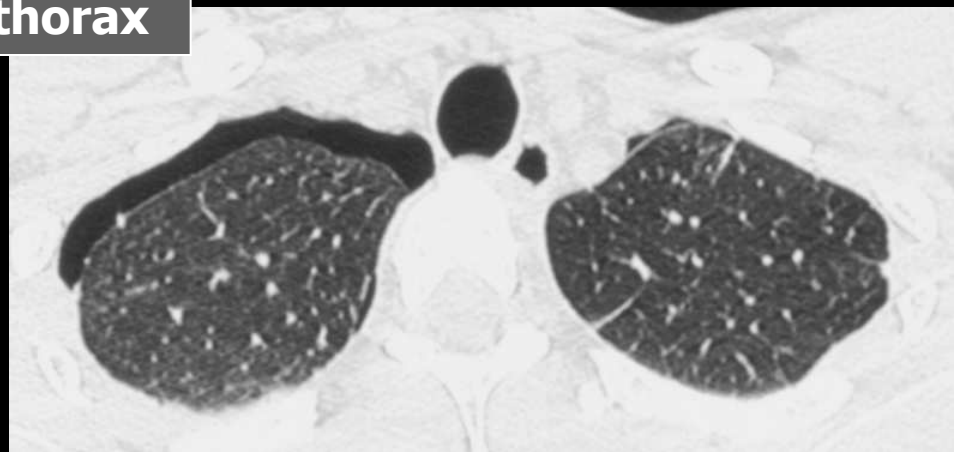
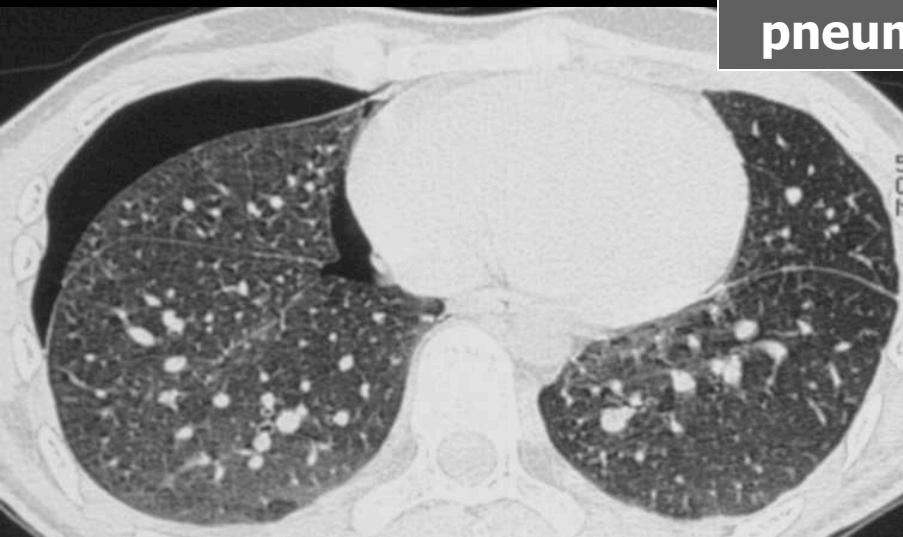
Lâcher de ballon
Métastases pulmonaires
Distribution hémotogènes



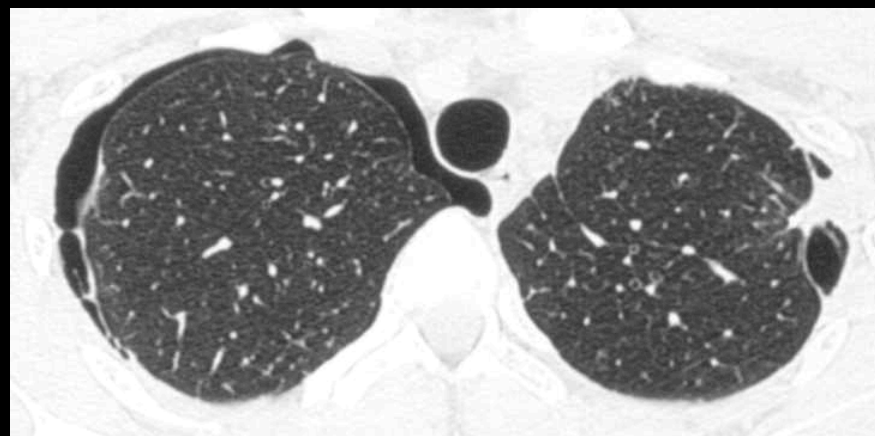
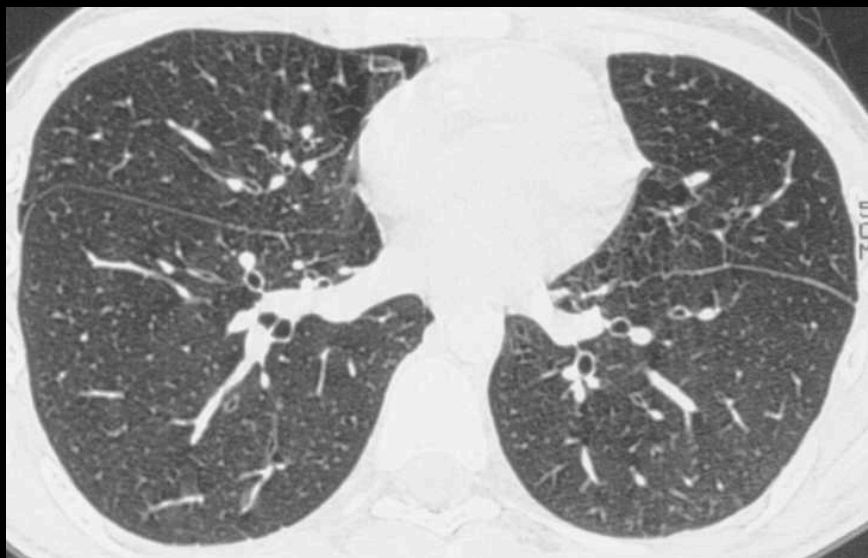

Hyperclartés
Bulles
d' emphysème

pneumothorax



coupes en expiration



coupes en inspiration

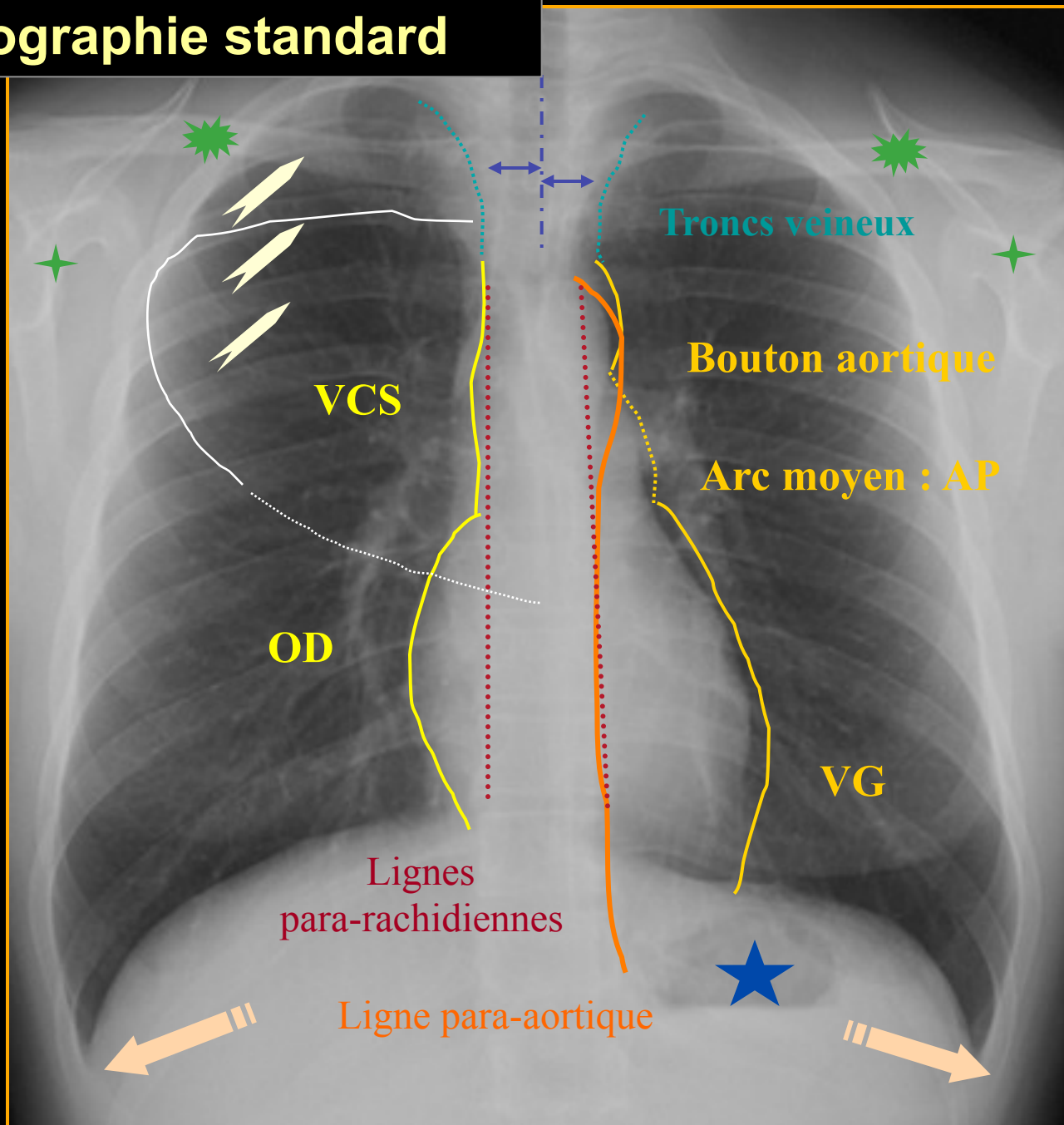


2/ RADIOANATOMIE DU MEDIASTIN

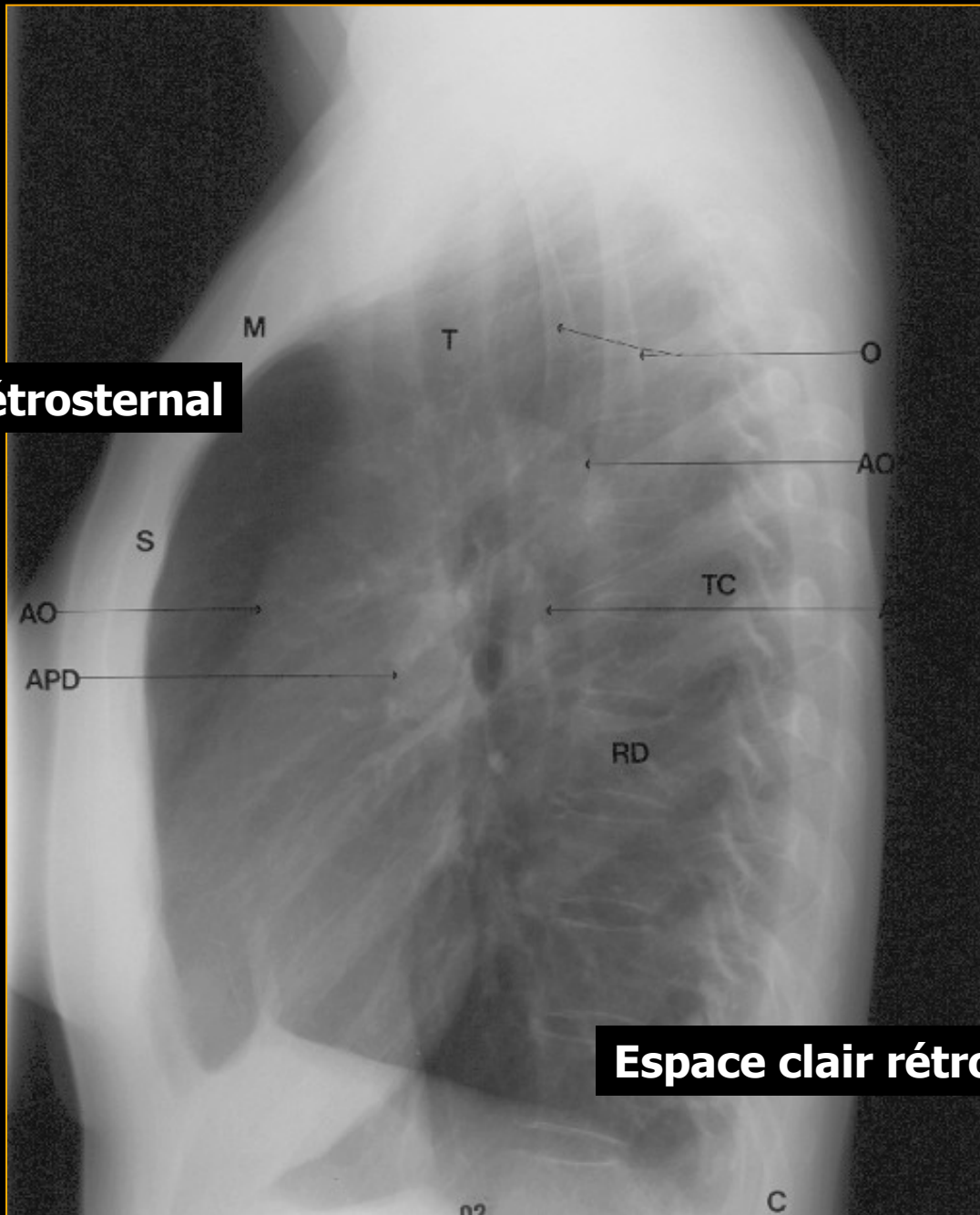
- **GENERALITES**
- **VAISSEAUX**
- **CŒUR**
- **ŒSOPHAGE**
- **CHAINES GANGLIONNAIRES**

Radiographie standard

DE FACE



Espace clair rétrosternal



Espace clair rétrocardiaque

Les 10 lignes du médiastin

RadioGraphics

The journal of continuing medical education in radiology

[HOME](#) | [CURRENT ISSUE](#) | [PAST ISSUES](#) | [COLLECTIONS](#) | [COVER GALLERY](#) | [RADIOLOGY](#)

Lines and Stripes: Where Did They Go? —From Conventional Radiography to CT

Jerry M. Gibbs, MD, Chitra A. Chandrasekhar, MBBS,
Emma C. Ferguson, MD and Sandra A. A. Oldham, MD

+ Author Affiliations

Address correspondence to

J.M.G. (e-mail: jerry.m.gibbs@uth.tmc.edu).

ABSTRACT

10

« Previous | Next Article »
Table of Contents

This Article

doi:
10.1148/rg.271065073
January 2007 RadioGraphics,
27, 33-48.

Abstract **Free**

Figures Only

» Full Text

Full Text (PDF)

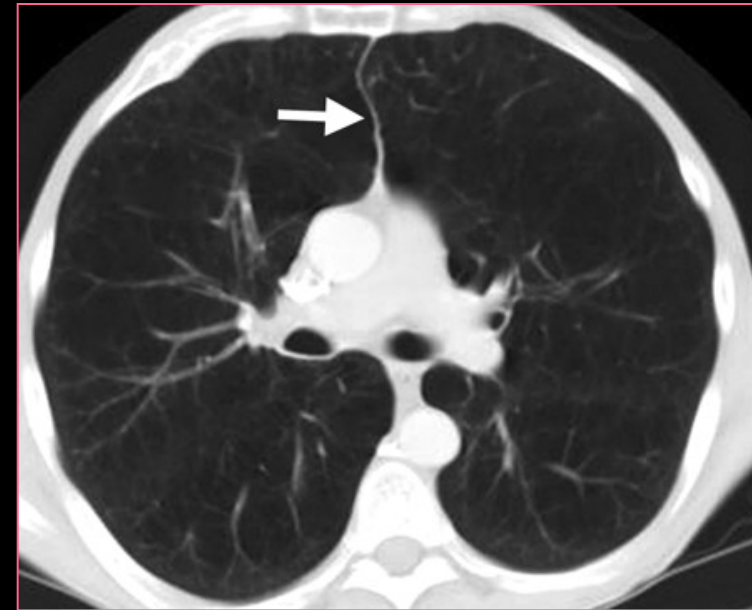
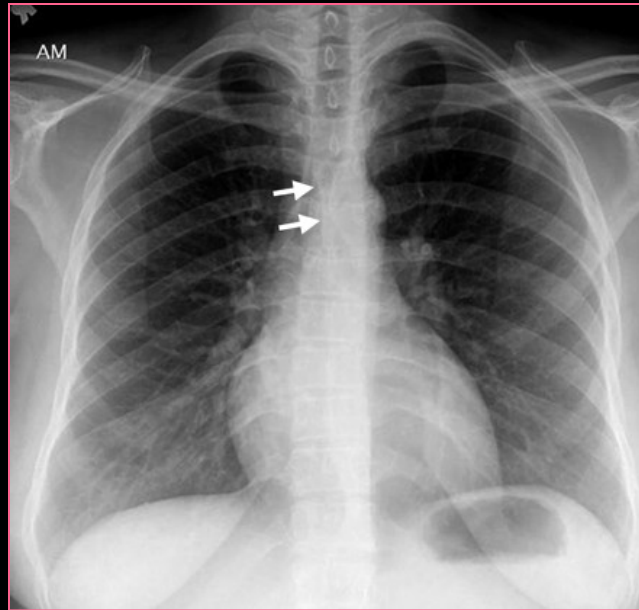
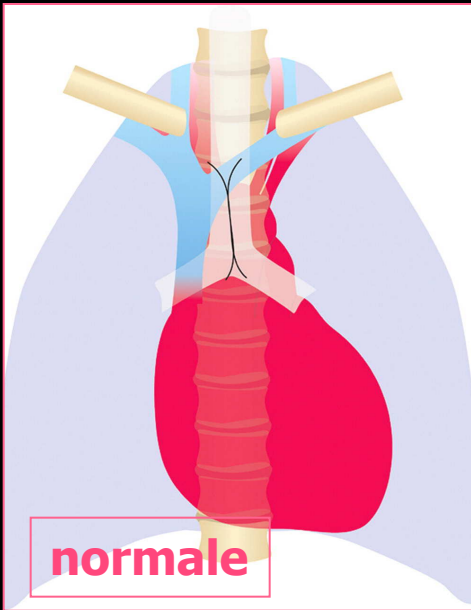
CME Test

- Classifications

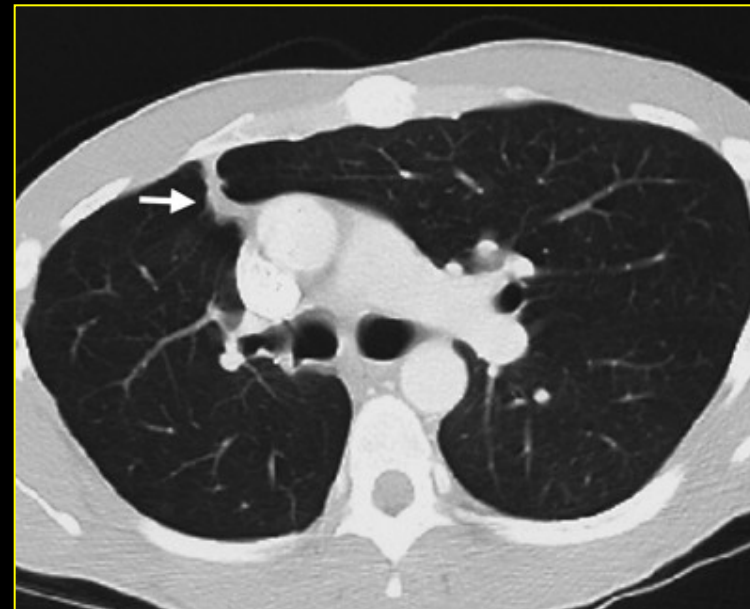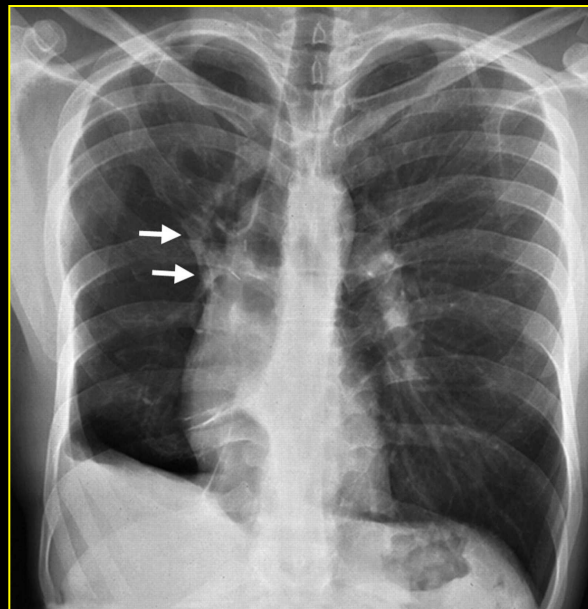
Series:

Continuing Medical
Education

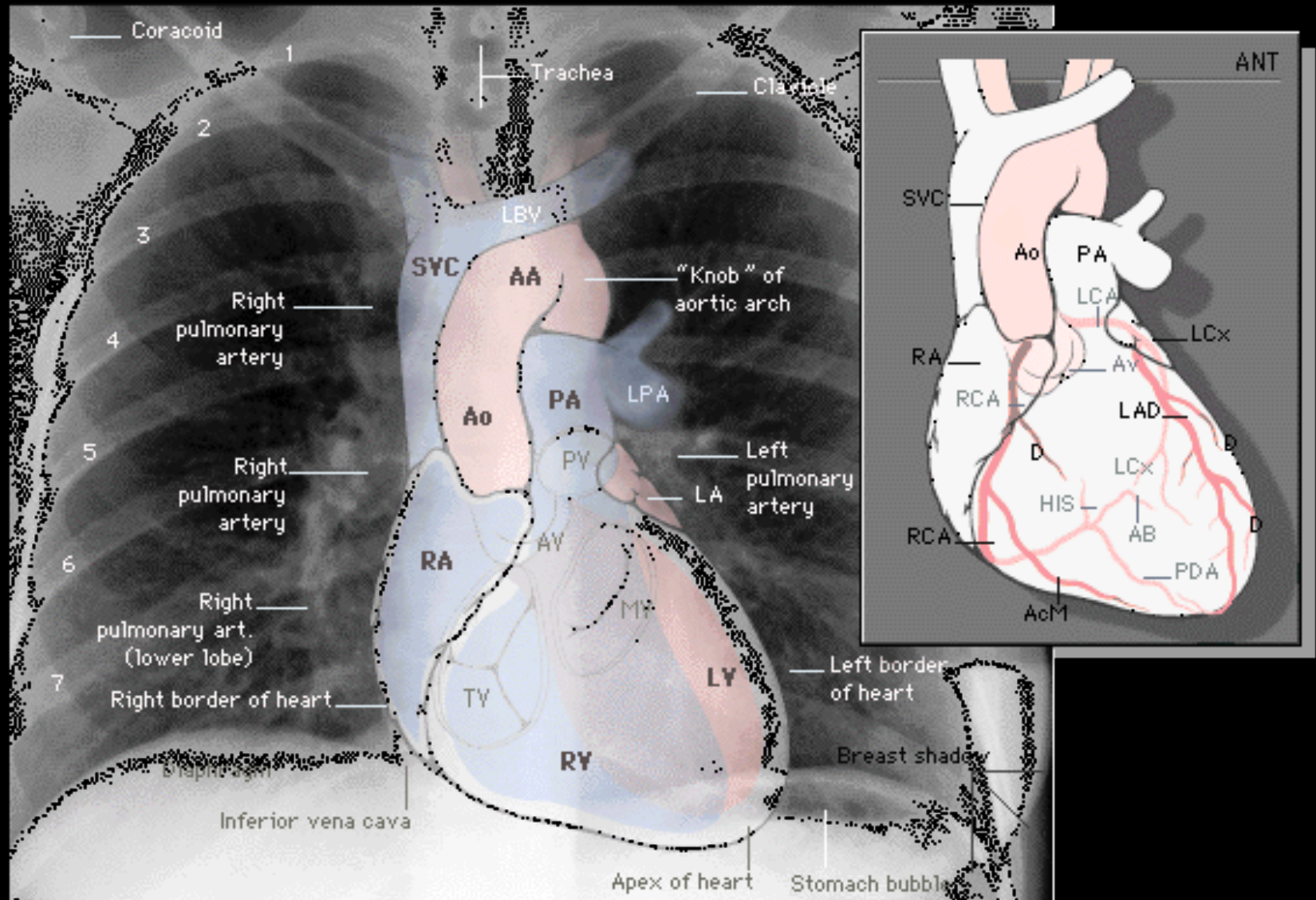
Ligne de jonction médiastinale antérieure



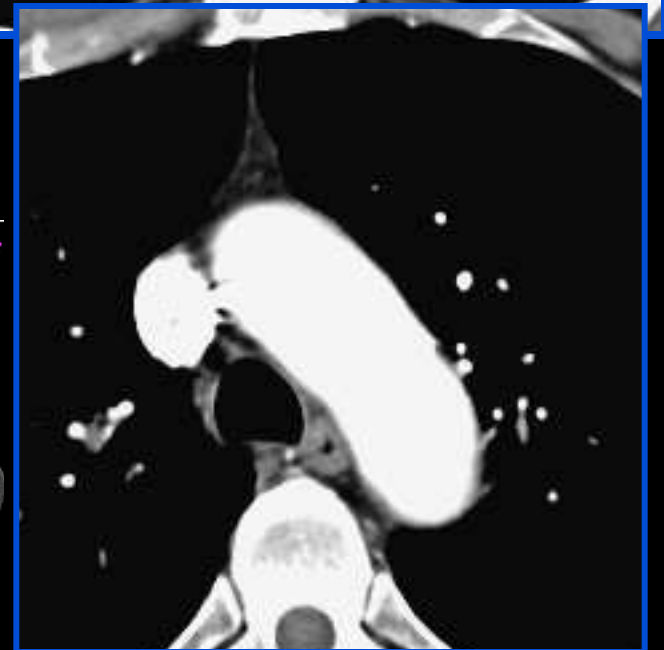
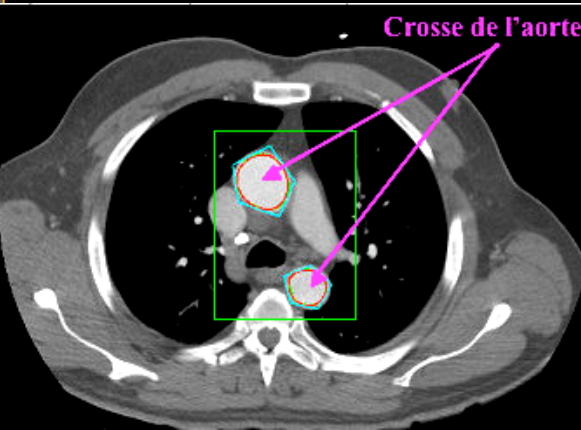
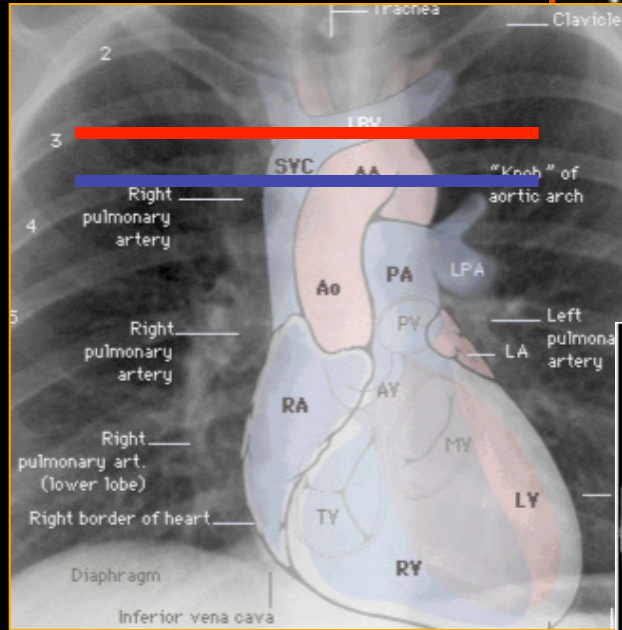
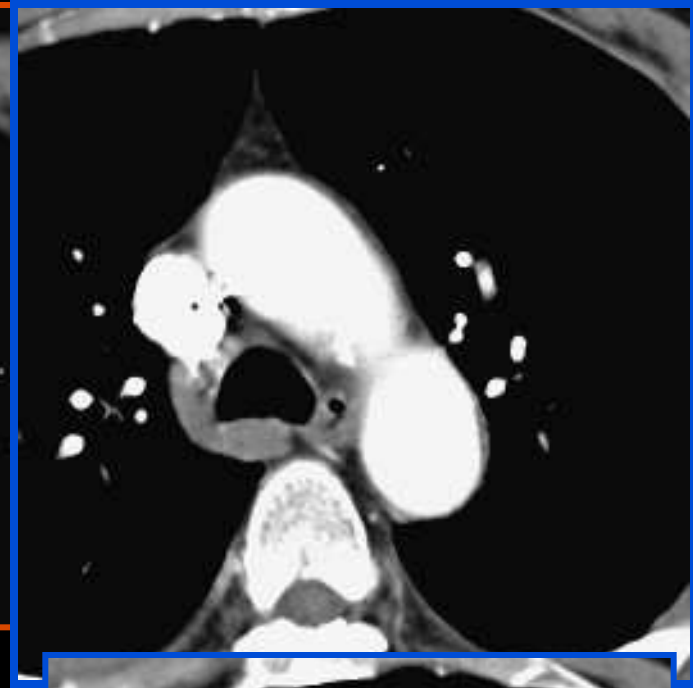
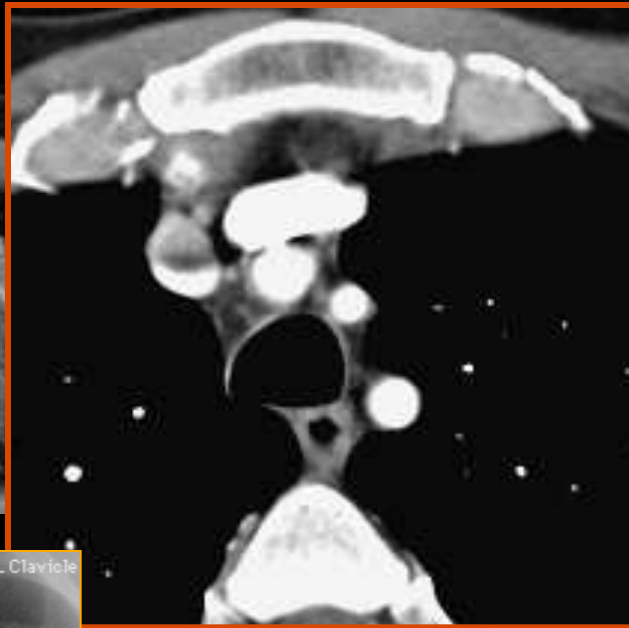
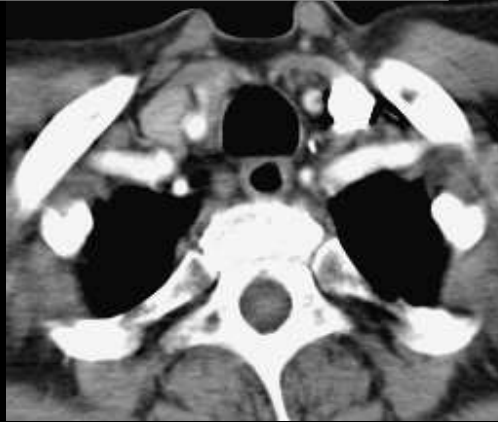**Déplacement
après lobectomie
moyenne droite**

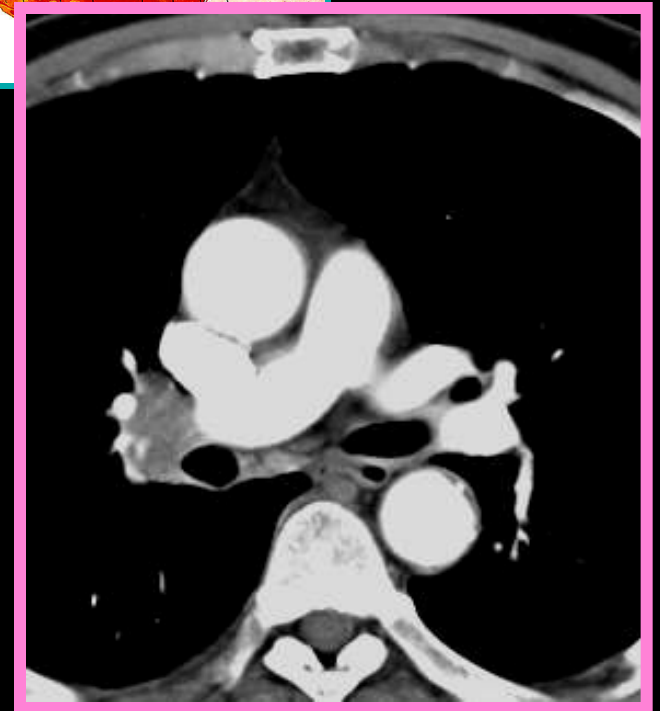
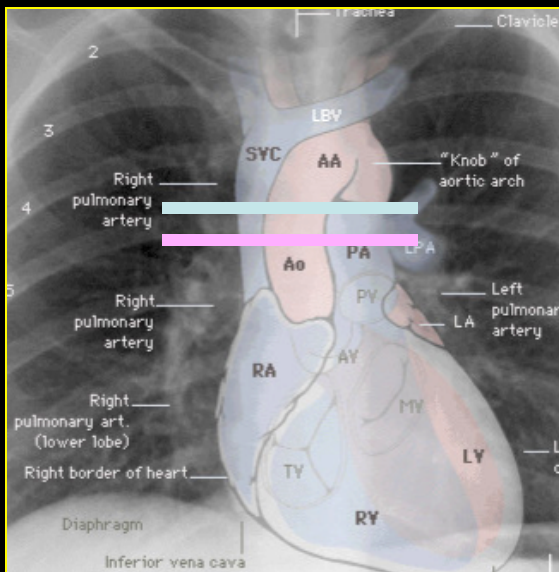
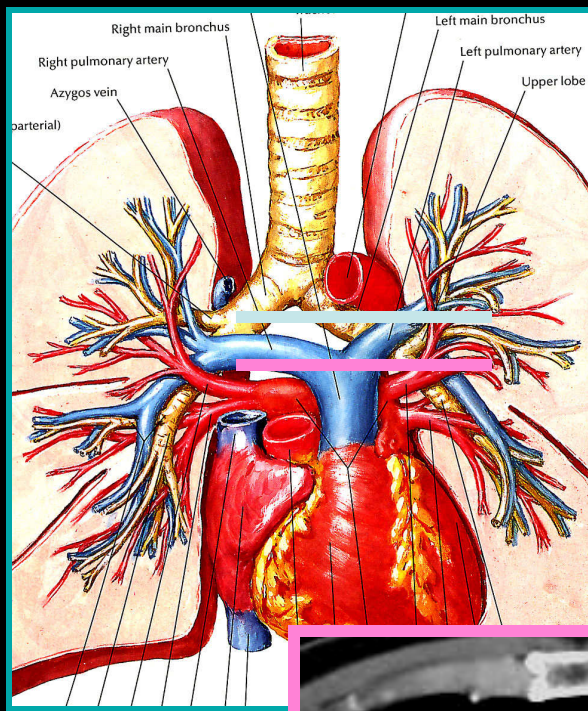
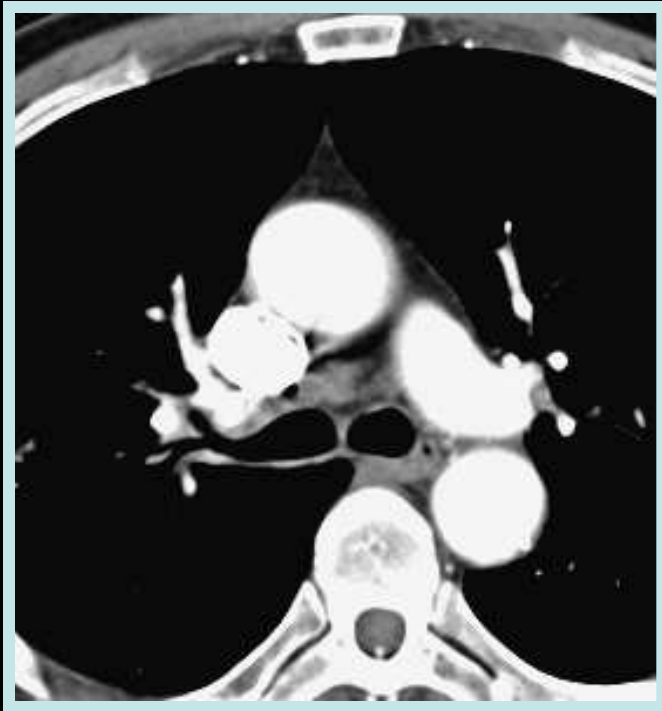


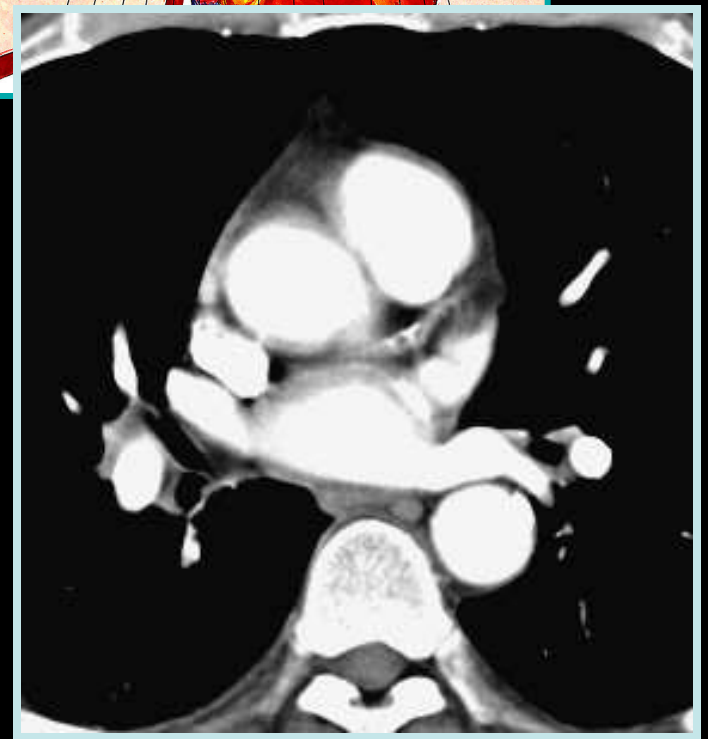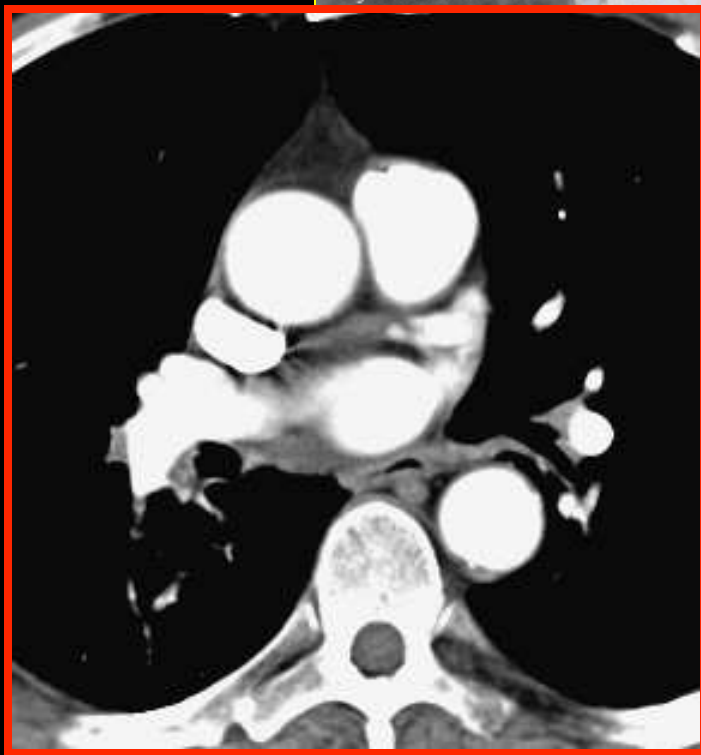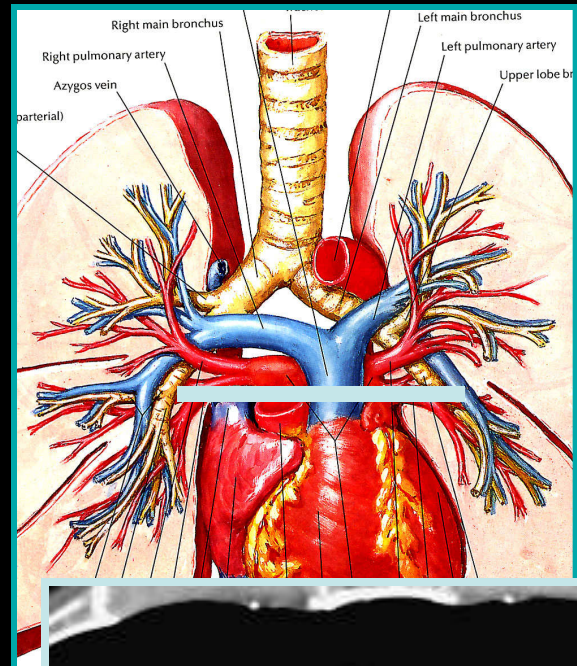
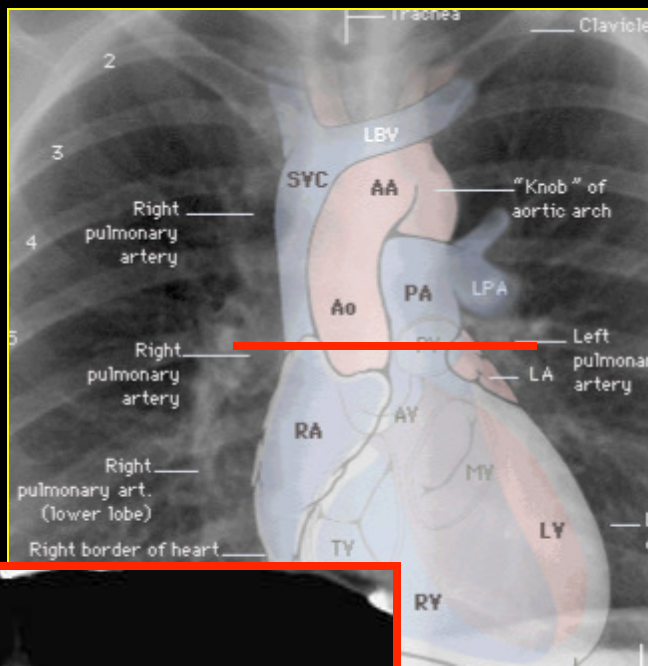
Reconnaître les structures vasculaires

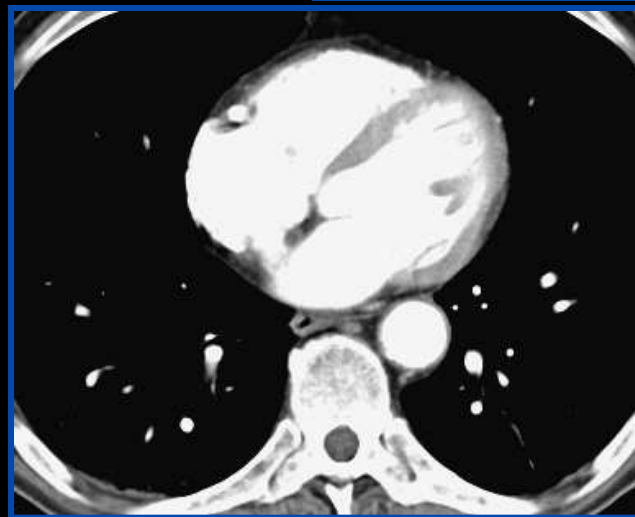
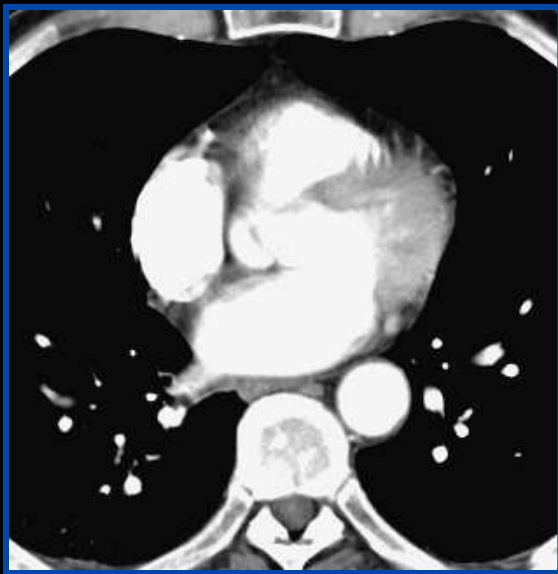
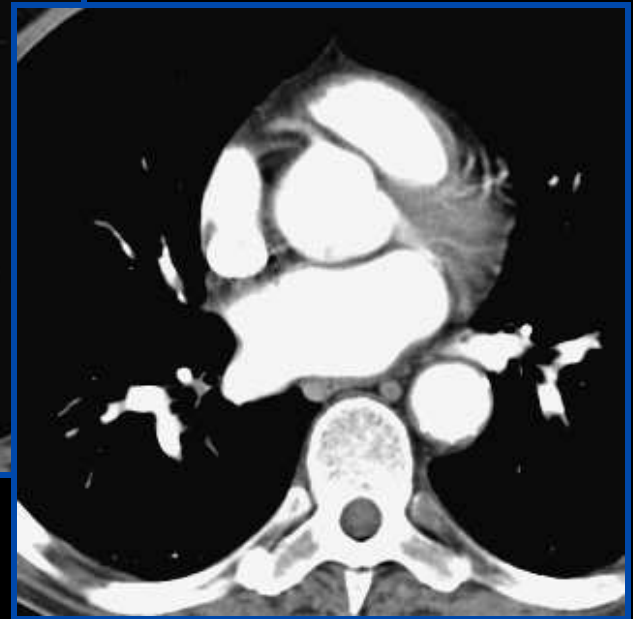
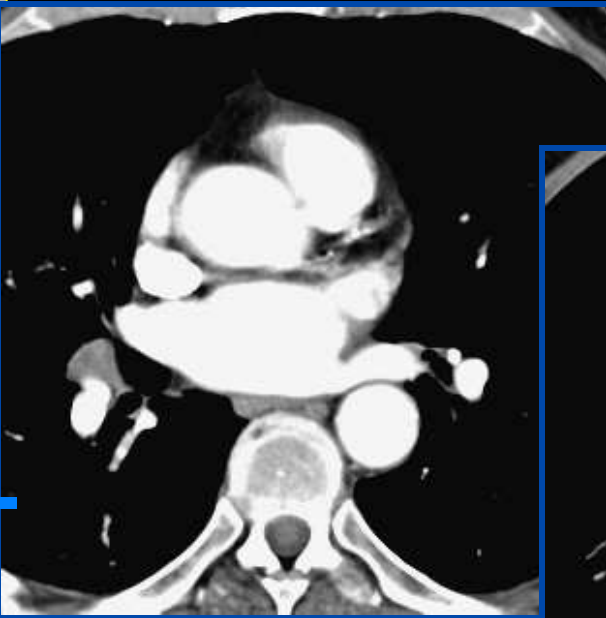
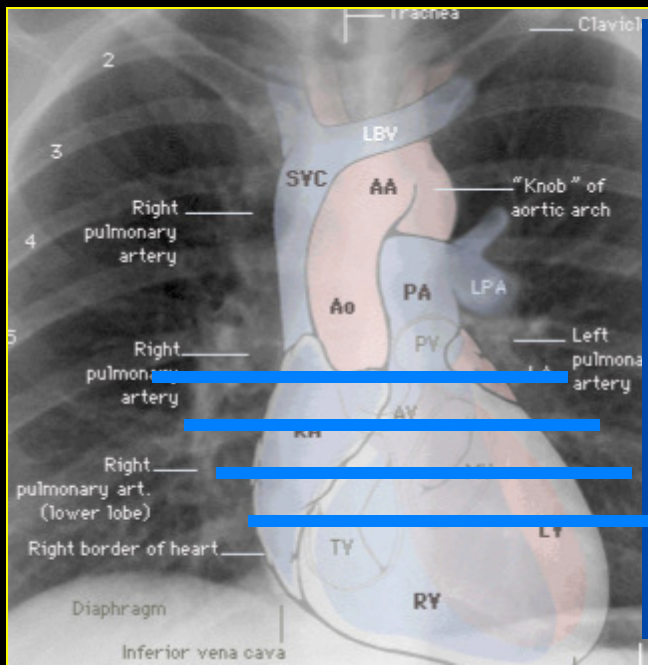


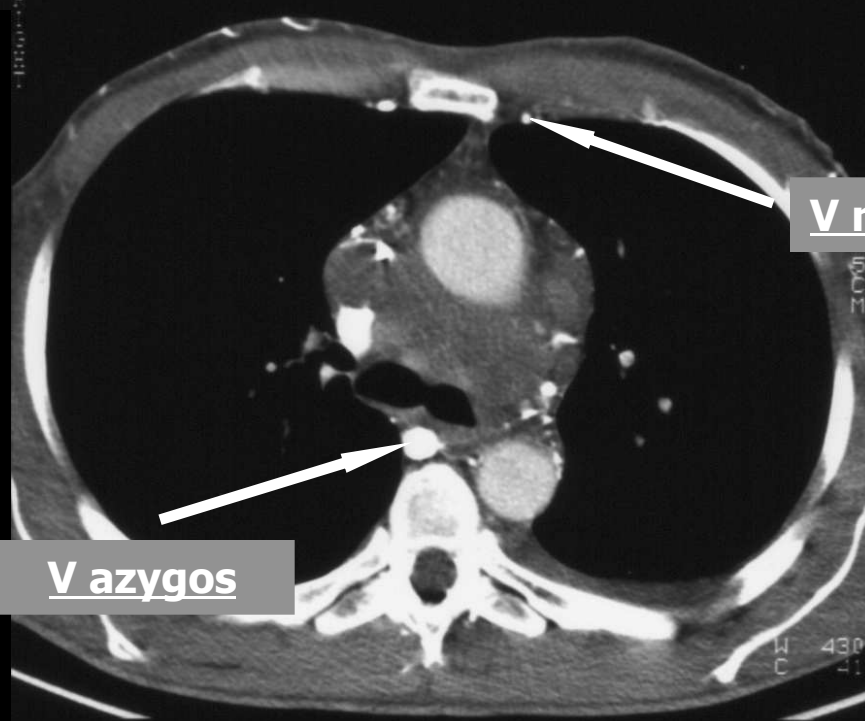
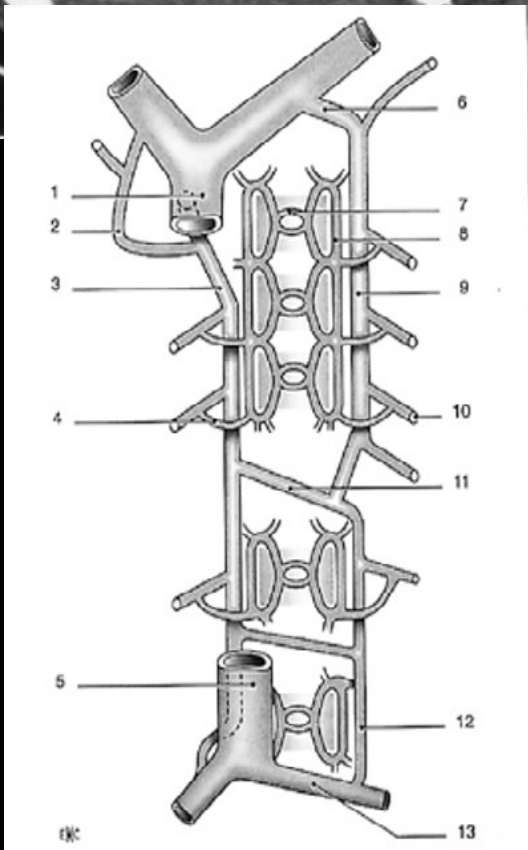
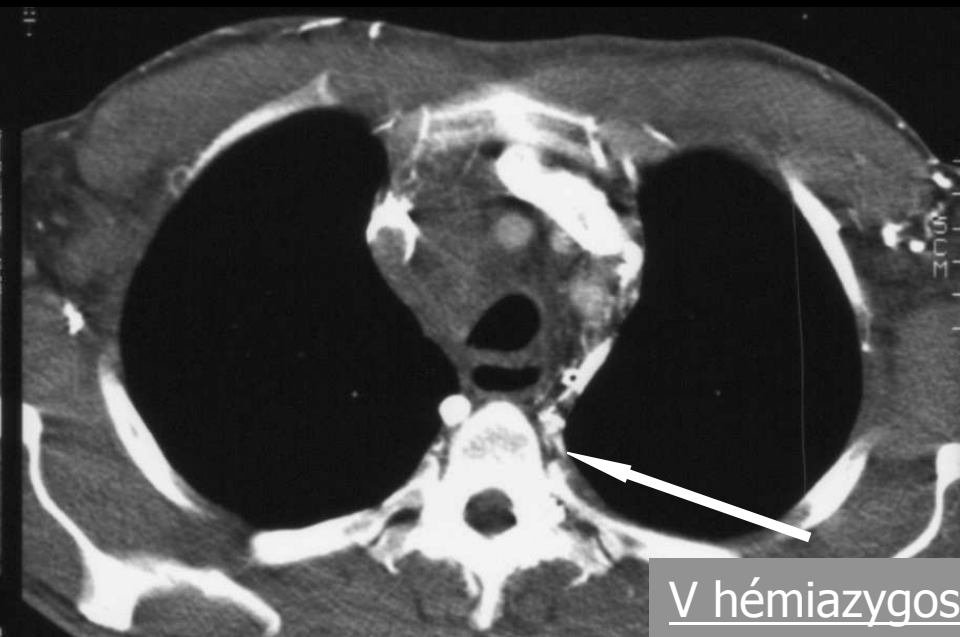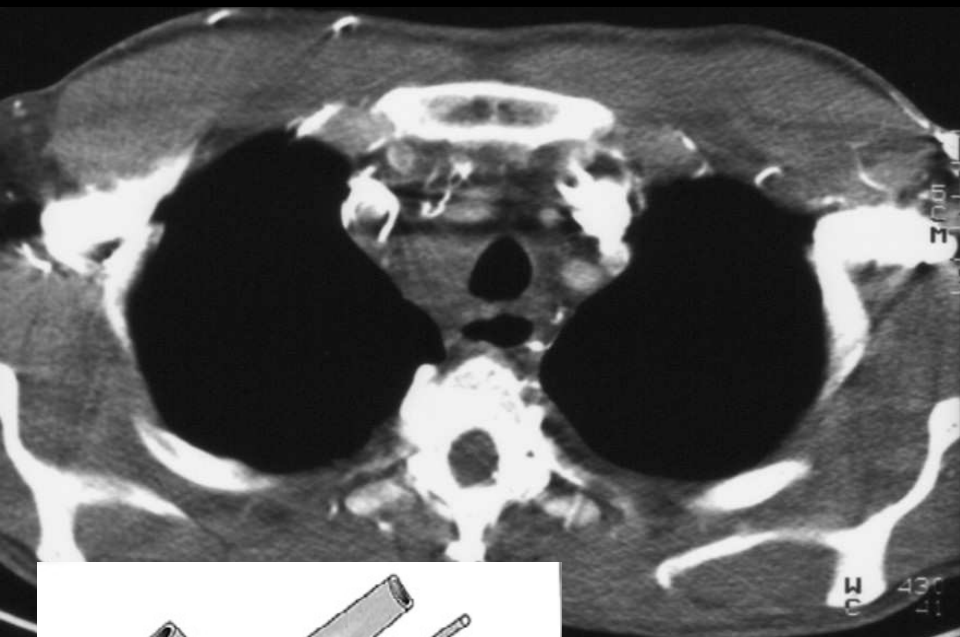
Scanner







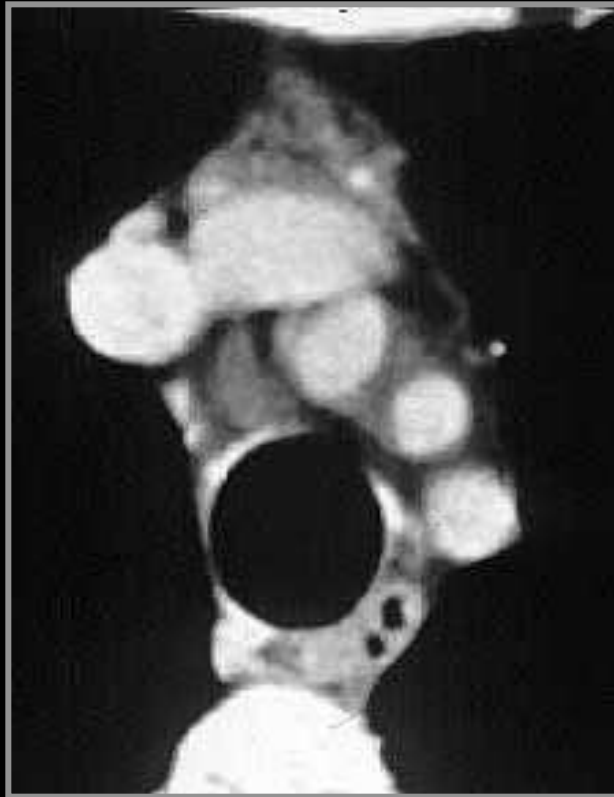




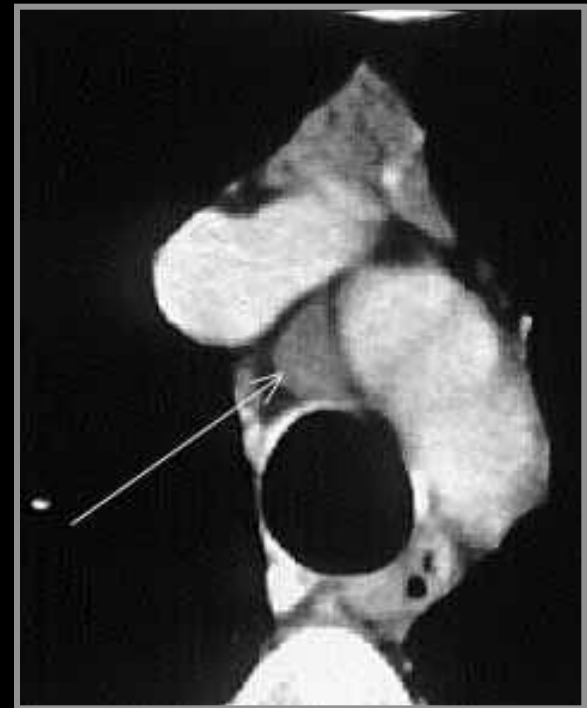

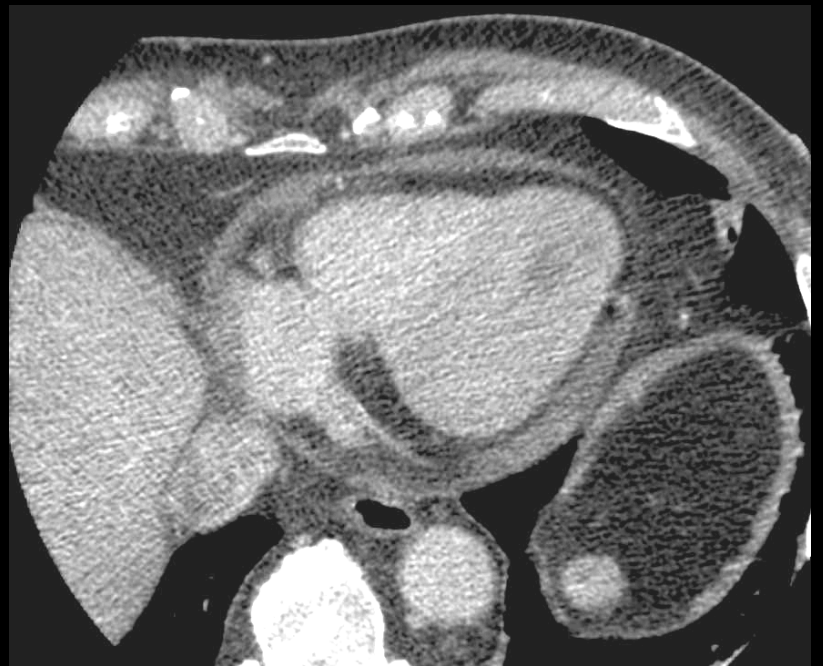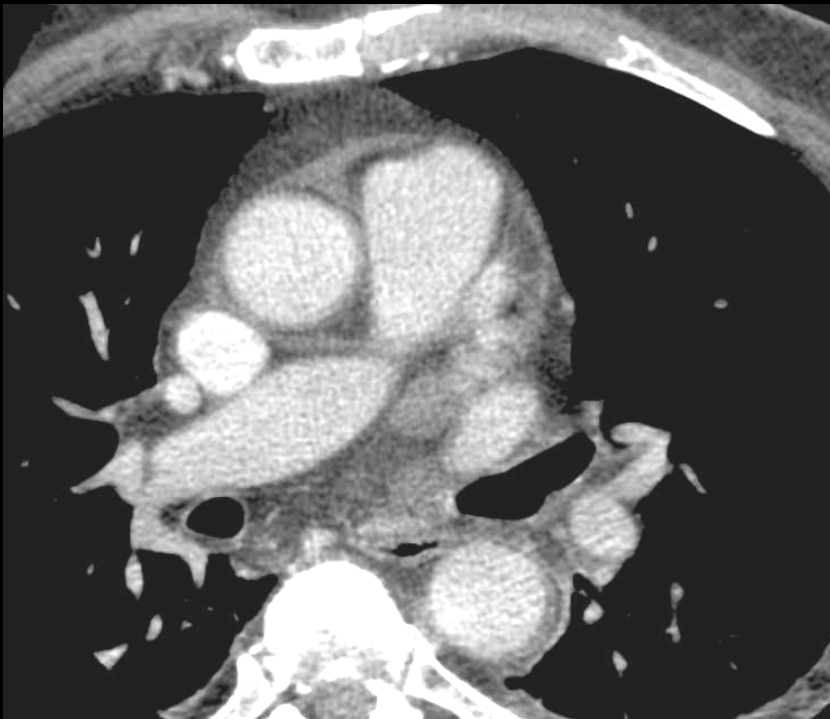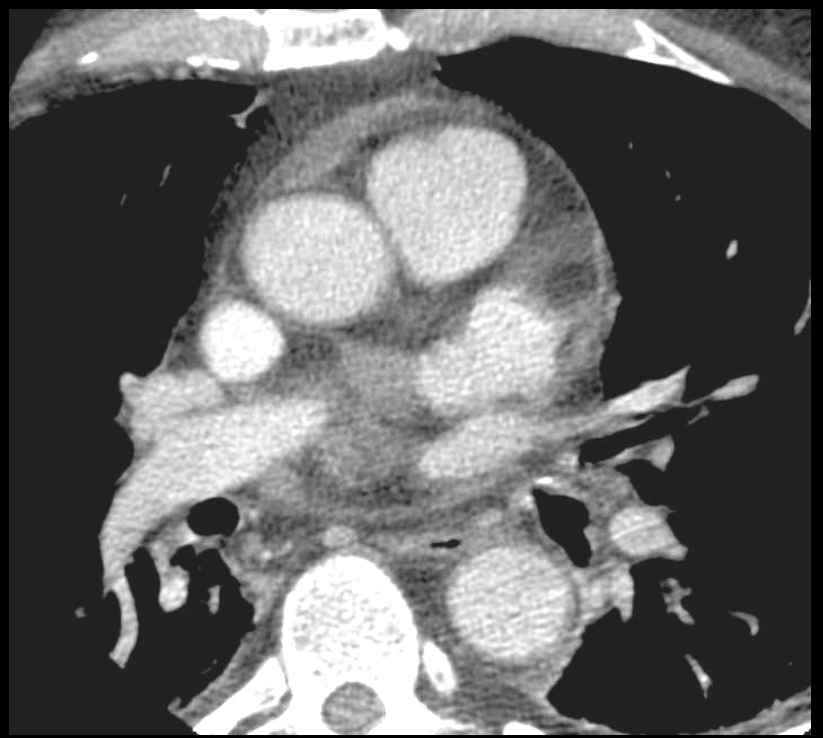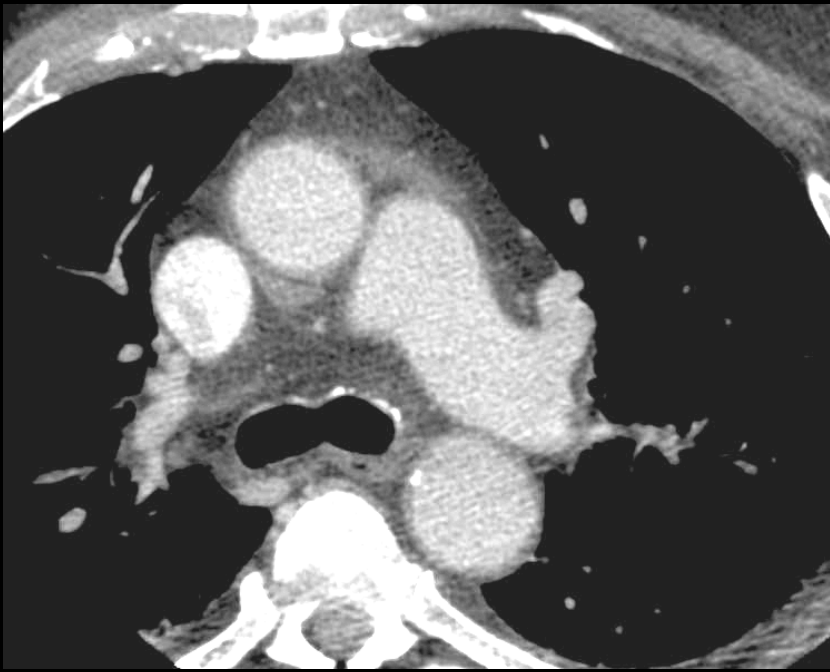**UN PEU DE PATHOLOGIE ET
VARIATIONS ANATOMIQUES...**

Pièges et erreurs

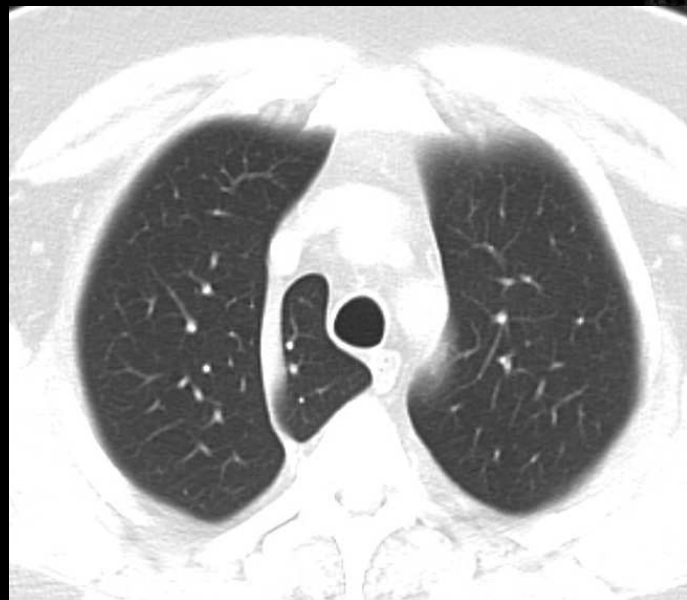
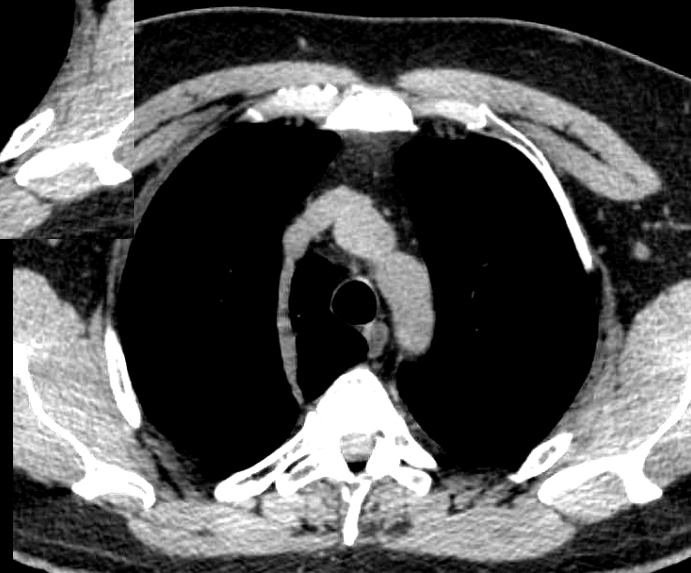
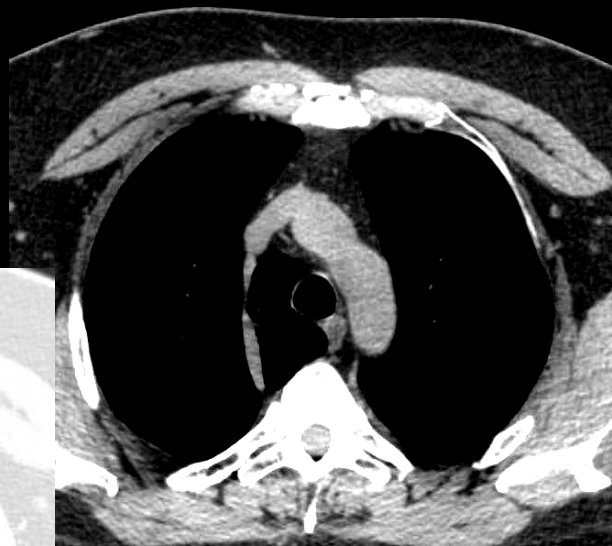
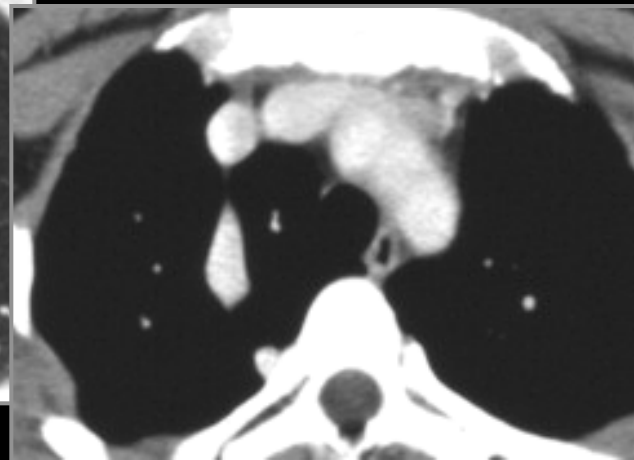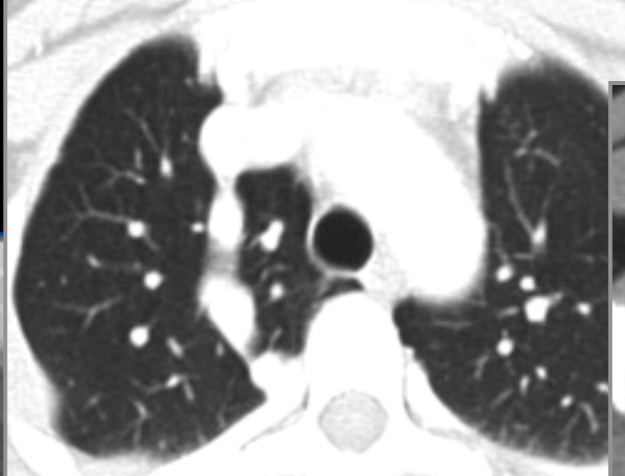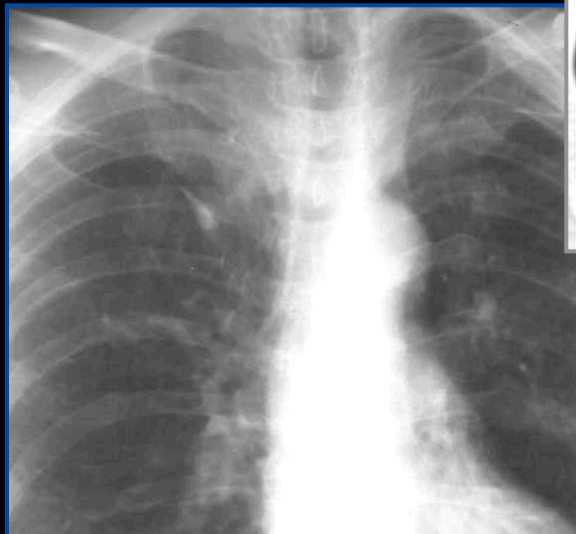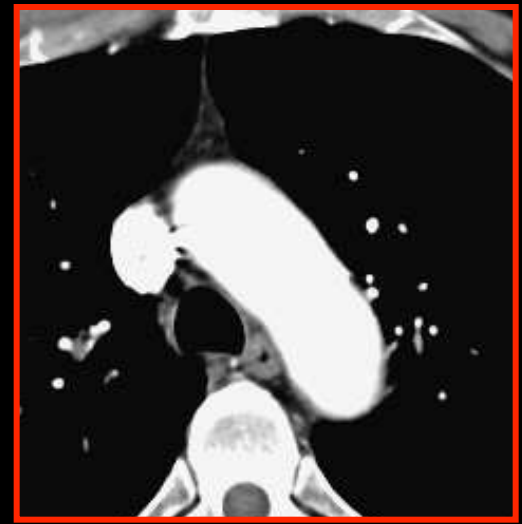
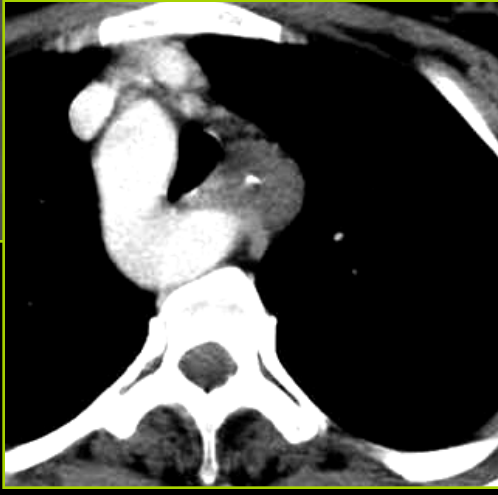
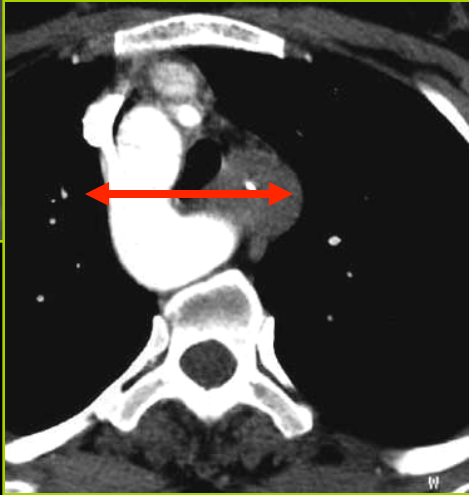
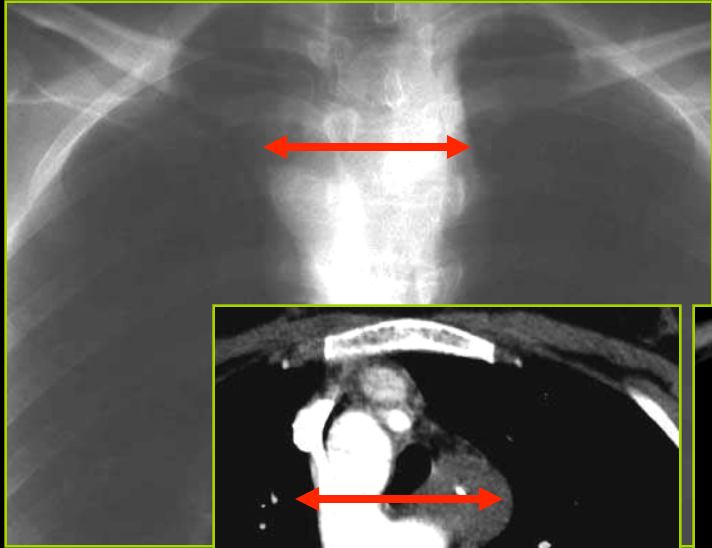
Récessus péricardique



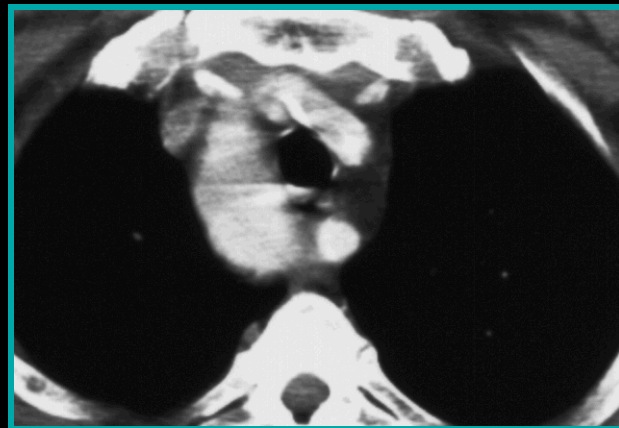
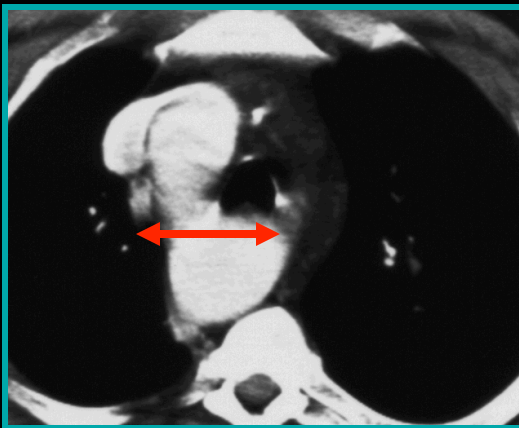


Scissure azygos





Arche aortique à droite

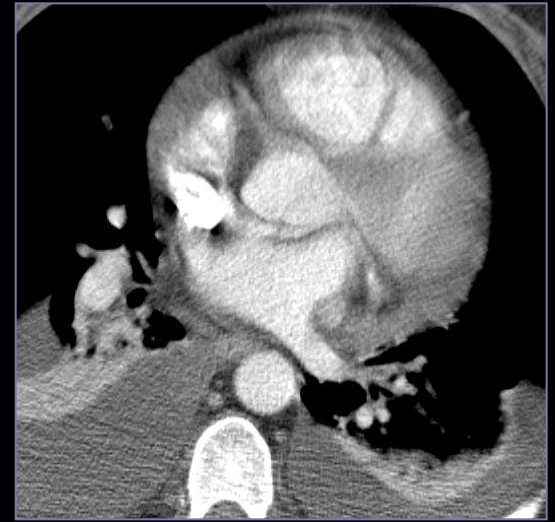
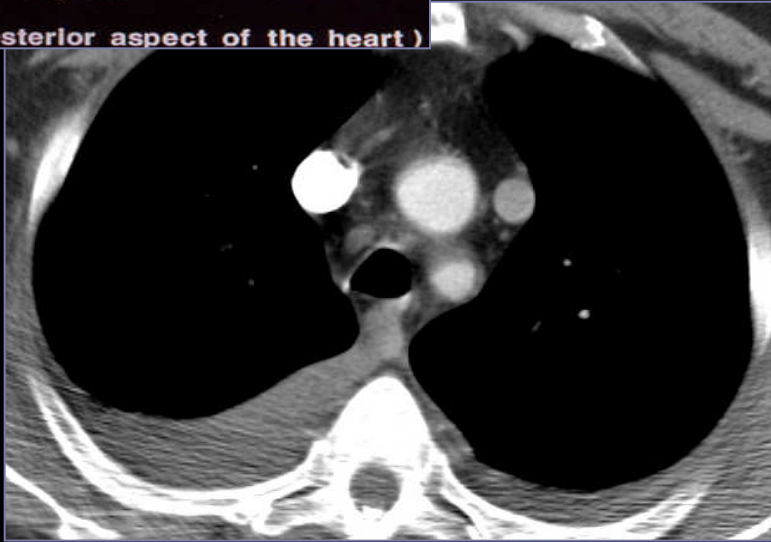


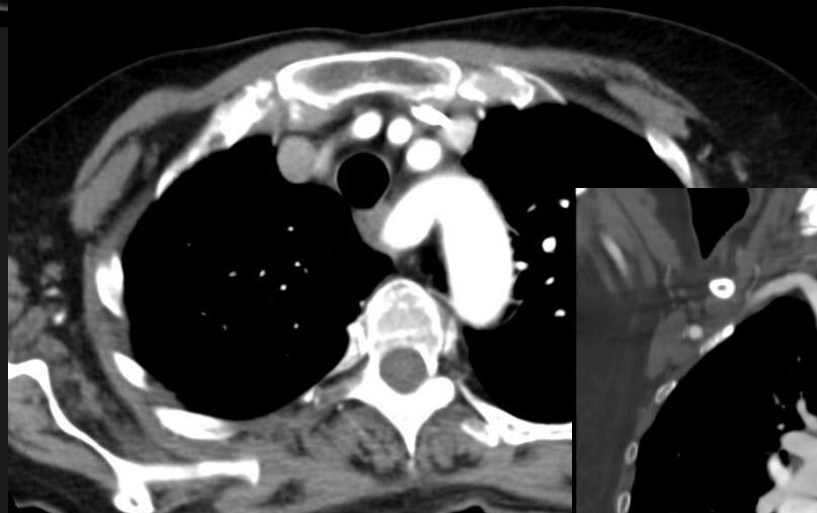
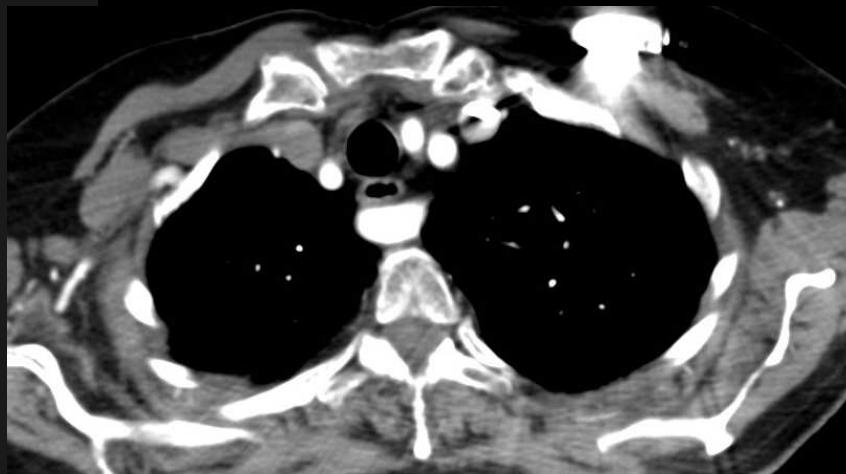
Double Veine cave sup

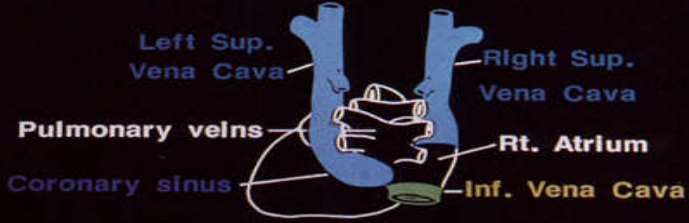

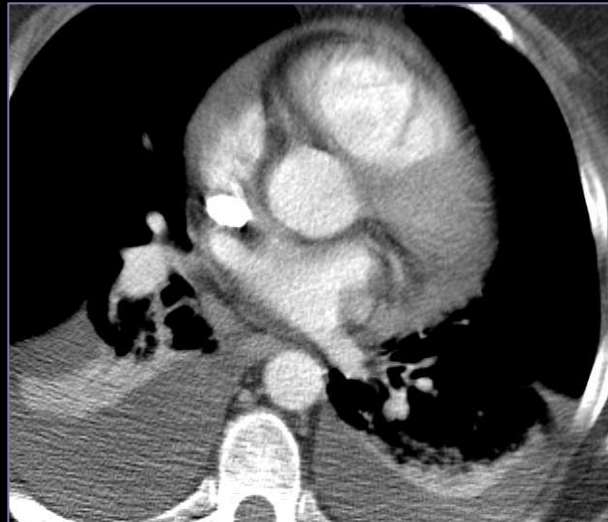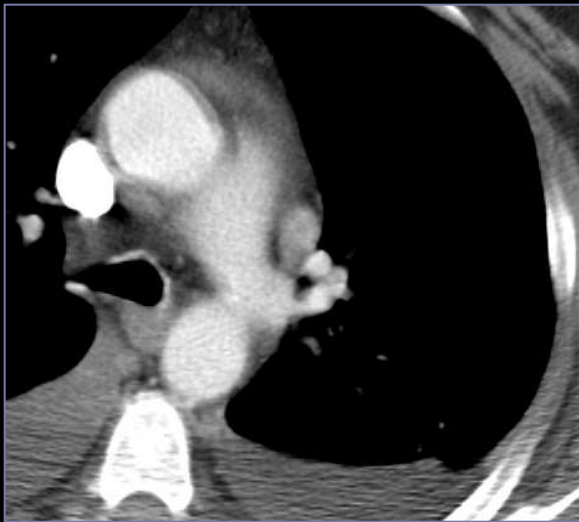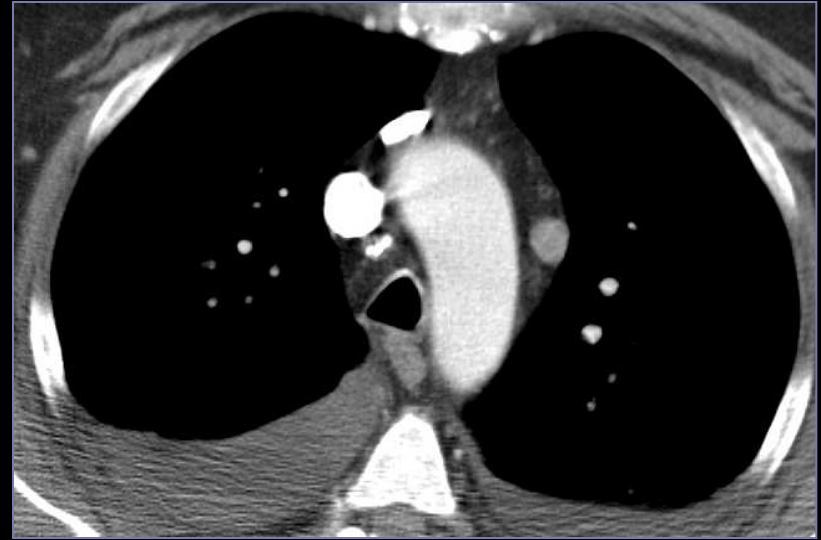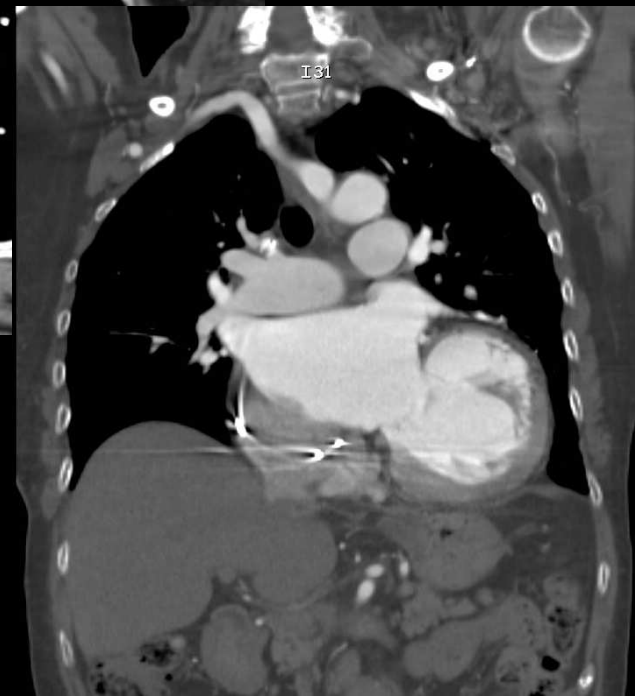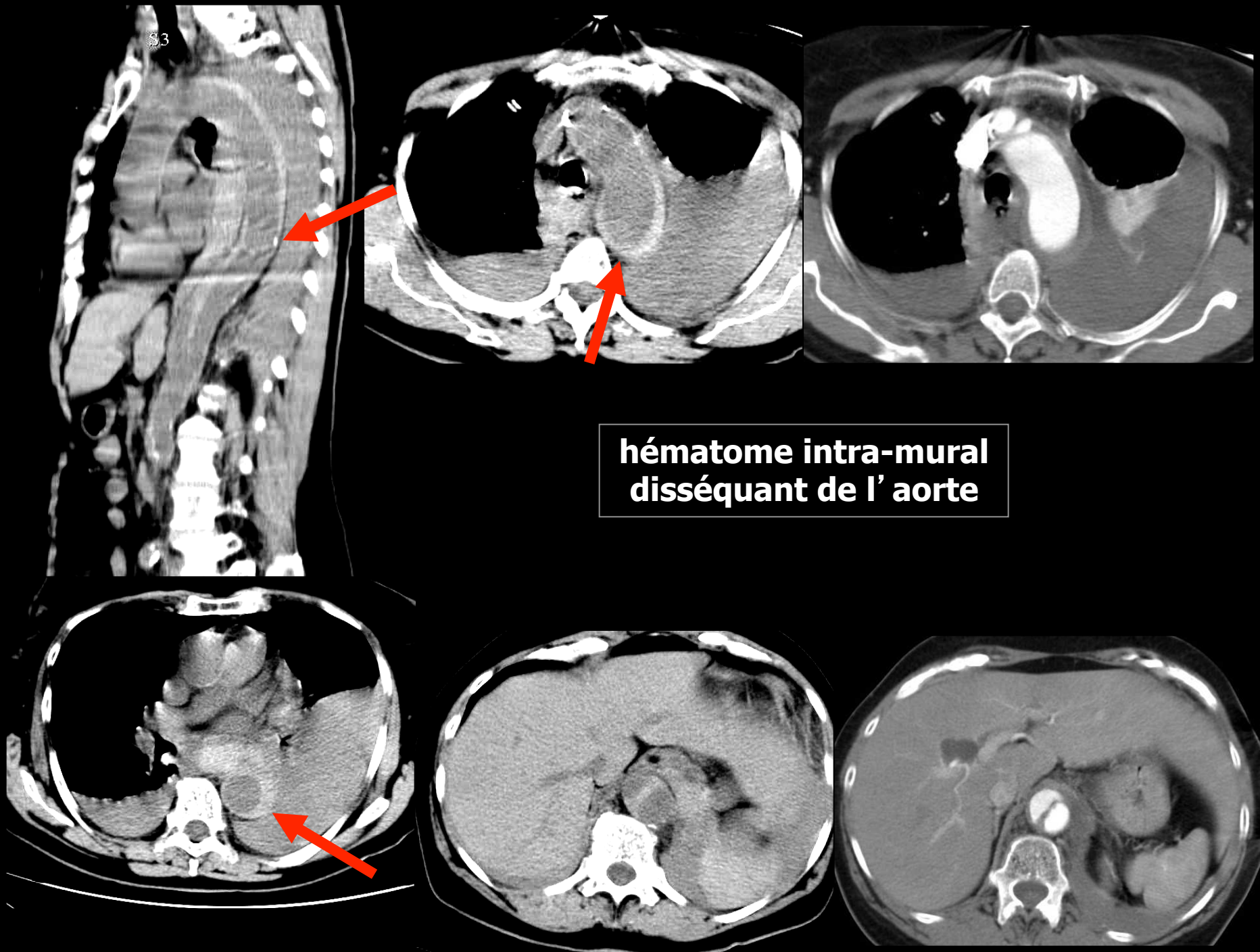
Fig 8B

(Viewed from posterior aspect of the heart)

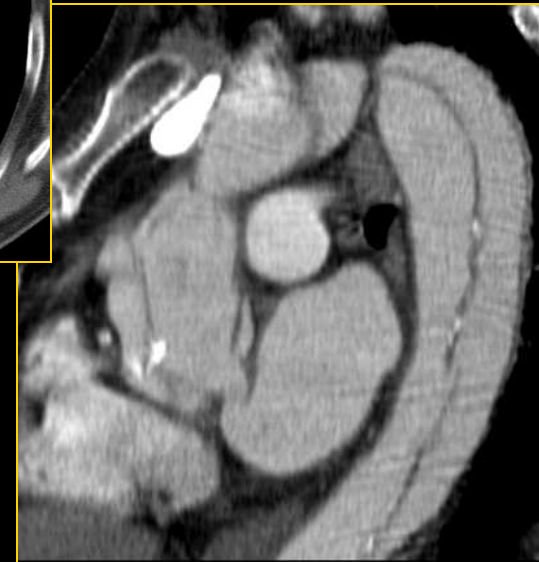
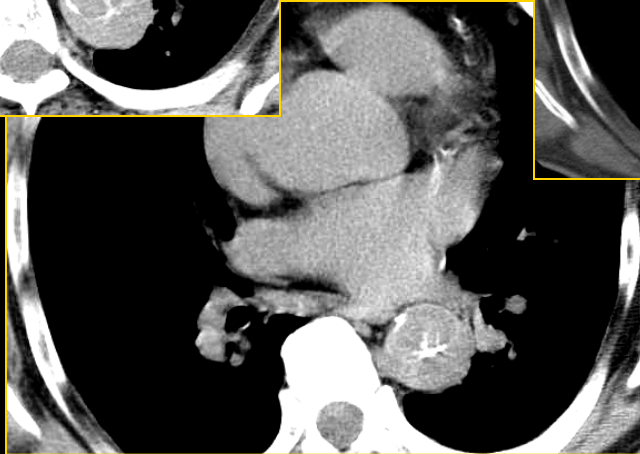
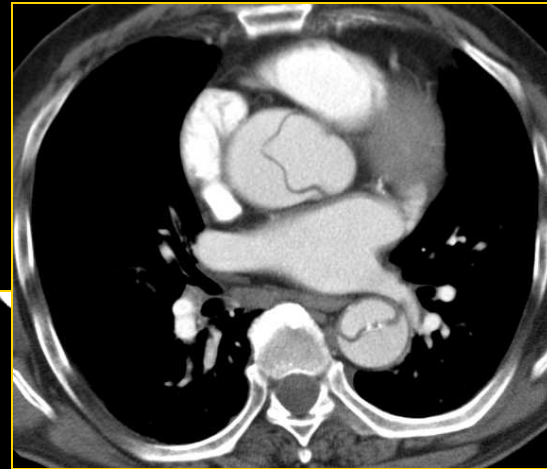
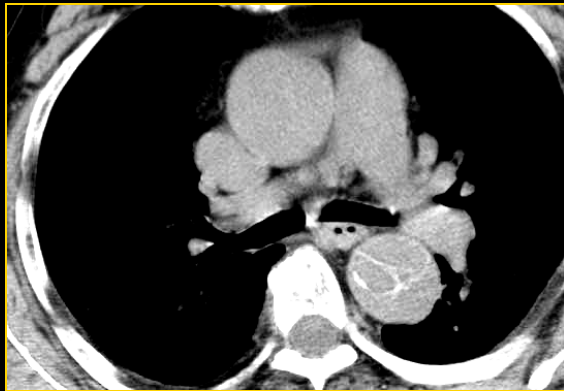
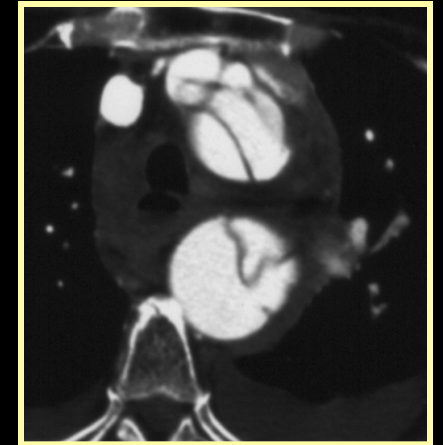
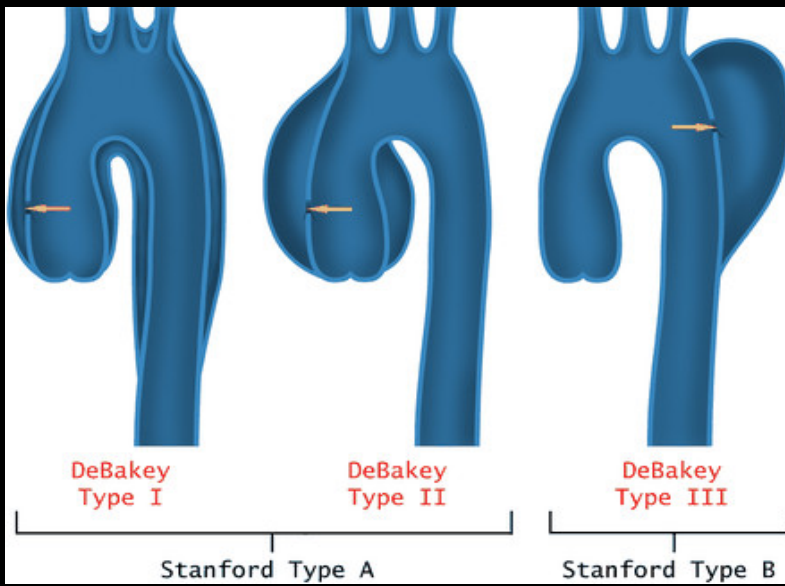


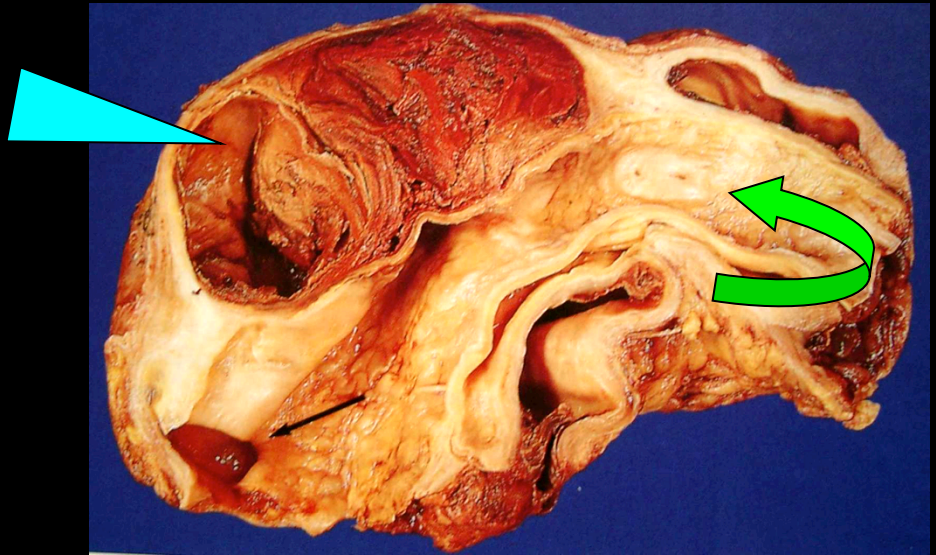
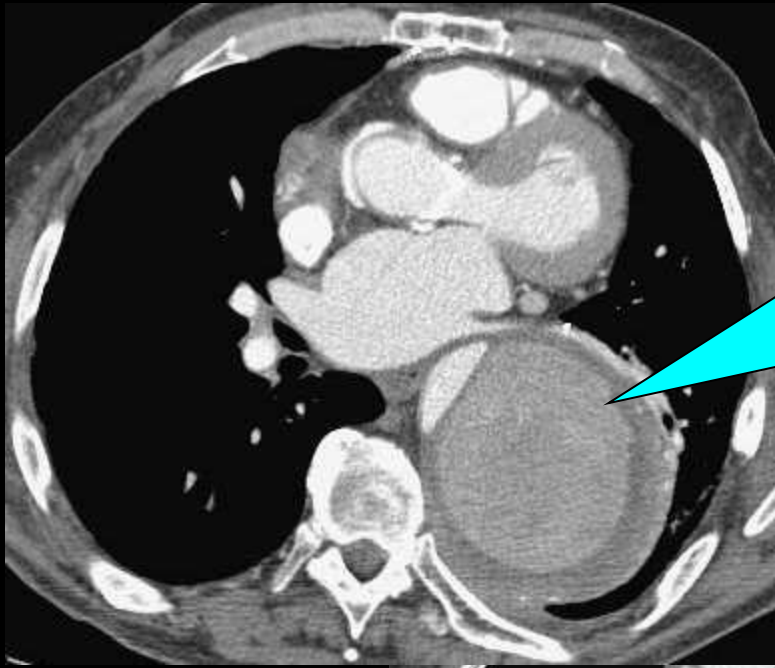


**Artère sous clavière droite
rétrooesophagienne: arteria lusoria**

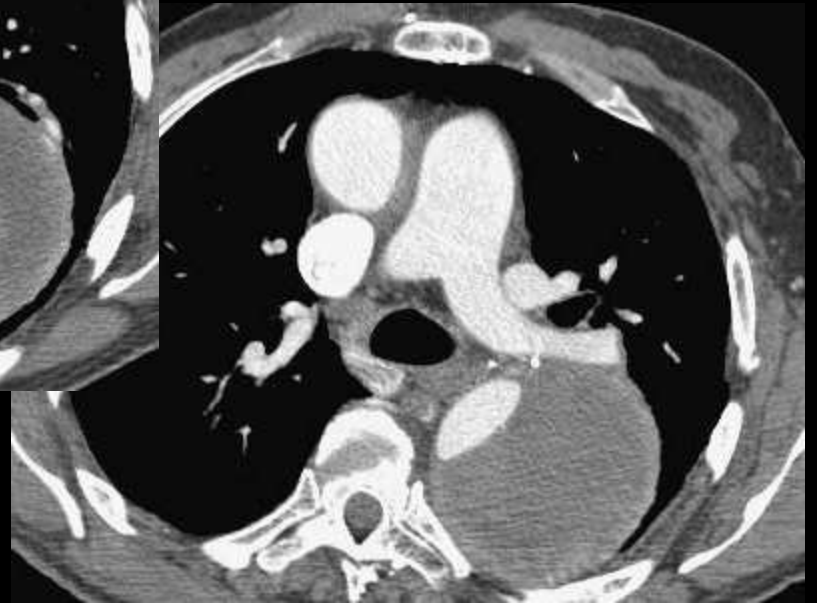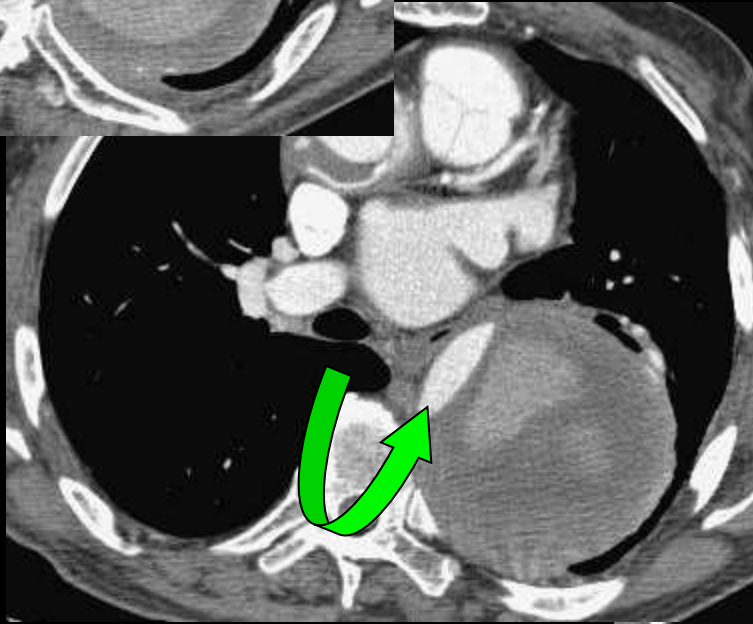


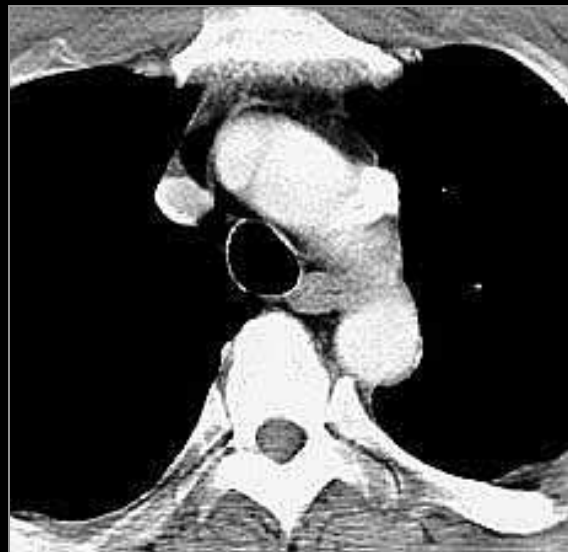
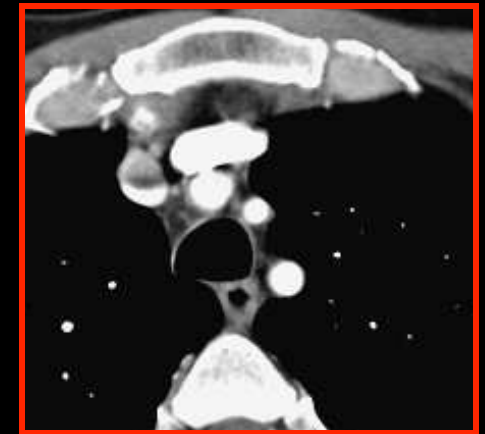
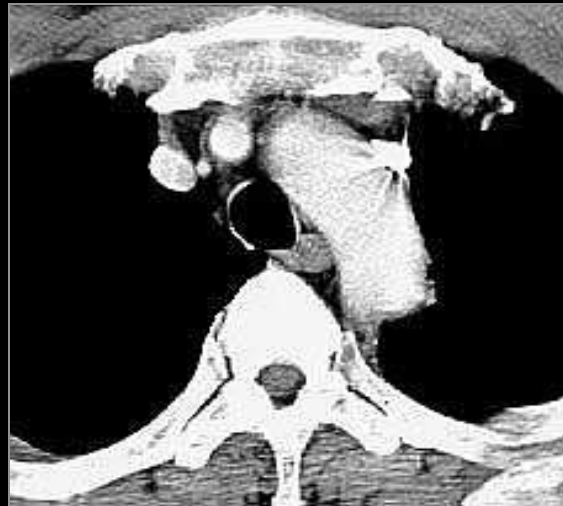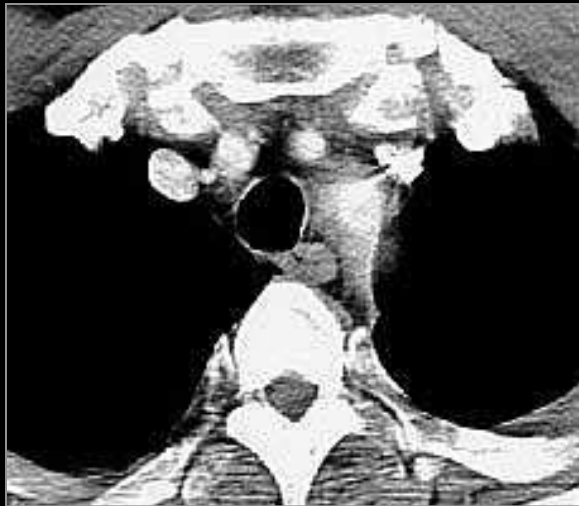Dissection aortique aiguë



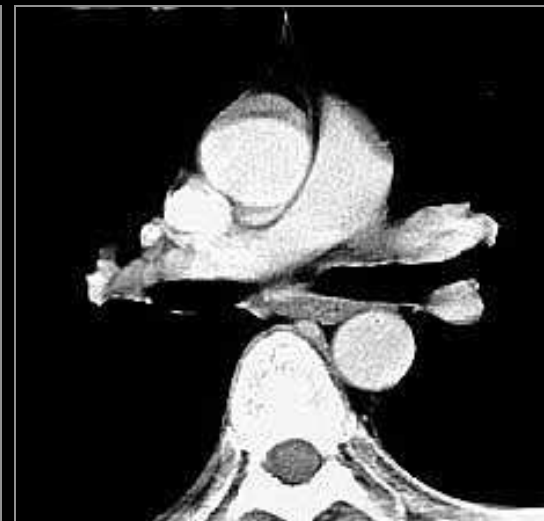
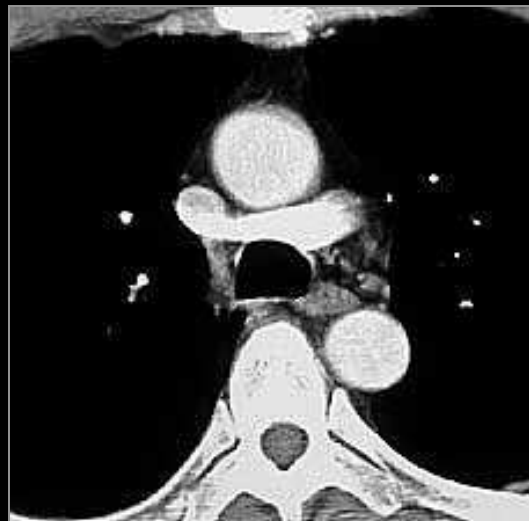

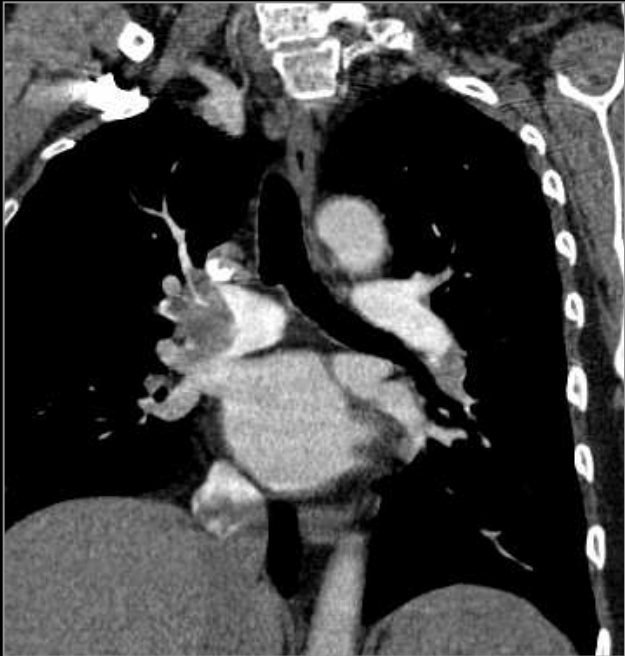Dissection aortique et dilatation anévrysmale du faux chenal





Veine brachiocéphalique G aberrante





Artères pulmonaires
Embolie pulmonaire

