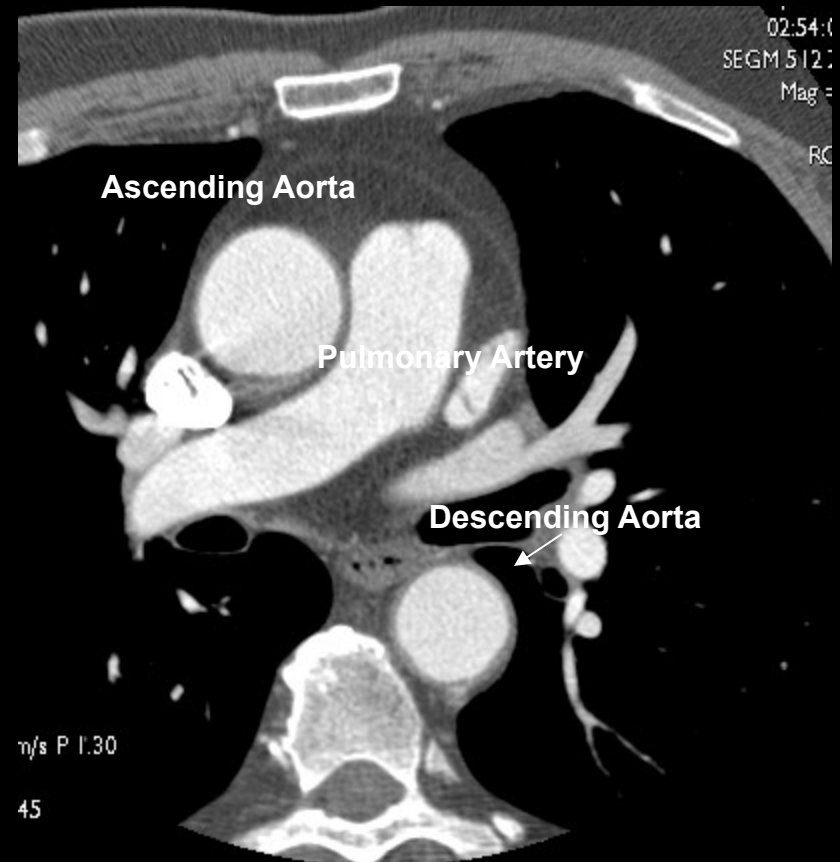
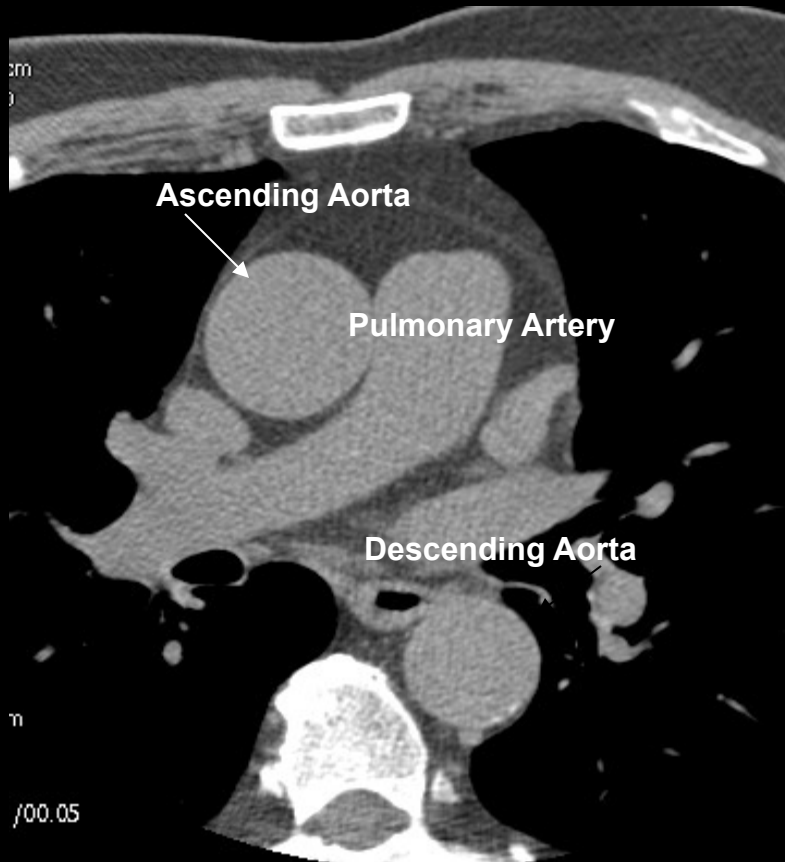


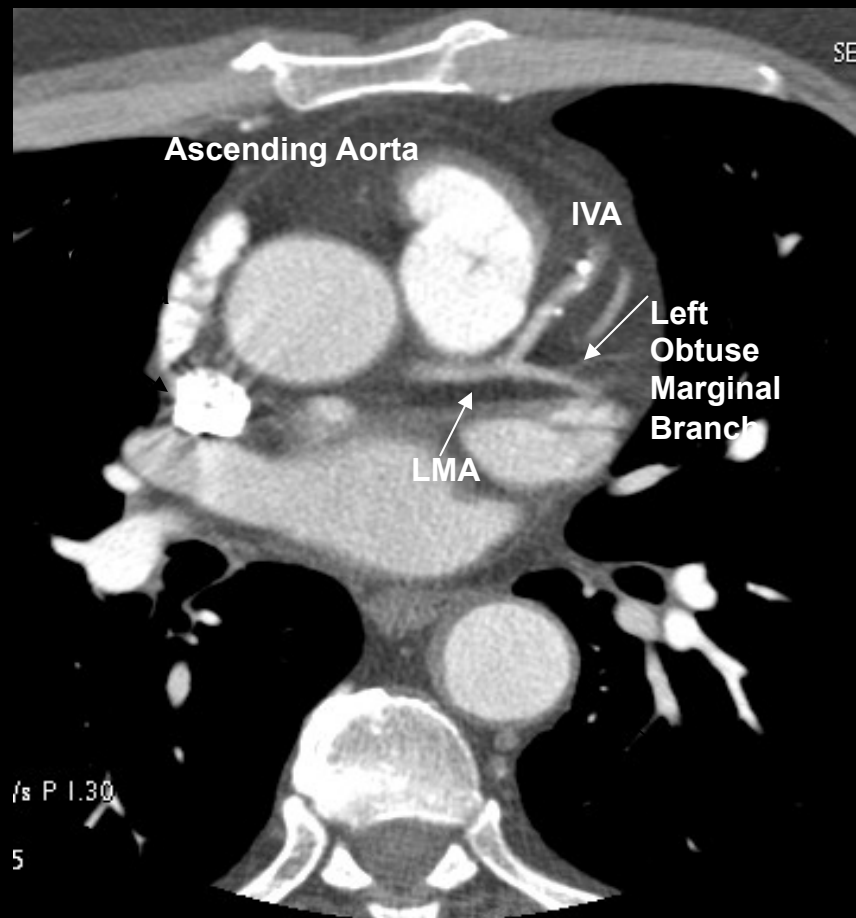
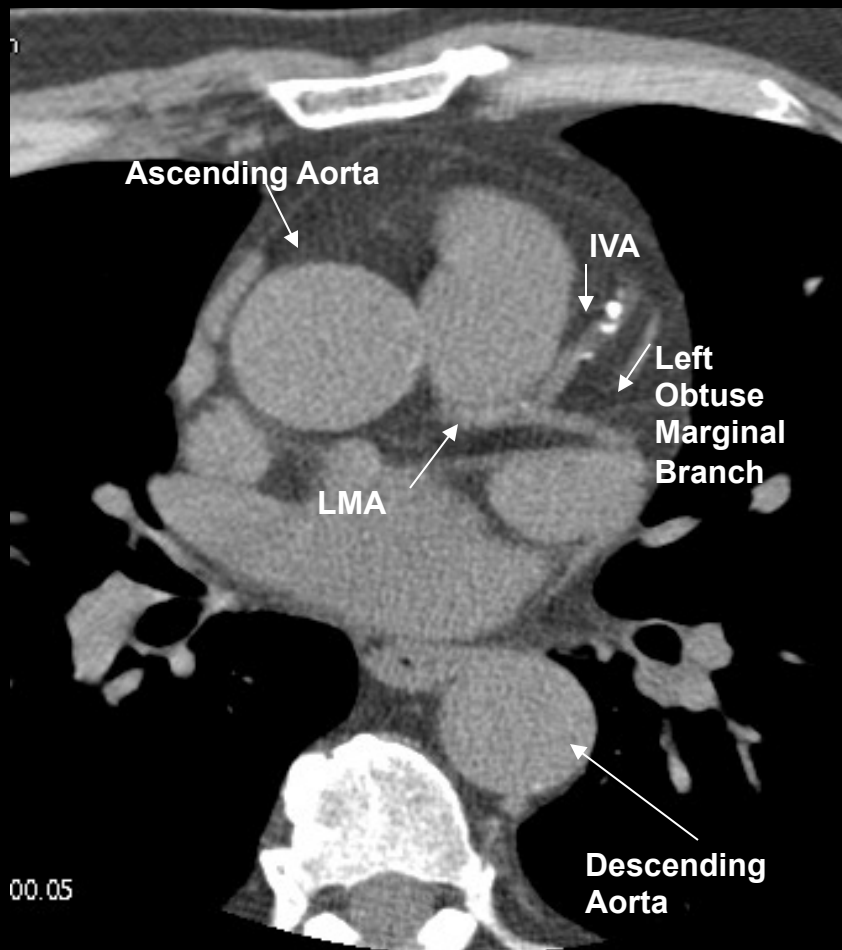


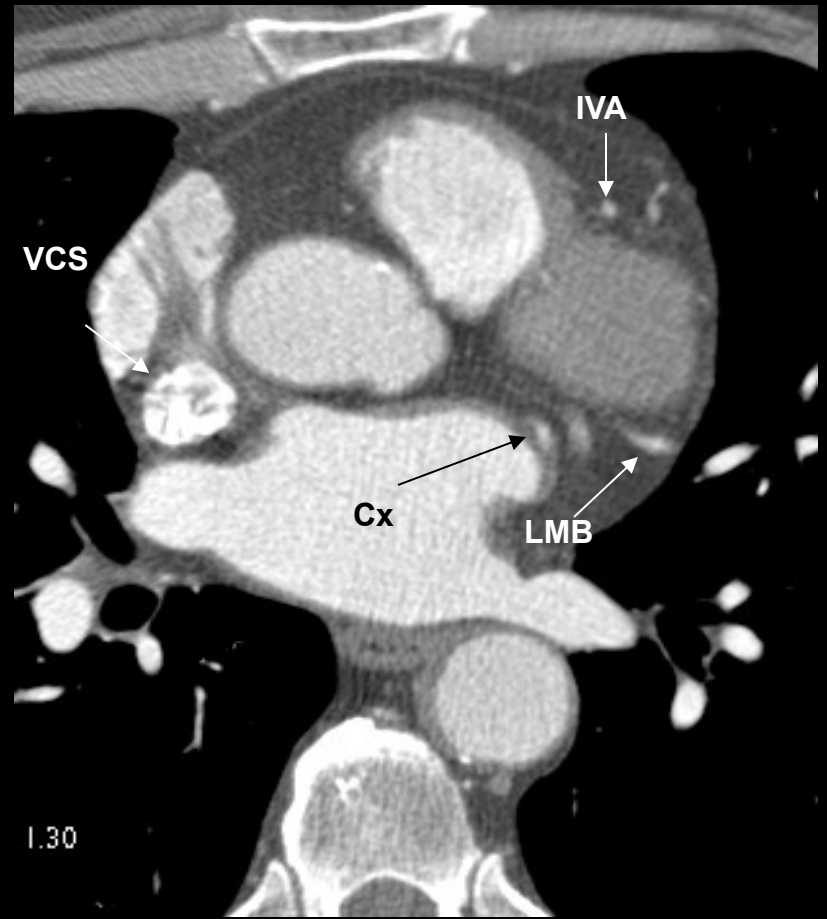
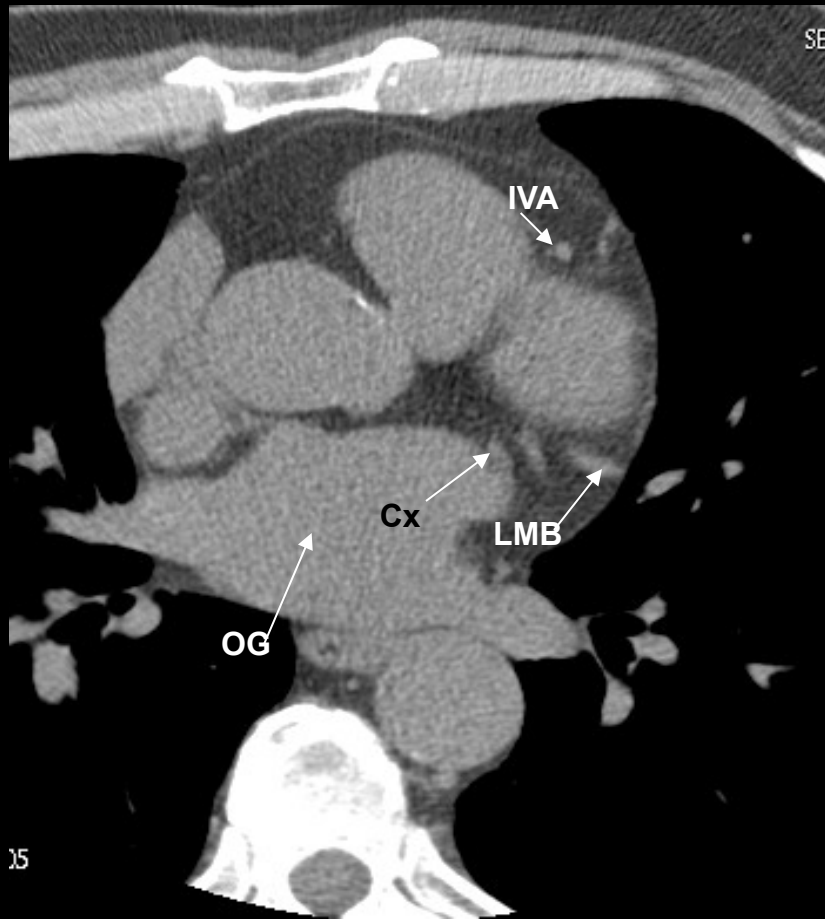
2/ RADIOANATOMIE DU MEDIASTIN

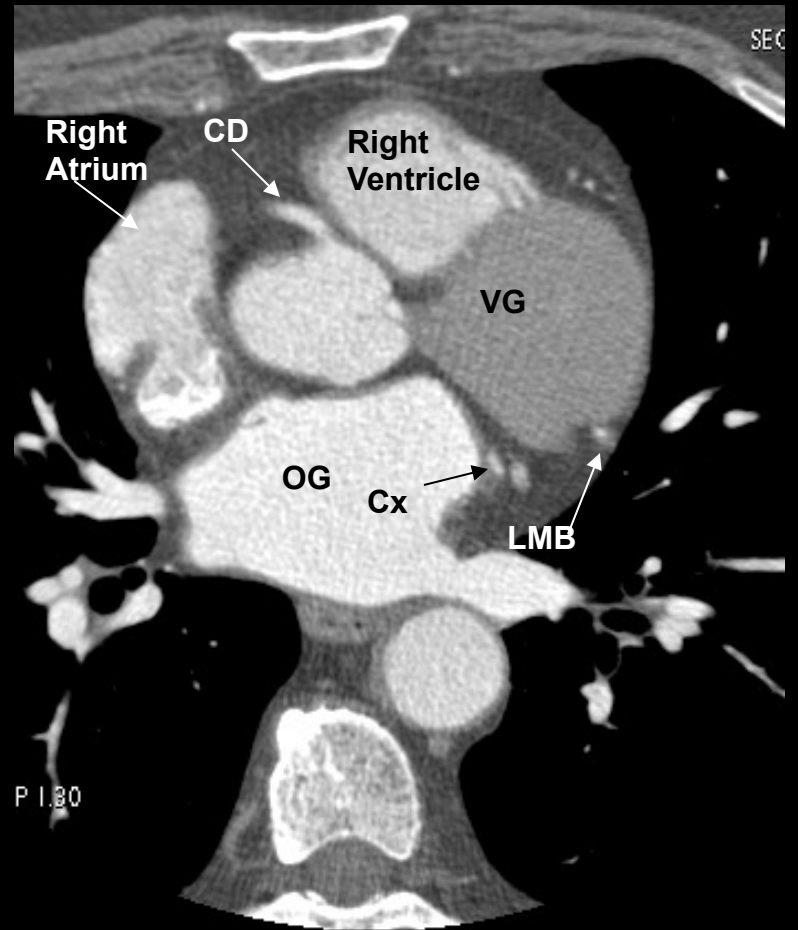
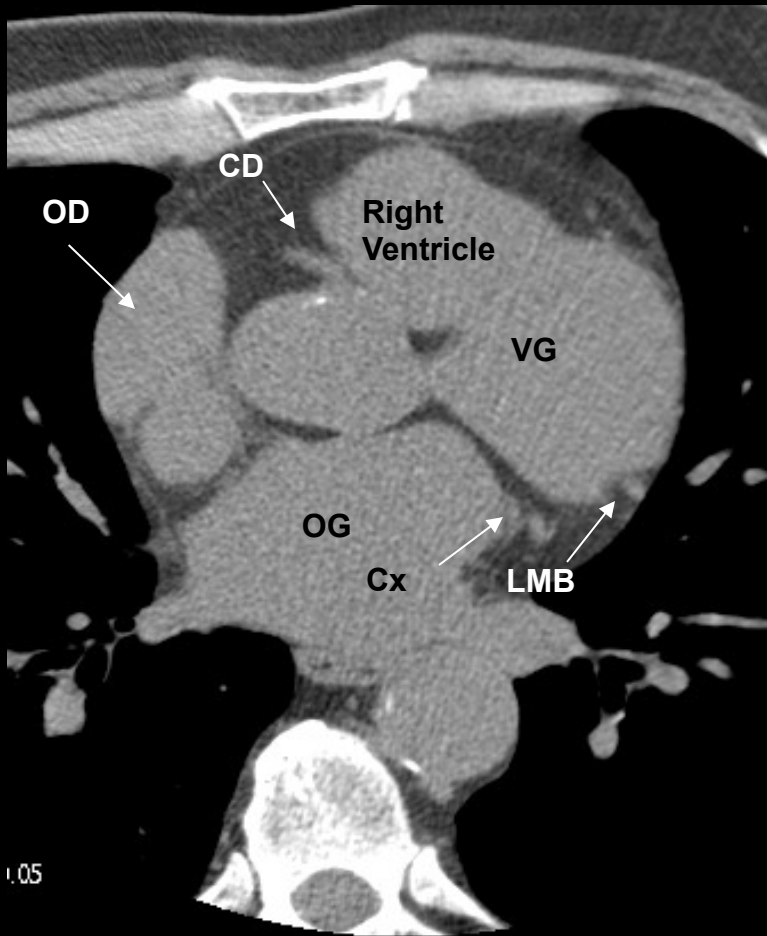
- **VAISSEAUX**
- **CŒUR**
- **ŒSOPHAGE**
- **CHAINES GANGLIONNAIRES**

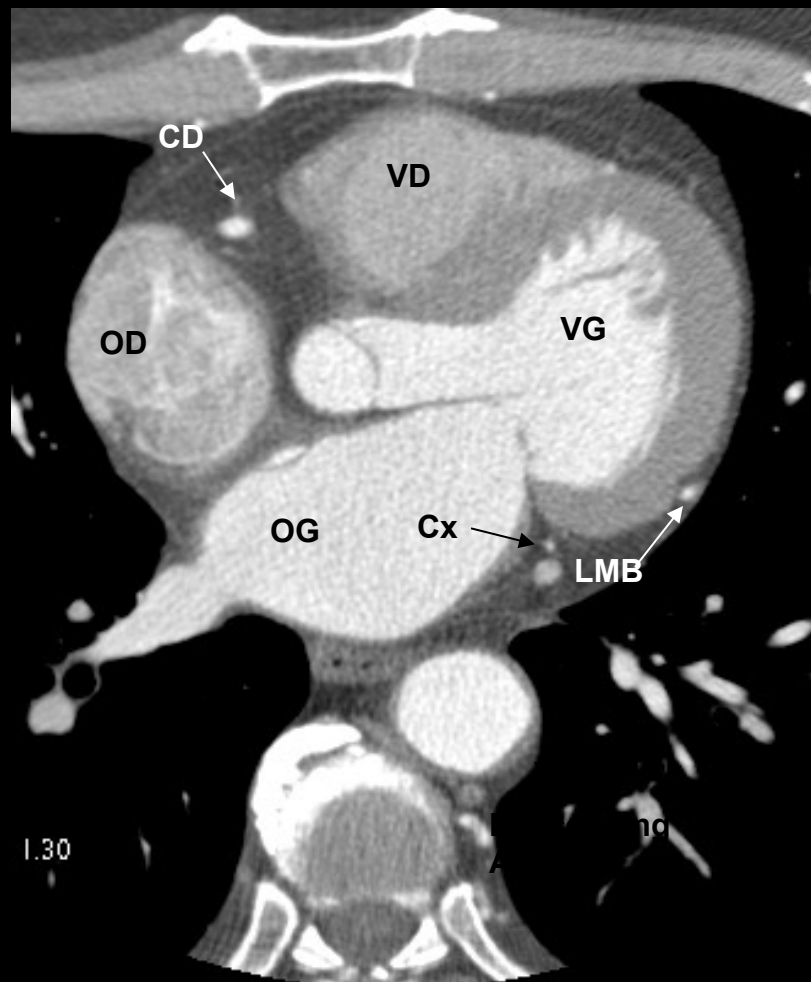
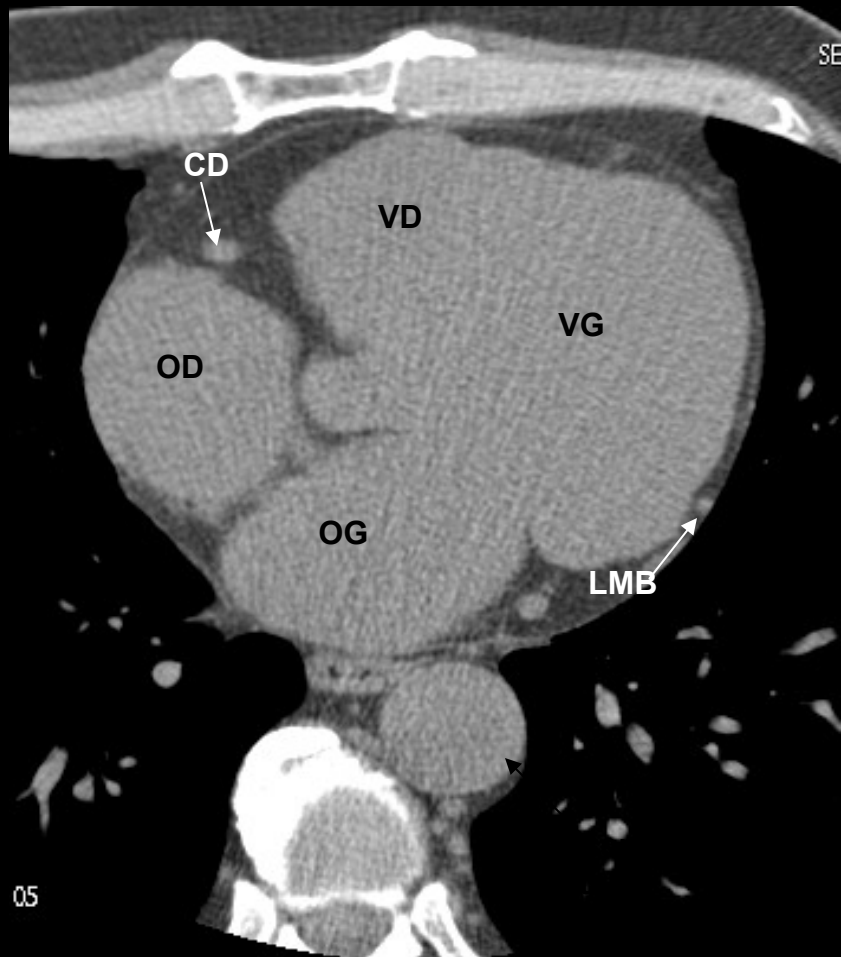


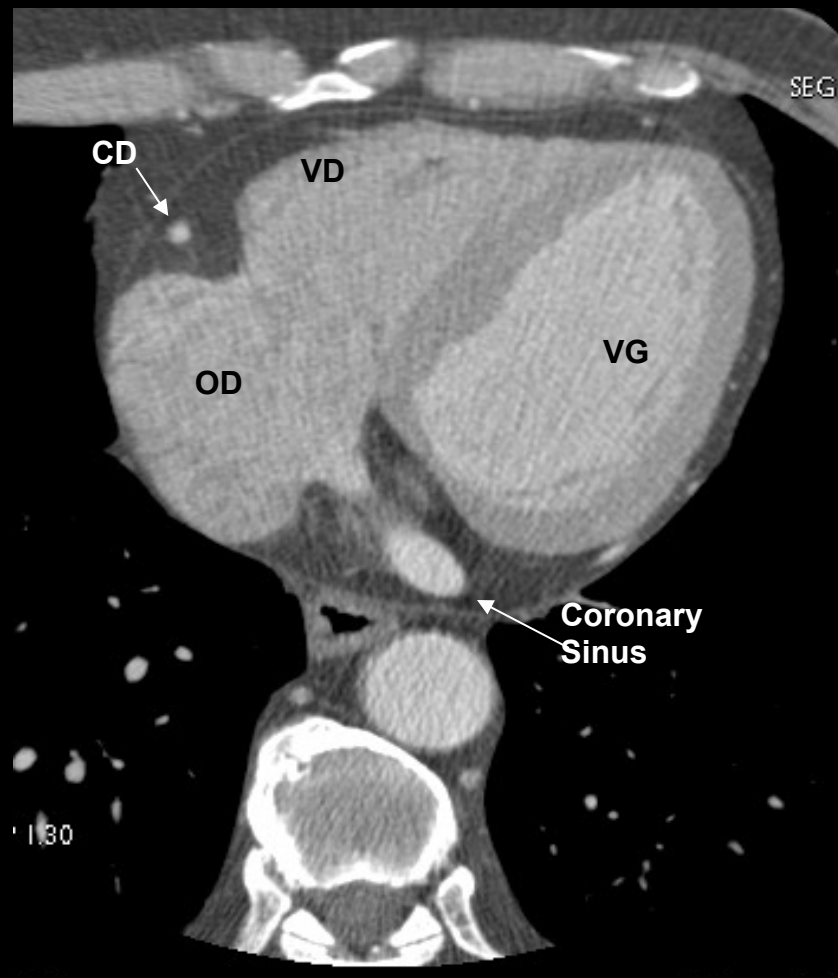
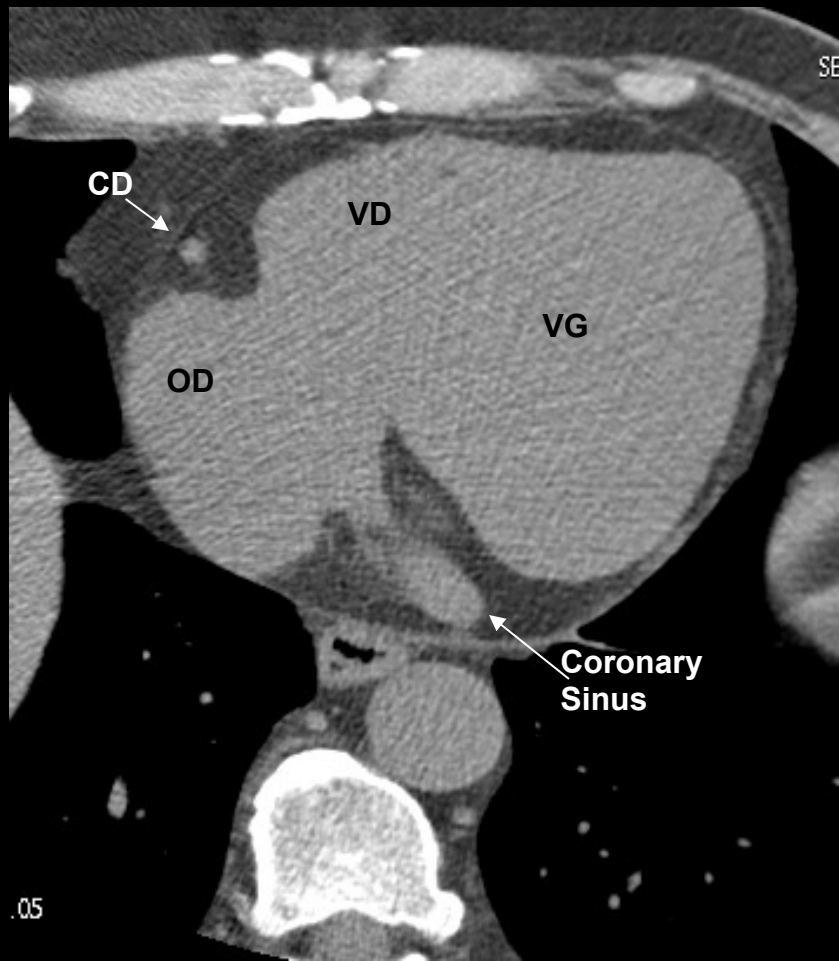
LMA - Left Main Artery (tronc commun)
LAD - Left Anterior Descending Artery (inter ventriculaire IVA)
LCX - Left Circumflex Artery (circonflexe)
LMB - Left Obtuse Marginal Branch (branche marginale gauche)
RCA - Right Coronary Artery (coronaire droite)
PDA - Posterior Descending Artery (rétro ventriculaire postérieure)

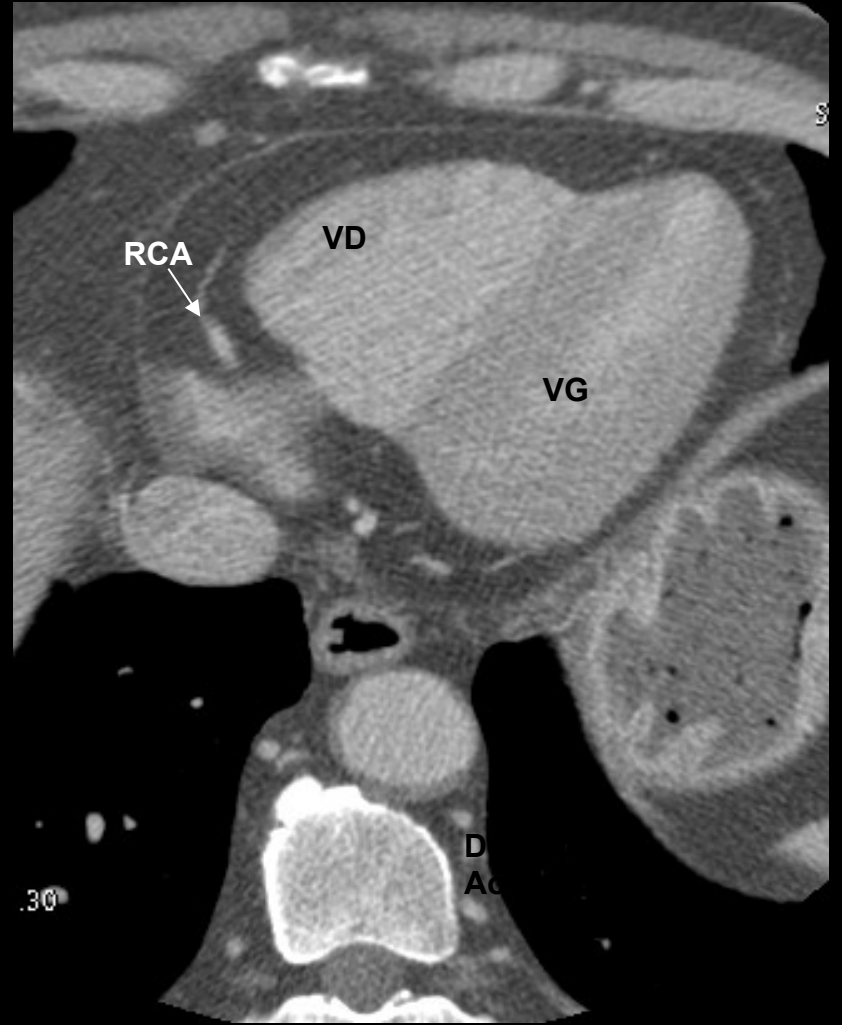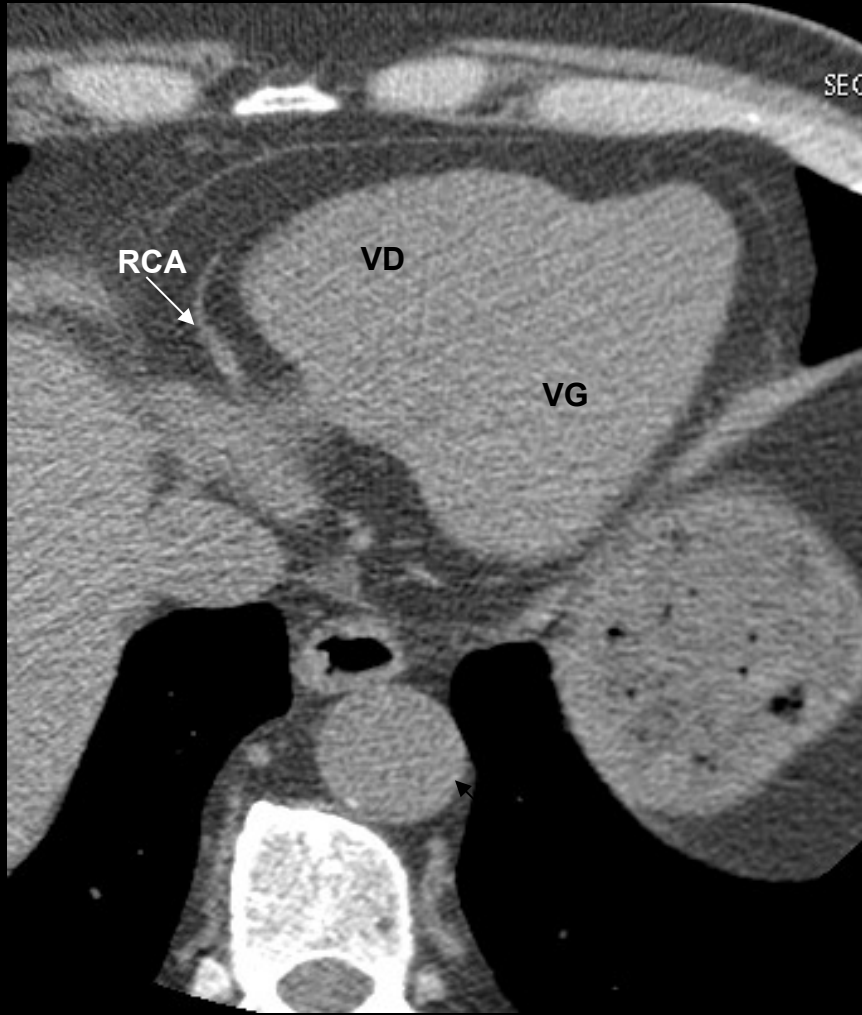


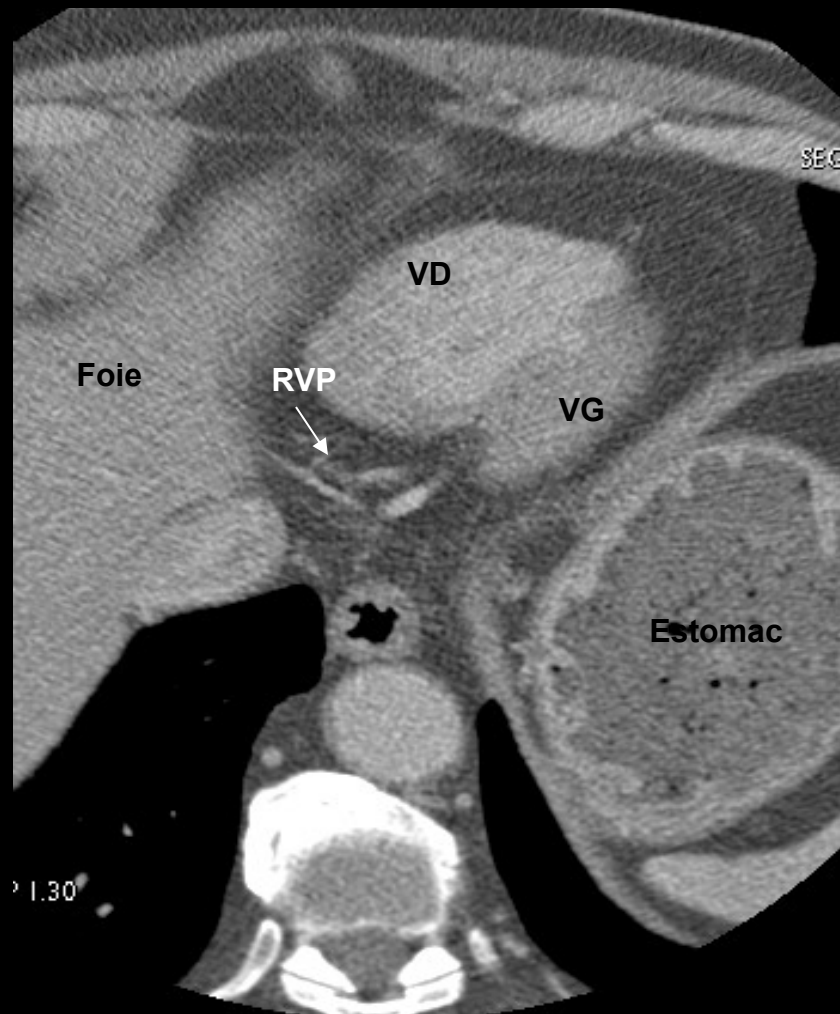

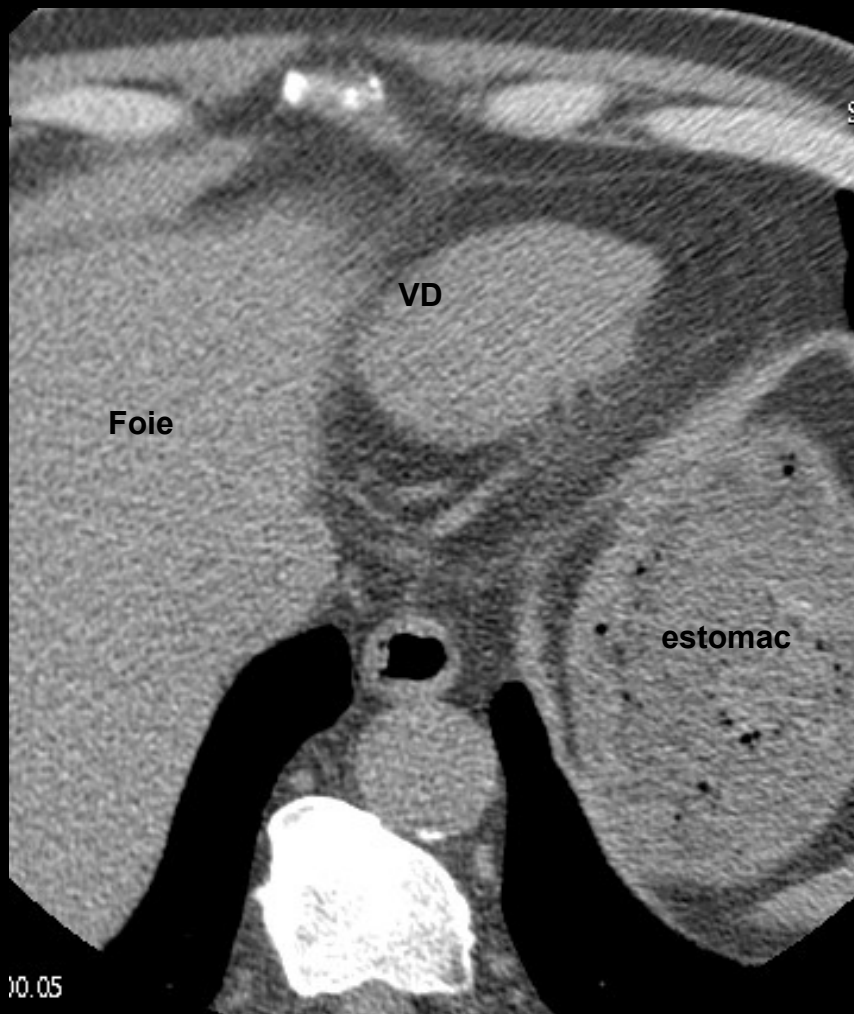


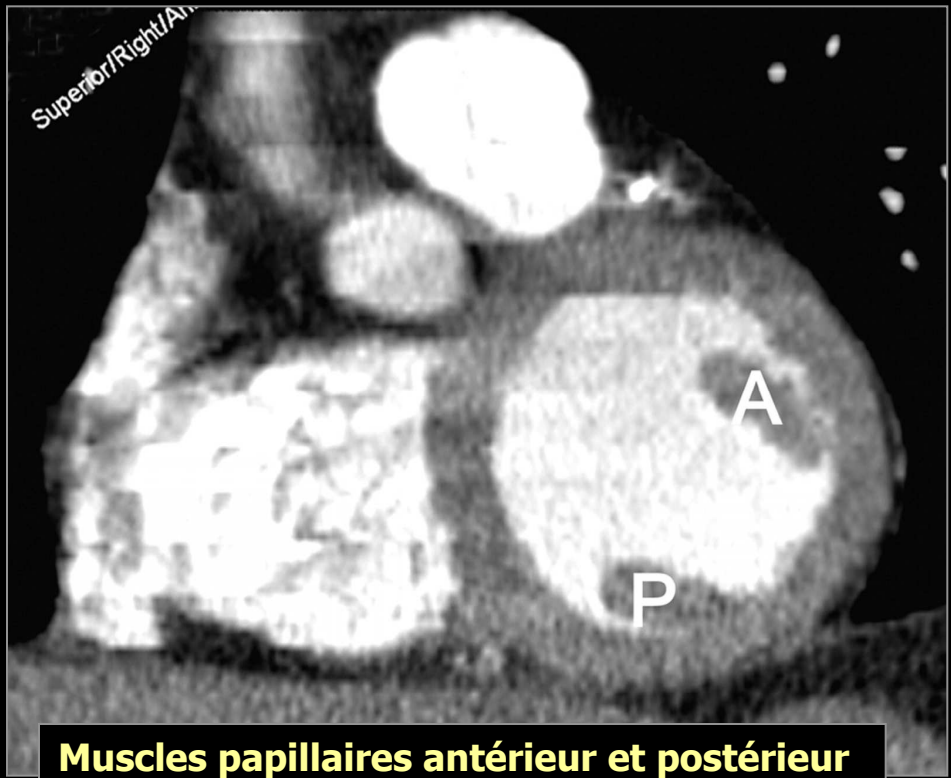


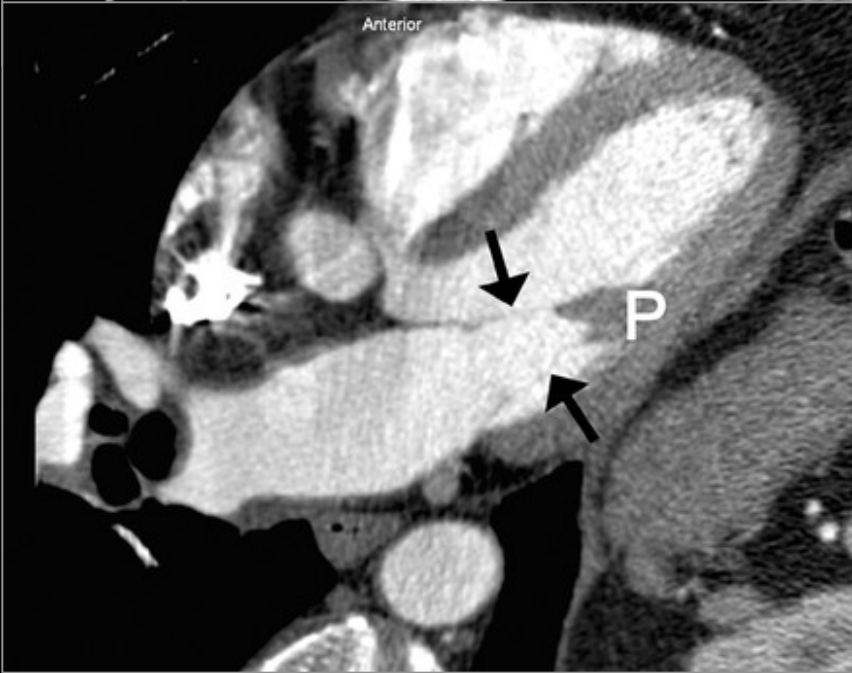
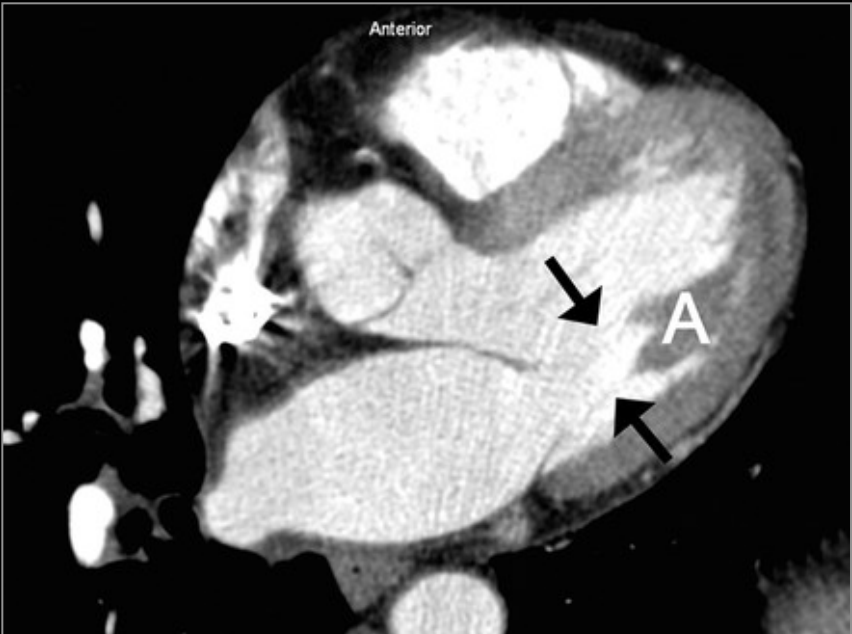




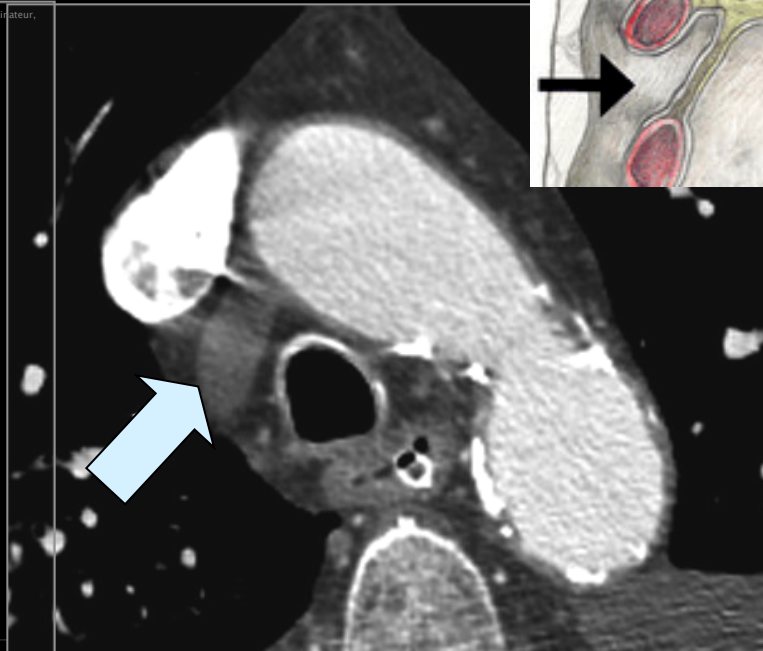
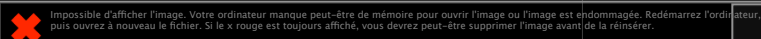
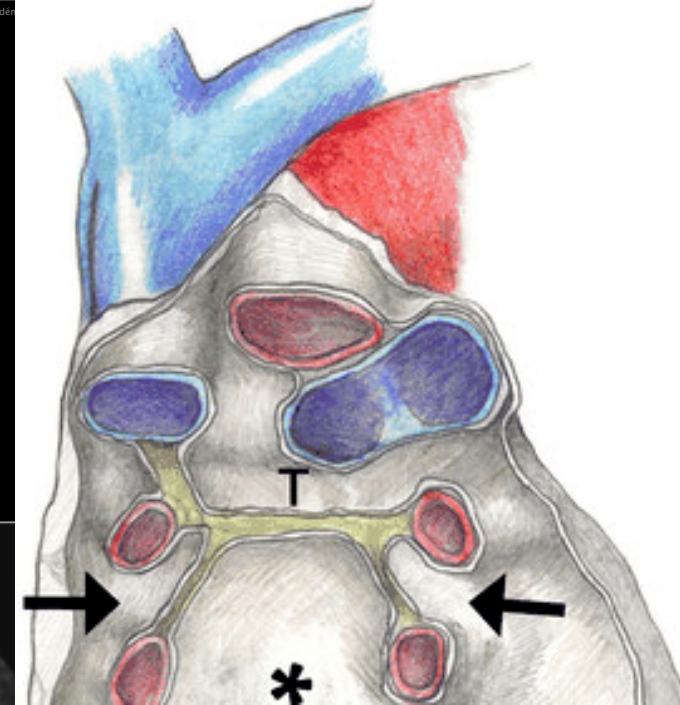

Ventricules



**Muscles papillaires antérieur et postérieur
Et cordages mitraux**

Impossible d'afficher l'image. Votre ordinateur manque peut-être de mémoire pour ouvrir l'image ou l'image est endommagée. Redémarrez l'ordinateur, puis ouvrez à nouveau le fichier. Si le x rouge est toujours affiché, vous devrez peut-être supprimer l'image avant de la réinsérer.

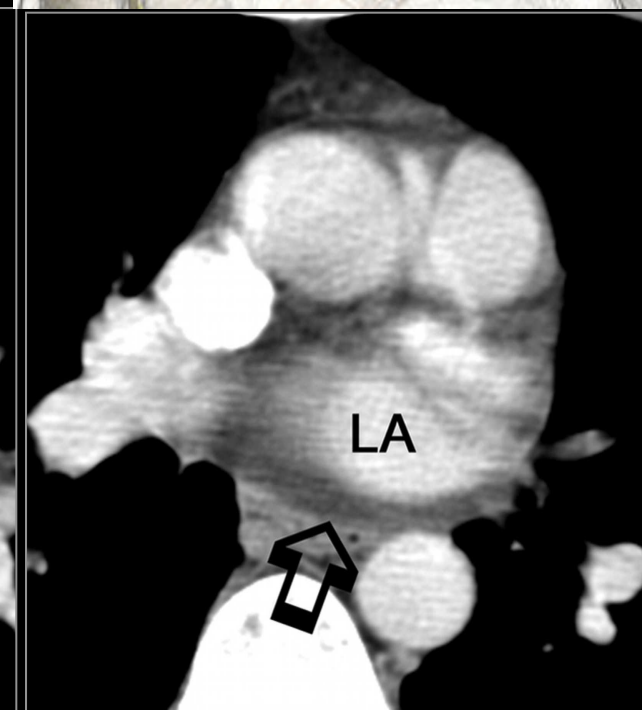
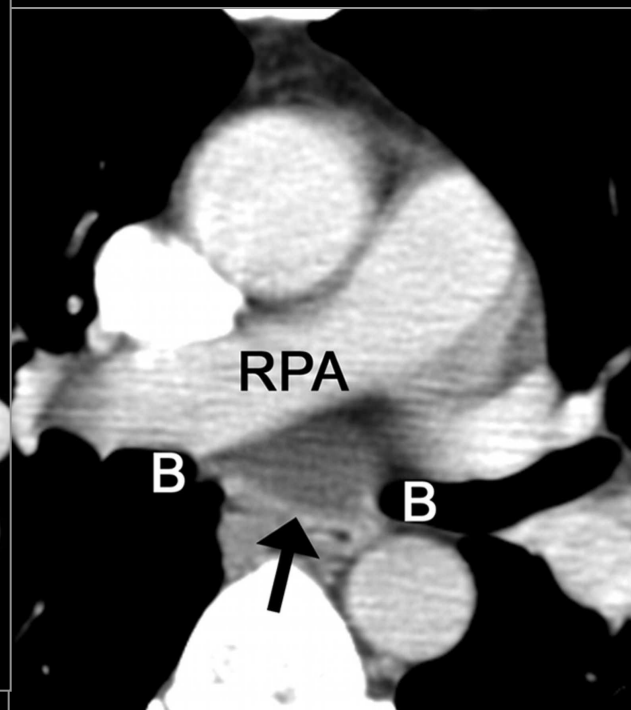
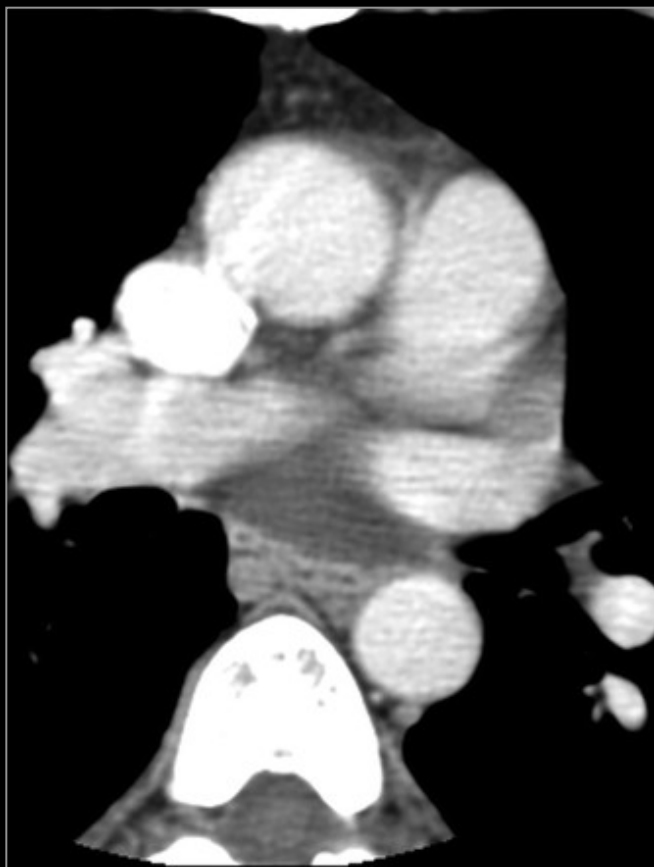
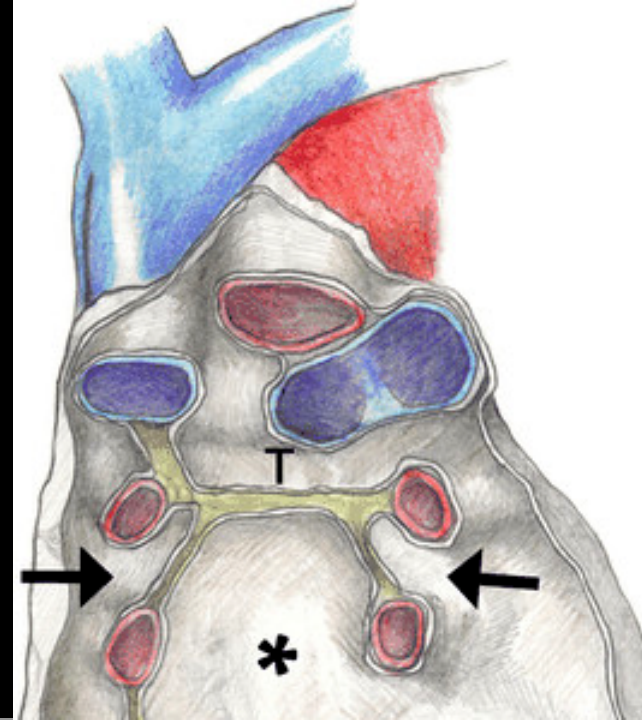
Recessus péricardiques

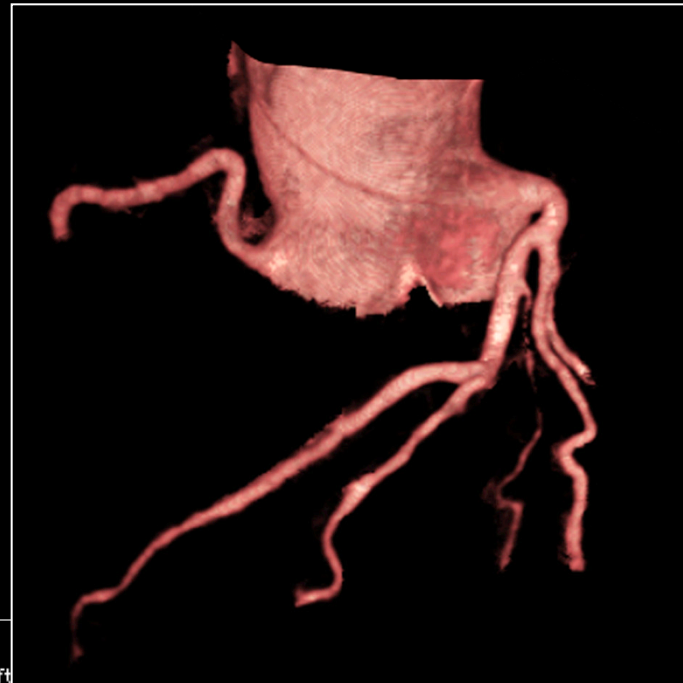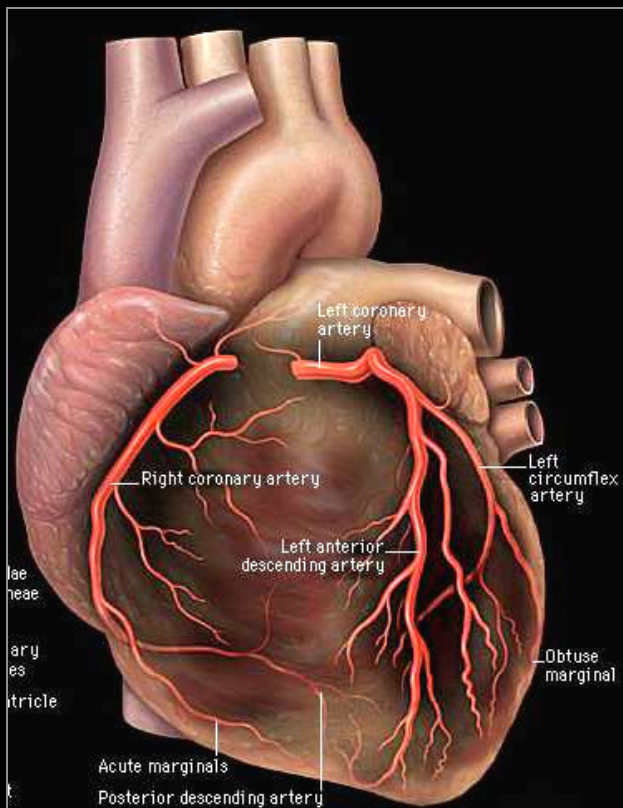


Recessus péricardique aortique supérieur
provient du sinus transverse
s' étend à la face antérieure de l' aorte ascendante avec des portions
antérieure, **postérieure** et latérale droite

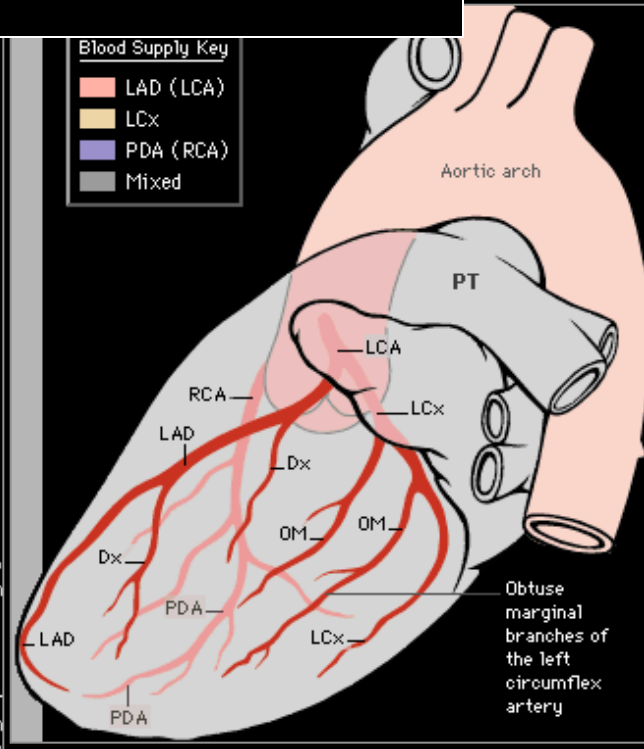
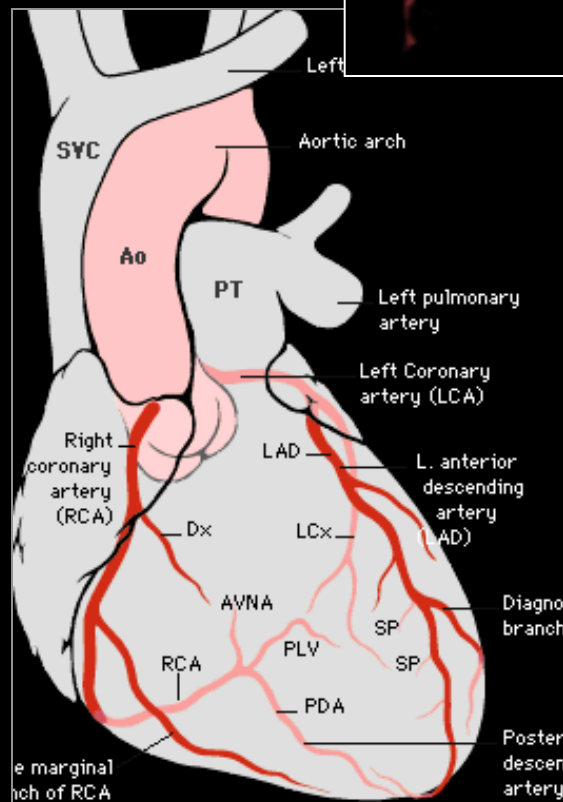
Recessus péricardique postérieur

Extension supérieure du sinus oblique
En arrière de l' AP droite sous carinaire



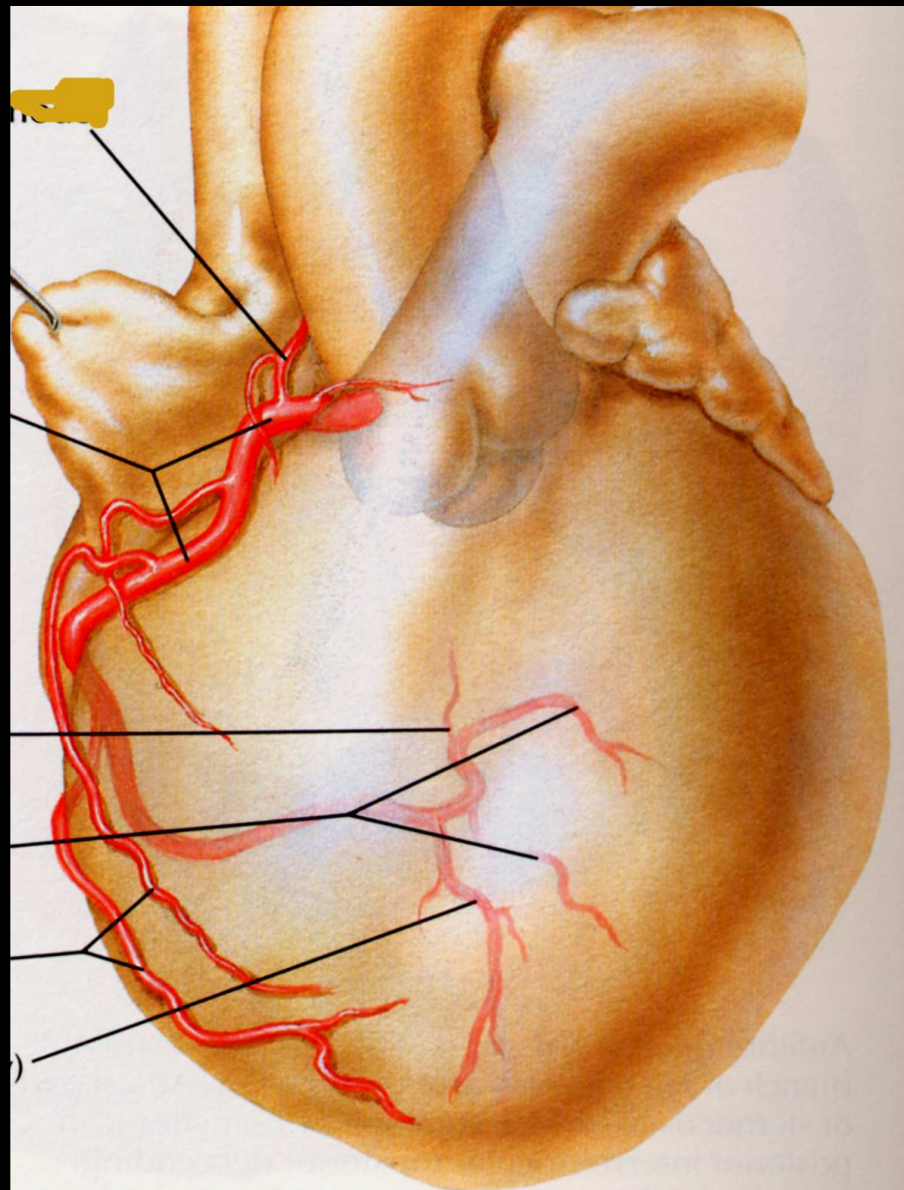
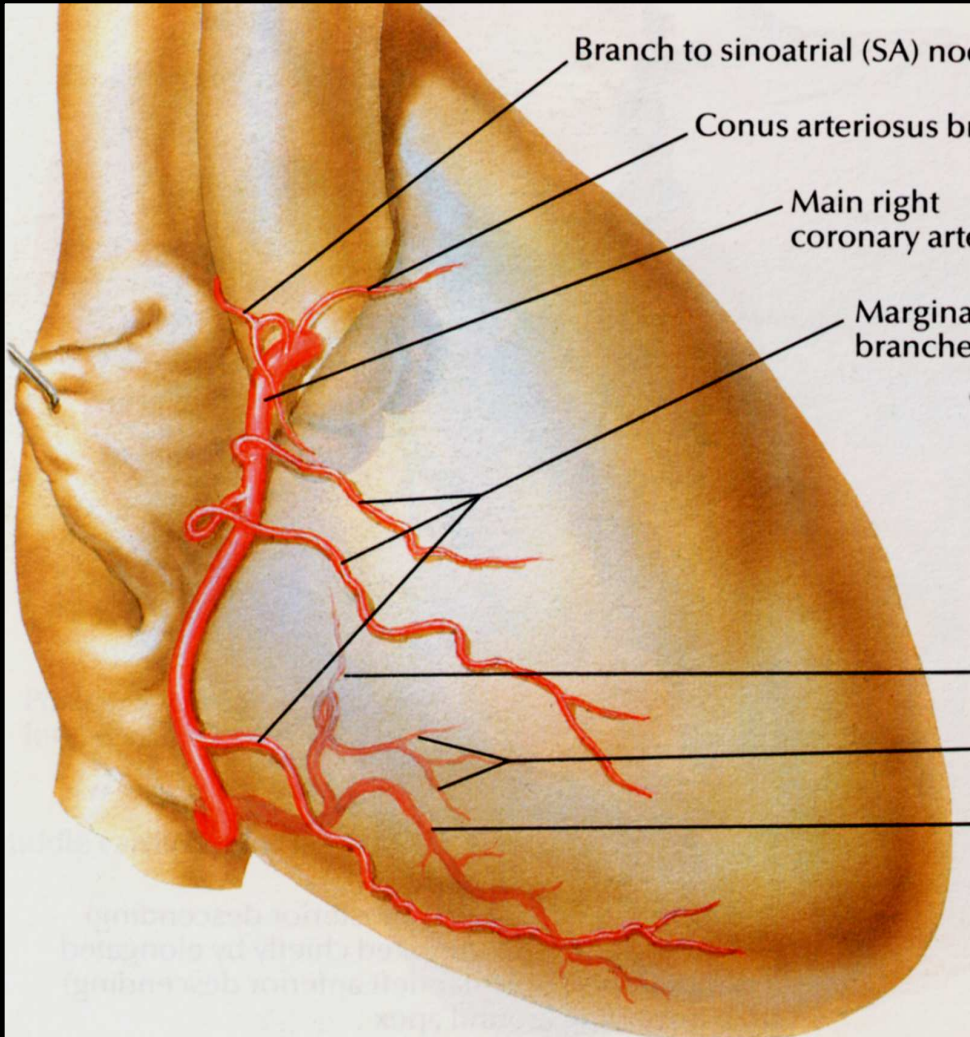


Étude des coronaires



Blood Supply Key

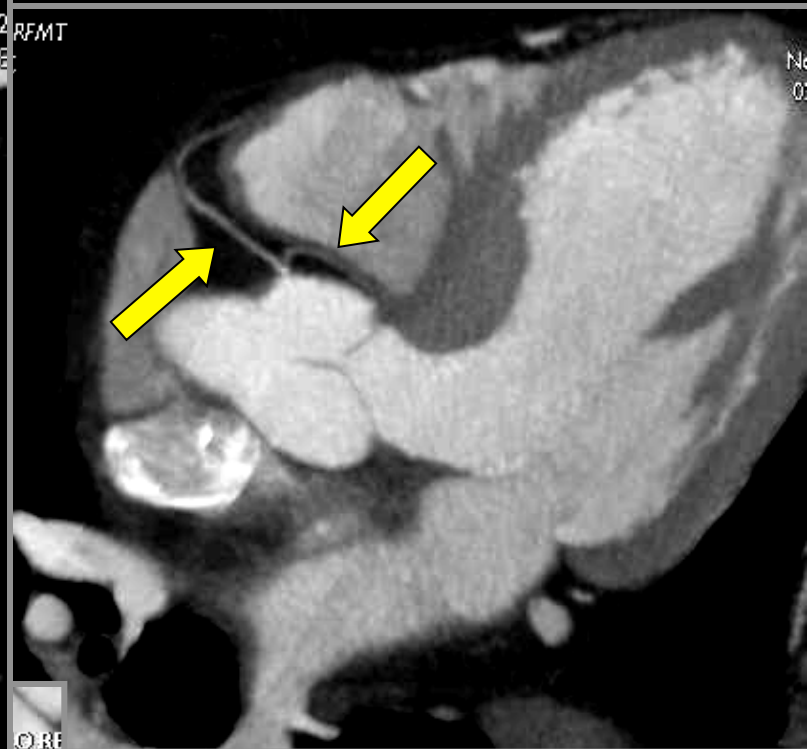
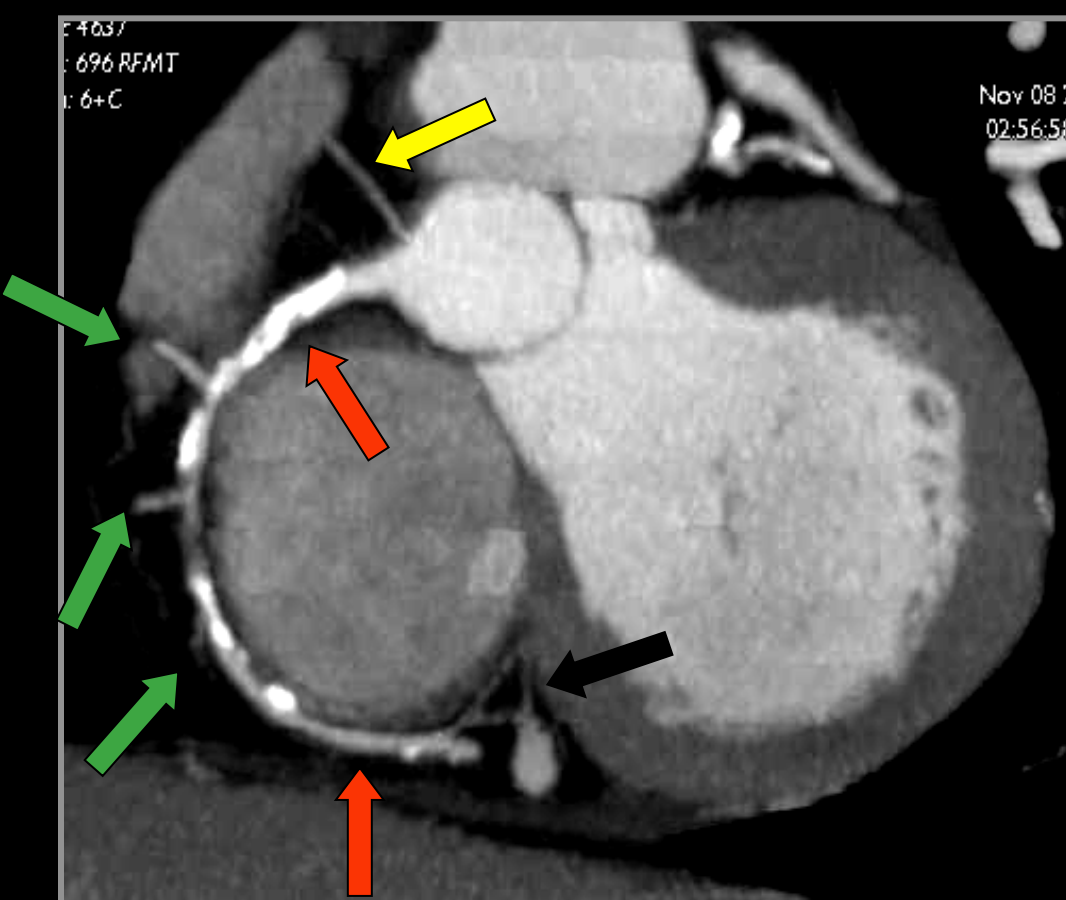
Red	LAD (LCA)
Yellow	LCx
Purple	PDA (RCA)
Grey	Mixed



Coronaire droite

F4037
: 696 RFMT
: 6+C

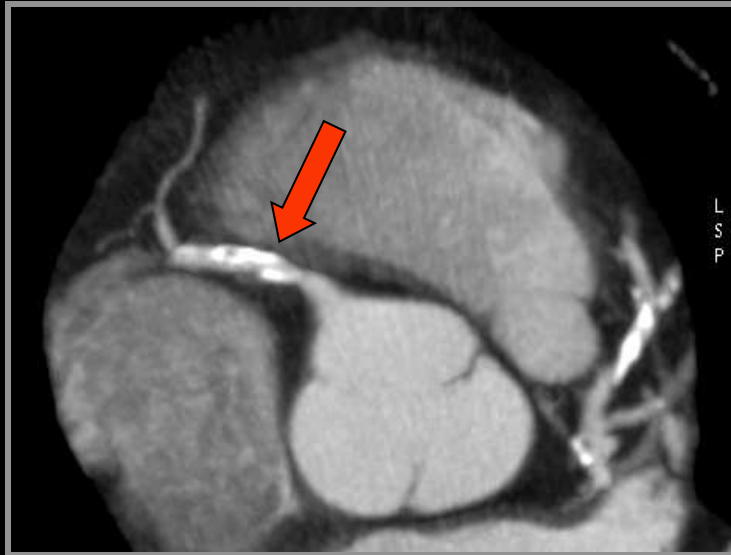
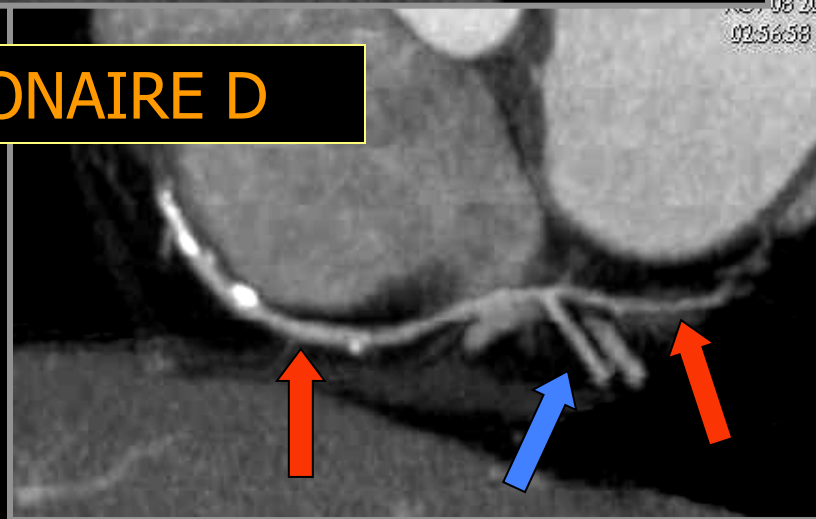
Nov 08 20
02:56:58



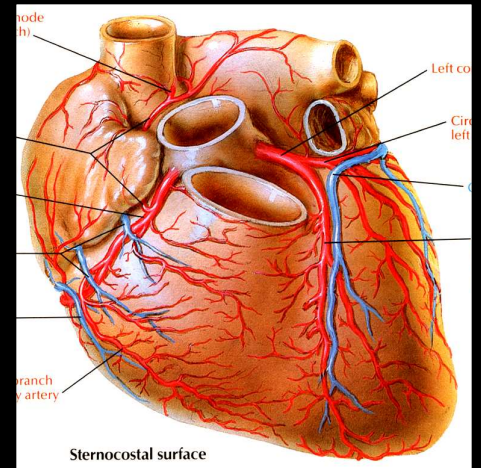
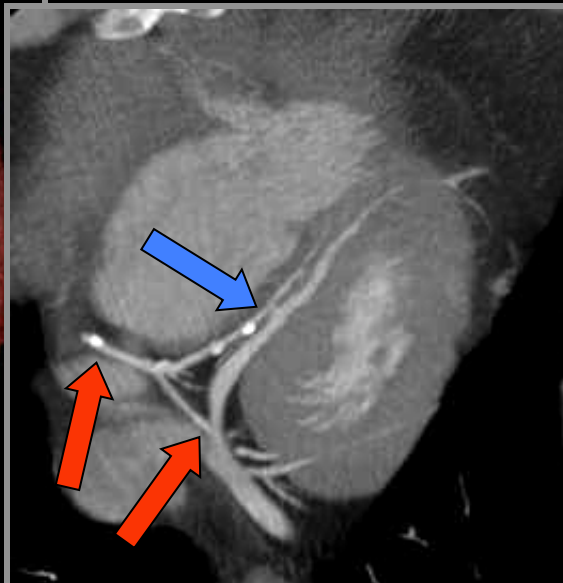
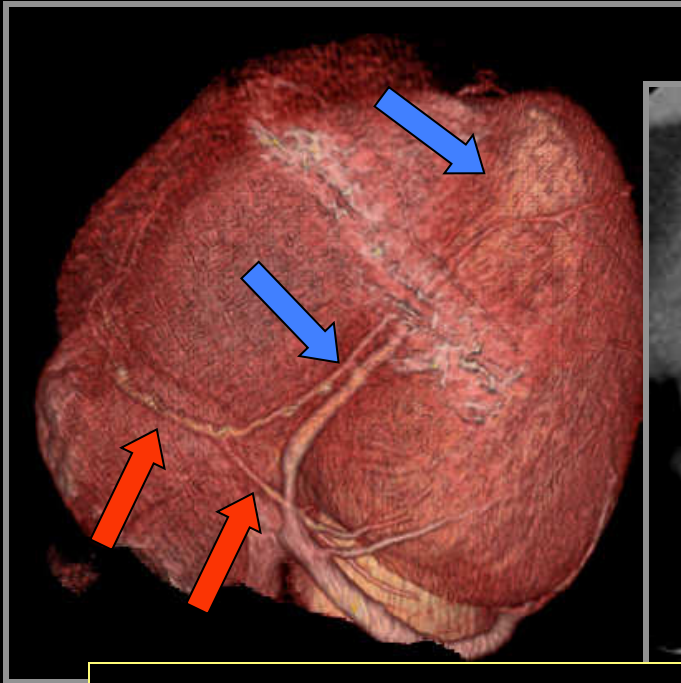
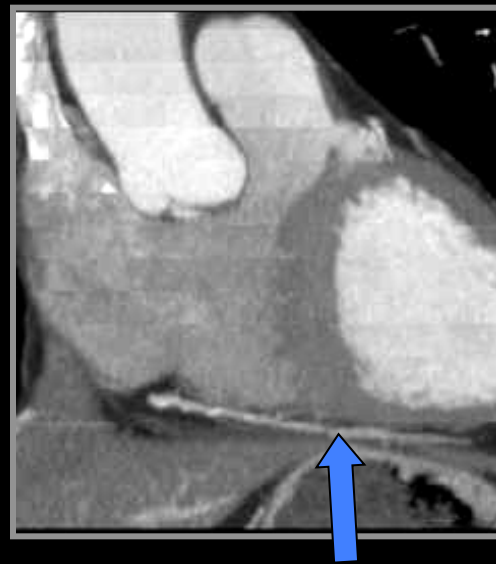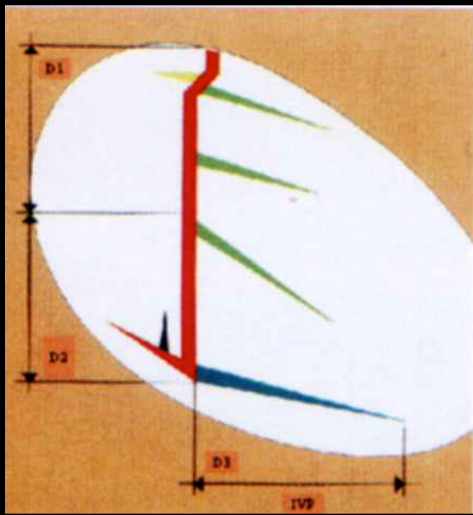
CORE

Nov 08 20
02:56:58

CORONAIRE D

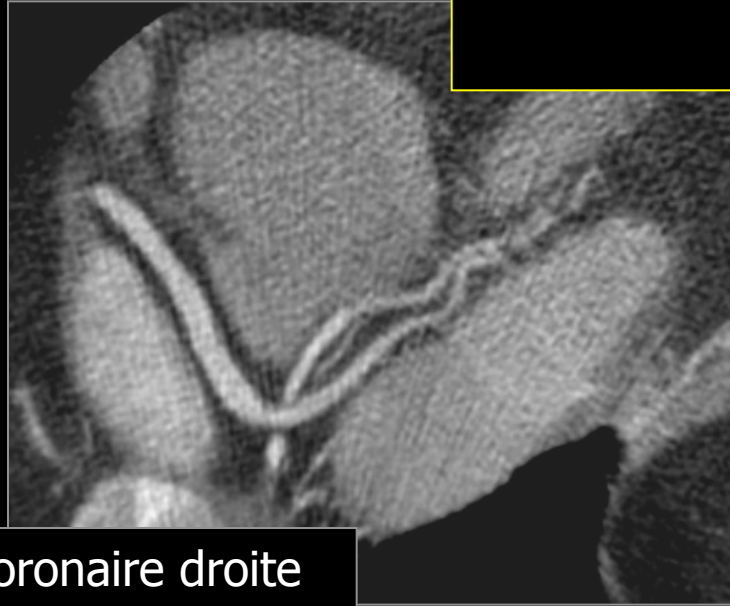
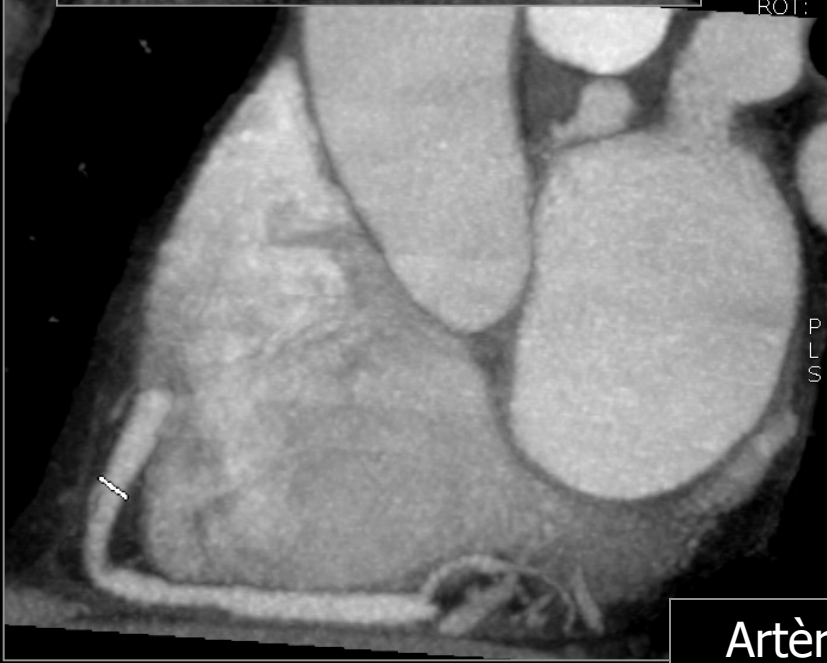
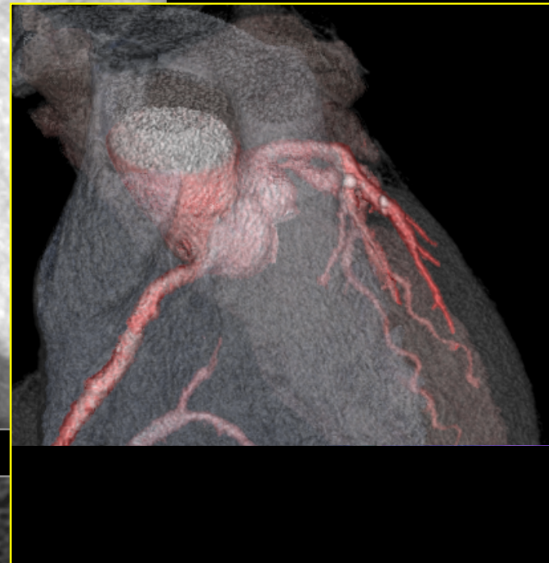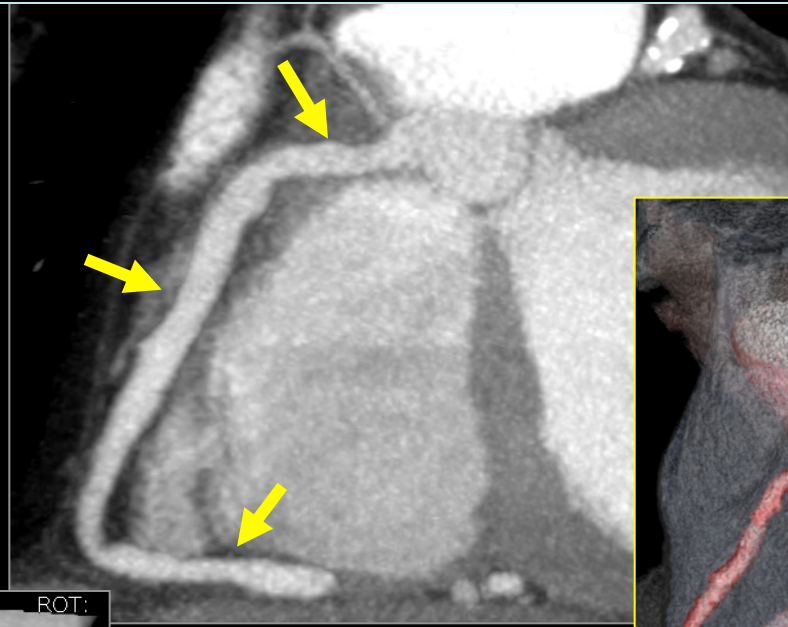

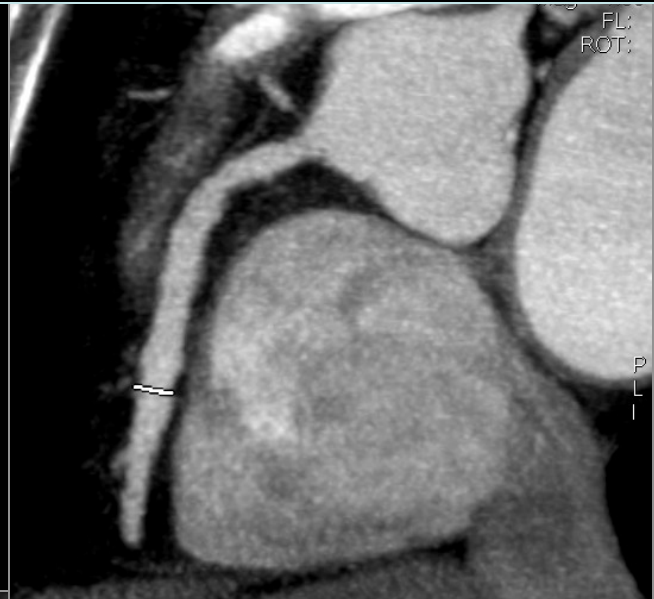
L
S
P

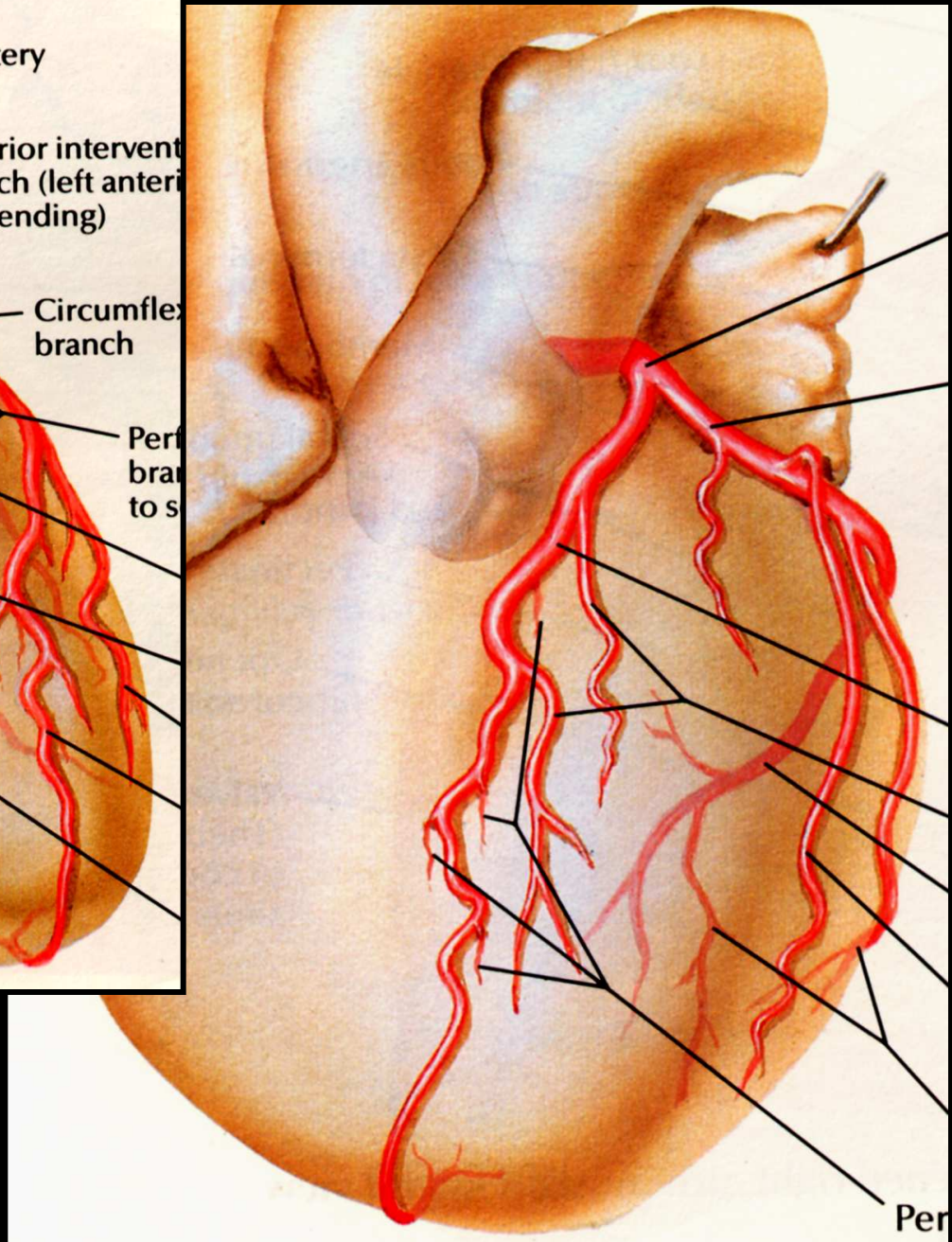
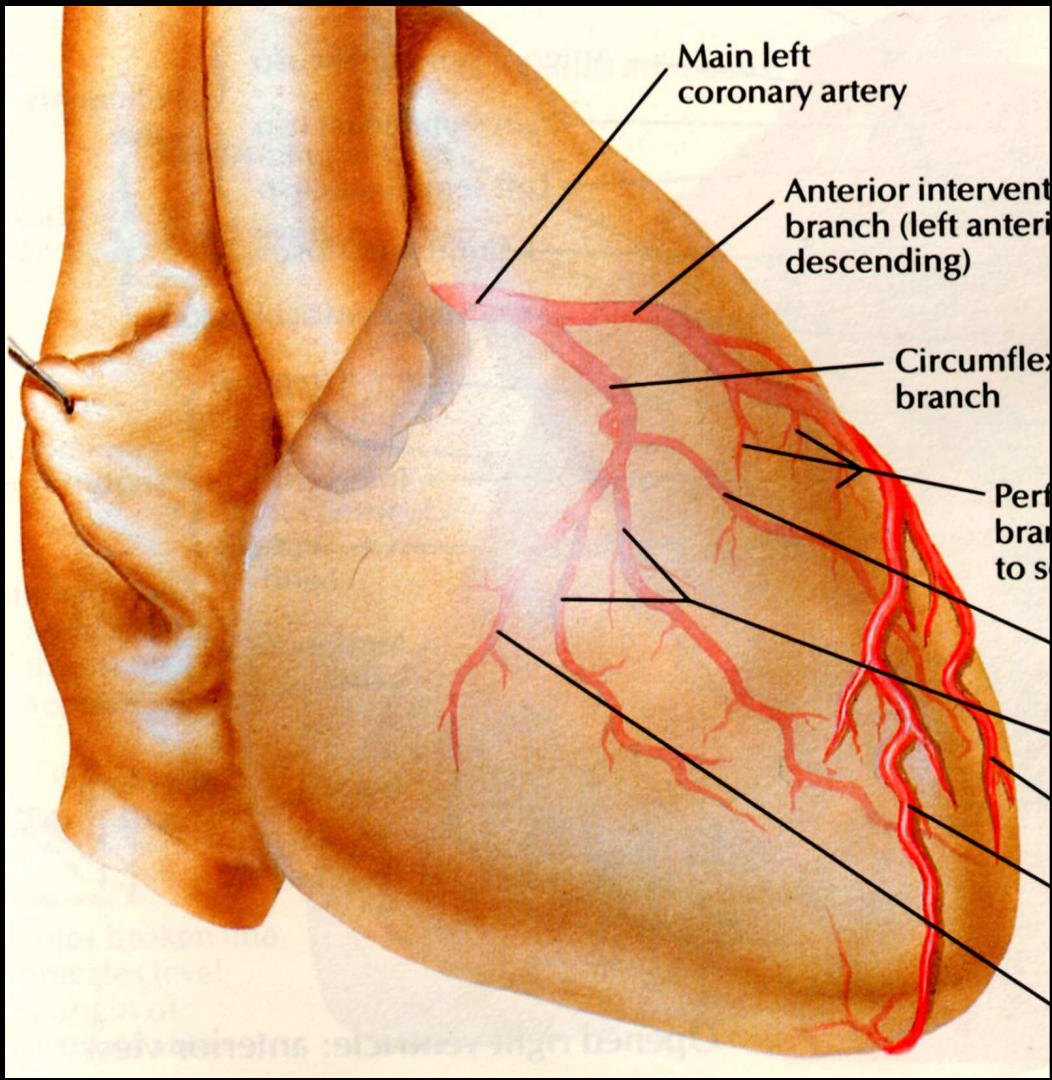


CORONAIRE D
branche rétro et inter ventriculaire postérieure

**Homme de 54 ans, bilan coronarien angiographique non invasif
angor d'effort sans ischémie authentifiée**

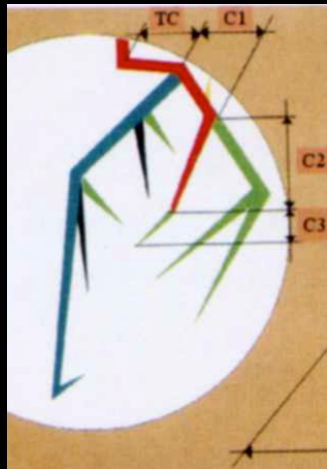
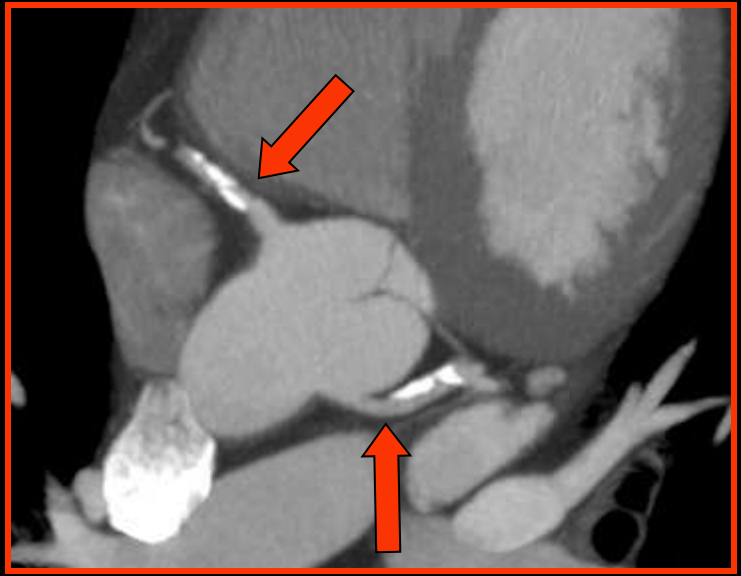
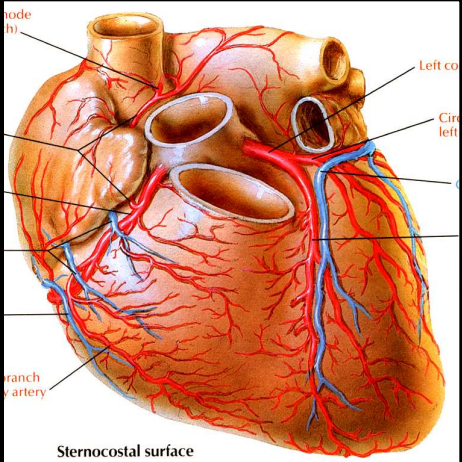
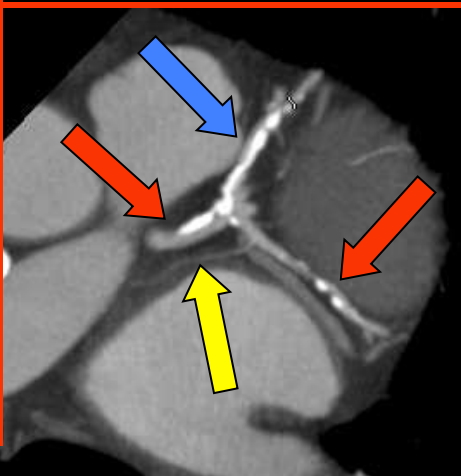
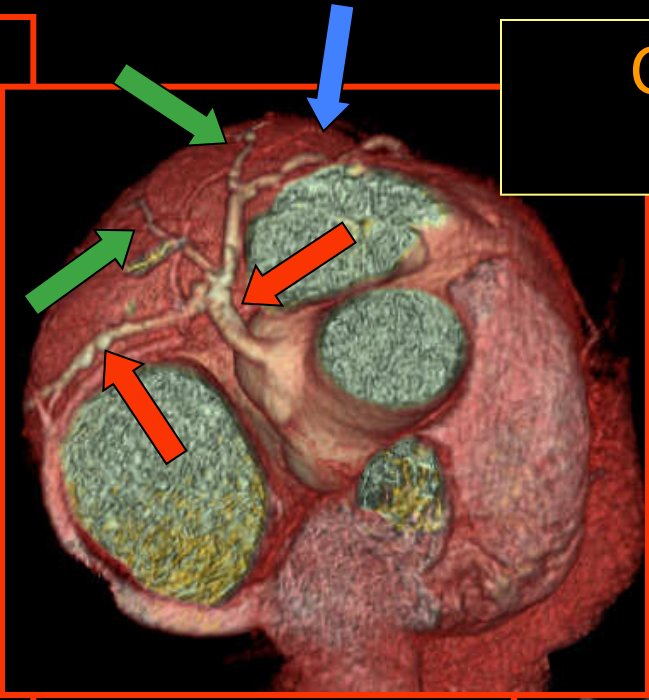
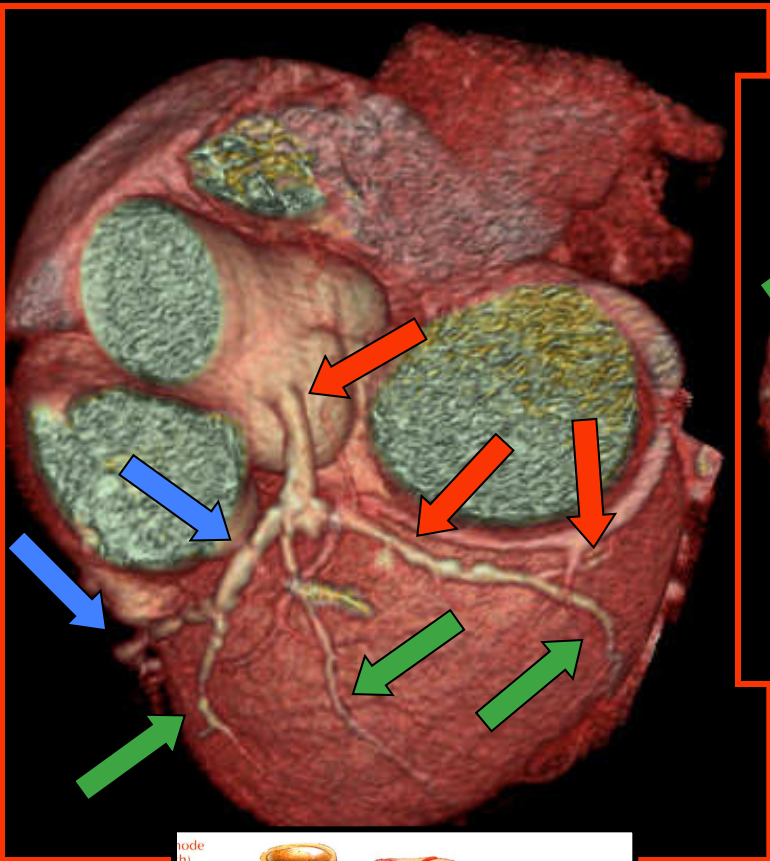


Artère coronaire droite

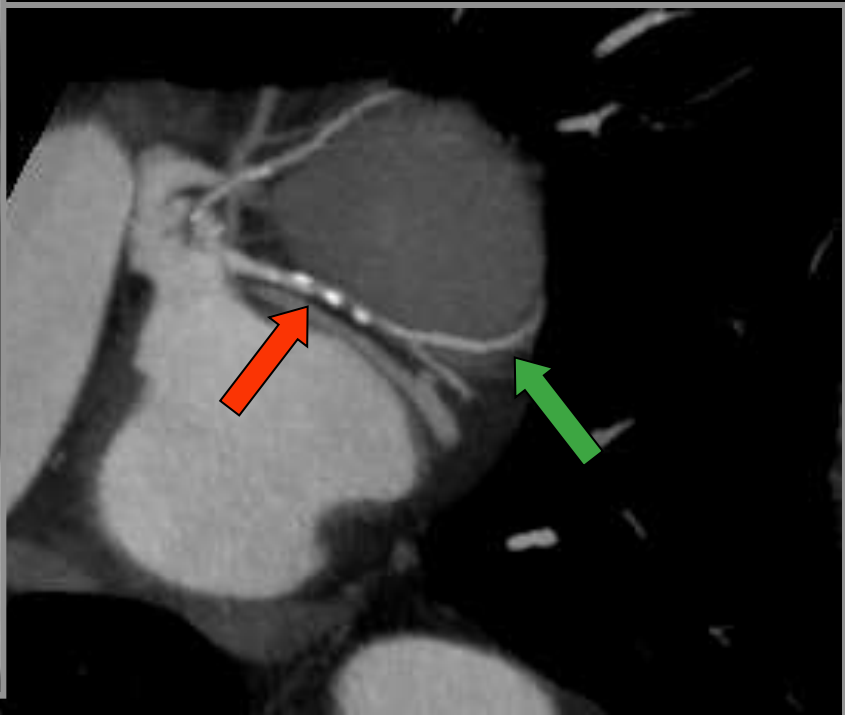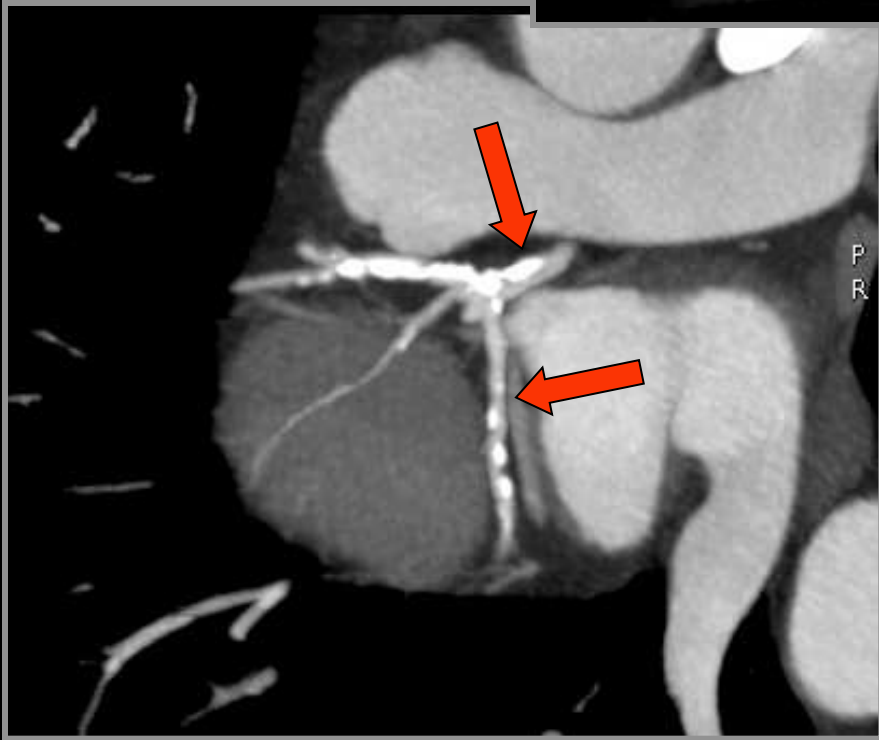
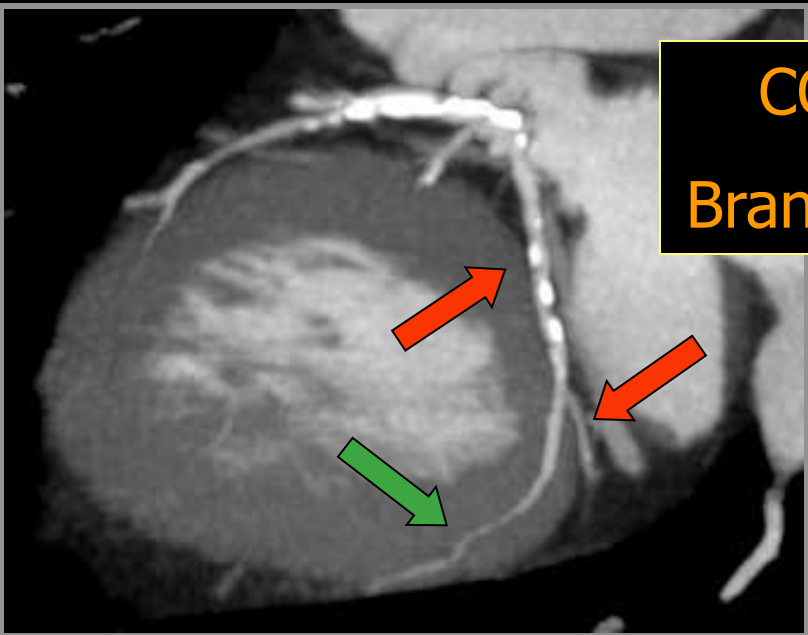


Coronaire gauche

CORONAIRE GAUCHE

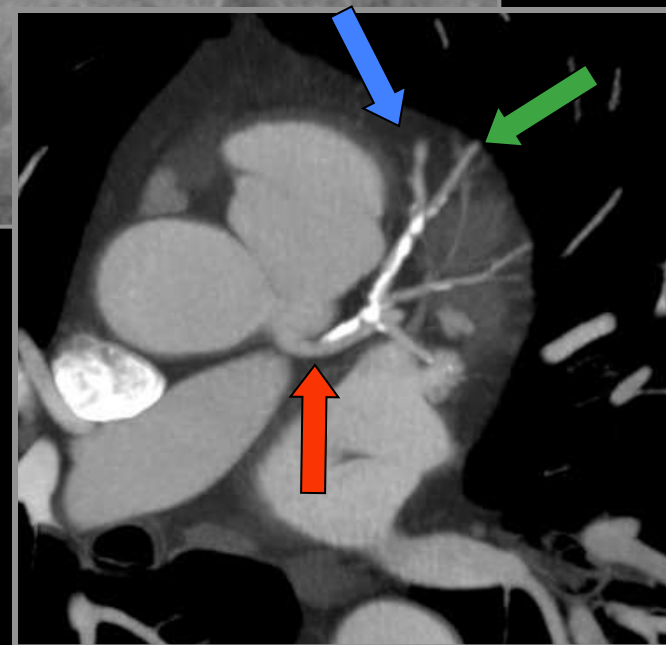
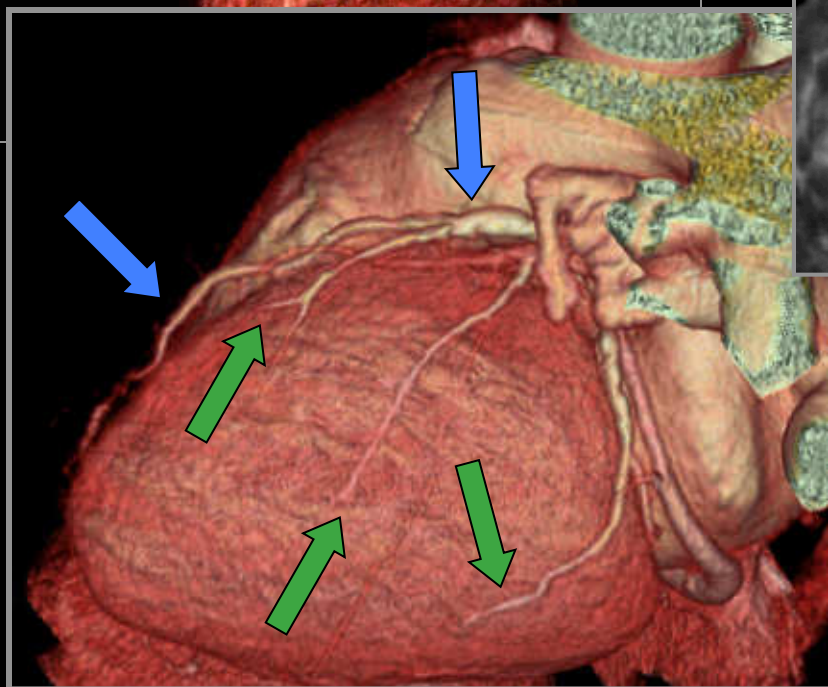
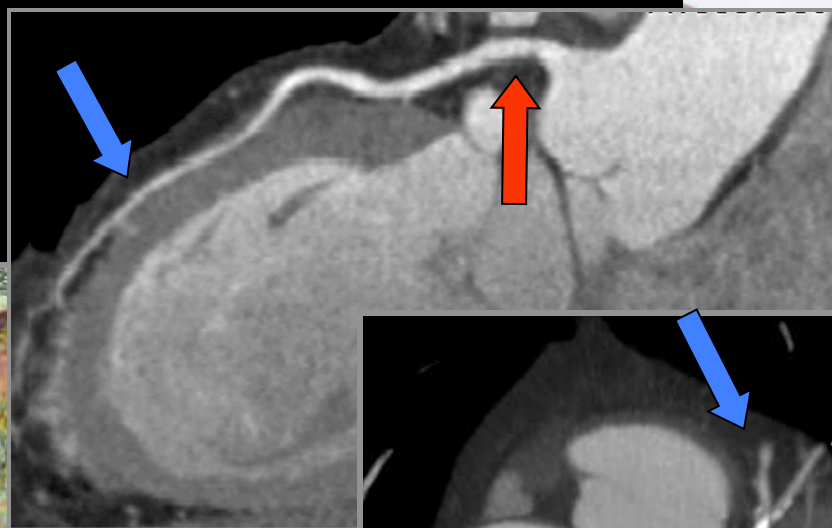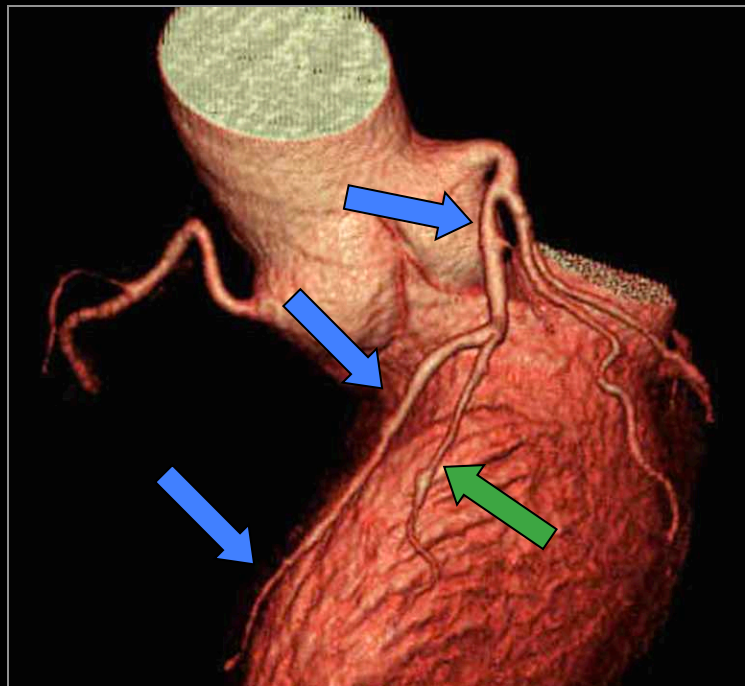
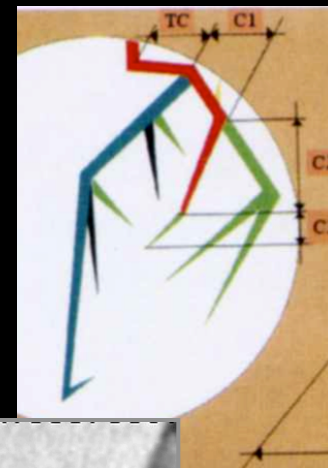


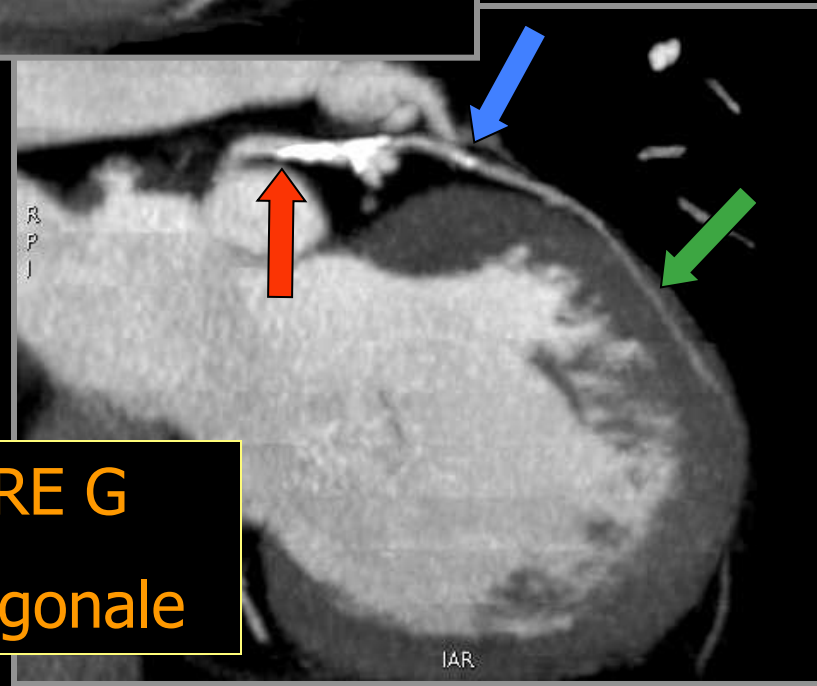
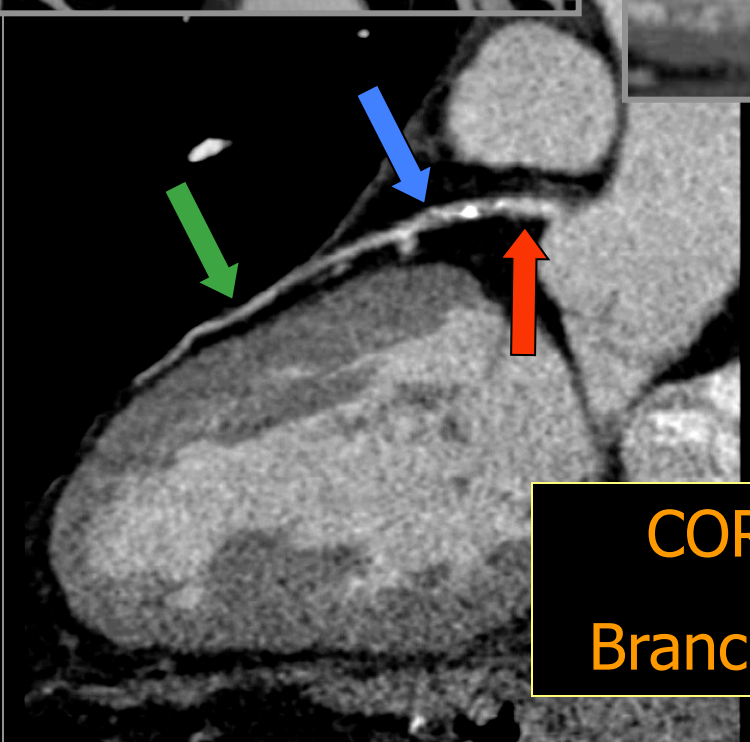
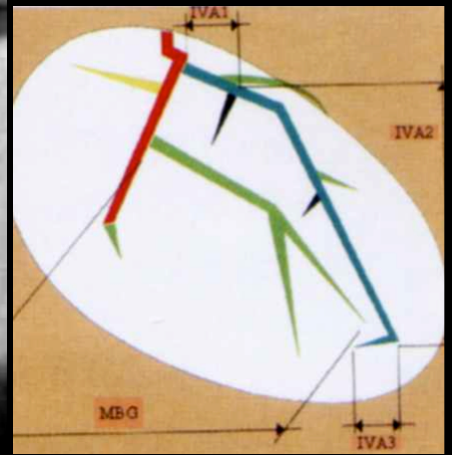
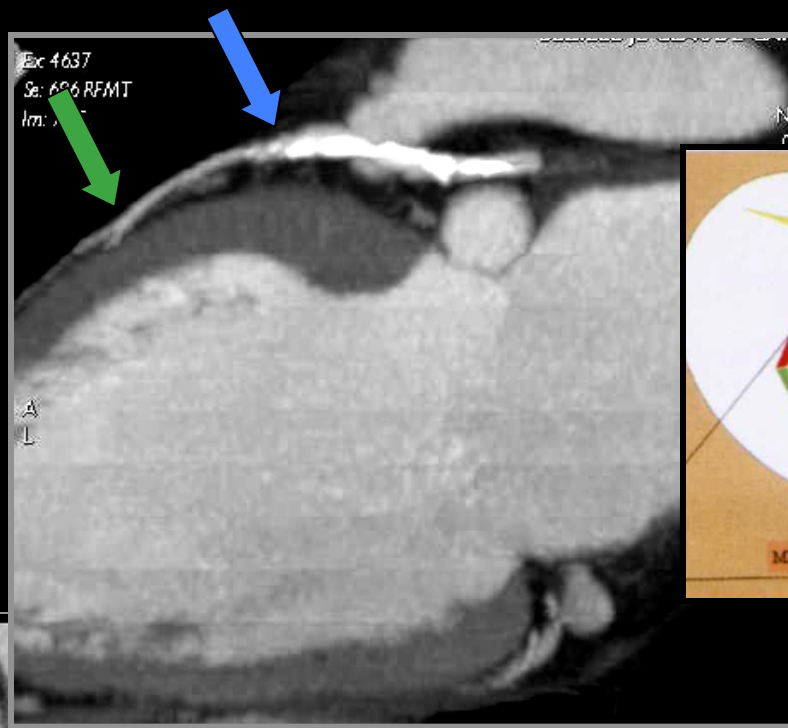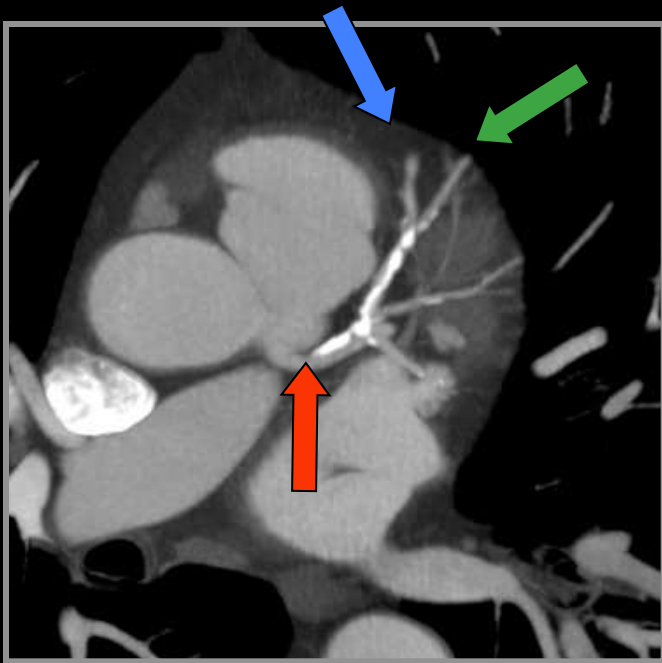
CORONAIRE G
Branche Circonflexe



CORONAIRE G

Branche
interventriculaire
antérieure



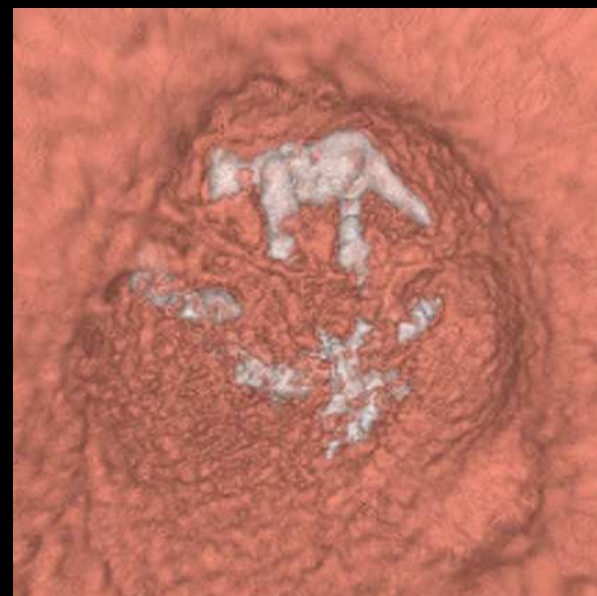
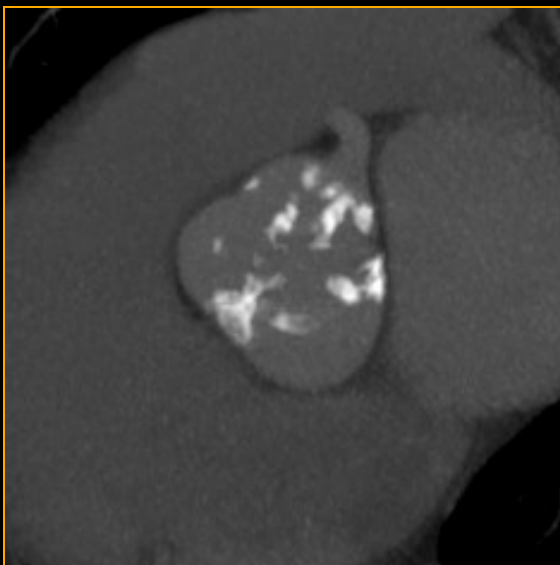
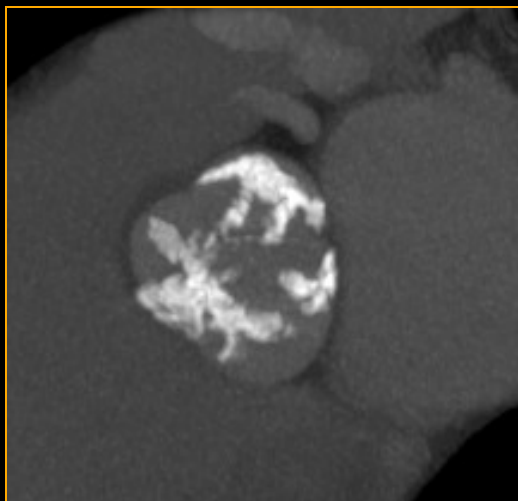
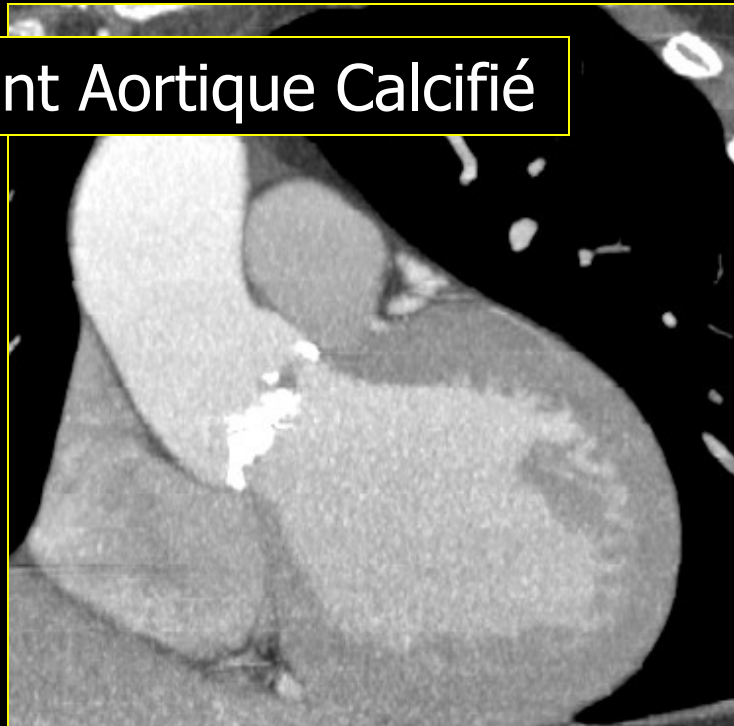
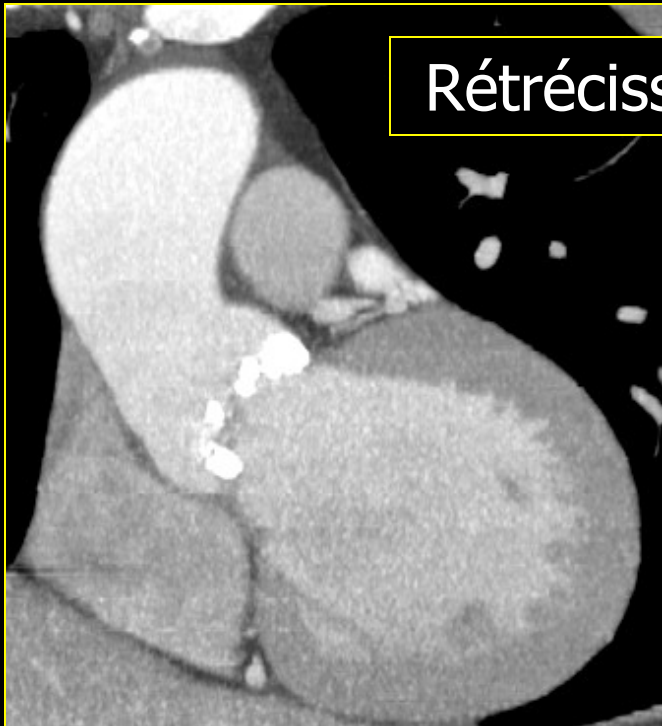

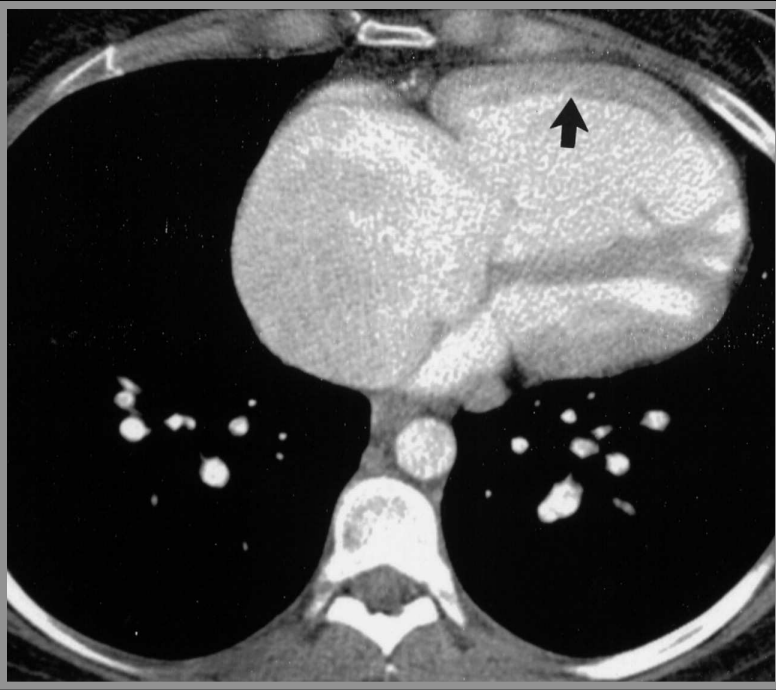
CORONAIRE G
Branche Diagonale



**UN PEU DE PATHOLOGIE ET
VARIATIONS ANATOMIQUES...**

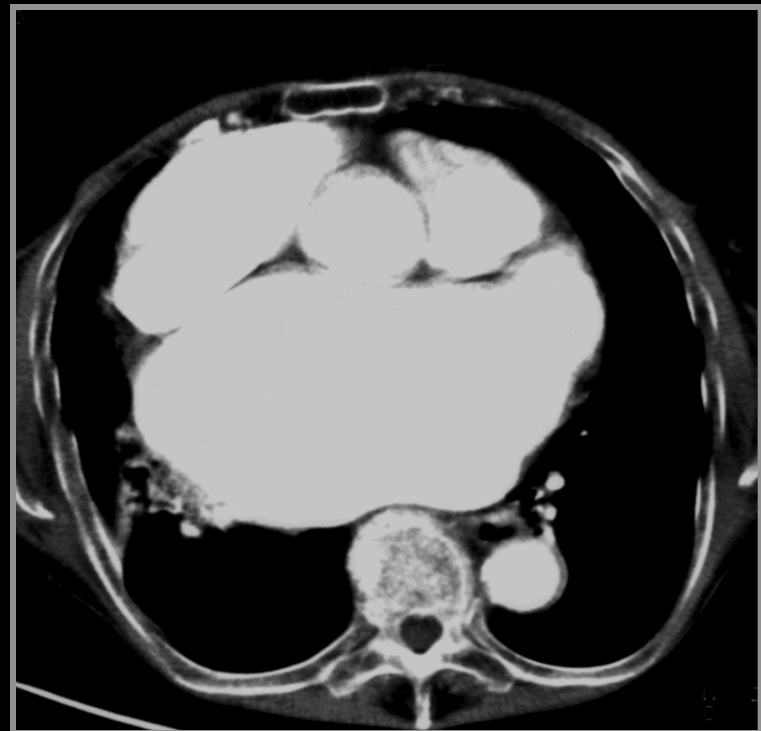Rétrécissement Aortique Calcifié

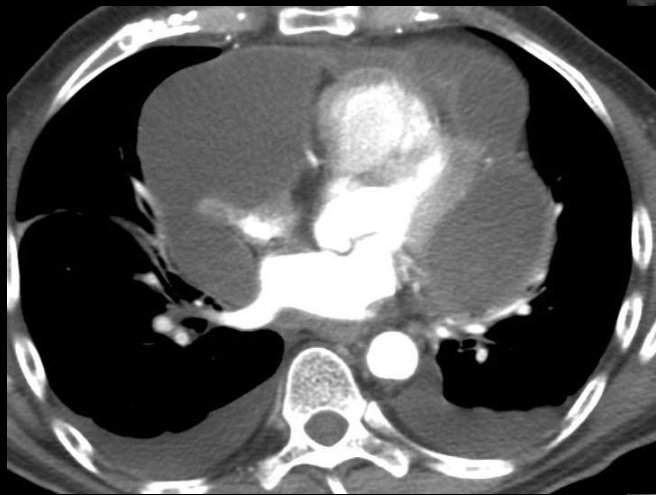




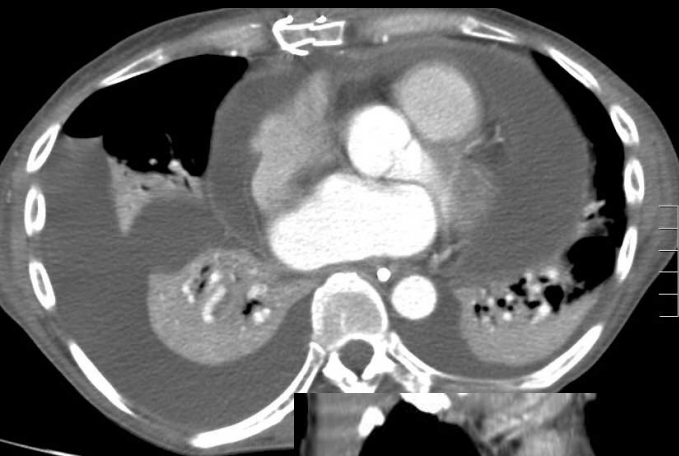
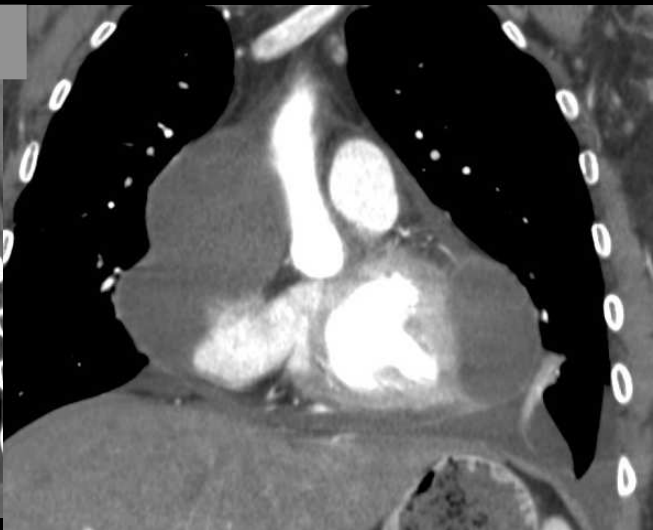
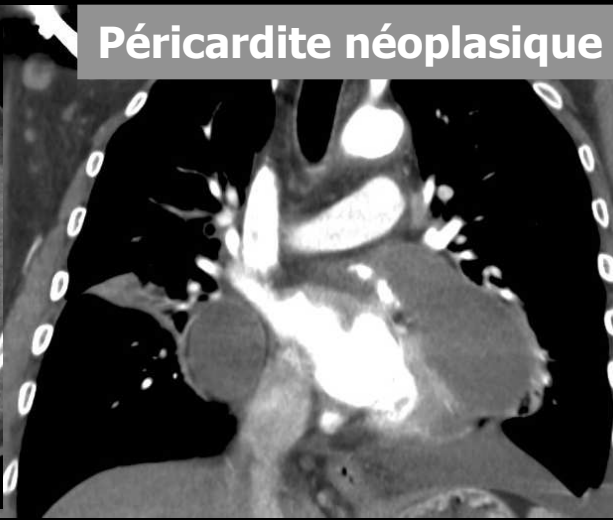
Oreillette droite
HTAP précapillaire
et HVD

Oreillette gauche
Rétrécissement mitral

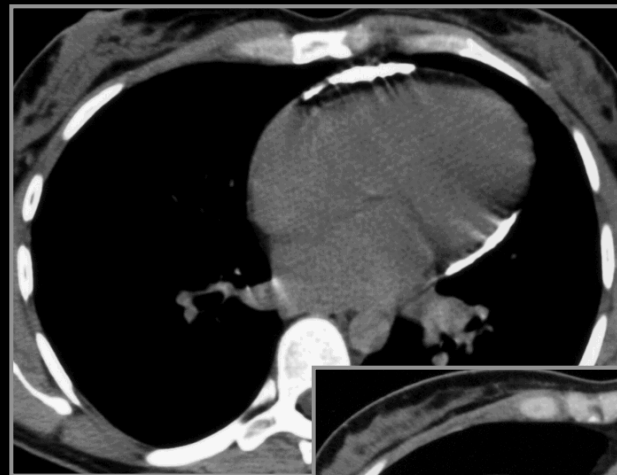
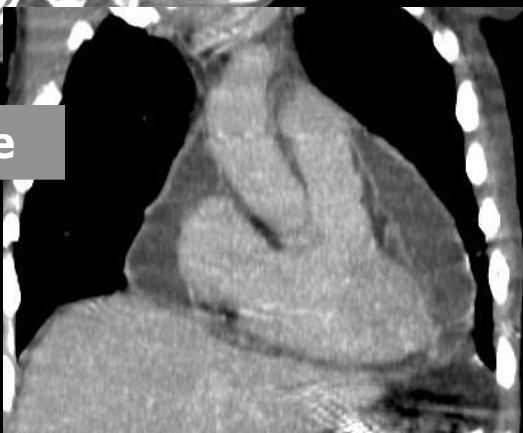




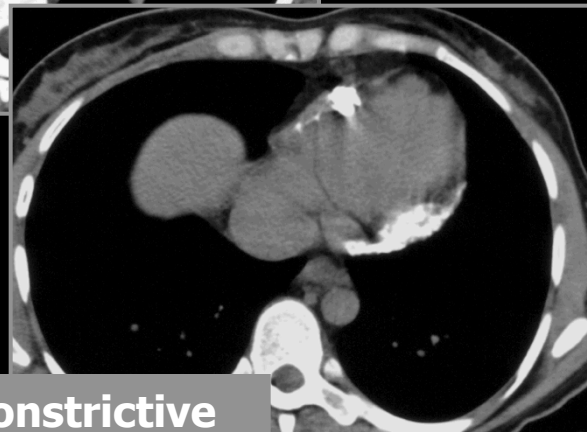Péricardite néoplasique

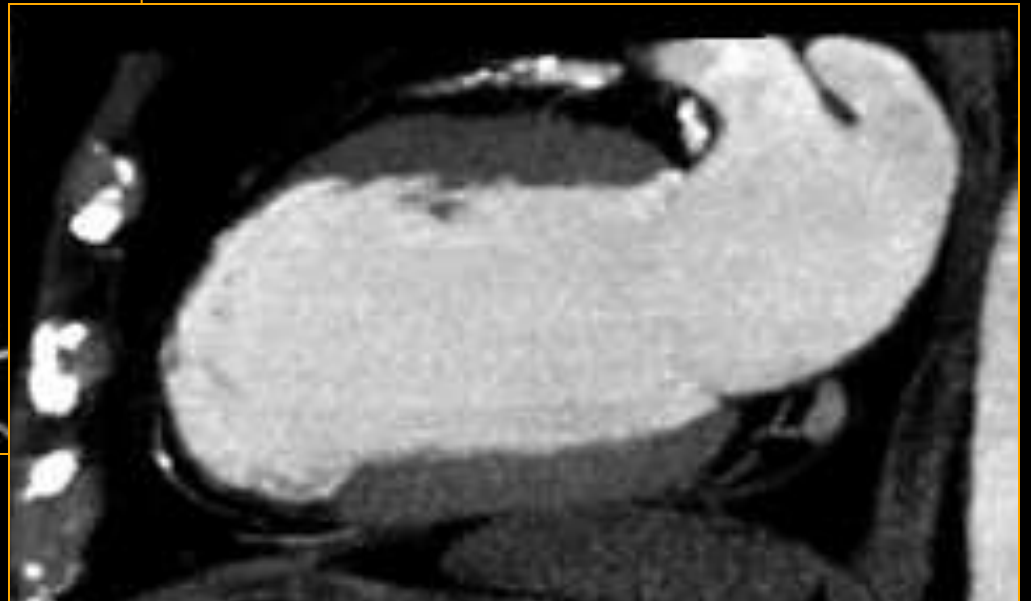
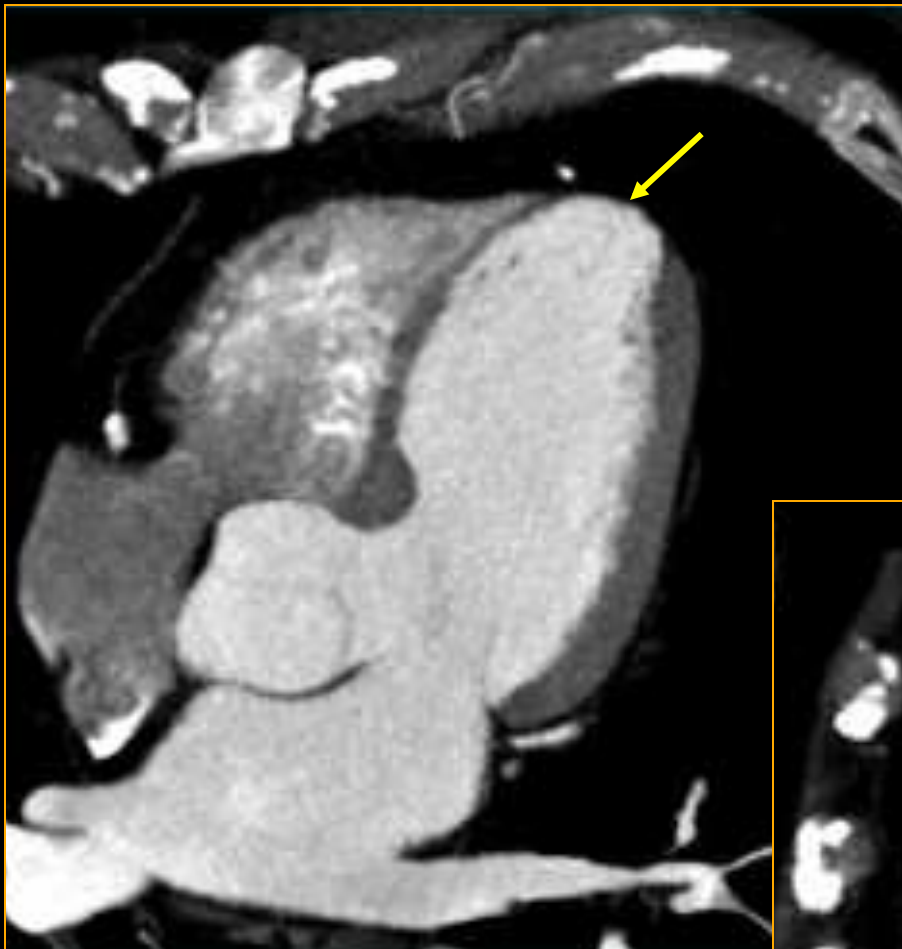

Péricardite

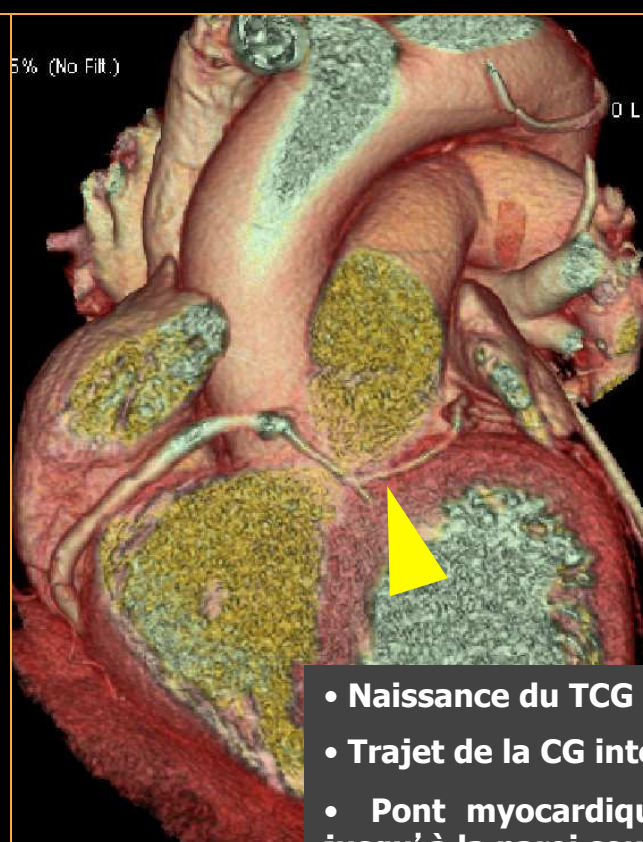
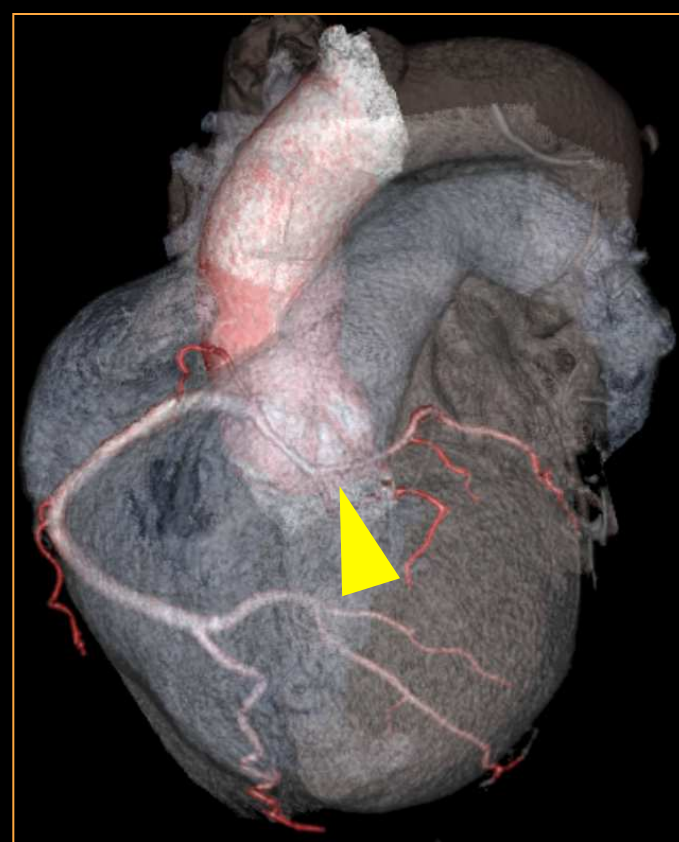
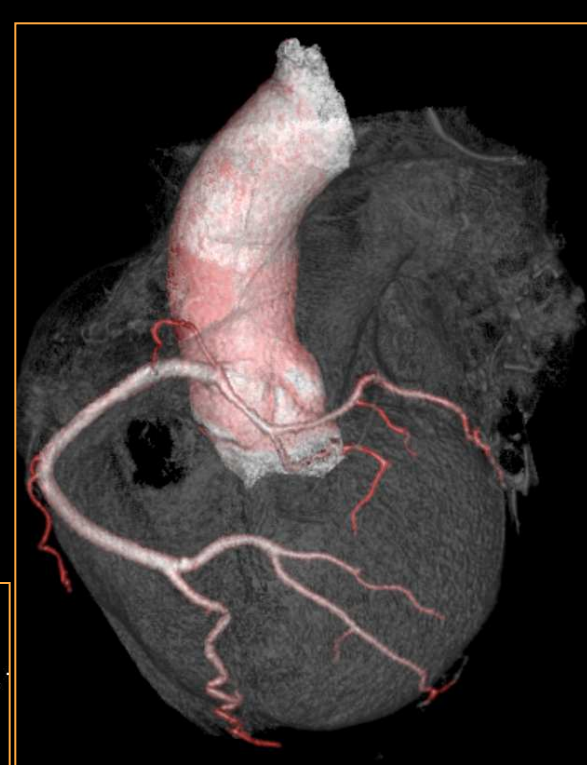
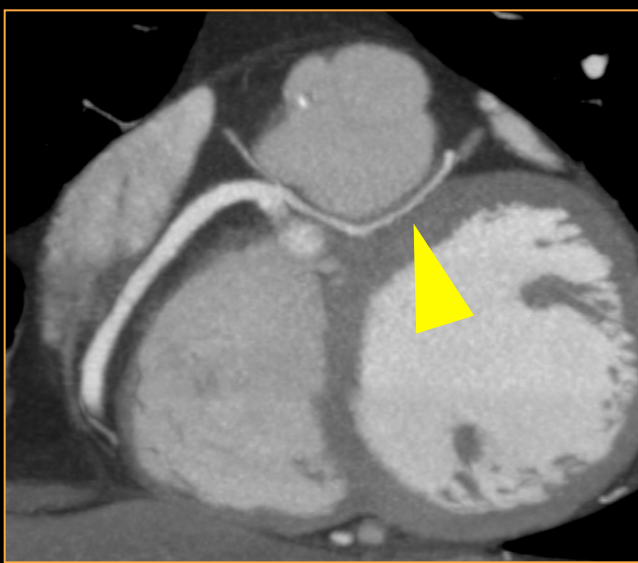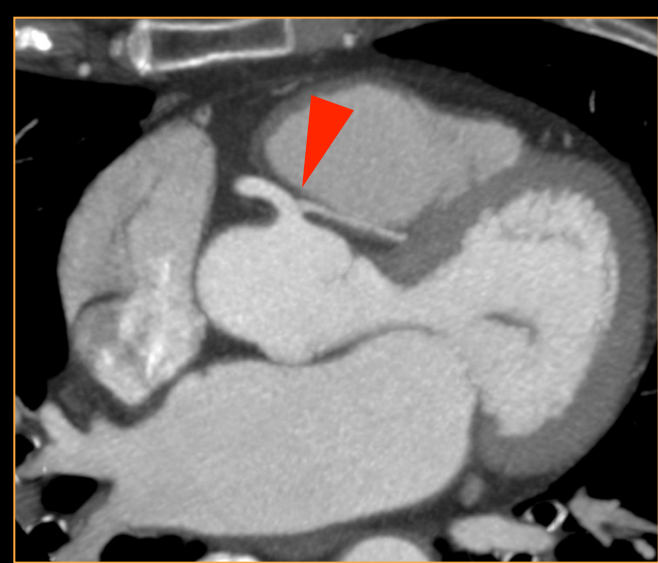


Péricardite constrictive





Anévrisme ventriculaire



- Naissance du TCG de CD1
- Trajet de la CG interartériel, dans la paroi de l'AP
- Pont myocardique profond de l'IVA prox et moy jusqu'à la paroi sous-endocardique du VD



2/ RADIOANATOMIE DU MEDIASTIN

- VAISSEAUX
- CŒUR
- **ŒSOPHAGE**
- CHAINES GANGLIONNAIRES

Définition

- Segment du tube digestif reliant l'hypopharynx à l'estomac
- Tube musculaire de 25 cm de longueur (de C6 à D11)
- 3 régions anatomiques : cervicale, thoracique et abdominale
- Passe en arrière de la trachée, traverse le médiastin postérieur dans toute sa hauteur, se déplace progressivement vers la gauche.
- Traverse le diaphragme à hauteur de T10 par le hiatus oesophagien ou il présente un rétrécissement

Anatomie

Œsophage **cervical** : de C6 à T1, 16 à 21 cm des AD

Œsophage **thoracique** : T1 à T10, 21 à 37 cm des AD

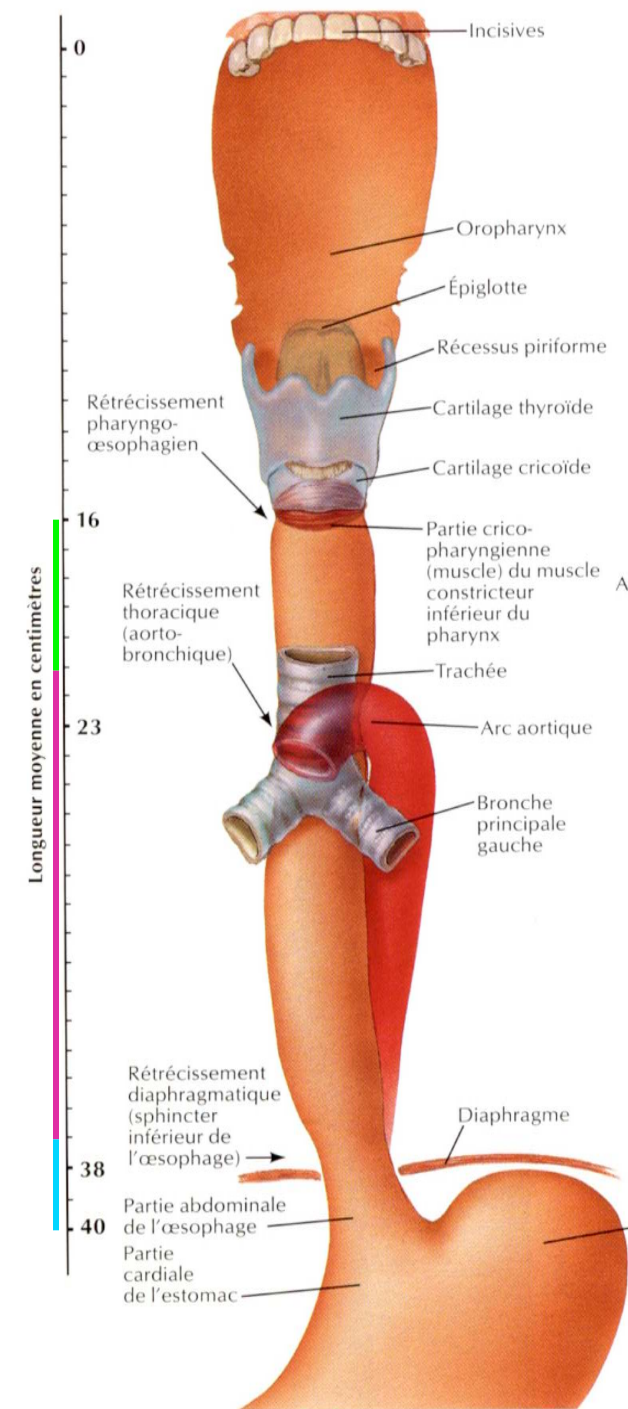
Œsophage **abdominal** : T10-11, 37 à 40 cm des AD

Œsophage intra-thoracique :

Tiers supérieur : de l'orifice supérieur du thorax à la bifurcation trachéale, à 24 cm approximativement des incisives supérieures

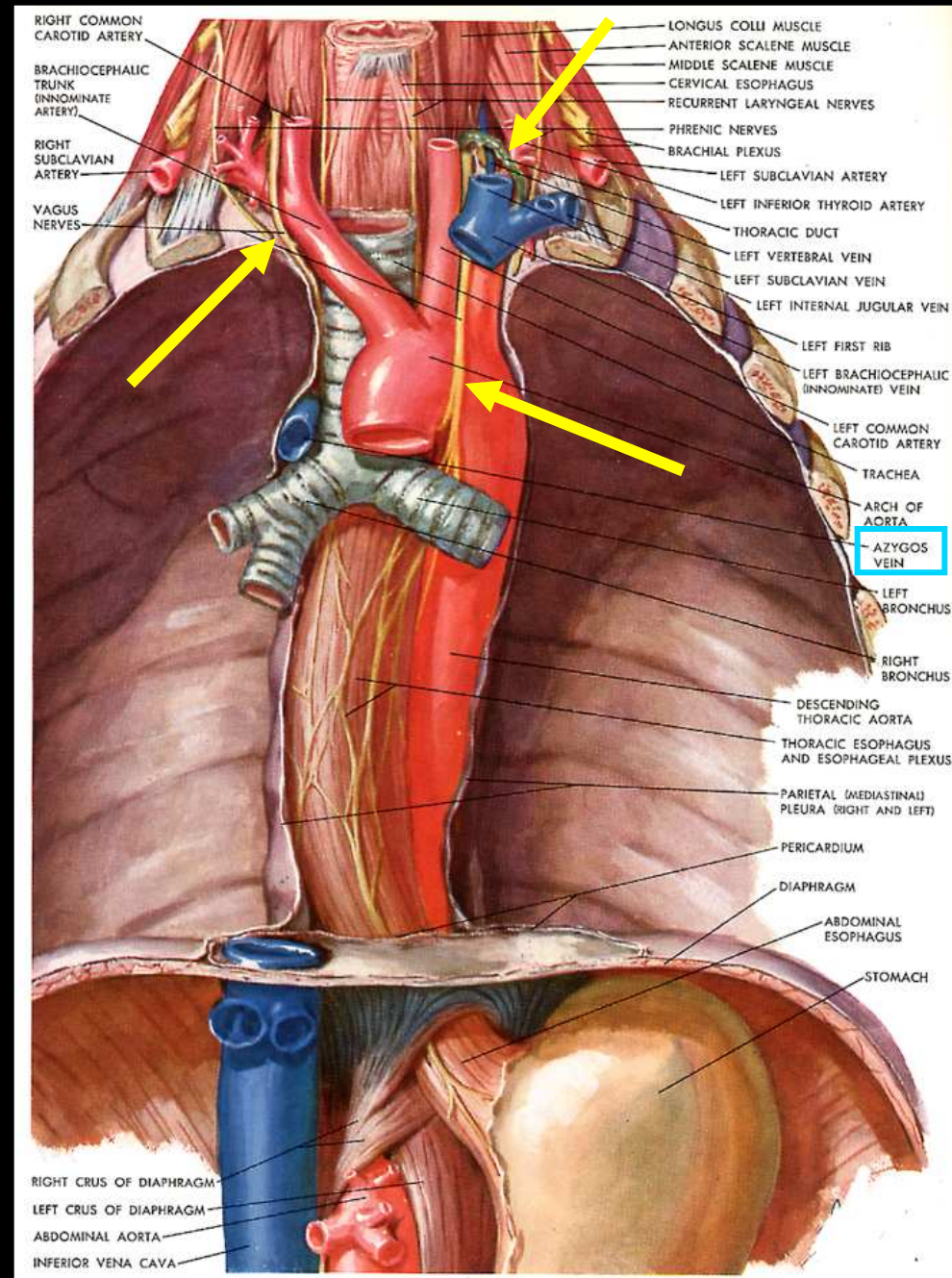
Tiers moyen : débutant à la hauteur de la bifurcation trachéale, de 24 à 32 cm approximativement des incisives supérieures

Tiers inférieur : (incluant l'oesophage abdominal), de 32 à 40 cm approximativement des incisives supérieures.



Rapports

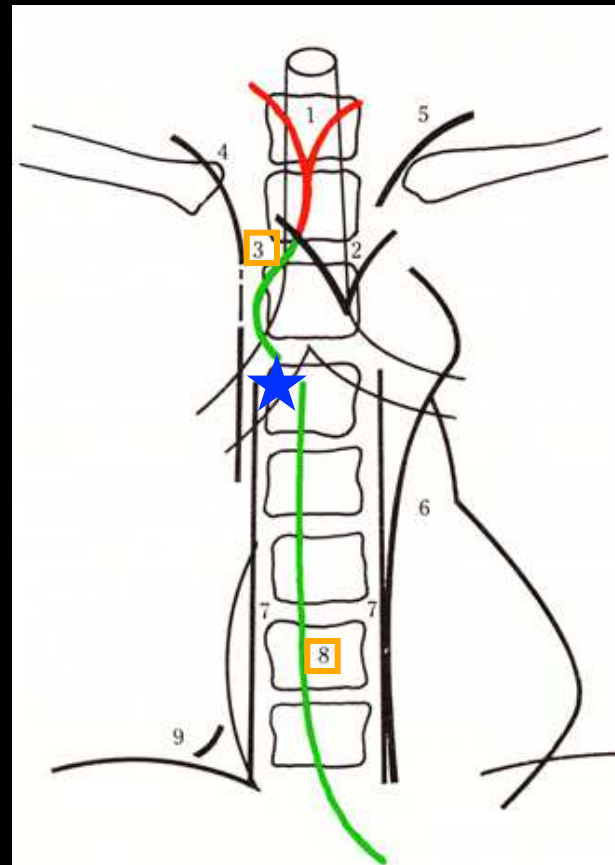
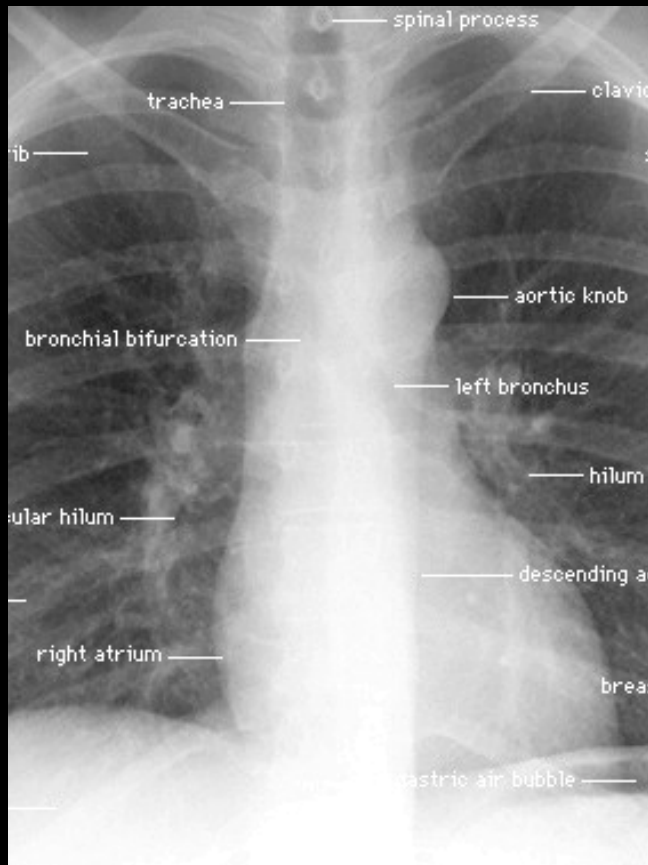
- **Trachée** : axe du médiastin postérieur, bifurque en T5, l'oesophage y adhère par les muscles de Luscha
- **Conduit thoracique** : monte en arrière plaqué contre l'aorte, en rapport avec l'oesophage sur une partie de son trajet.
- **Nerfs vagues** :
droit : passe en arrière de l'oesophage
gauche : en avant de l'oesophage
- **Chaîne orthosympathique latéro-vertébrale** et ses ganglions
- **Azygos, hémiazygos, hémiazygos accessoire**



Radio de thorax F/P

Ligne para-azygo-oesophagienne : au dessus de la bifurcation trachéale. Naît de l'interface du poumon droit avec l'œsophage en bas et la veine azygos en haut.

Ligne para-oesophagienne inf droite : en dessous de la bifurcation



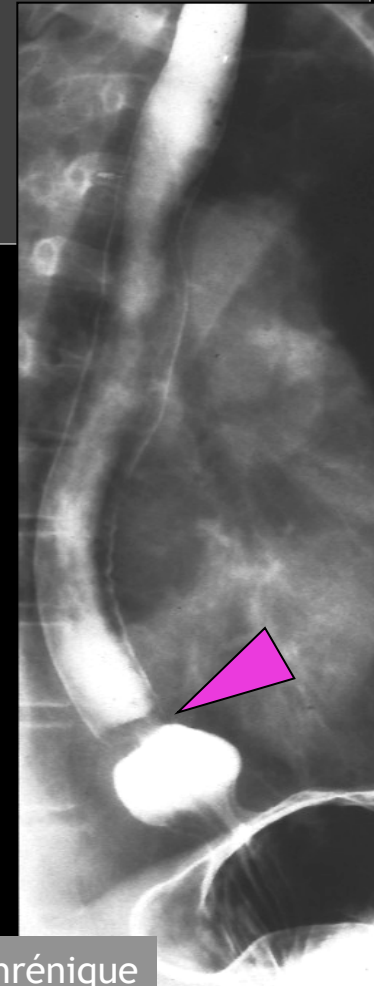
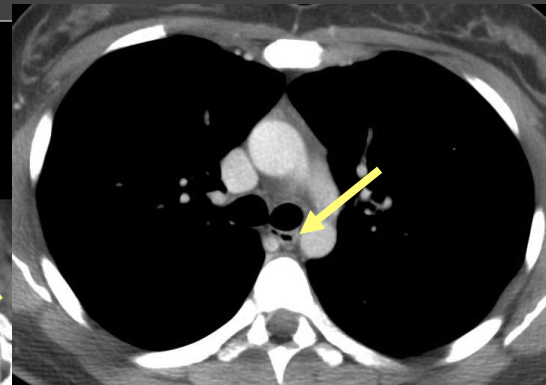
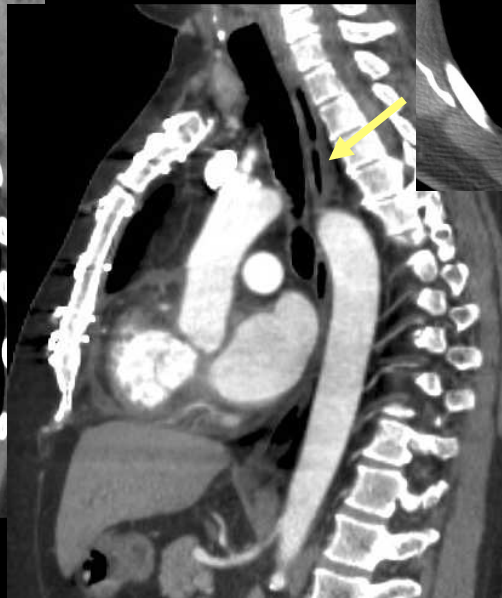
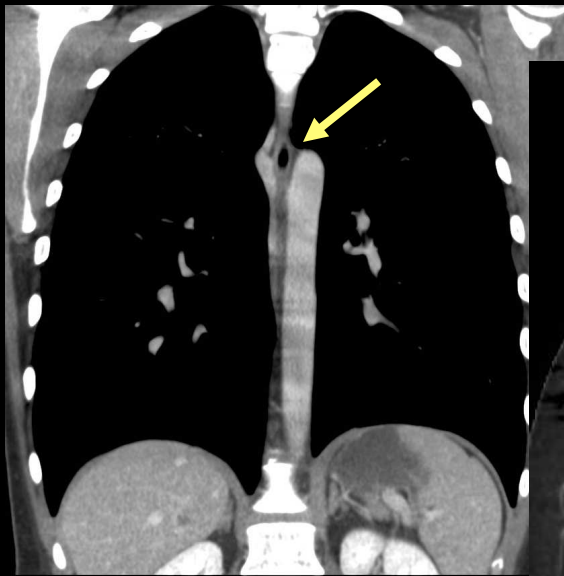
Transit oesophagien

- double contraste

- BaSO4 haute densité-viscosité faible
- air dégluti ou mieux **insufflé**

Scanner: pathologie tumorale ++

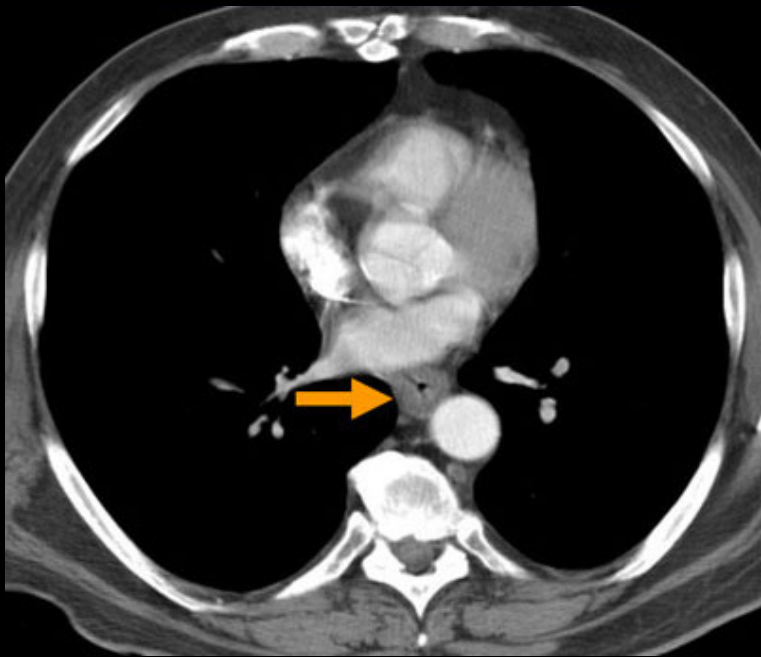
Avec ingestion d' hydrosolubles ++++



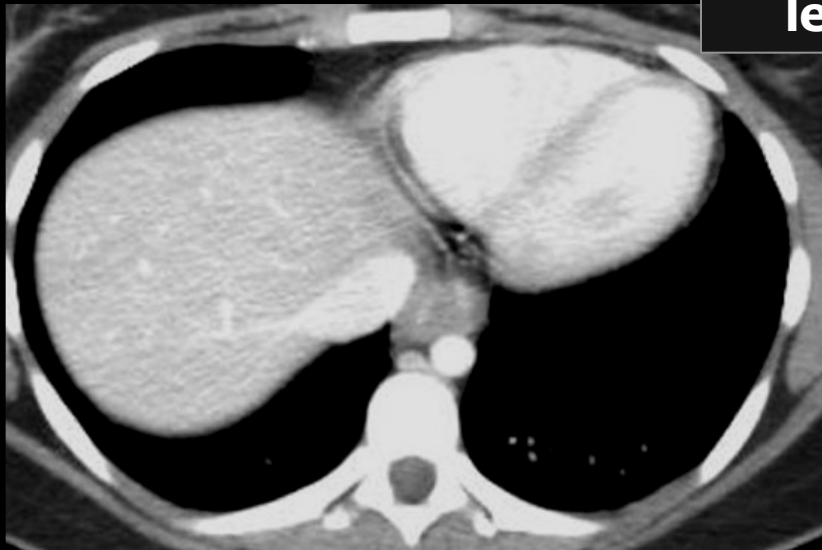ampoule épiphrénique



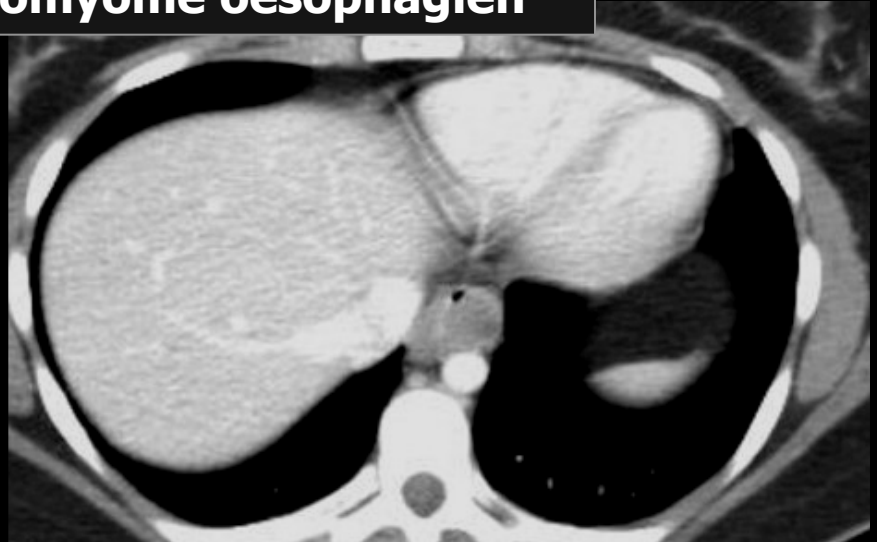
**UN PEU DE PATHOLOGIE ET
VARIATIONS ANATOMIQUES...**

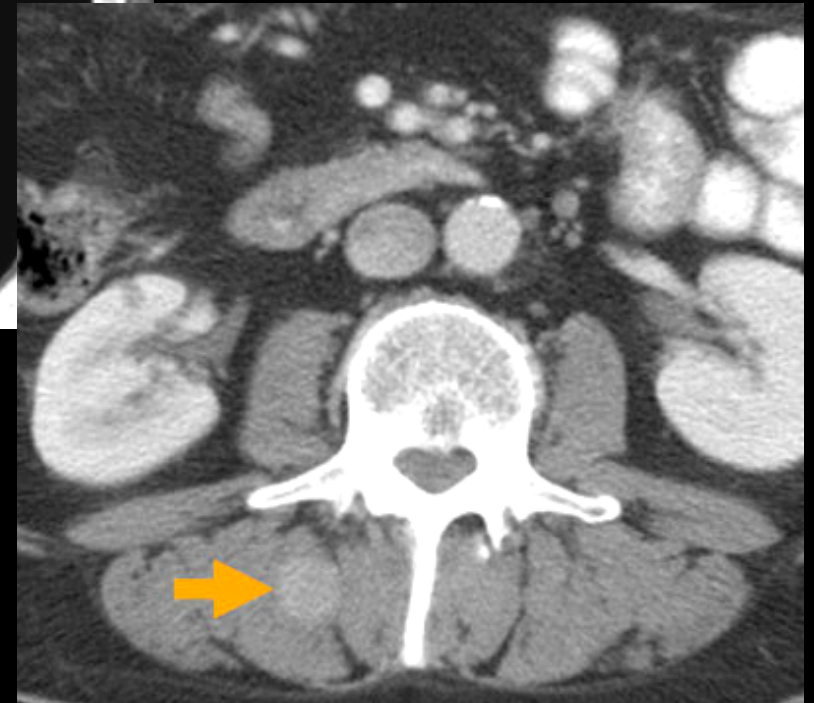
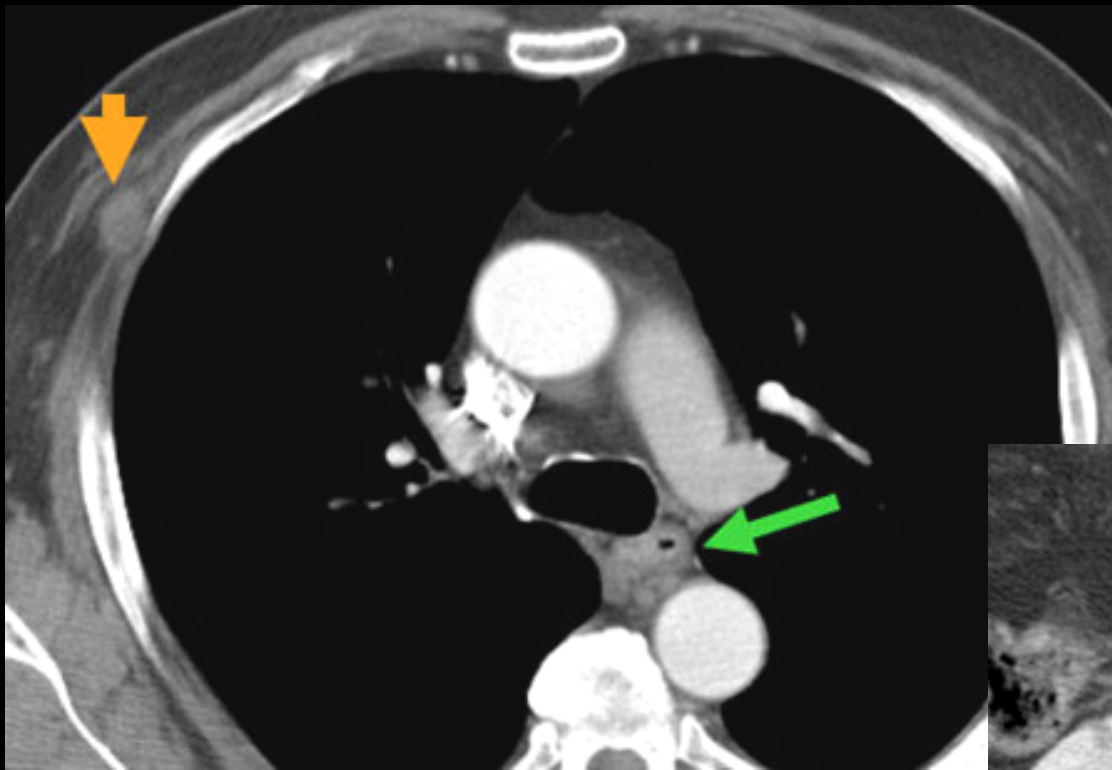


**carcinome épidermoïde
de l'oesophage**

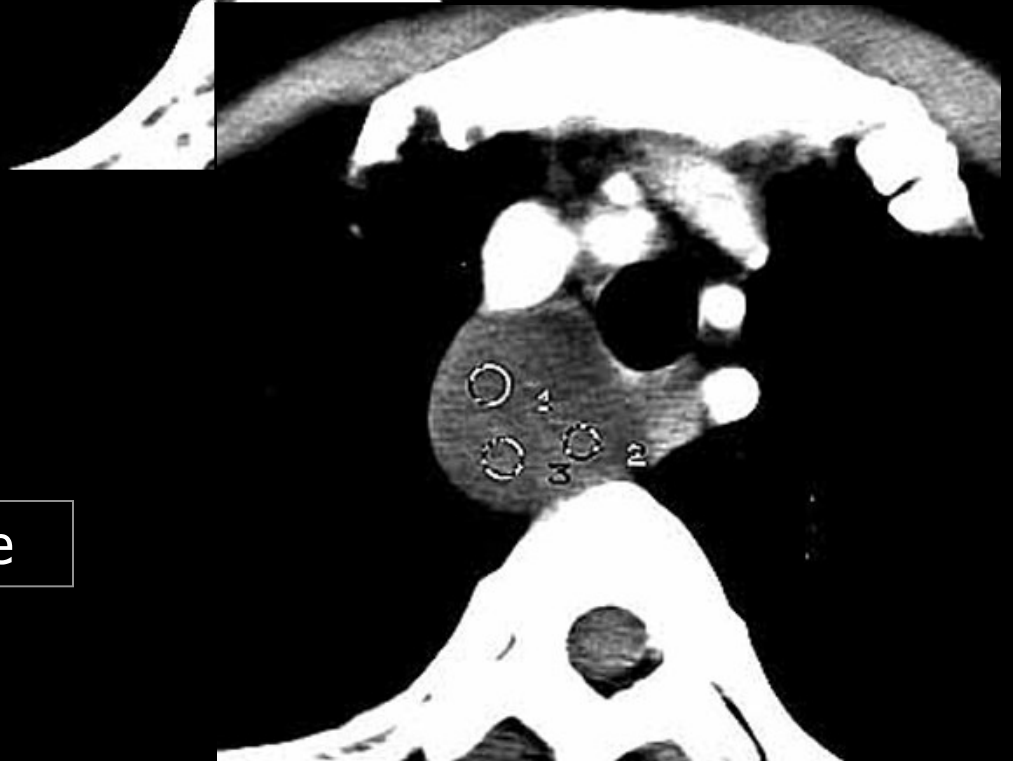
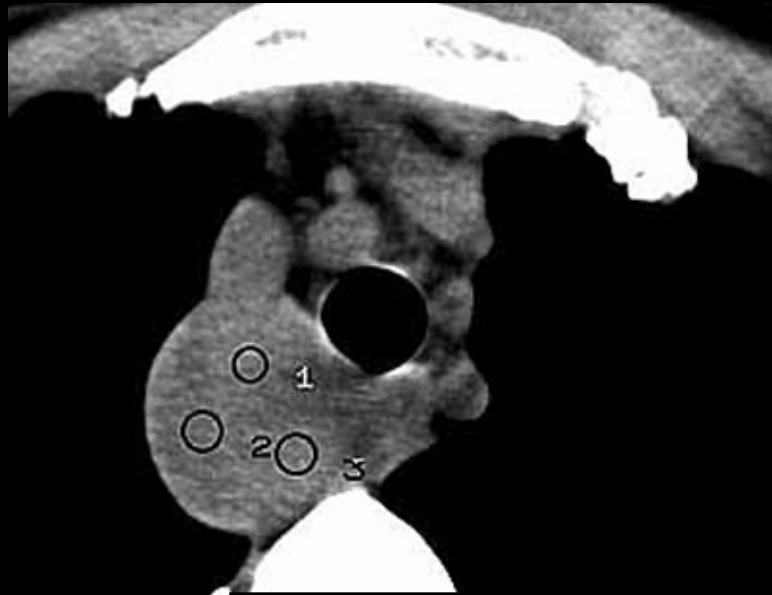
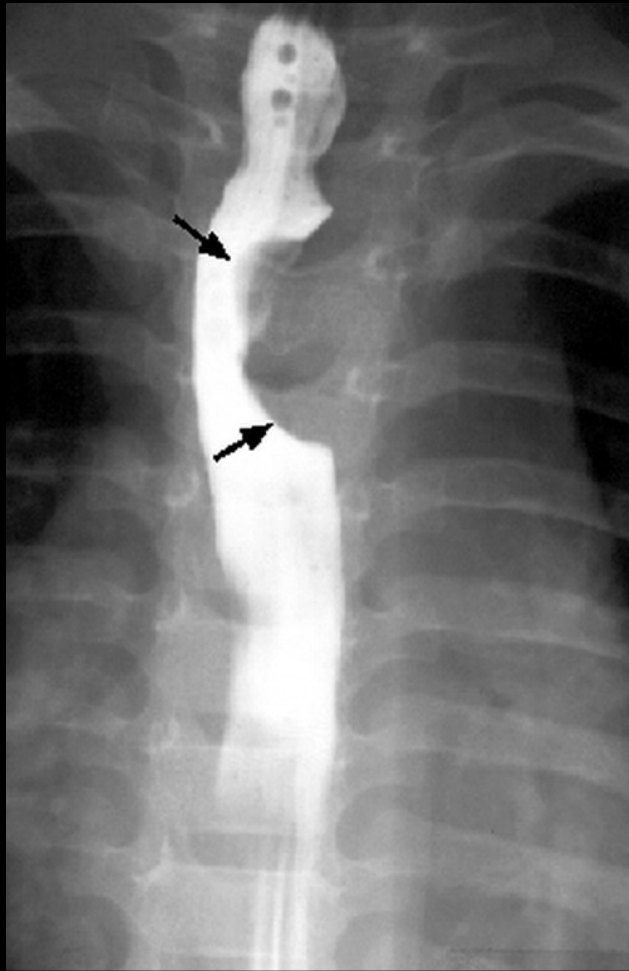


leiomyome oesophagien

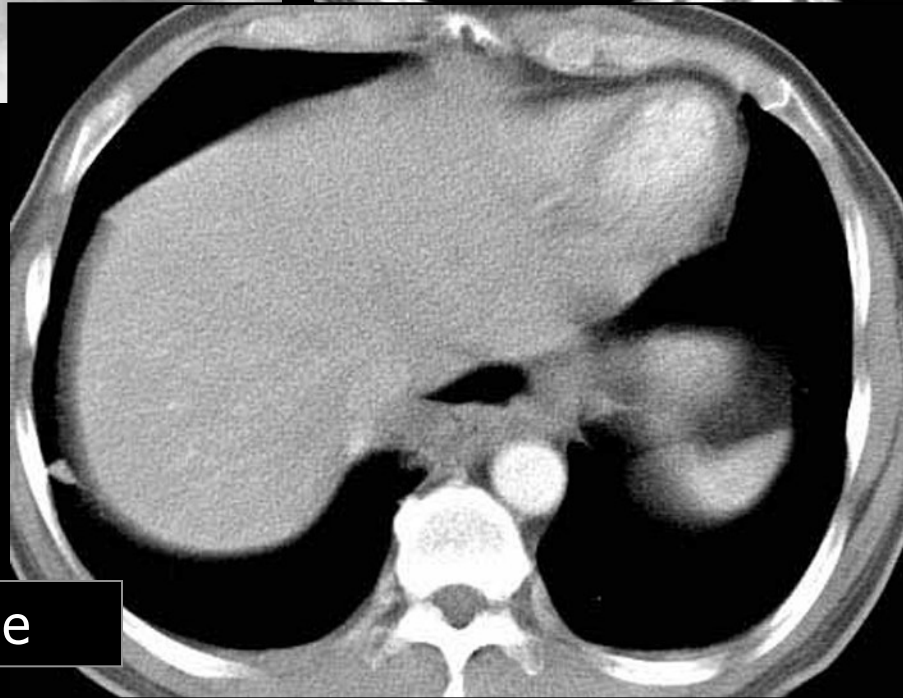
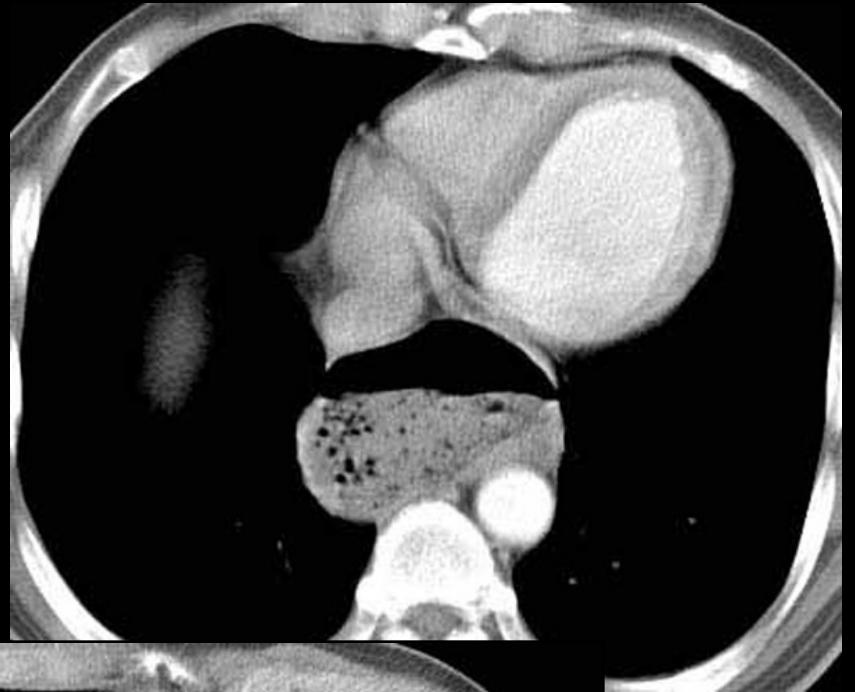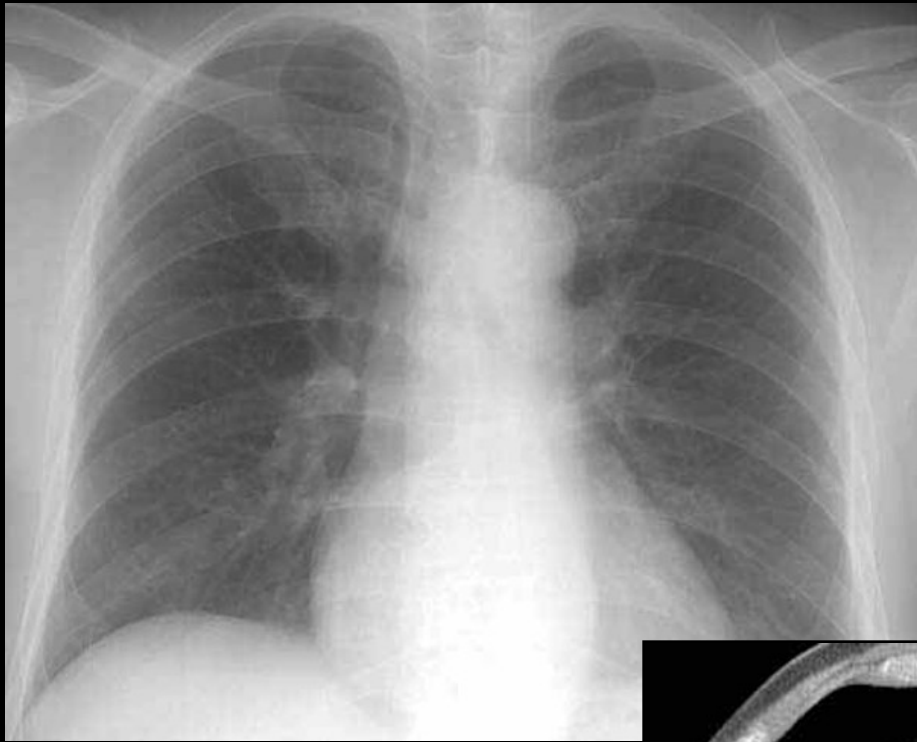




Carcinome épidermoïde
de l'œsophage
et métastases



Duplication oesophagienne



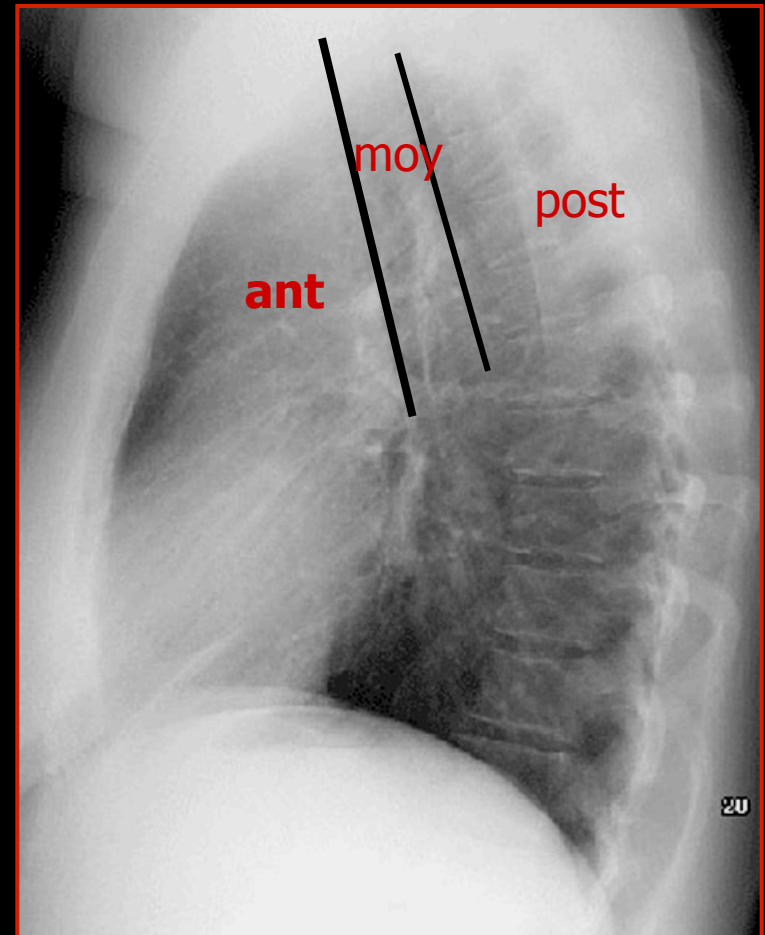
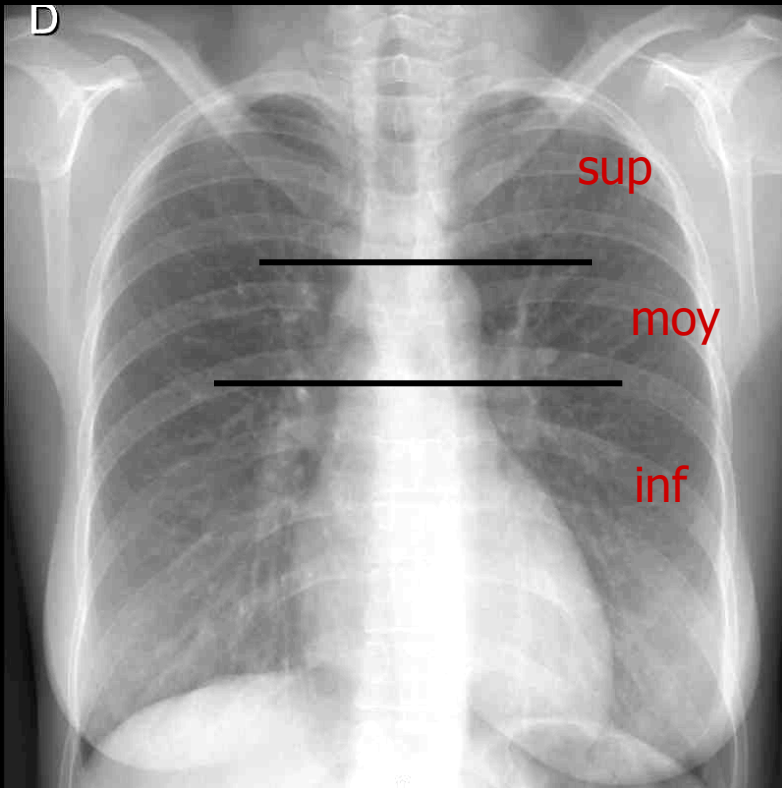
Diverticule épiphrénique

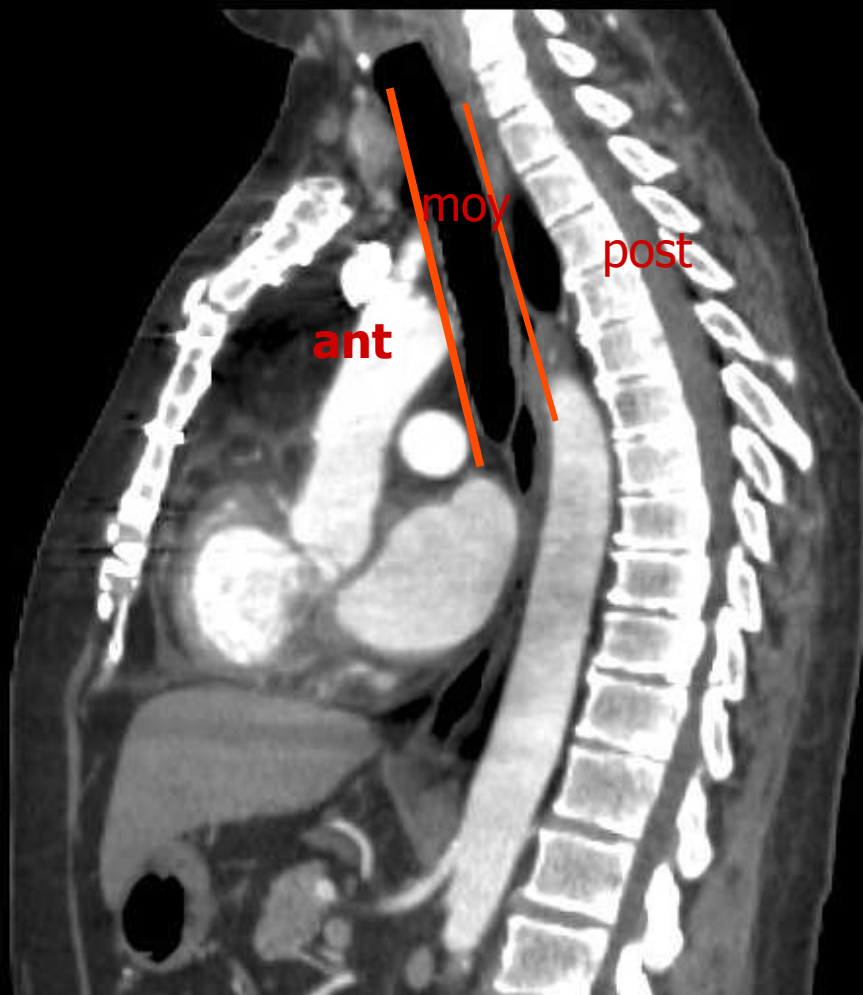
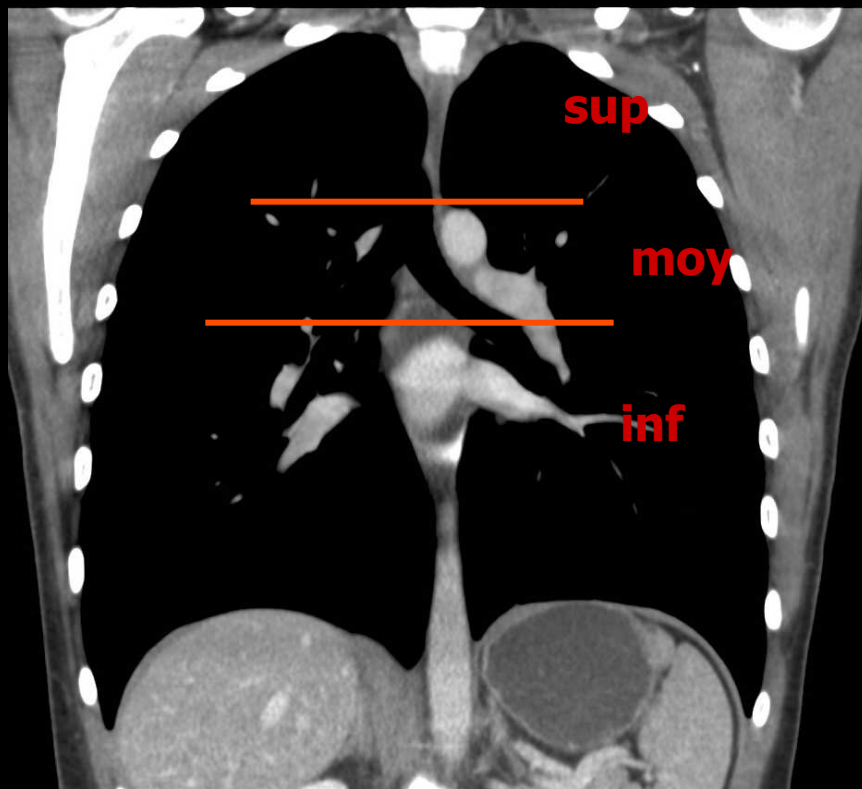


2/ RADIOANATOMIE DU MEDIASTIN

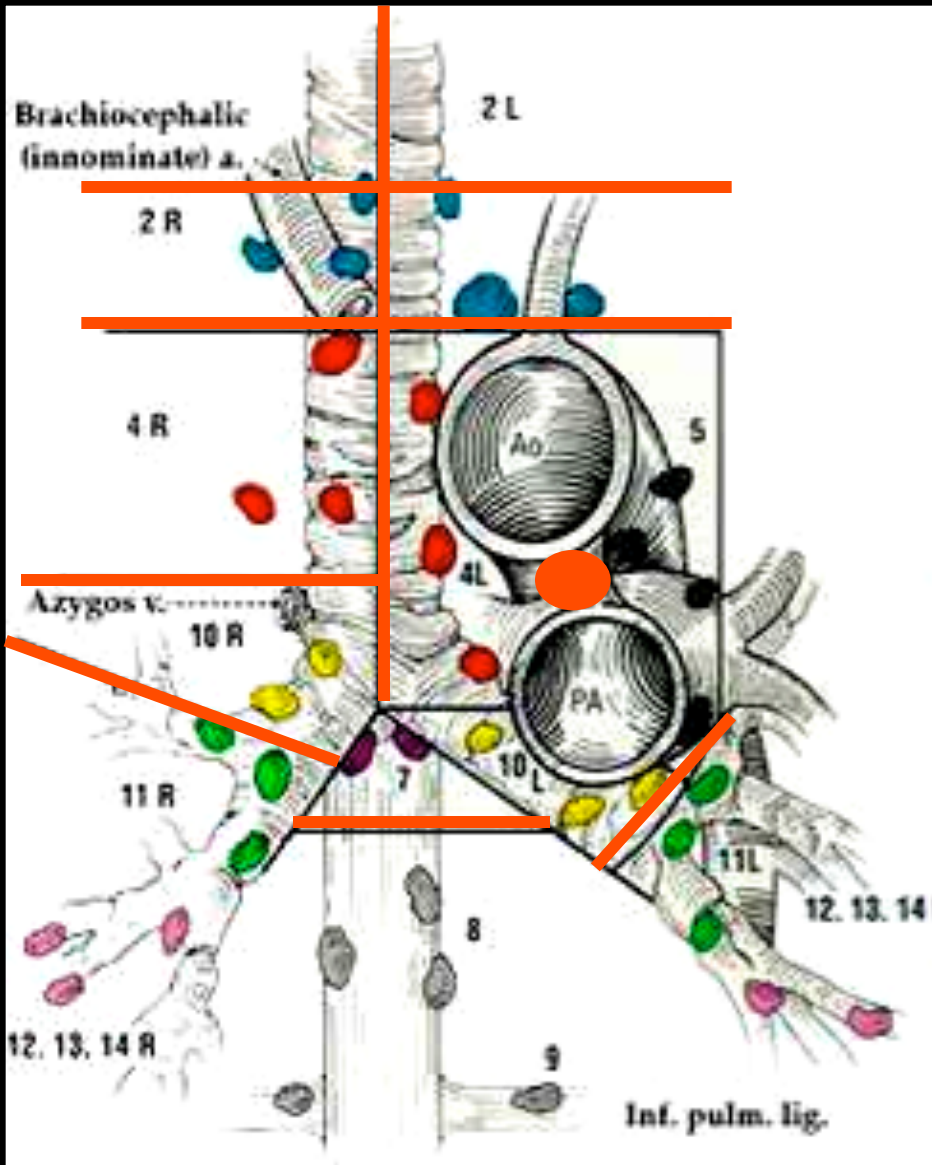
- VAISSEAUX
- CŒUR
- ŒSOPHAGE
- **CHAINES GANGLIONNAIRES**

Les régions du médiastin





Les loges ganglionnaires du médiastin



Repères anatomiques

1/Trachée face antérieure ligne de haut en bas carène

2/TVBC croise milieu face ant trachée

3/Tangente horizontale au bord sup aorte

4/ ligament artériel face ant aorte à origine AP

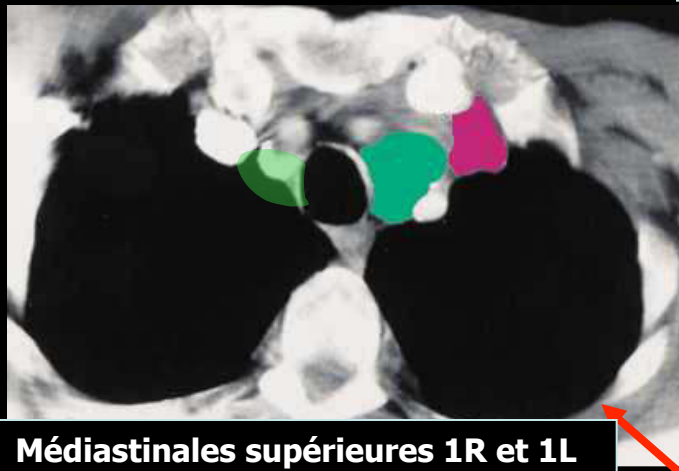
5/bronche souche droite et bronche lobaire supérieure droite

6/bronche souche gauche et bronche lobaire sup

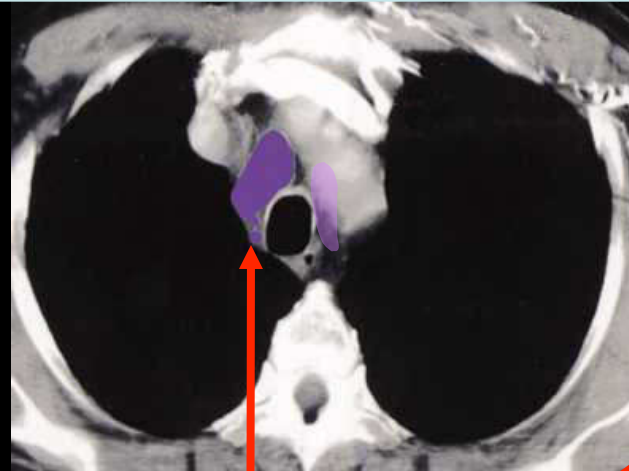
7/région sous carinaire

8/crosse de la veine azygos

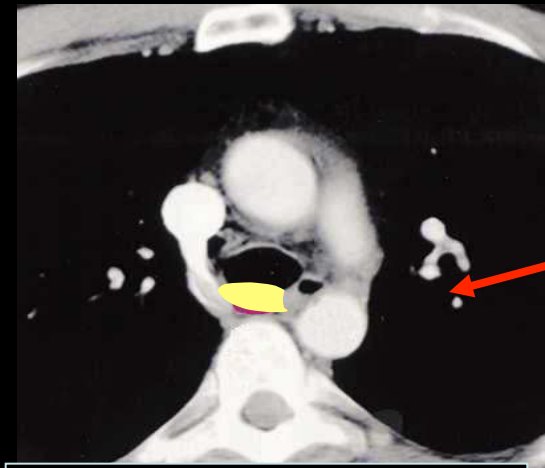
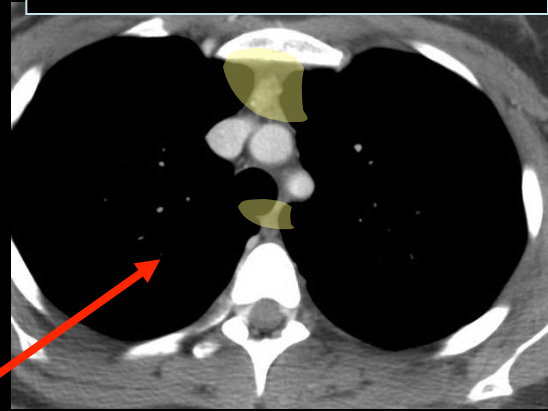
Paratrachéales supérieures 2R et 2L



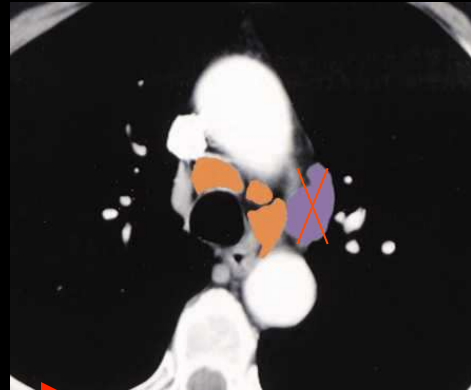
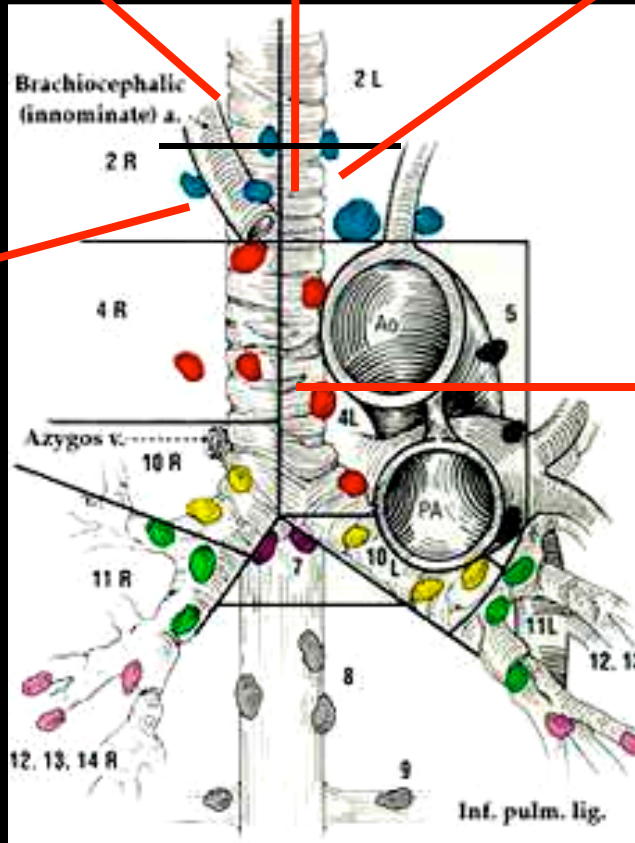
Médiastinales supérieures 1R et 1L



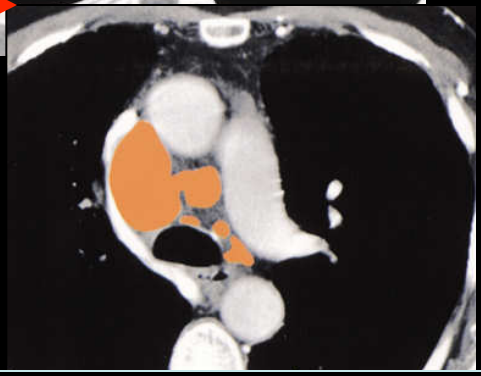
Prévasculaire 3A
rétrotrachéale 3R



rétrotrachéale 3R

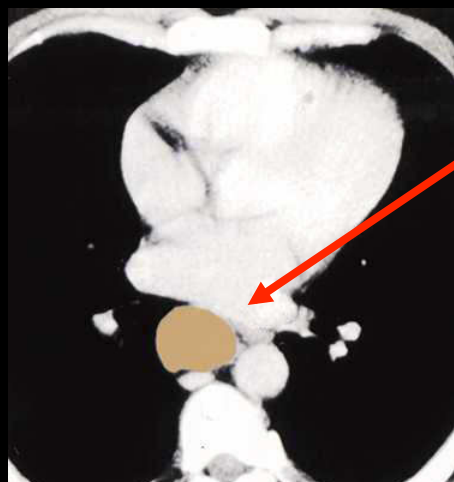
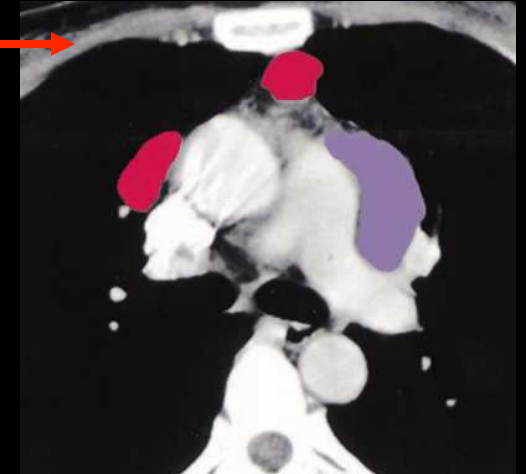
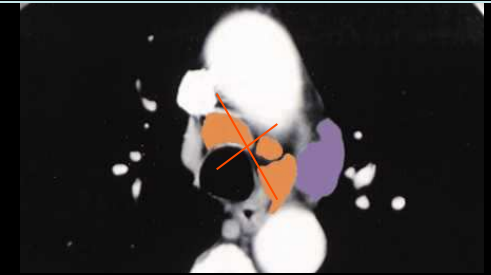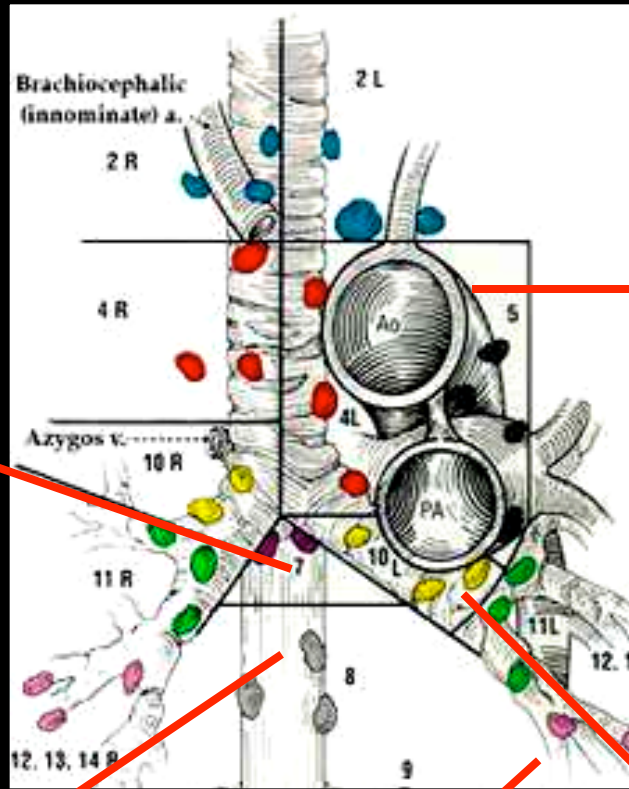
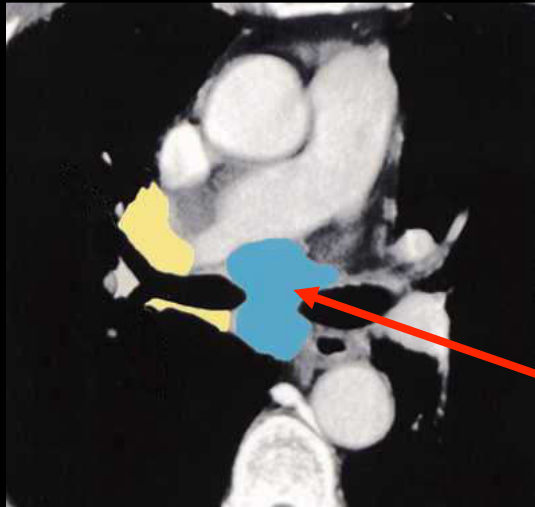


Paratrachéales inférieures
droite et gauche 4R et 4 L

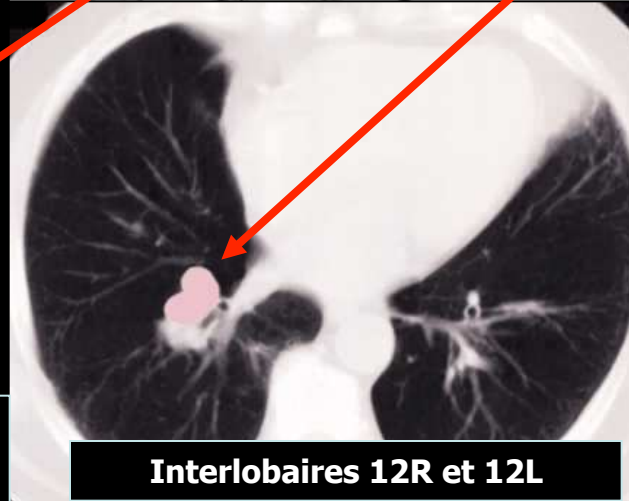


Fenêtre aorto pulmonaire 5

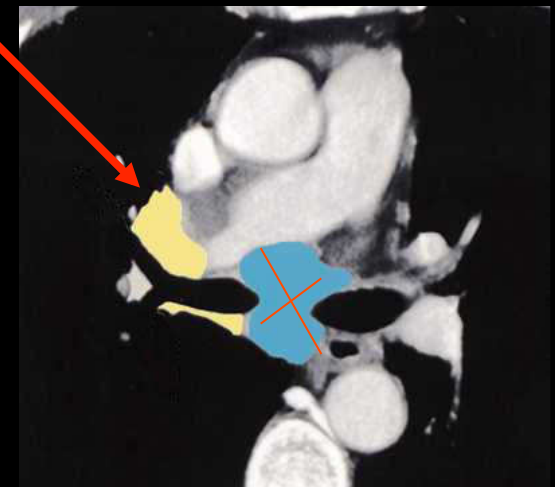Sous carinaires 7



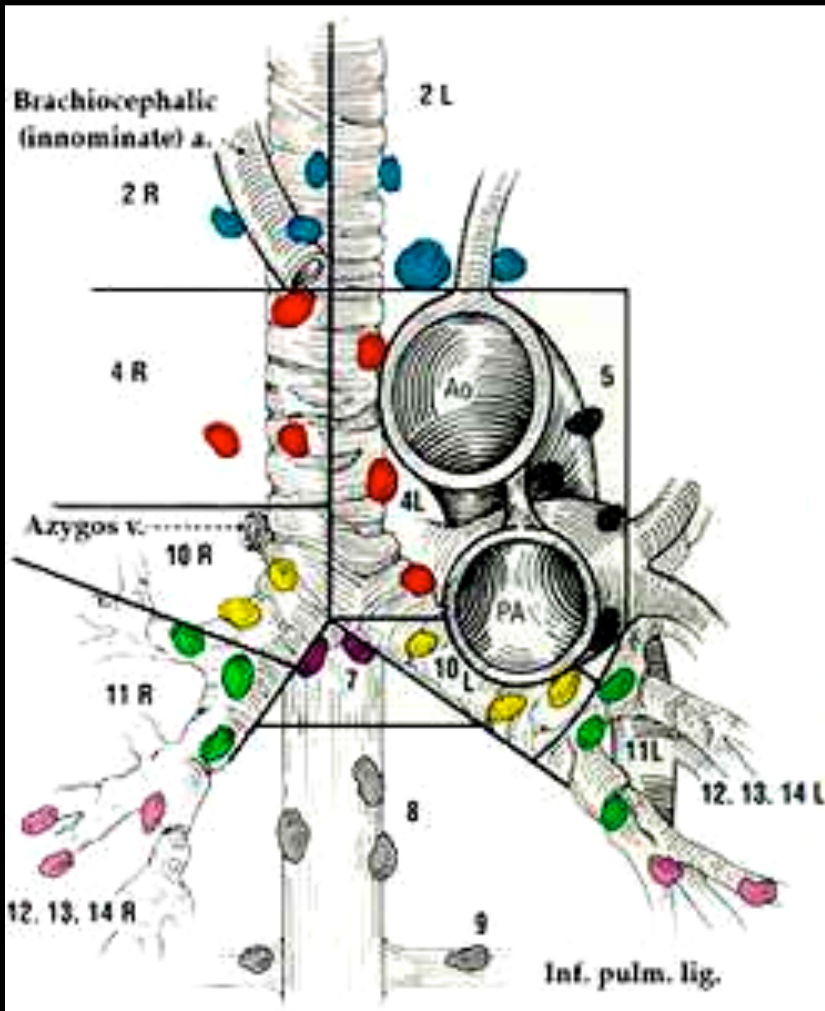
Para oesophagienne 8
Œsophage sous carinaire



Interlobaires 12R et 12L



Hilaires 10R et 10L







N1ganglions **homolatéraux** péribronchiques**N2**ganglions **homolatéraux** médiastinaux et/ou sous-carinaires

Regional Nodal Stations For Lung Cancer Staging

N₁ NODES

SUPERIOR MEDIASTINAL NODES

LOCATION

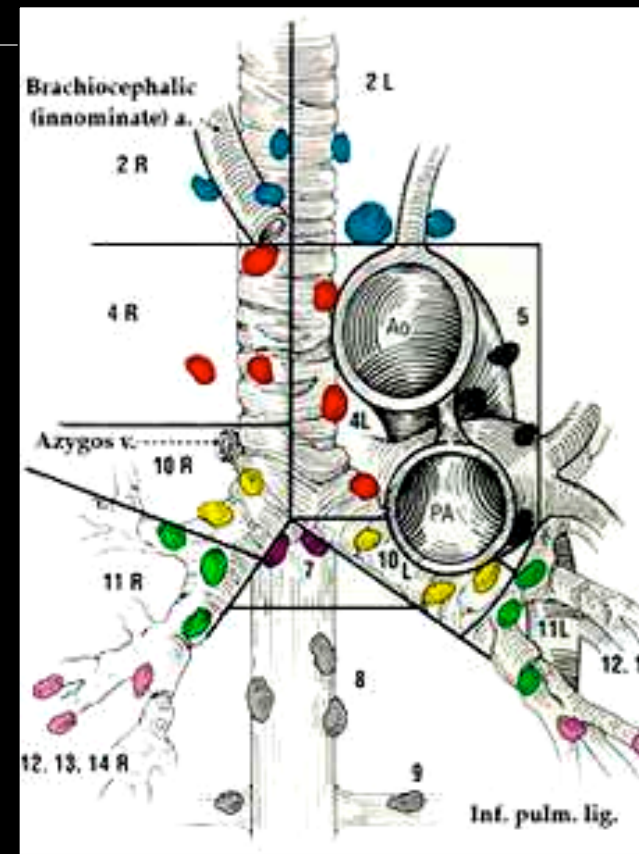
- | | | |
|---|-------------------------------------|--|
|  2R | Right upper paratracheal nodes | Between intersection of caudal margin of innominate a. with trachea and the apex of the lung (supra-innominate nodes). |
|  2L | Upper left paratracheal nodes | Between top of aortic arch and apex of the lung (supra-aortic nodes). |
|  4R | Right lower paratracheal nodes | Between intersection of caudal margin of innominate a. with trachea and cephalic border of azygos v. |
|  4L | Left lower paratracheal nodes | Between top of aortic arch and carina (medial to ligamentum arteriosum) |
|  10R | Right tracheo-bronchial angle nodes | From cephalic border of azygos v. to origin of RUL bronchus. |
|  10L | Left tracheo-bronchial angle nodes | Between carina and LUL (medial to ligamentum arteriosum). |

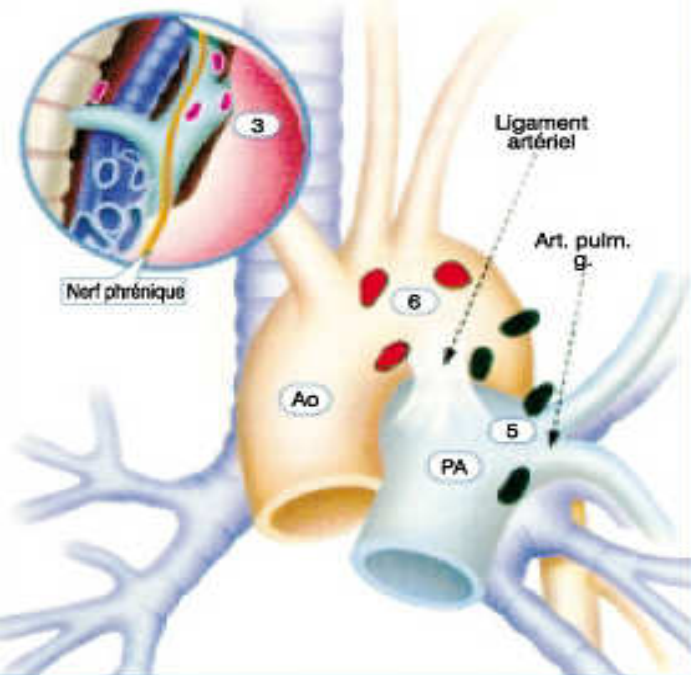
N 3

ganglions **controlatéraux** médiastinaux et/ou sous-carinaires

ganglions scalènes ou sus claviculaires

Contre-indiquent la chirurgie ; rôle respectifs du PET CT +++ et de la médiastinobiopsie pour le diagnostic d'envahissement des ganglions contro-latéraux





Ganglions médiastinaux supérieurs

- 1 Médiastinaux les plus hauts
- 2 Paratrachéaux supérieurs
- 3 Prévasculaire et rétrotrachéaux
- 4 Paratrachéaux inférieurs (y compris ganglions de l'azygos)

N₂ = 1 seul chiffre, homolatéraux

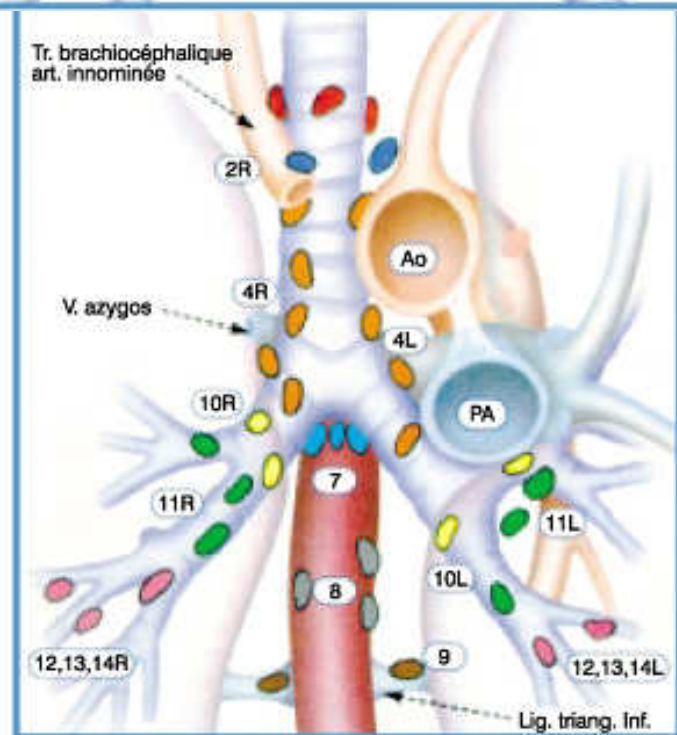
N₃ = 1 seul chiffre, controlatéraux ou sus-claviculaire

Ganglions aortiques

- 5 Sous-aortiques (communication interaorto-pulmonaire)
- 6 Para-aortiques (de l'aorte descendante ou diaphragmatique)

Ganglions médiastinaux inférieurs

- 7 Sus-carénares
- 8 Paraoesophagiens (sous la carène)
- 9 Du ligament triangulaire

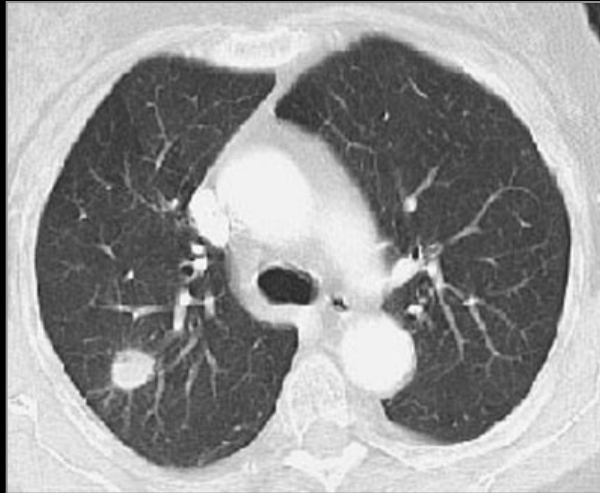


Ganglions N₁

- 10 Hilaires
- 11 Interlobaires
- 12 Lobaires
- 13 Segmentaires
- 14 Sous-segmentaires

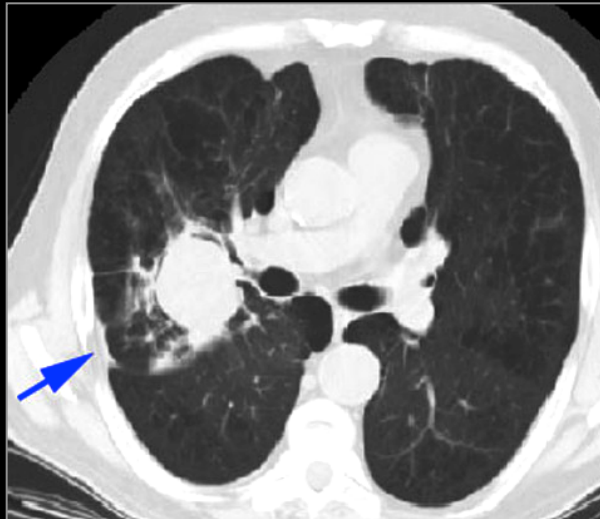
Classification TNM des CNPC

T1



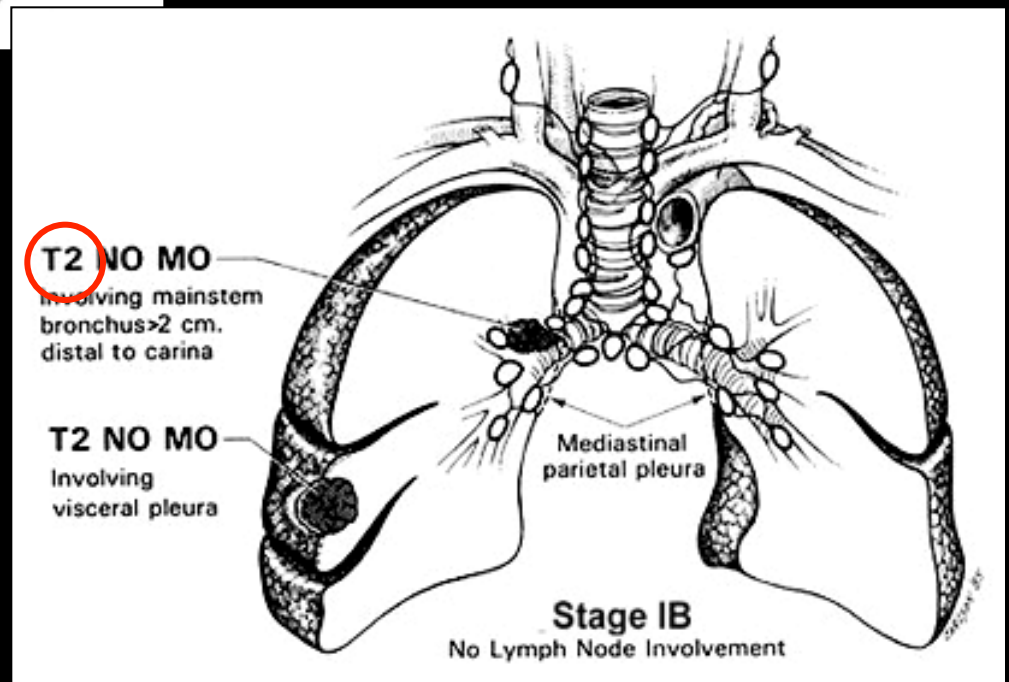
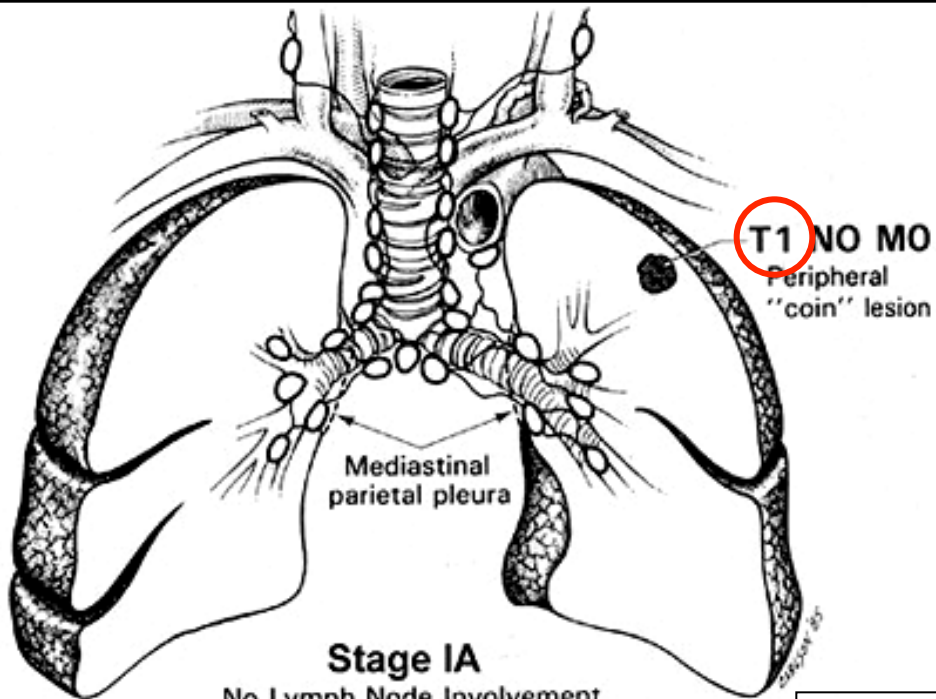
Tumeur de 3 cm ou moins dans sa plus grande dimension, entourée par le poumon ou la plèvre viscérale, sans évidence bronchoscopique d'invasion plus proximale que la bronchique lobaire (c-à-d pas la bronche souche)

T2

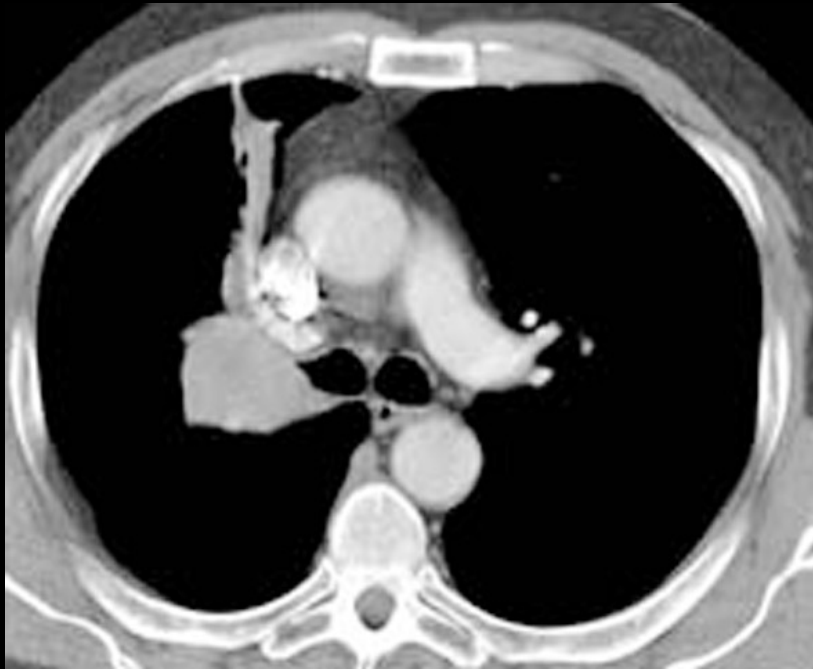

tumeur >3 cm et < à 7 cm ou :

- **Atteinte de la bronche souche à 2 cm ou plus de la carène.**
- **envahissant la plèvre viscérale avec atélectasie ou pneumonie obstructive n'intéressant pas tout le poumon**

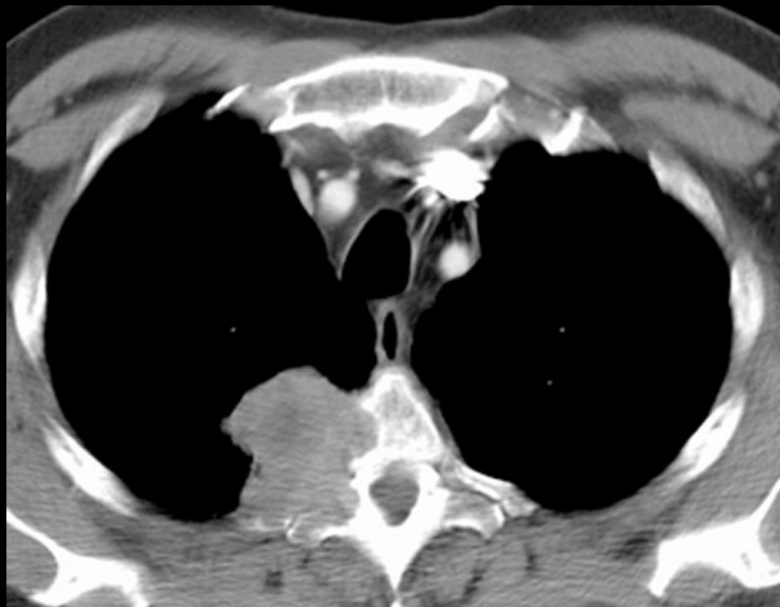

T3

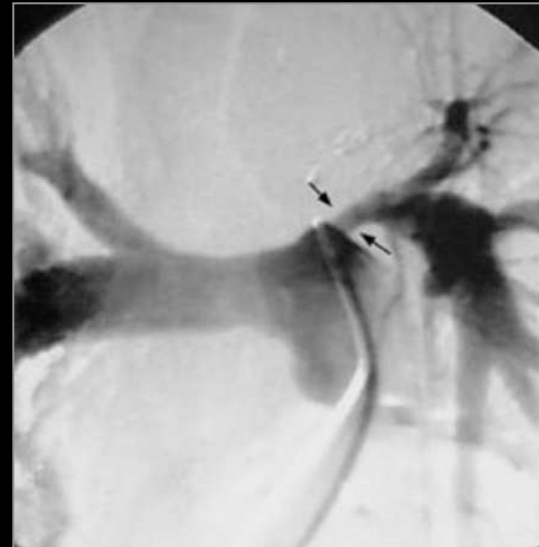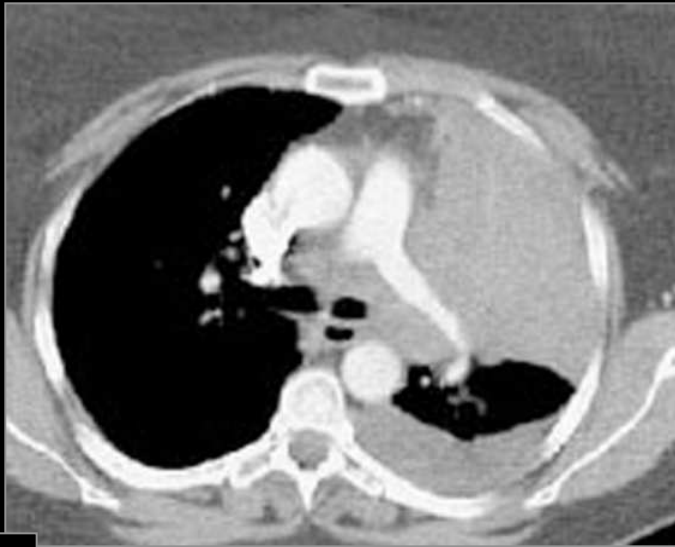


Tumeur de plus de 7 cm
- ou envahissant directement une des structures suivantes : la paroi thoracique (y compris la tumeur de Pancoast), le diaphragme, le nerf phrénique, la plèvre médiastinale, pleural ou pariétal ou le péricarde
- ou une tumeur dans la bronche souche à moins de 2 cm de la caréna sans l'envahir
- ou associée à une atélectasie ou d'une pneumopathie obstructive du poumon entier
- ou **présence d'un nodule tumoral distinct dans le même lobe**

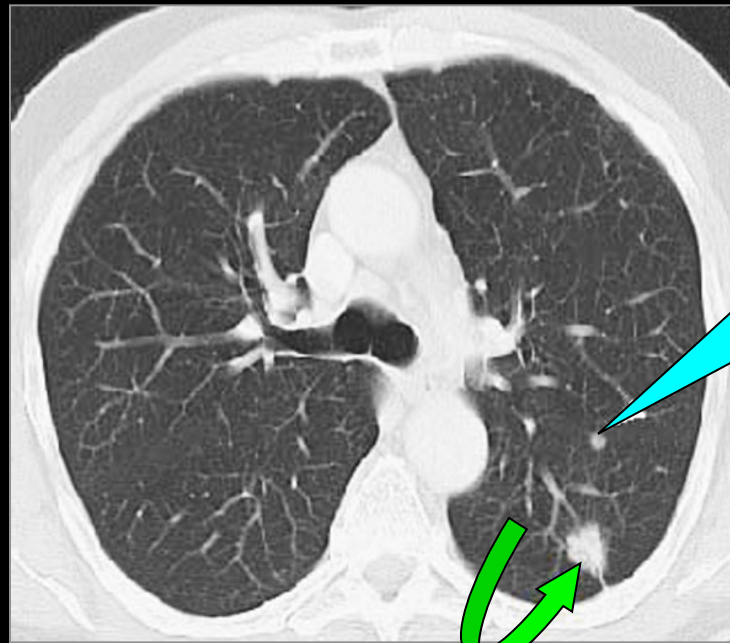
T4

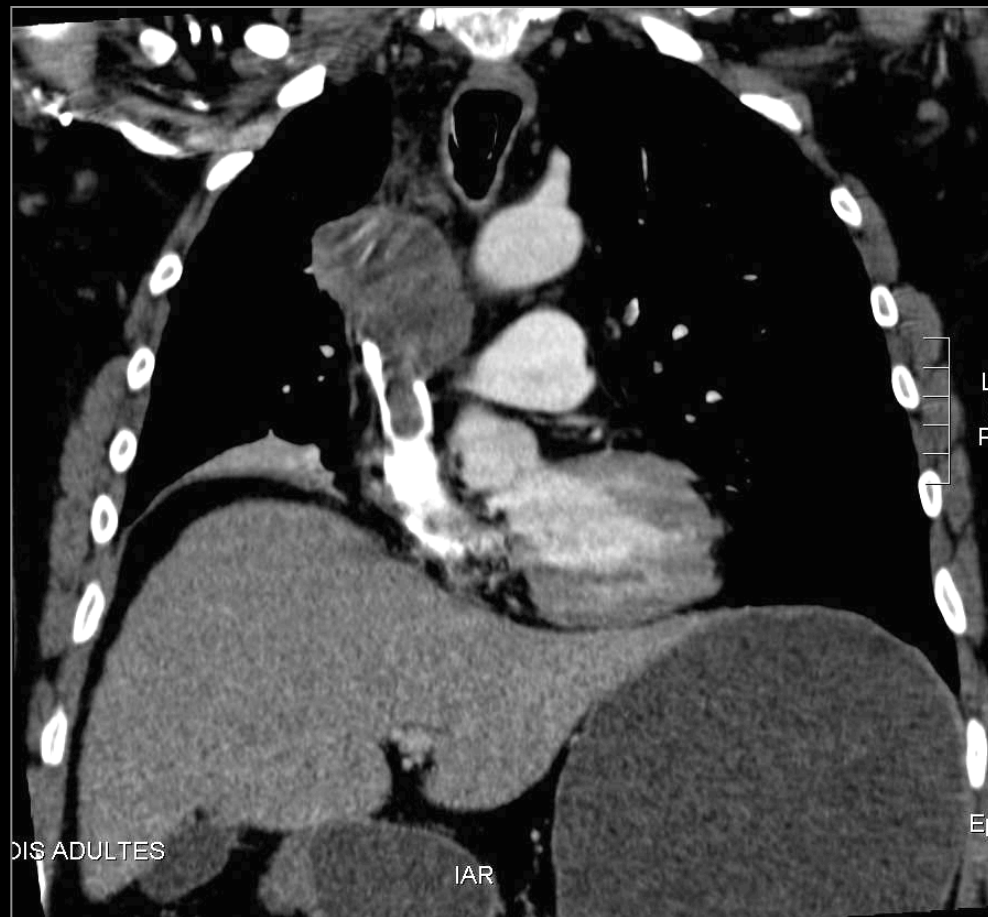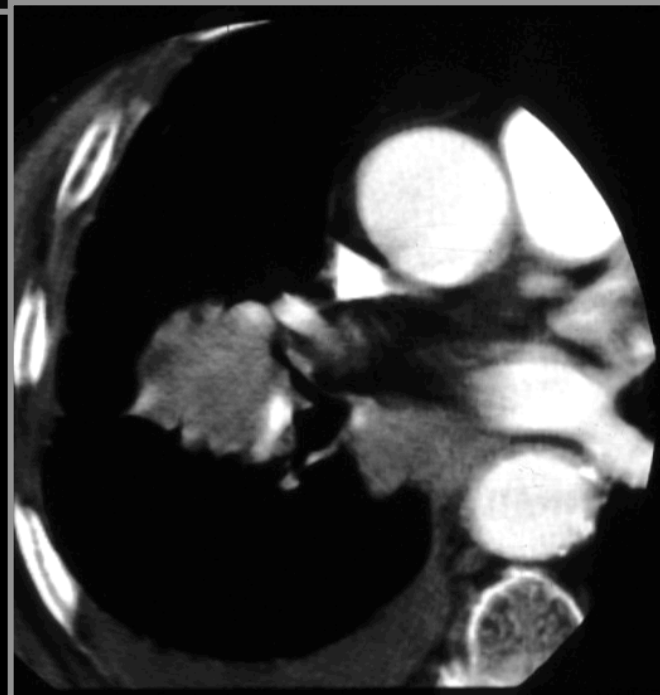
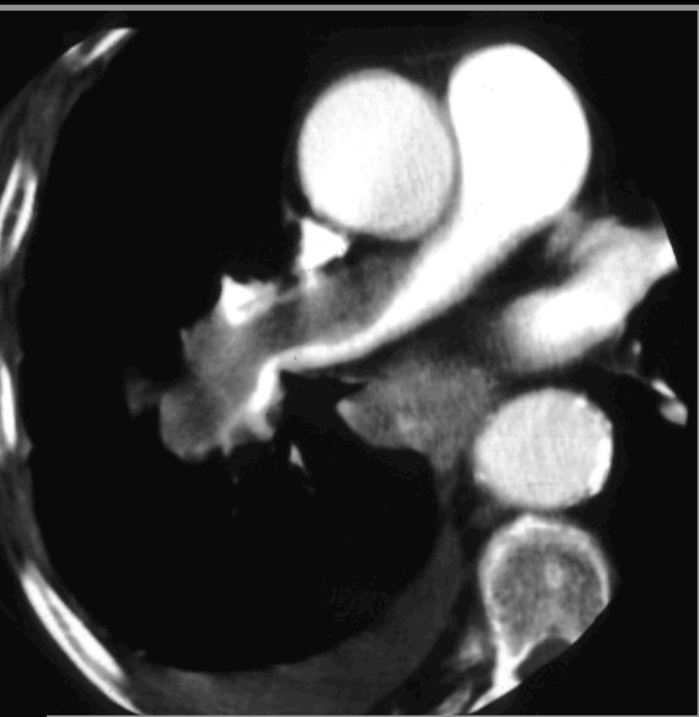


Tumeur de tout taille envahissant directement une des structures suivantes : médiastin, cœur, grands vaisseaux, trachée, nerf laryngé récurrent, œsophage, corps vertébral, carène
- Ou **présence d'un nodule tumoral distinct dans un autre lobe du poumon atteint**



T4 !





Extension vasculaire T4

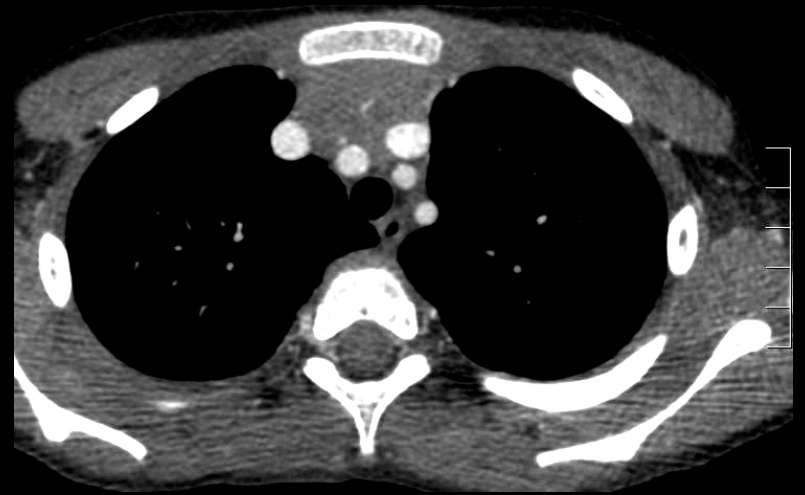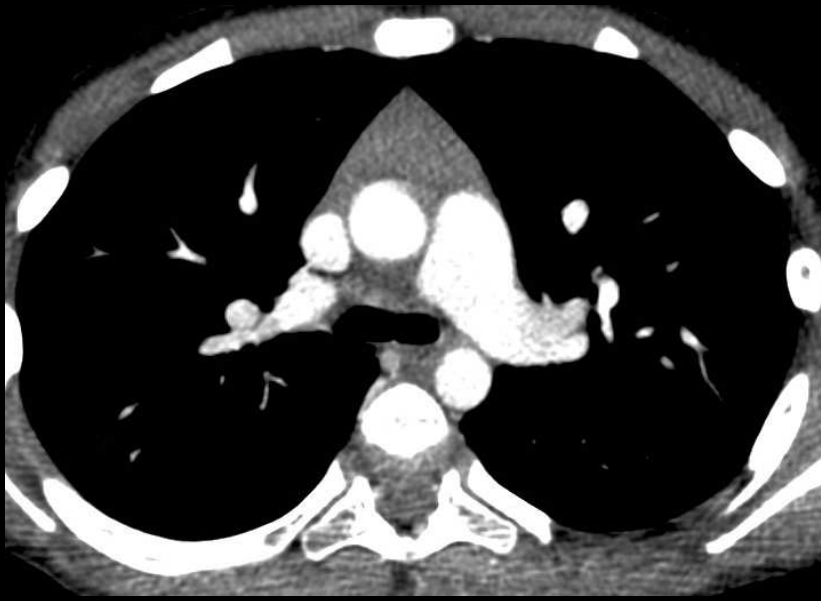Principaux changements 1997 vs 2009 :

1. **T4 nodule même lobe → T3**
2. **T4 dissémination pleurale ou péricardique → M1**
3. **M1 nodule supplémentaire autre lobe ipsilatéral → T4**

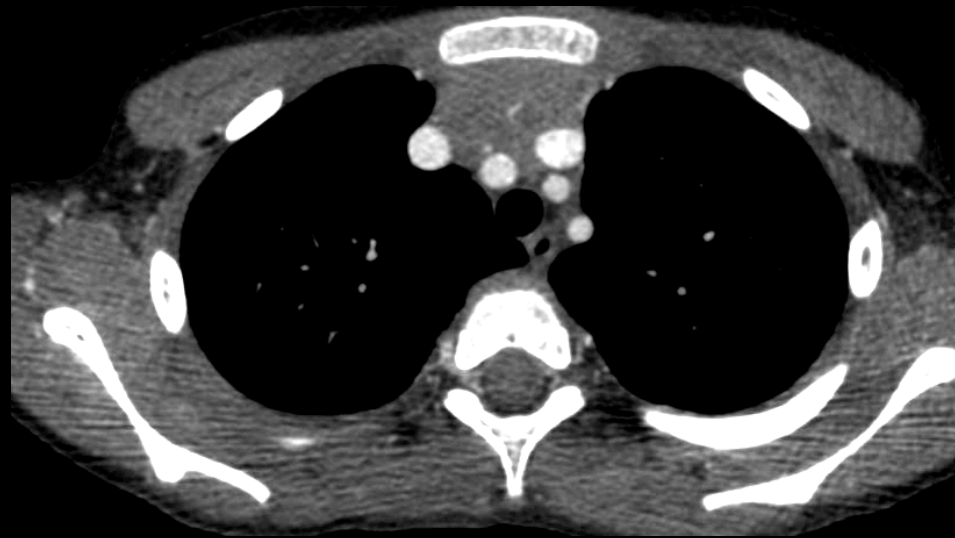- **Reclasser la dissémination pleurale de T4 à M1a**
- **Classer la présence de nodules controlatéraux en M1a**
- **Classer la présence de métastases à distance en M1b**

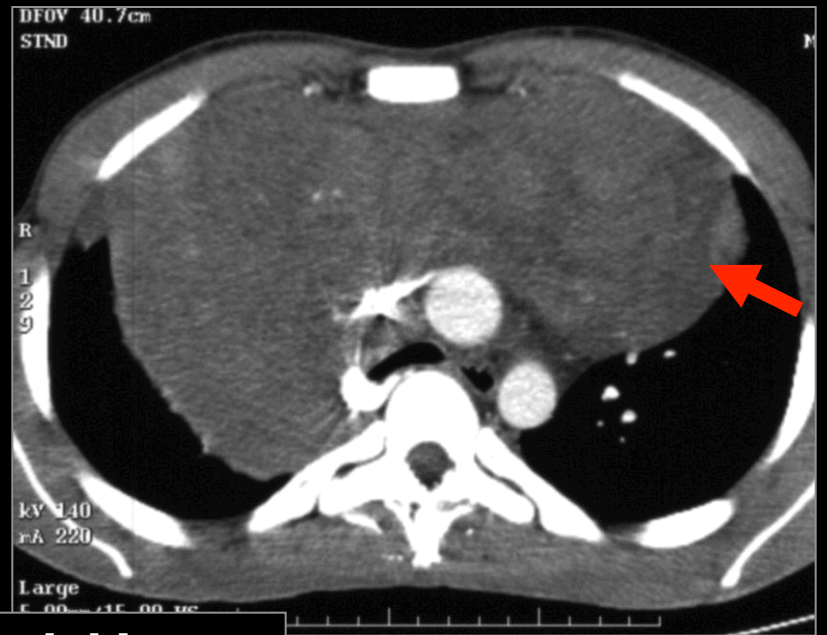
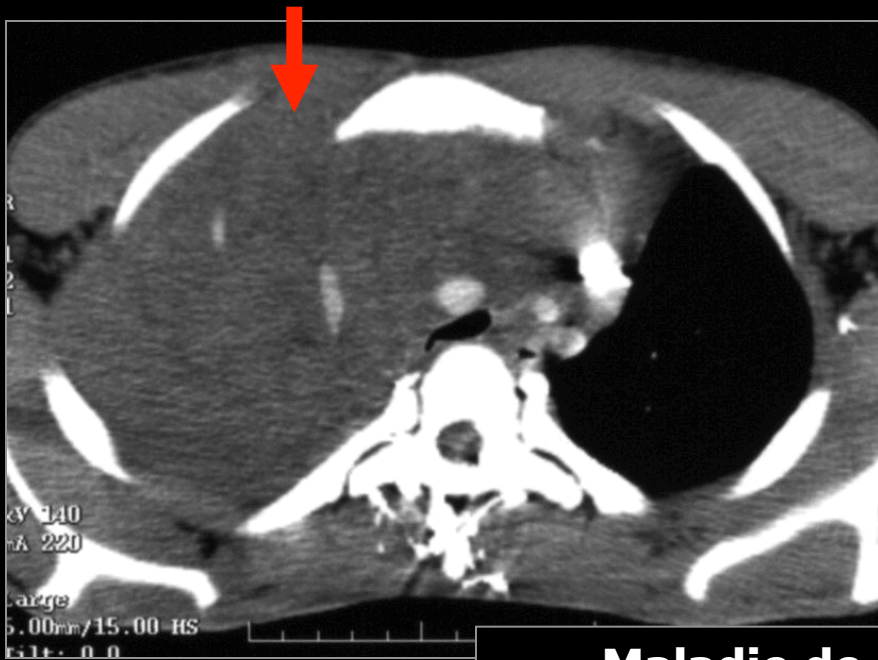

**UN PEU DE PATHOLOGIE ET
VARIATIONS ANATOMIQUES...**

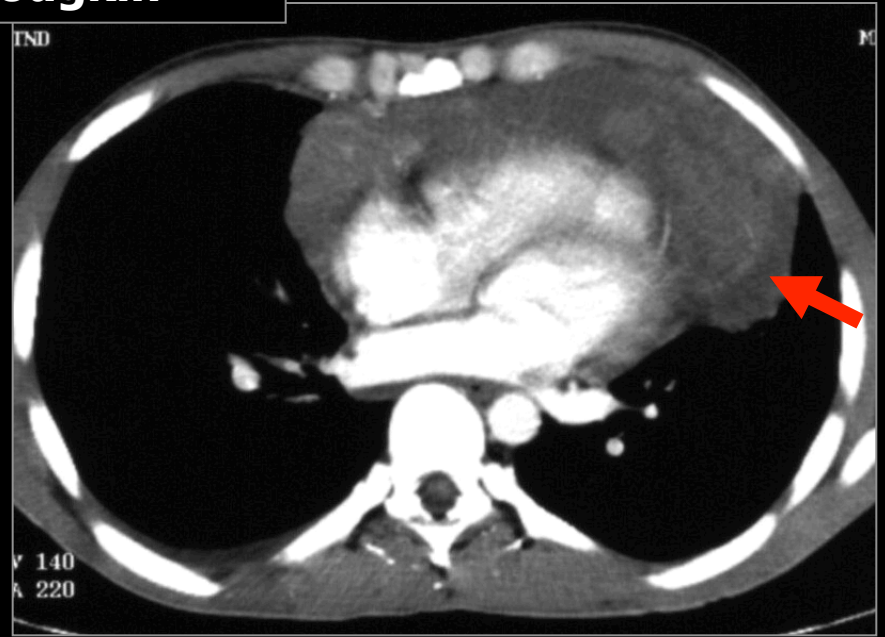
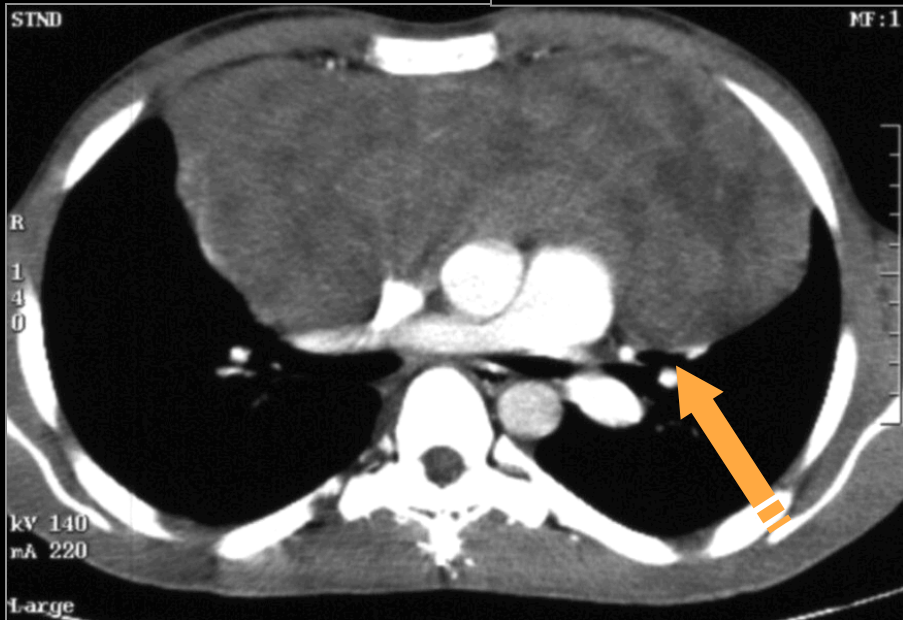


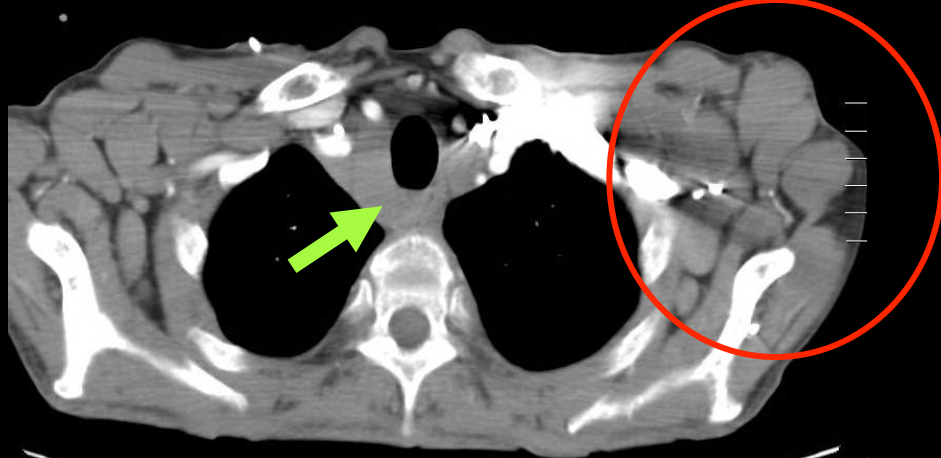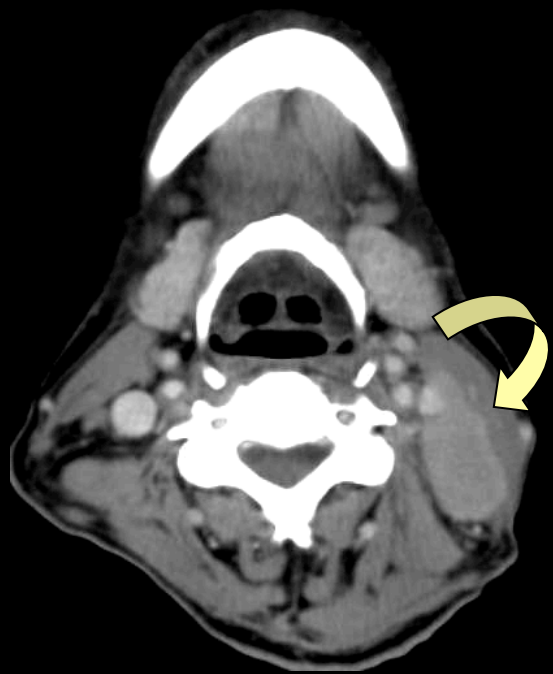
Thymus



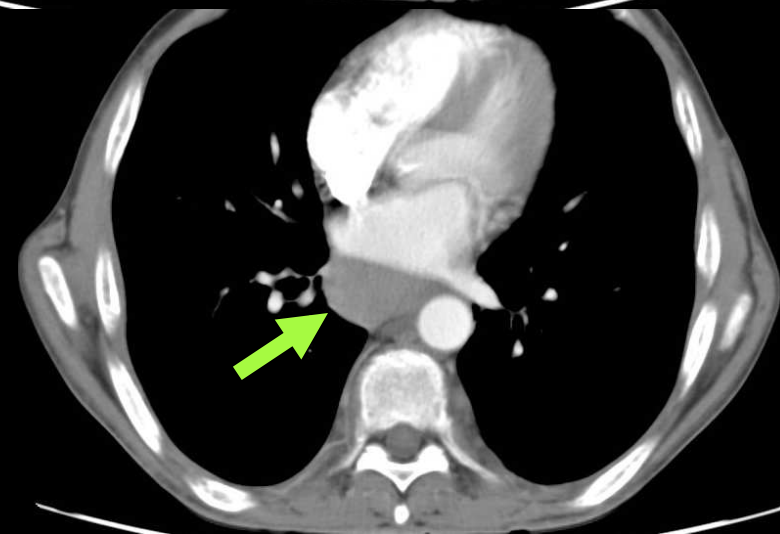
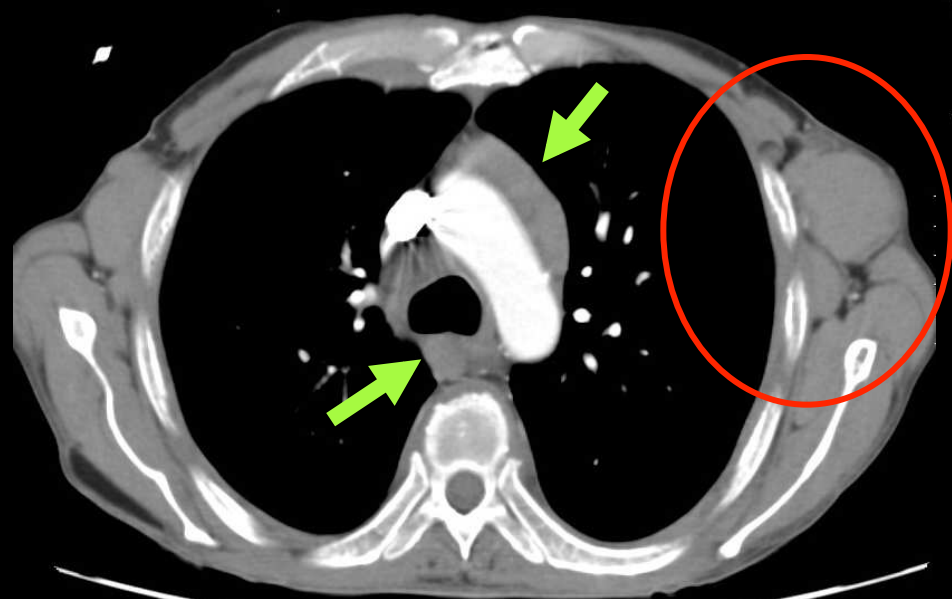
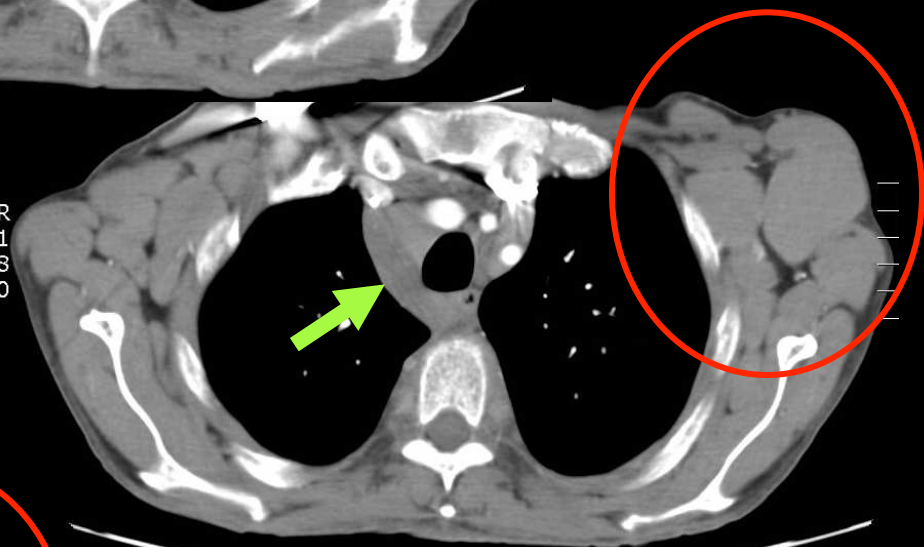


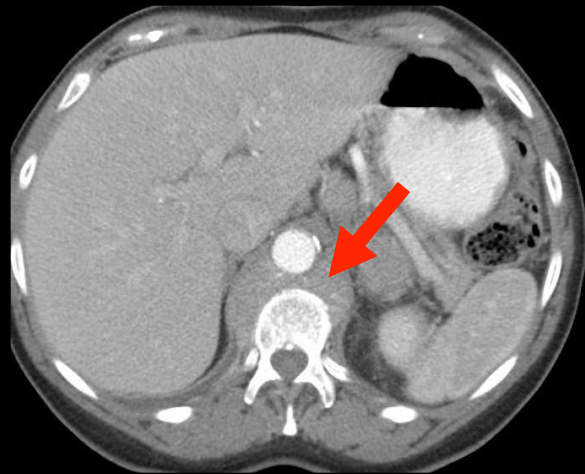
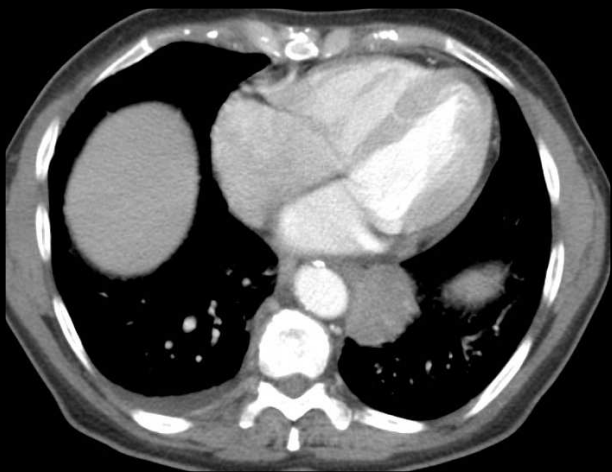
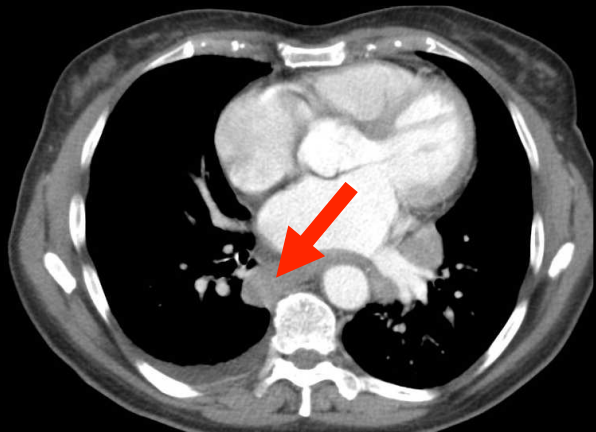
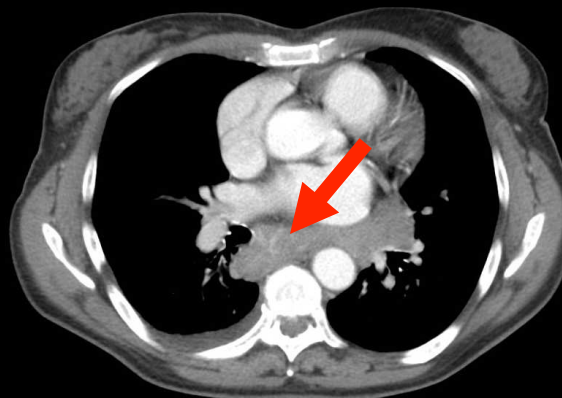
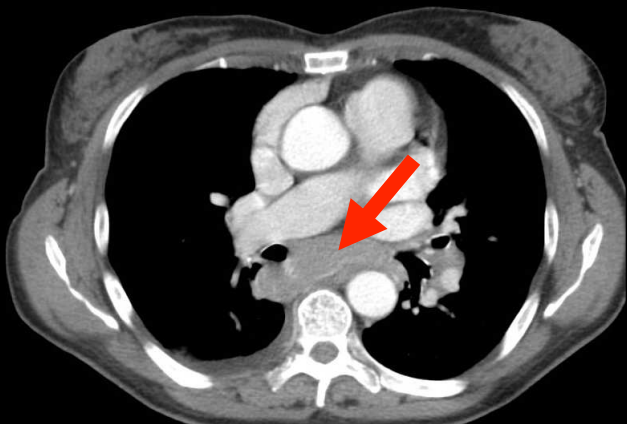
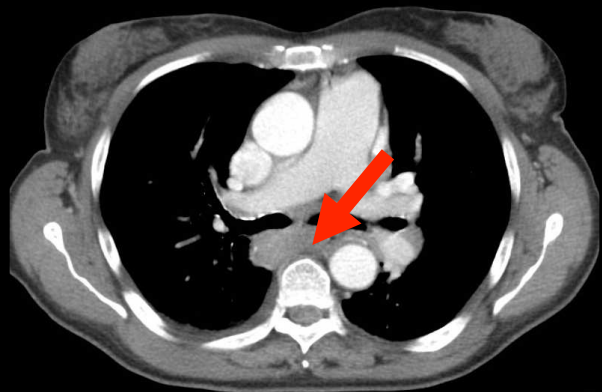
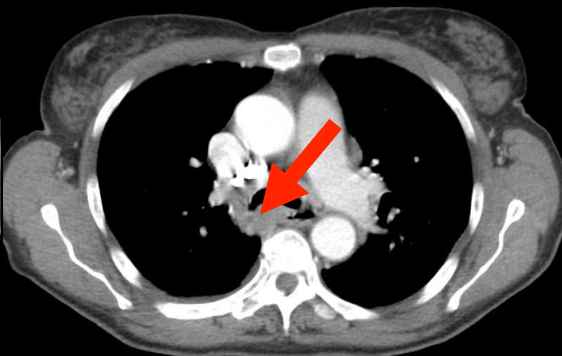
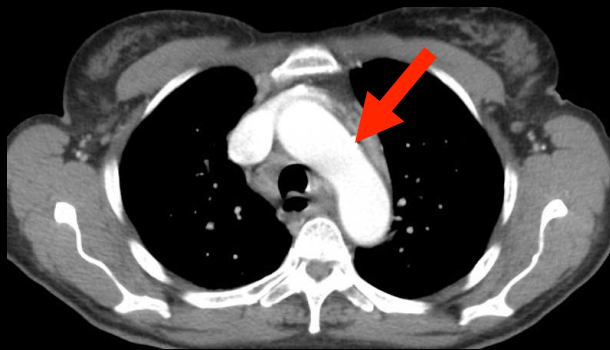
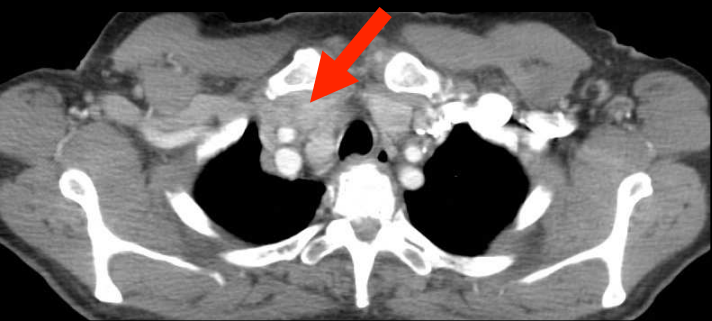
Maladie de Hodgkin

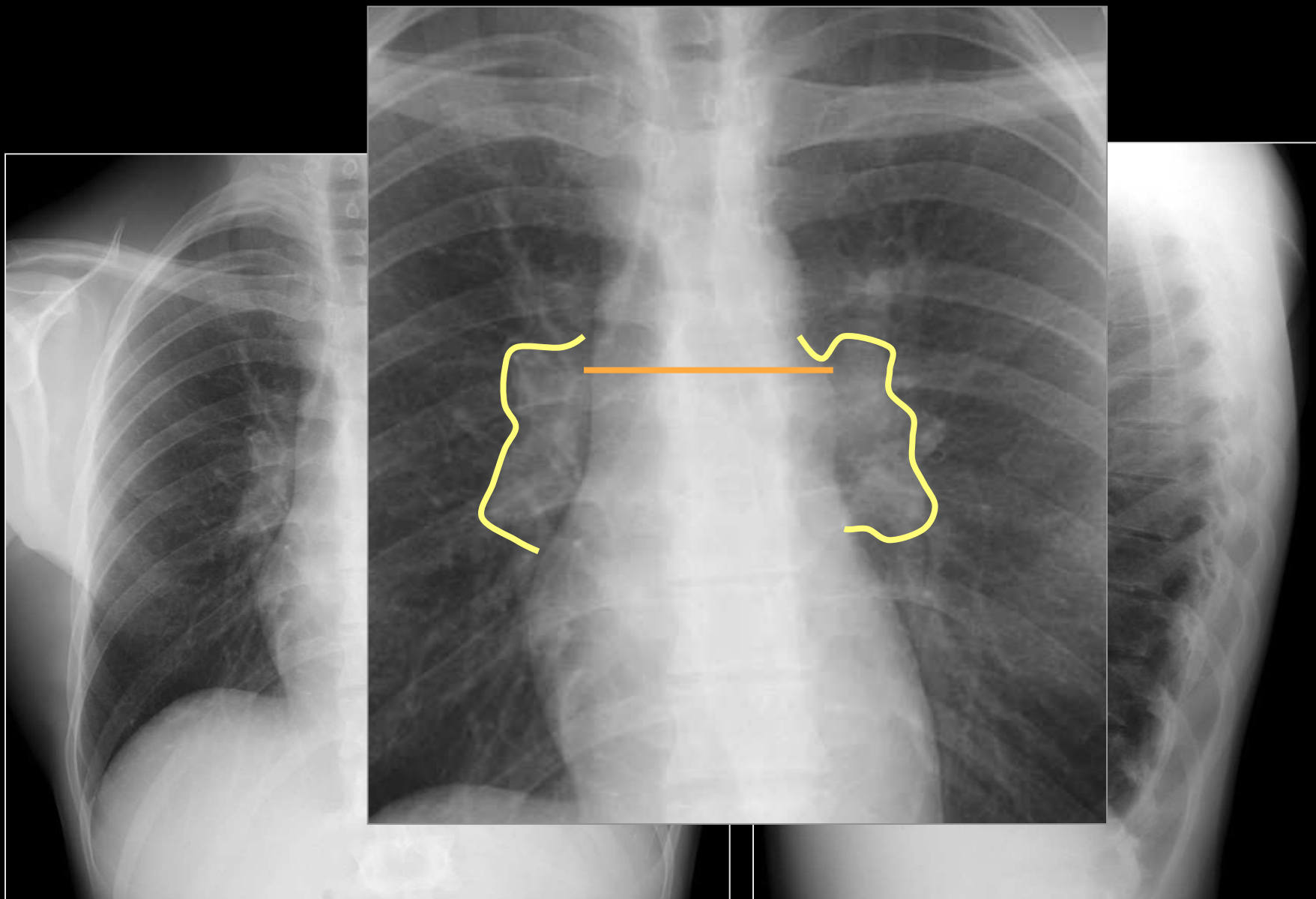




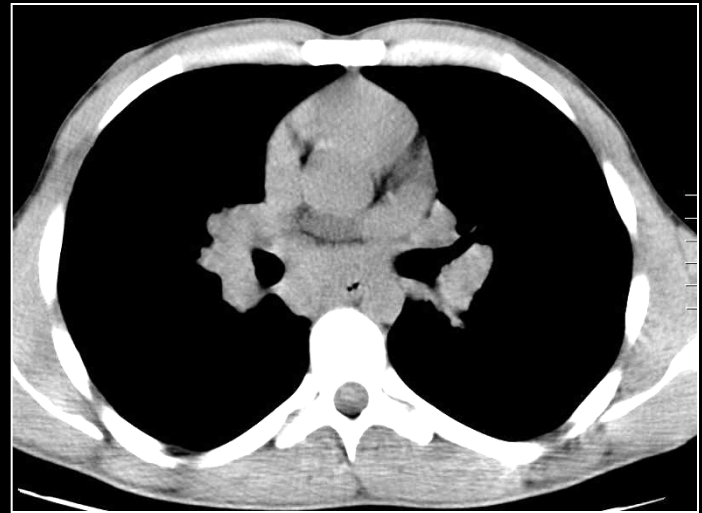
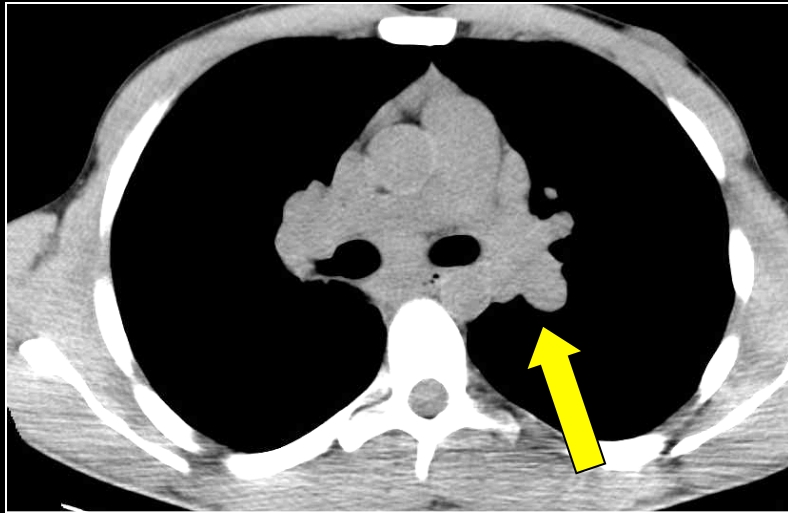
R
1
8
0



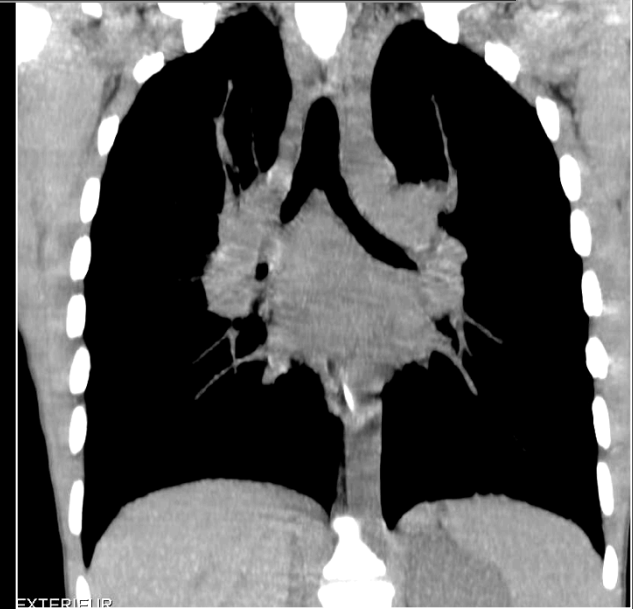
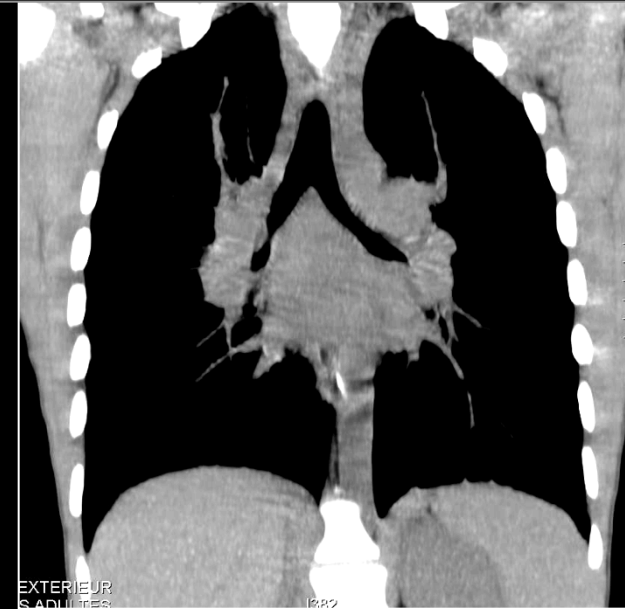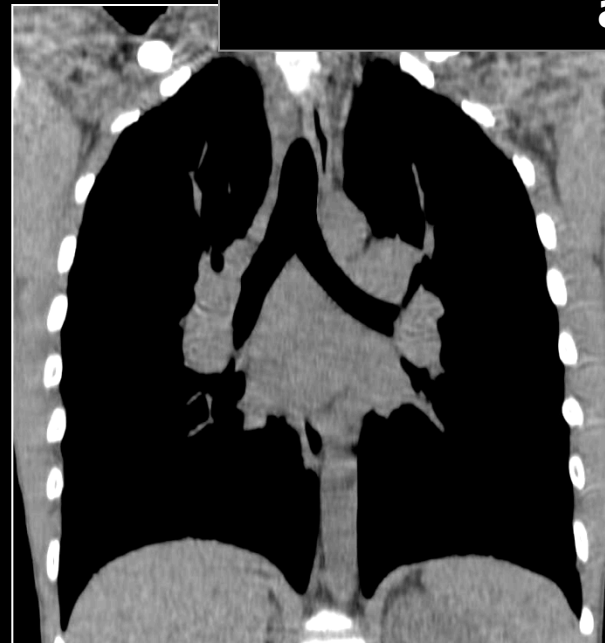



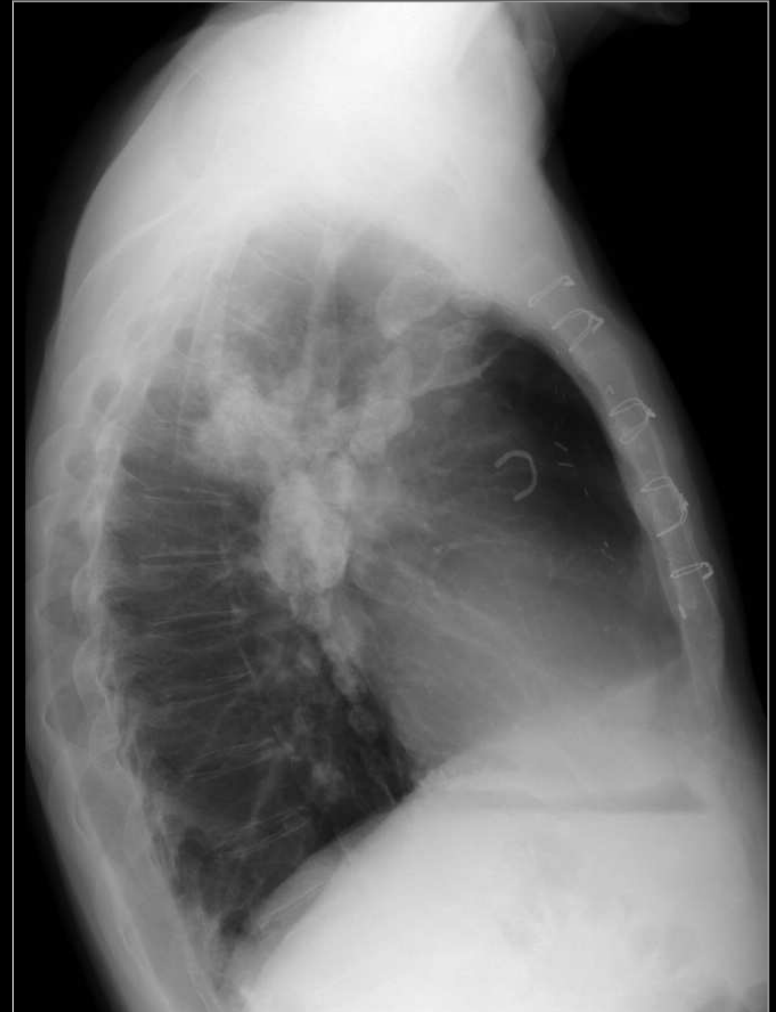
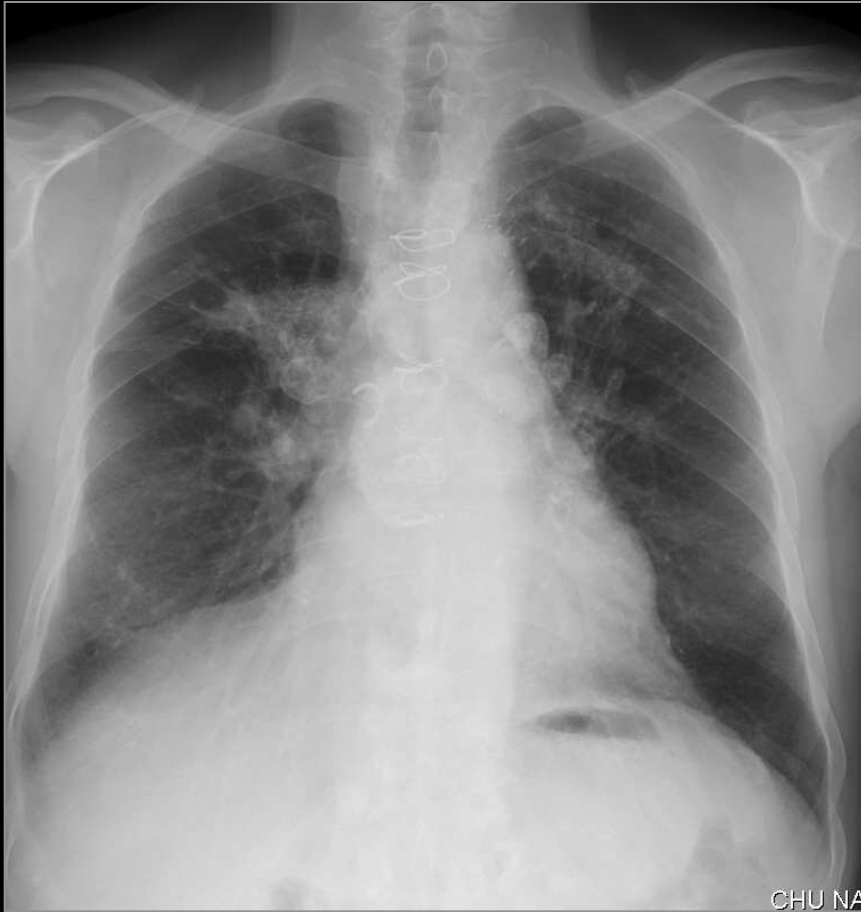**ADENOPATHIES ET GANGLIONS MEDIASTINAUX à
prédominance inter bronchique**

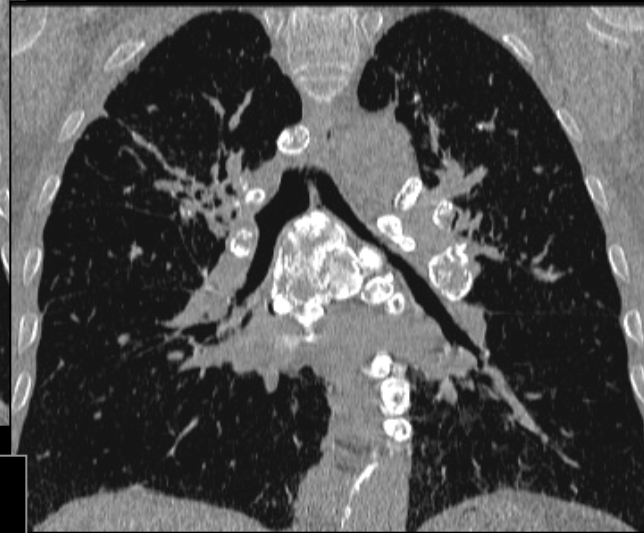
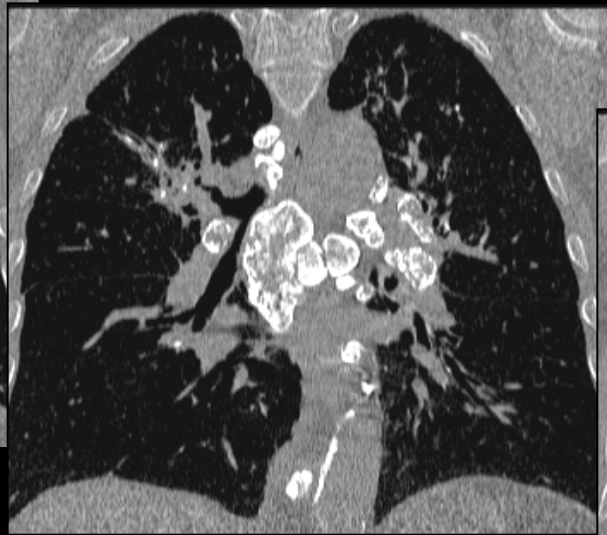
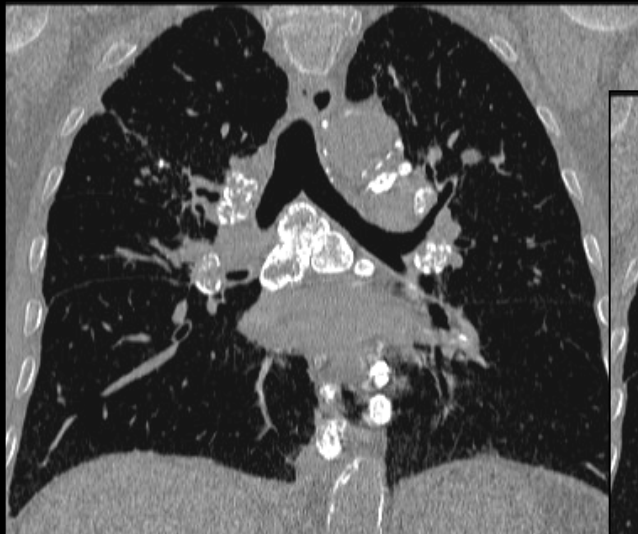
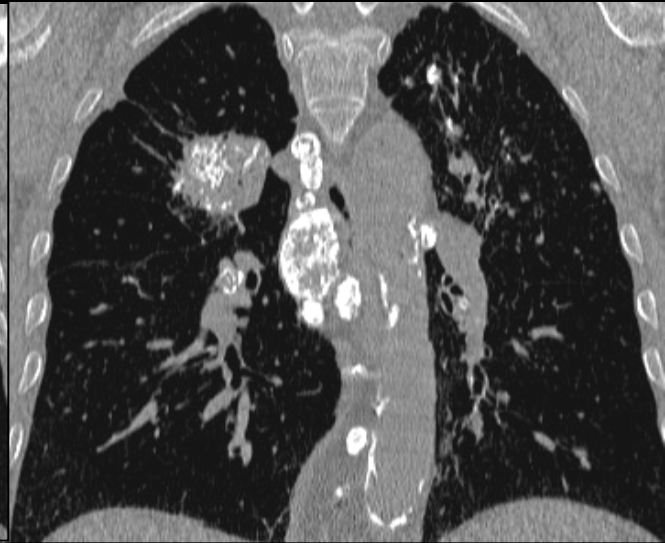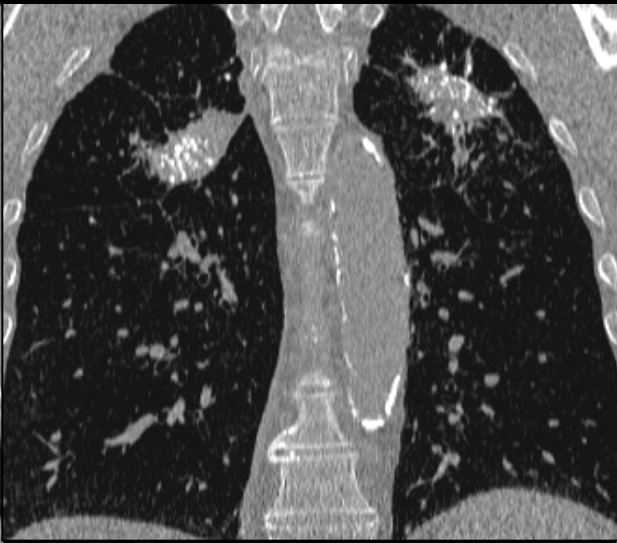

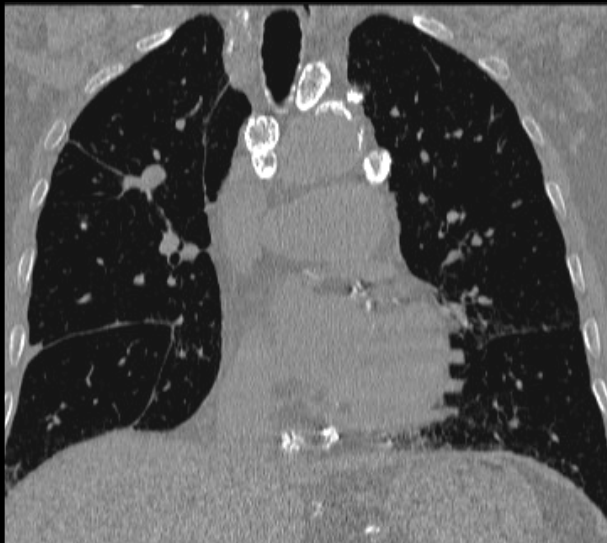
**ADENOPATHIES ET GANGLIONS MEDIASTINAUX
à prédominance inter bronchique**



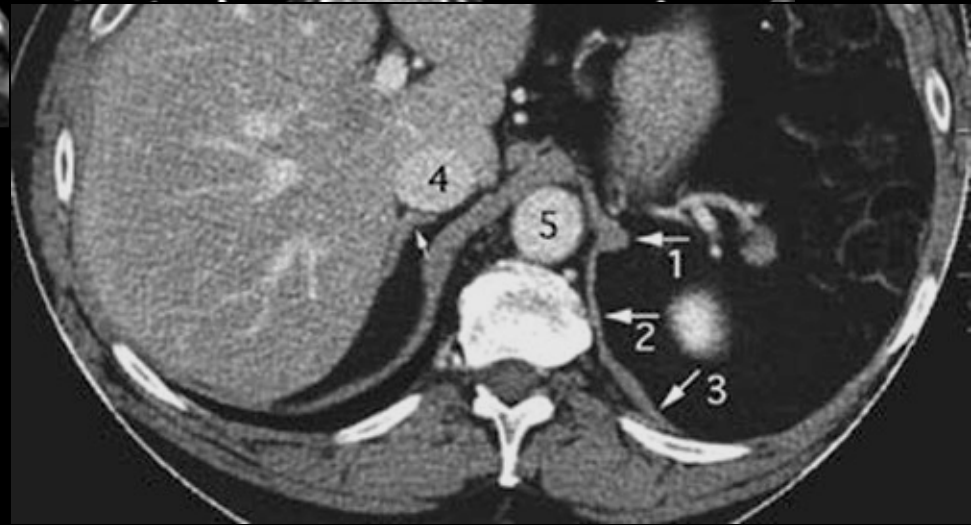
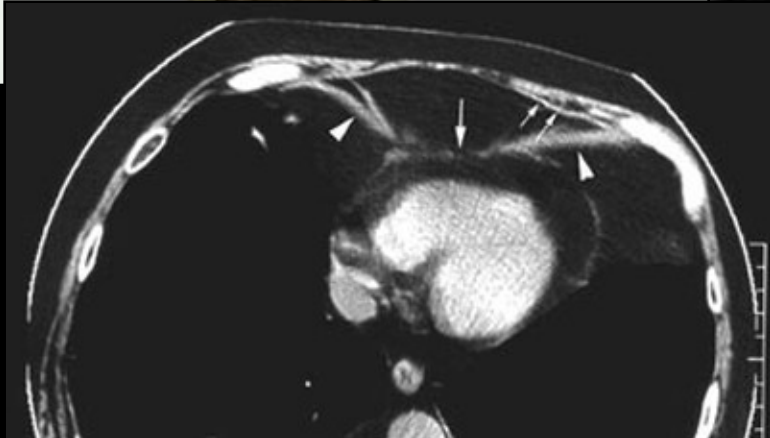
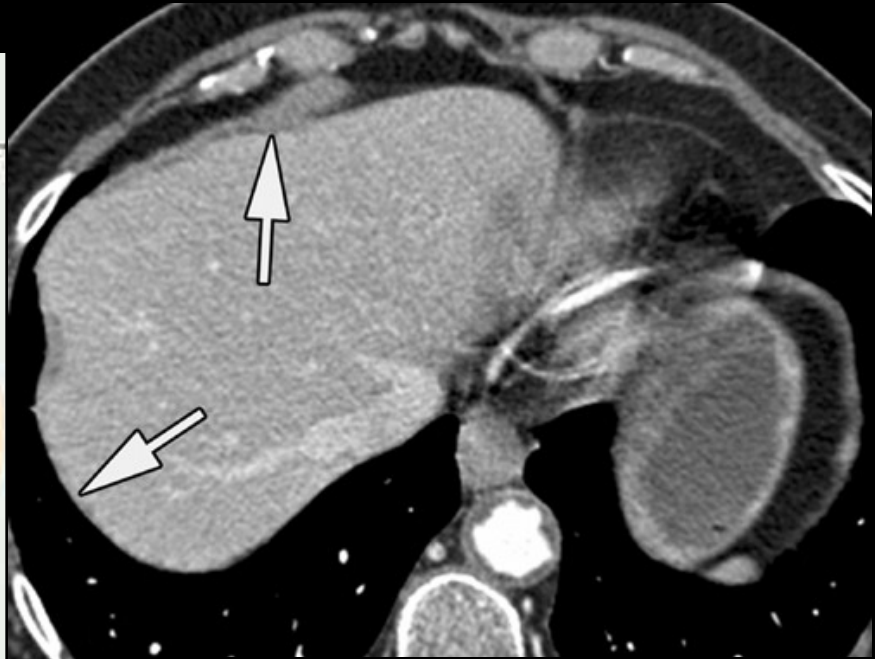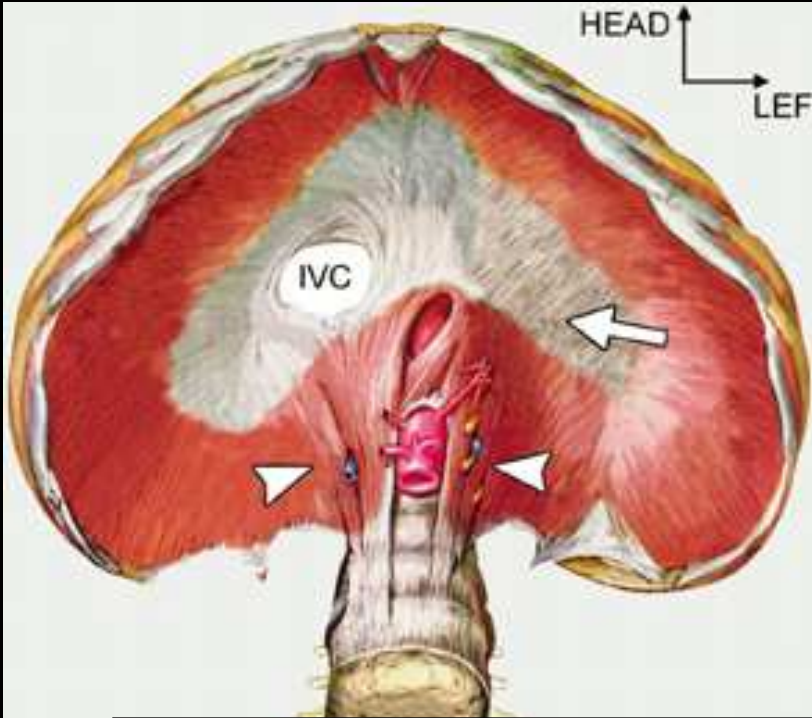


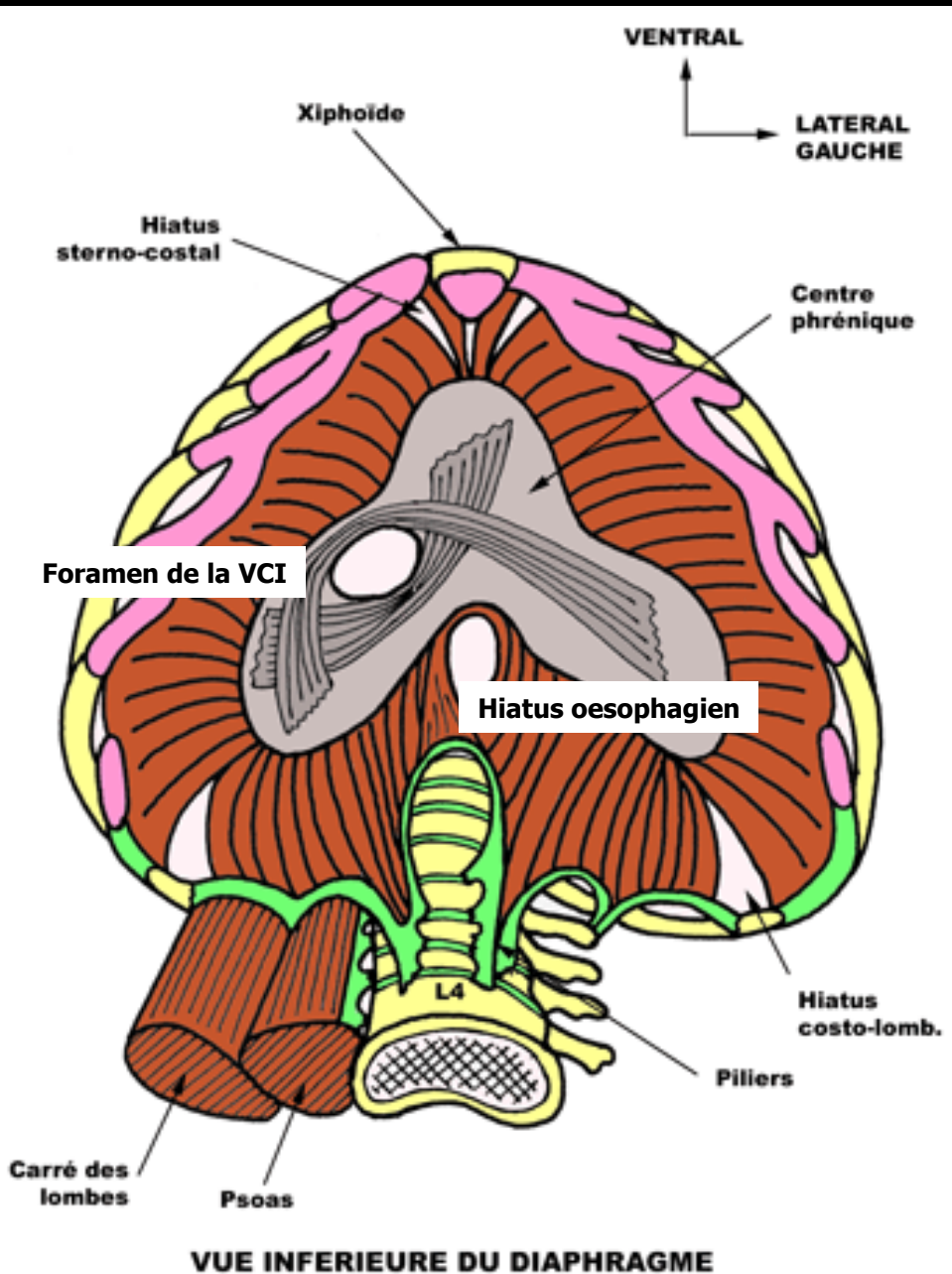
Élargissement hilare droit et médiastin



ADP calcifiées et masses biapicales : silicose

DIAPHRAGM





Orifices :

• T12 :

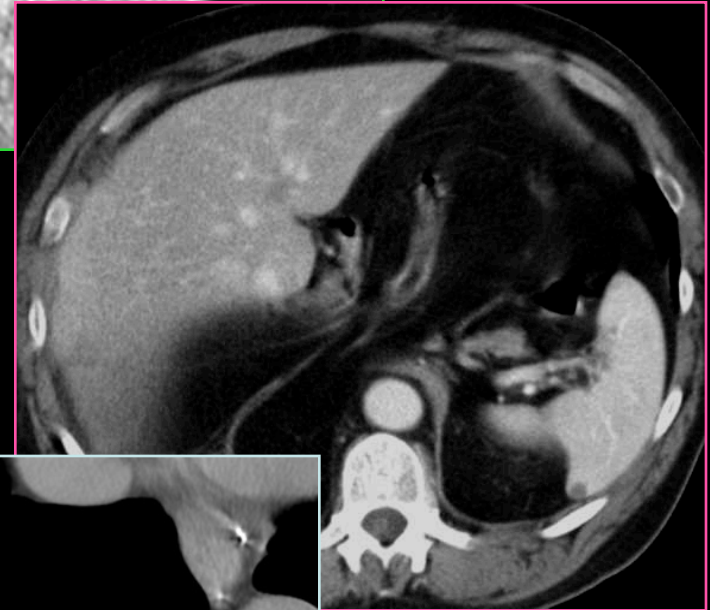
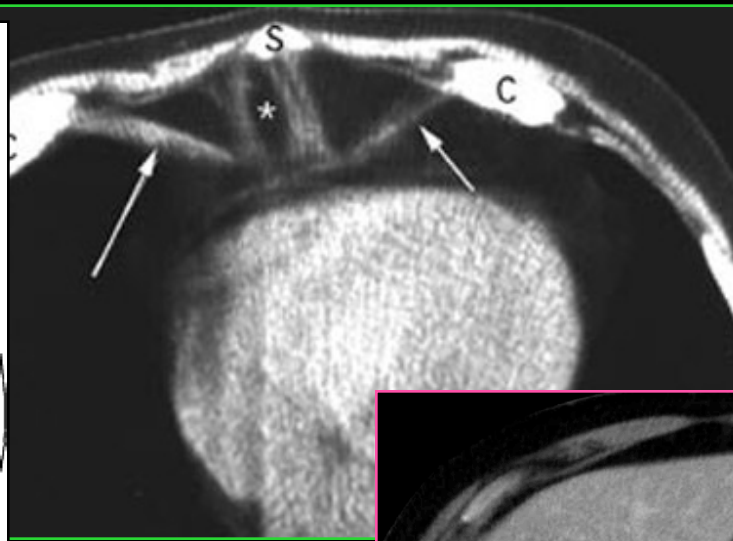
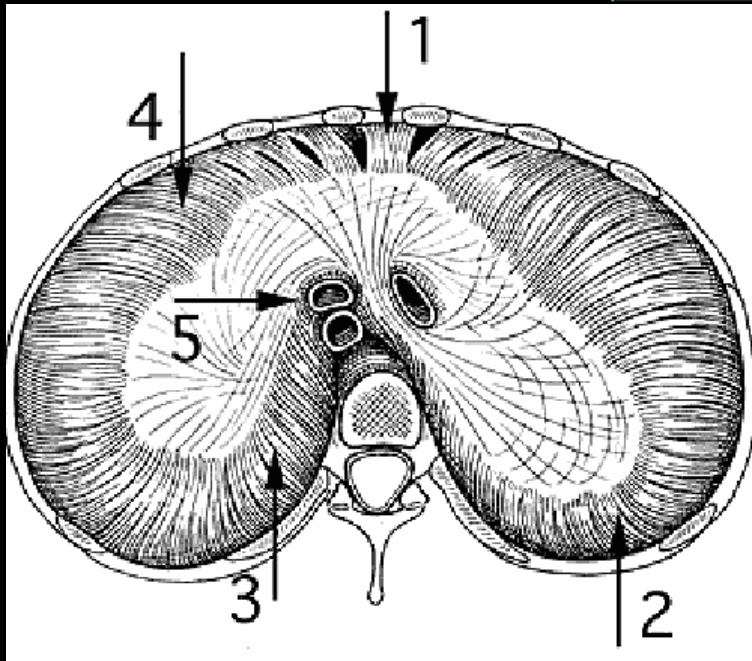
- AO
- Canal thoracique

• T10 :

- œsophage
- Nerfs X

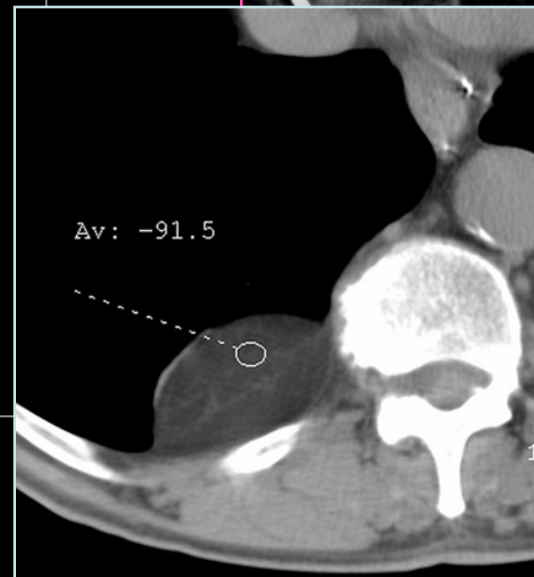• T9 :

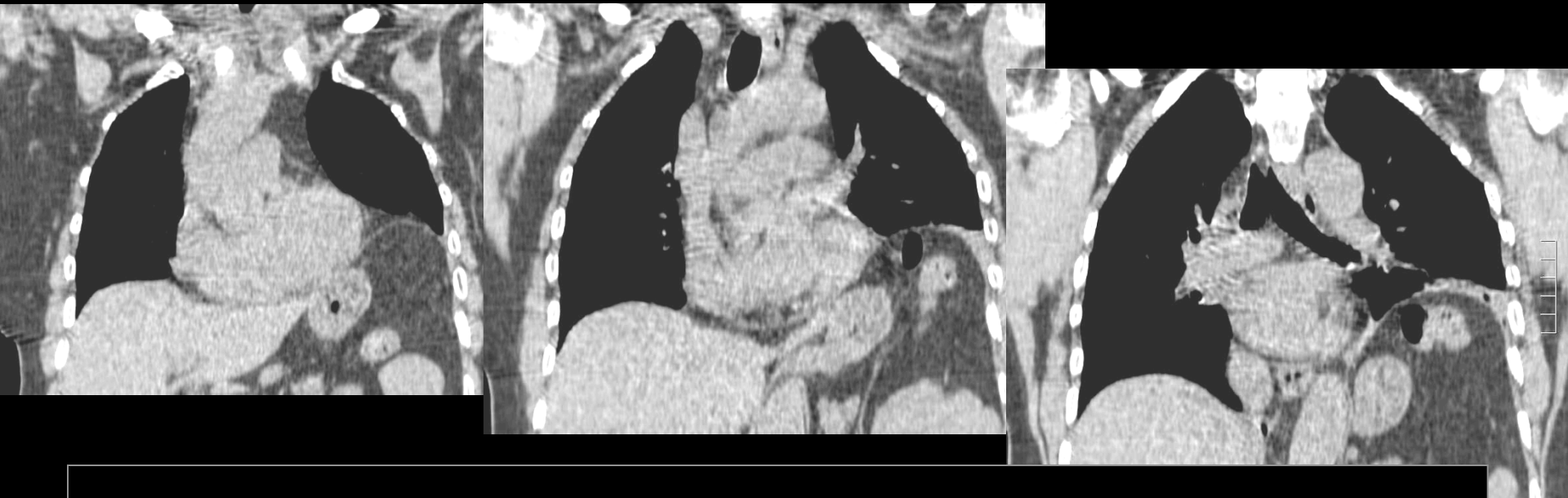- VCI
- N. phrénique D



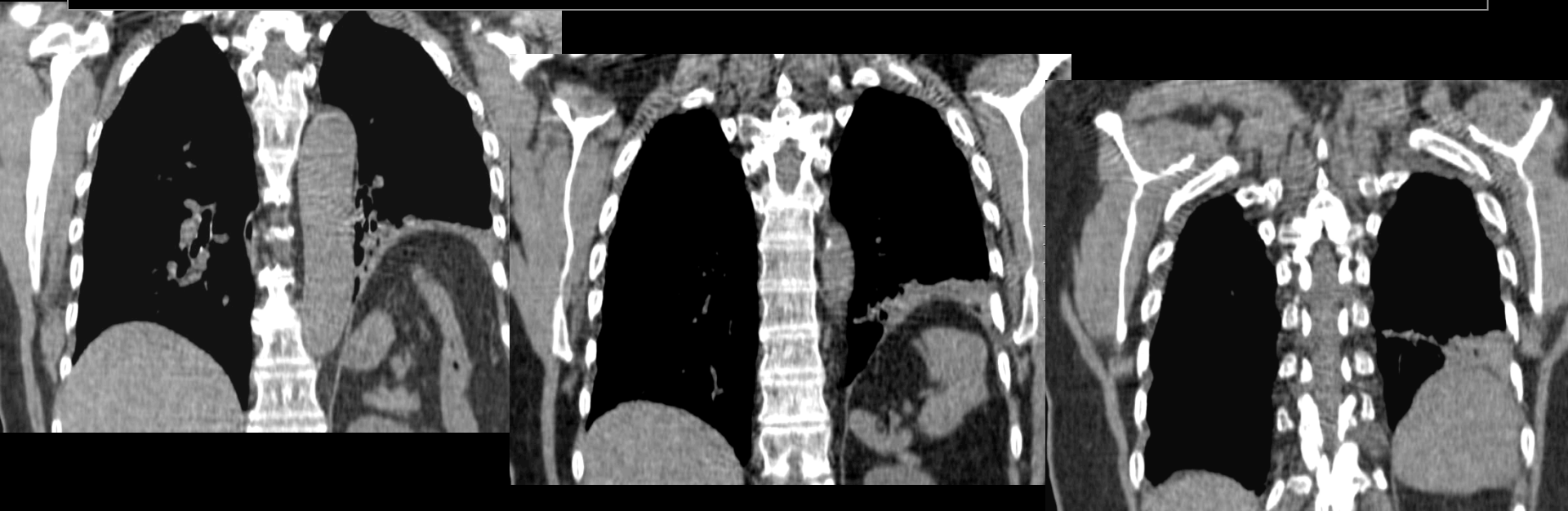Points de faiblesse :

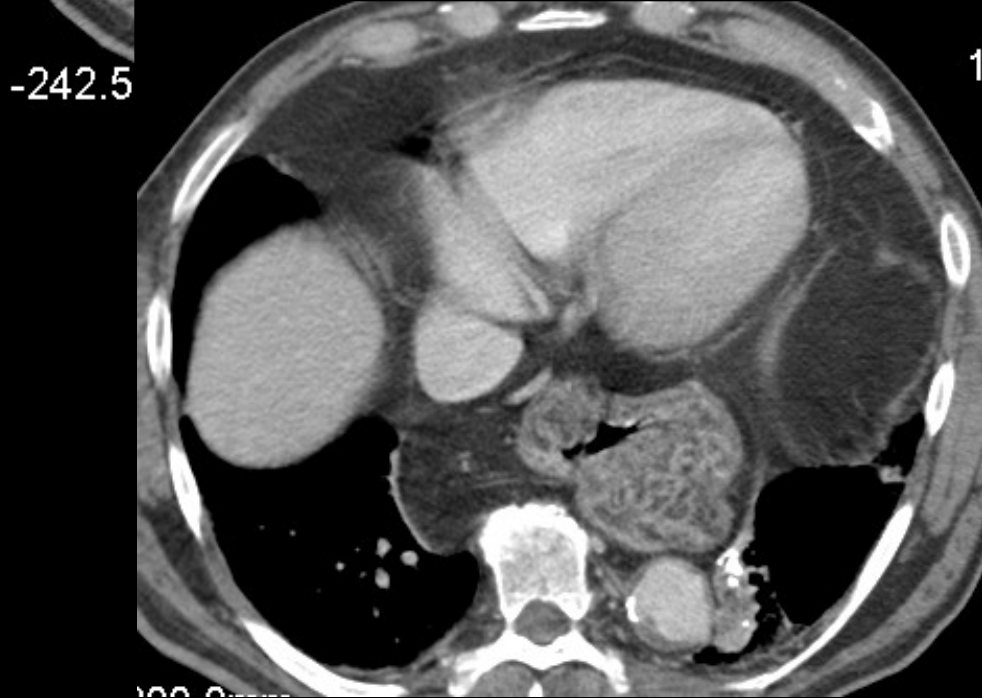
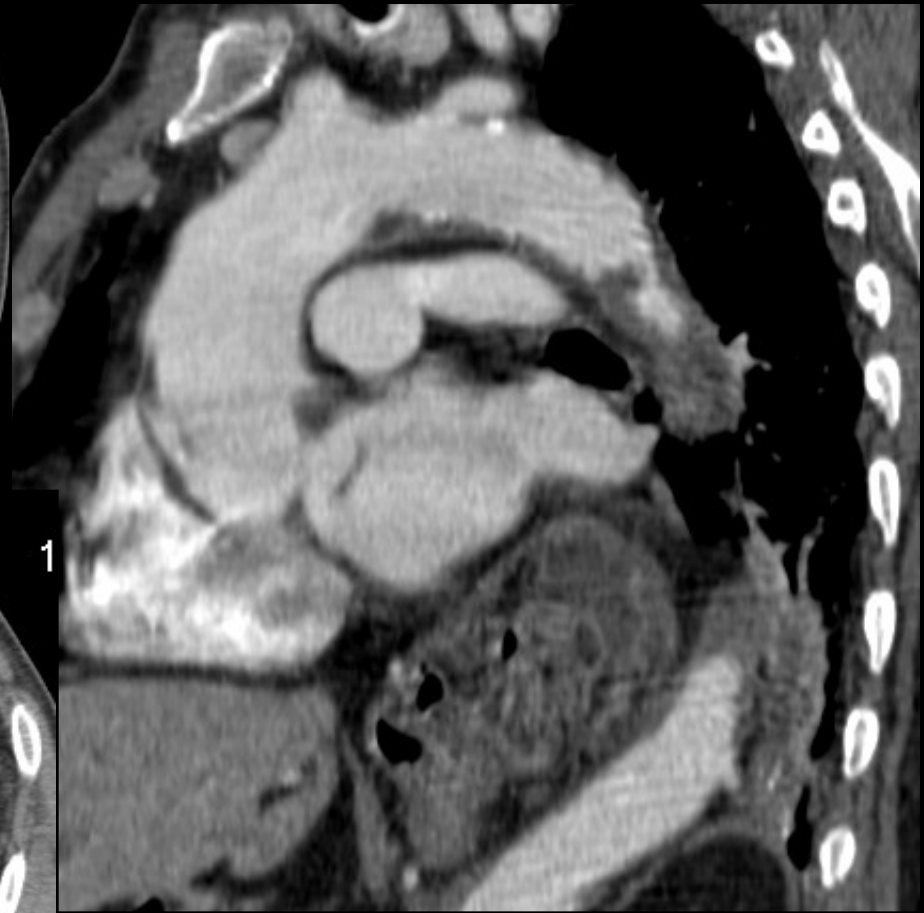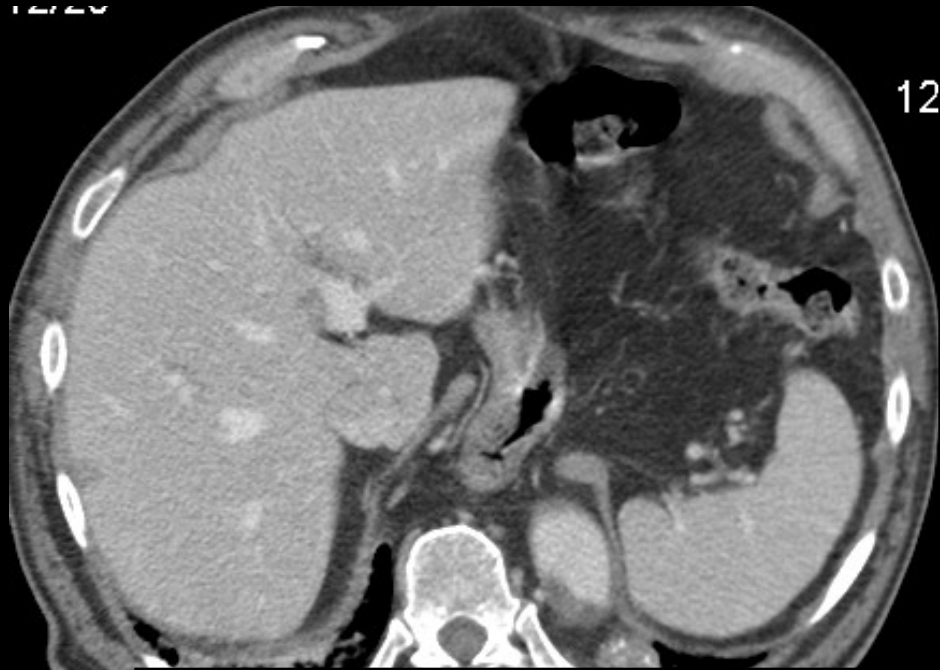- Hiatus postérieur : Bochdalek
- Hiatus rétro-costo-xyphoïdiens
 - lat : Morgani
 - médian : fente de Larrey
- Hiatus oesophagien





Paralysie phrénique ou éventration (relaxation) diaphragmatique ; cinétique diaphragmatique à vérifier (cliché inspi/expiré ou scopie TV low dose)

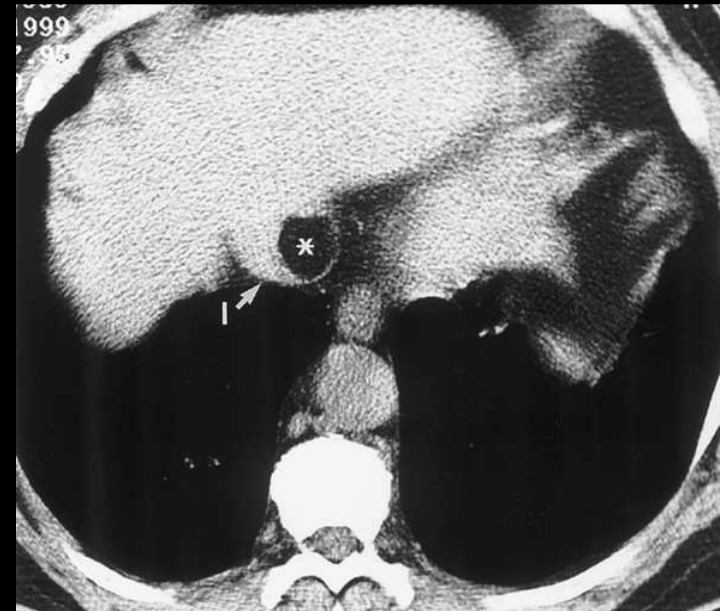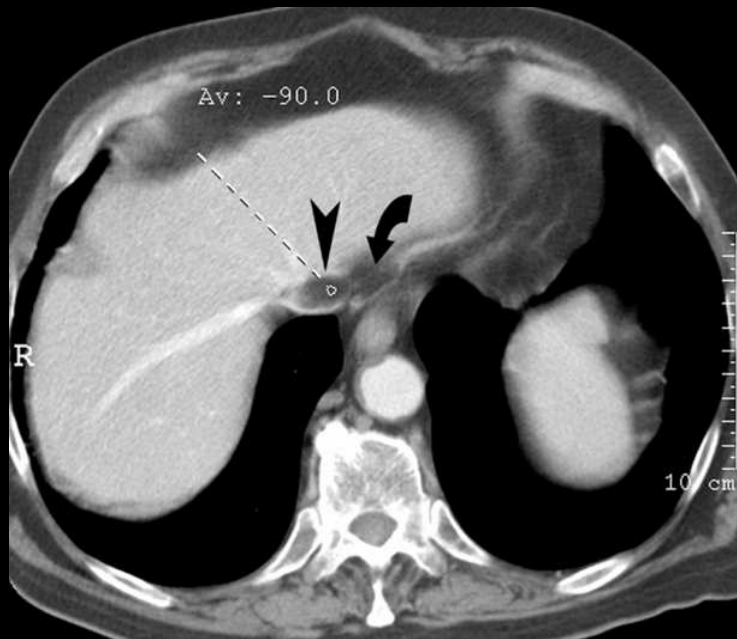
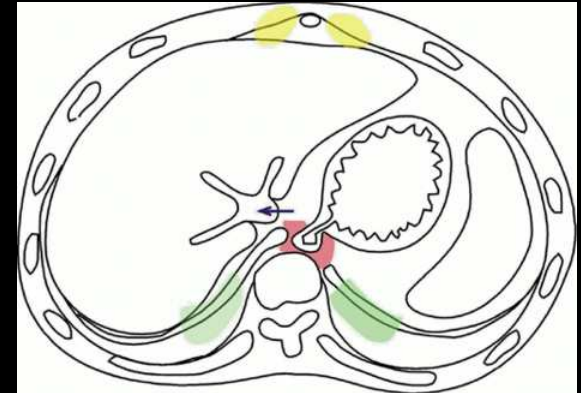




HH par glissement

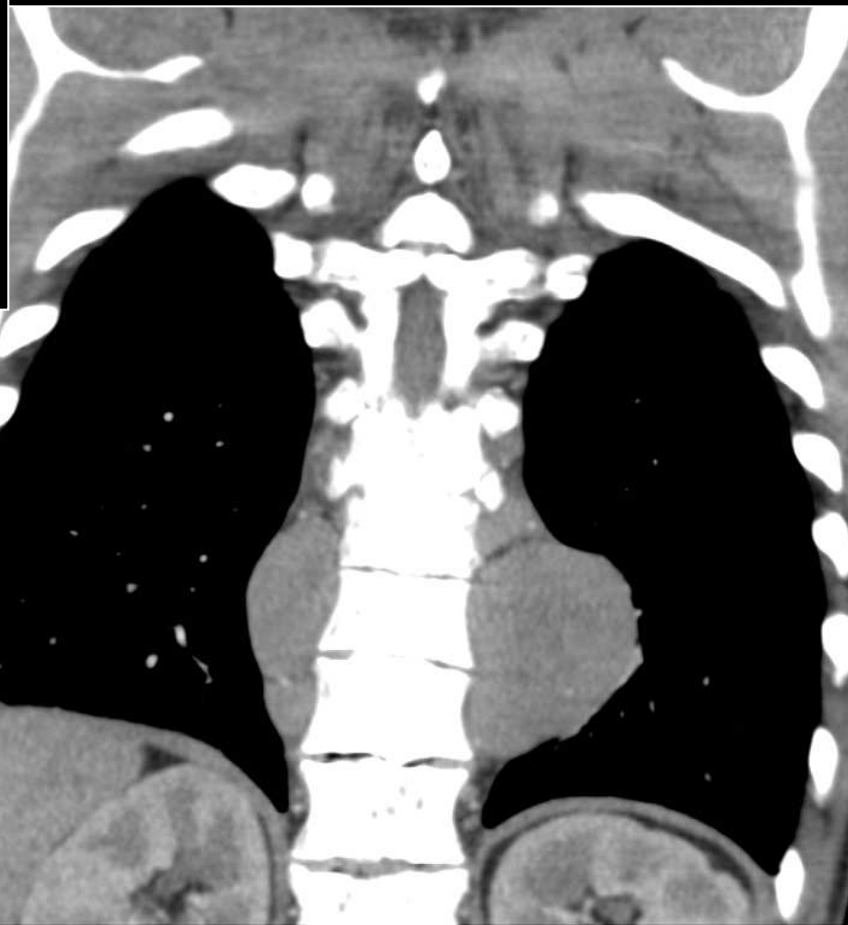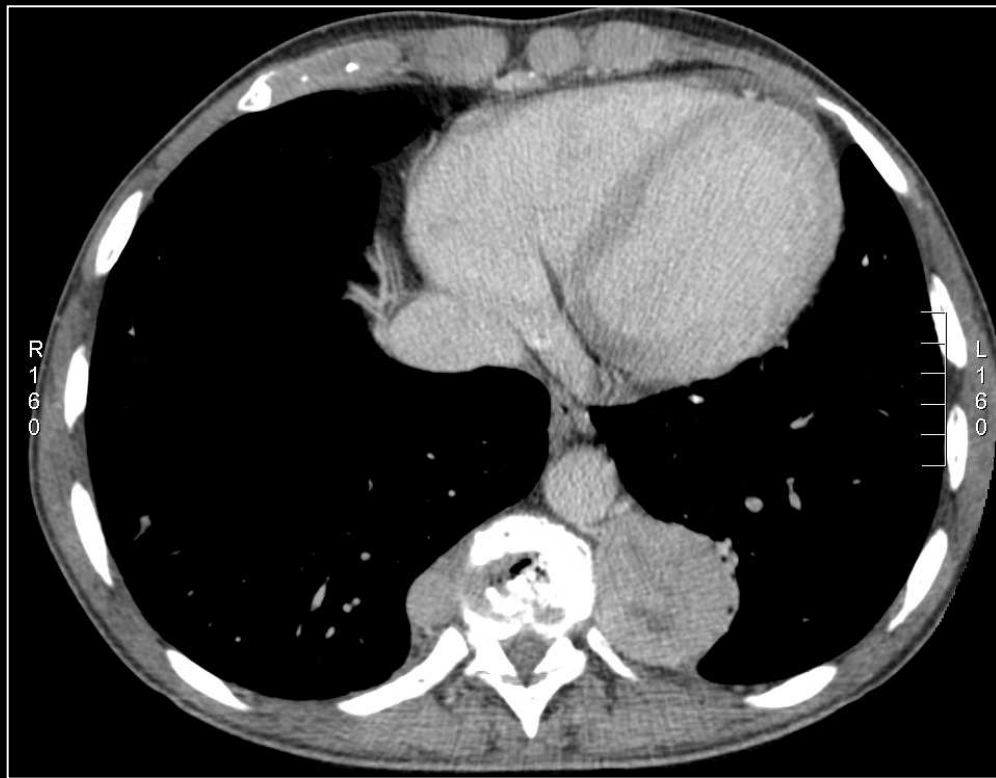
PSEUDO-LIPOME INTRA-CAVE

- confluence v sus-hép/VCI
- en continuité avec graisse péri-oesophagienne
- IIaire angulation et rétrécissement portion médiale de la VCI
- image variable selon la respiration



A retenir

- Lésions du médiastin antérieur :
 - Thyroïde
 - Thymus
 - Lymphome
 - Tumeur germinale
- Lésions du médiastin antéro-inférieur :
 - Kyste pleuro-péricardique
 - hernie de la fente de Larrey
 - Lipome, hémangiome, lymphangiome
- Lésions du médiastin moyen :
 - Adénopathies
 - Kyste bronchogénique
 - Œsophage
 - Vasculaire
- Lésions du médiastin postérieur :
 - Hématopoïèse extramédullaire
 - Tumeurs neurogènes
 - Kyste bronchogénique
 - Abscès juxta-osseux (BK, etc)

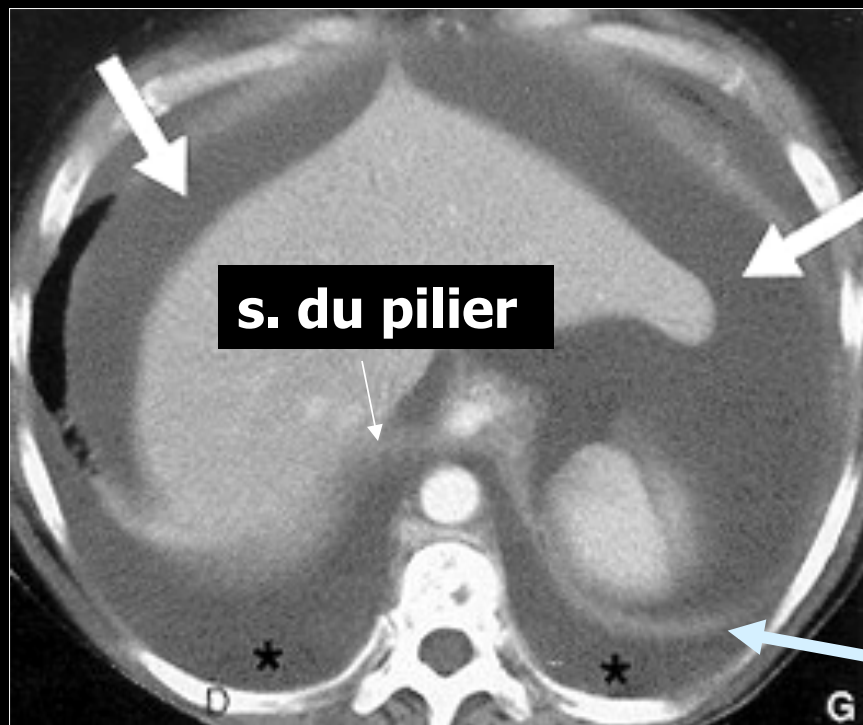
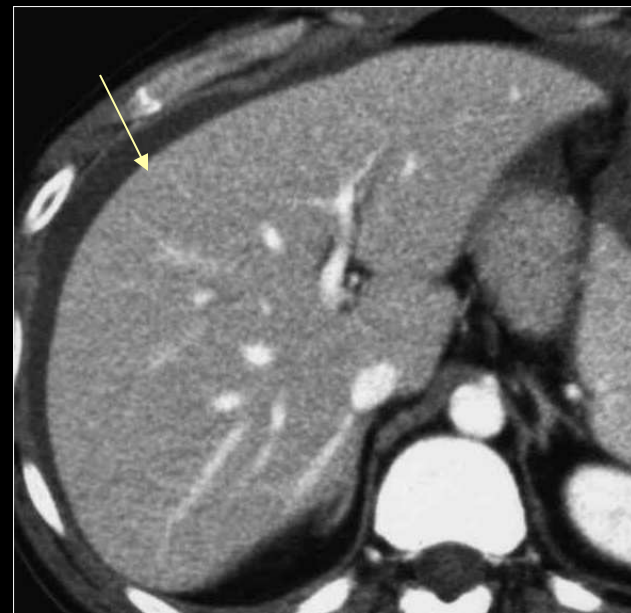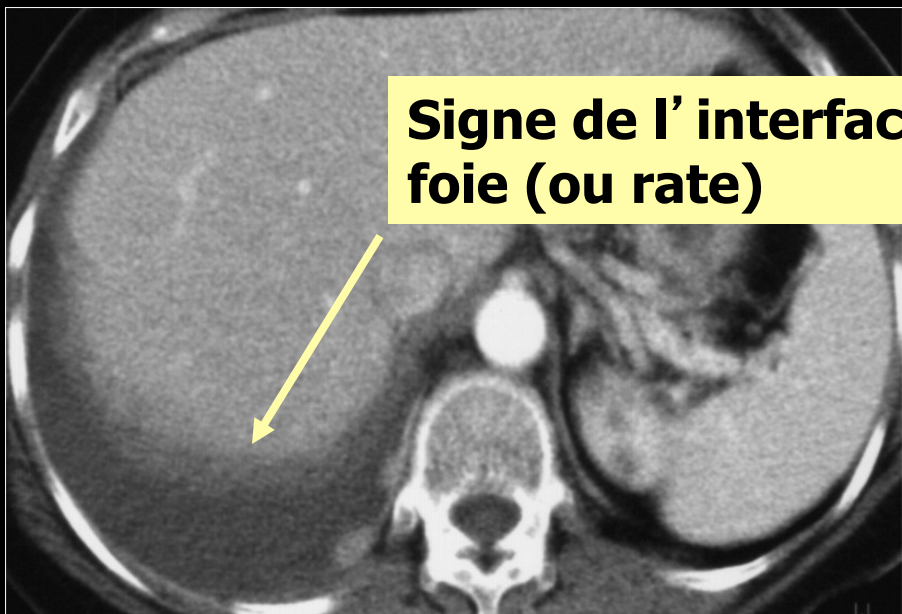


**Hématopoïèse
extramédullaire**

3/ PAROI THORACIQUE

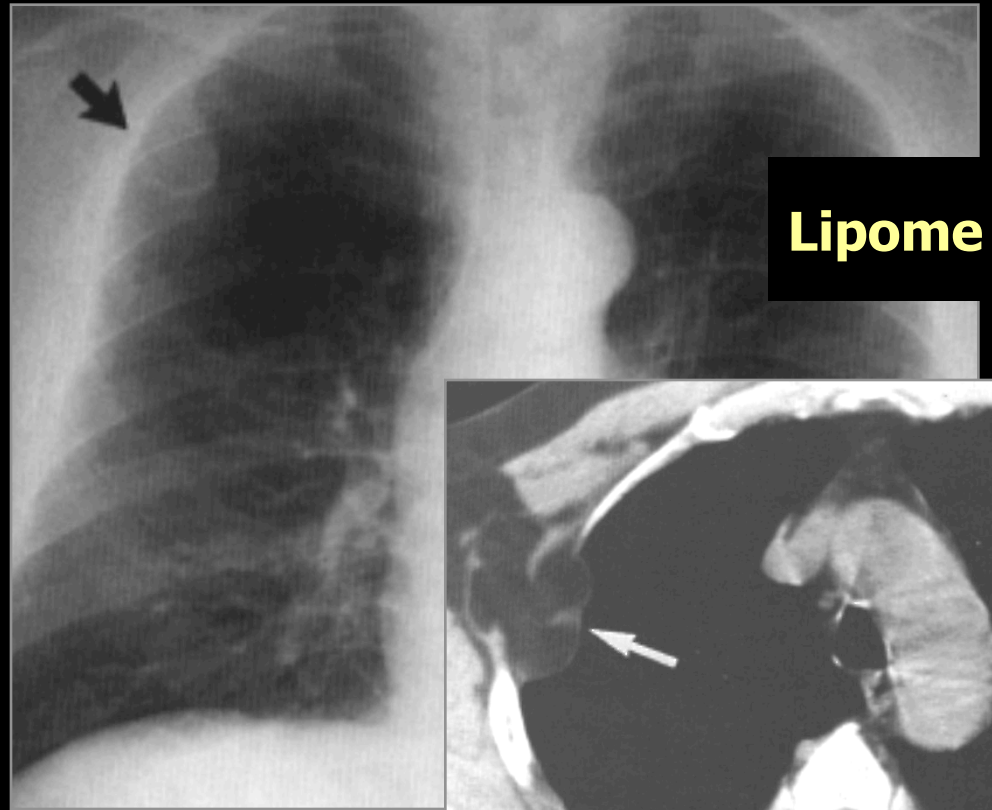
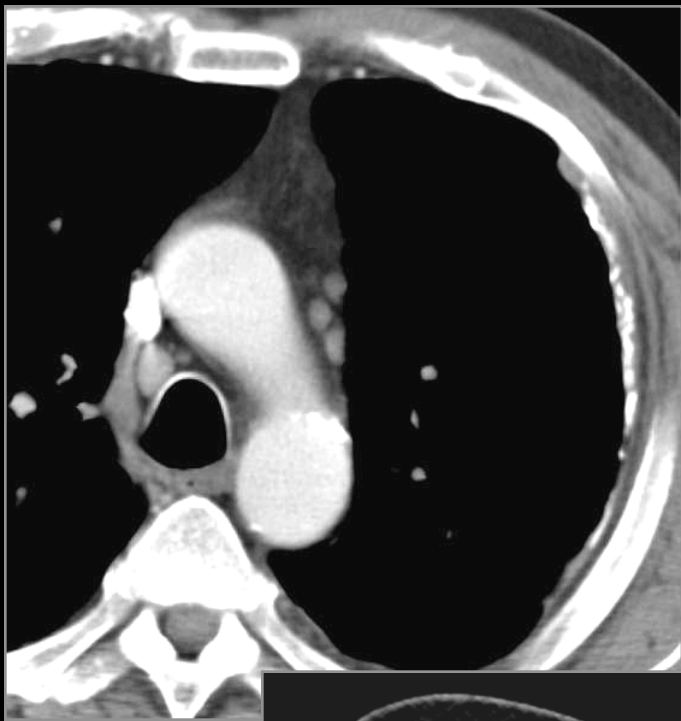- **PLEVRE**
- **CÔTES**

**Signe de l'interface
foie (ou rate)**

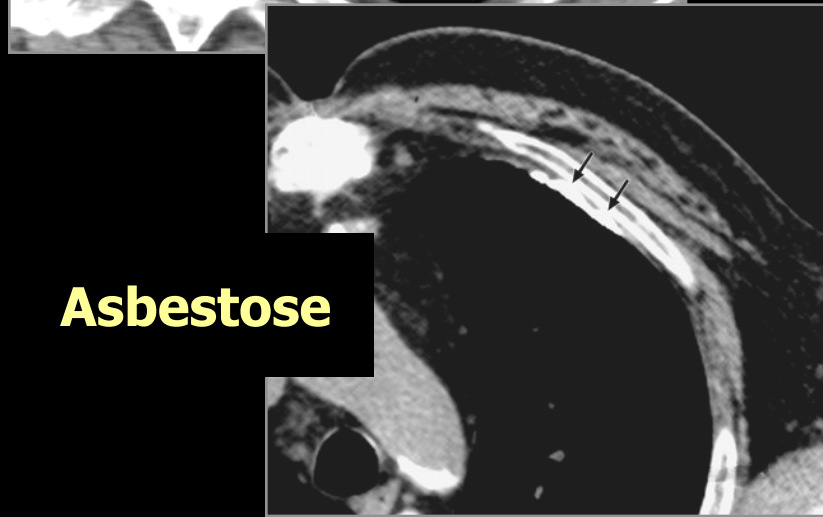


s. du pilier

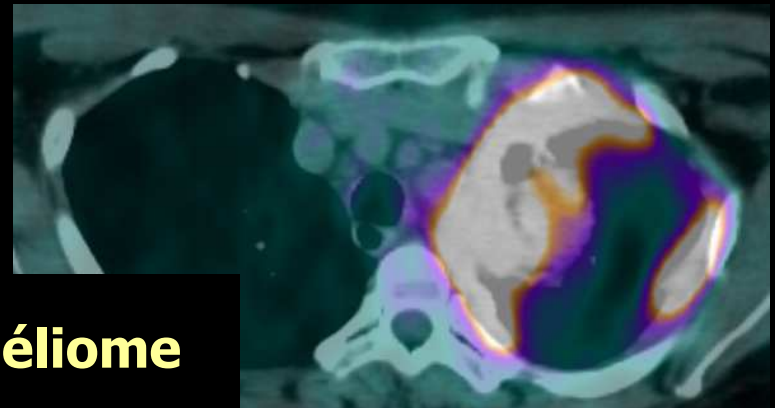
**s. du
diaphragme**



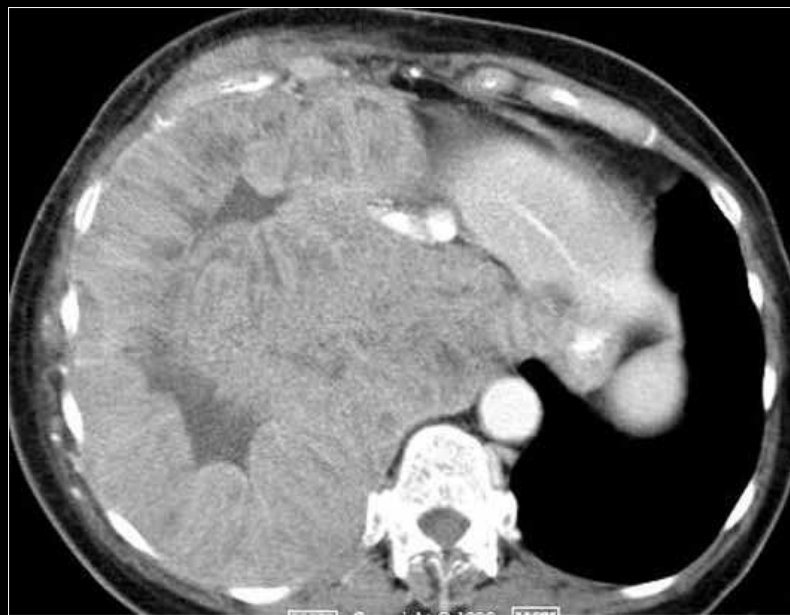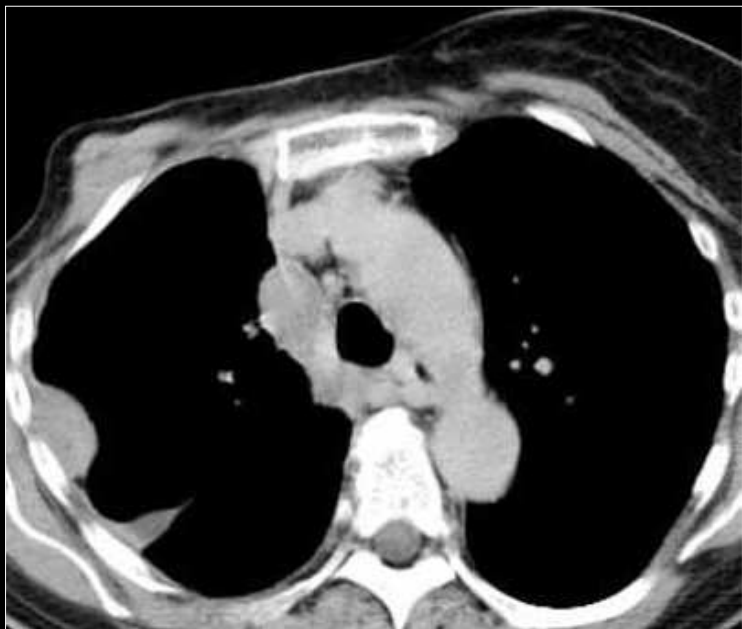Lipome



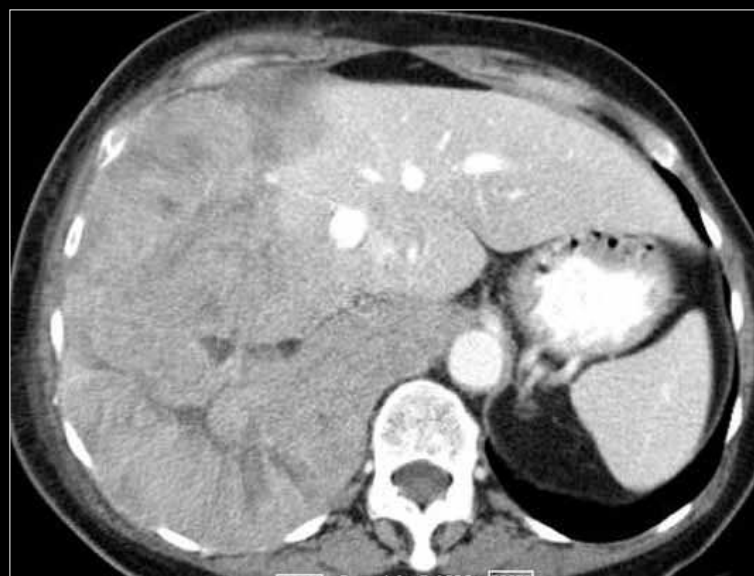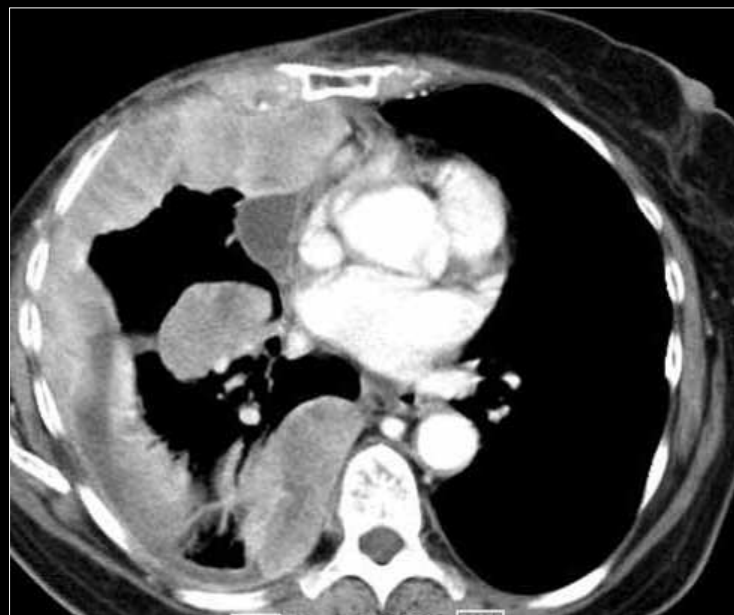
Asbestose



Mésothéliome



Métastases K sein

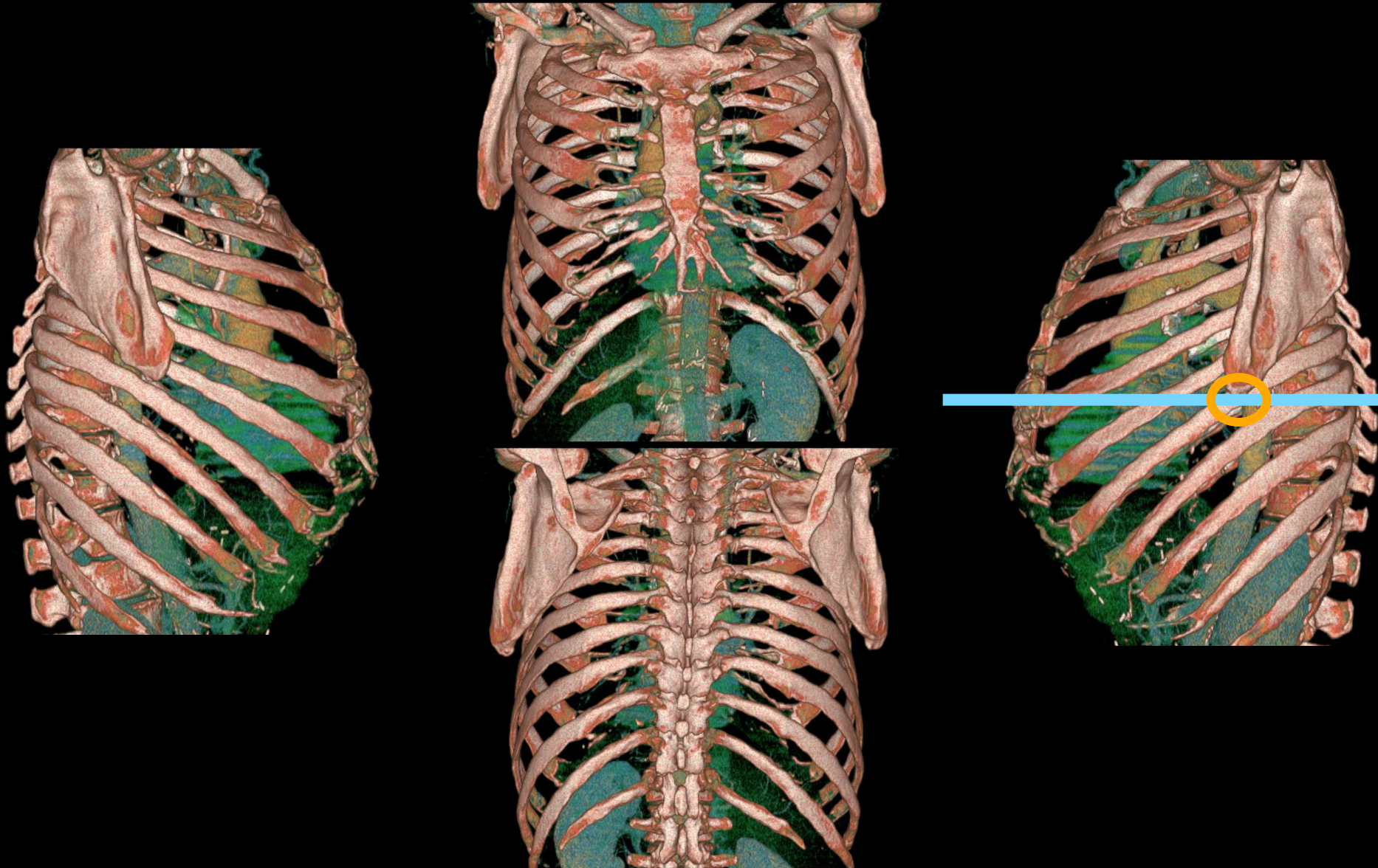


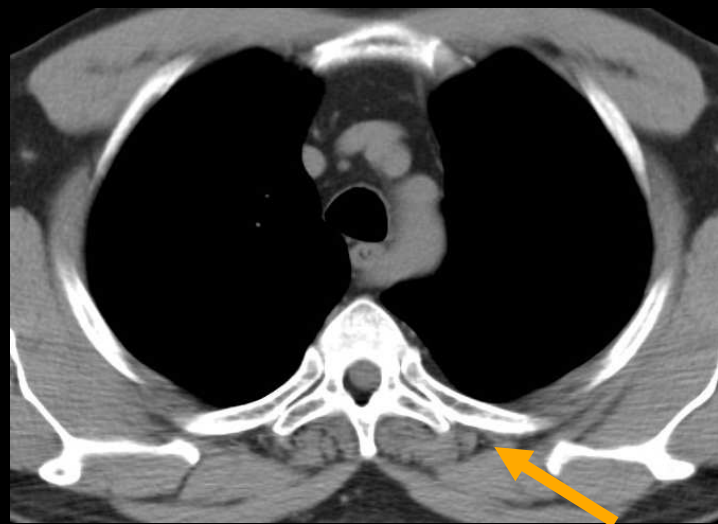
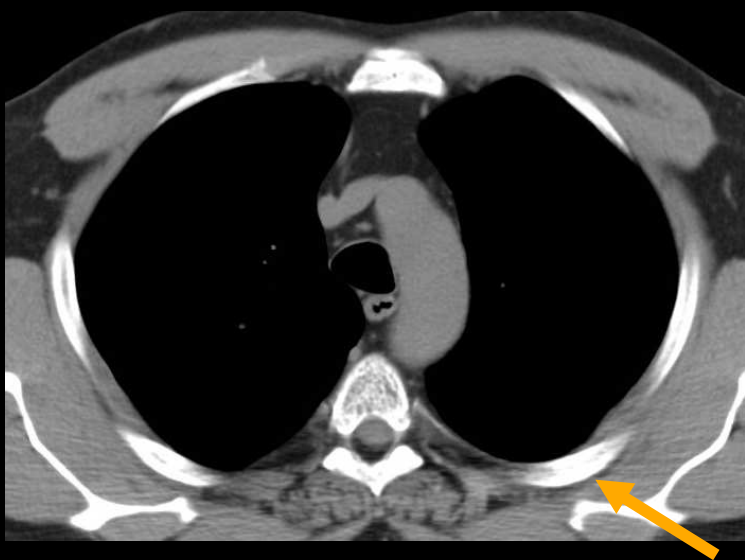
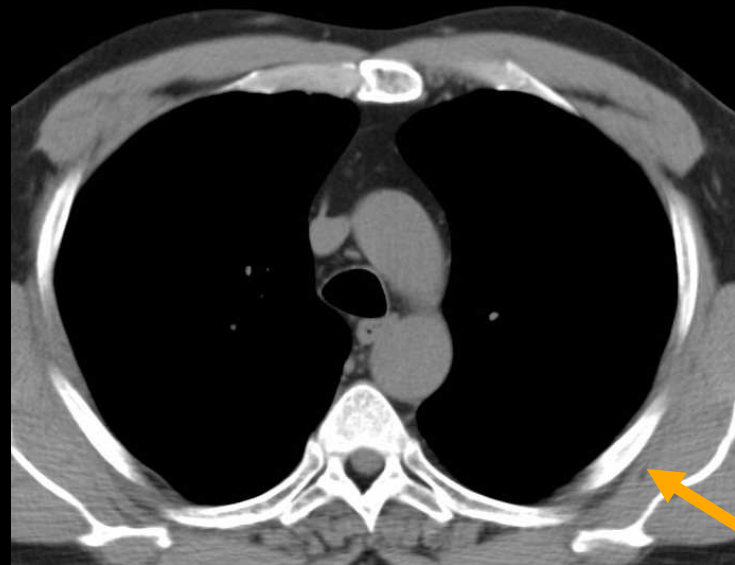
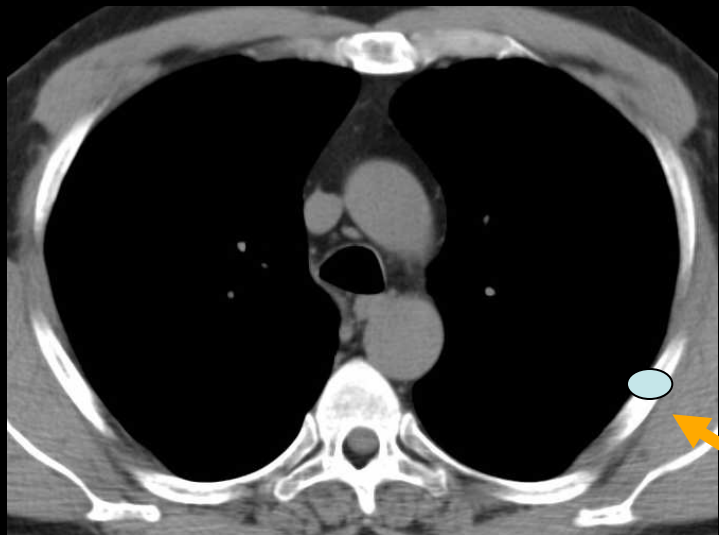


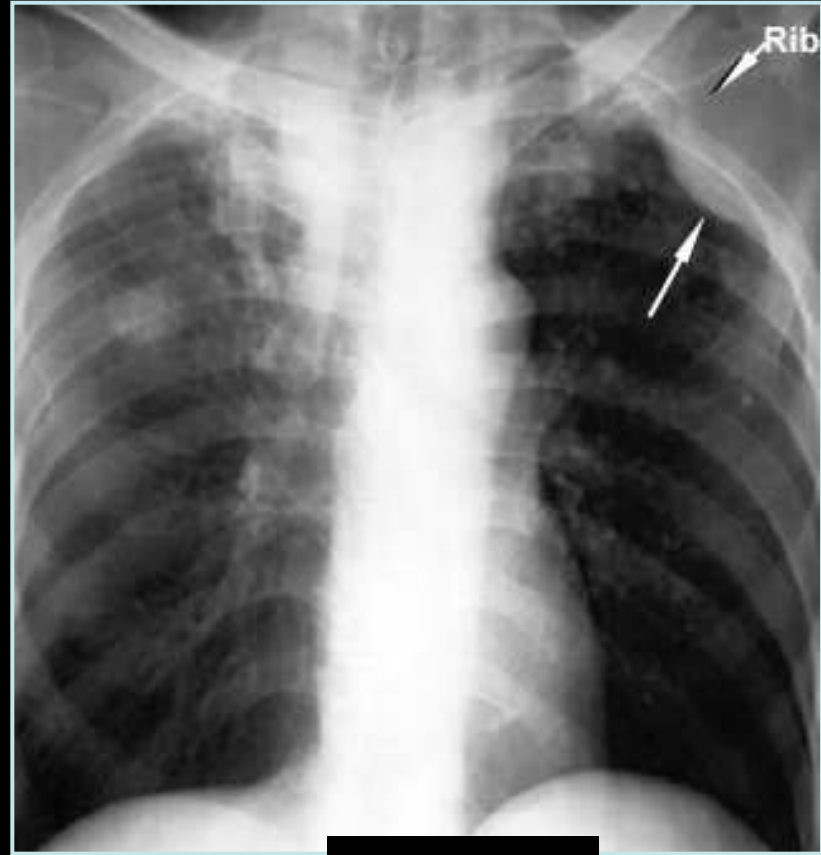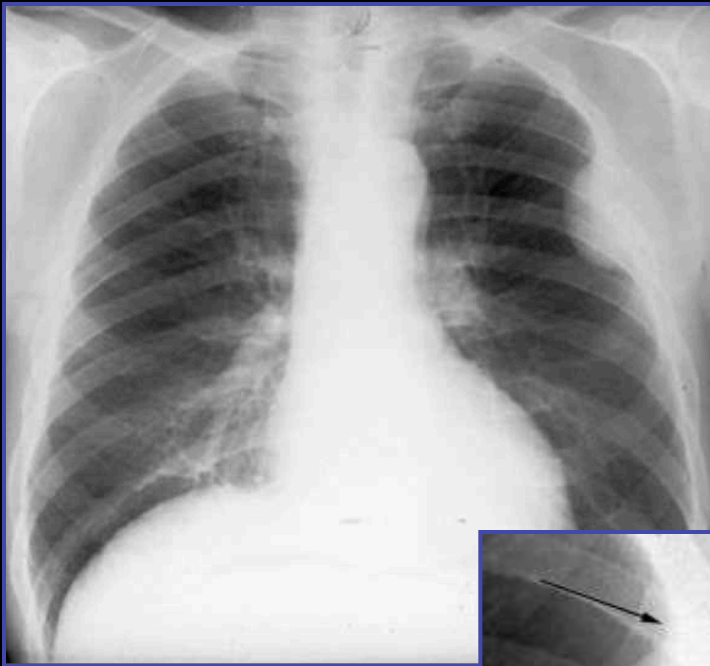
3/ PAROI THORACIQUE

- PLEVRE
- **CÔTES**

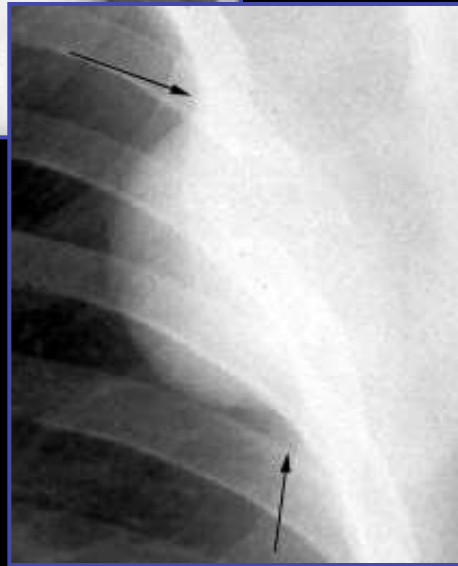Les côtes



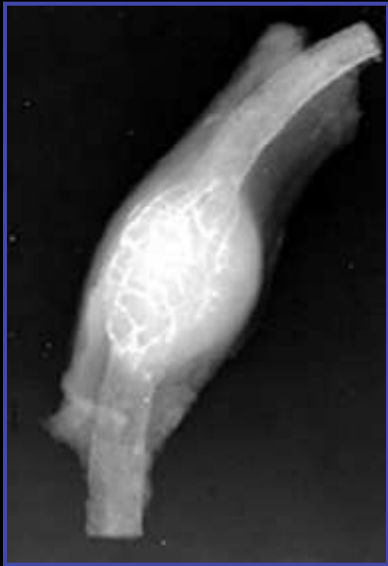


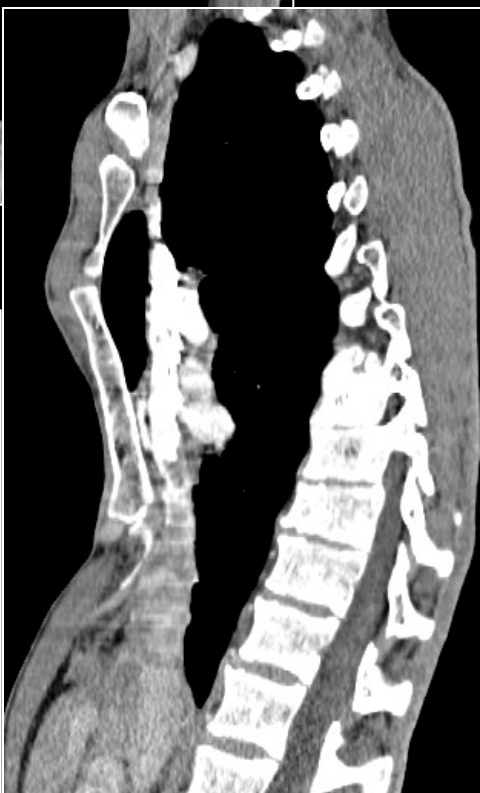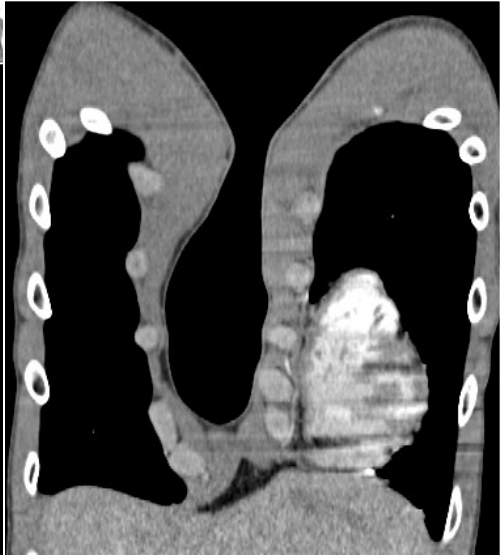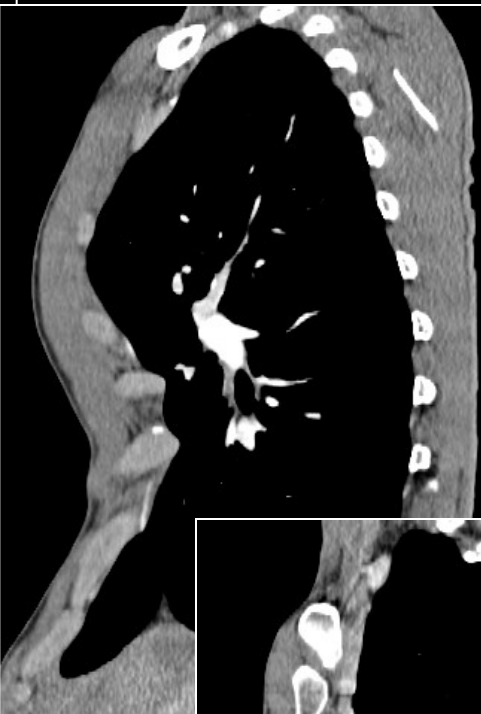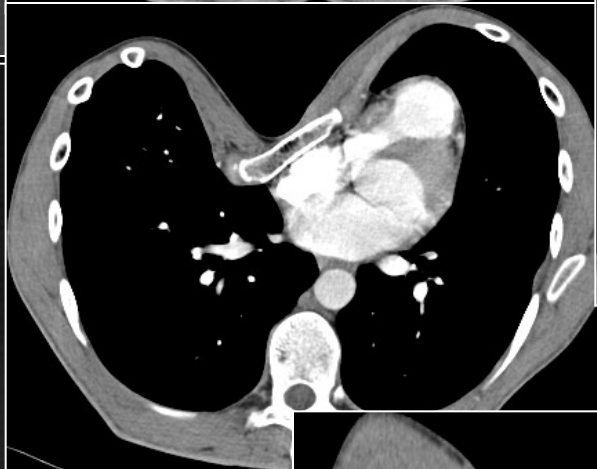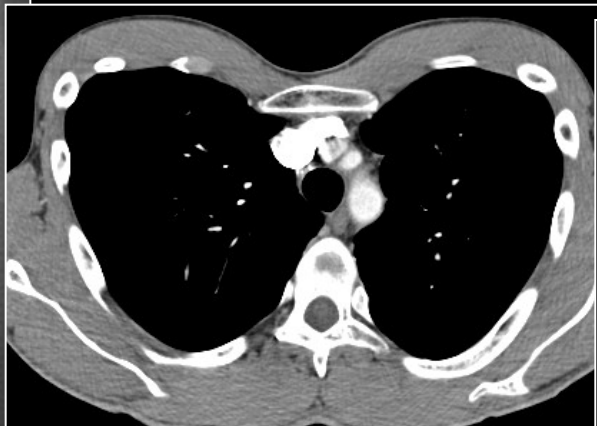
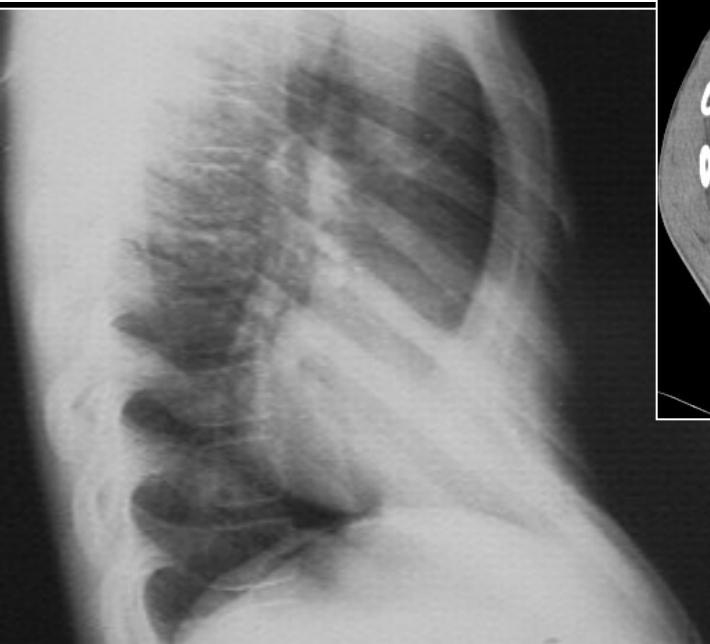
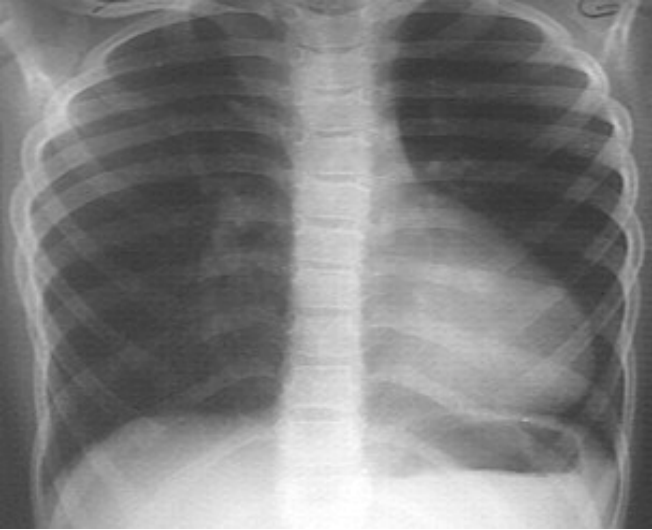


Métastase



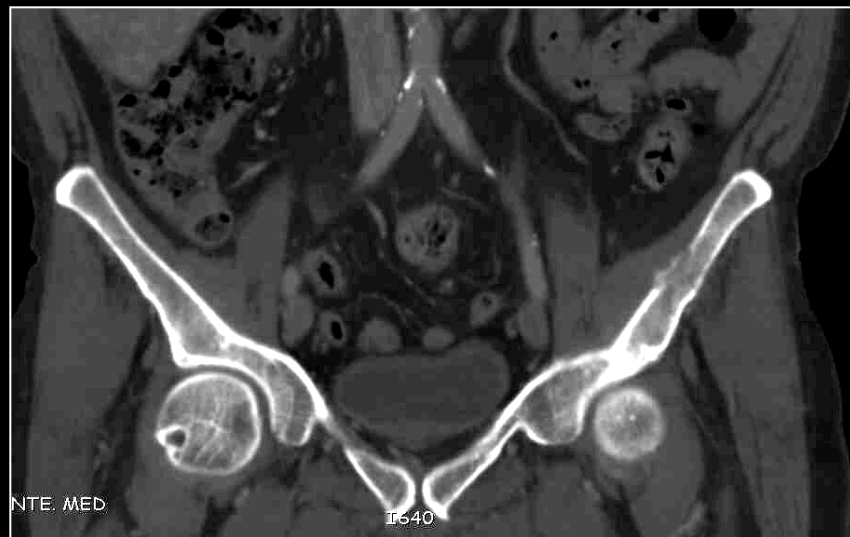
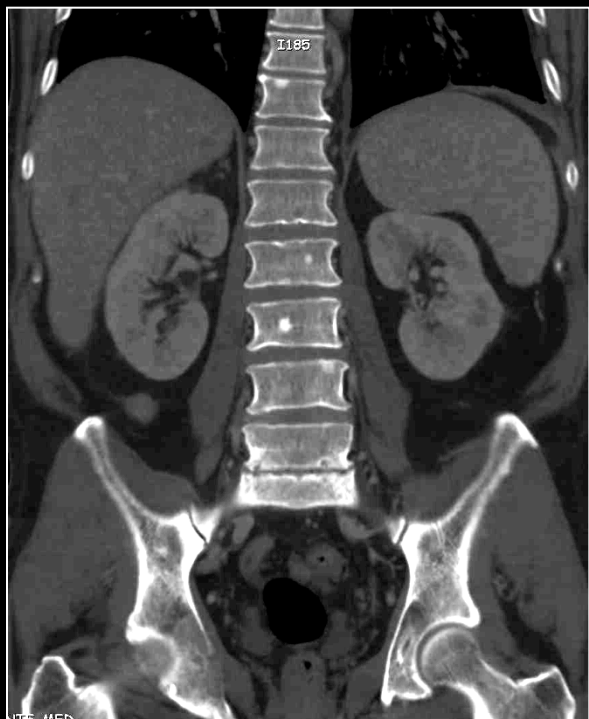
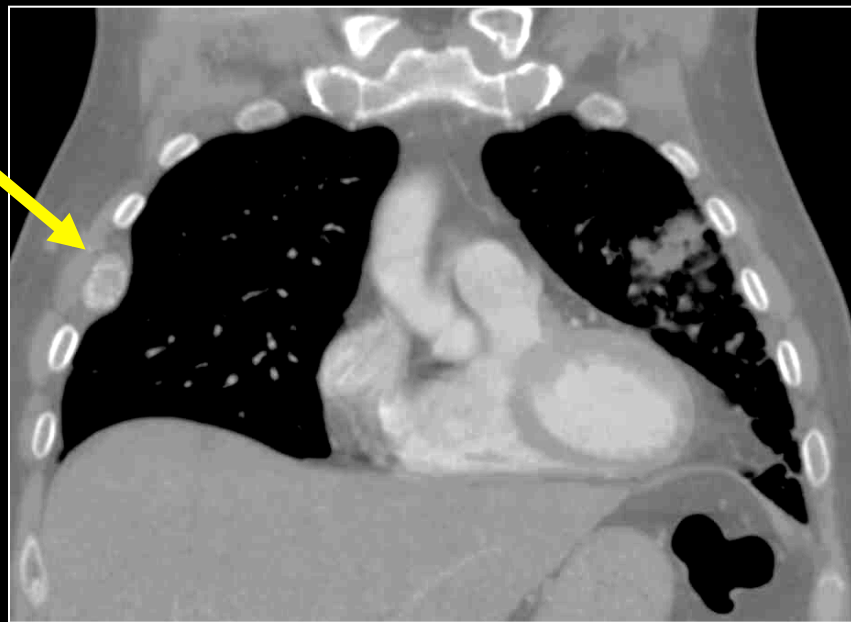
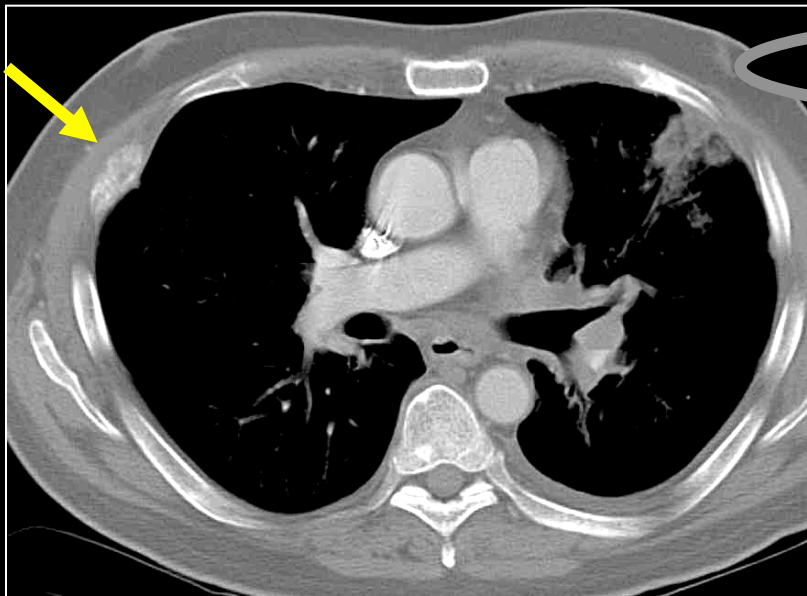
Plasmocytome

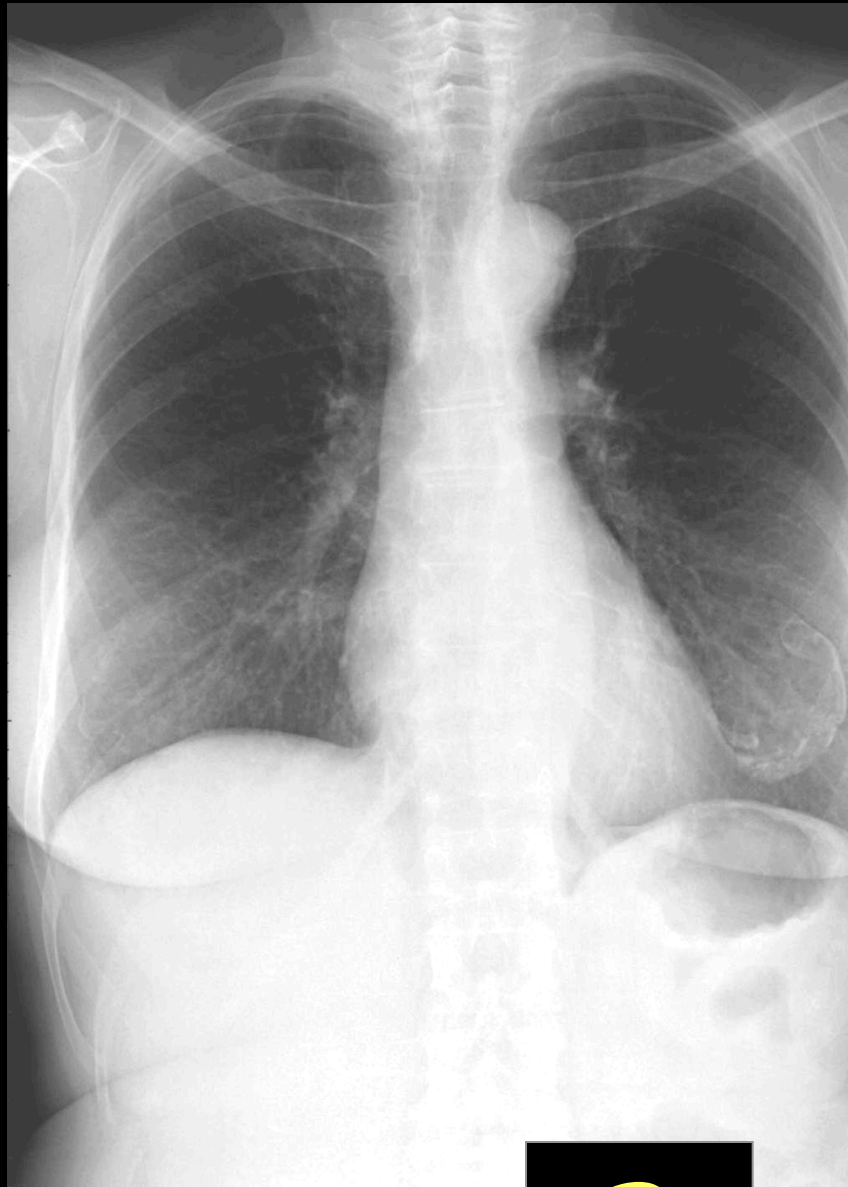




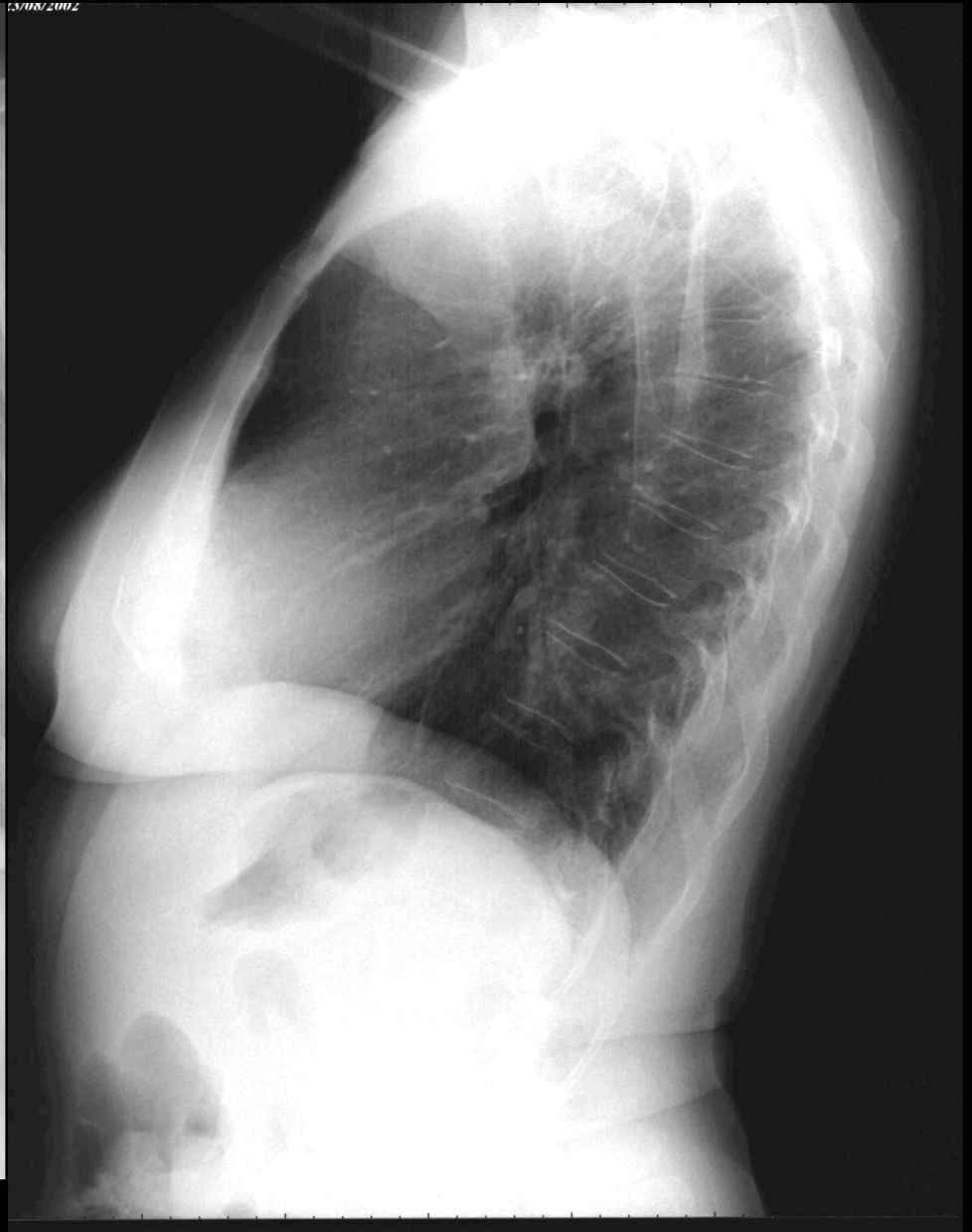
Pectus excavatum

Métastase de carcinome bronchique

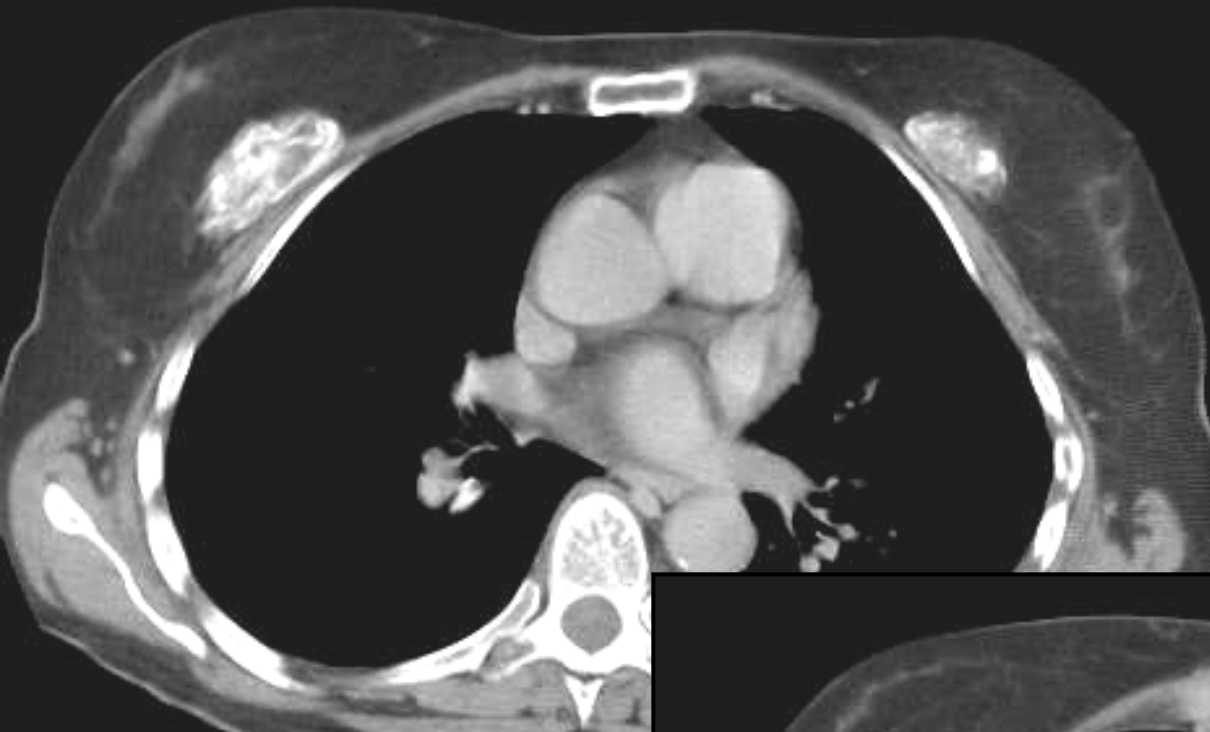



15/08/2002



?



Ancienne PROTHESES MAMMAIRES !!!

