

# Radioanatomie du thorax

[www.e-anatomy.org](http://www.e-anatomy.org)

**A. OLIVER**  
**N. DIDOT**  
**AVRIL 2012**

# THORAX

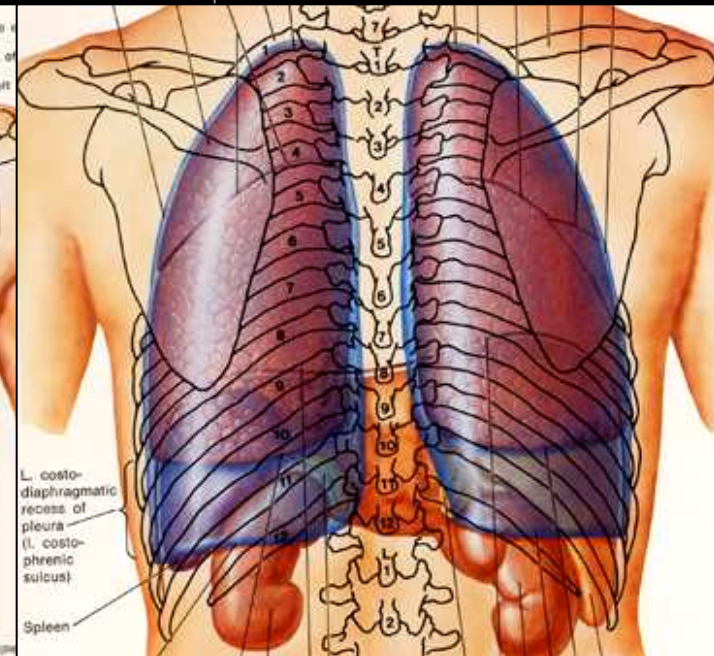
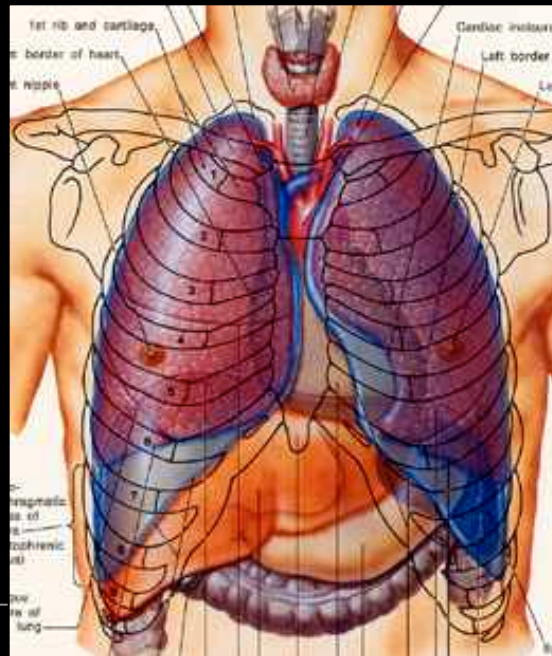
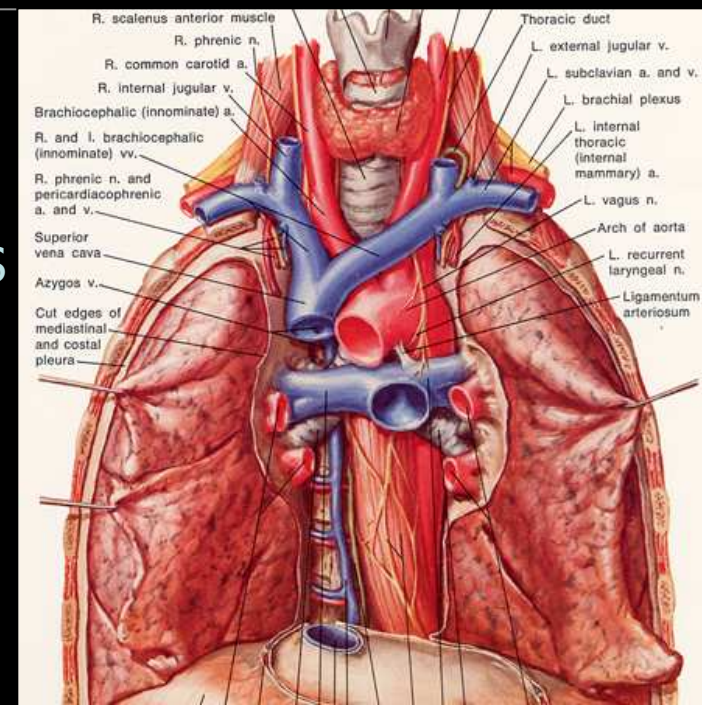
## 1/ RADIOANATOMIE PULMONAIRE ET DES BRONCHES

## 2/ RADIOANATOMIE DU MEDIASTIN

- VAISSEAUX
- CŒUR
- ŒSOPHAGE
- CHAINES GANGLIONNAIRES

## 3/ PAROI THORACIQUE

- PLEVRE
- COTES





# **1/ RADIOANATOMIE PULMONAIRE ET DES BRONCHES**

# ANATOMIE de l' ARBRE TRACHEO-BRONCHIQUE

**Trachée** conduit semi rigide anneaux cartilagineux en avant

membrane fibreuse postérieure

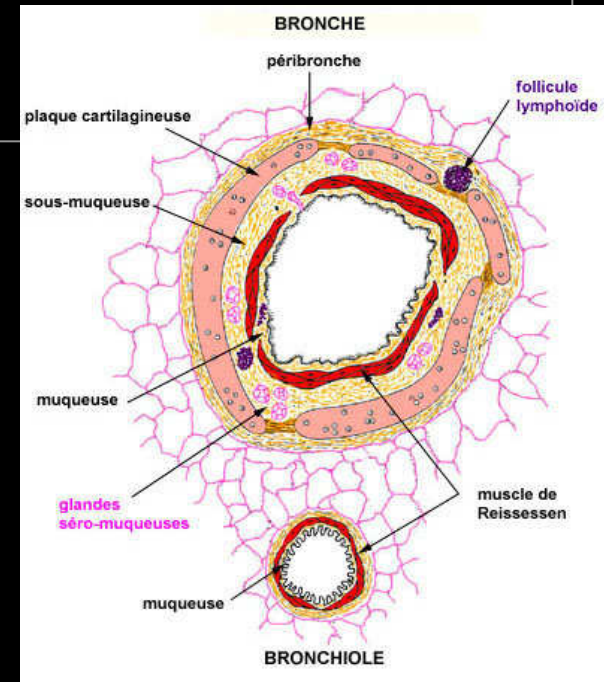
sous glottique à carène

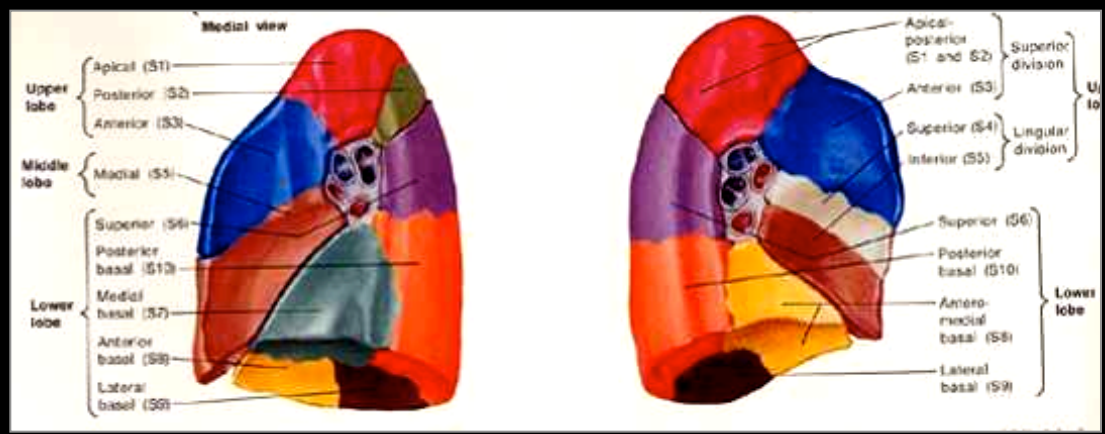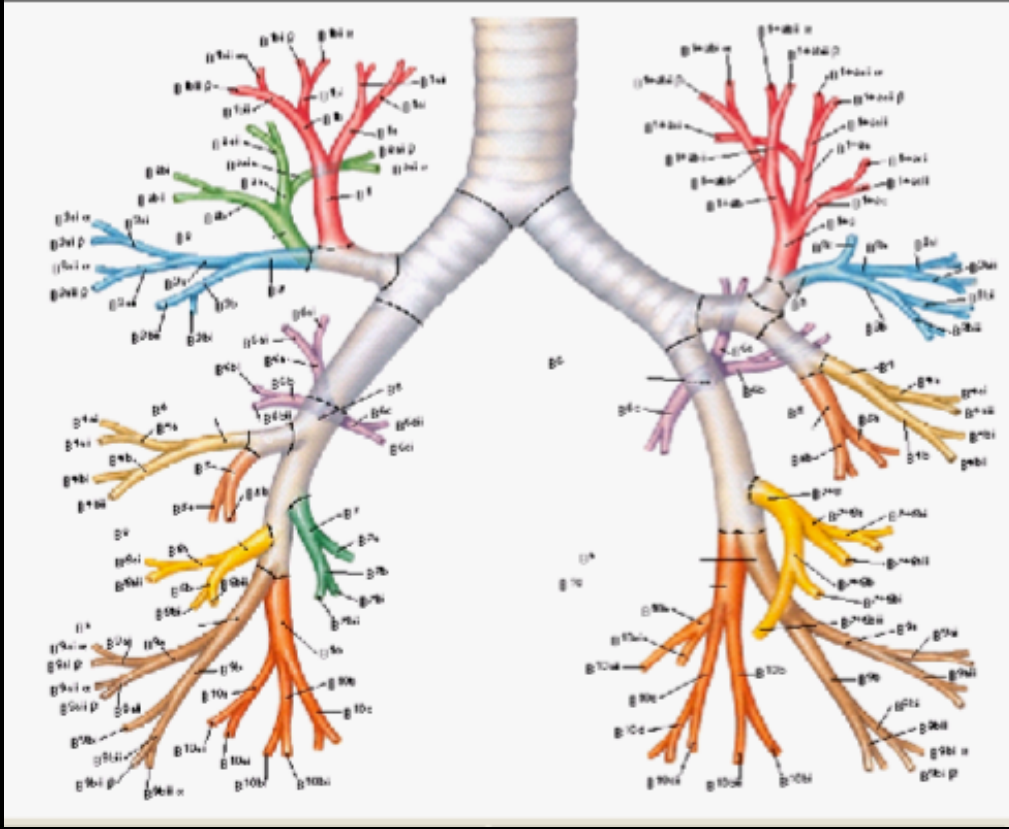
diamètre inférieur à 30 mm

**Bronches**

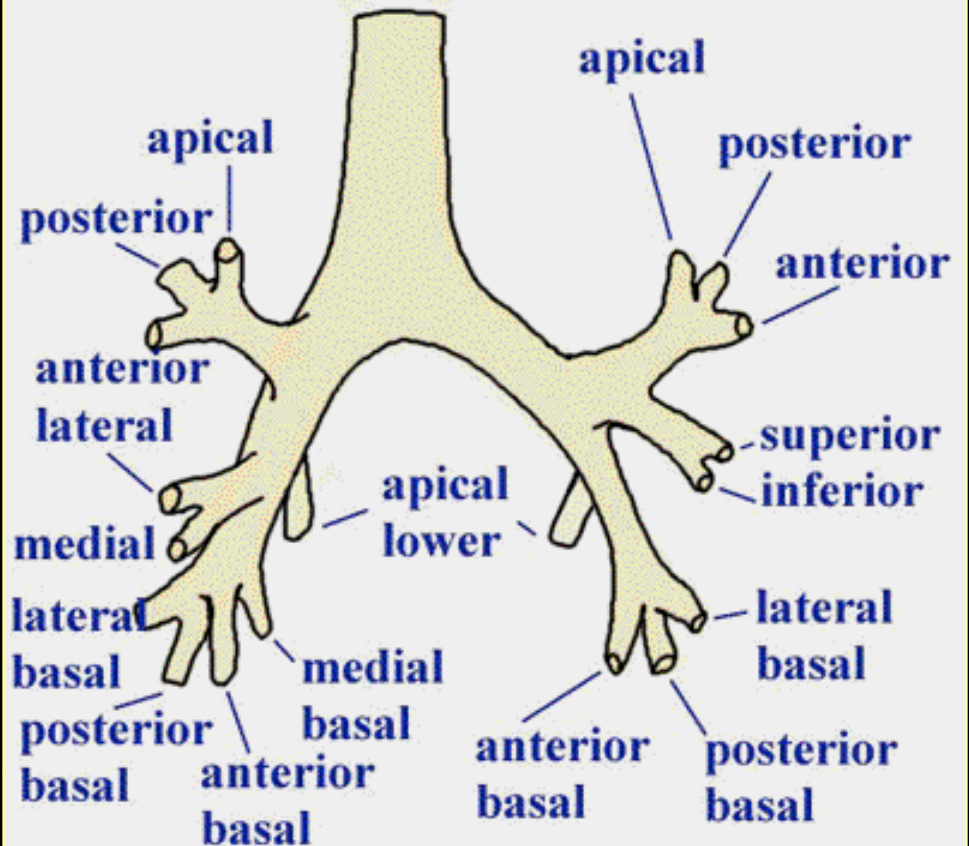
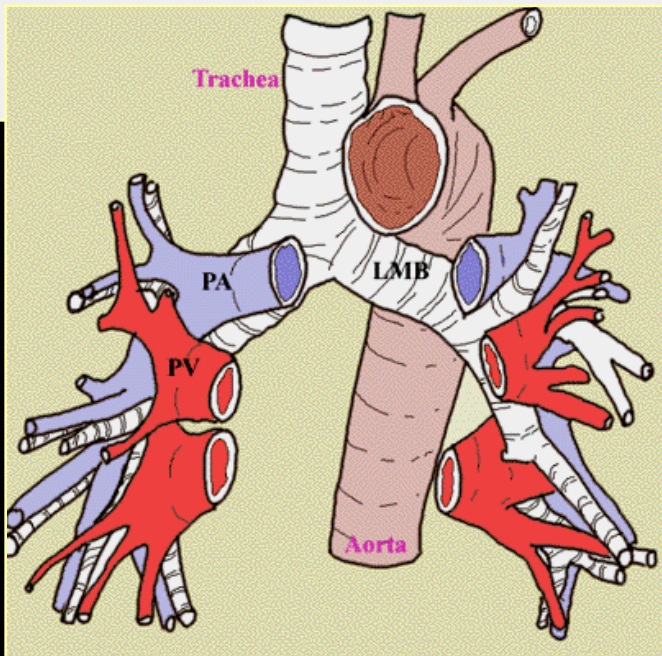
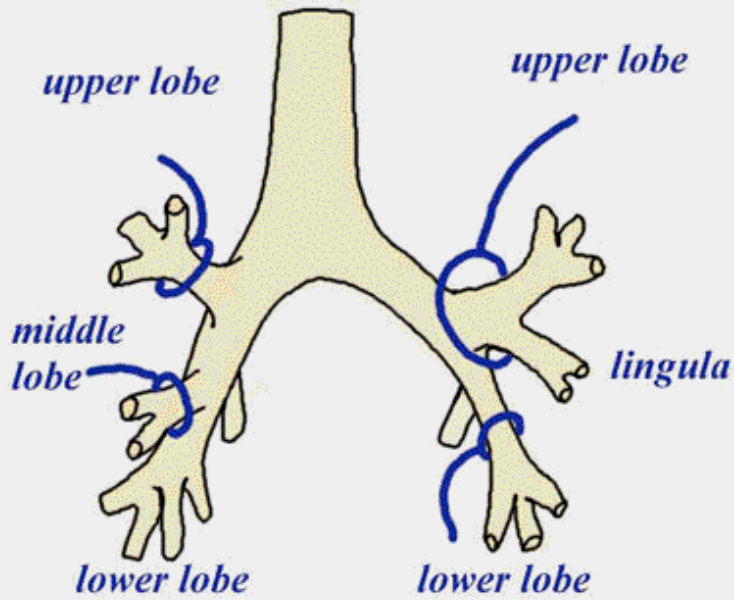
cartilage + m. lisse + fibres élastiques

élastine et collagène alvéoles

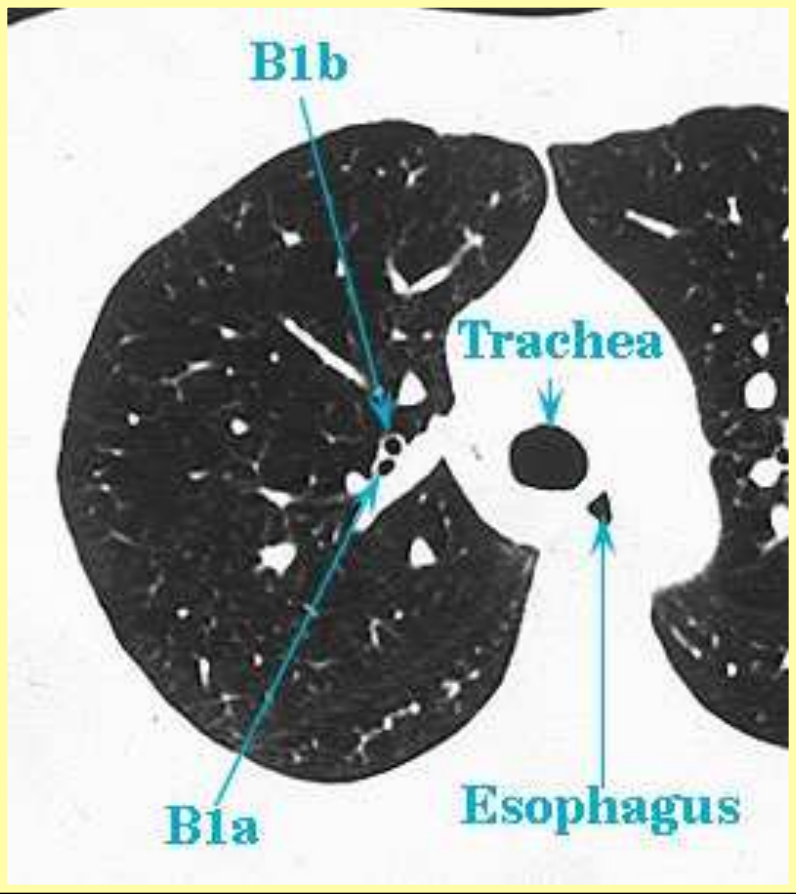
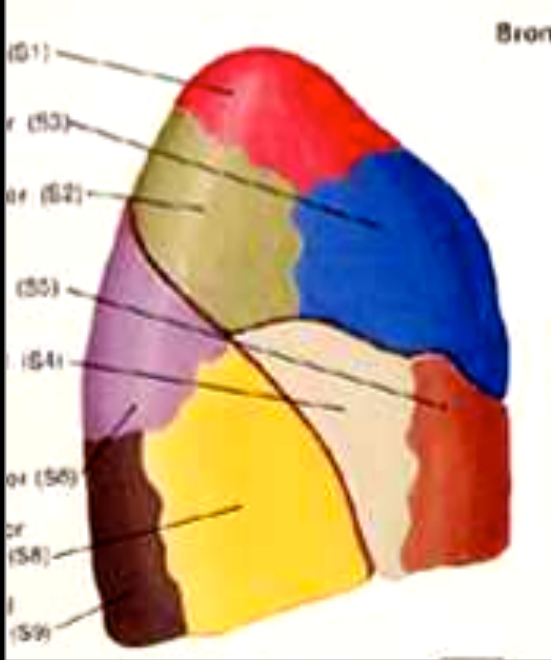




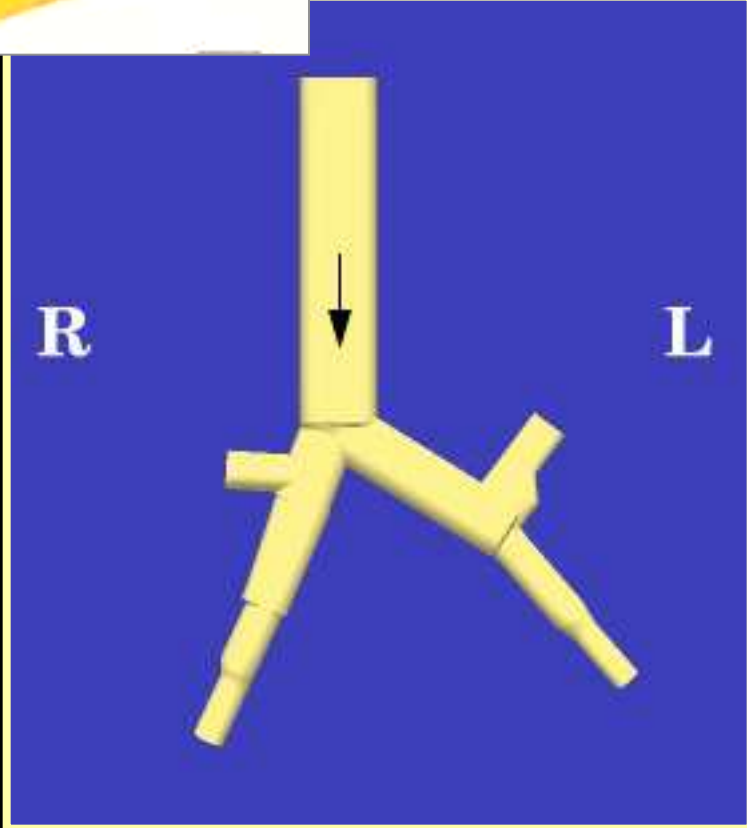
# Systeme bronchique



# POUMON DROIT

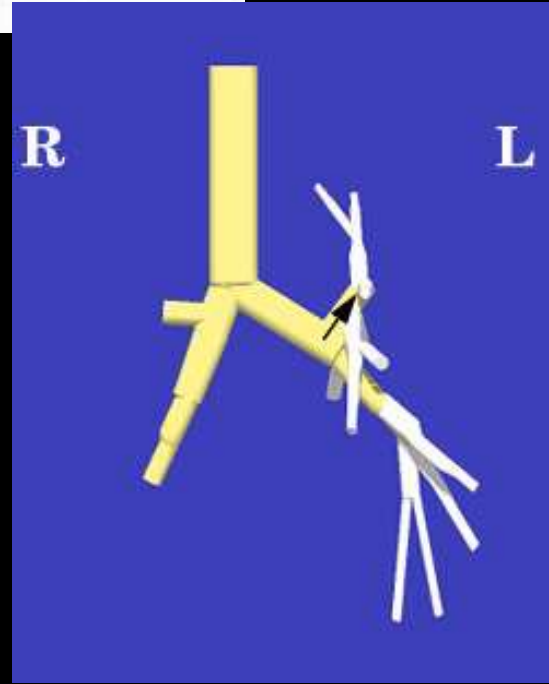
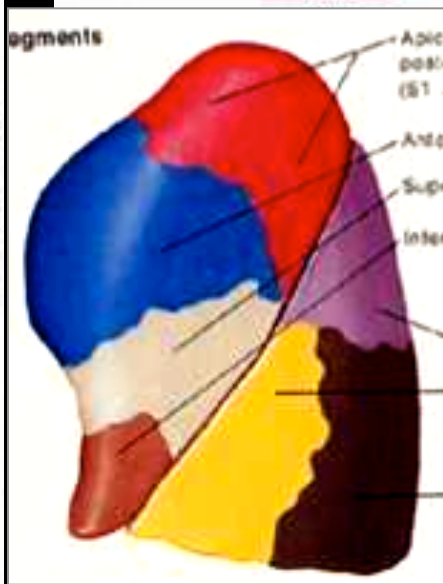
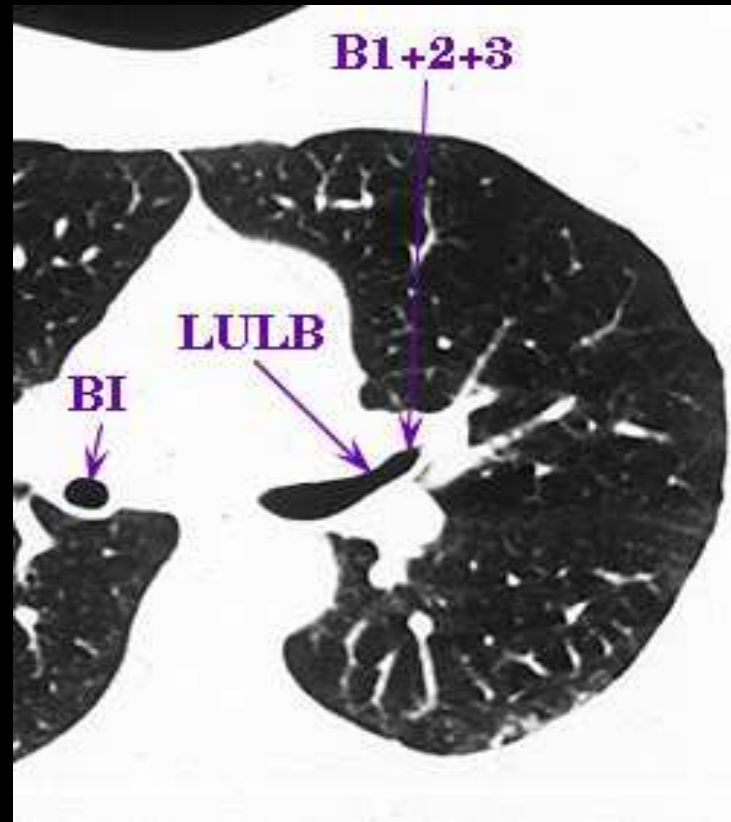
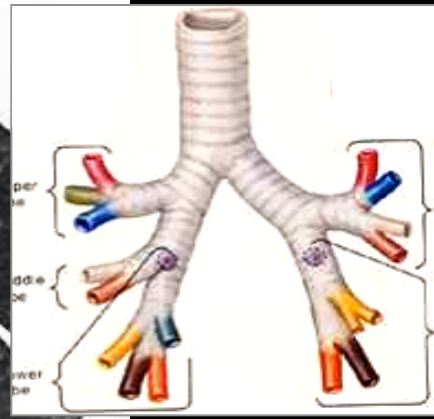
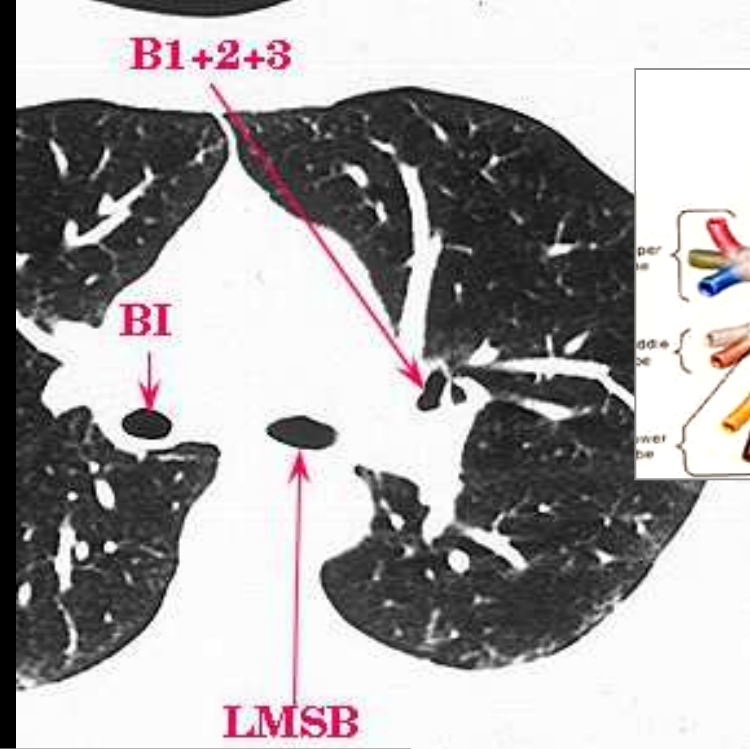


**B1 apical**

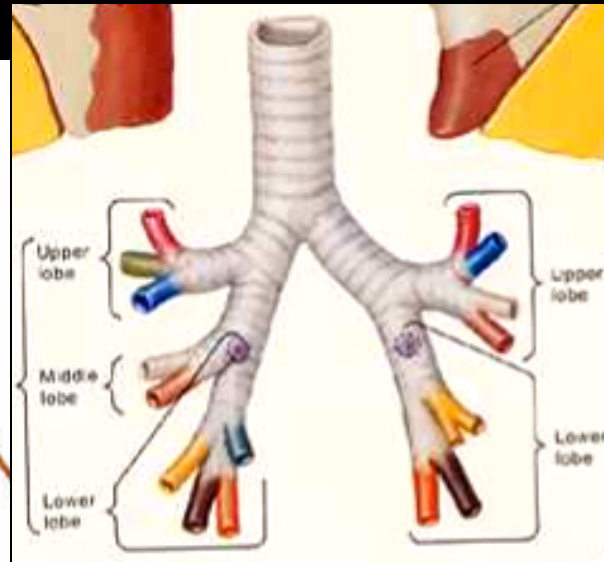


# POUMON GAUCHE

**Bronche Lobaire Supérieure**  
B1+2 apical postérieur  
B3 antérieur  
= culmen

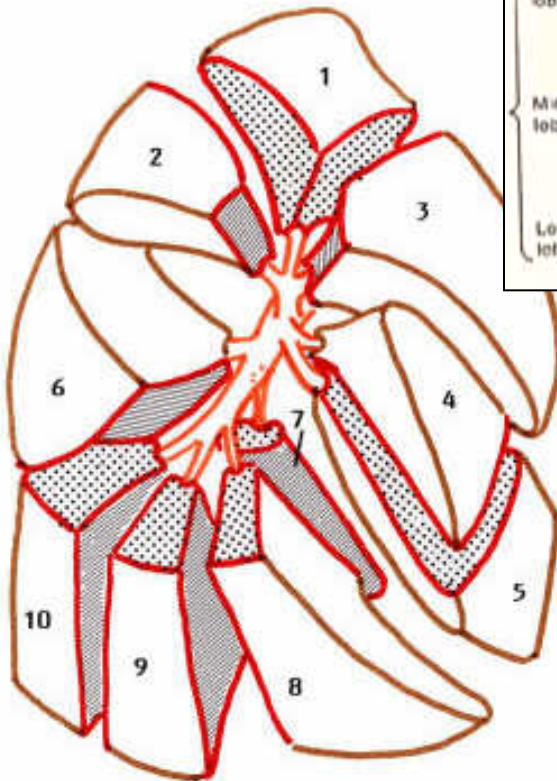


# SEGMENTATION PULMONAIRE



POUMON DROIT

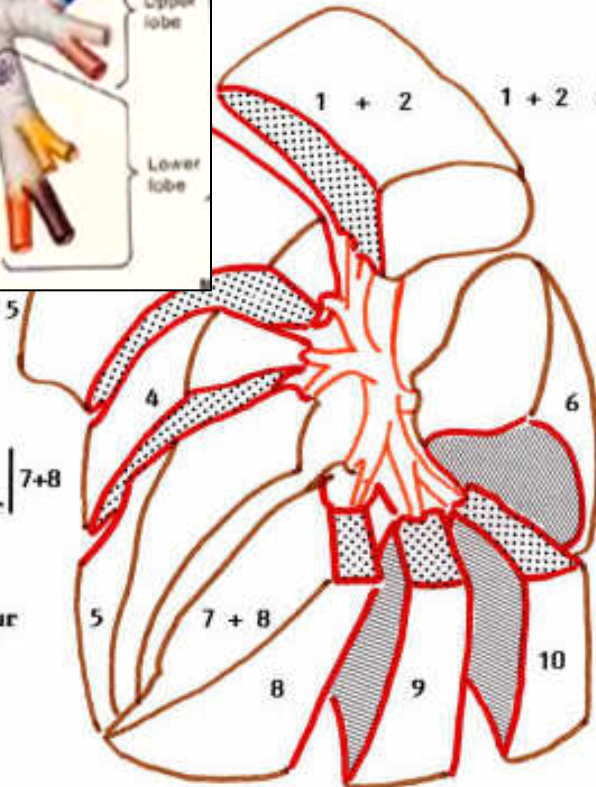
AV  
BS



1, 2....., 10 : Nomenclature chiffrée de Boyden

POUMON GAUCHE

AV  
BS

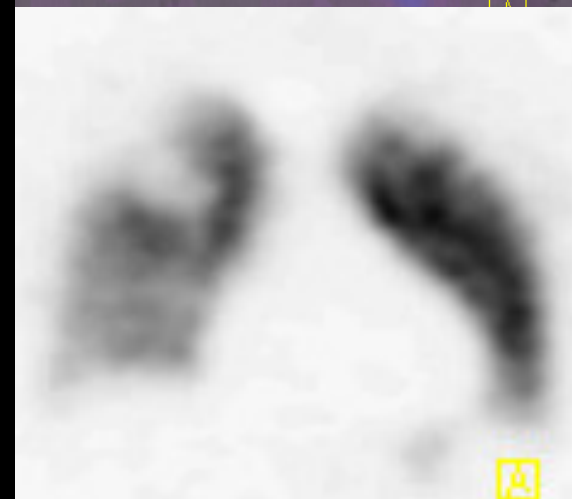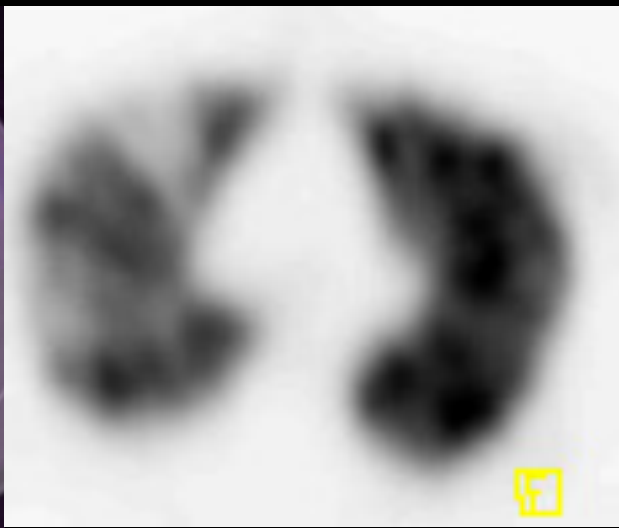
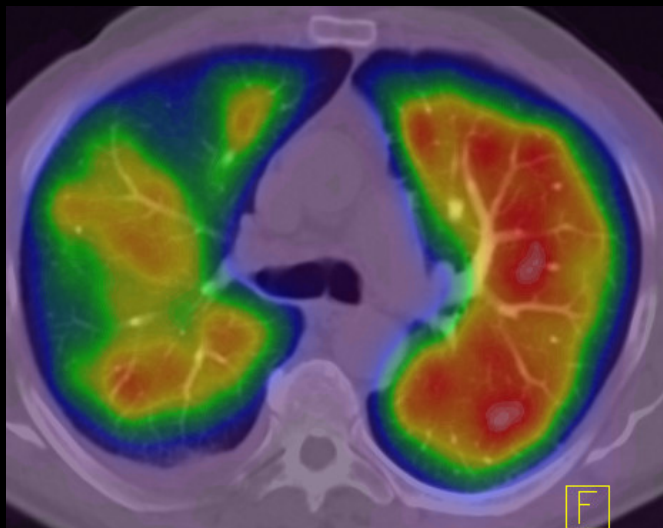
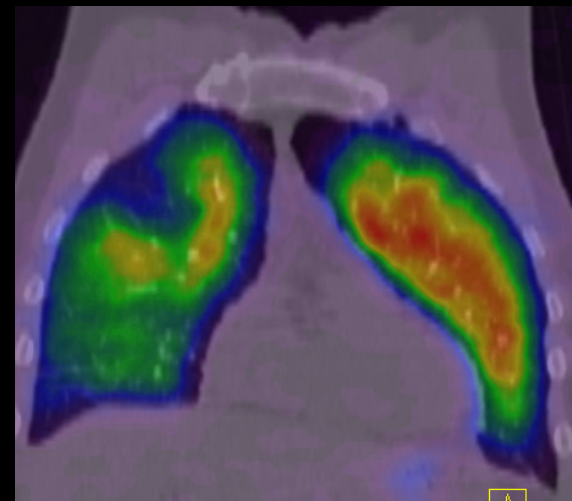
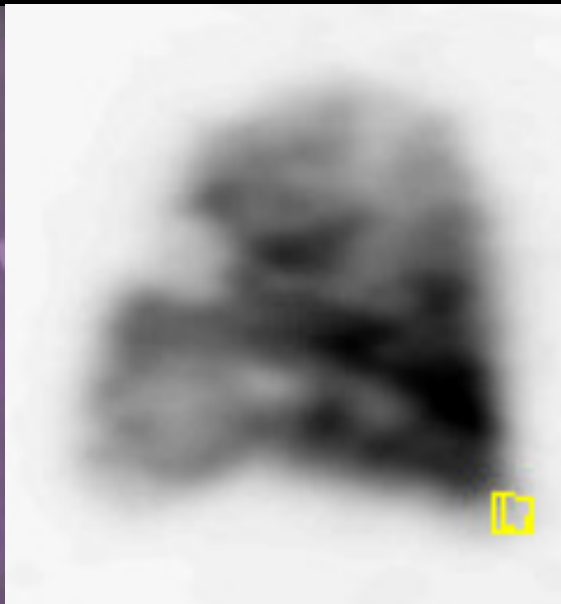
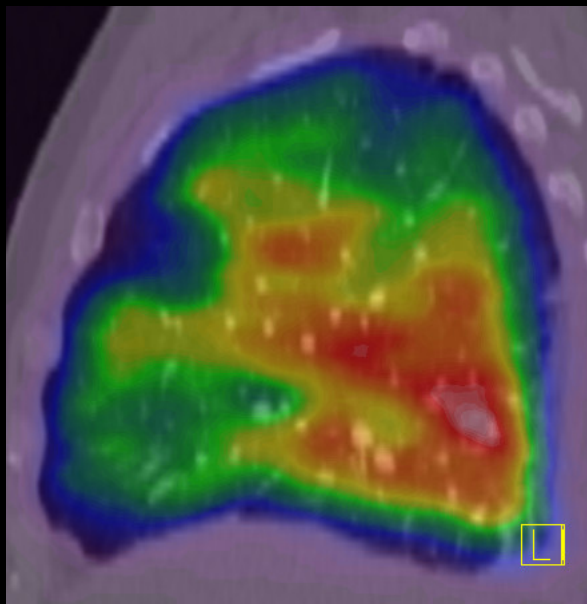


- 5. Médial Infér 5
- 6. Supérieur (apical du LI)
- 7. Basal médial
- 8. Basal antérieur
- 9. Basal latéral
- 10. Basal postérieur

1 + 2 Apico-postérieur

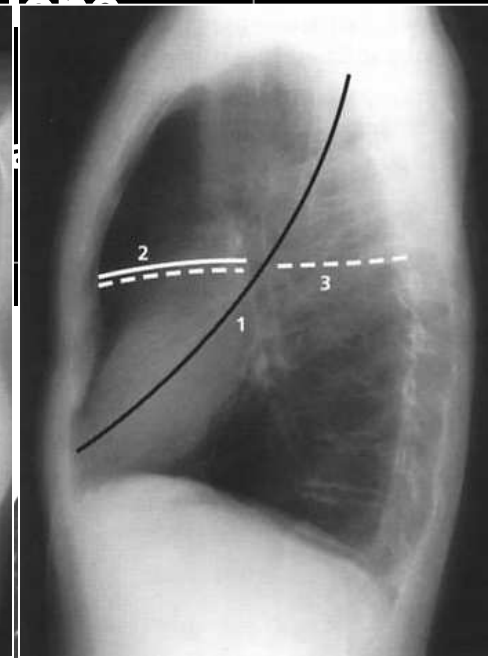
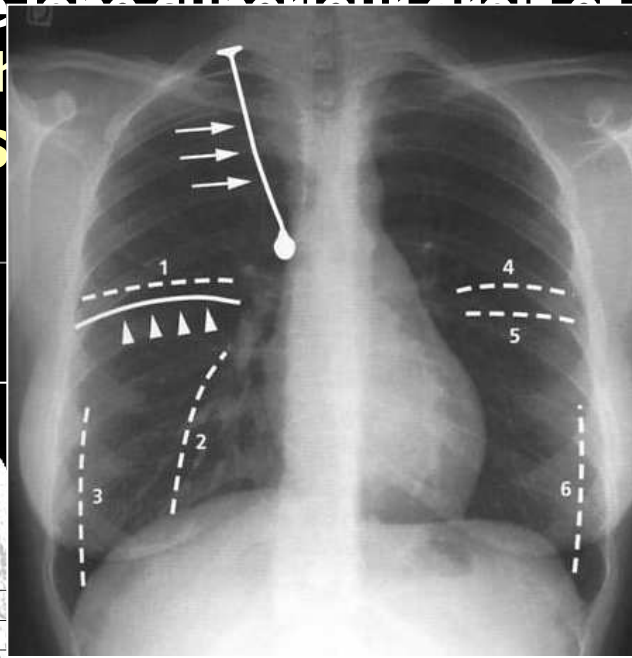
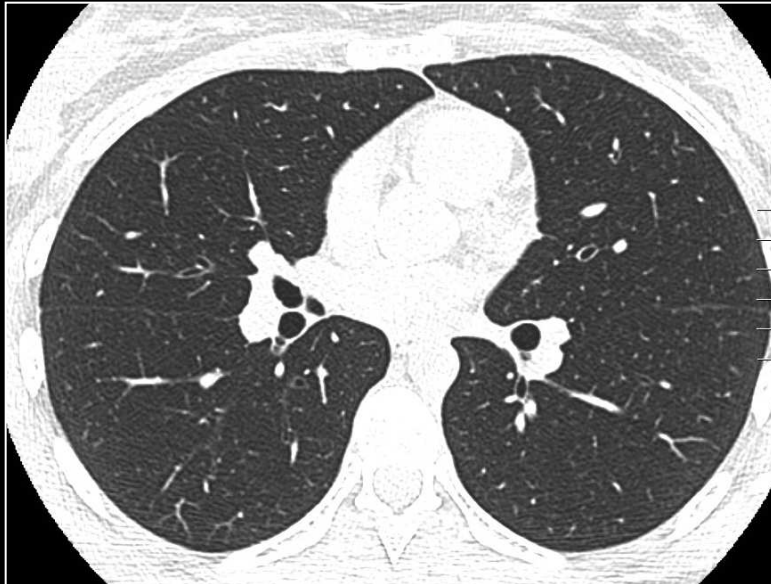7 + 8 basal antéro-médial

**Embolie pulmonaire  
segment ant LSD**



# LES SCISSURES

- La plèvre viscérale s'insinue dans les scissures
- **GRANDES SCISSURES** entre les lobes supérieur et inférieur et sont obliques
- **PETITE SCISSURE** entre le lobe supérieur droit et lobe moyen et est proche de l'arc costal
- **SCISSURES ACCESSOIRES** la scissure verticale externe, la scissure para-cardiaque et la scissure verticale interne...



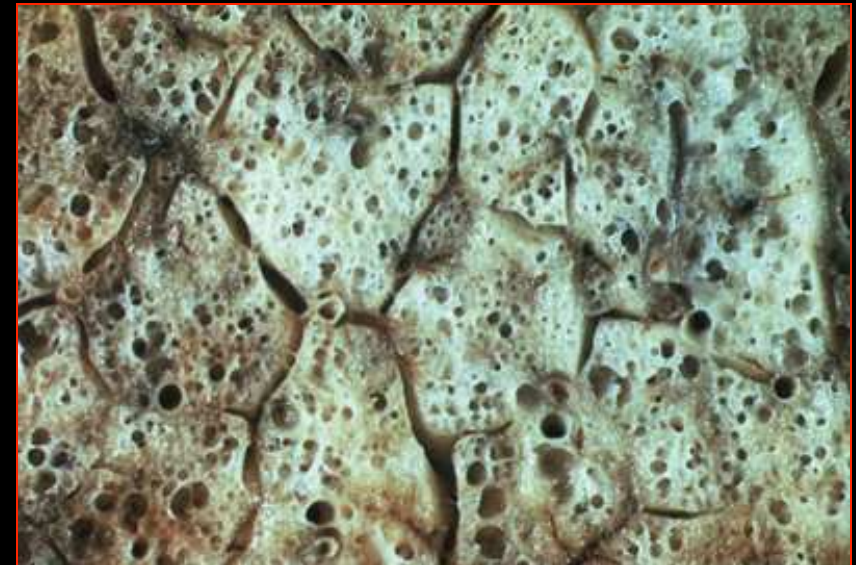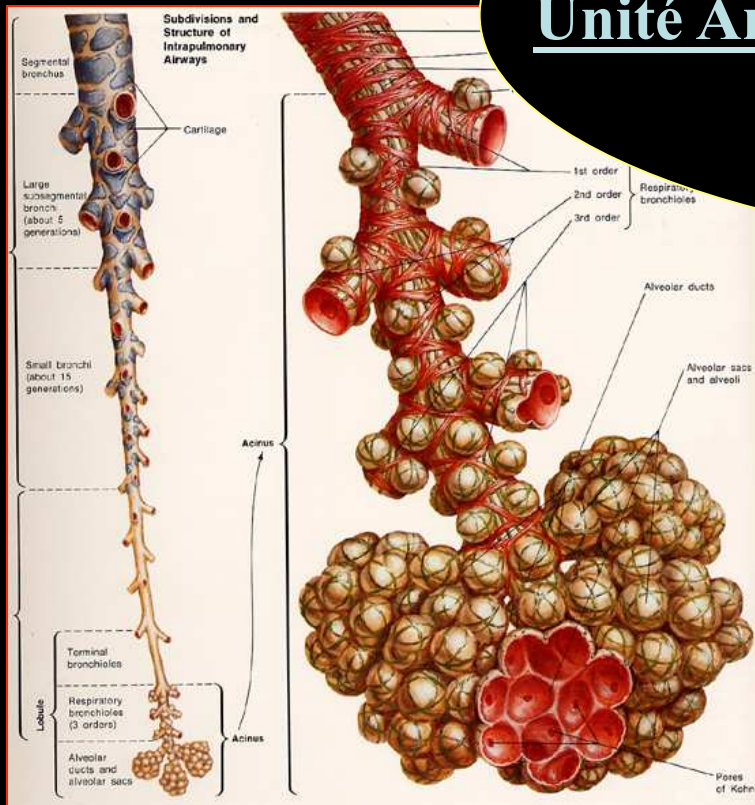
- 1.Scissure du segment S6 droit
- 2.Scissure para-cardiaque droite
- 3.Scissure verticale externe gauche
- 4.Scissure linguale
- 5.Scissure du segment S6 gauche
- 6.Scissure verticale externe gauche

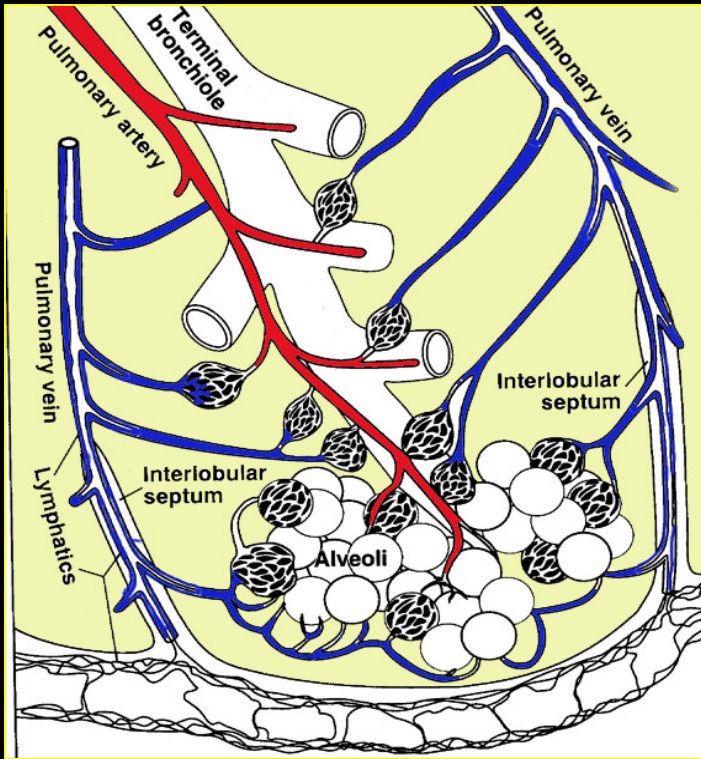
# Imagerie du Lobule Secondaire

- grâce au **Scanner Haute Résolution** (coupes millimétriques)

## Lobule II de Miller

Unité Anatomique et Fonctionnelle du poumon  
Polyédrique, 1 à 1,5 cm  
Contient 3 à 5 acini





**Bronchiole centrolobulaire**

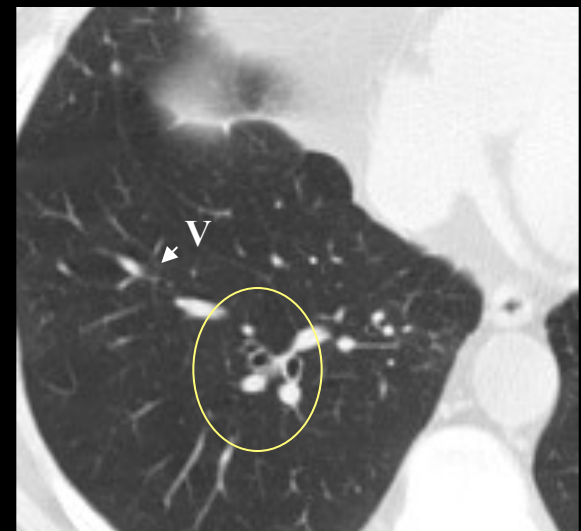
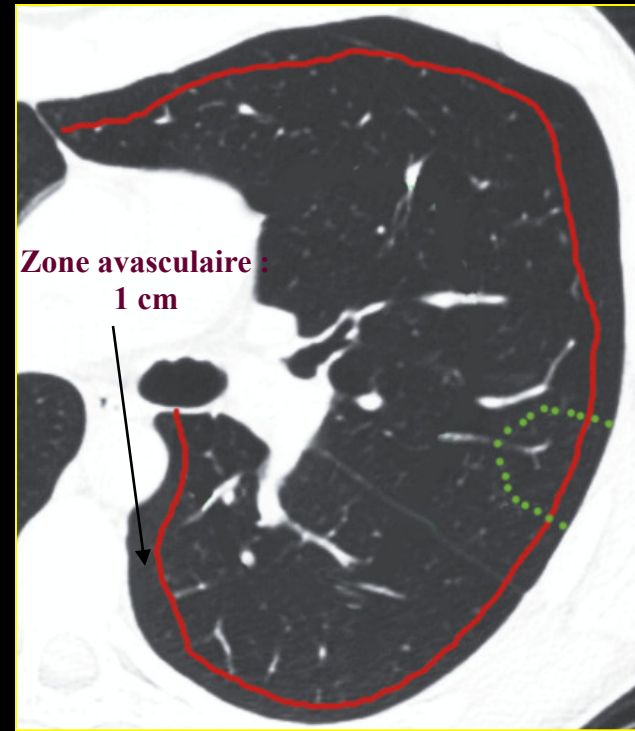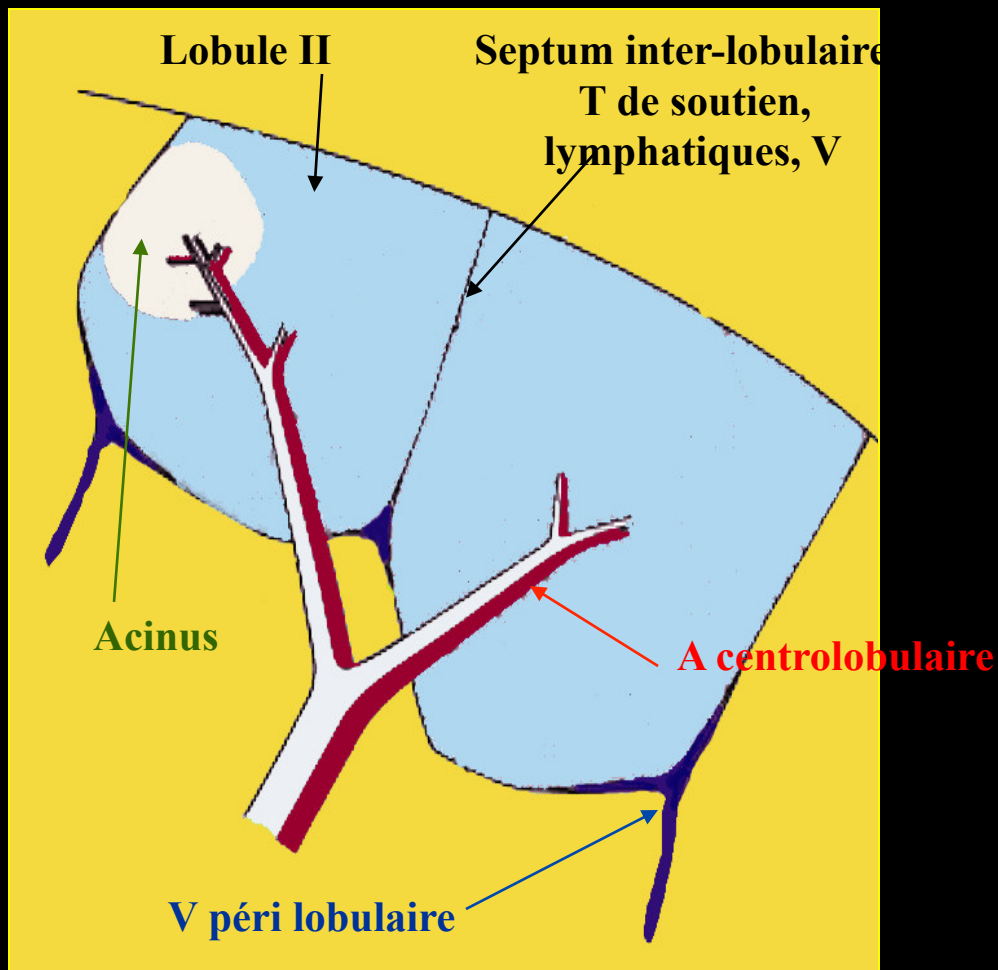


**Bronchioles terminales**



**Bronchioles respiratoires/ bordées  
d'alvéoles (=acinus ou lobule primaire  
de Miller)**

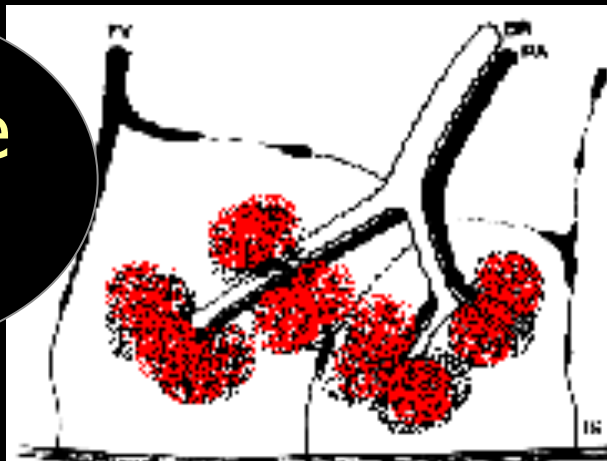- ✓ **Membrane Air/Sang** : Échanges gazeux alvéolo-capillaires
- ✓ **Secteur Interstitiel** (de soutien) :
  - Inter et péri lobulaire (V et lymphatiques)
  - Sous pleural
  - Péri Bronchovasculaire (jusqu' au hile)
- ✓ **Secteur aérique** : alvéolaire, bronchique



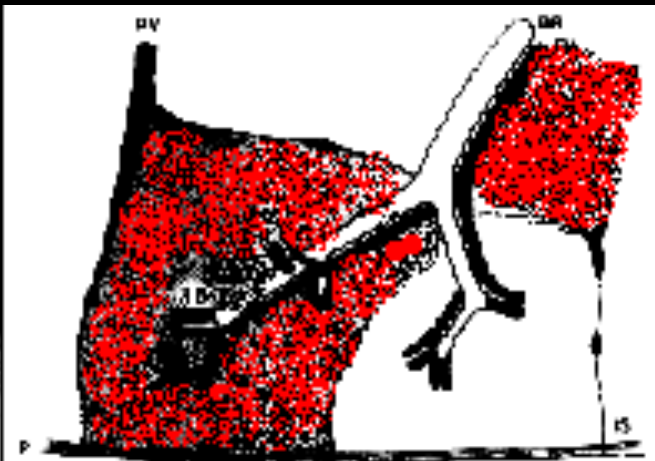**A l'état normal :**  
**Bronchioles et septa non vus, en périphérie**  
**A. visualisées plus loin que V.**

# Différentes atteintes pulmonaires

Aérique  
Alvéoles,  
Bronches

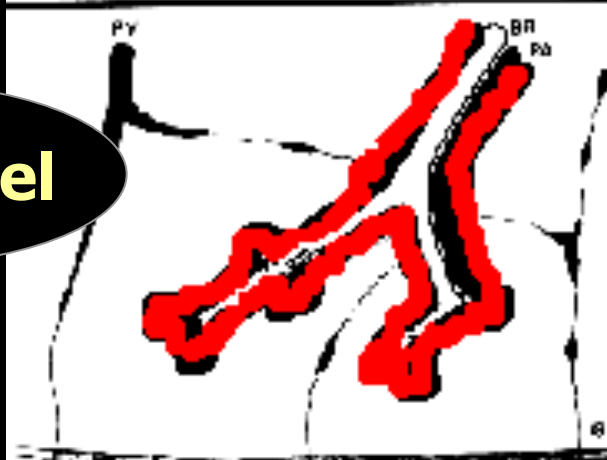

Centilobular

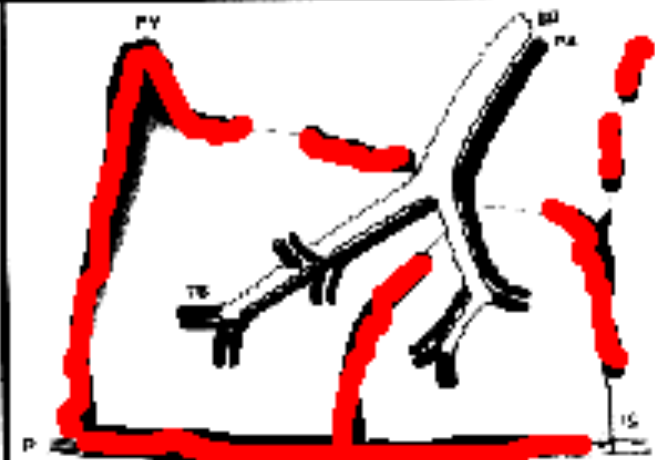

Panlobular

Interstitiel

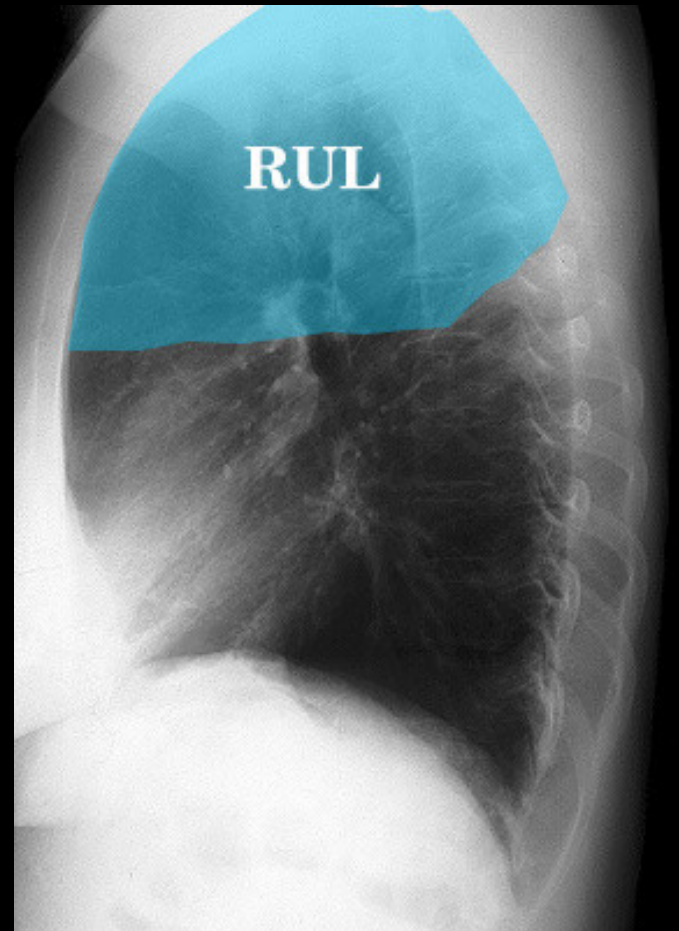
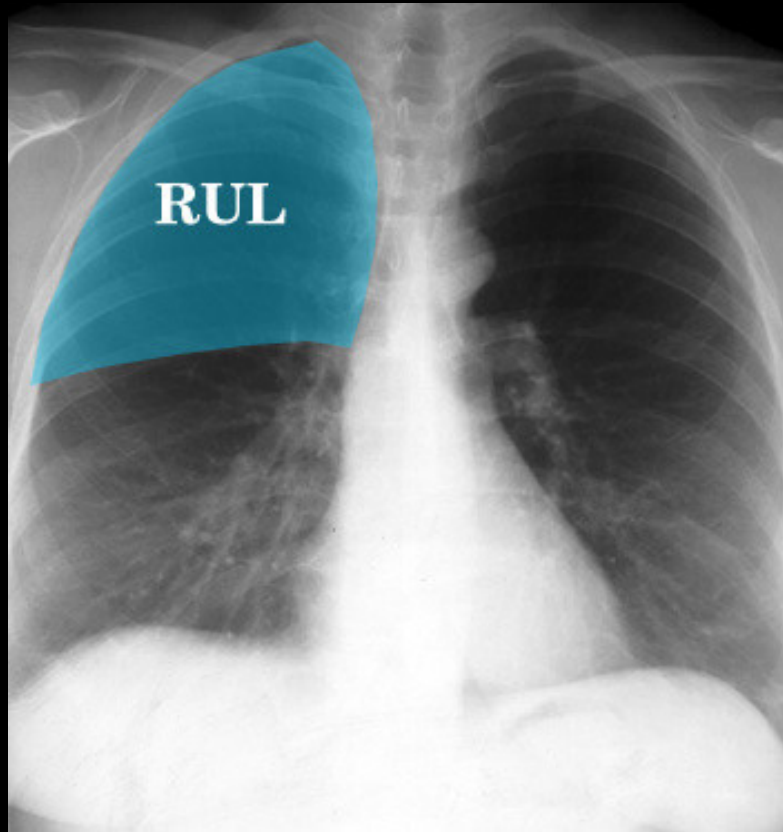


T. Soutien péri-broncho-vascul

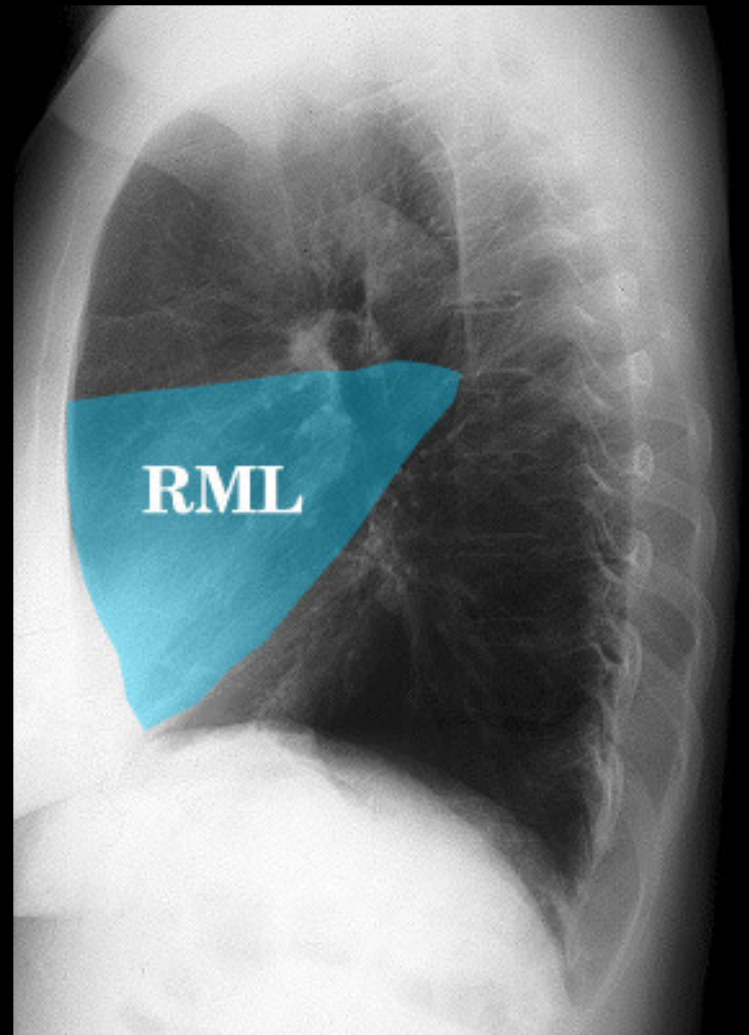
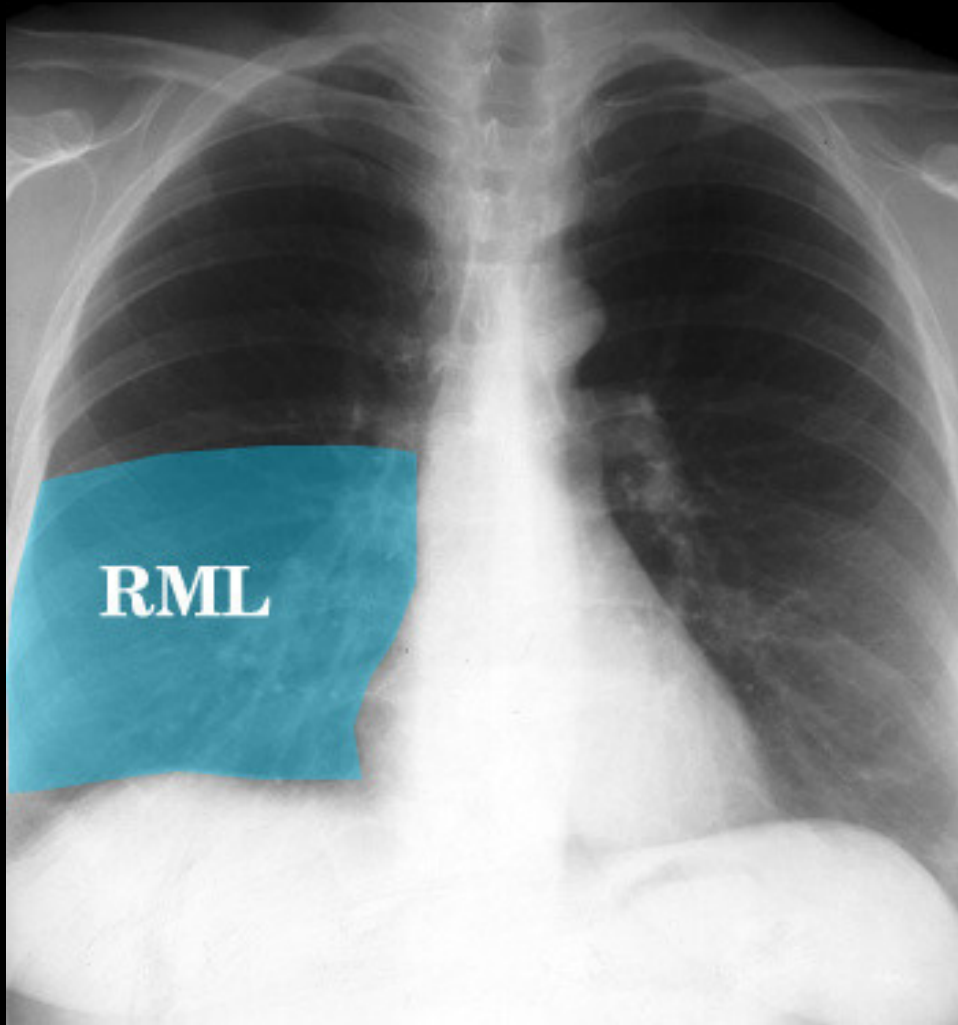


Septal (Perilobular)

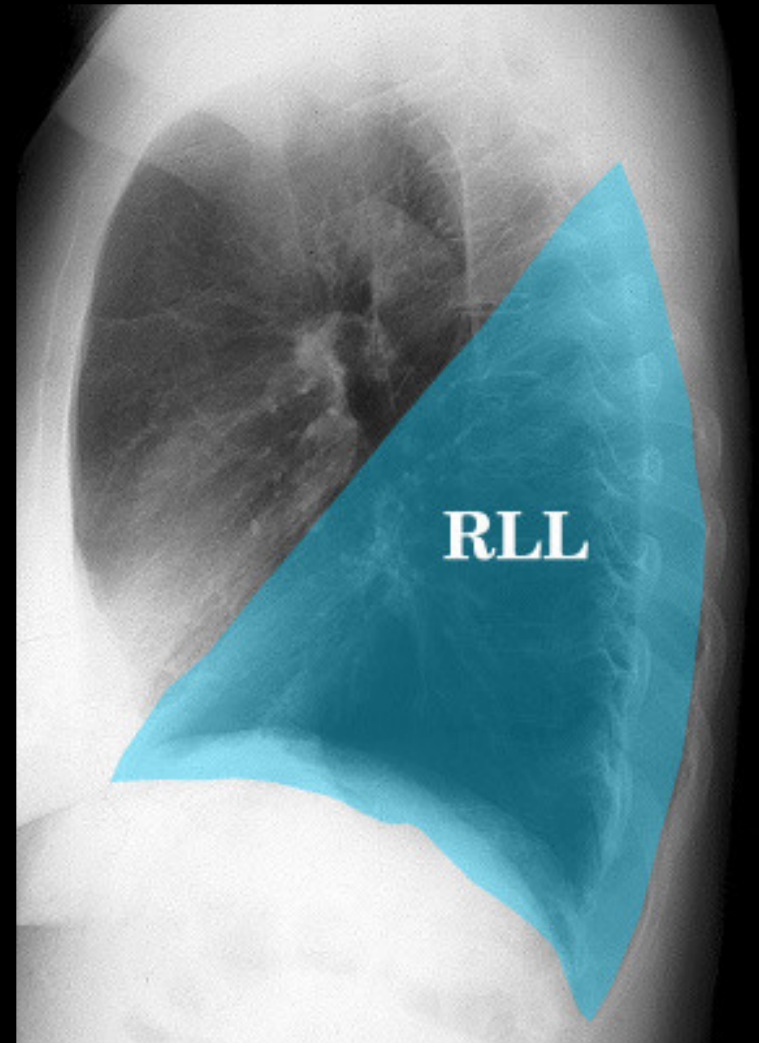
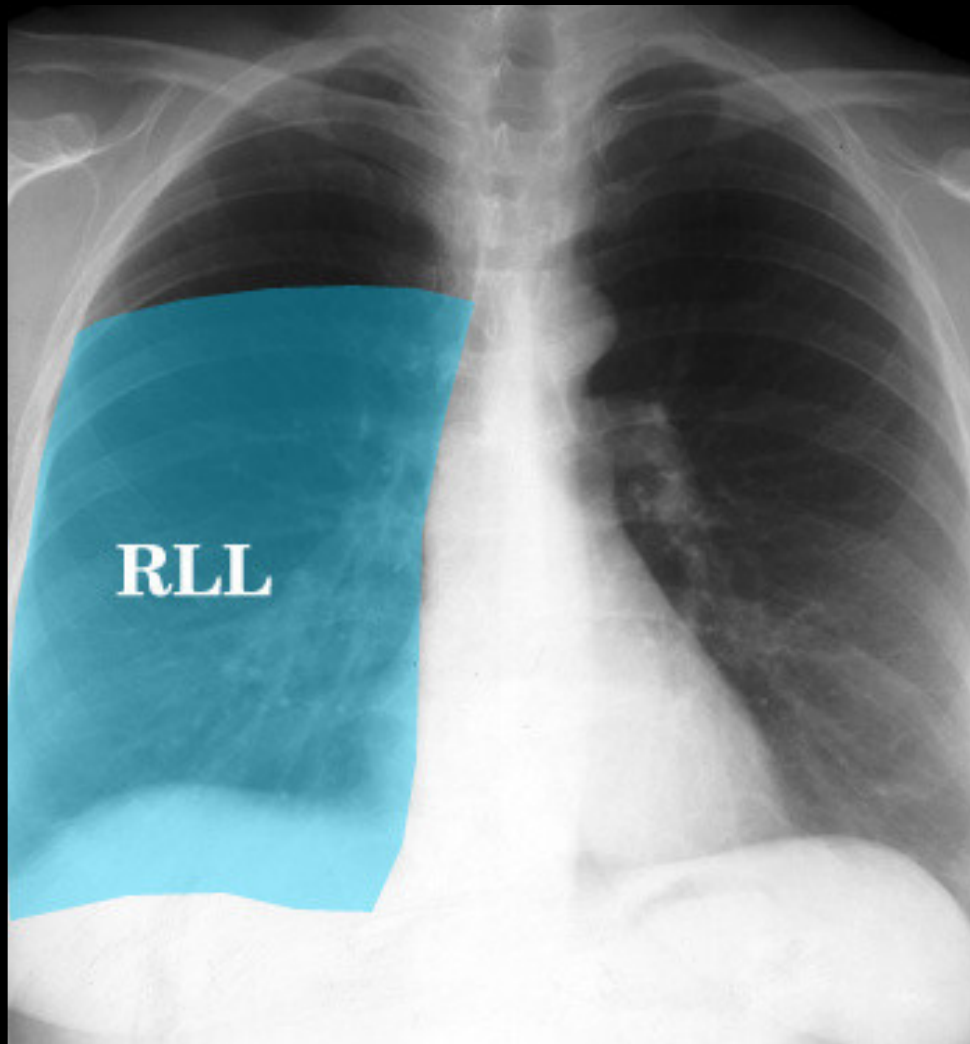
## Radiographie standard



**Lobe supérieur droit**

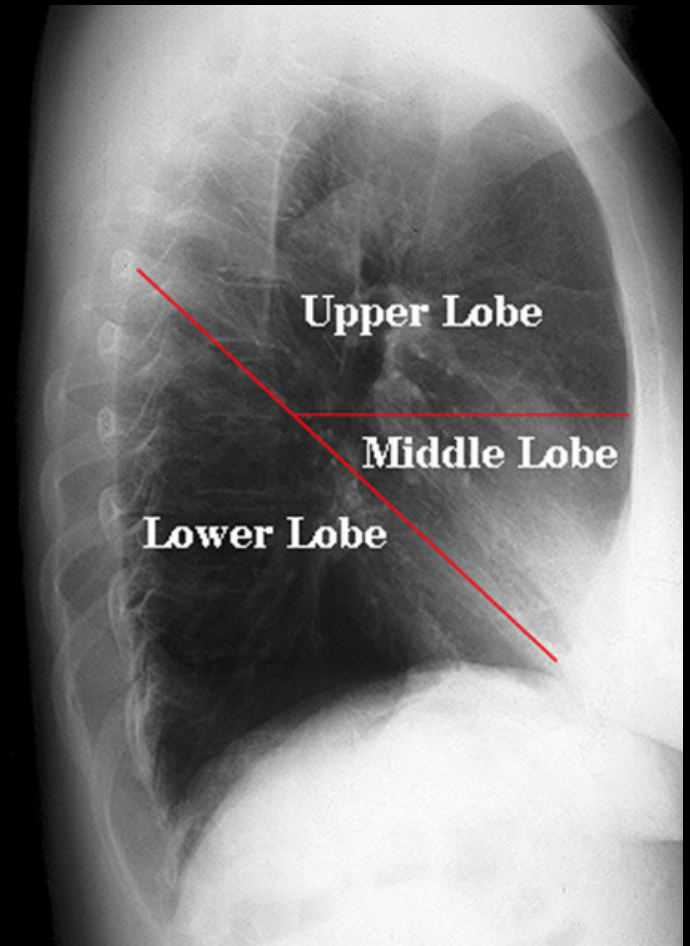
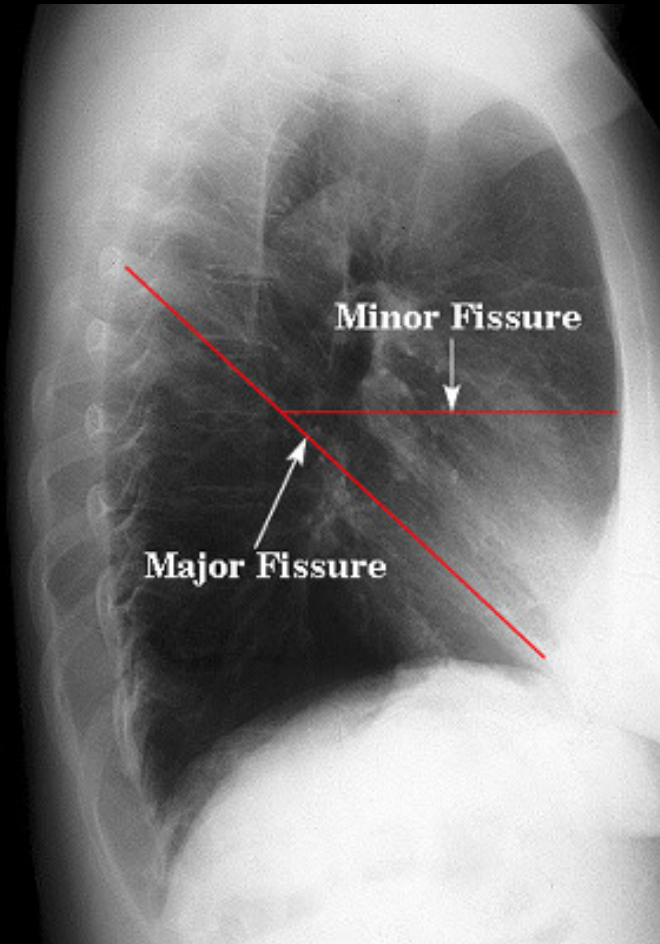


**Lobe moyen**



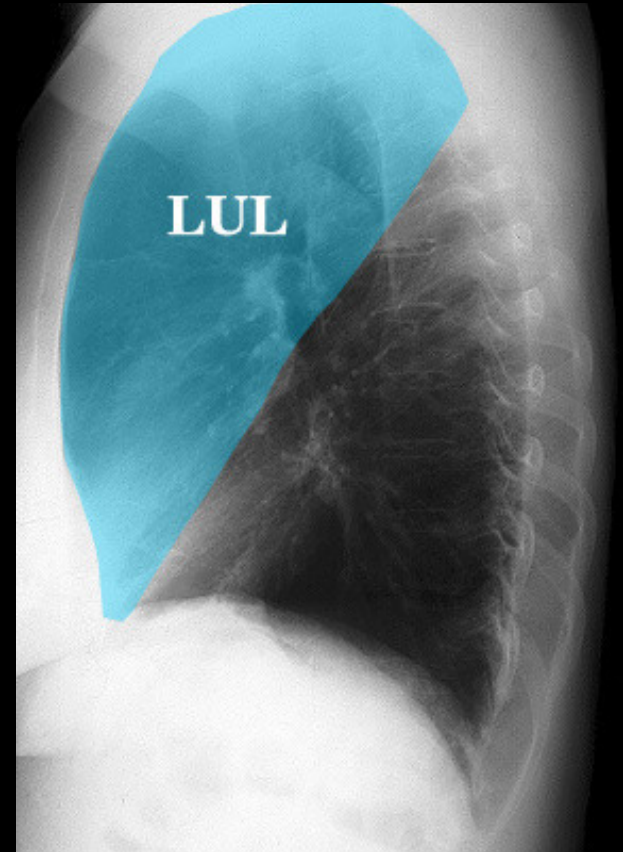
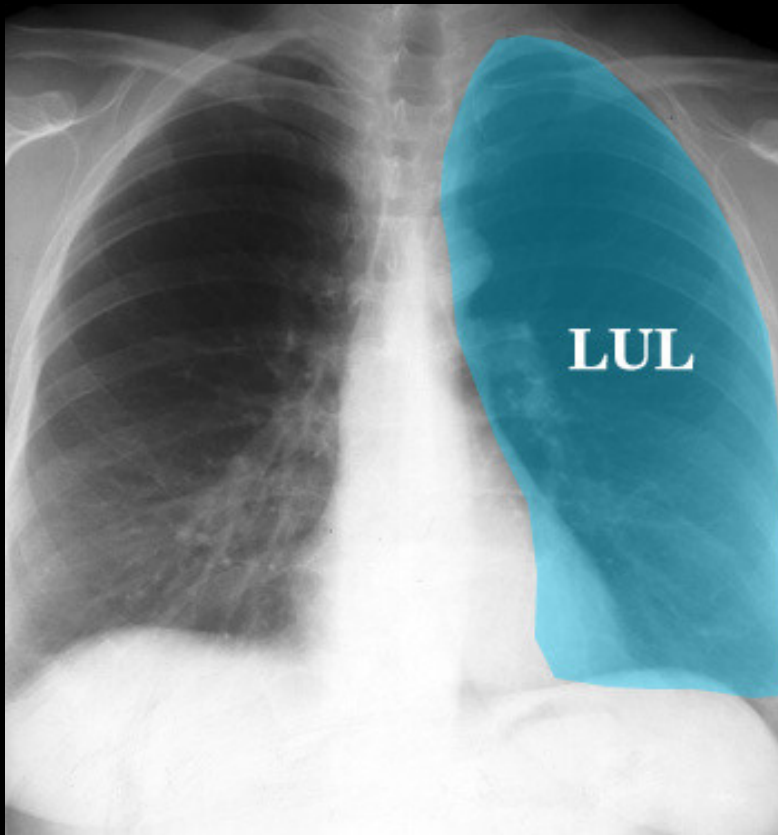
**Lobe inférieur droit**

# A droite: les scissures

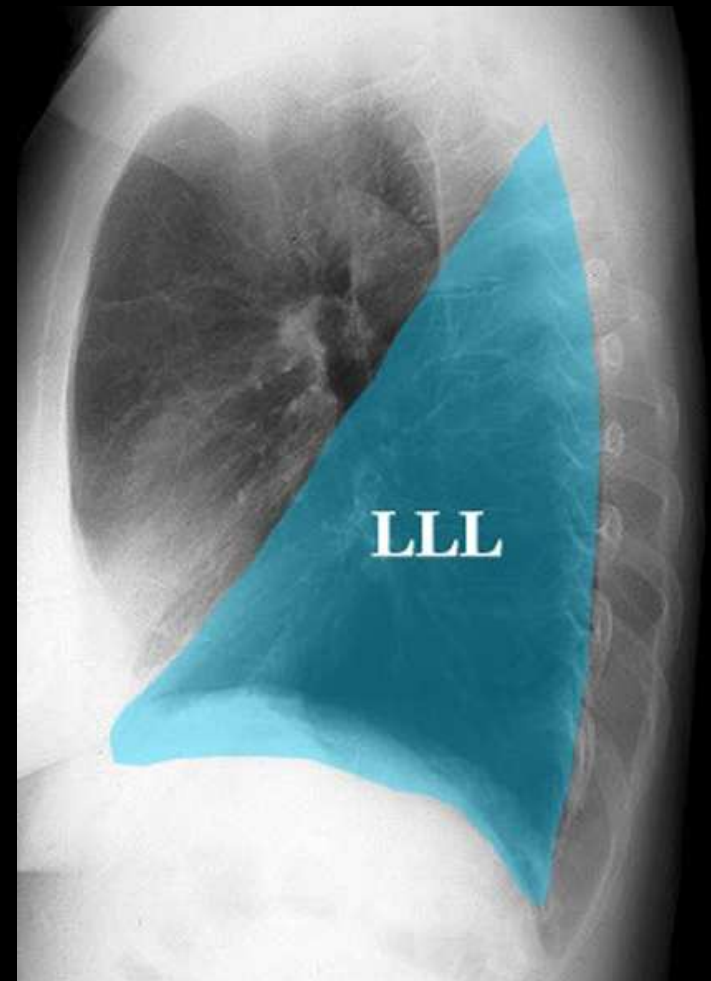
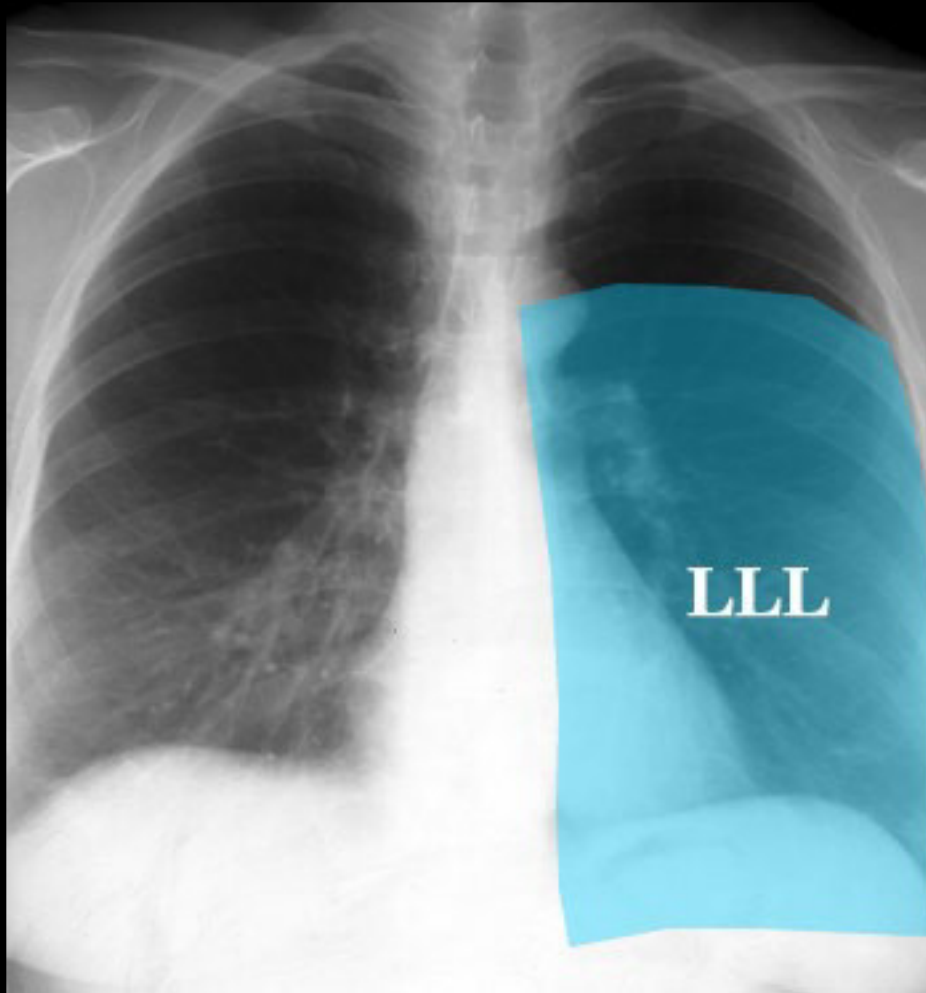


# Application : Le signe de la silhouette de Felson

- 2 structures de tonalité hydrique se confondent si elles sont situées dans le même plan
- De grande valeur pour la détermination topographique d'une opacité intra thoracique qu'elle soit médiastinale ou pulmonaire : en effet deux opacités qui se silhouettent (en effaçant leur bord) se trouvent sur un même plan.
- ex : opacité dans le lobe moyen effaçant le bord droit du coeur.

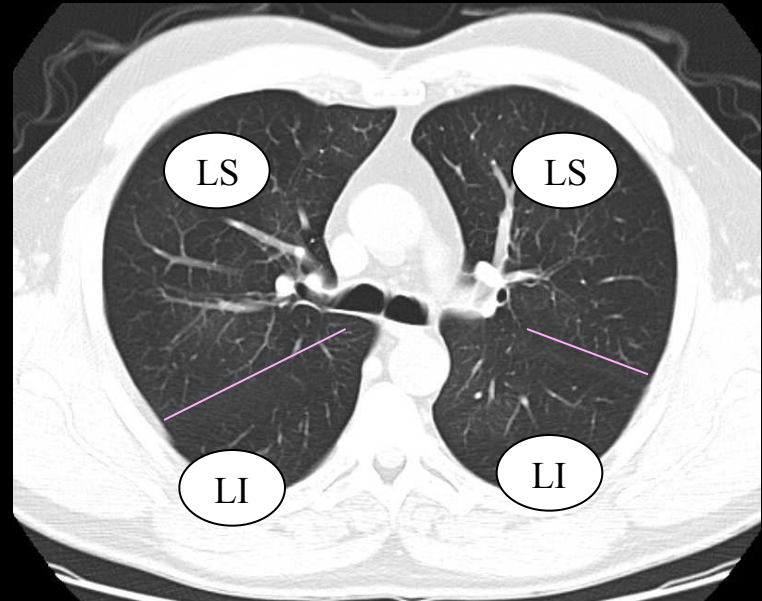
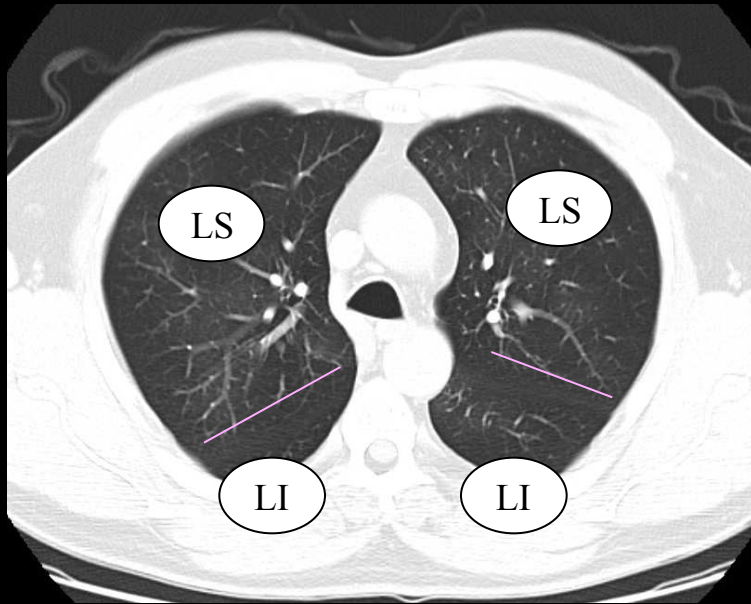
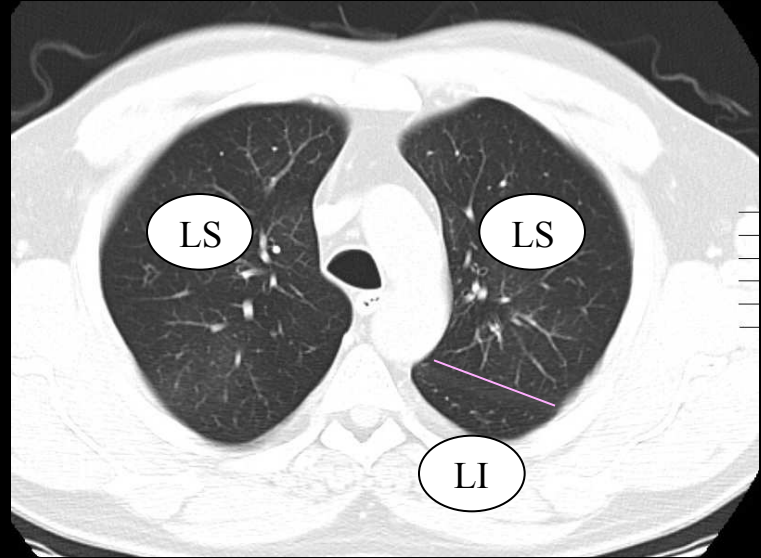
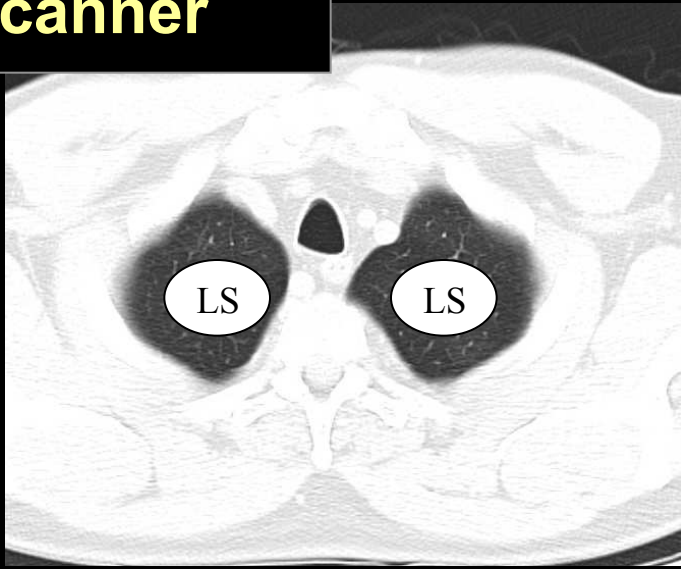


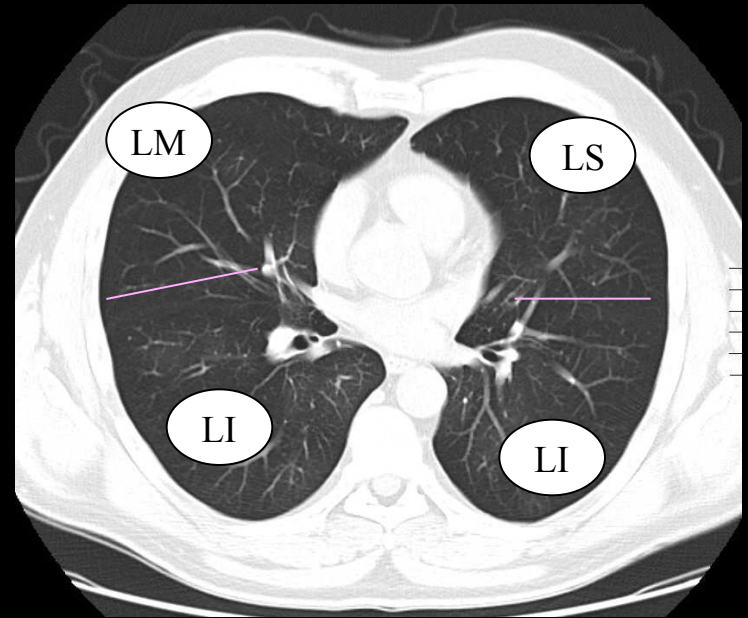
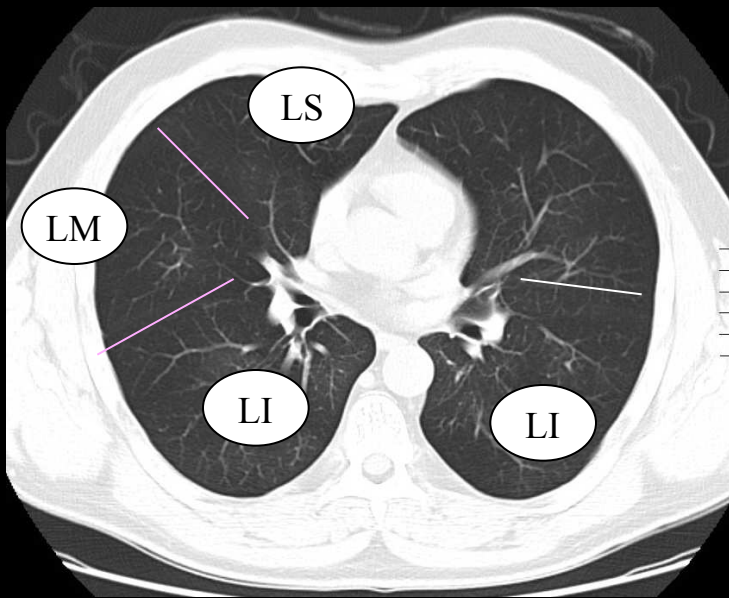
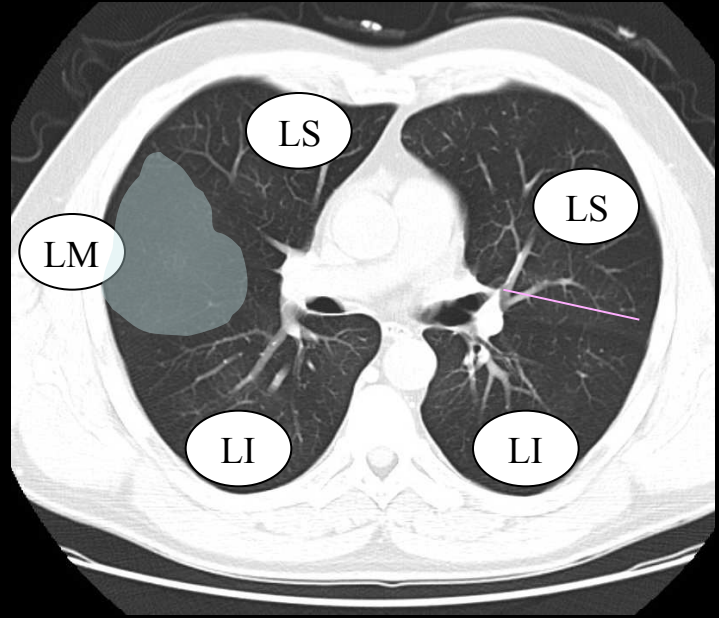
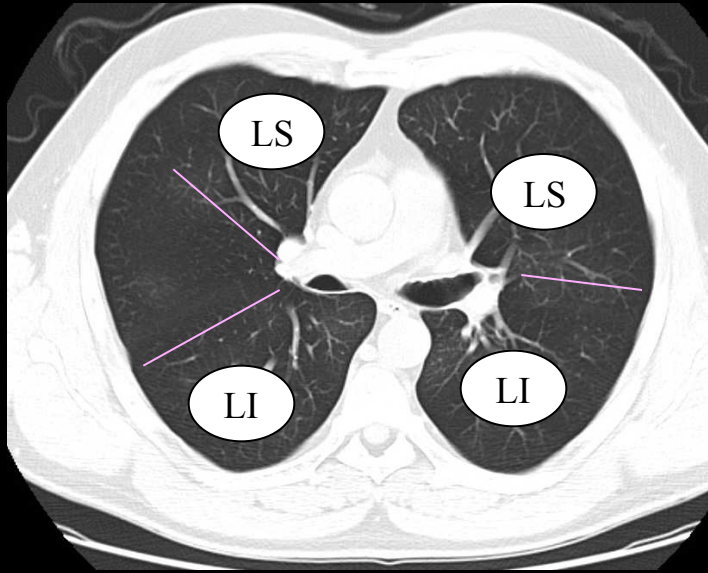
**Lobe supérieur gauche**

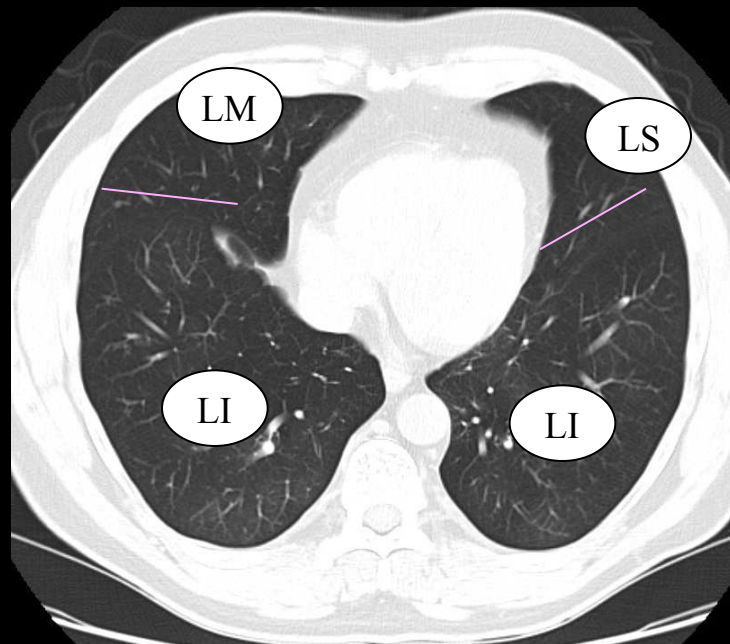
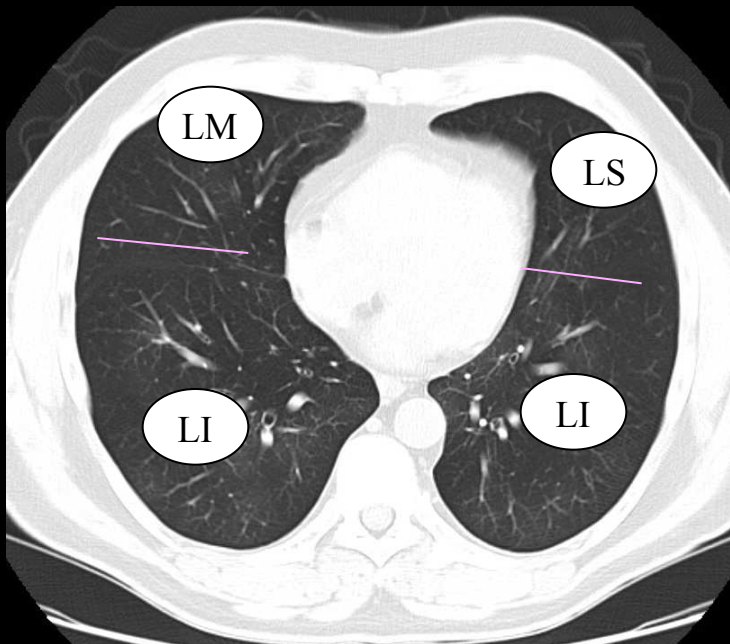
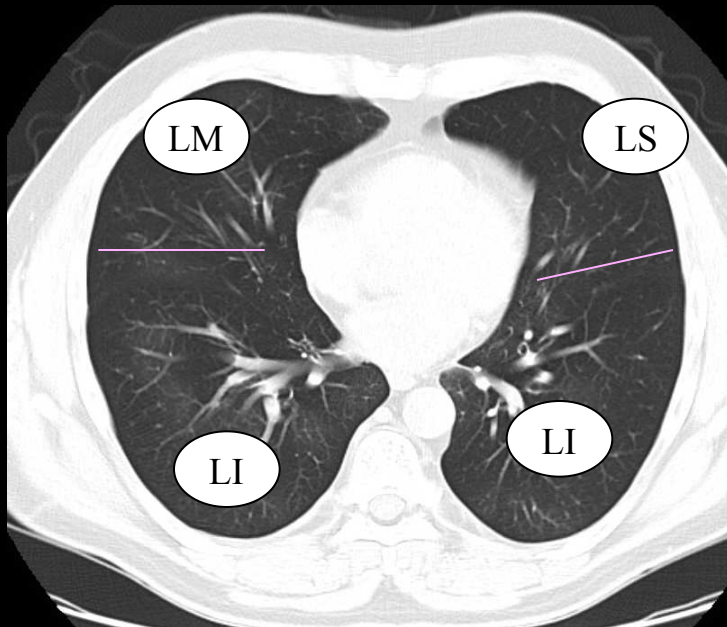
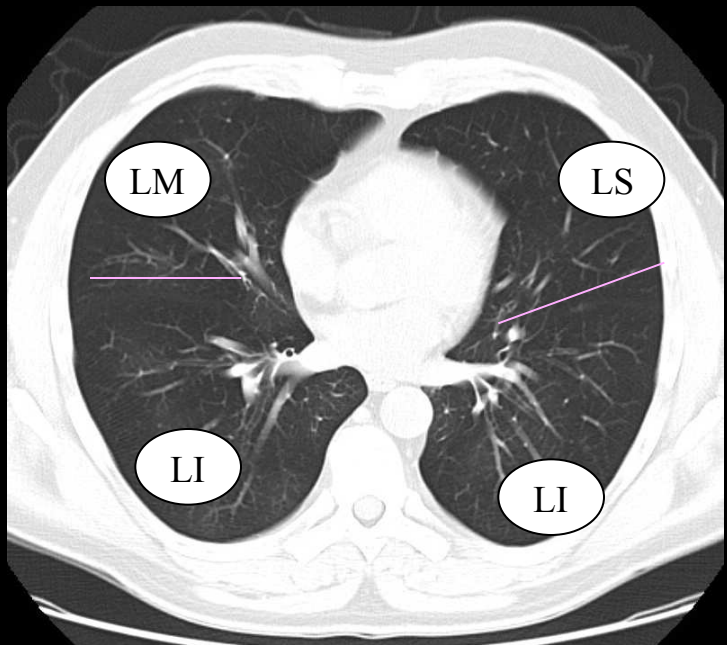


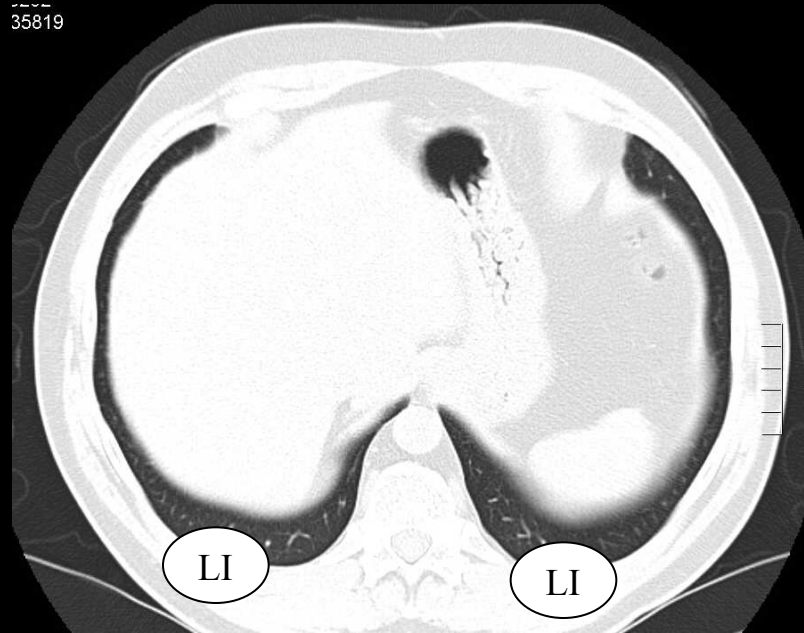
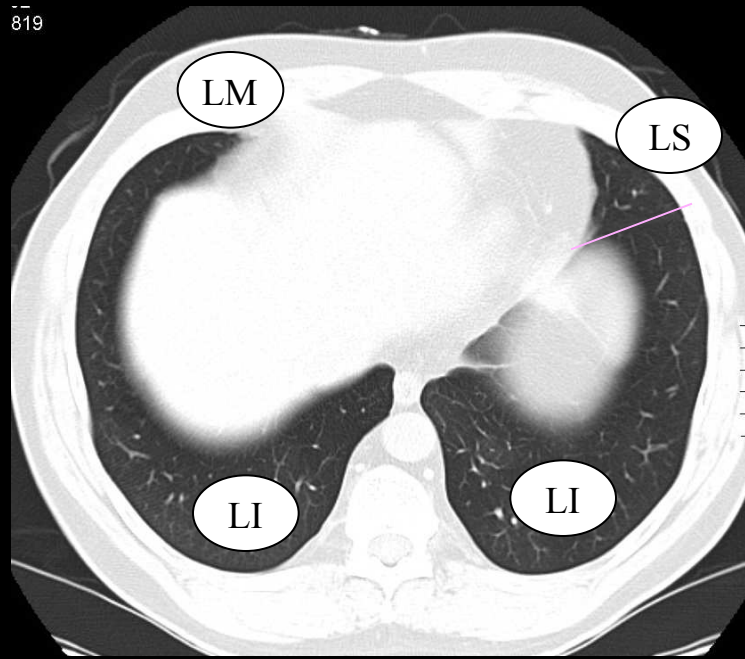
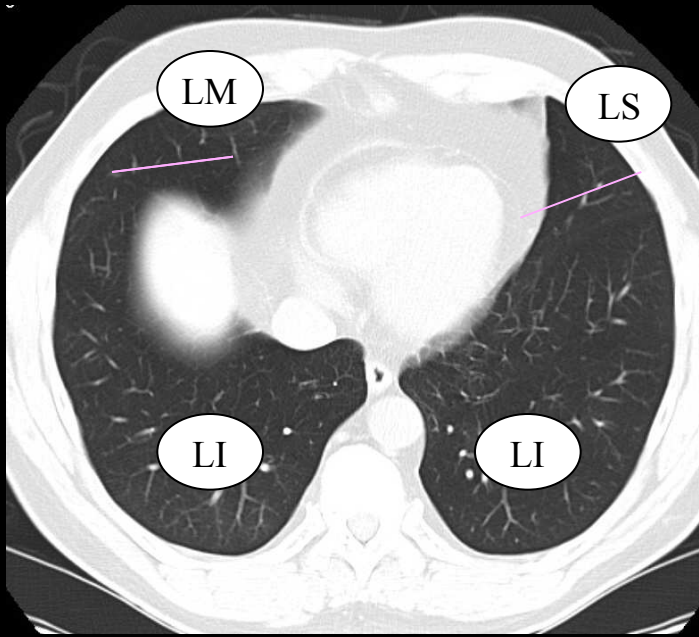
**Lobe inférieur gauche**

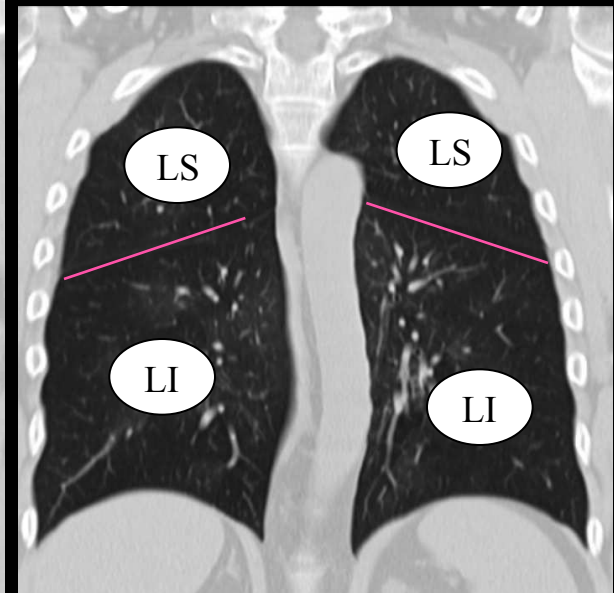
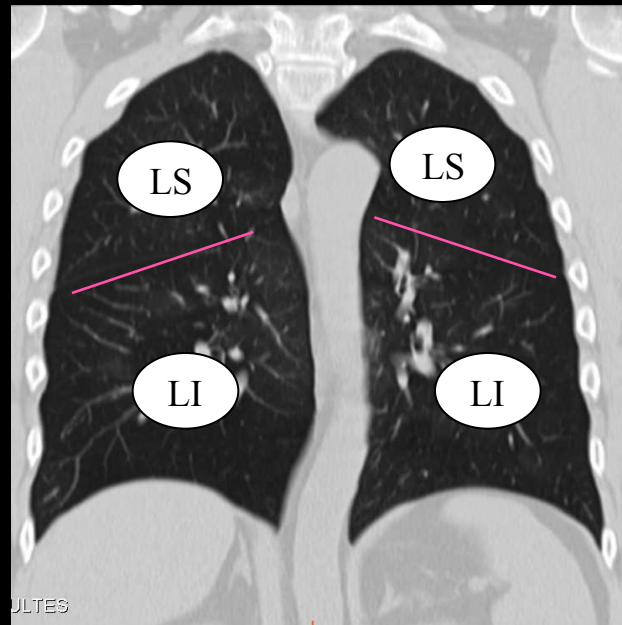
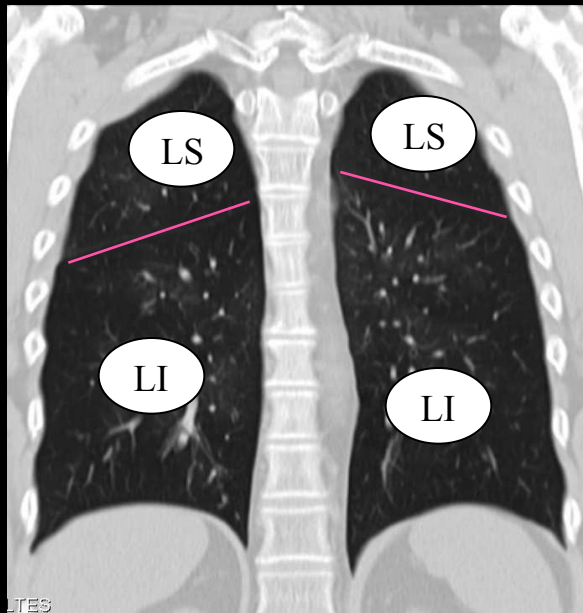
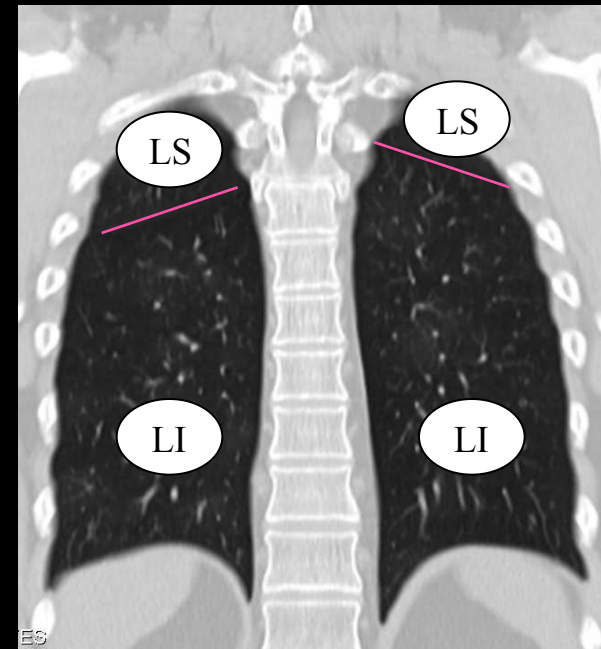
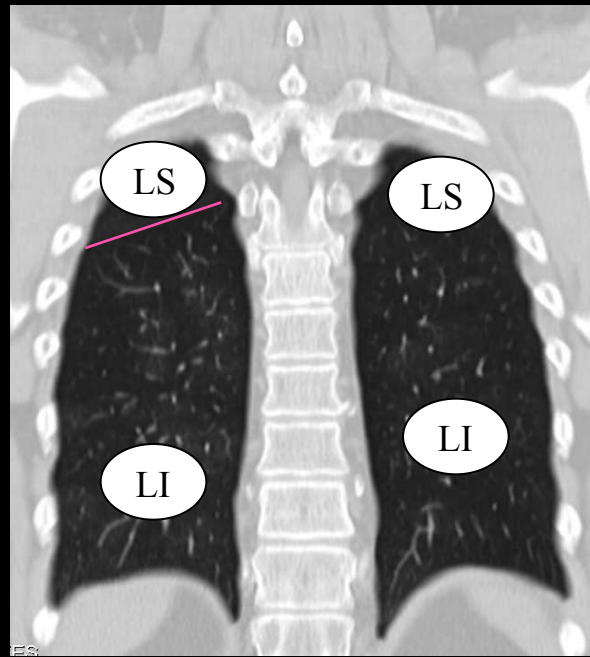
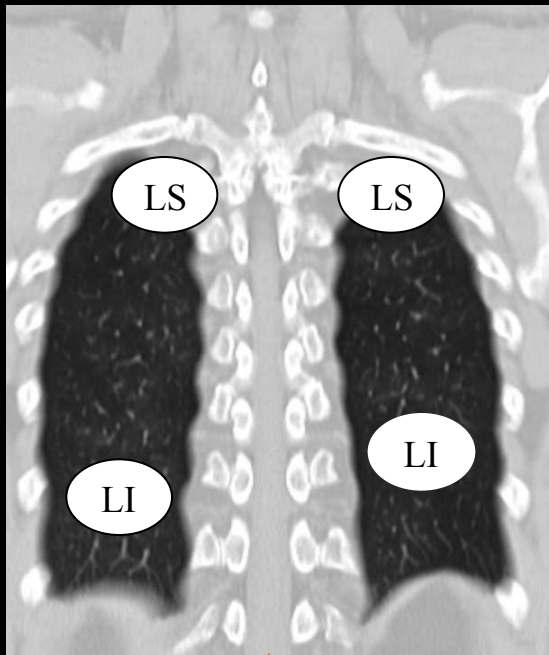
# Scanner

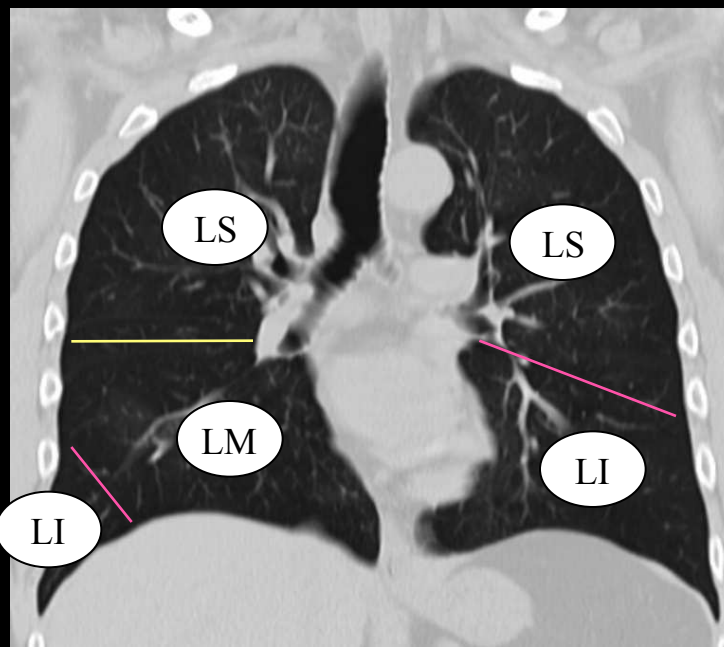
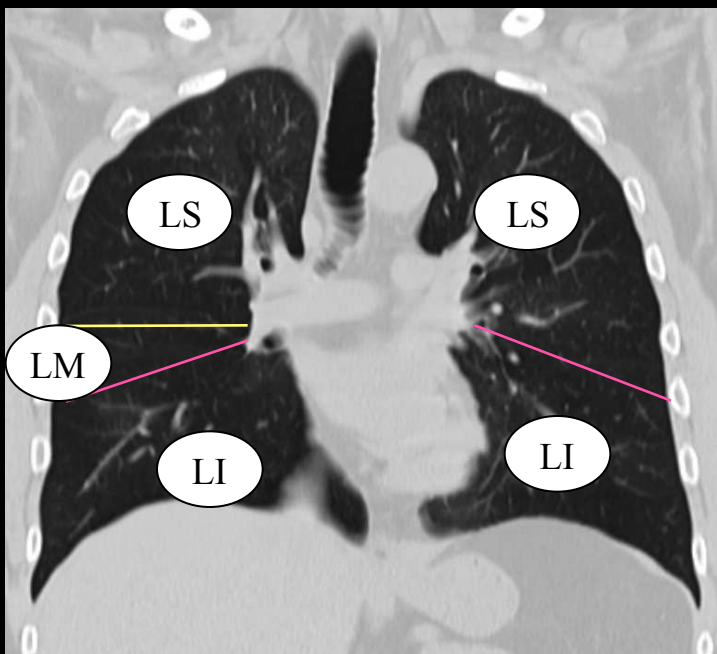
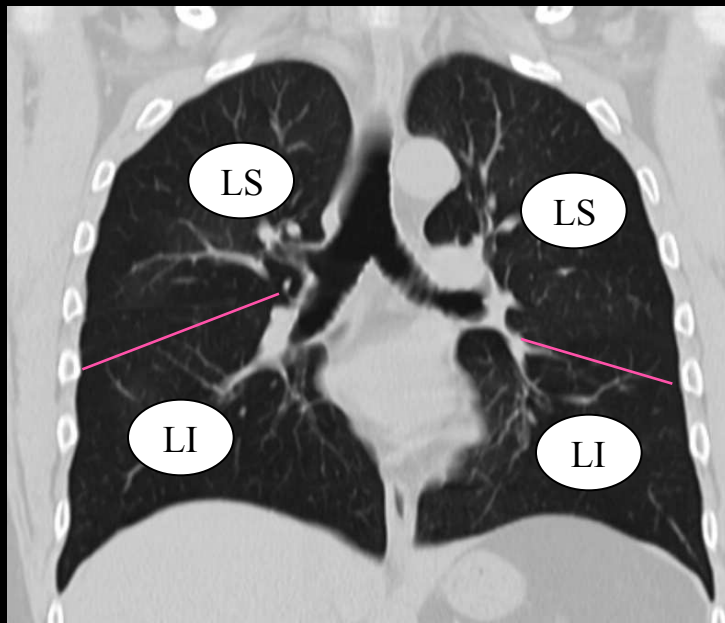
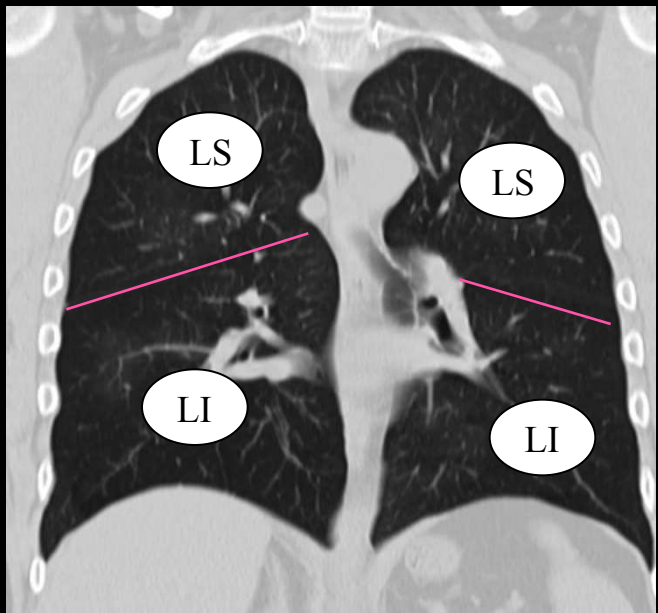


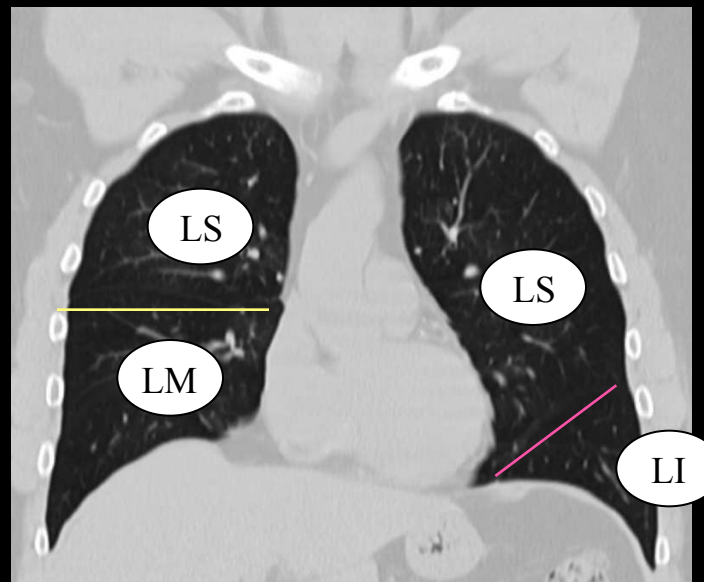
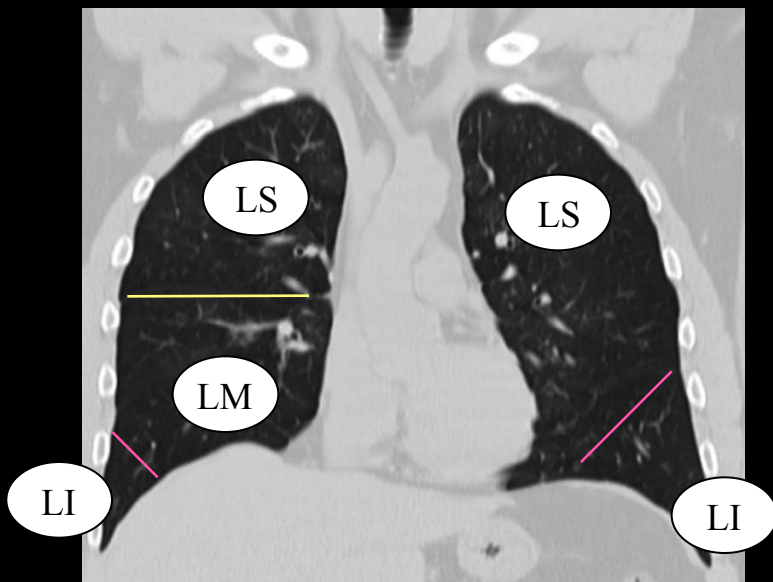
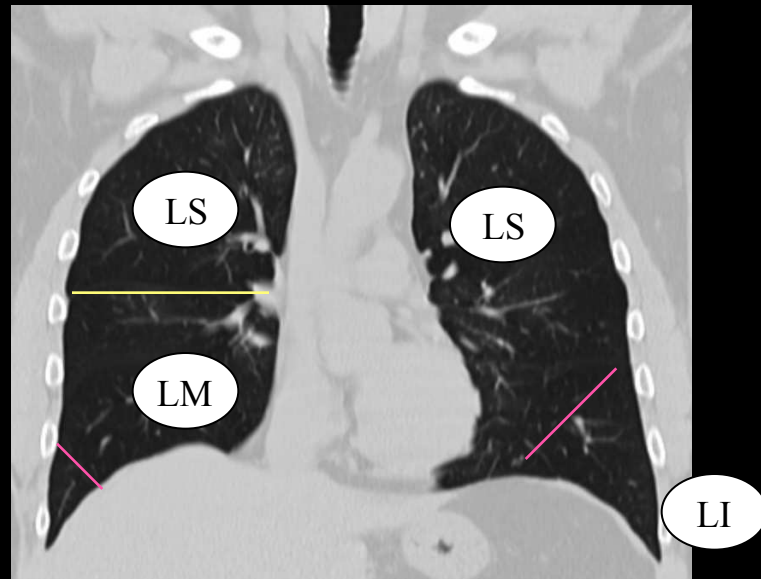
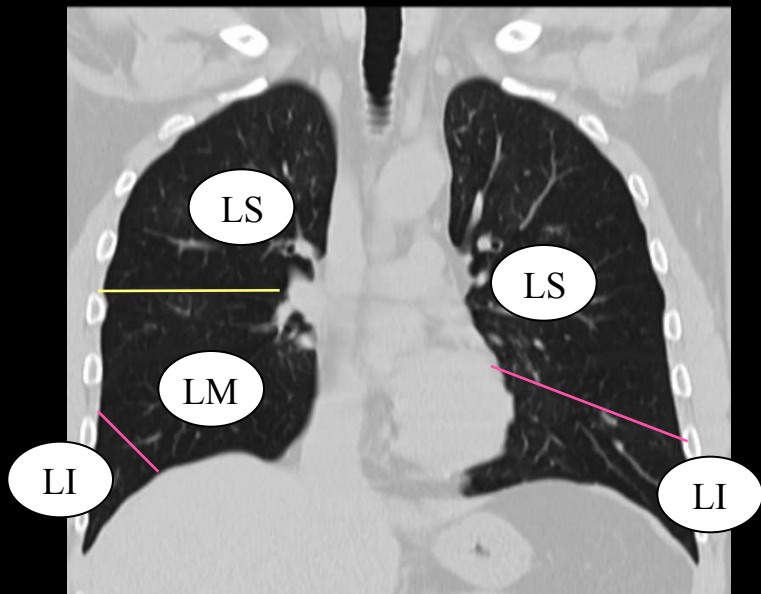








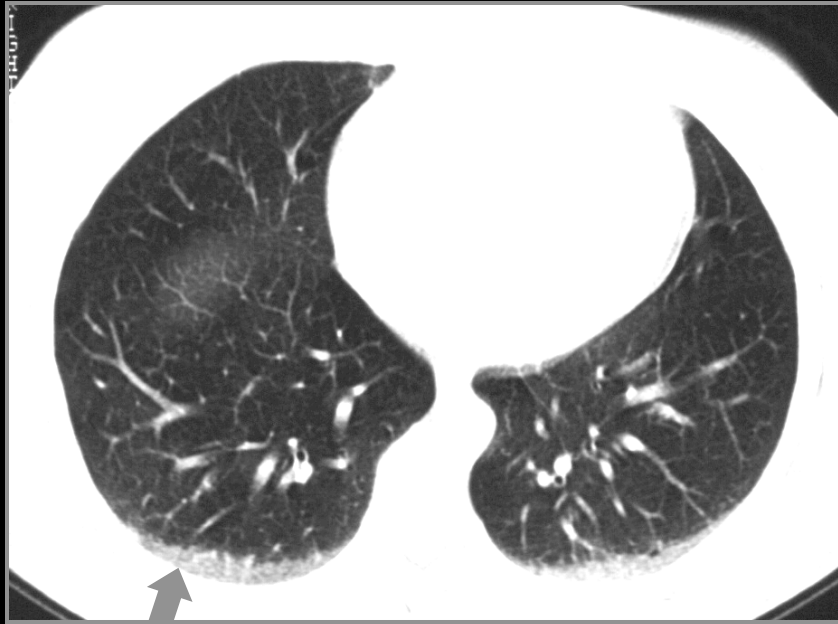






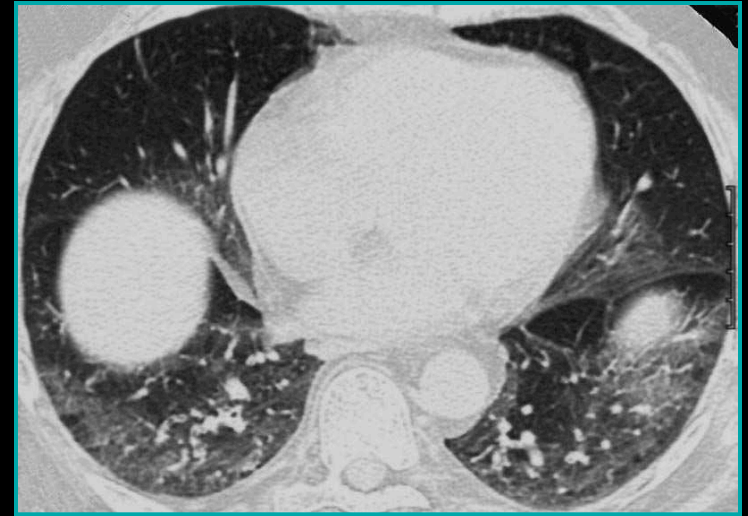
**UN PEU DE PATHOLOGIE ET  
VARIATIONS ANATOMIQUES...**

# Stase Physiologique

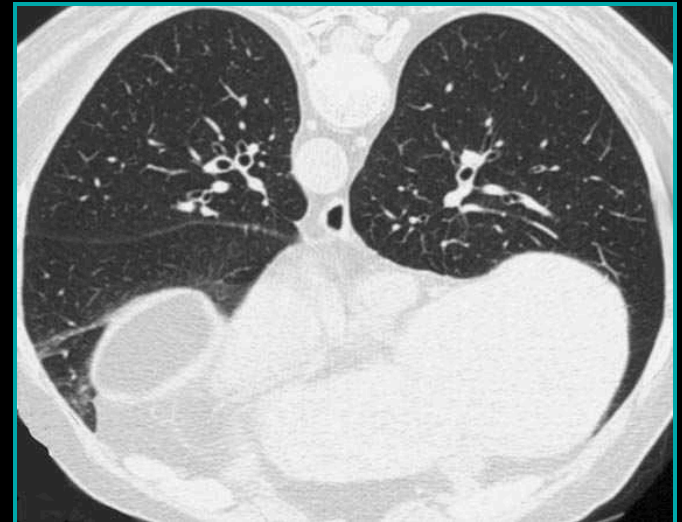


Territoires  
Déclives

inspiration



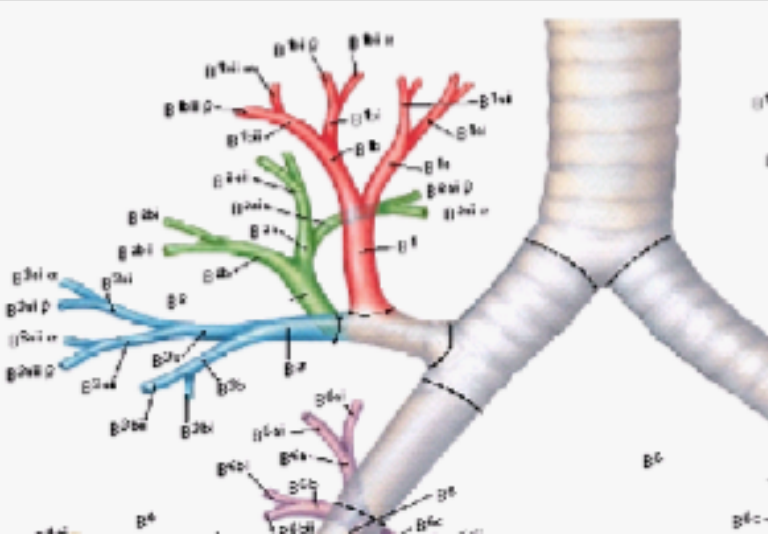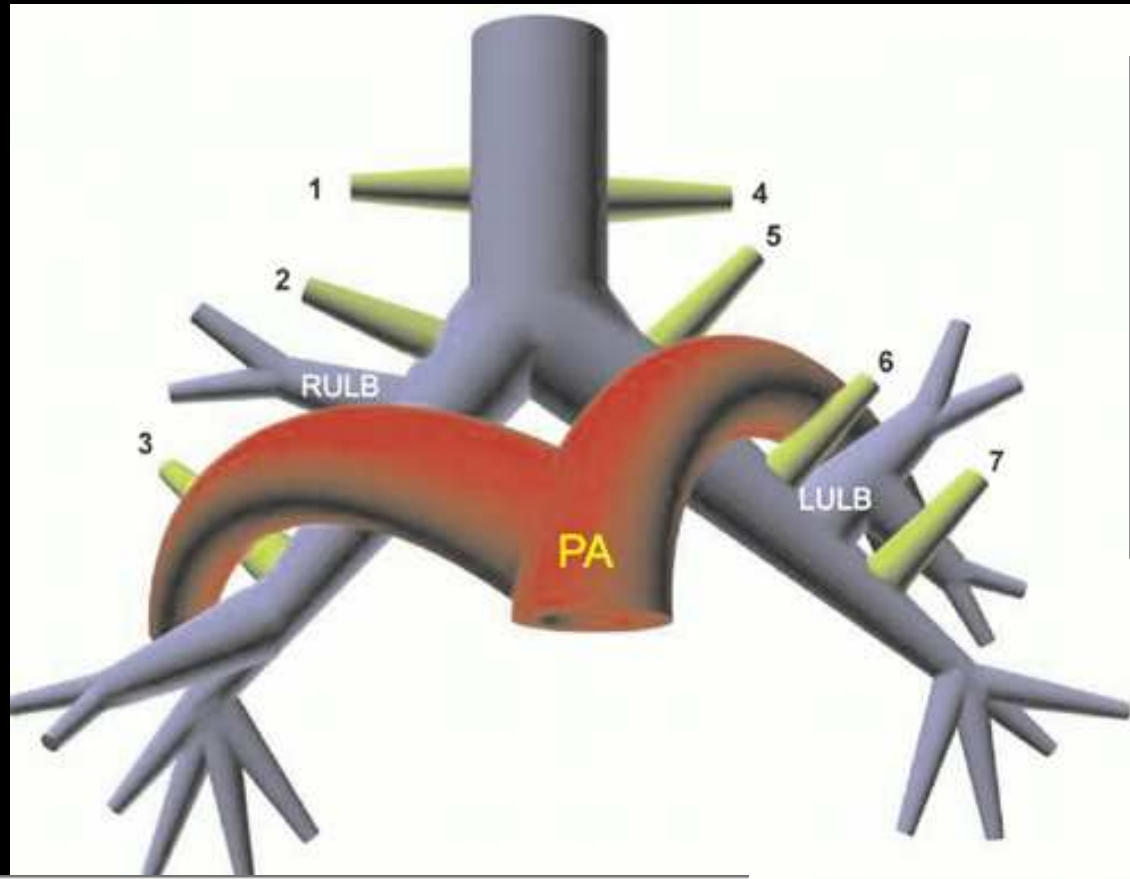
procubitus

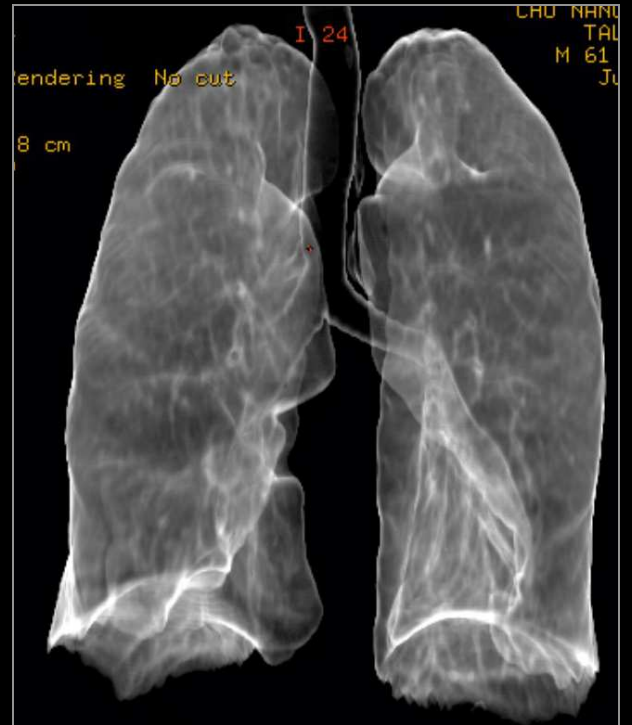
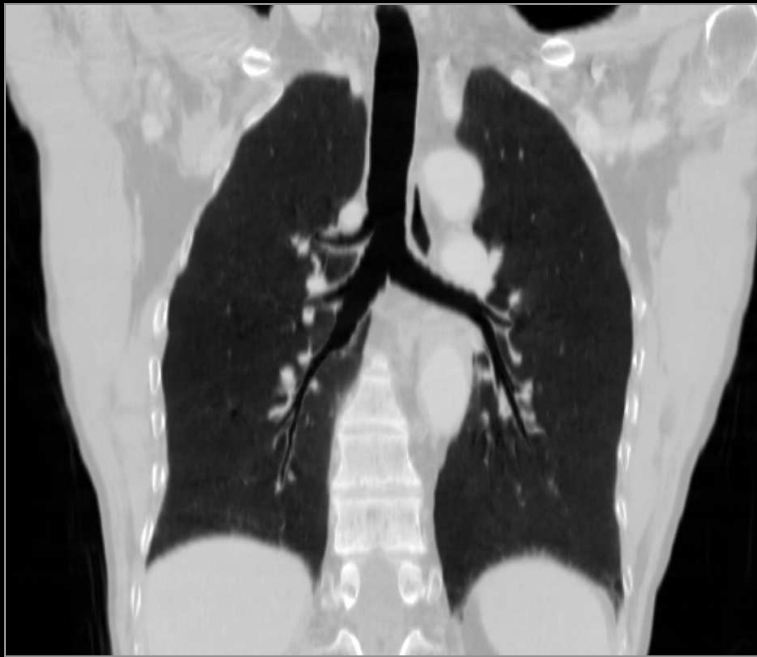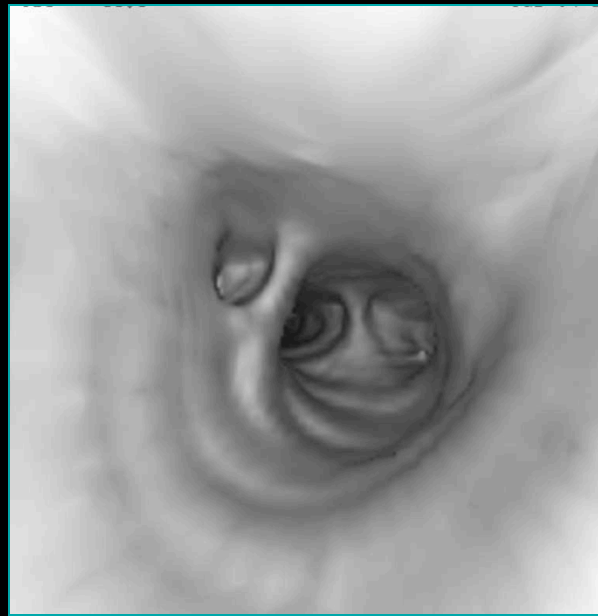
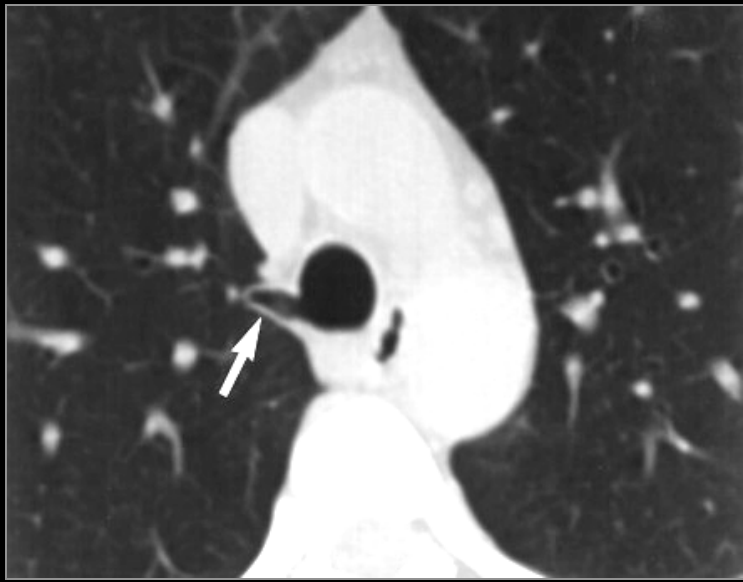


## Bronche ectopique

Les plus fréquentes 2%

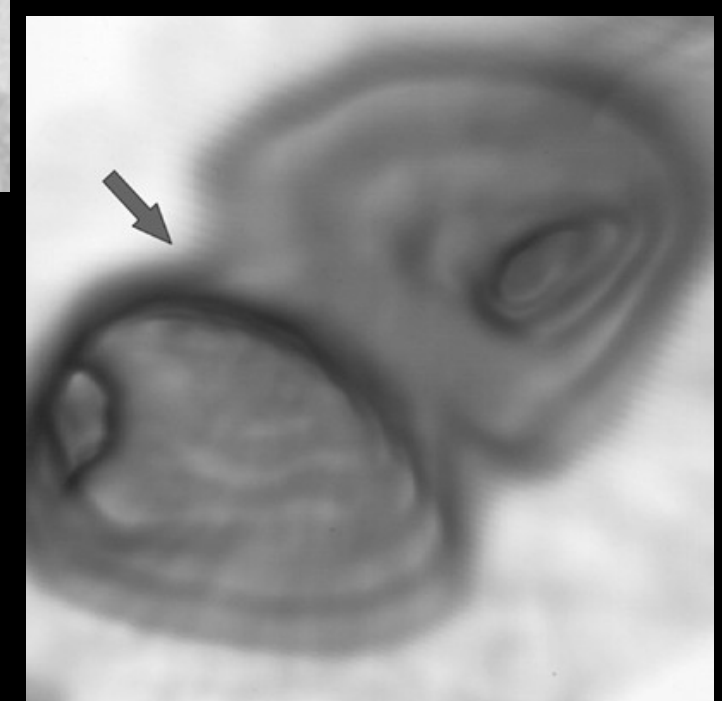
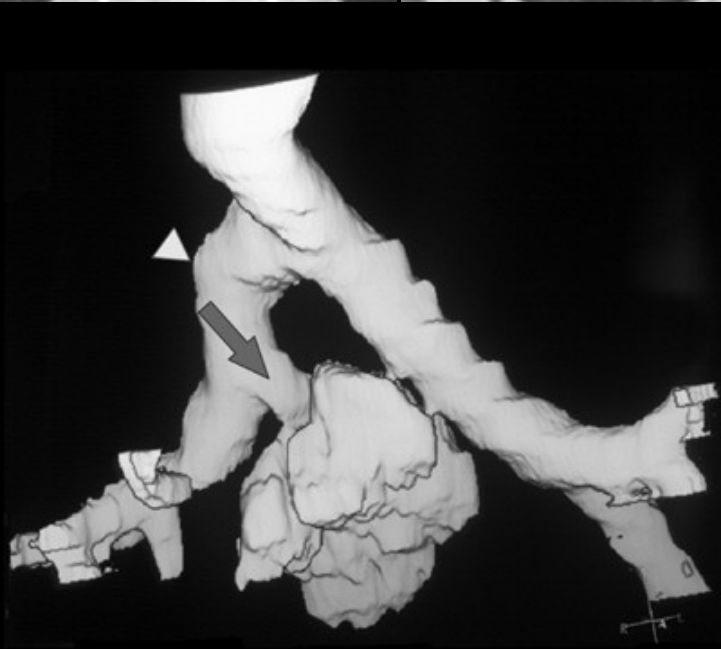
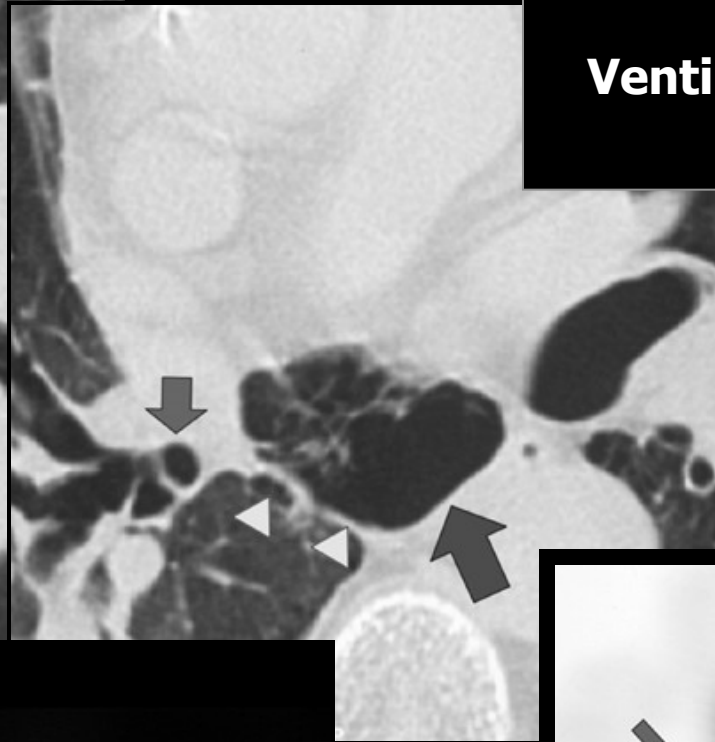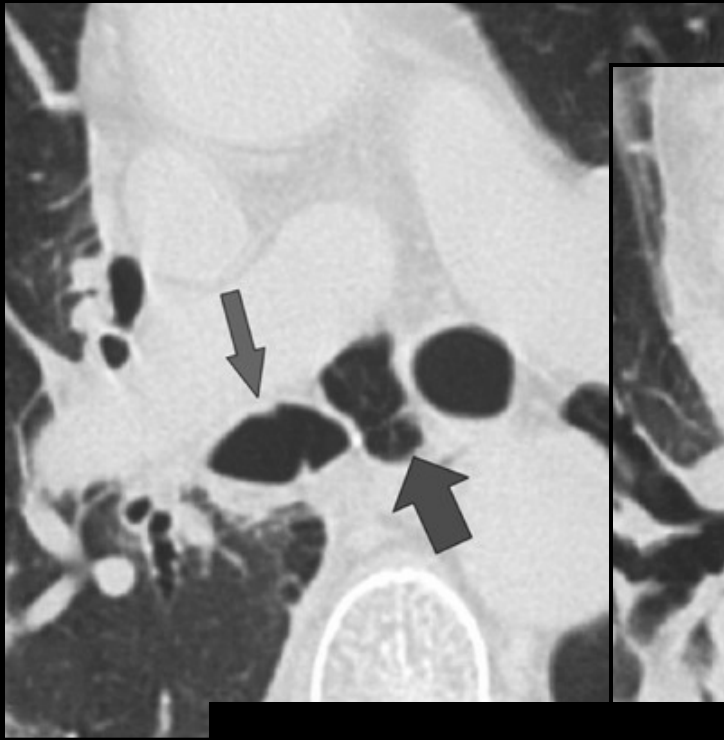
Origine déplacée  
drainage territoire normal  
anatomiquement





## Bronche surnuméraire

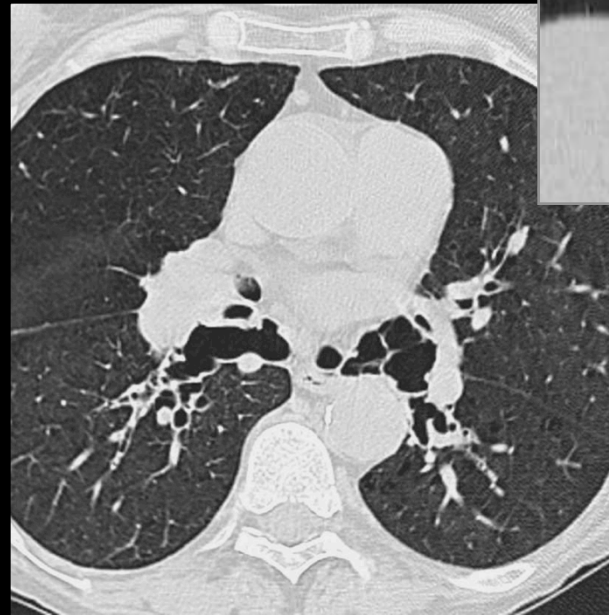
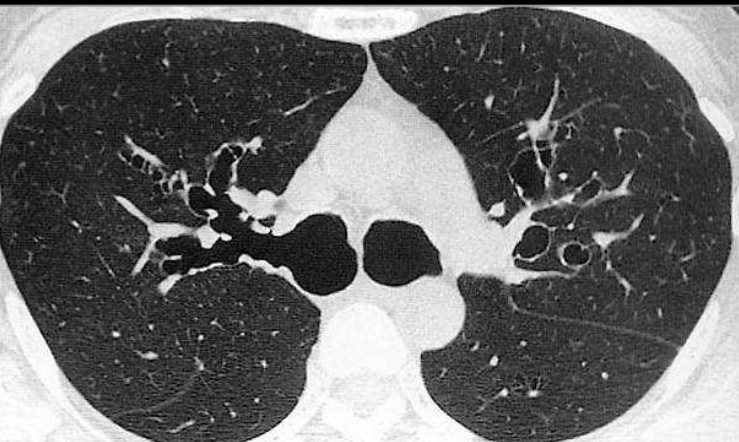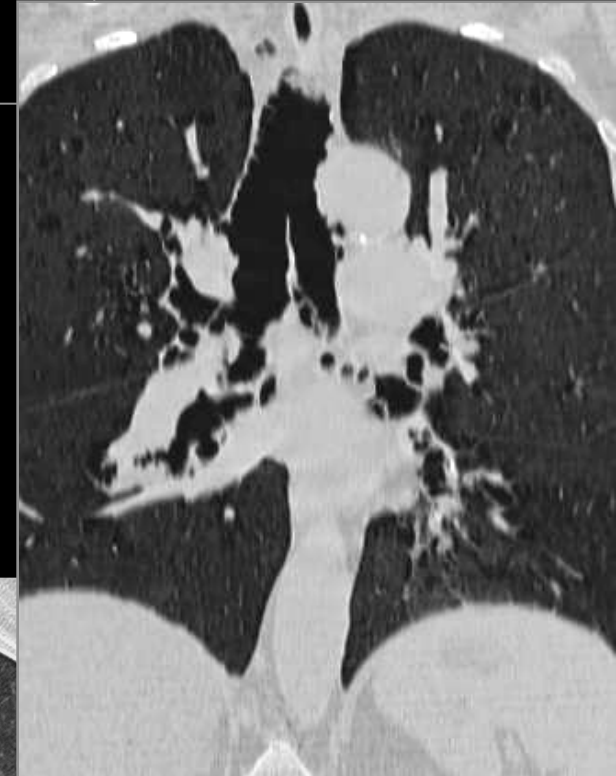
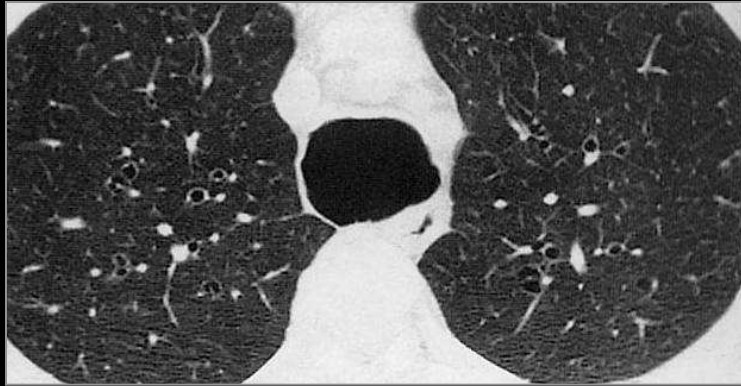Ventilation d'un territoire supplémentaire



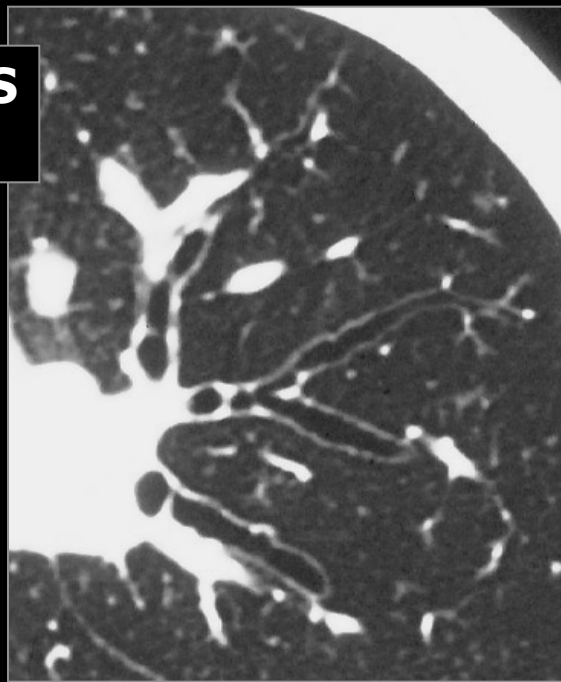
# Trachéobronchomégalie (maladie de Mounier-Kuhn)

Maladie des tissus musc. et élastiques

Maladie intrinsèque VA ou associée à maladie Ehler Danlos



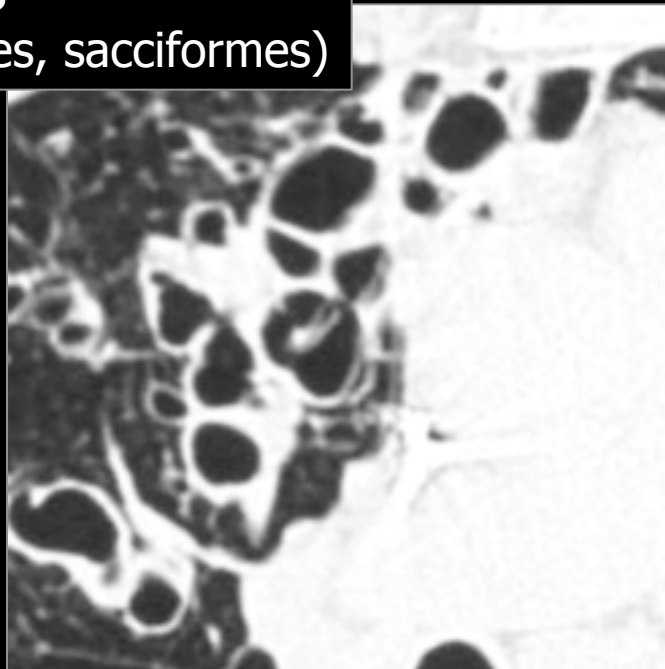
**CYLINDRIQUES**  
(= fusiformes)



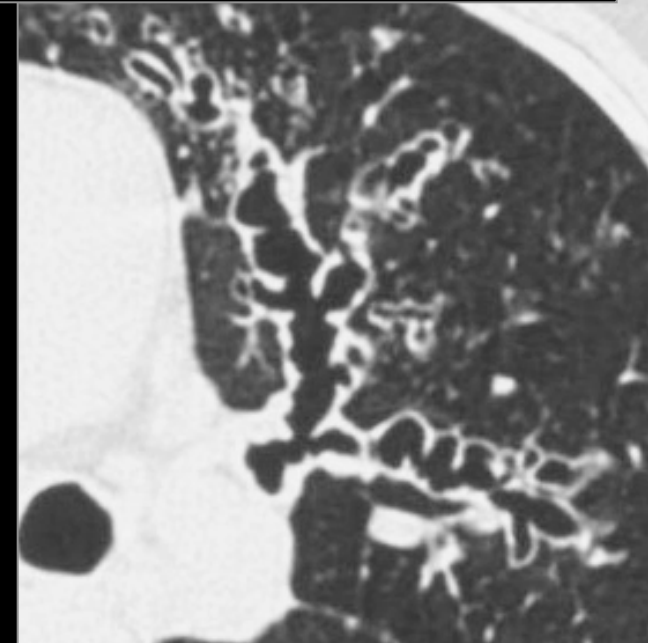
**Bronchiectasies**  
**Classification de Reid**  
**(1950)**

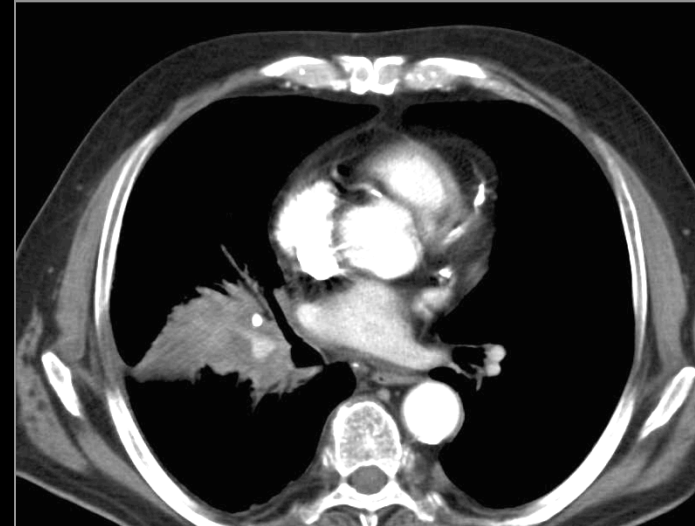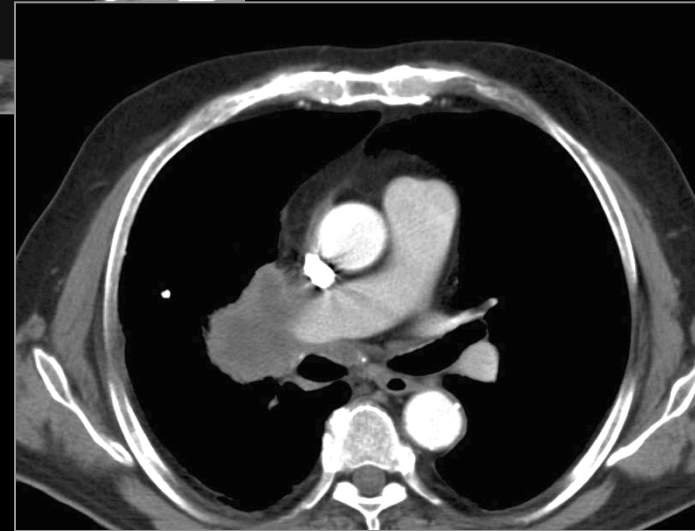
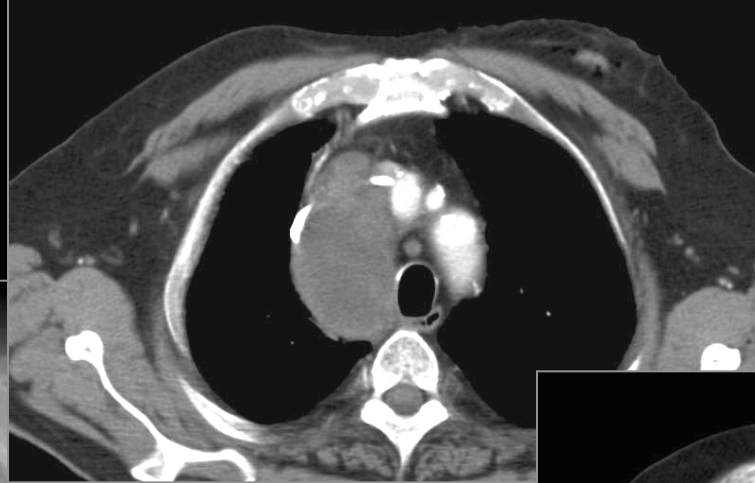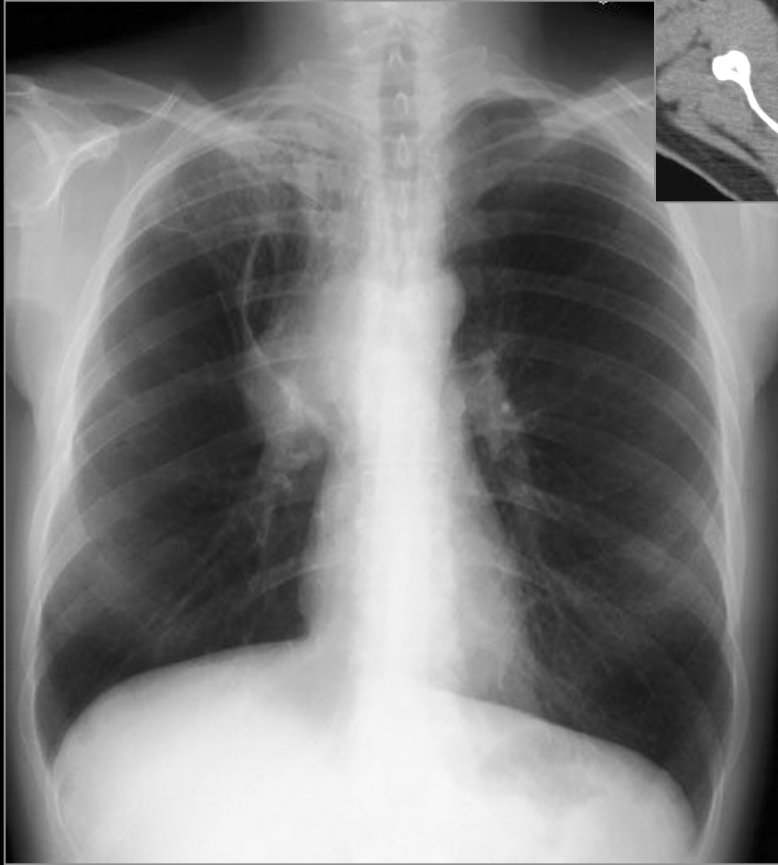


**KYSTIQUES**  
(= ampullaires, sacciformes)

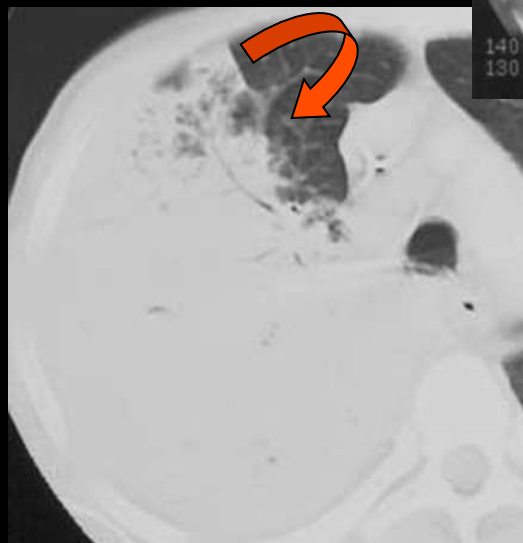
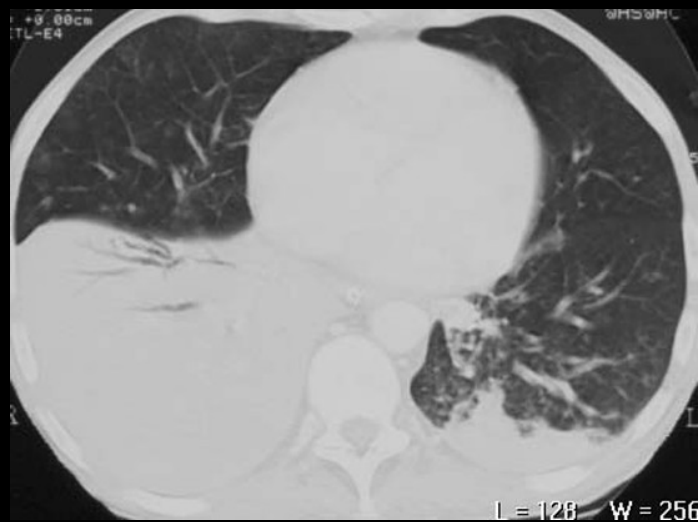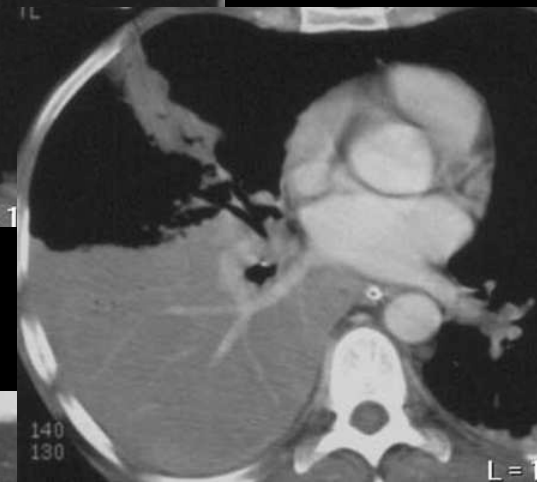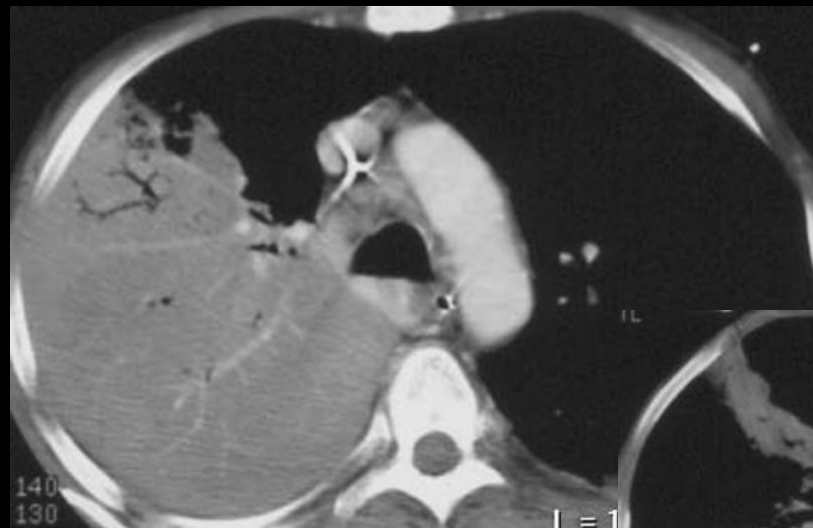


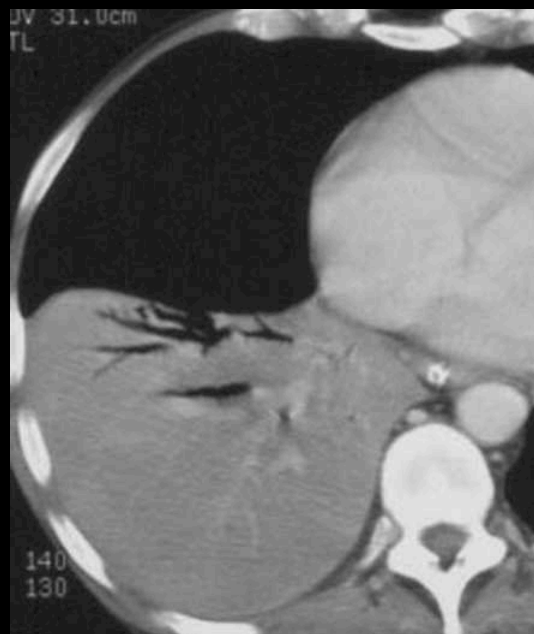**VARIQUEUSES**  
(= moniliformes, en grappe)

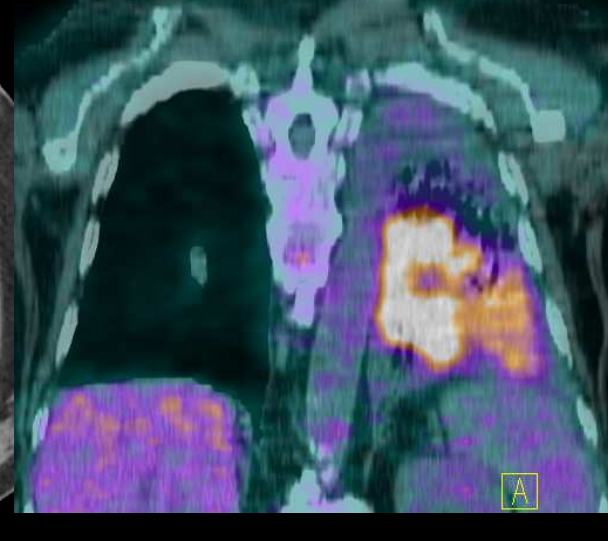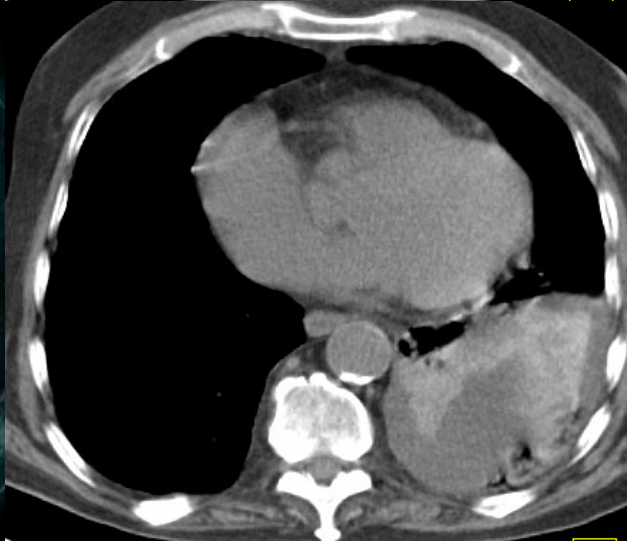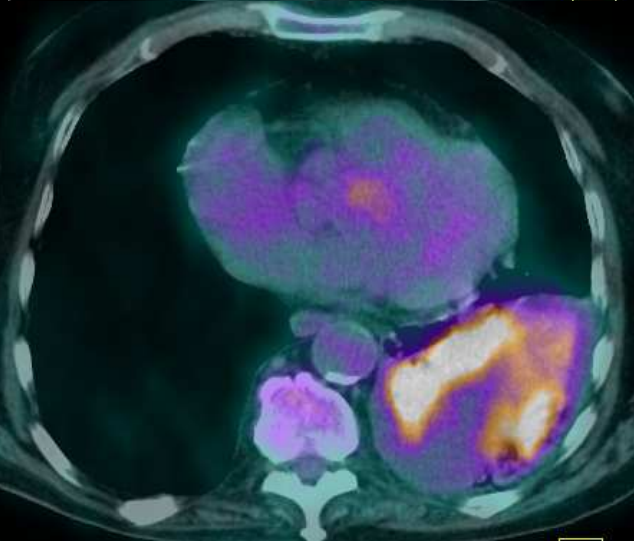
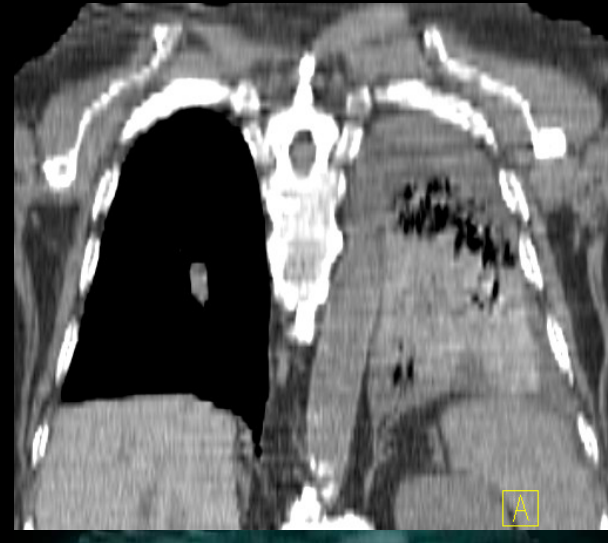
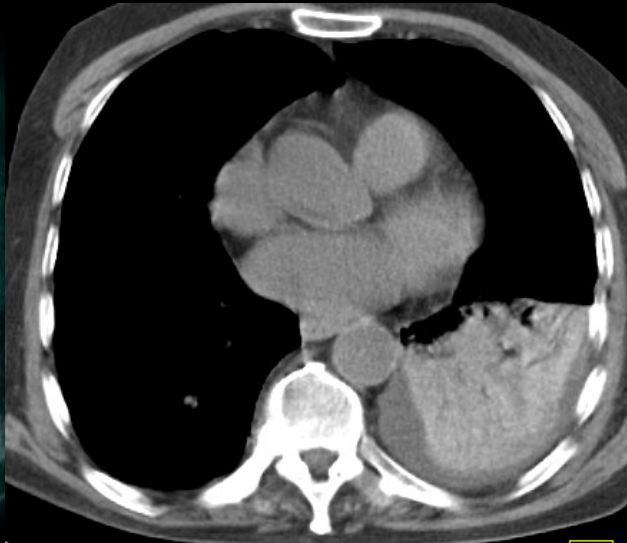


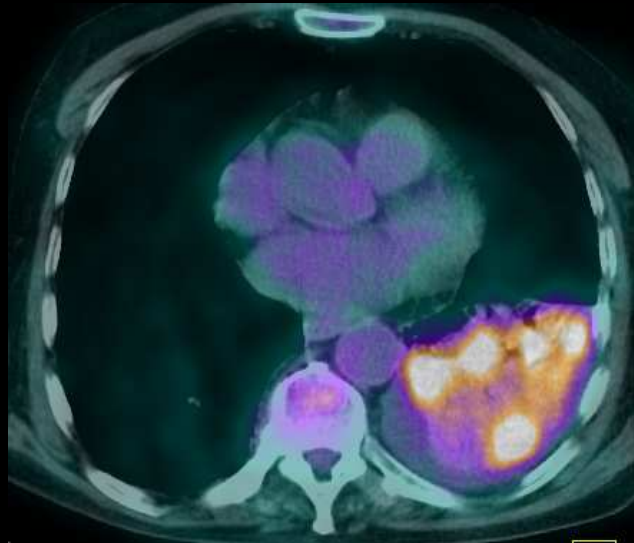

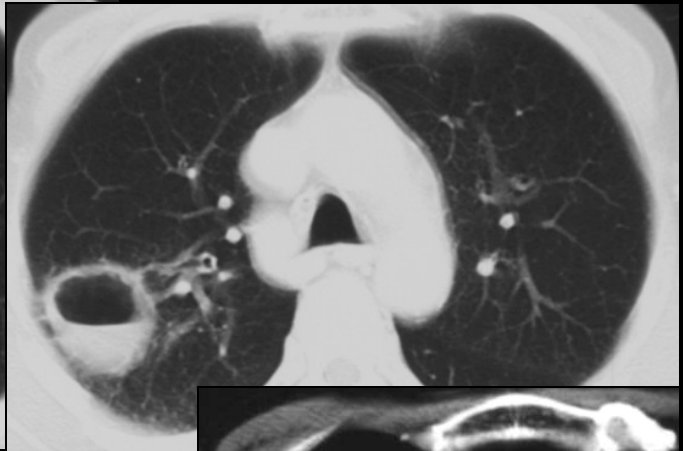
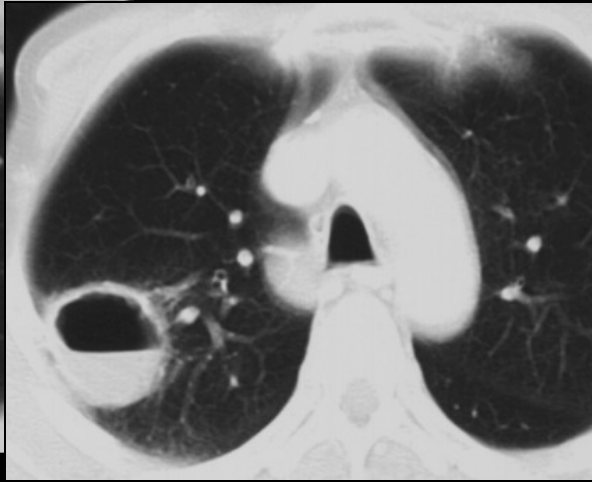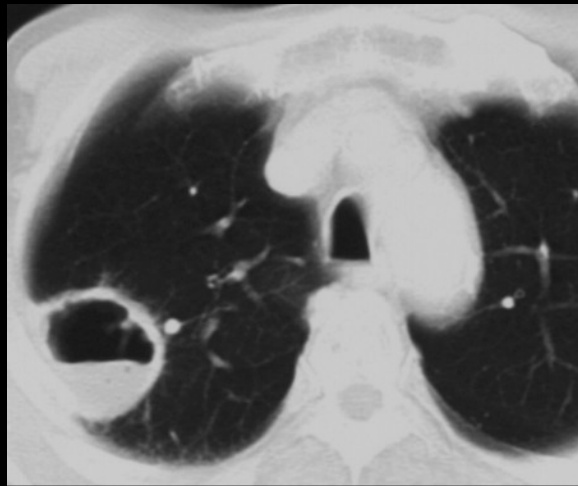
**Scissure azygos et carcinome à petites cellules**



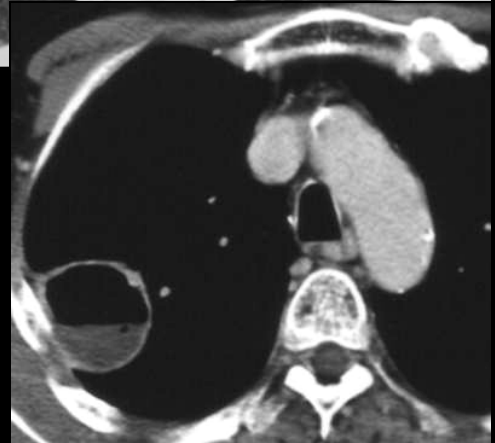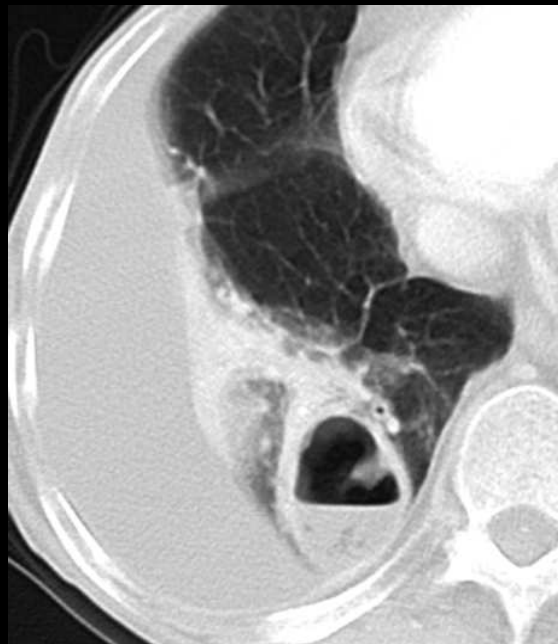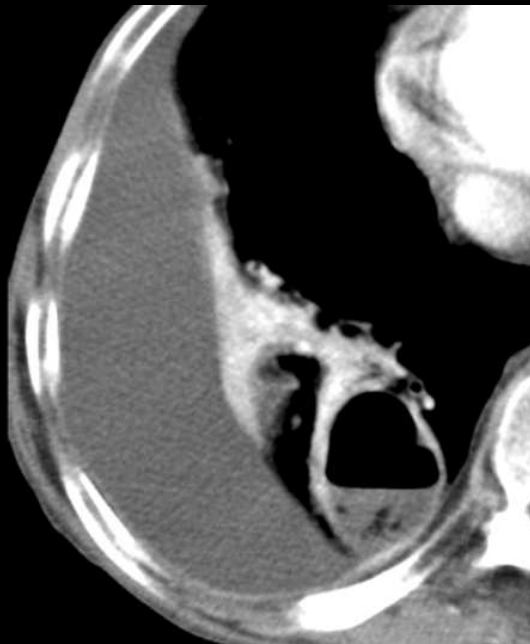**PFLA du lobe inférieur ( hépatisation )**



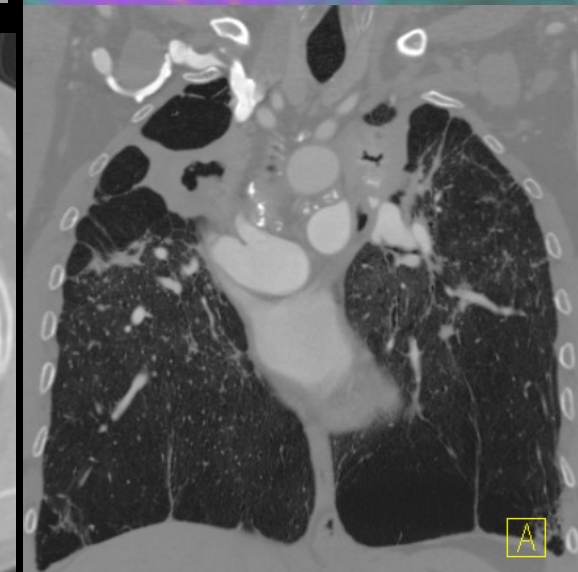
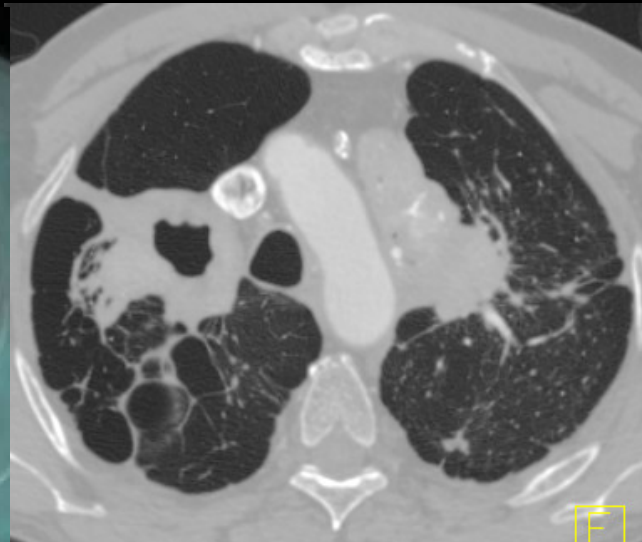
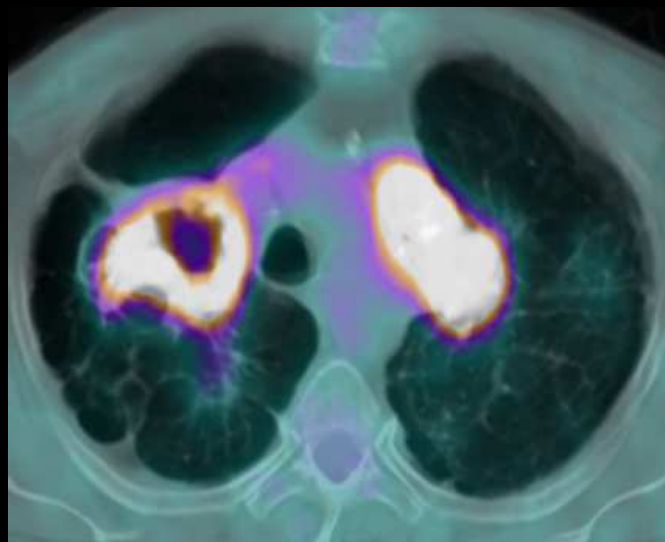
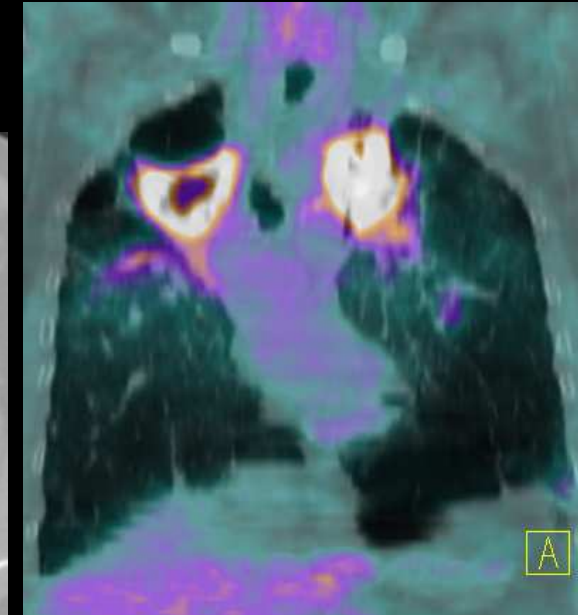
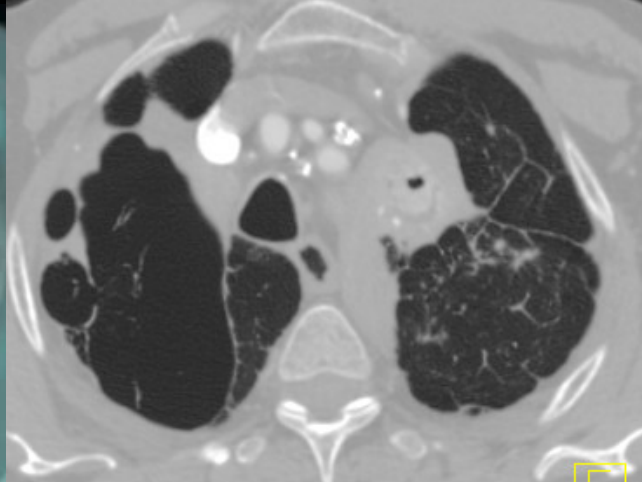
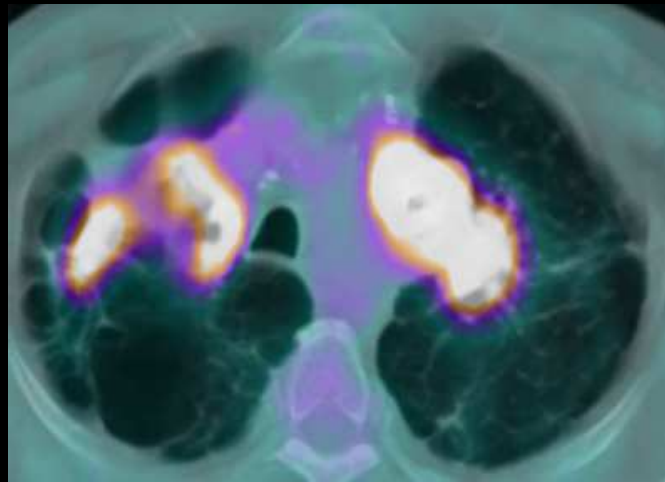
**Pleuro-pneumopathie du lobe inférieur**

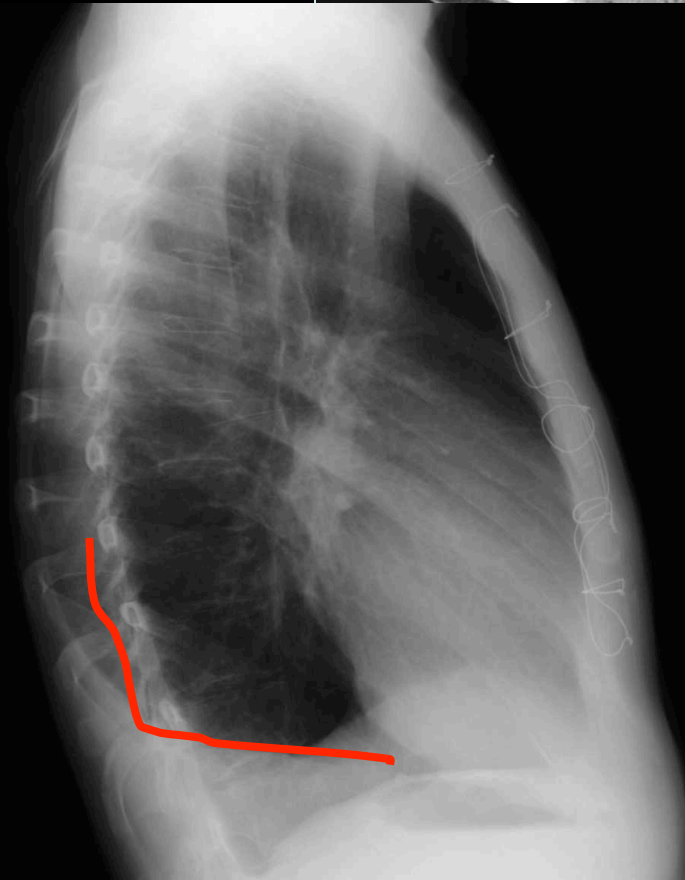
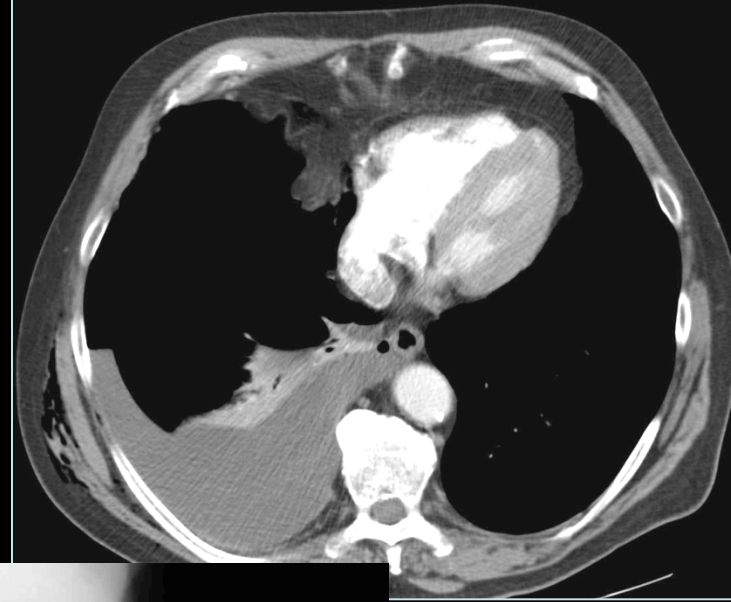
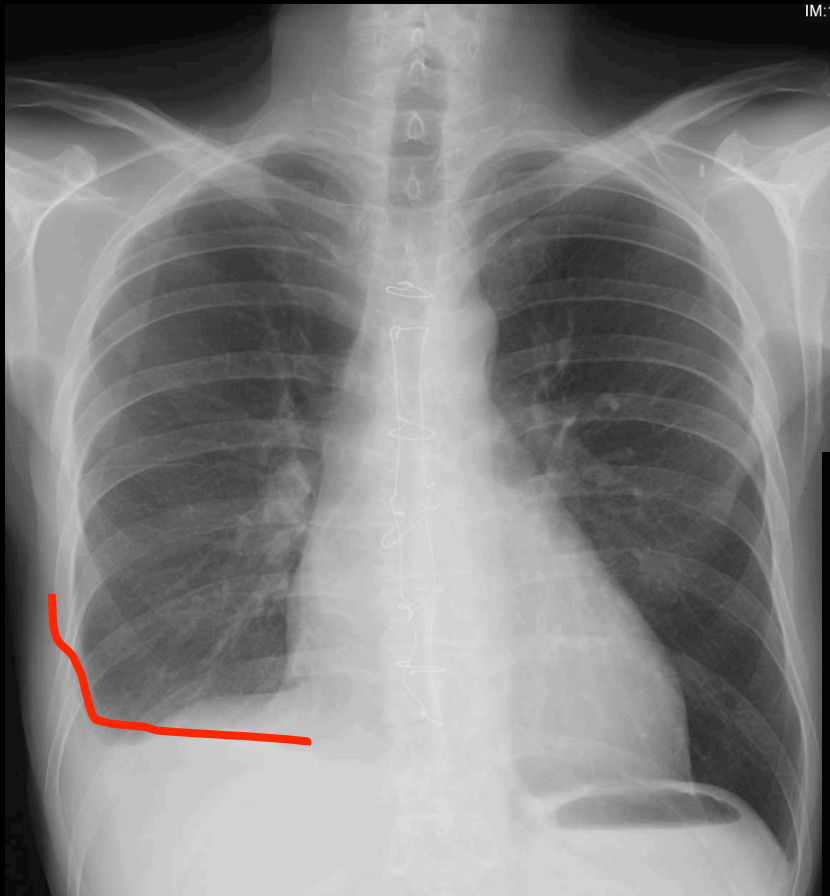


**abcès du poumon**

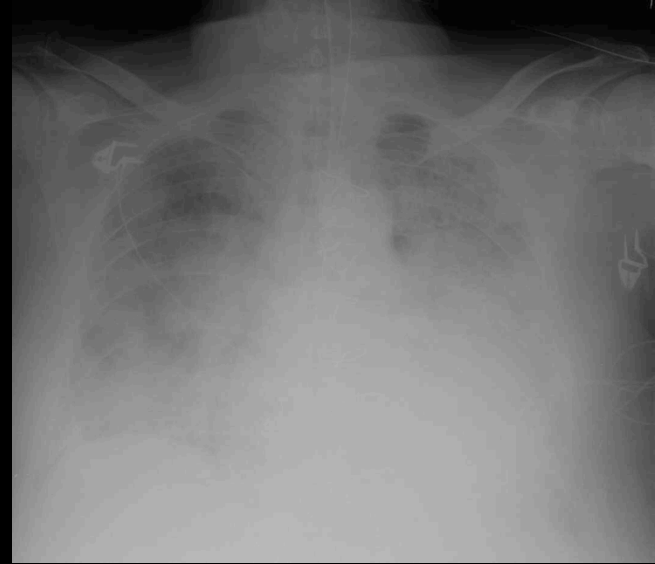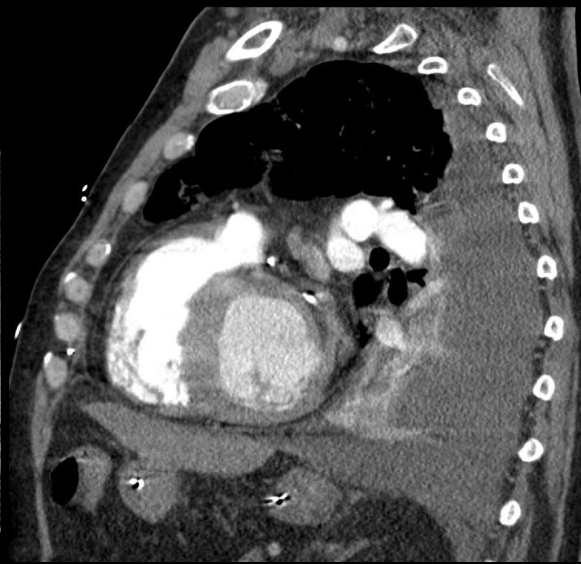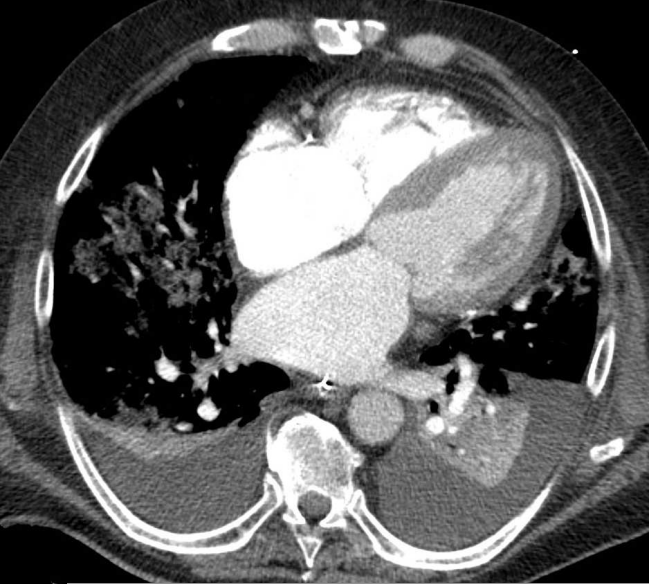


# Aspergillome

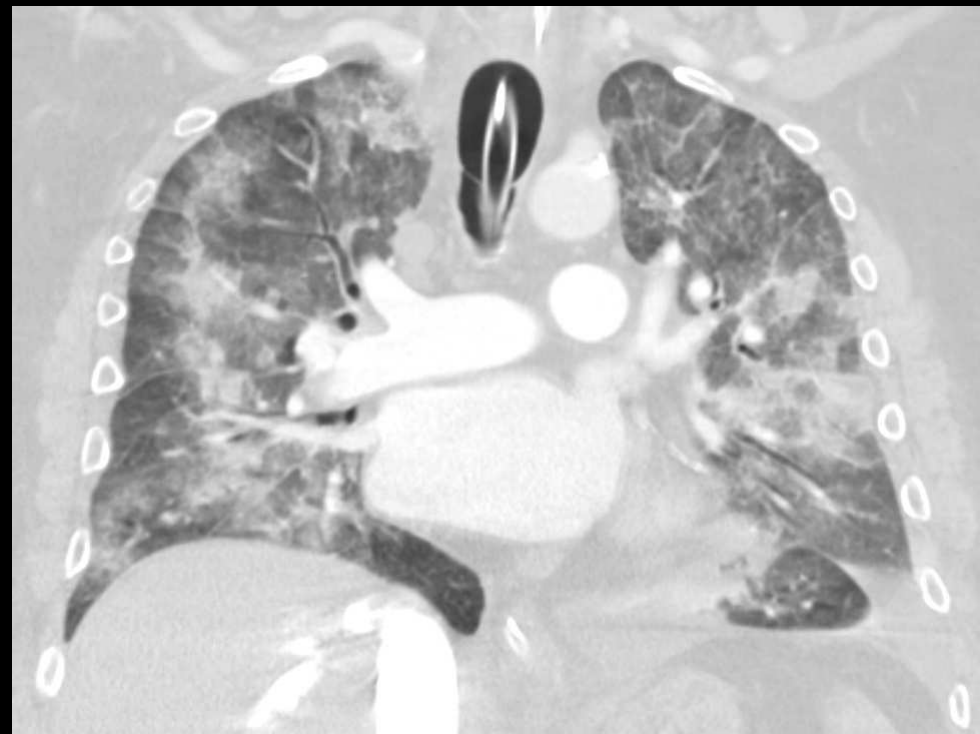
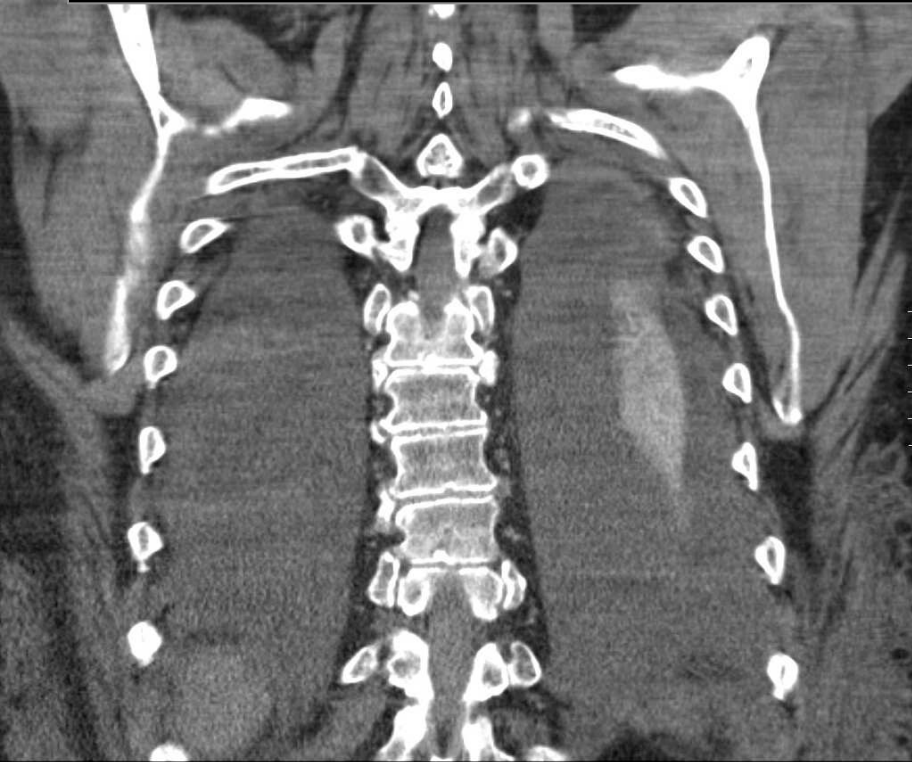


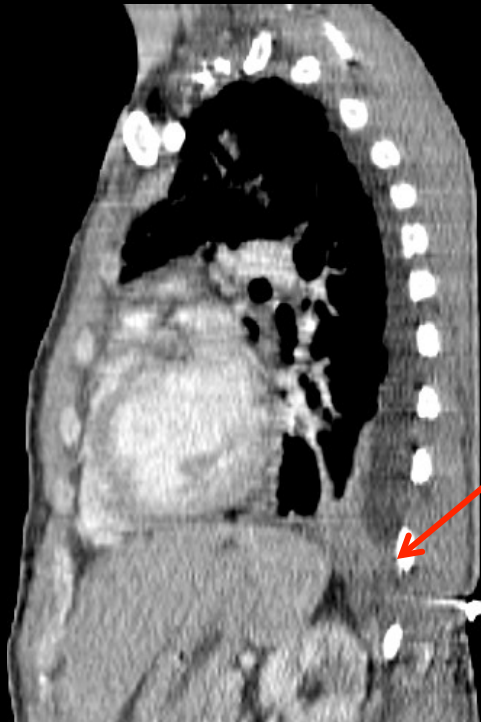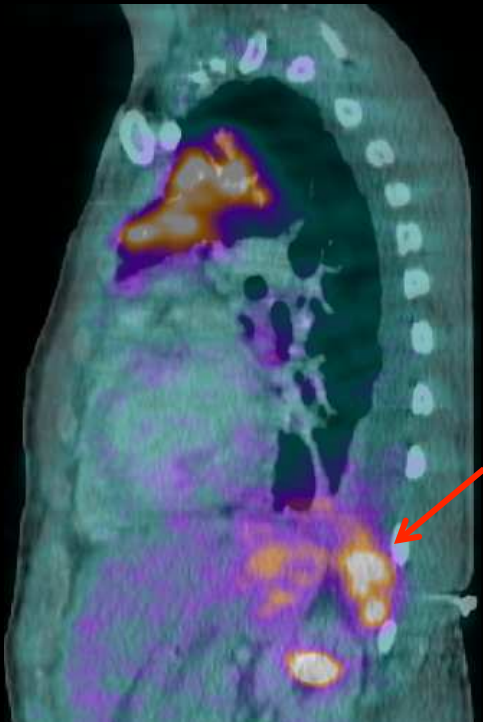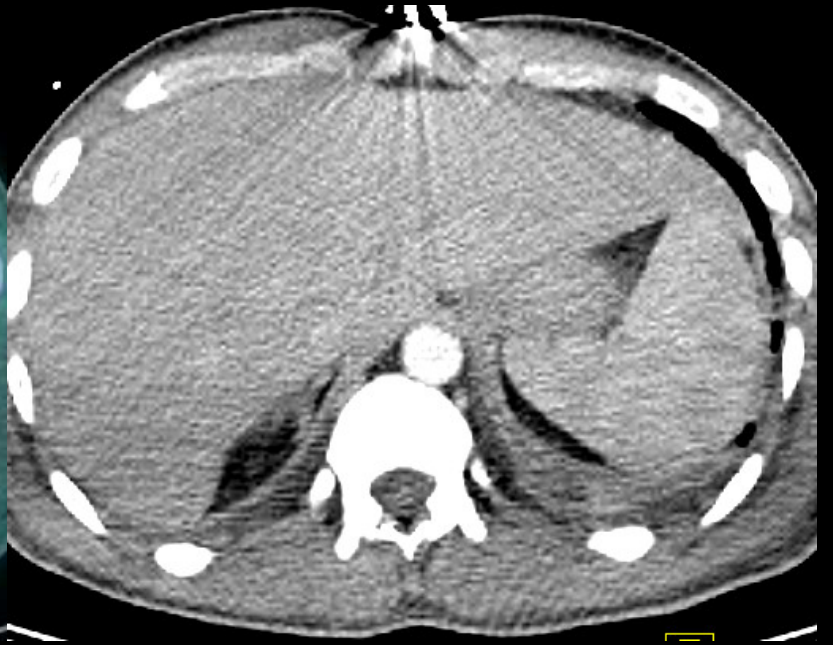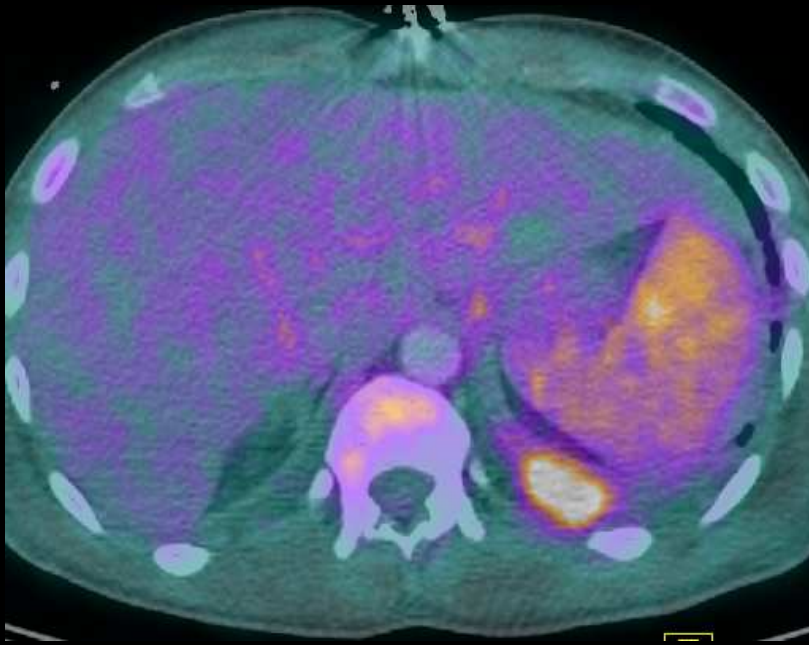


**Épanchement pleural  
droit**

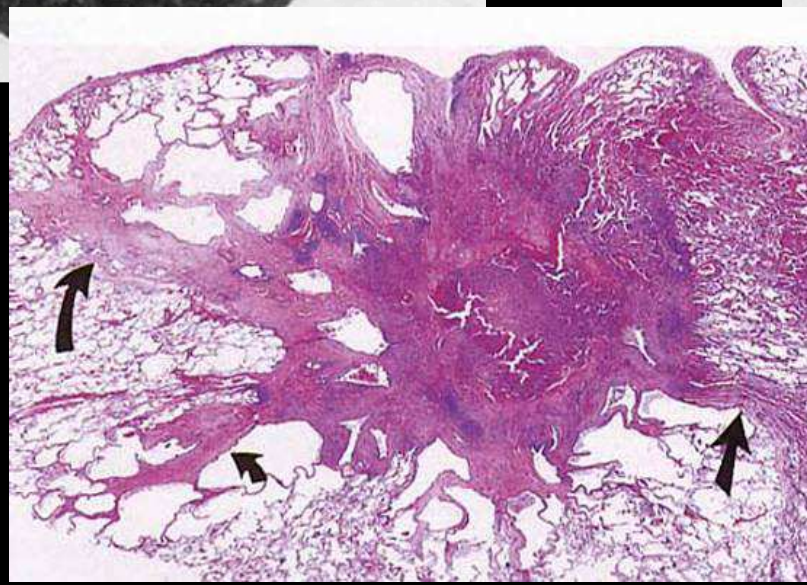
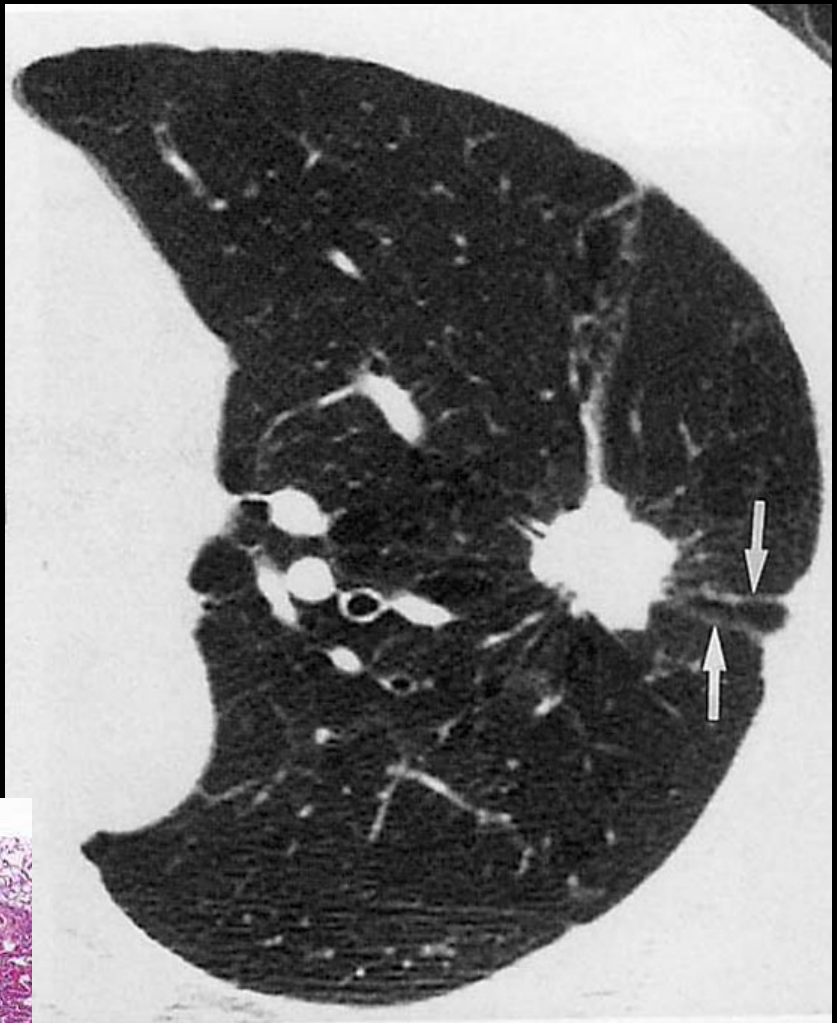
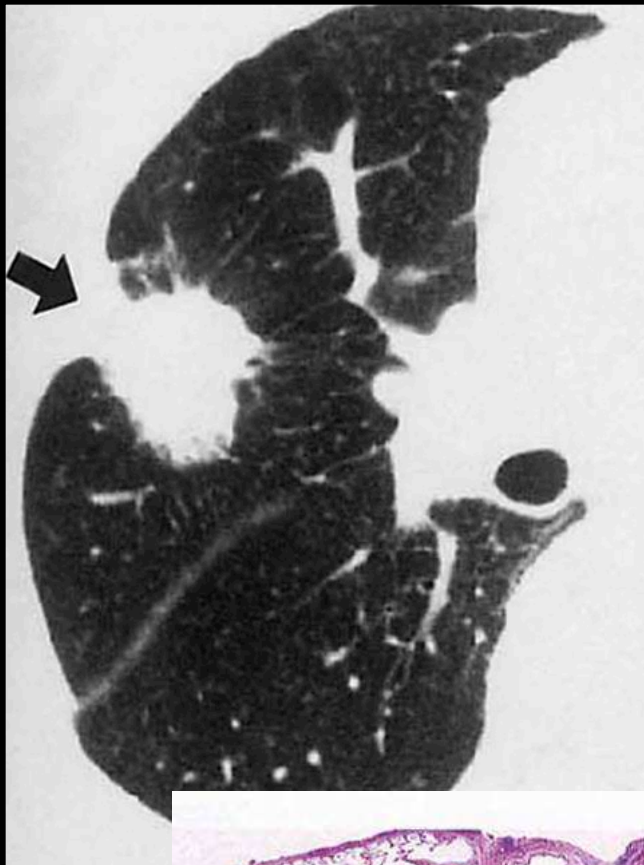
**Pleurésie bilatérale décompensation cardiaque**



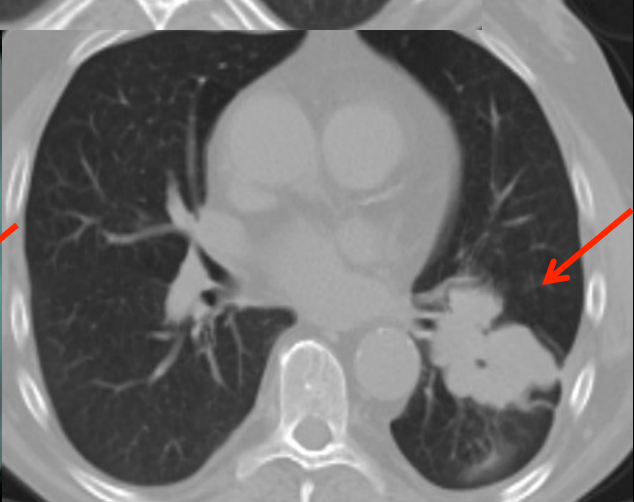
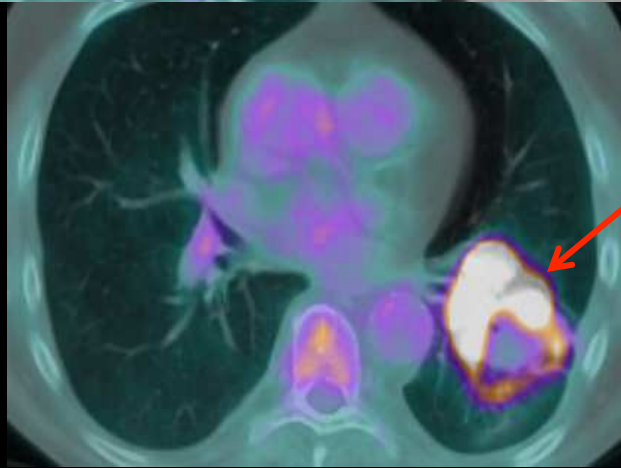
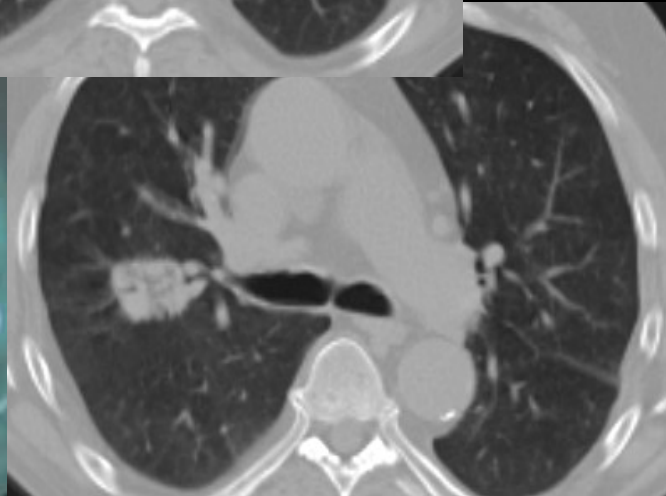
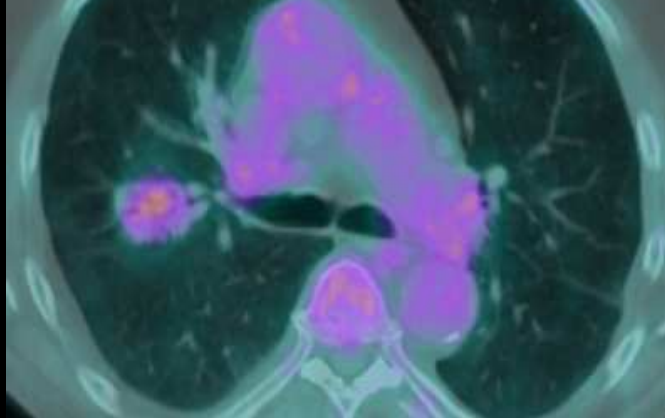
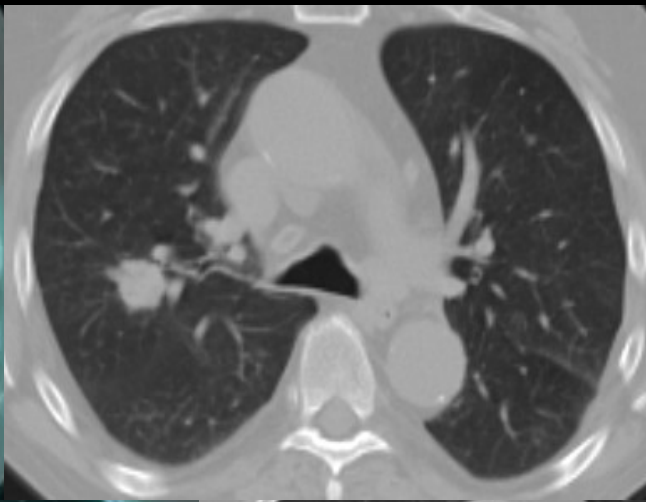
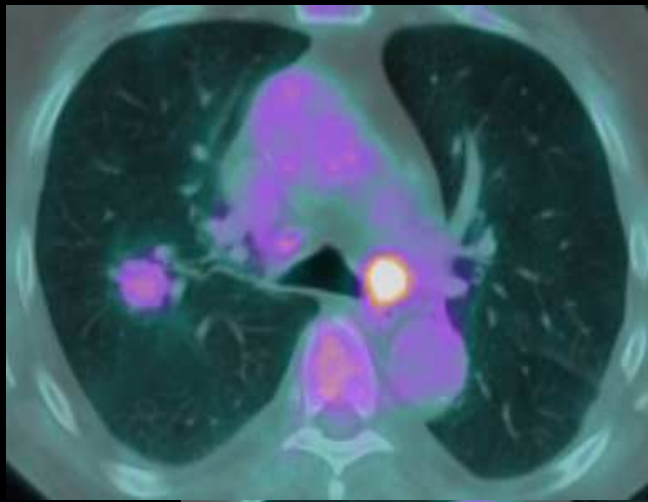
**Pleurésie  
enkystée**



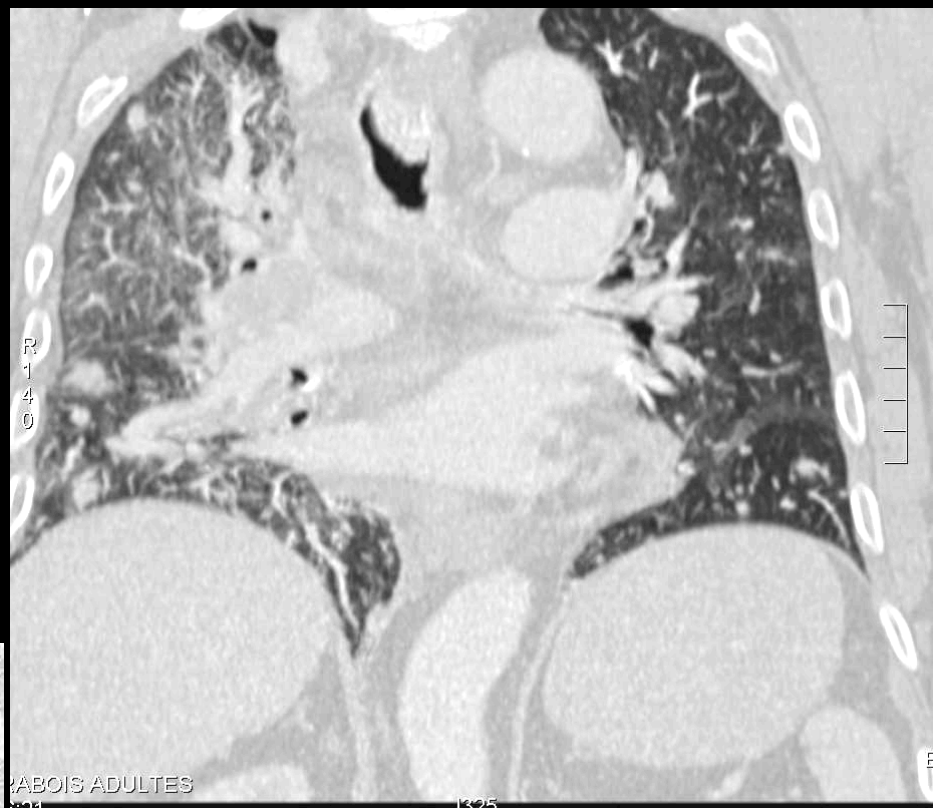
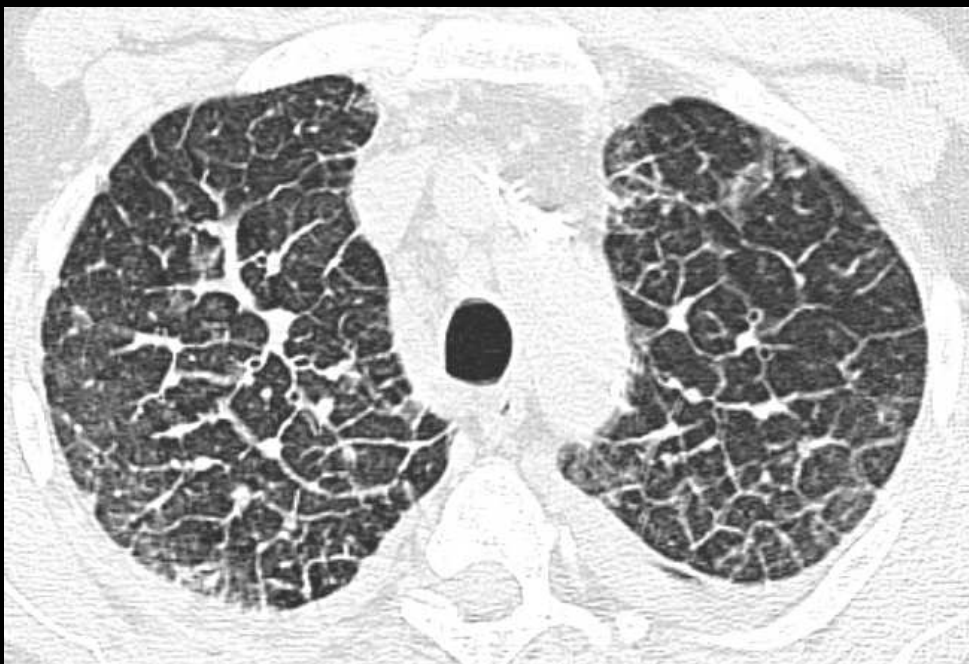
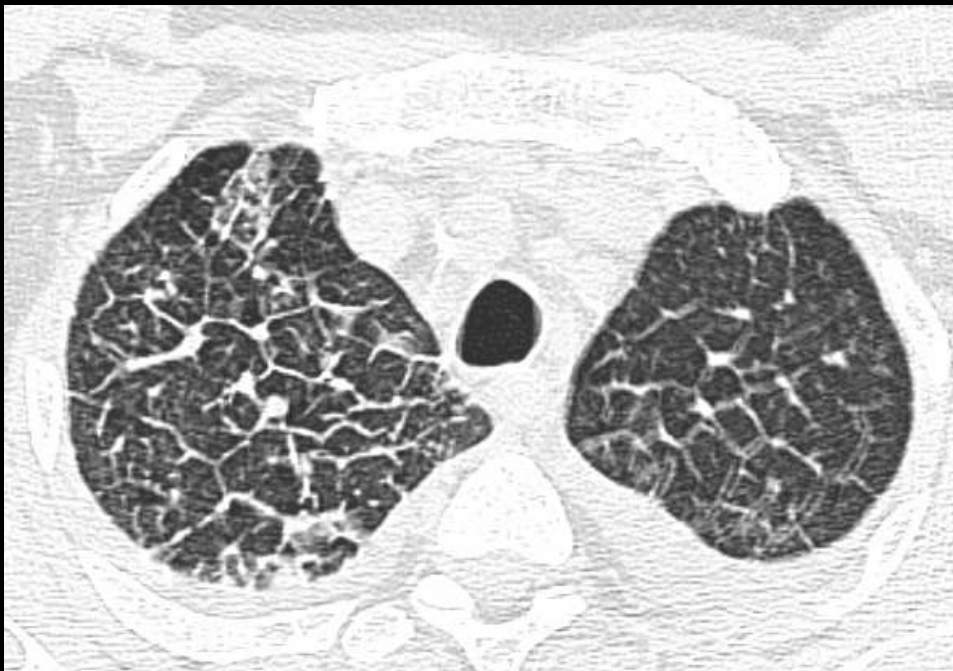
**adénocarcinomes  
infiltration et rétraction de  
la plèvre**

**Carcinome  
épidermoïde  
gauche et lésion  
synchrone à droite**





**Atteinte parenchymateuse interstitielle...**

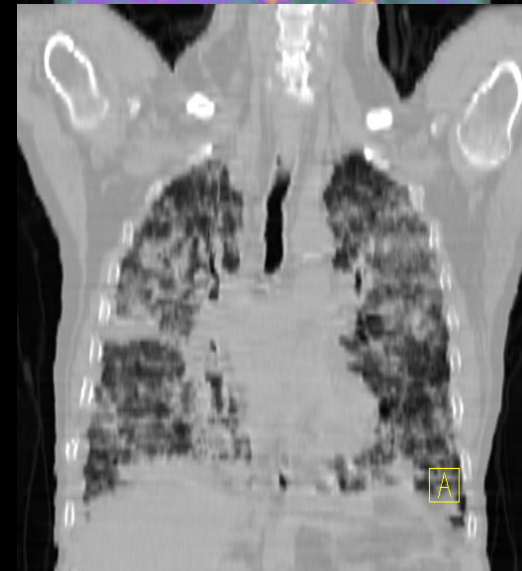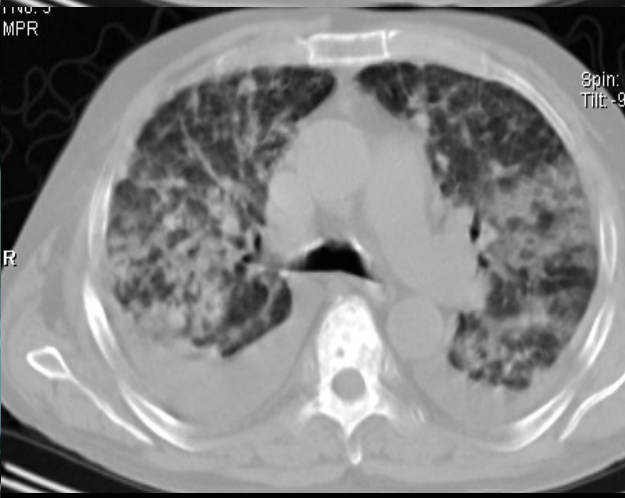
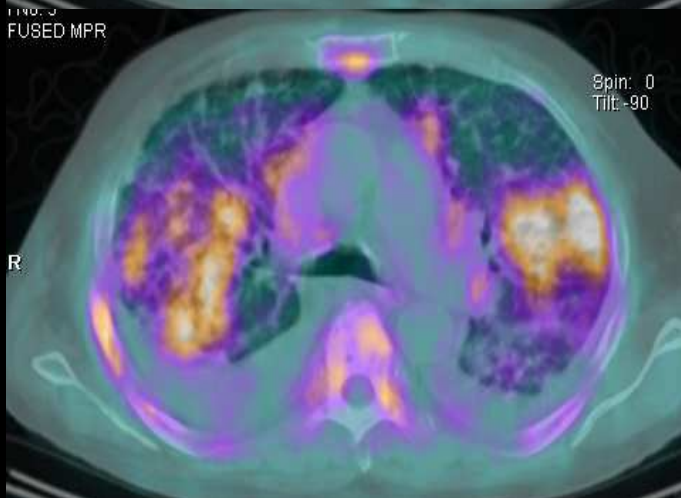
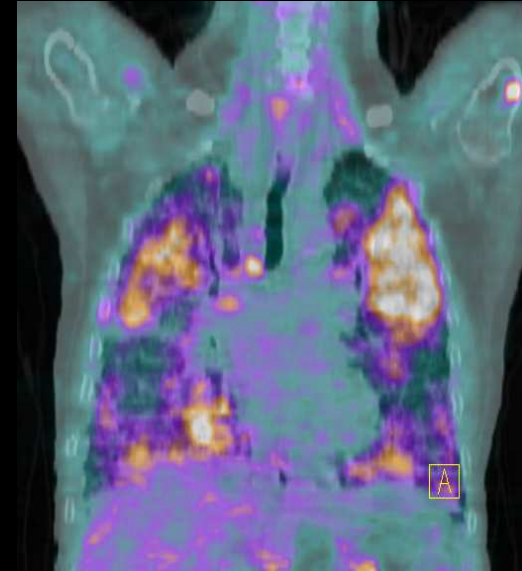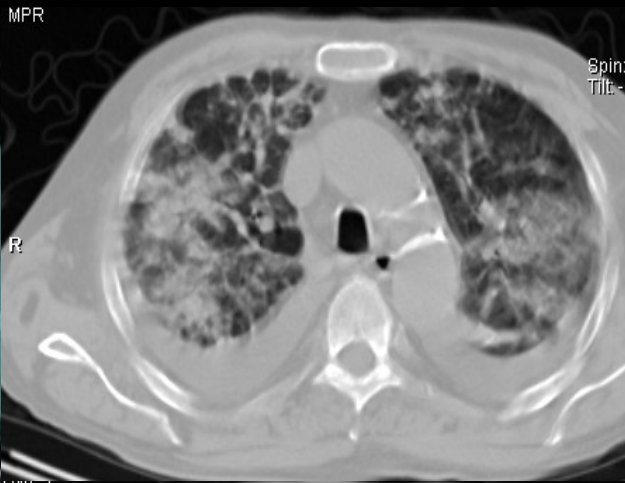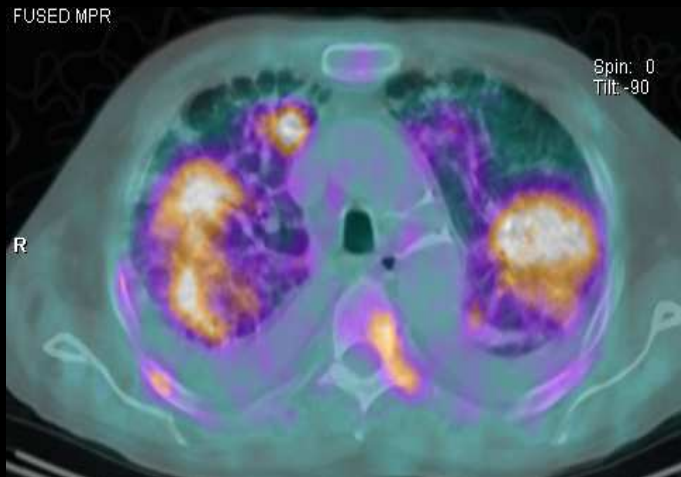


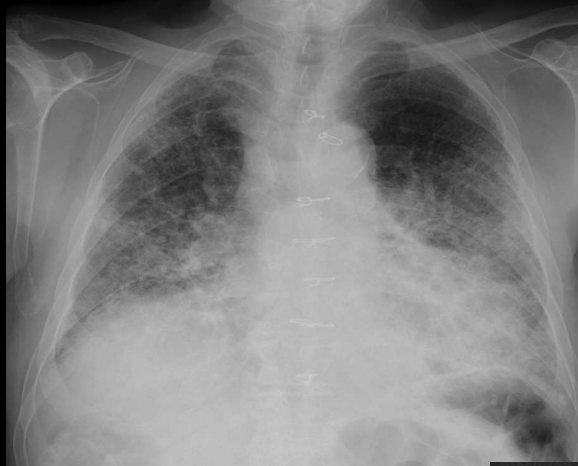LABOIS ADULTES  
3:21

1325

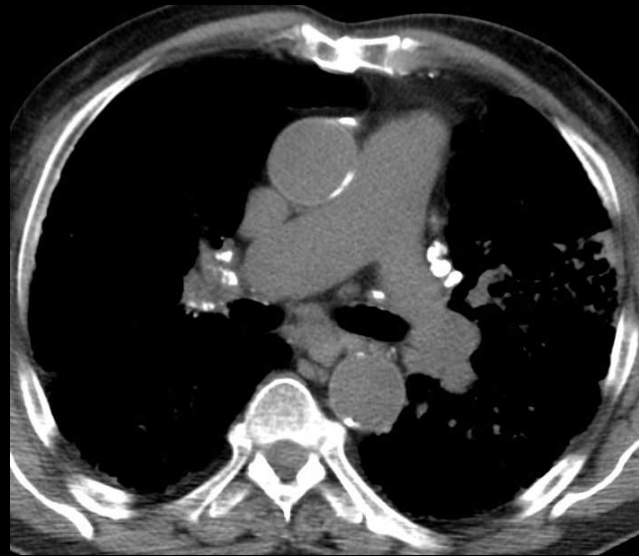
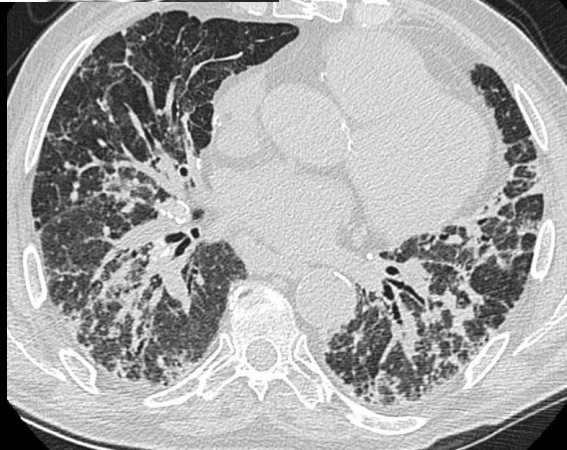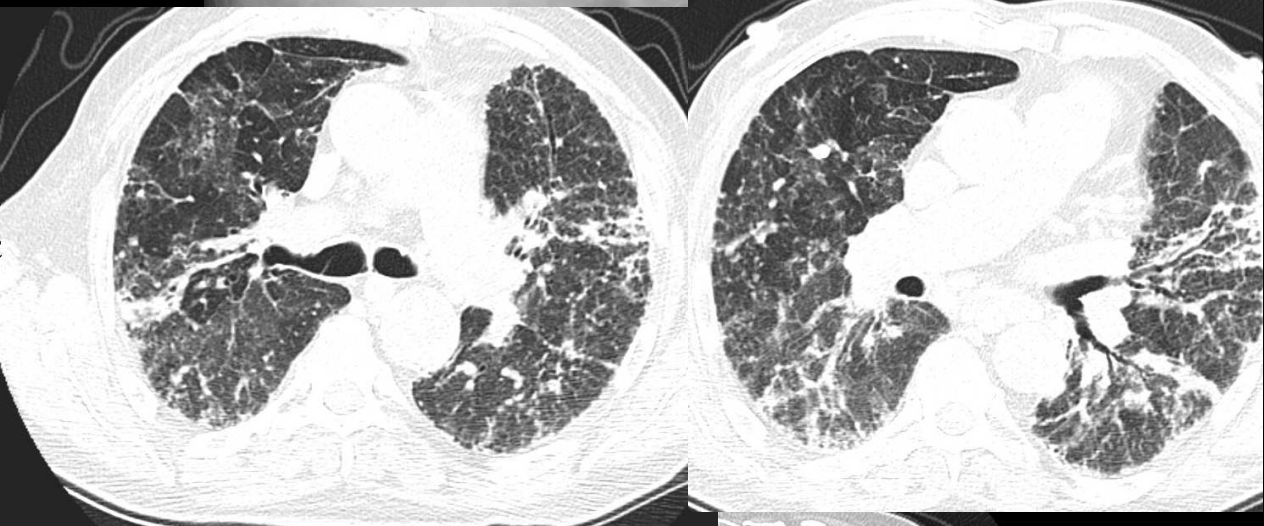
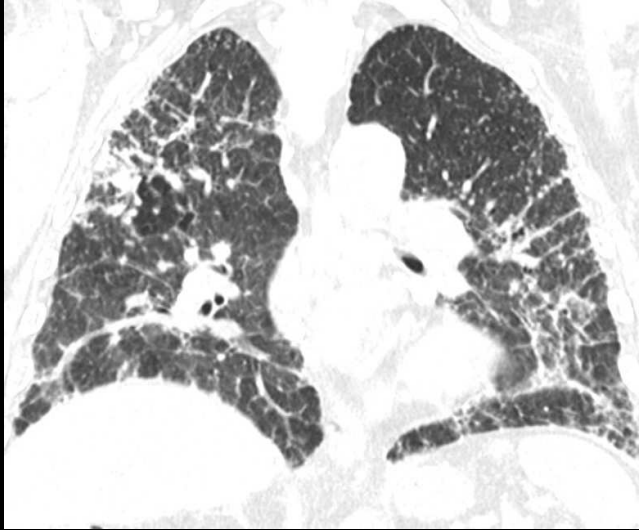
**Épaississements des  
septas et  
micronodules :  
lymphangite**

# Lymphangite

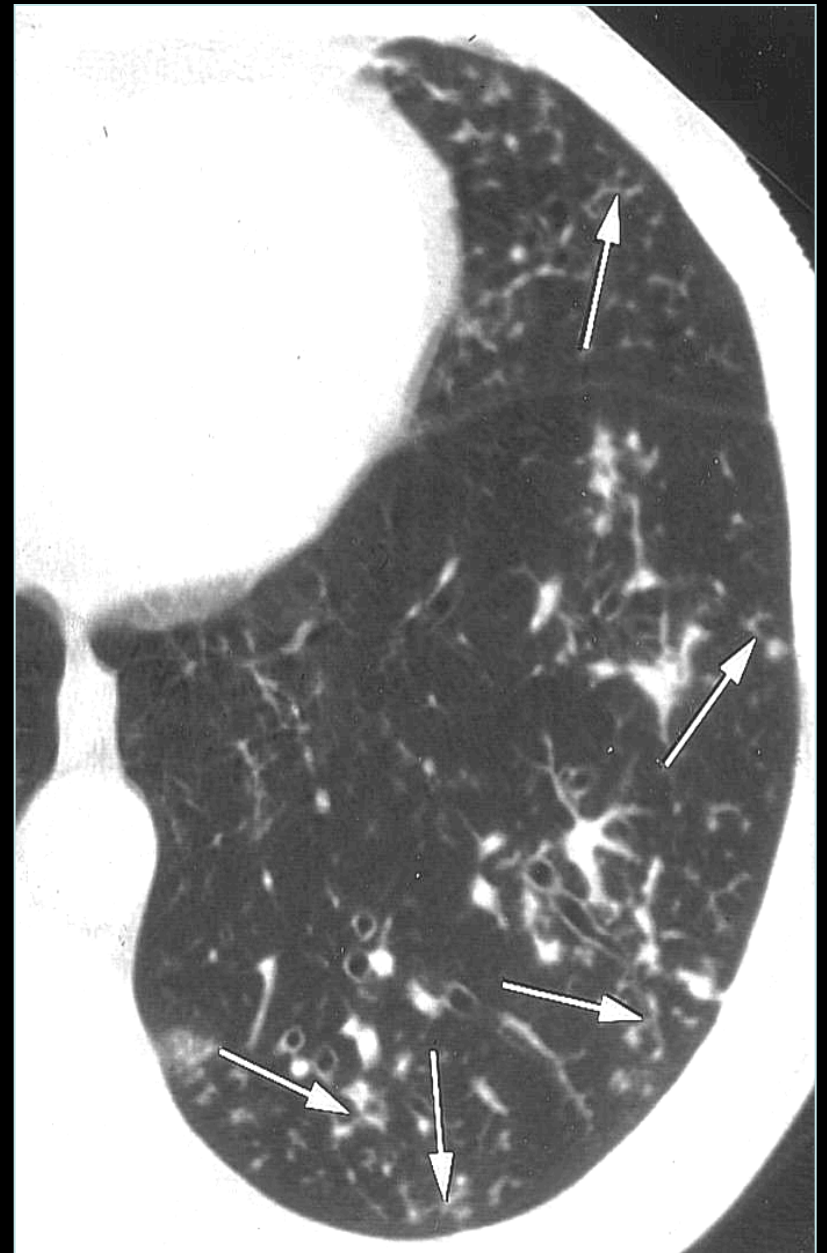
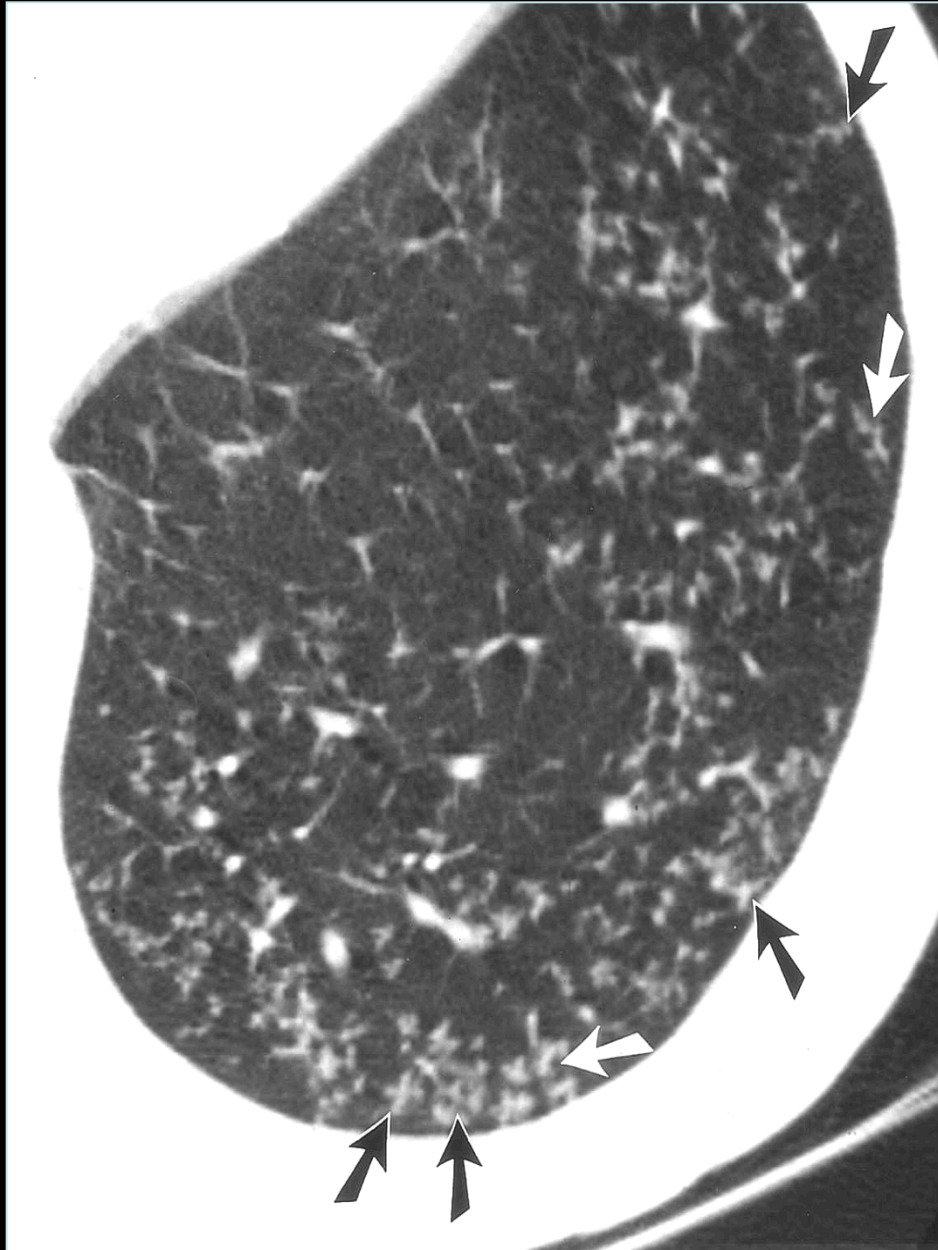




**silicose**

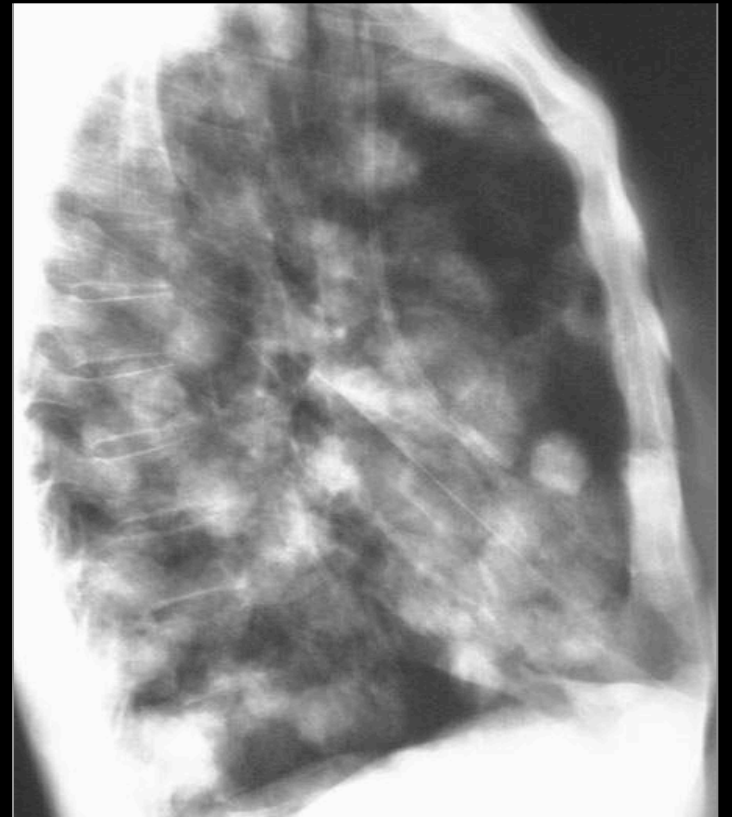
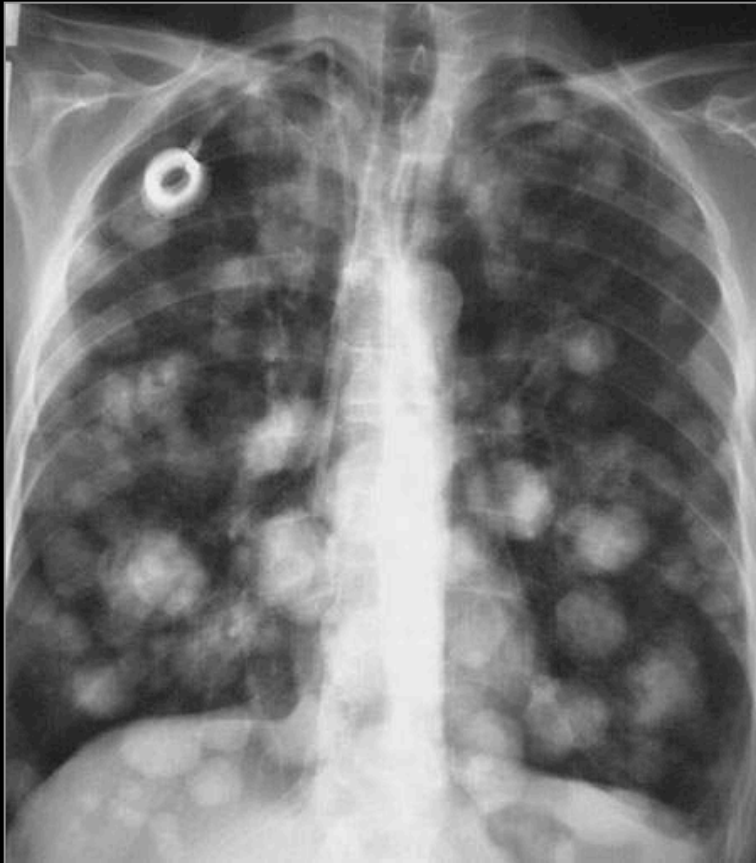
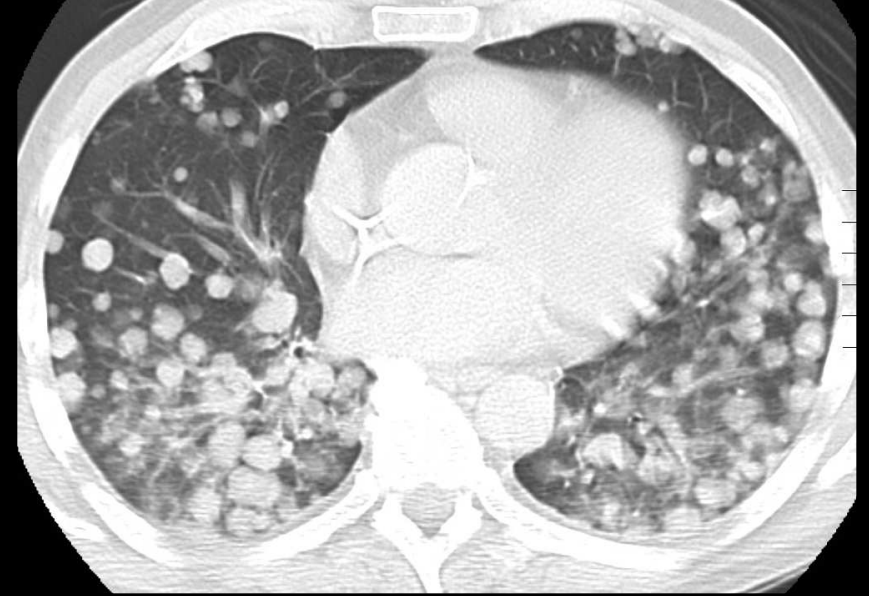


# Bronchiolite bactérienne

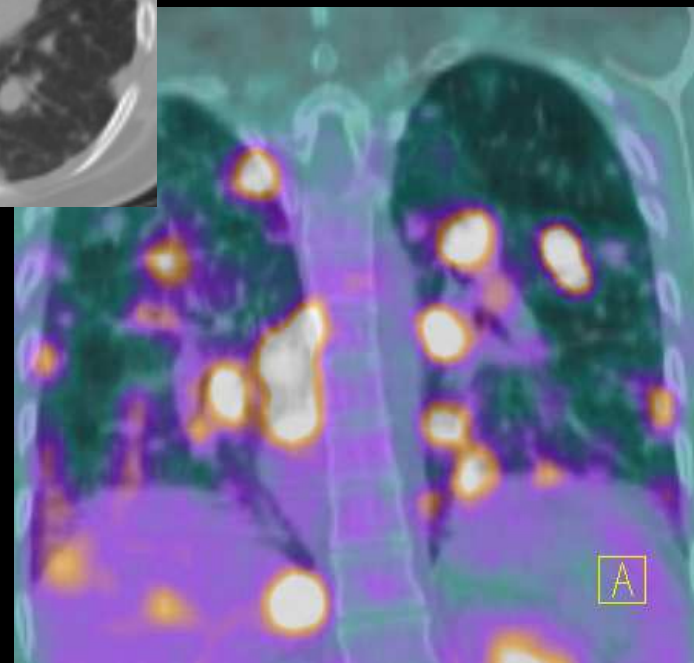
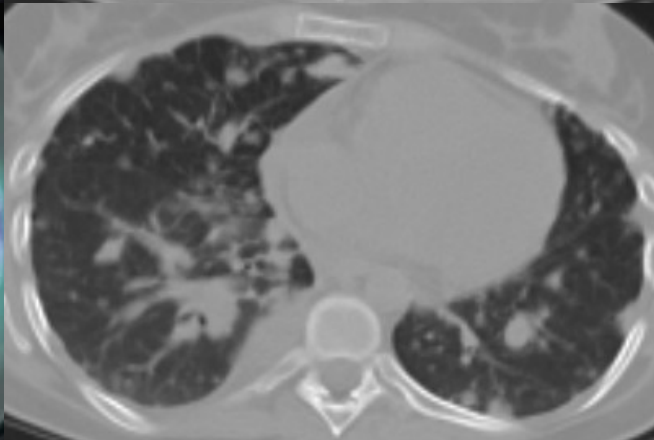
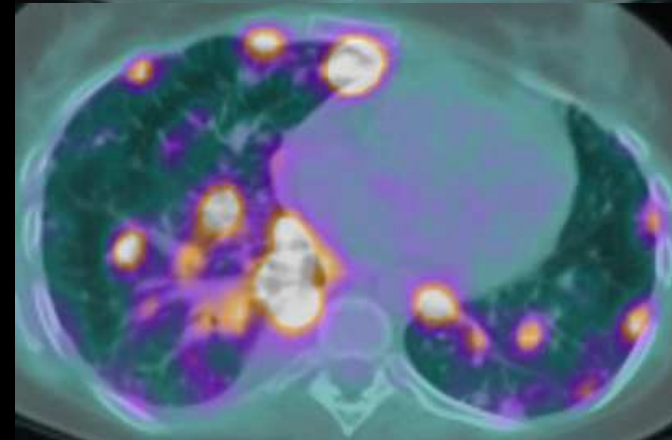
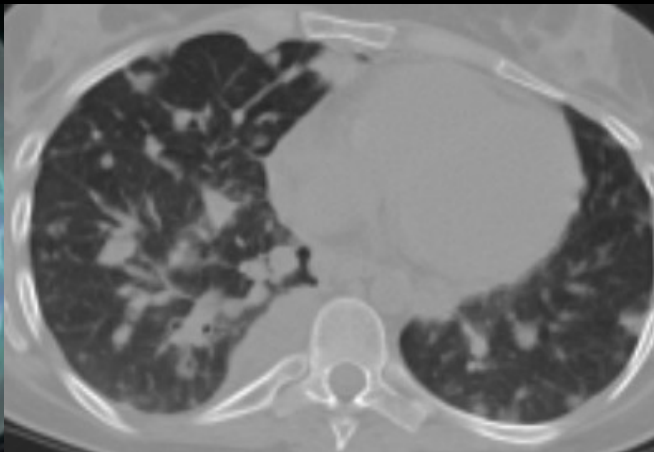
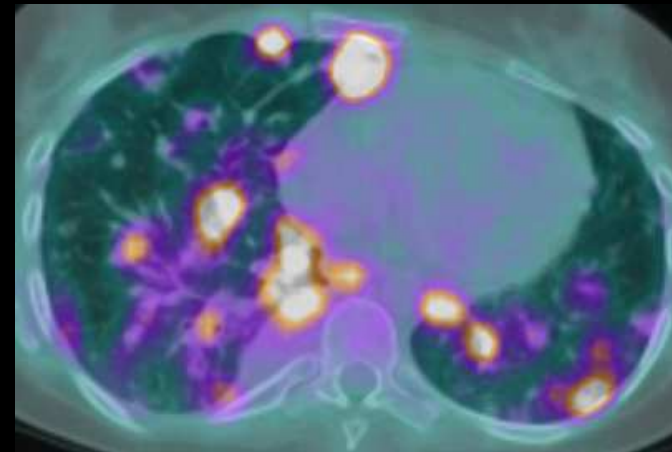


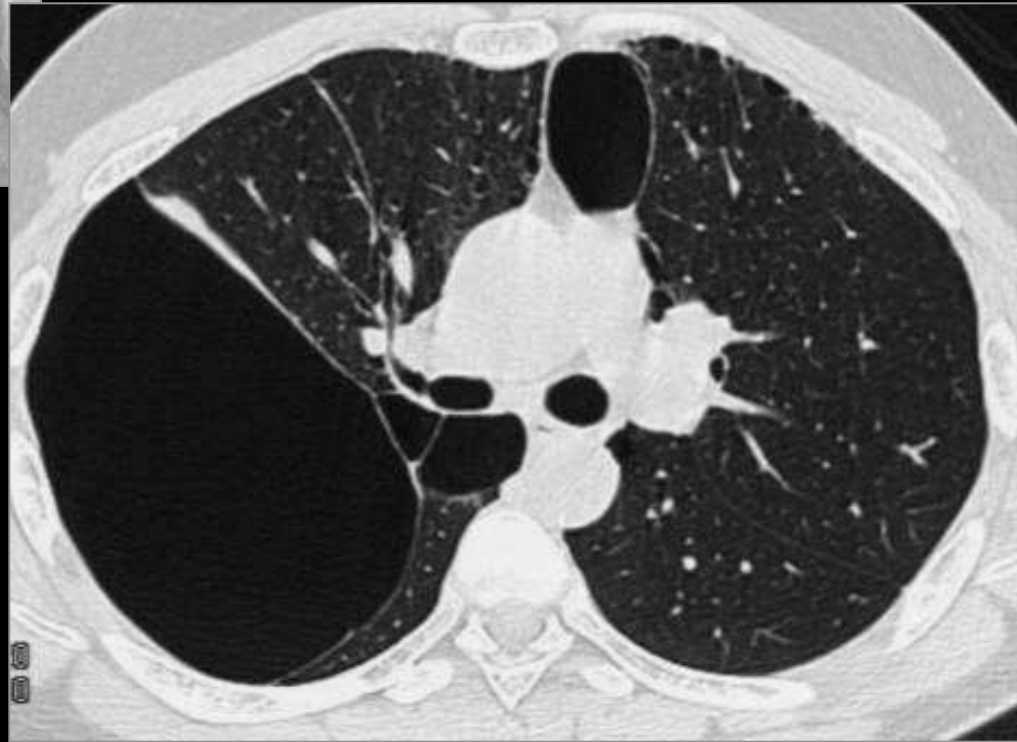
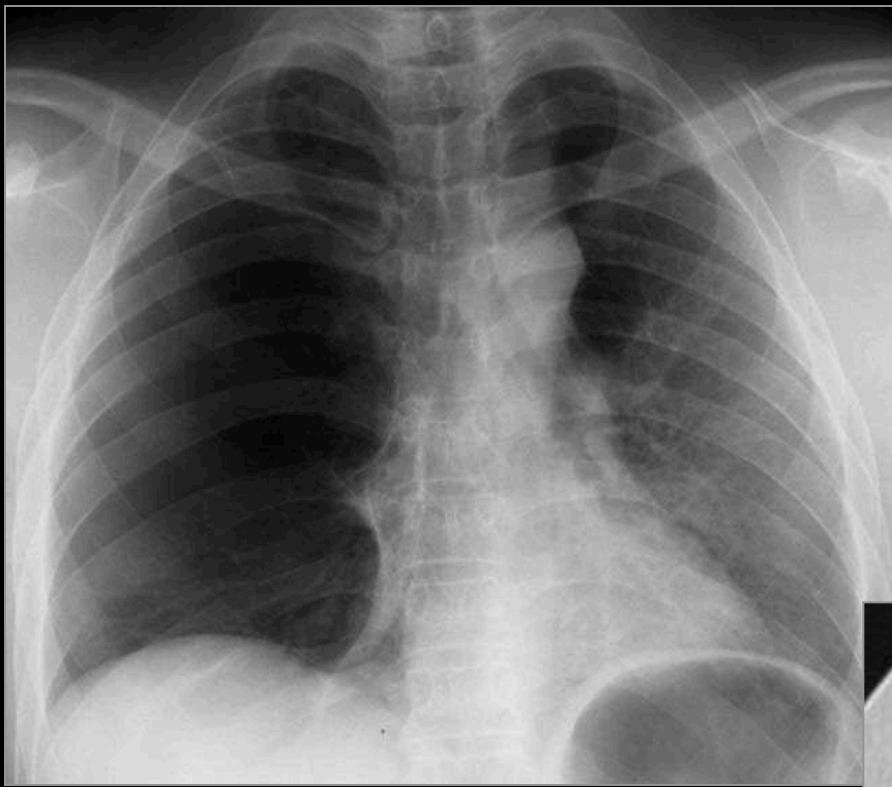
**Opacités macro nodulaires**

**Lâcher de ballon**  
**Métastases pulmonaires**  
**Distribution hémotogènes**



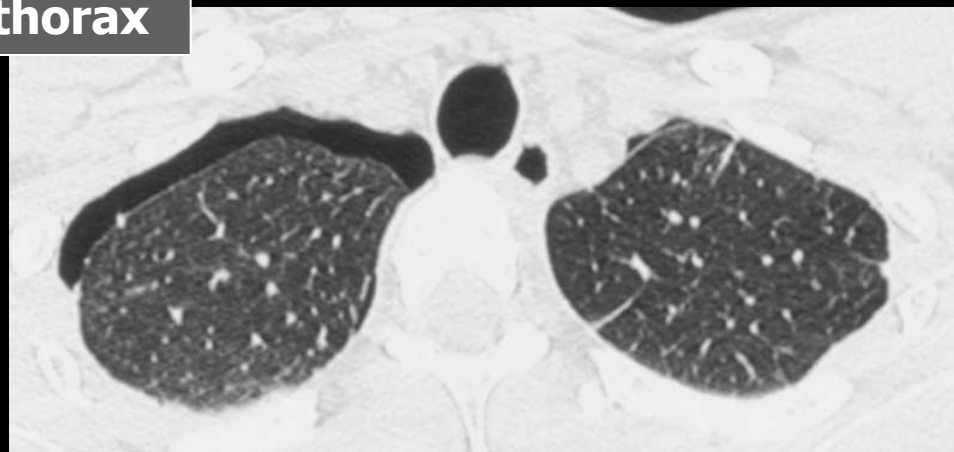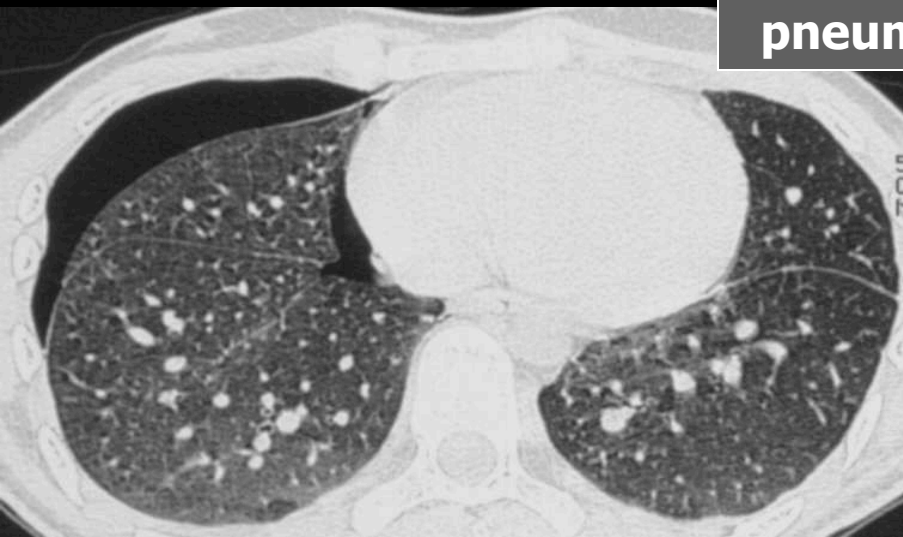
# Lâcher de ballons



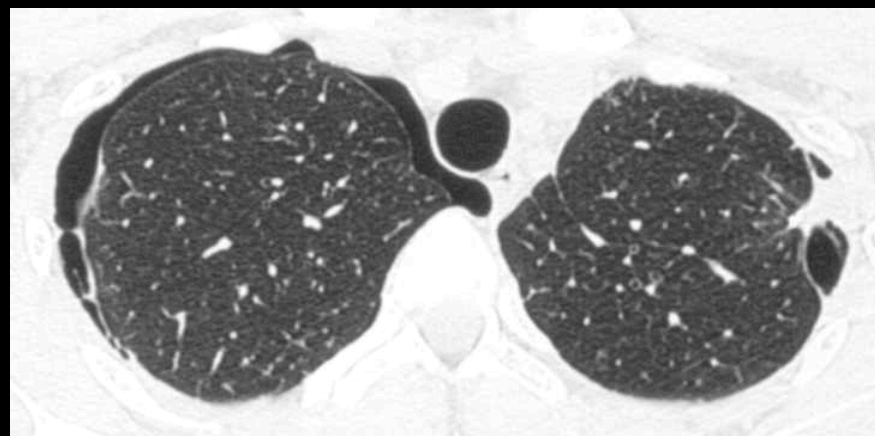
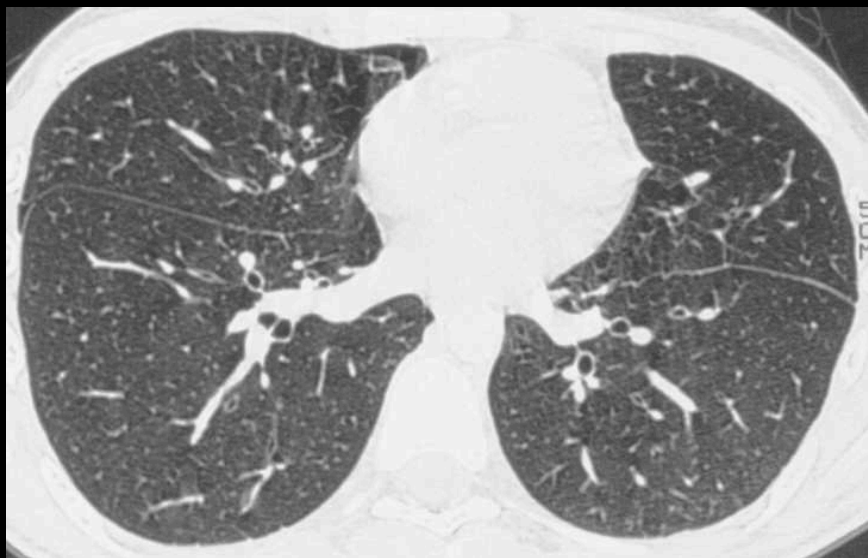


**Hyperclartés**  
**Bulles**  
**d' emphysème**

**pneumothorax**



**coupes en expiration**



**coupes en inspiration**

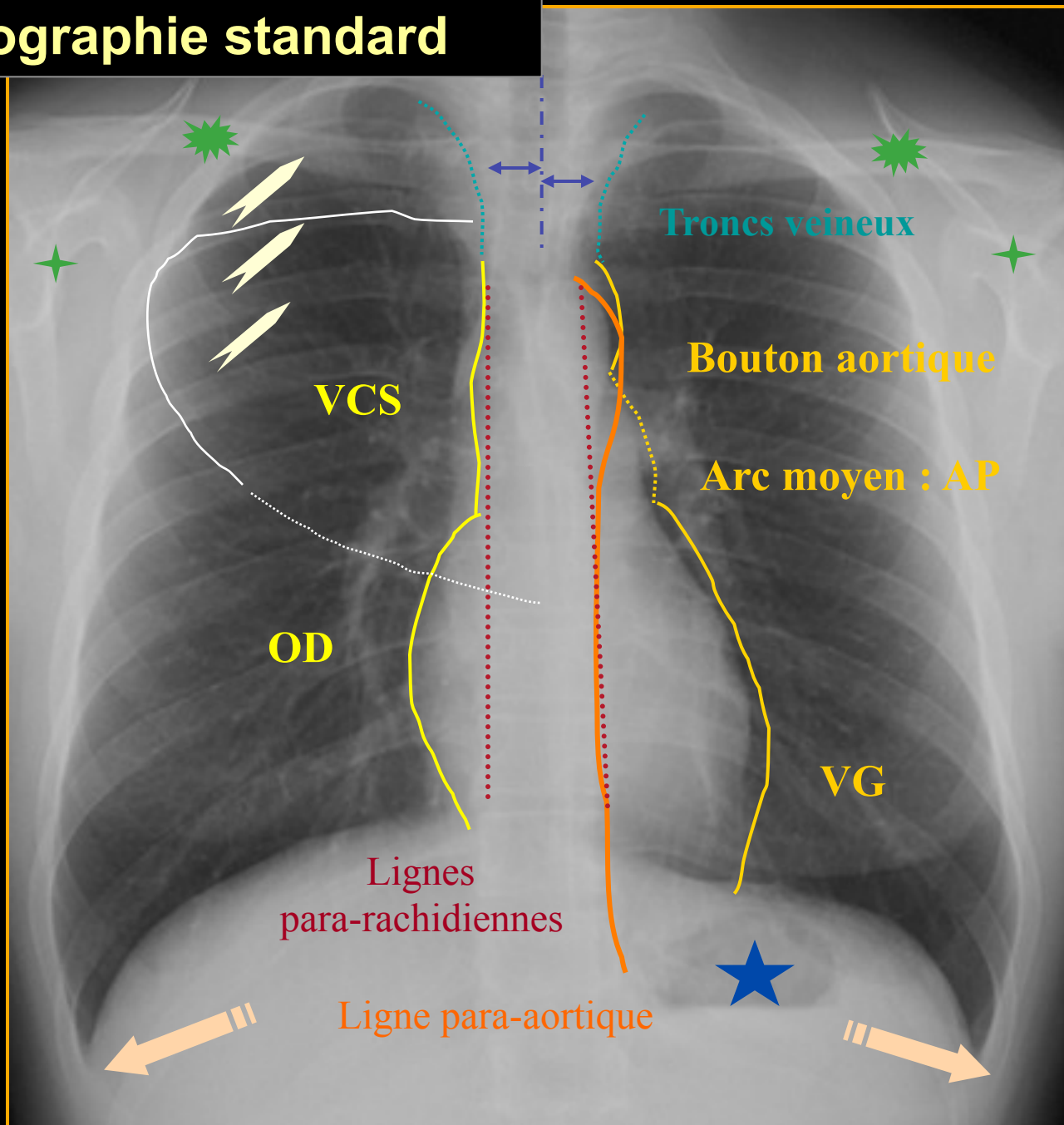


## 2/ RADIOANATOMIE DU MEDIASTIN

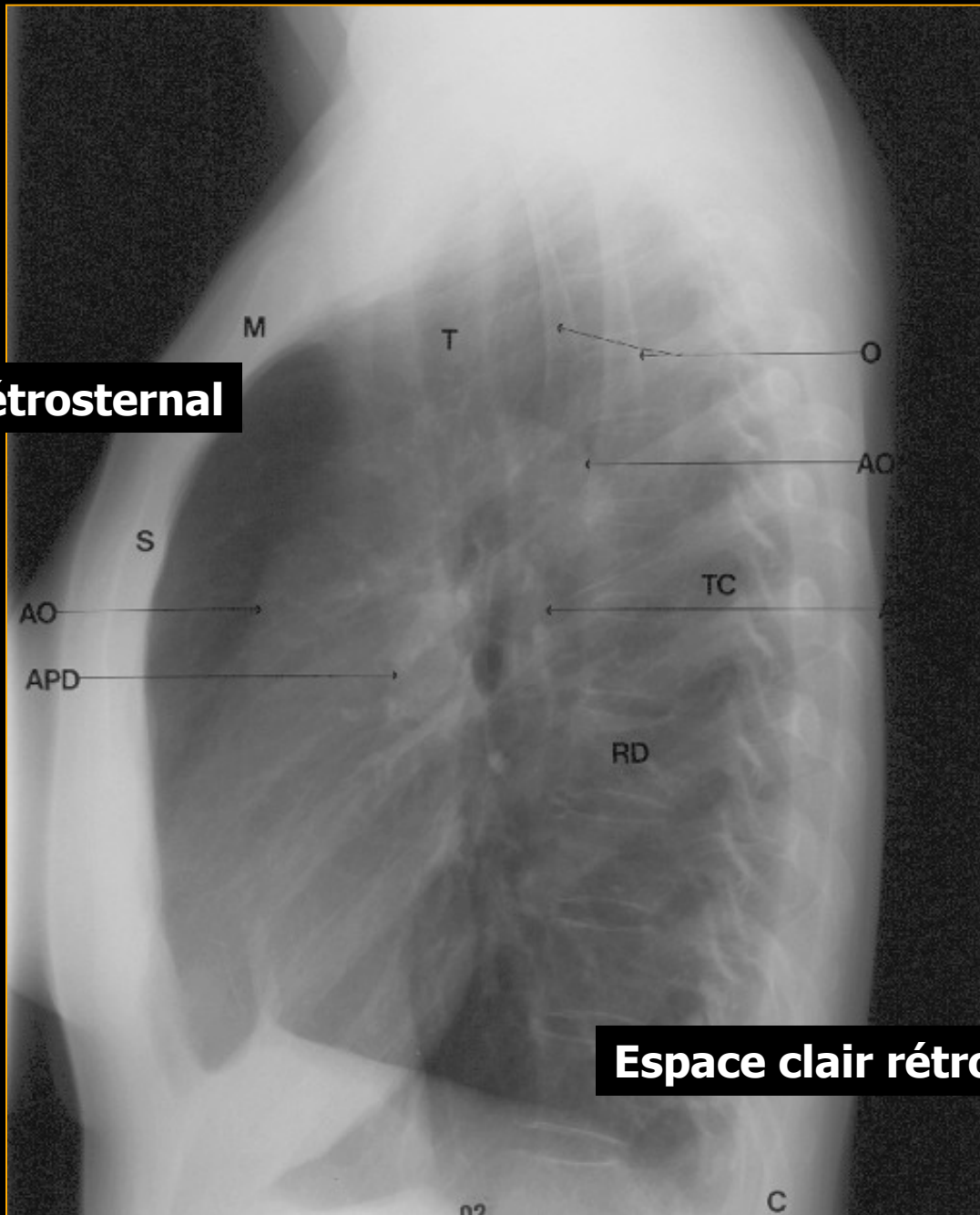
- **GENERALITES**
- **VAISSEAUX**
- **CŒUR**
- **ŒSOPHAGE**
- **CHAINES GANGLIONNAIRES**

# Radiographie standard

DE FACE



**Espace clair rétrosternal**



**Espace clair rétrocardiaque**

# Les 10 lignes du médiastin

# RadioGraphics

The journal of continuing medical education in radiology

[HOME](#) | [CURRENT ISSUE](#) | [PAST ISSUES](#) | [COLLECTIONS](#) | [COVER GALLERY](#) | [RADIOLOGY](#)

## Lines and Stripes: Where Did They Go? —From Conventional Radiography to CT

Jerry M. Gibbs, MD, Chitra A. Chandrasekhar, MBBS,  
Emma C. Ferguson, MD and Sandra A. A. Oldham, MD

+ Author Affiliations

Address correspondence to

J.M.G. (e-mail: [jerry.m.gibbs@uth.tmc.edu](mailto:jerry.m.gibbs@uth.tmc.edu)).

ABSTRACT

10

[« Previous | Next Article »](#)  
[Table of Contents](#)

### This Article

doi:  
10.1148/rg.271065073  
January 2007 RadioGraphics,  
27, 33-48.

Abstract **Free**

Figures Only

» **Full Text**

**Full Text (PDF)**

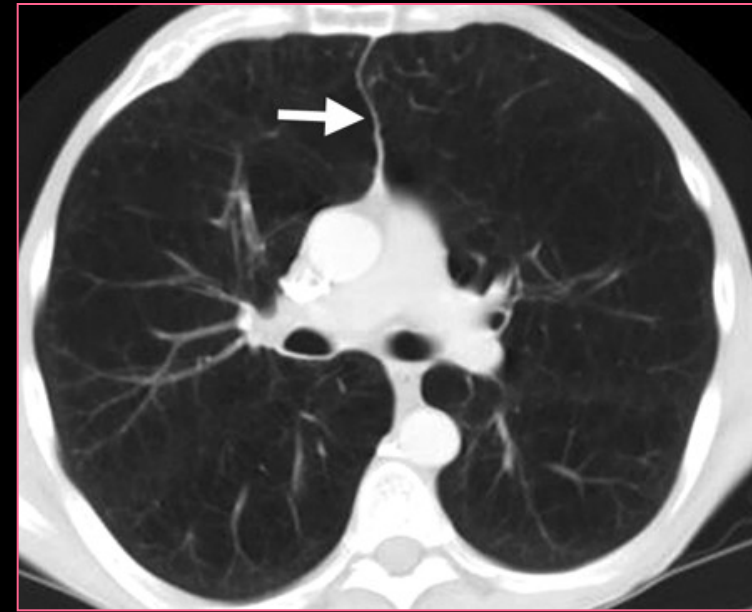
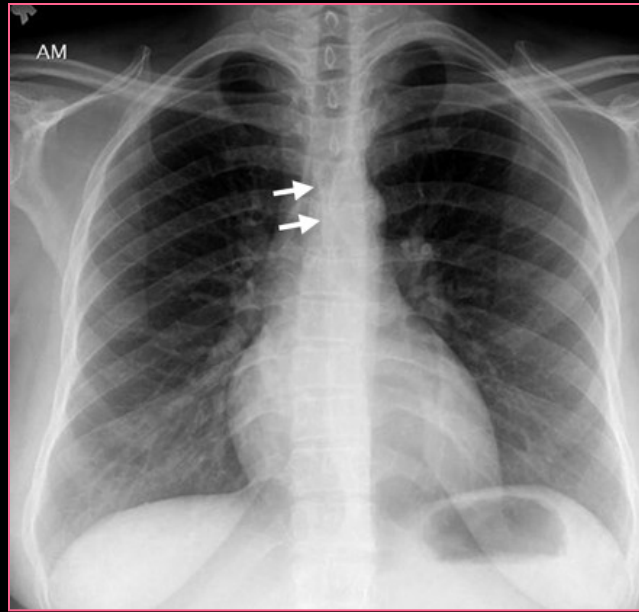
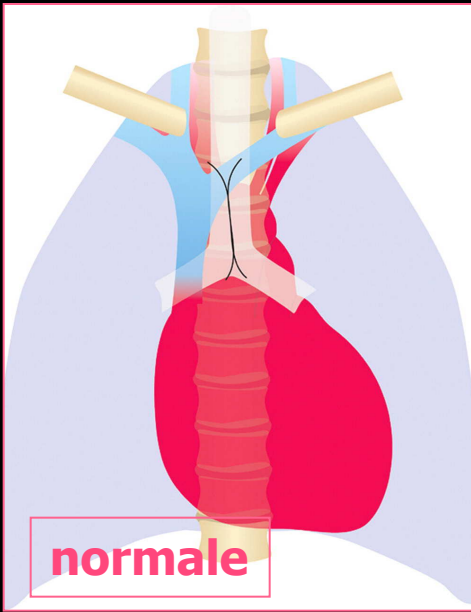
CME Test

- **Classifications**

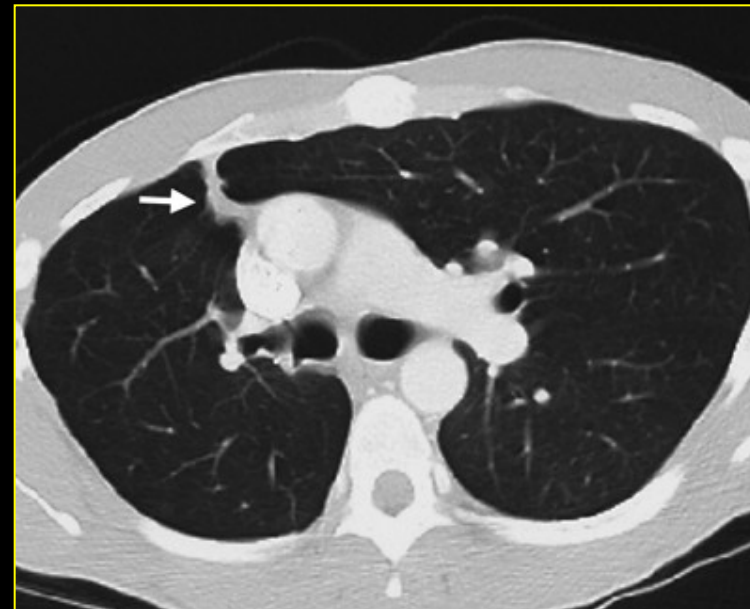
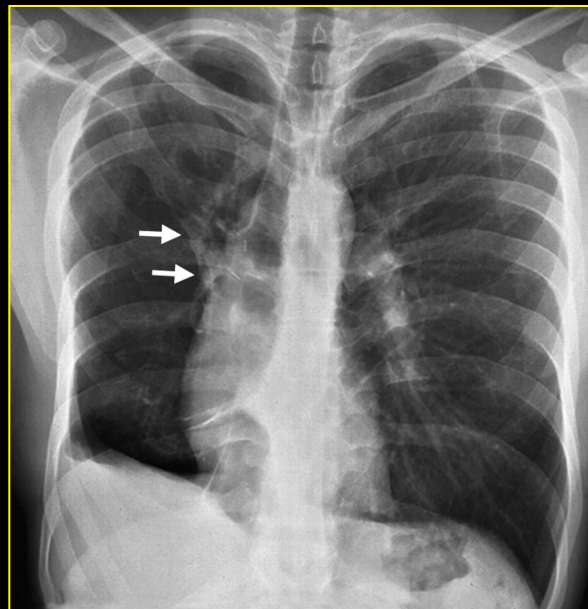
Series:

Continuing Medical  
Education

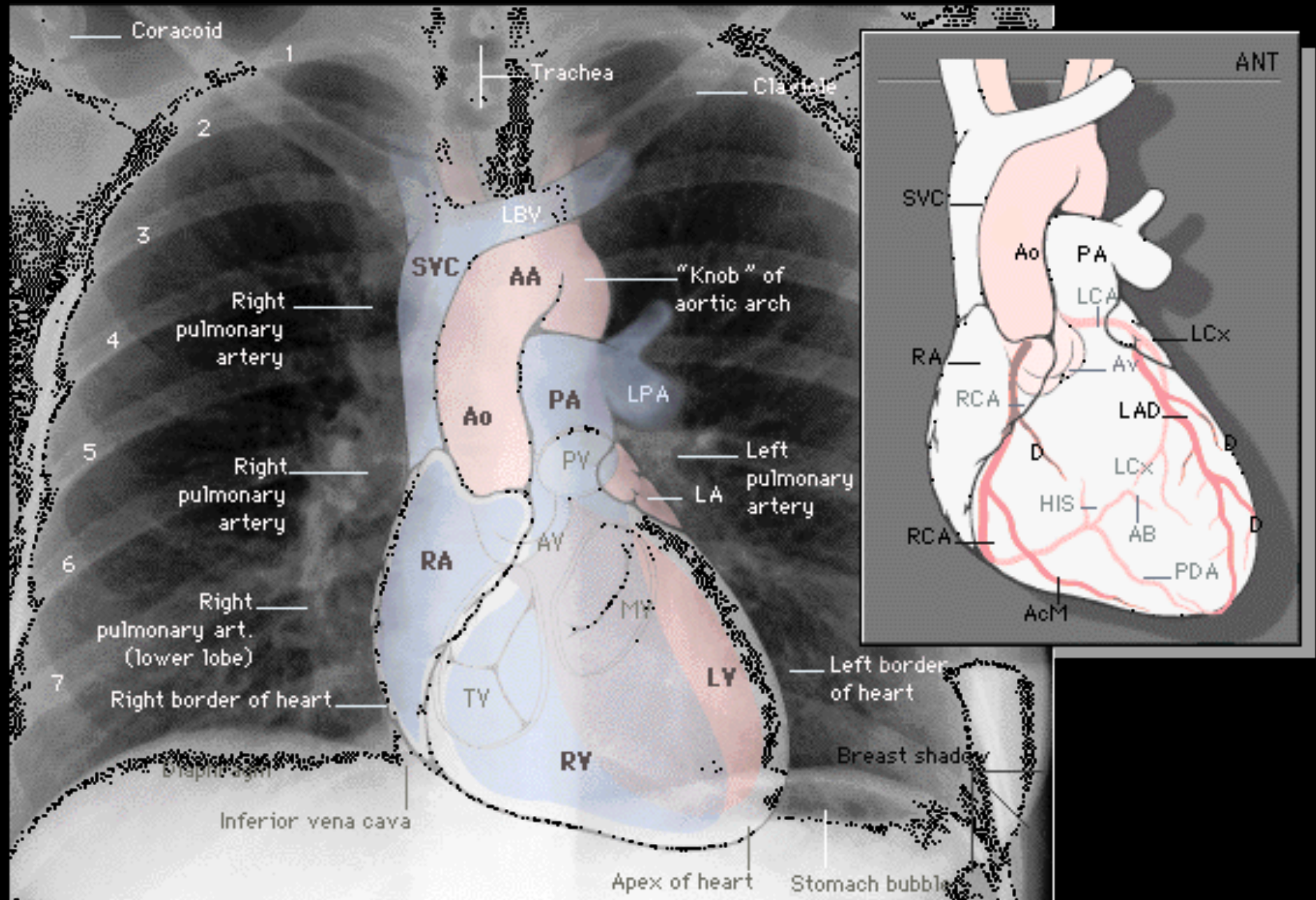
# Ligne de jonction médiastinale antérieure



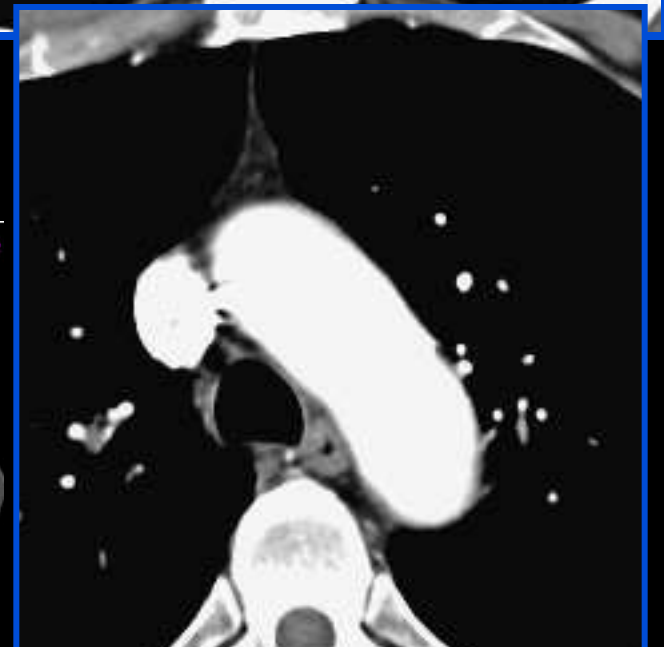
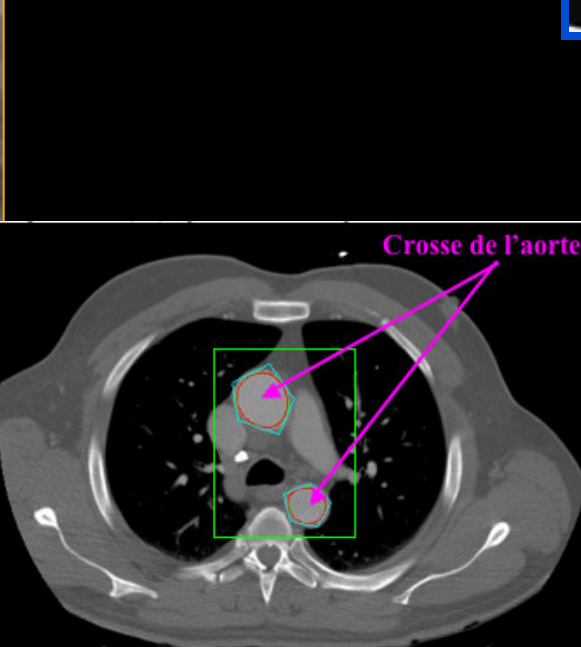
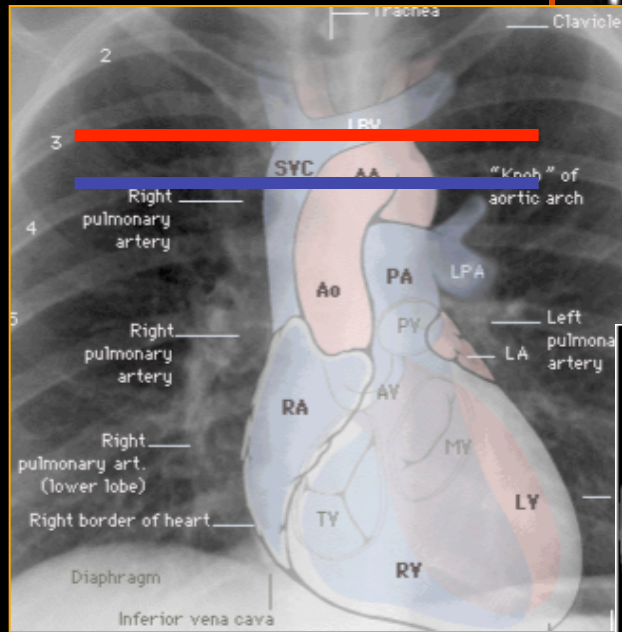
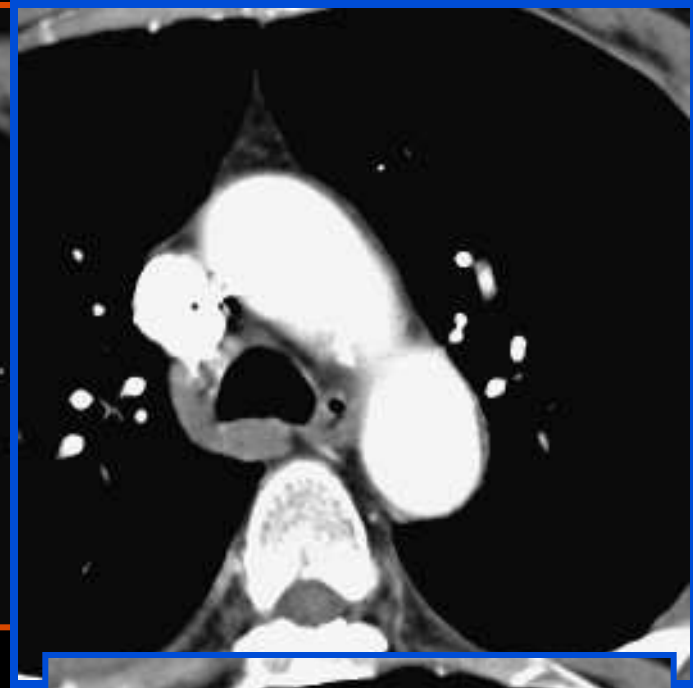
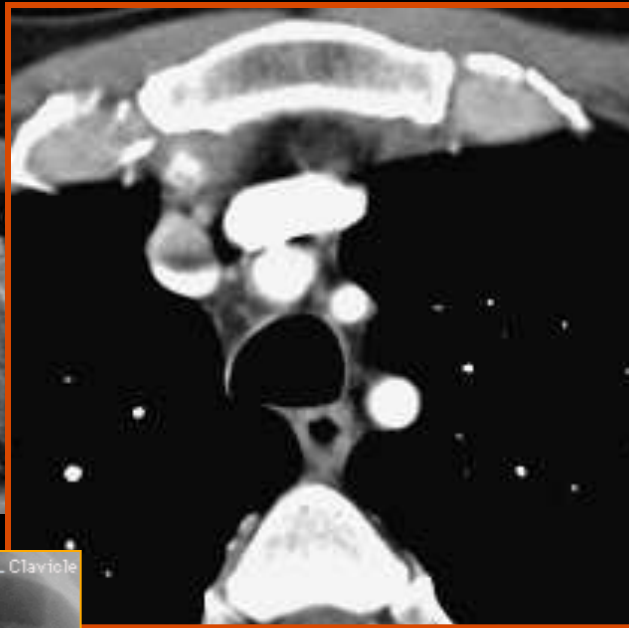
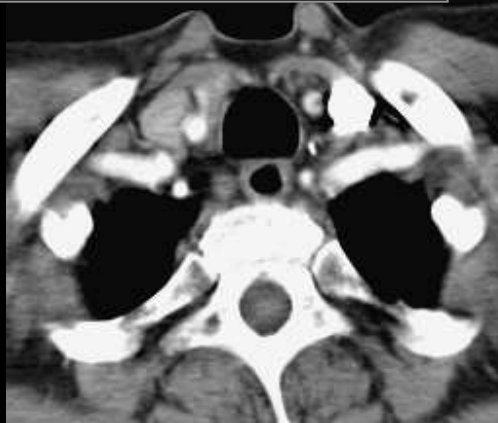**Déplacement  
après lobectomie  
moyenne droite**

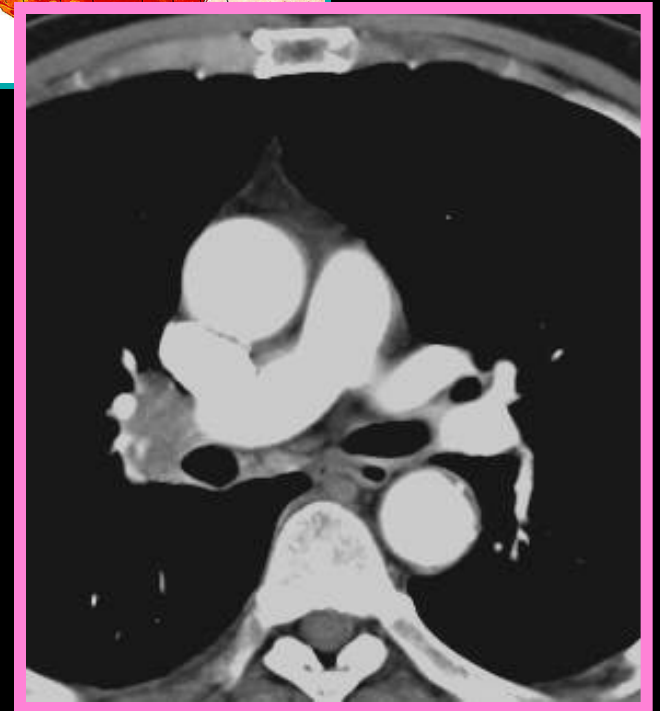
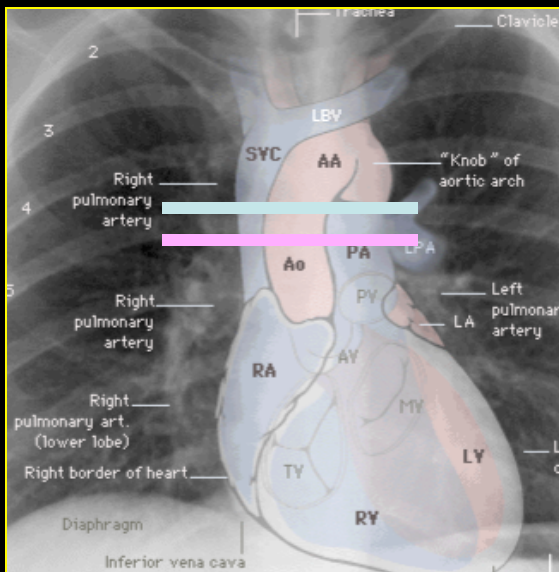
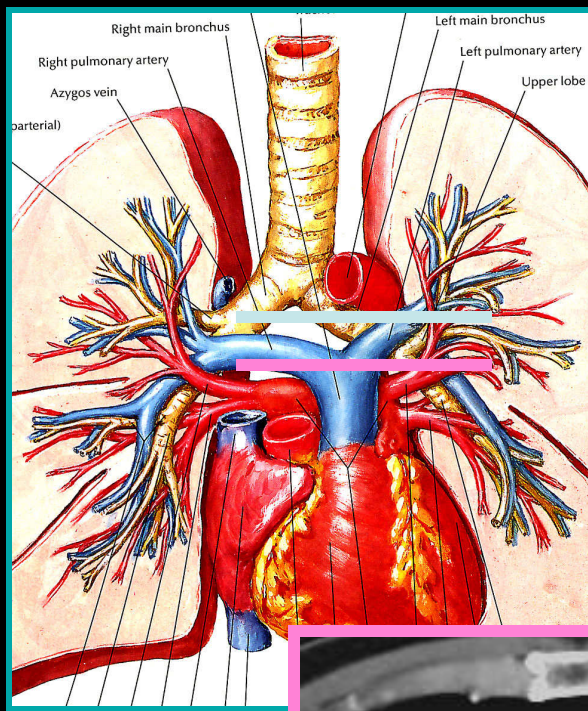
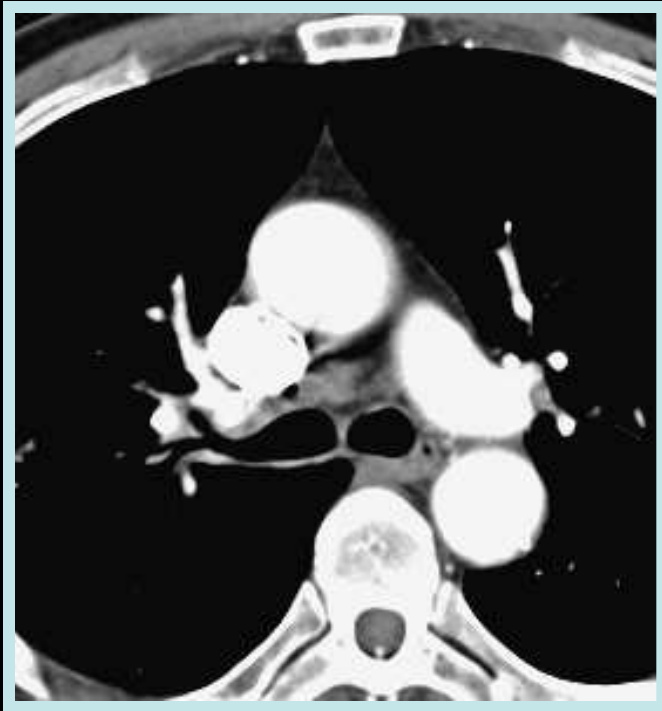


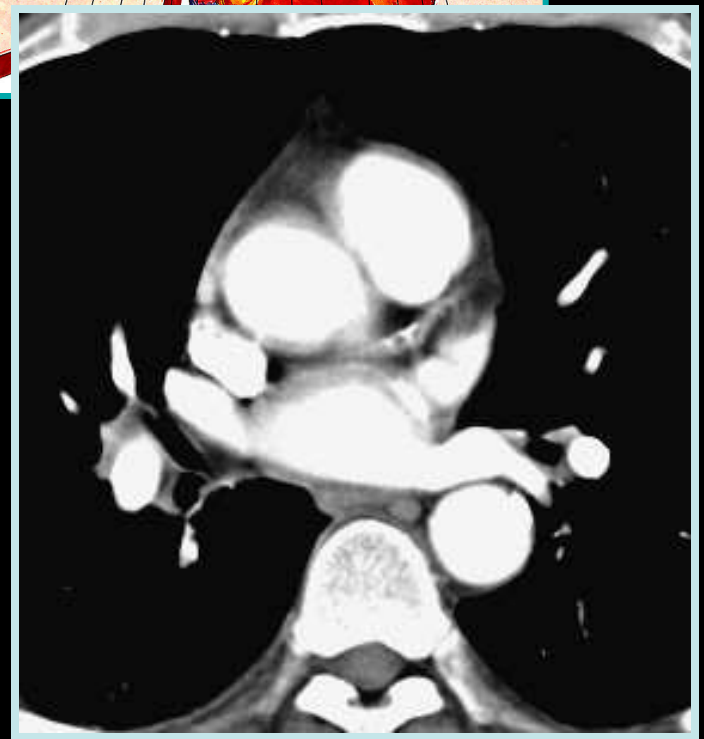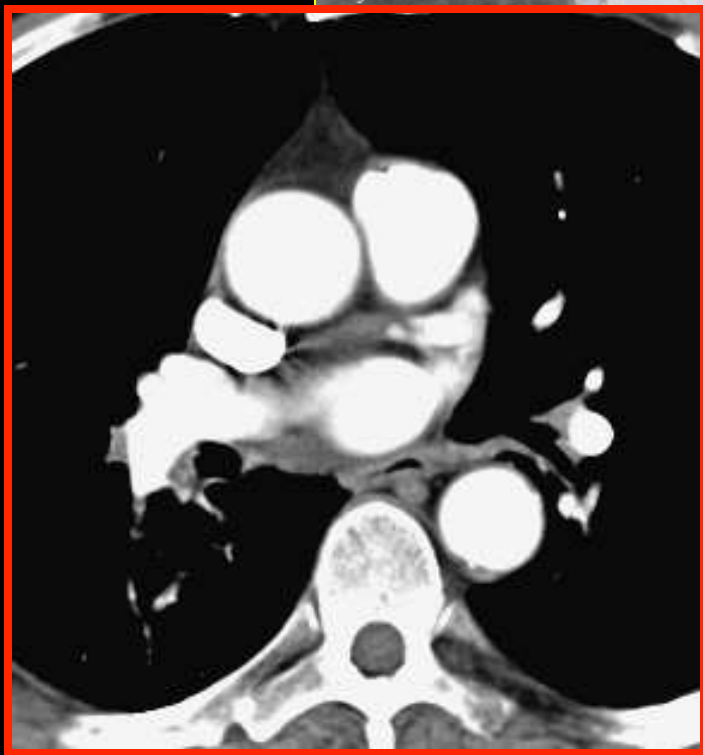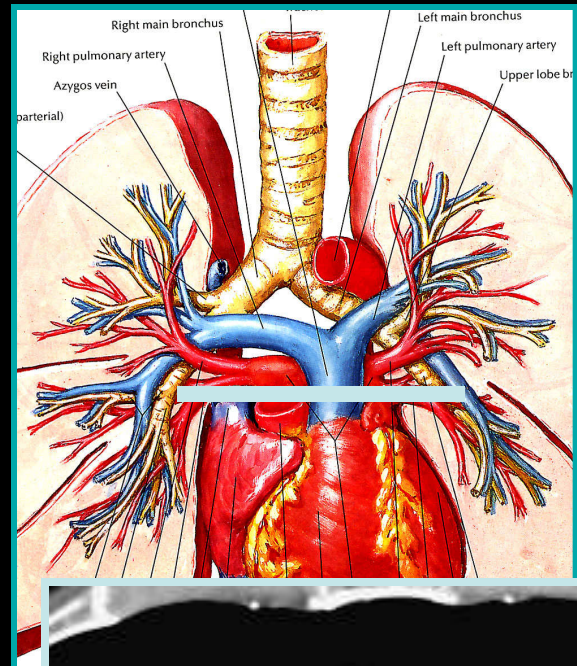
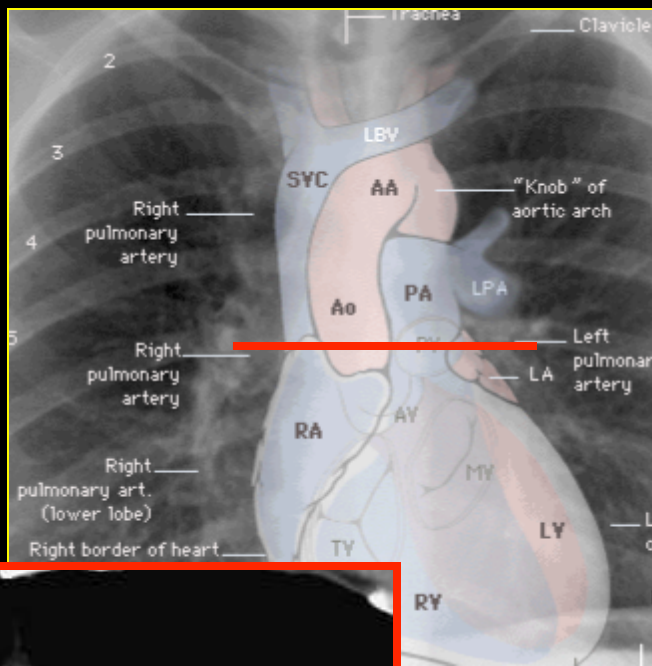
# Reconnaître les structures vasculaires

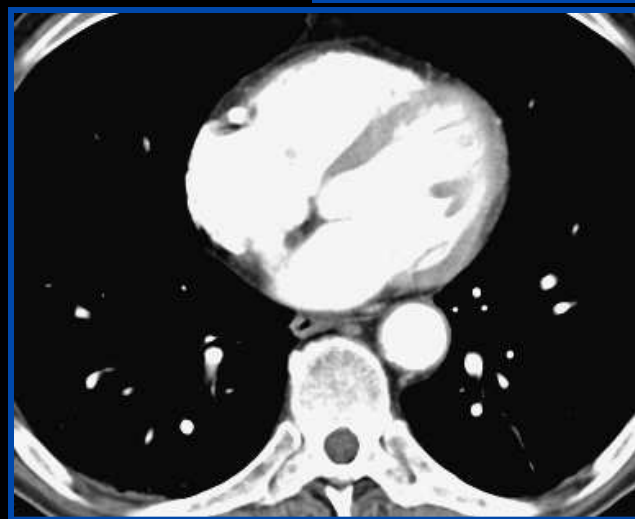
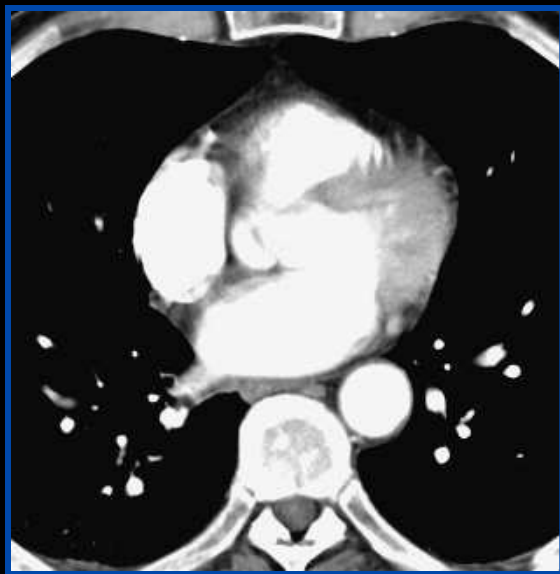
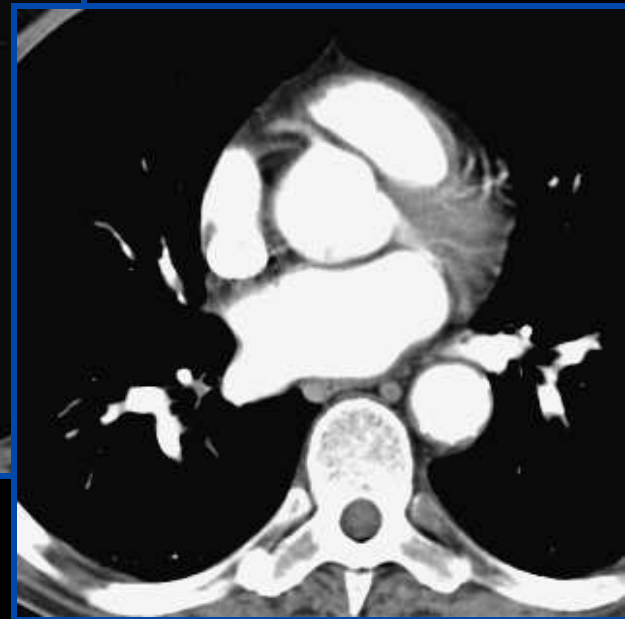
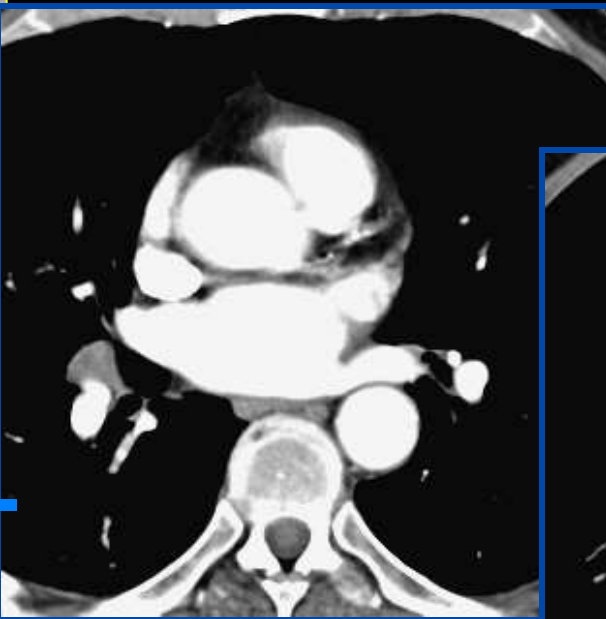
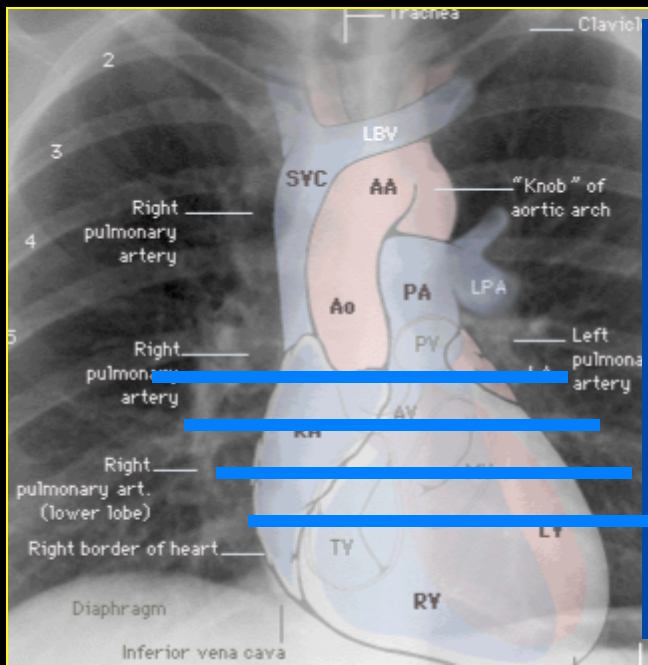


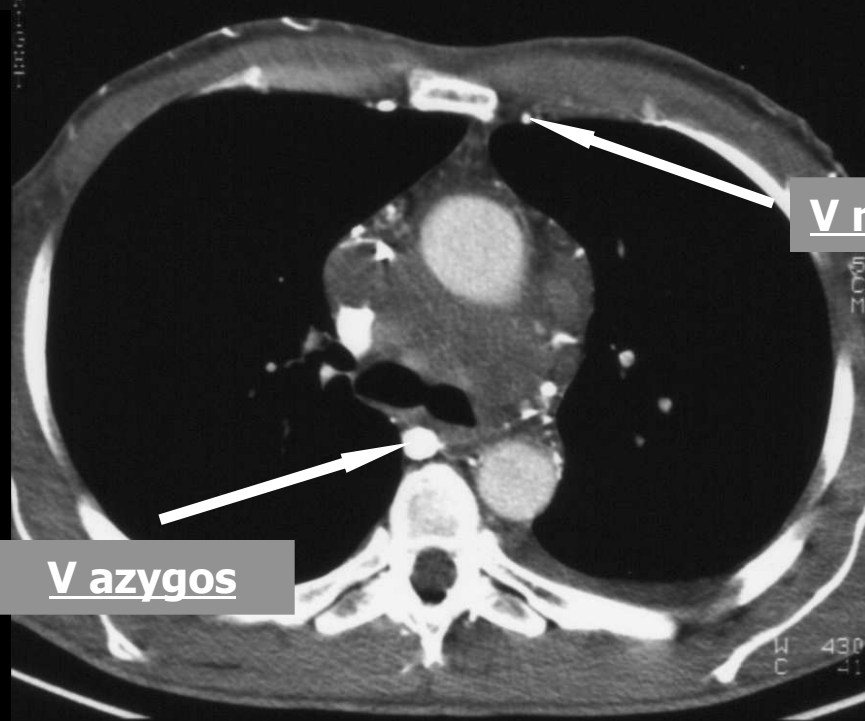
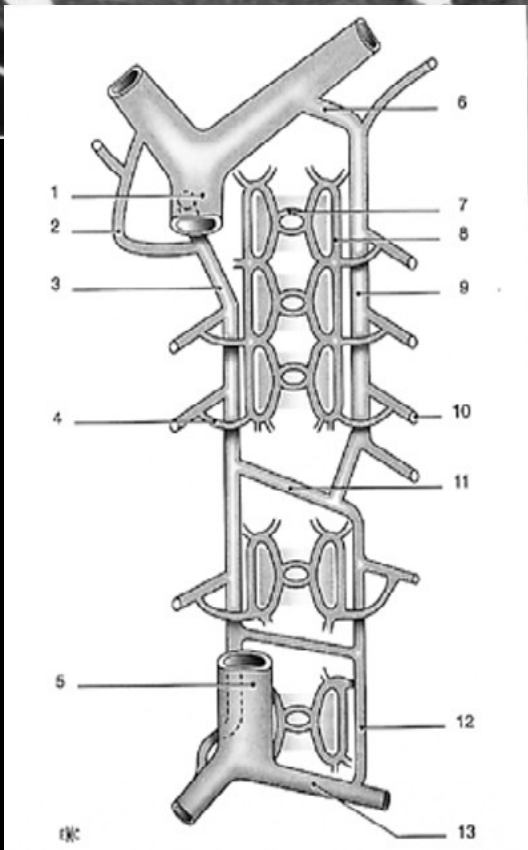
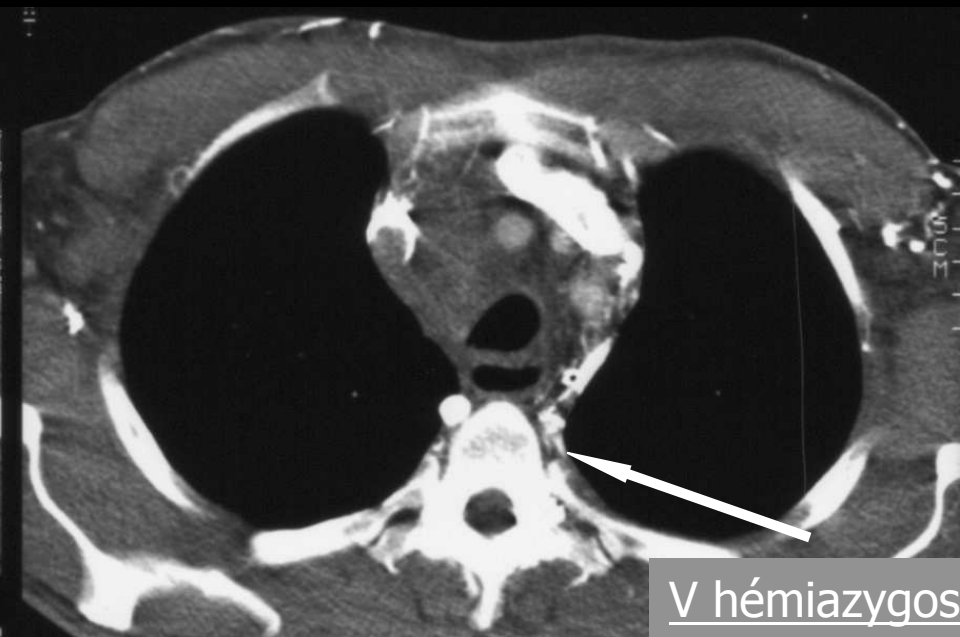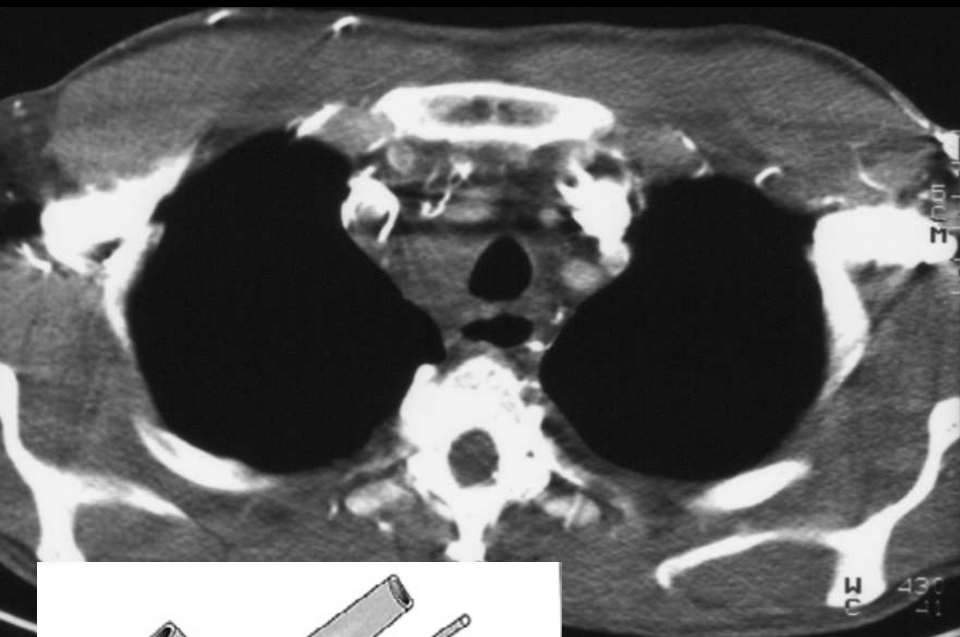
# Scanner







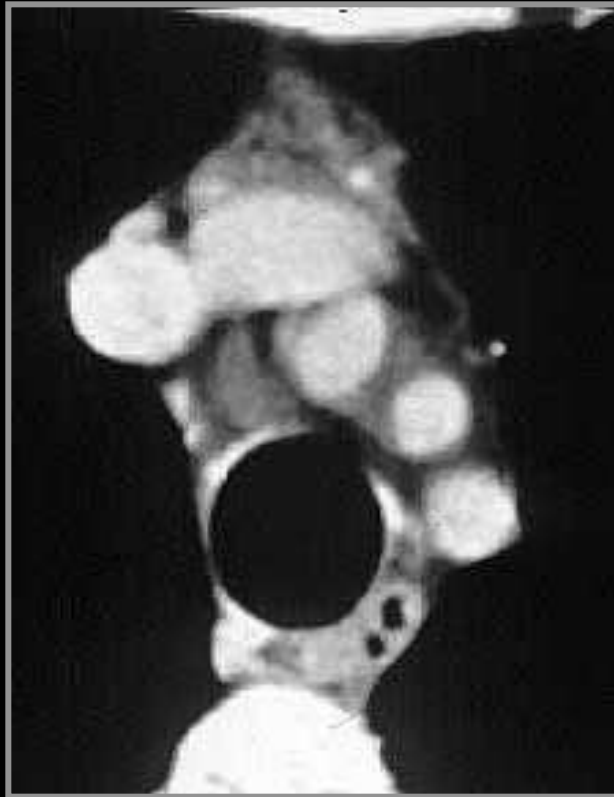




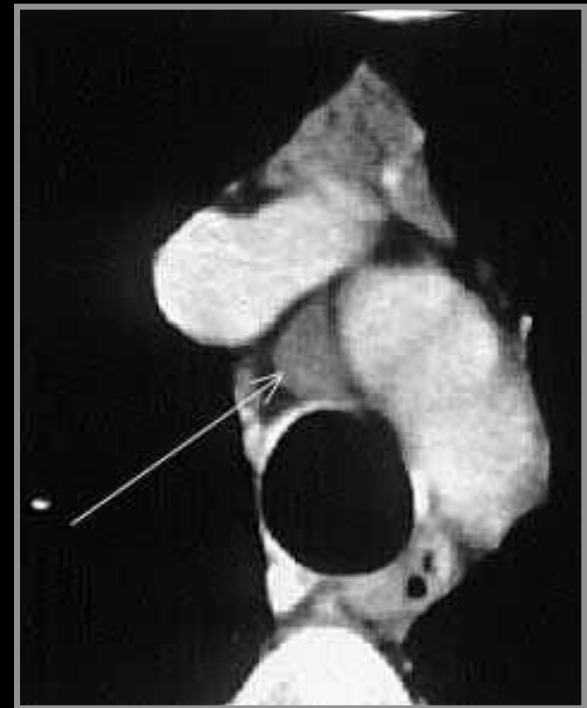

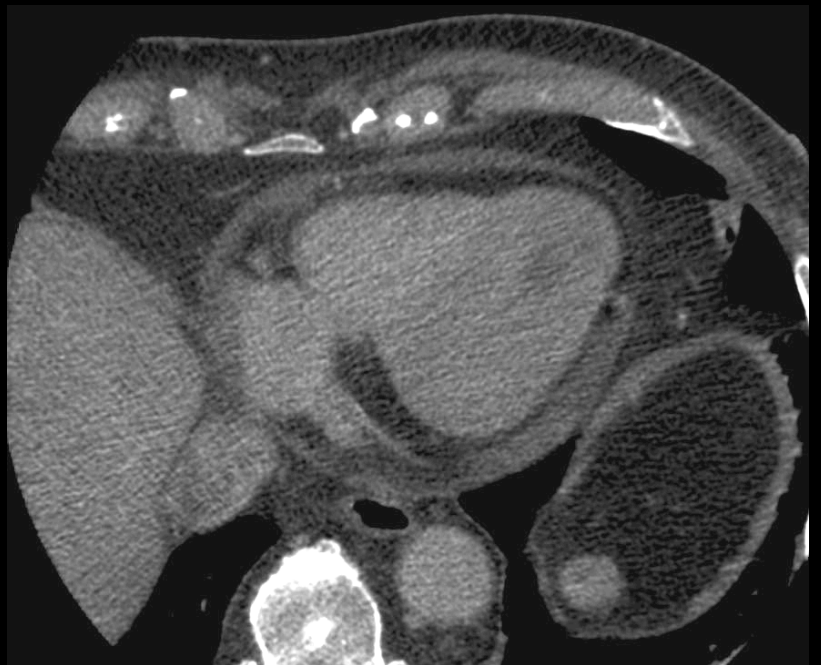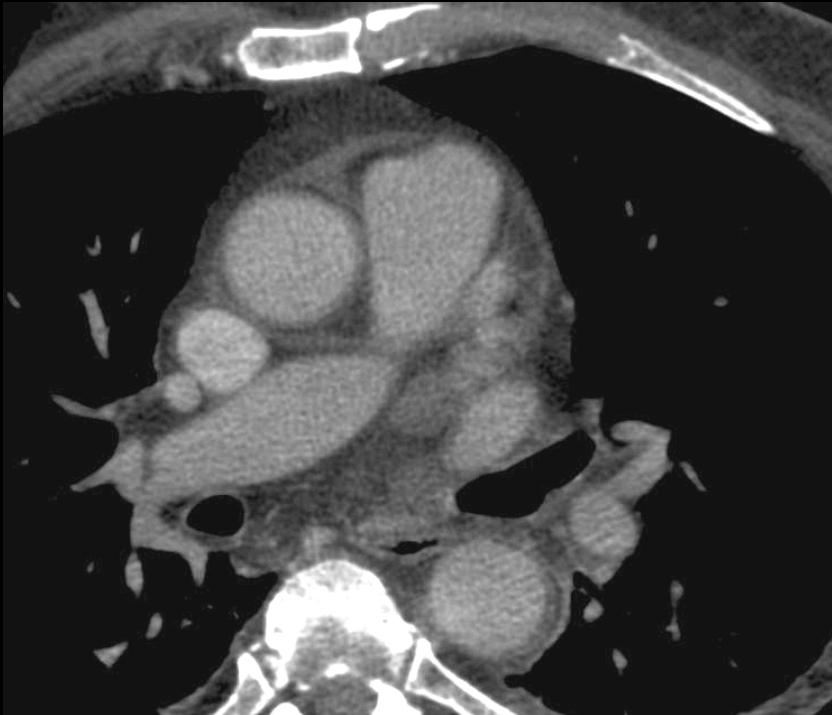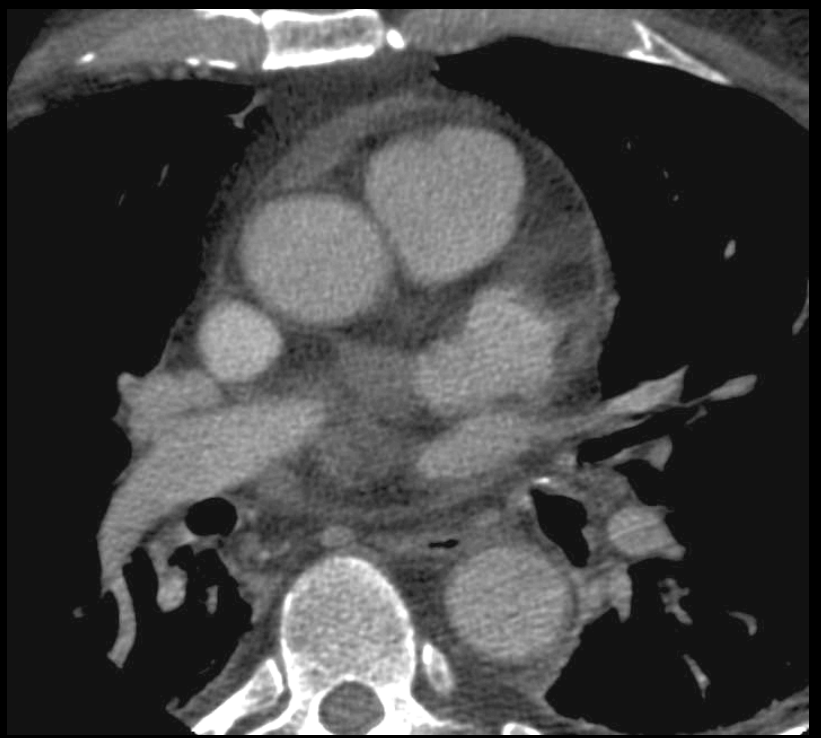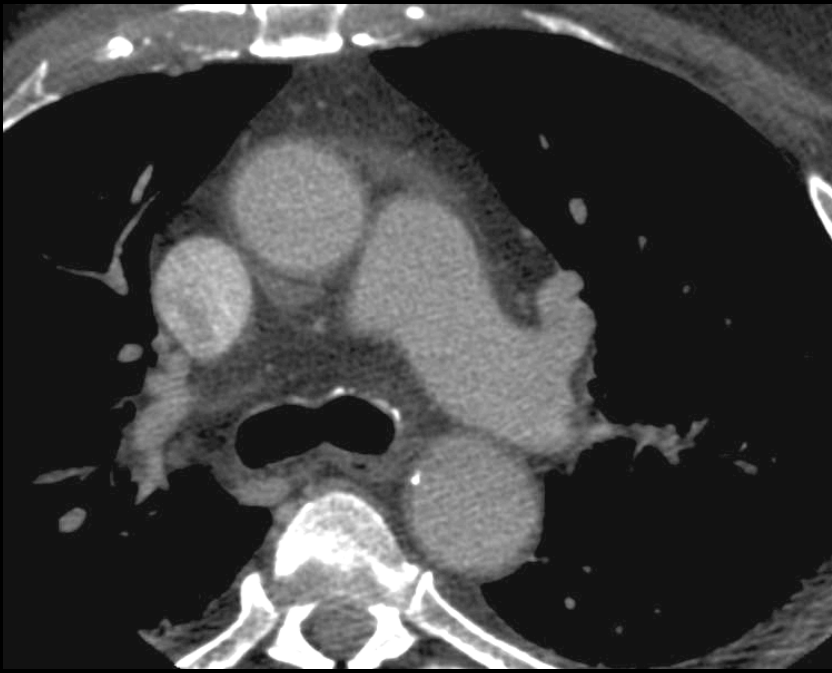**UN PEU DE PATHOLOGIE ET  
VARIATIONS ANATOMIQUES...**

# Pièges et erreurs

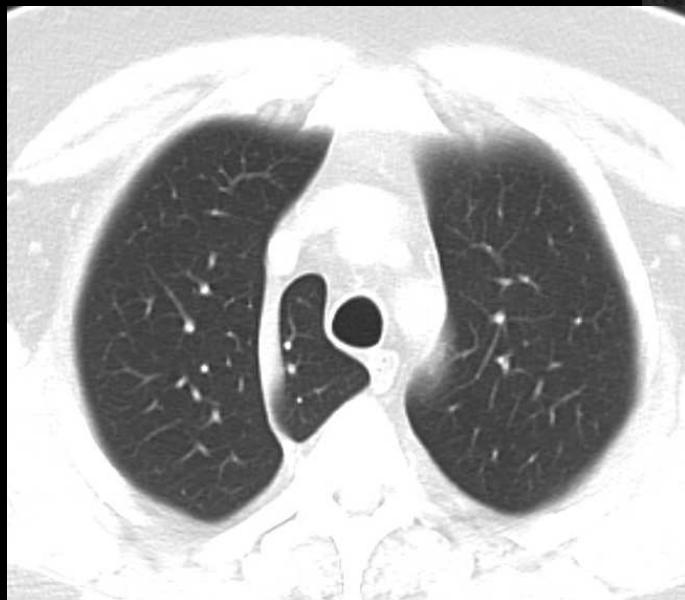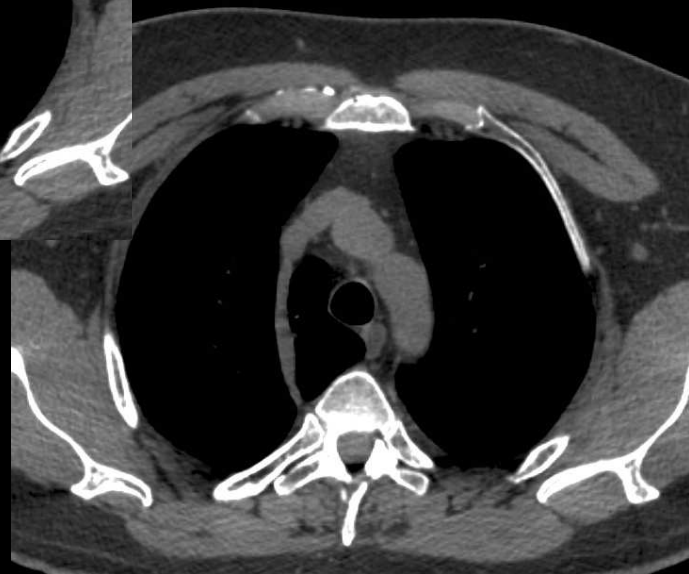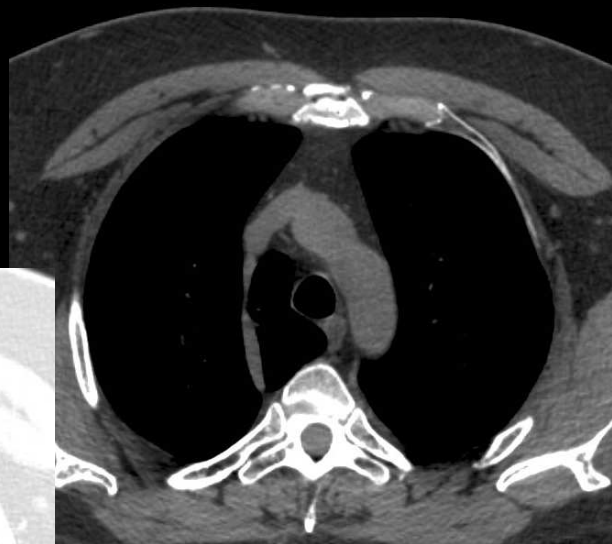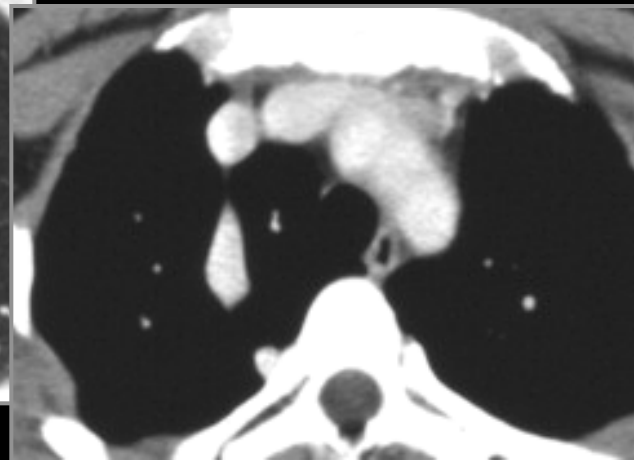


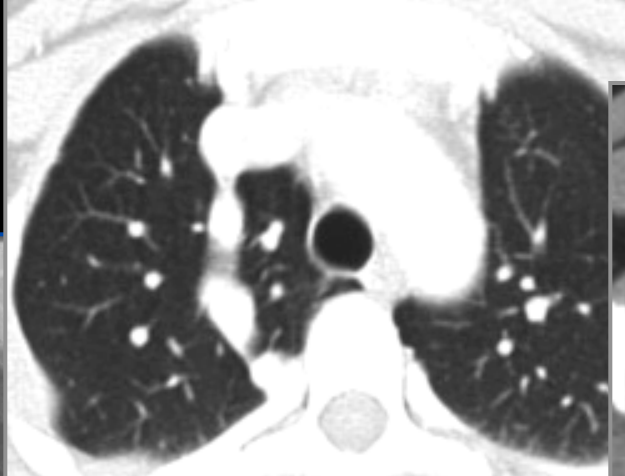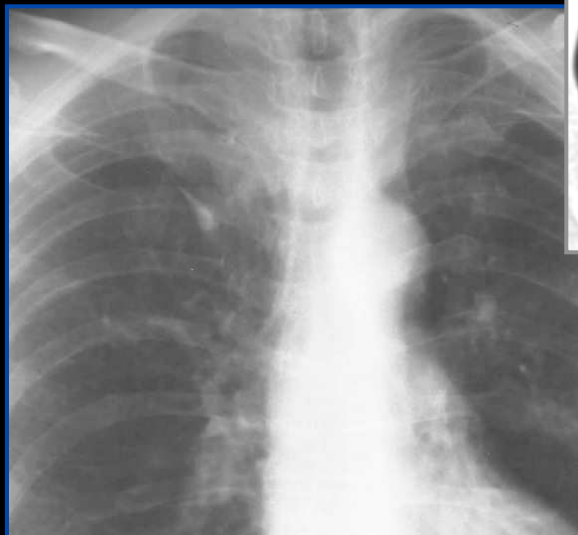Récessus péricardique

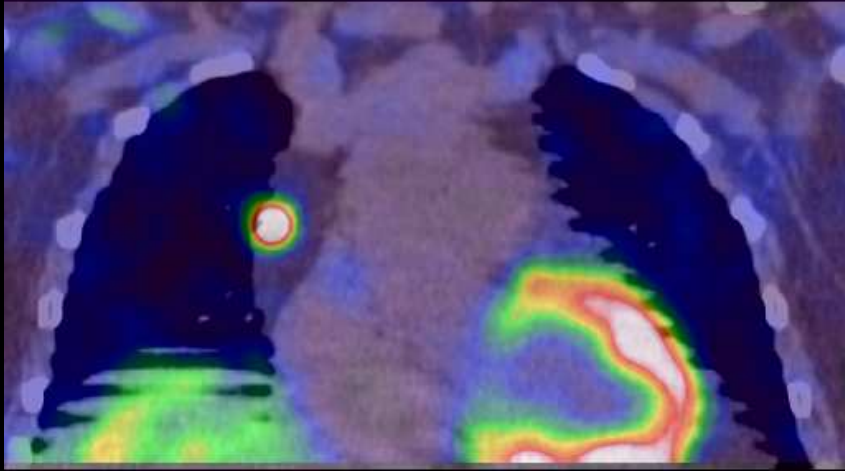
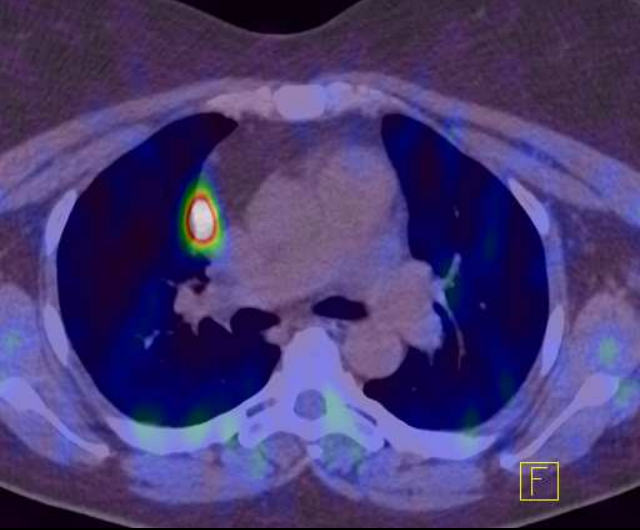
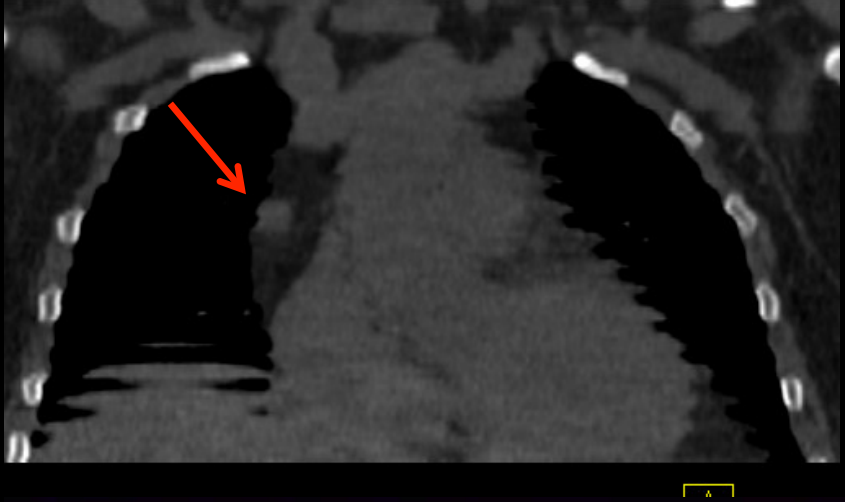
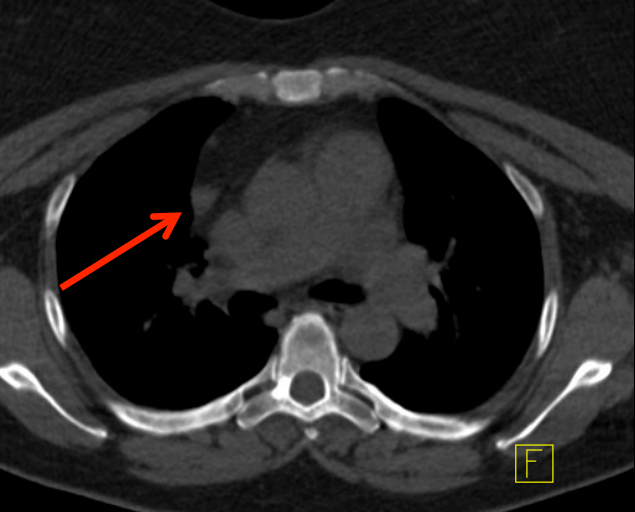




# Scissure azygos

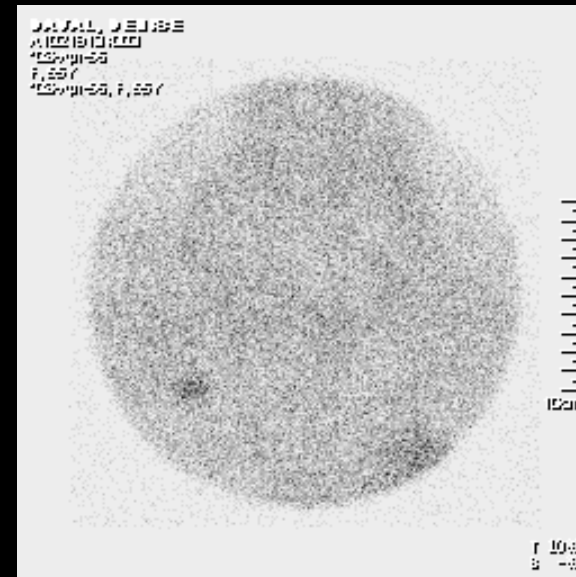
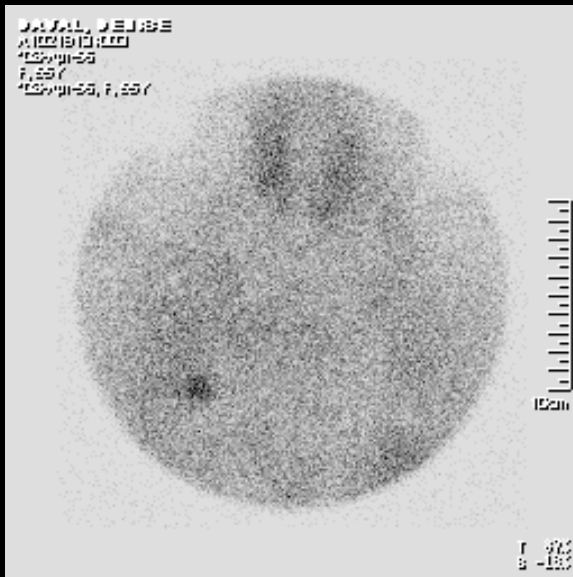
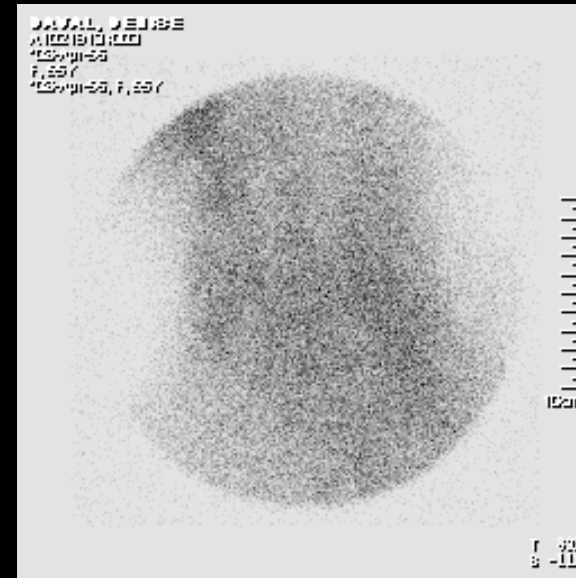
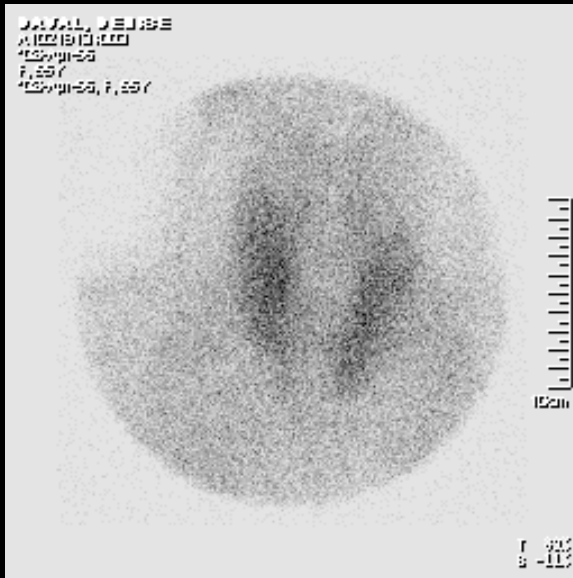


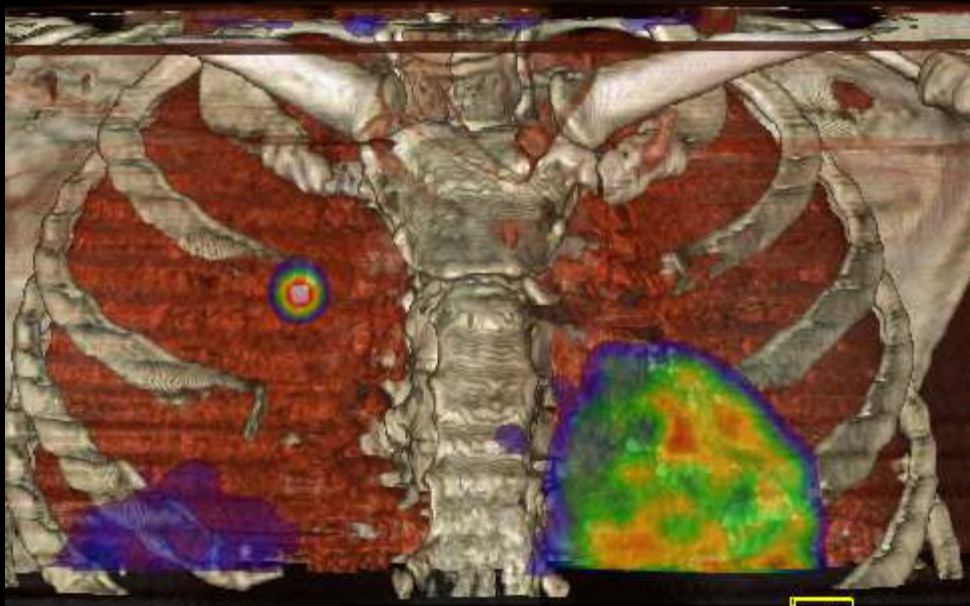
# Adénopathie médiastinale ?



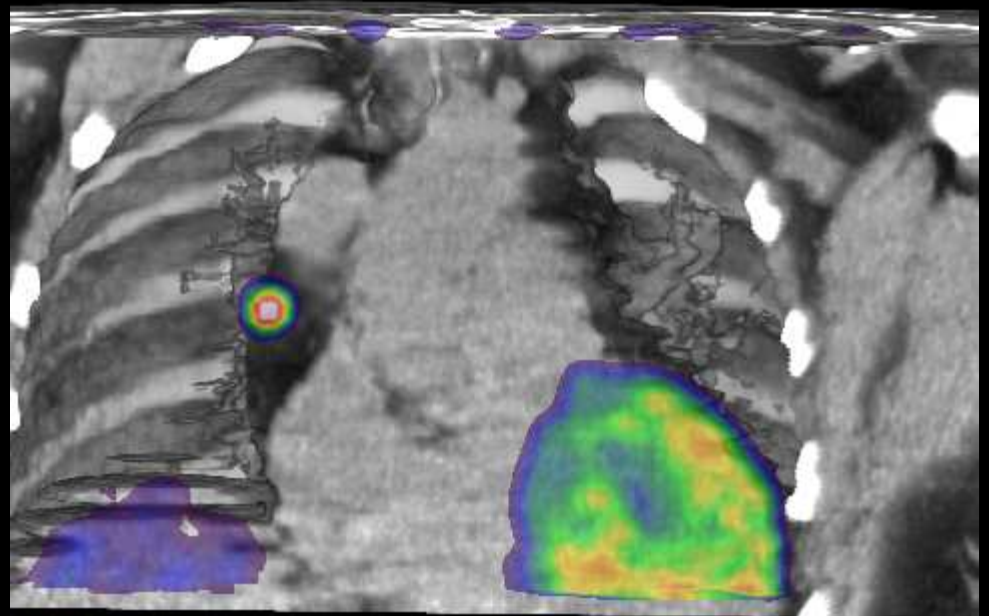
**Adénome parathyroïdien ectopique!**

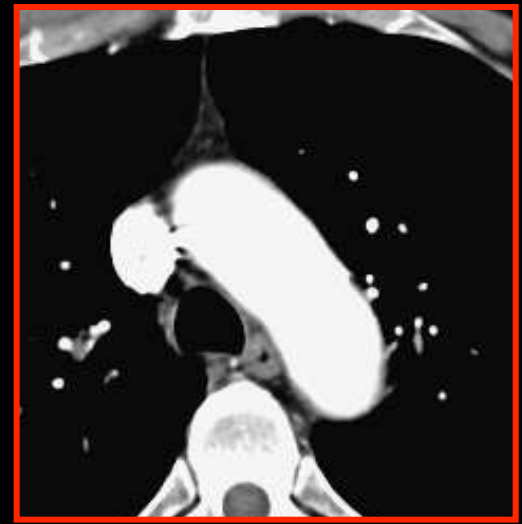
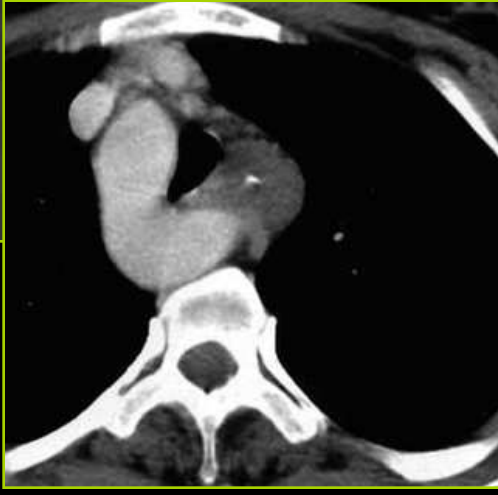
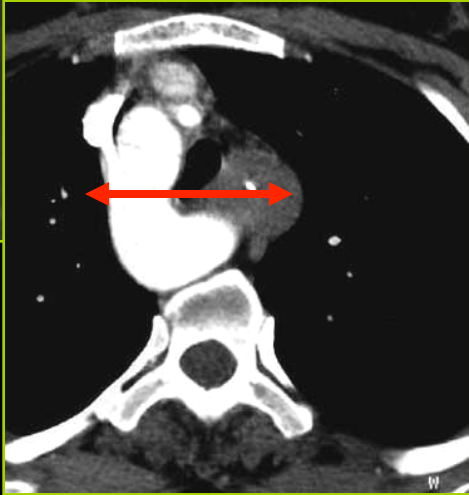
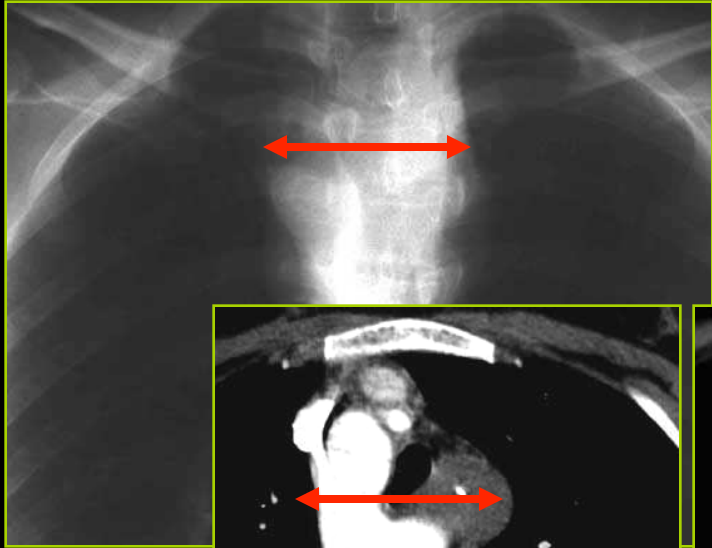
# $^{99m}\text{Tc}$ -SESTAMIBI : images précoces et tardives



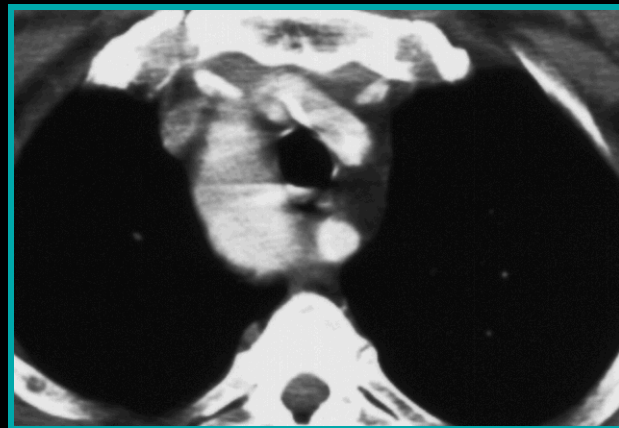
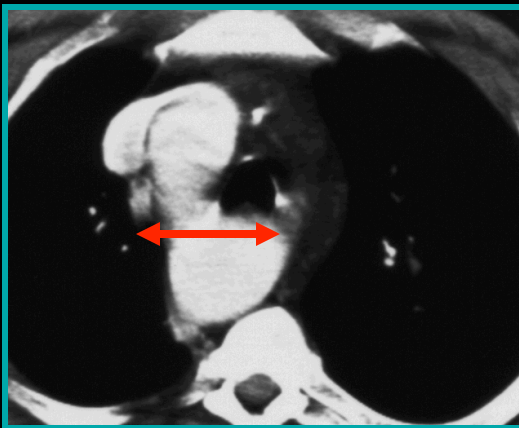


A





**Arche aortique à droite**

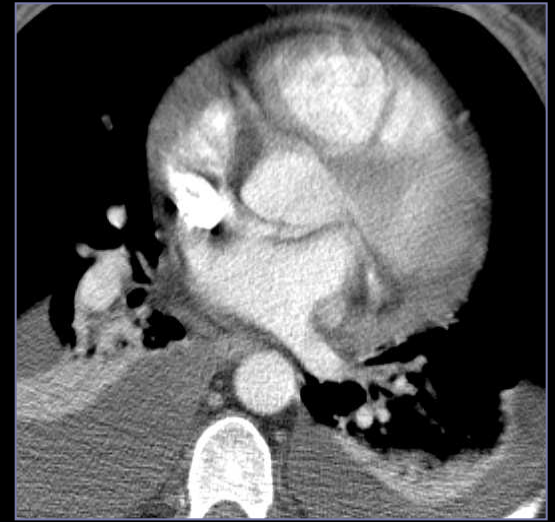
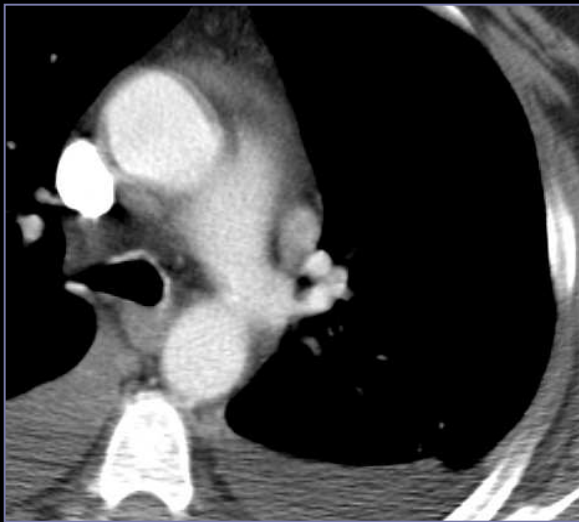
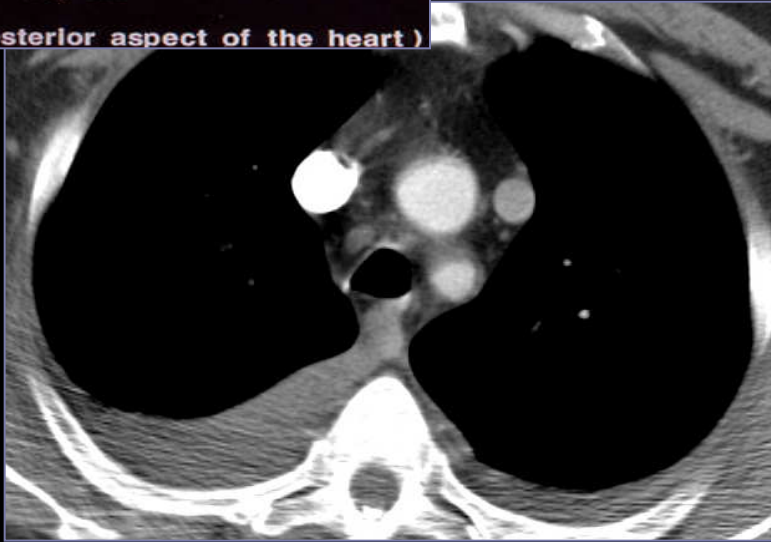


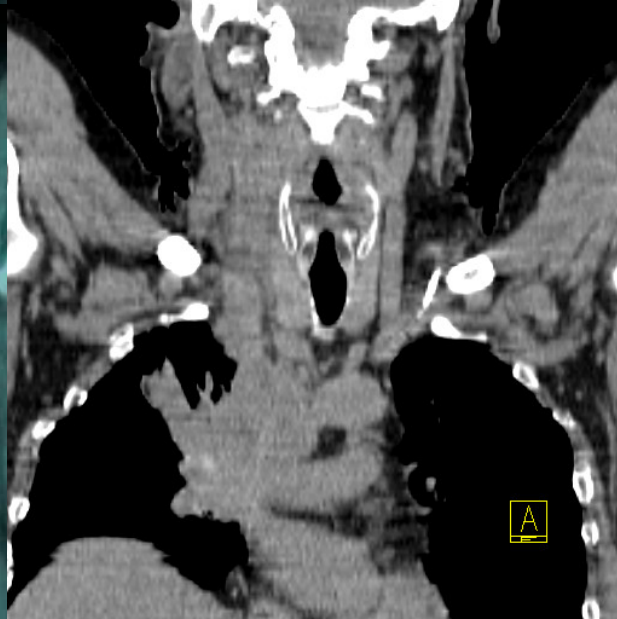
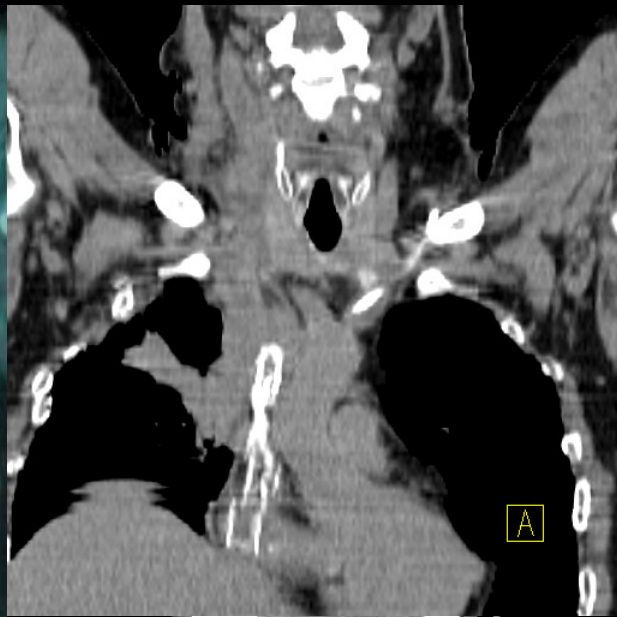
# Double Veine cave sup

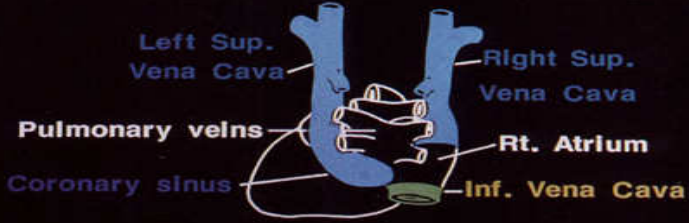

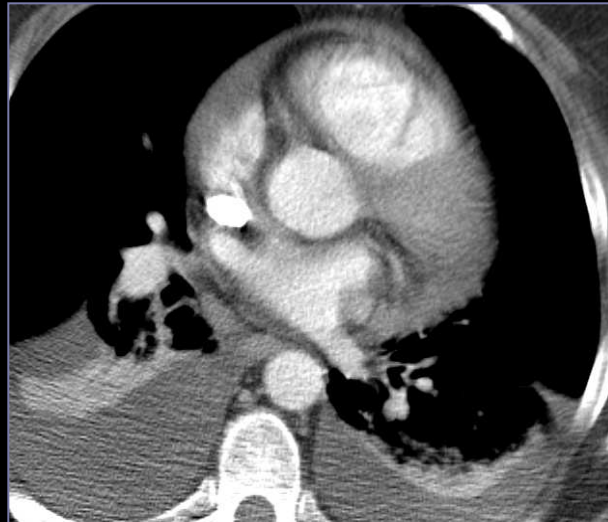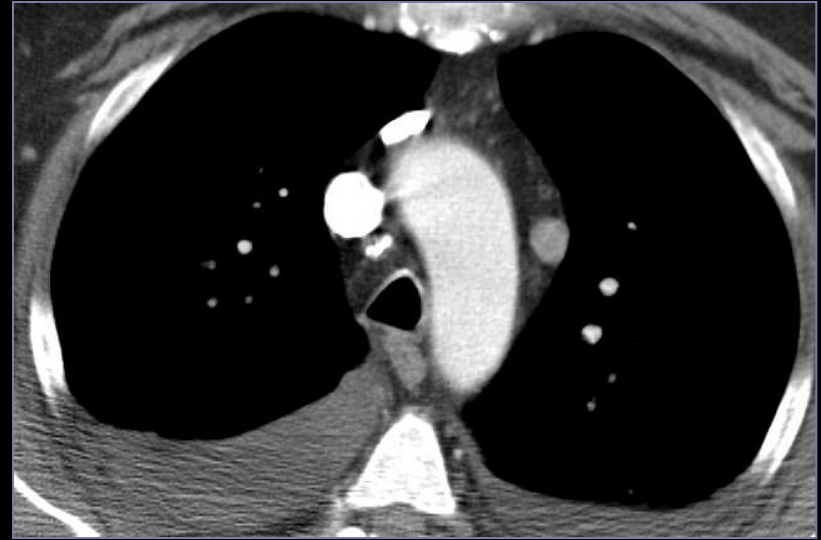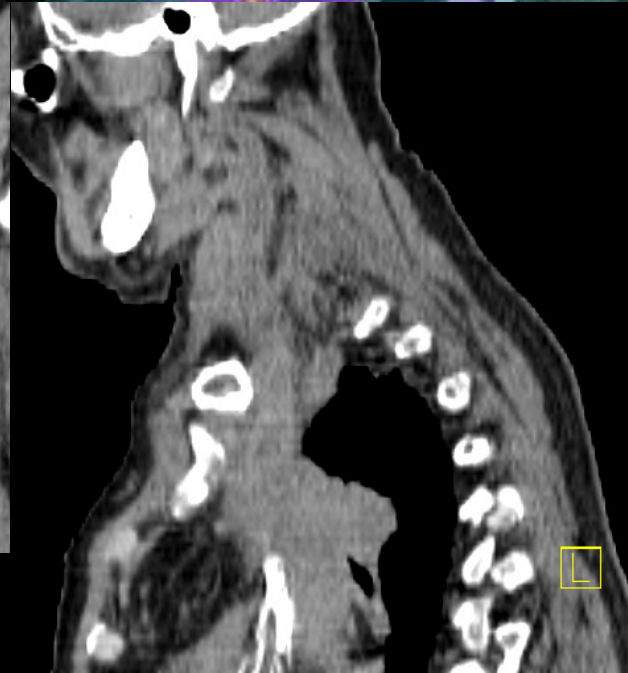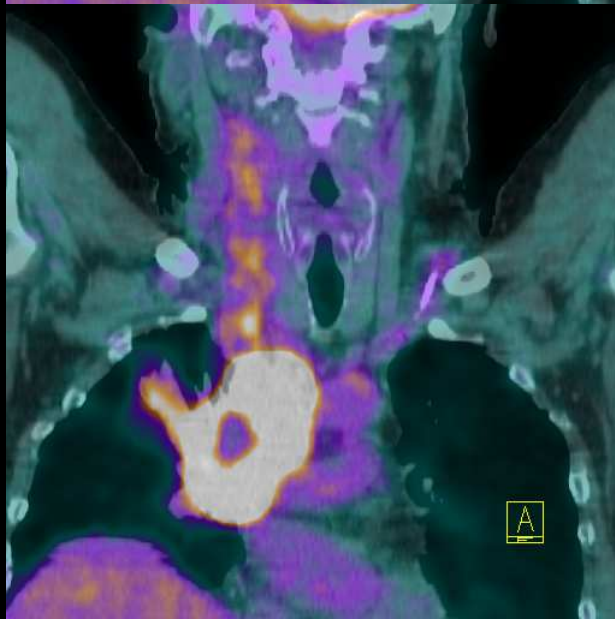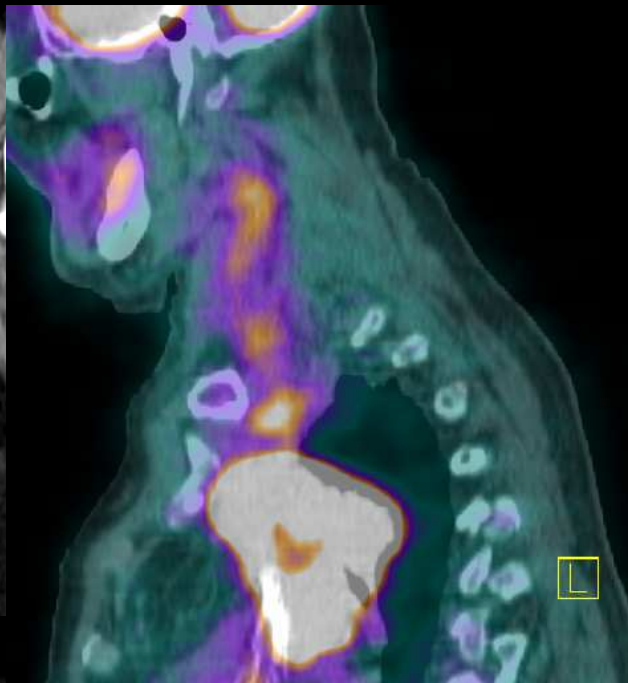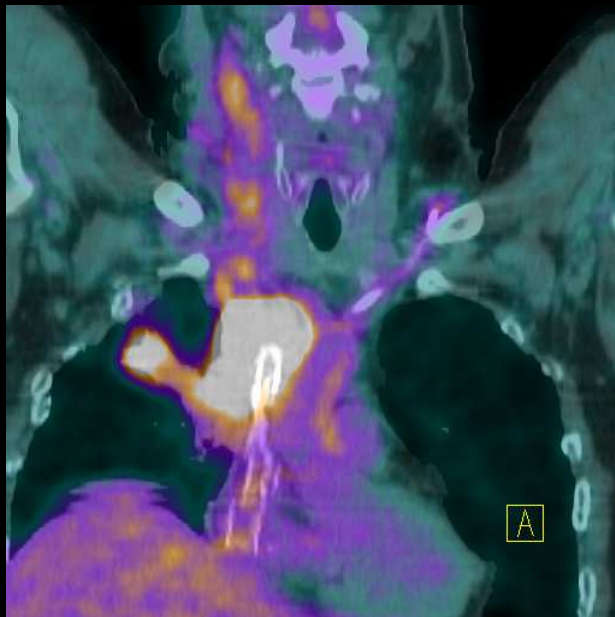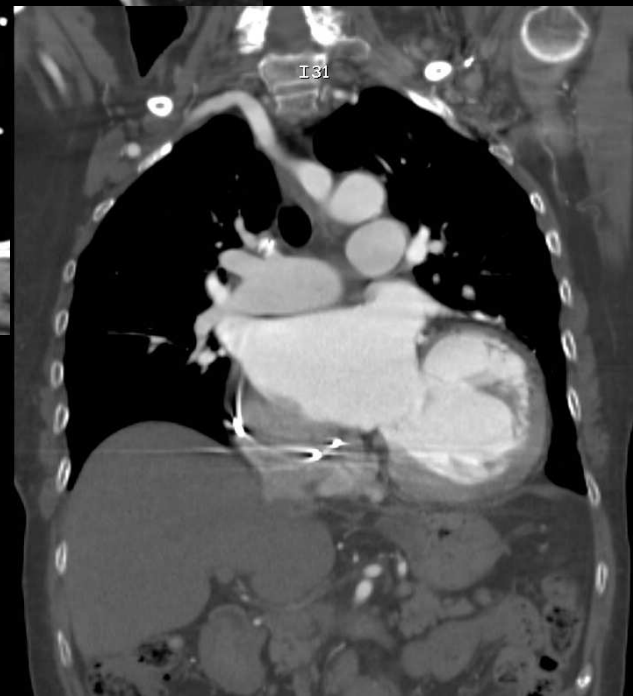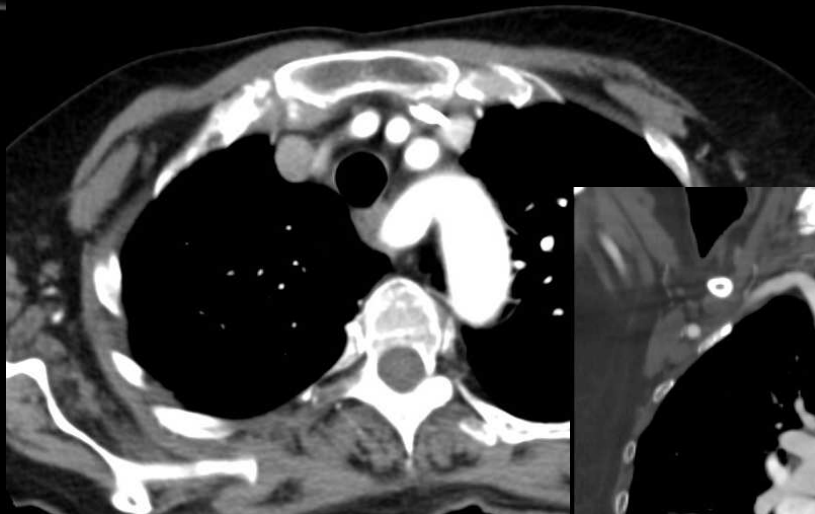
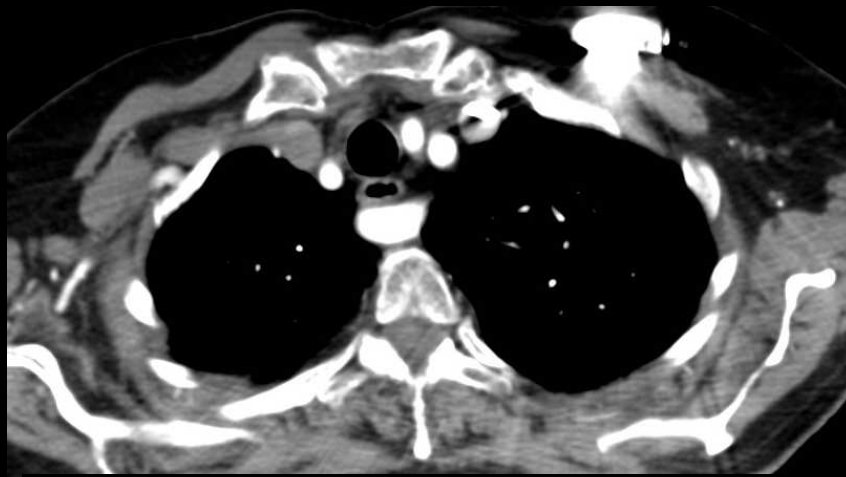Fig 8B

(Viewed from posterior aspect of the heart)

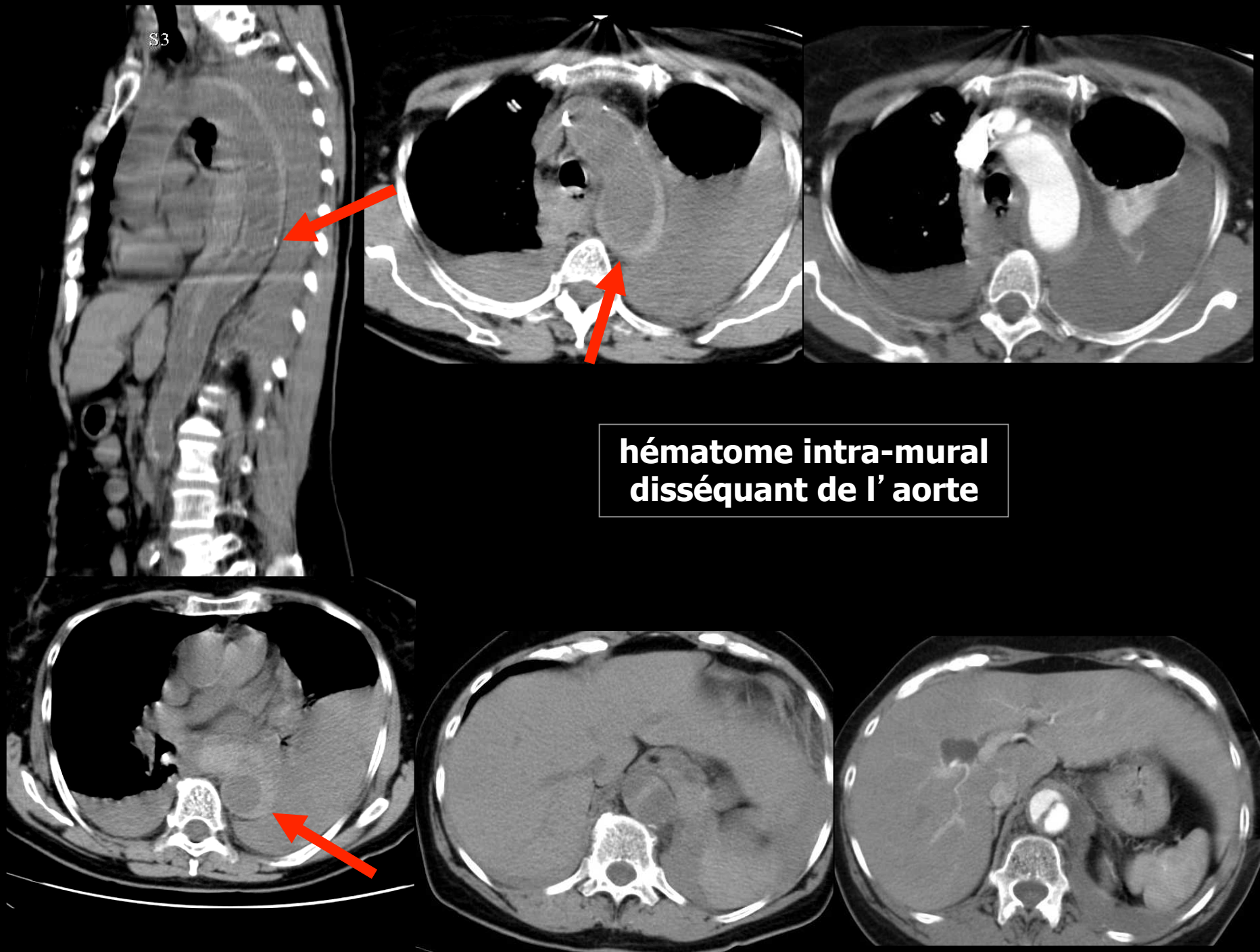




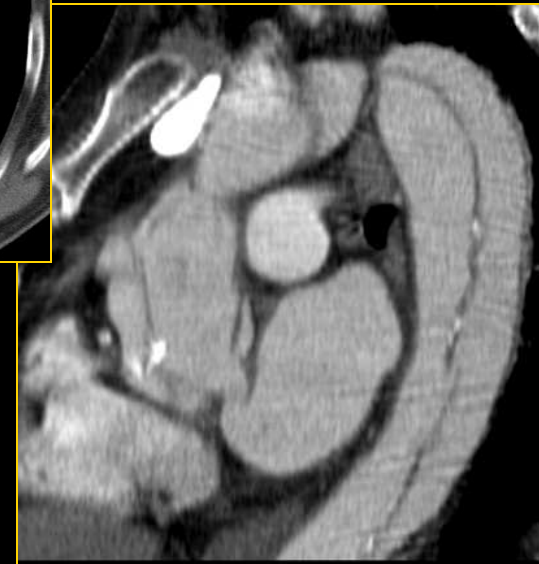
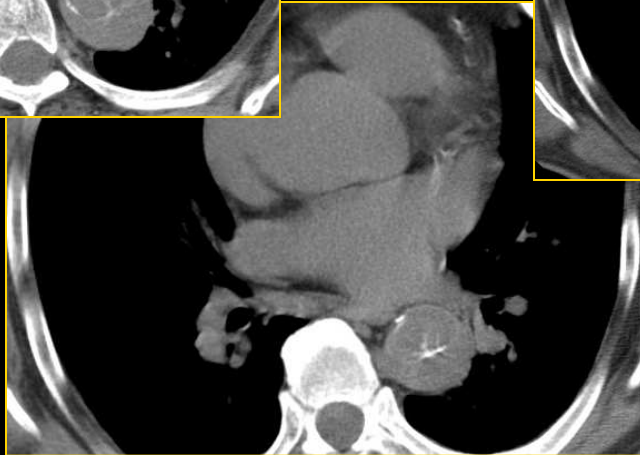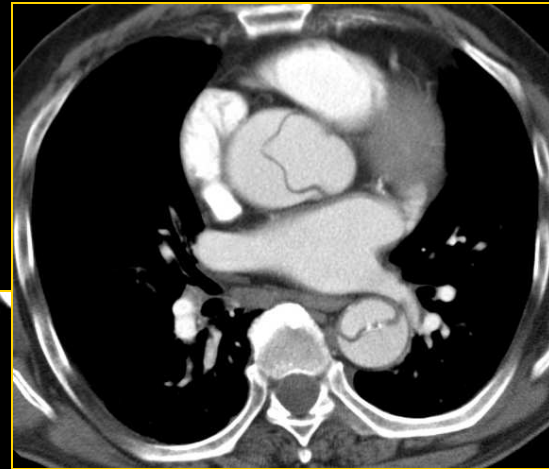
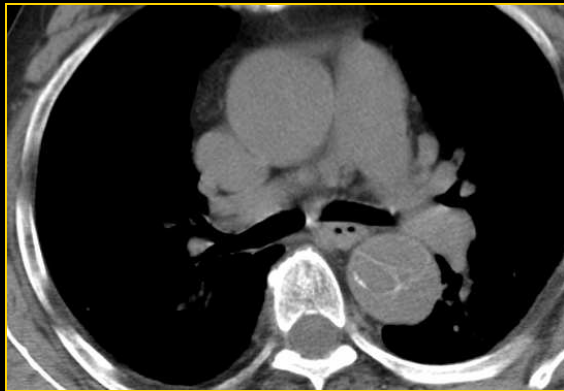
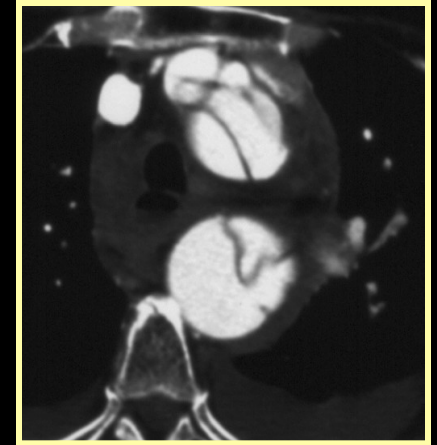
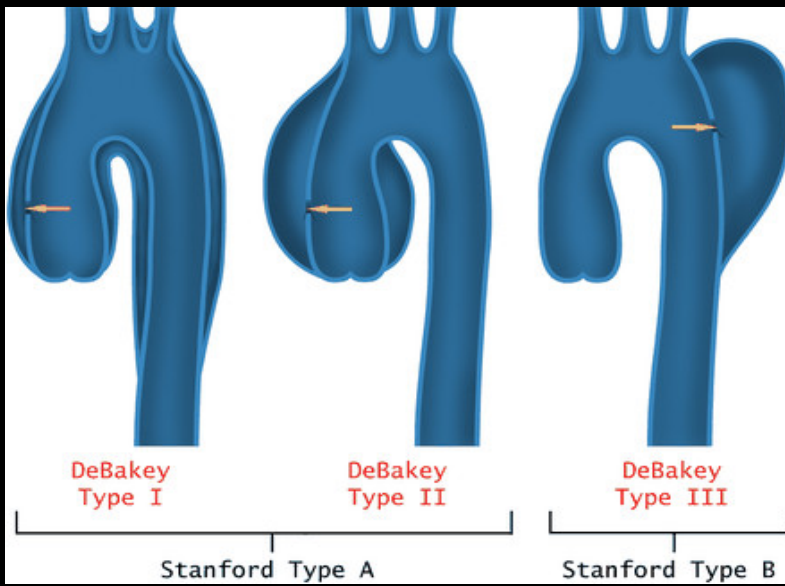
**Envahissement VBC droite**

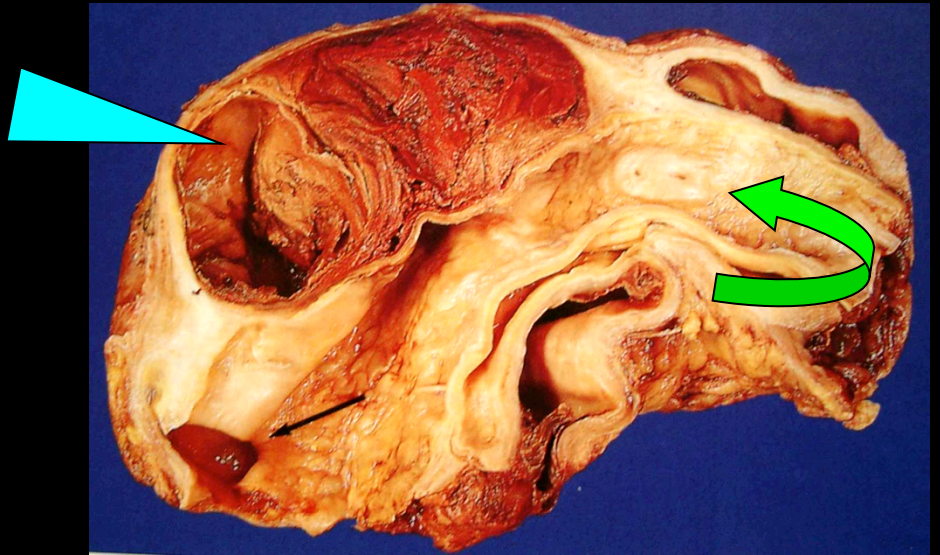
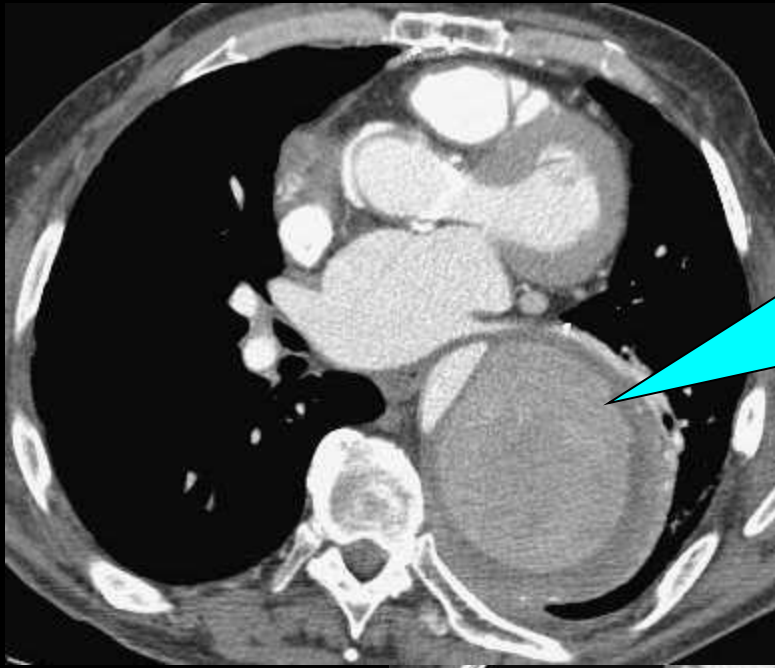


**Artère sous clavière droite  
rétrooesophagienne: arteria lusoria**

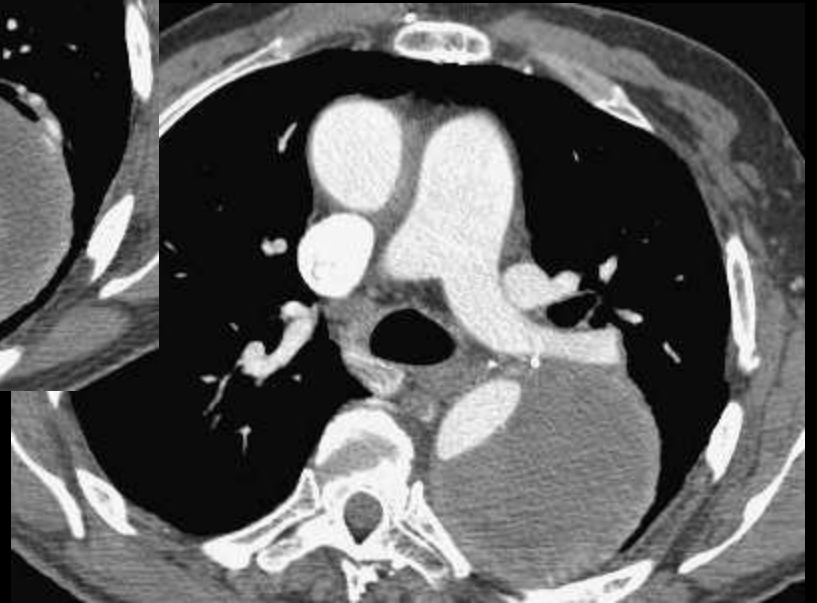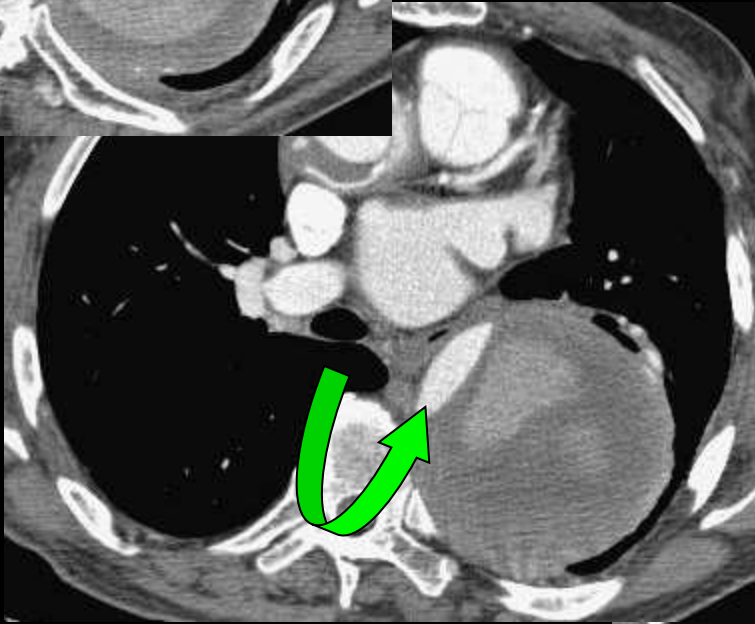


# Dissection aortique aiguë

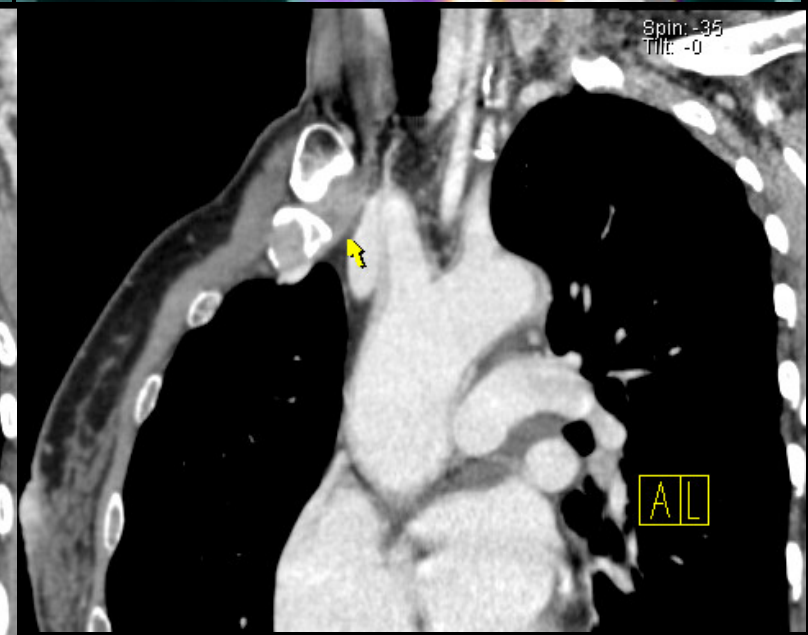
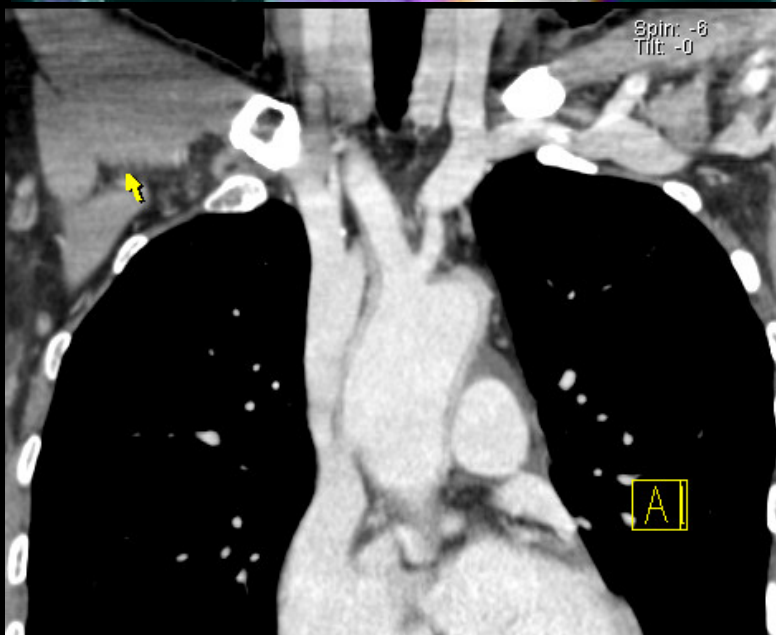
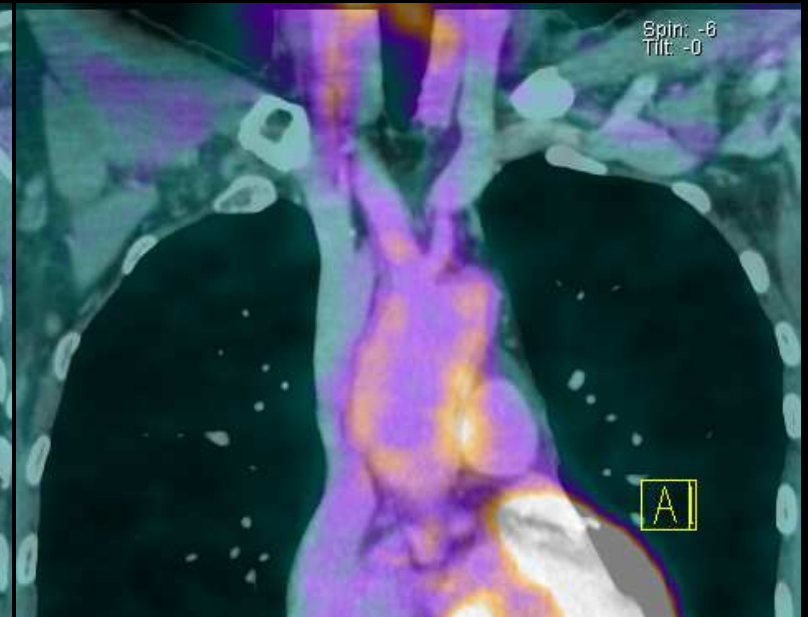
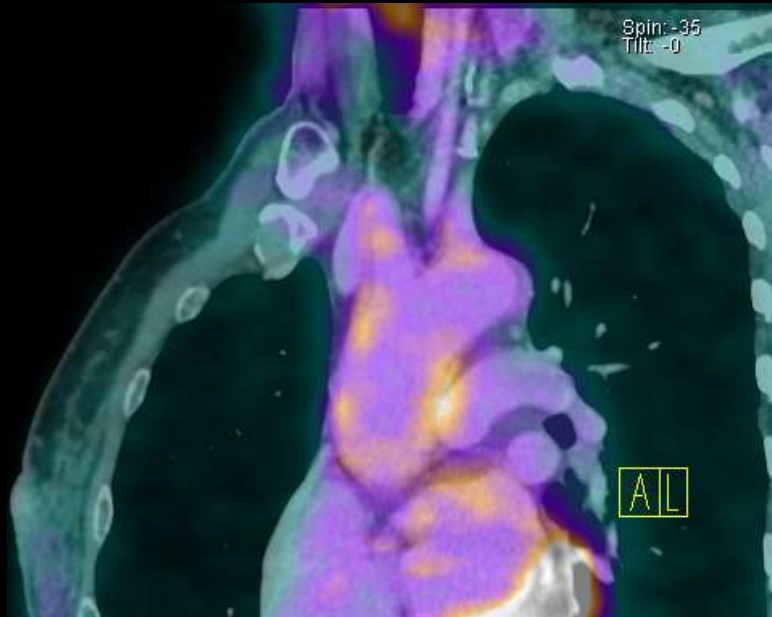


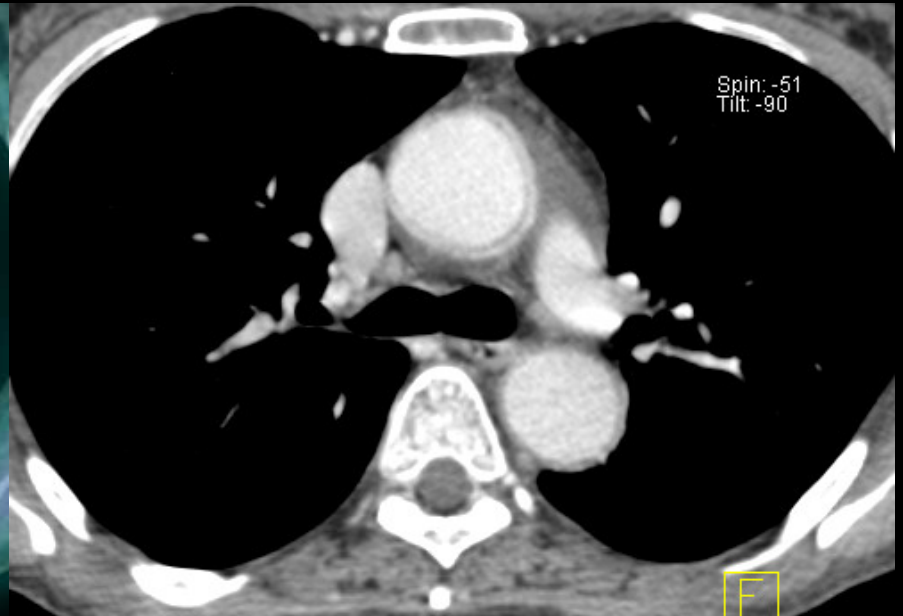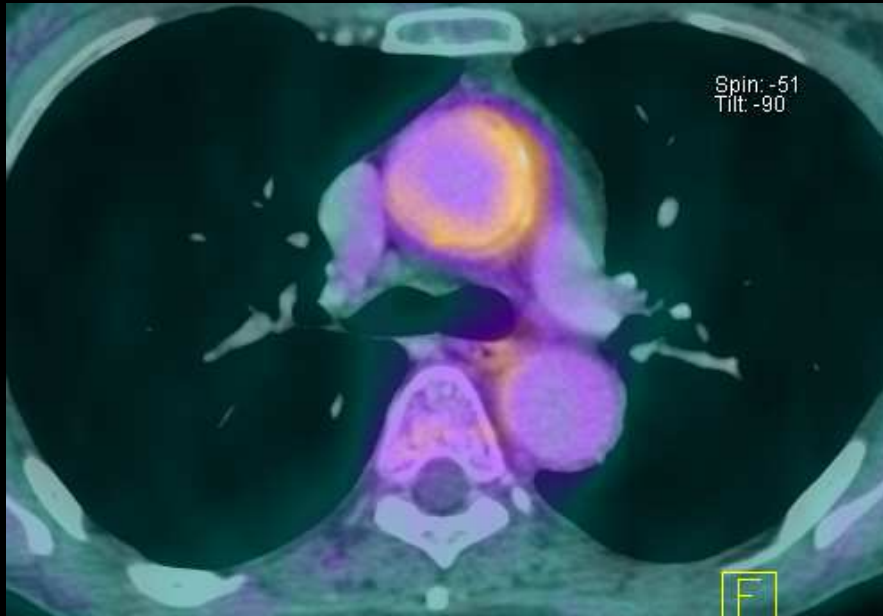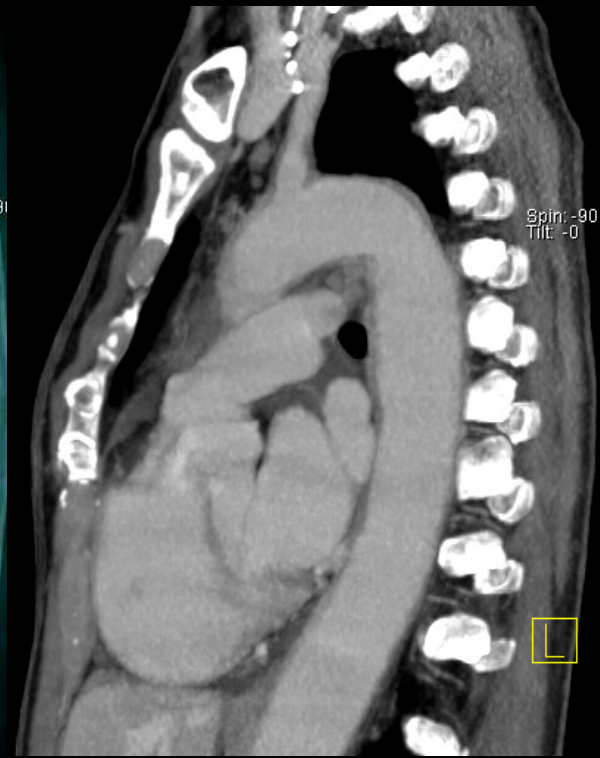
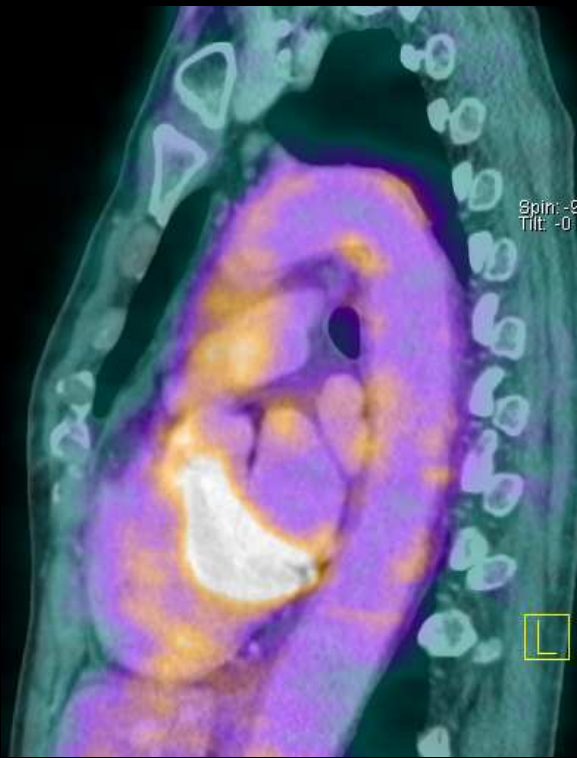**Dissection aortique et dilatation anévrysmale du faux chenal**

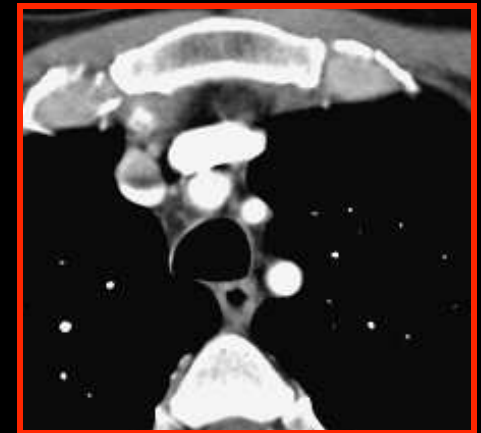
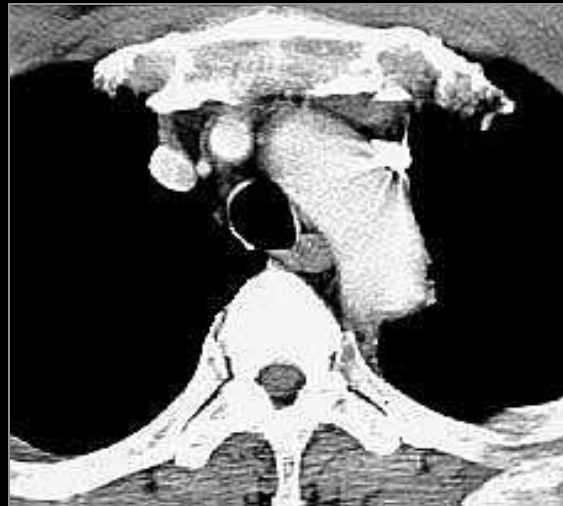
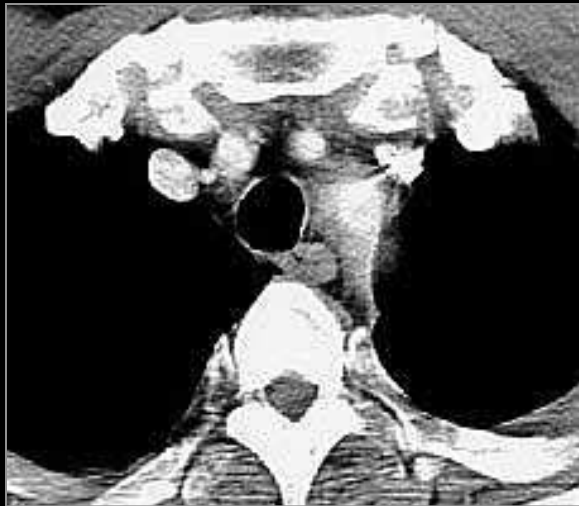

# Aortite (Maladie de Takayashu)

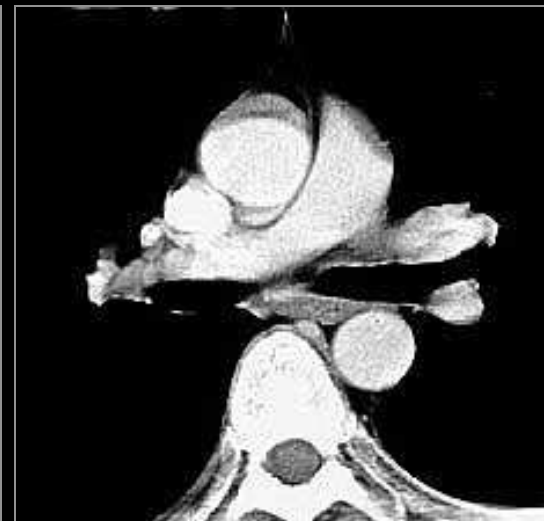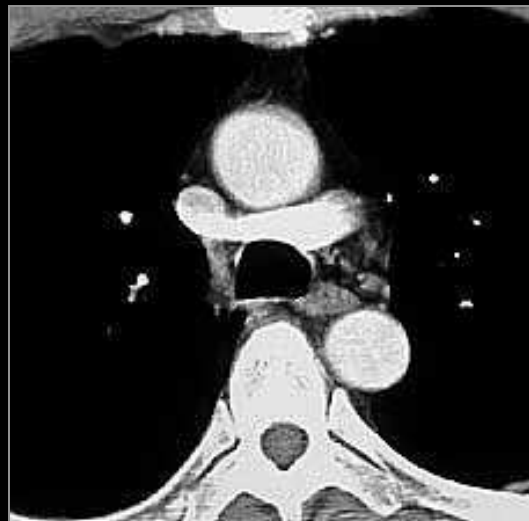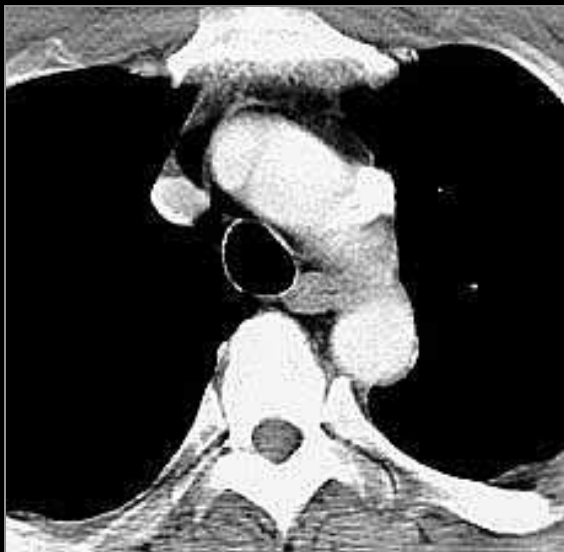


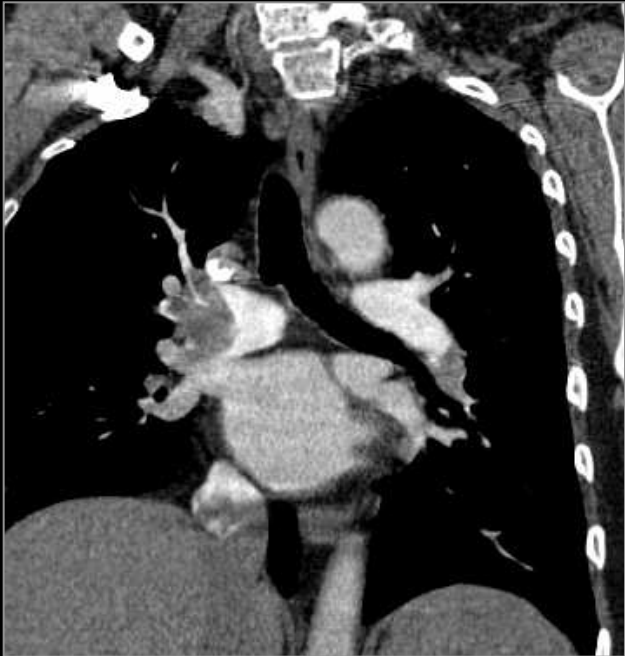# Aortite (Maladie de Takayashu)



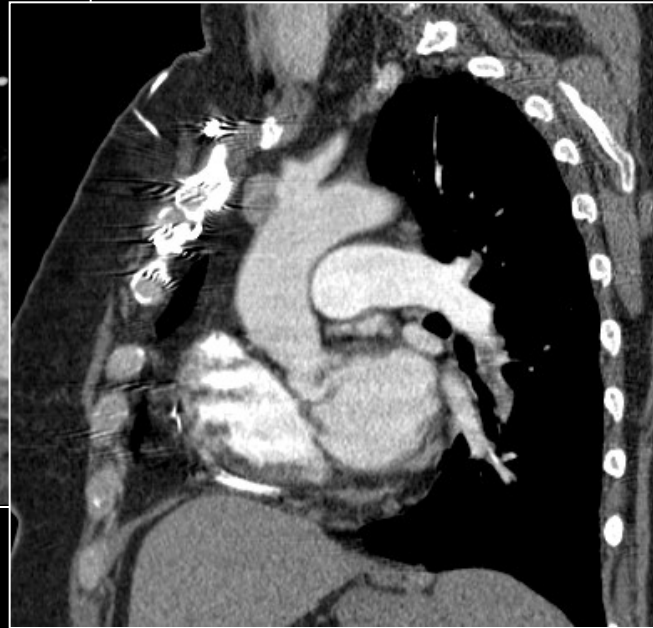
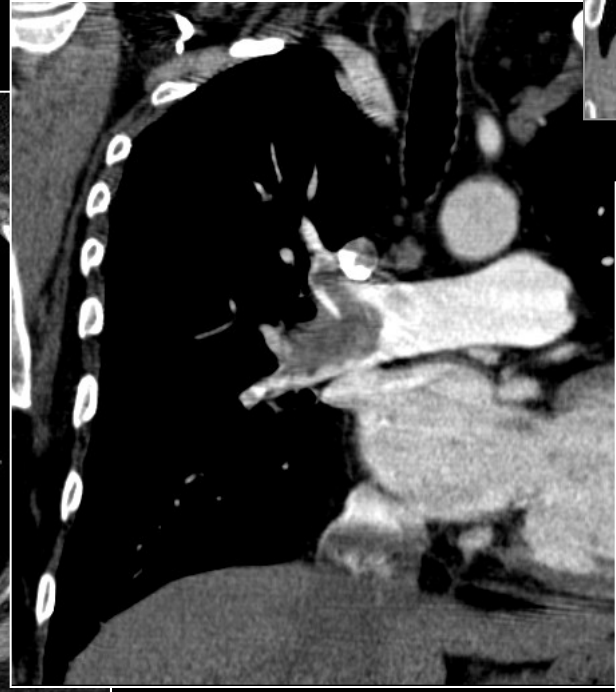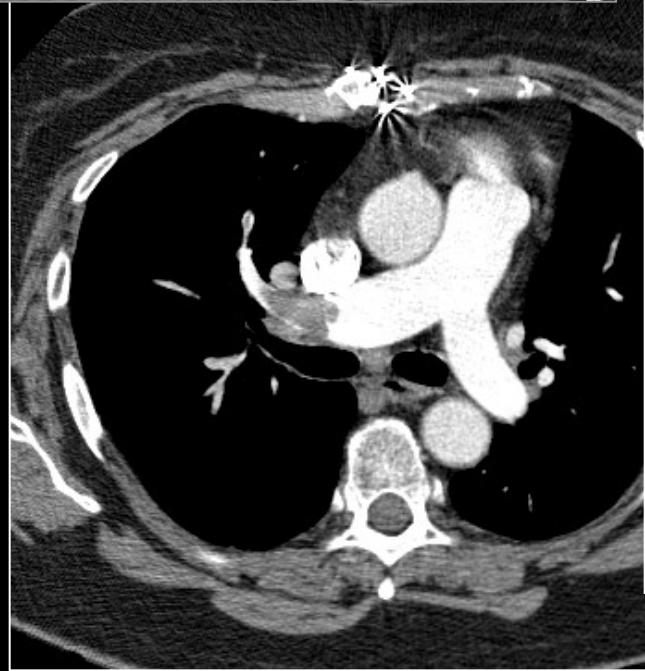

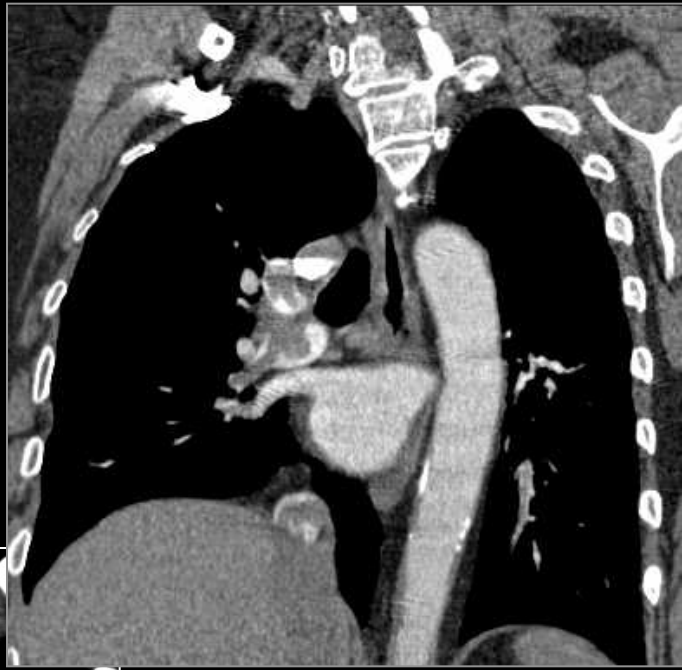
**Veine brachiocéphalique G  
aberrante**





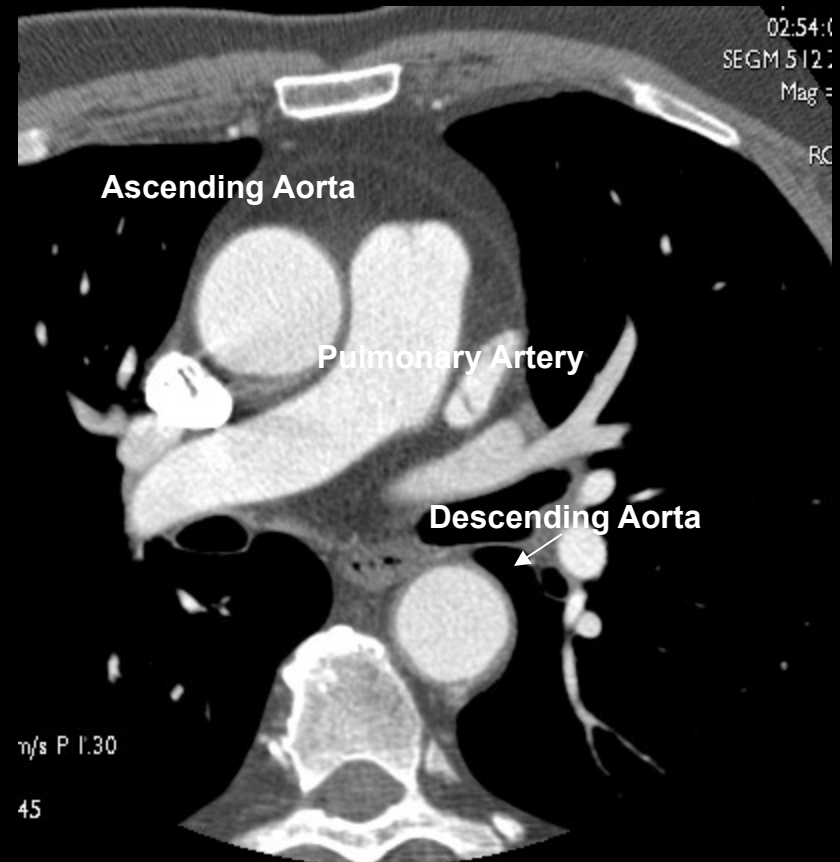
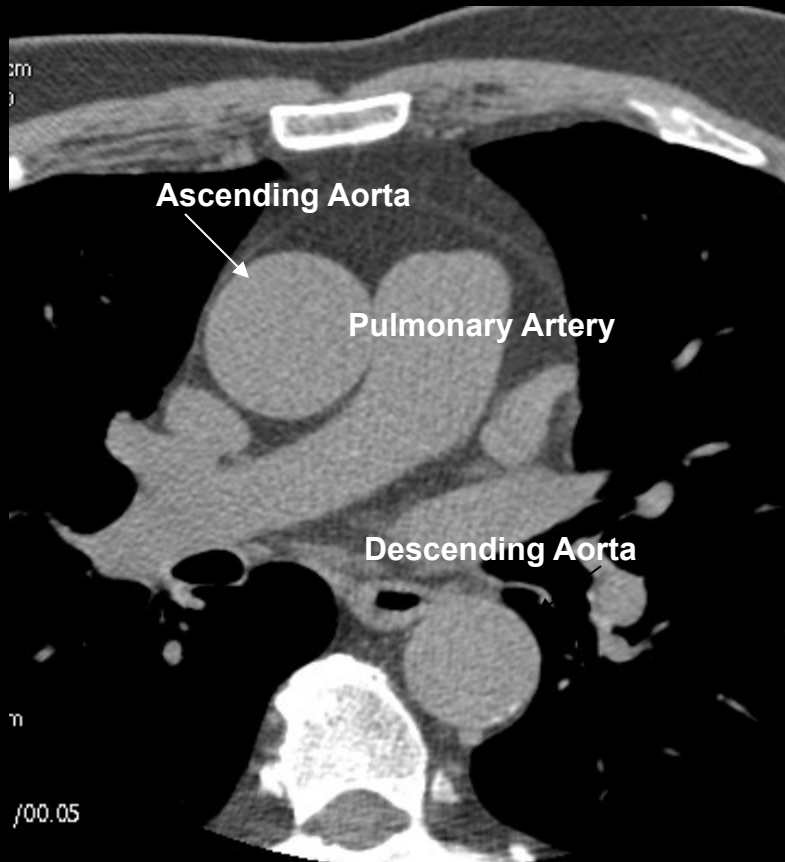
**Artères pulmonaires**  
**Embolie pulmonaire**



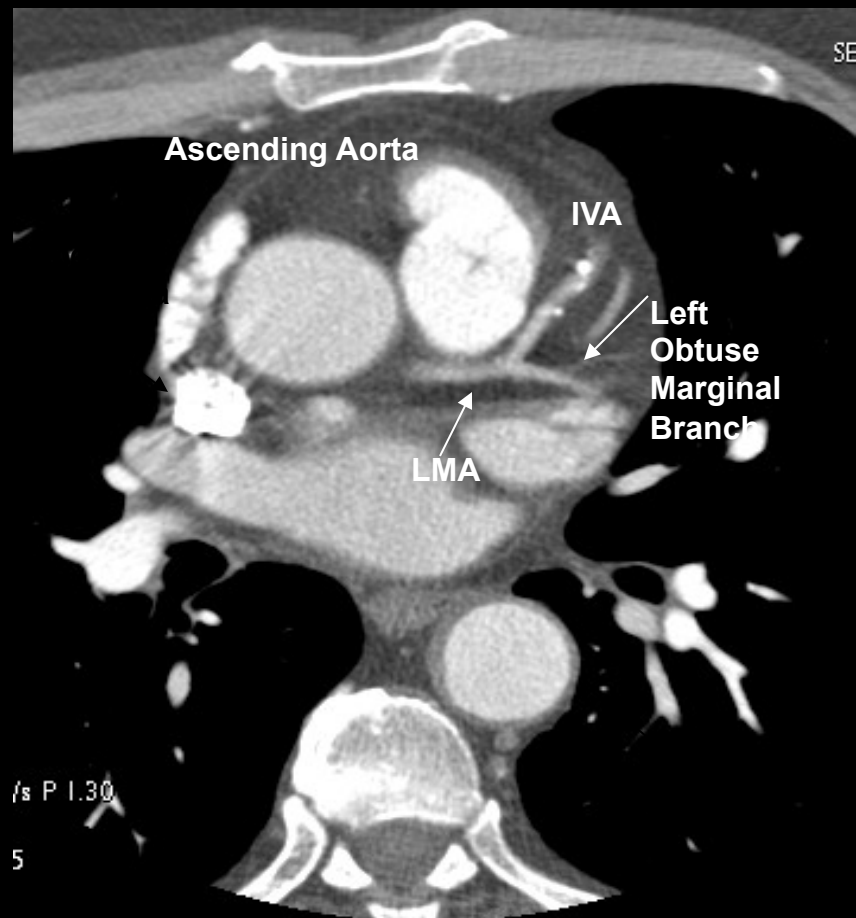
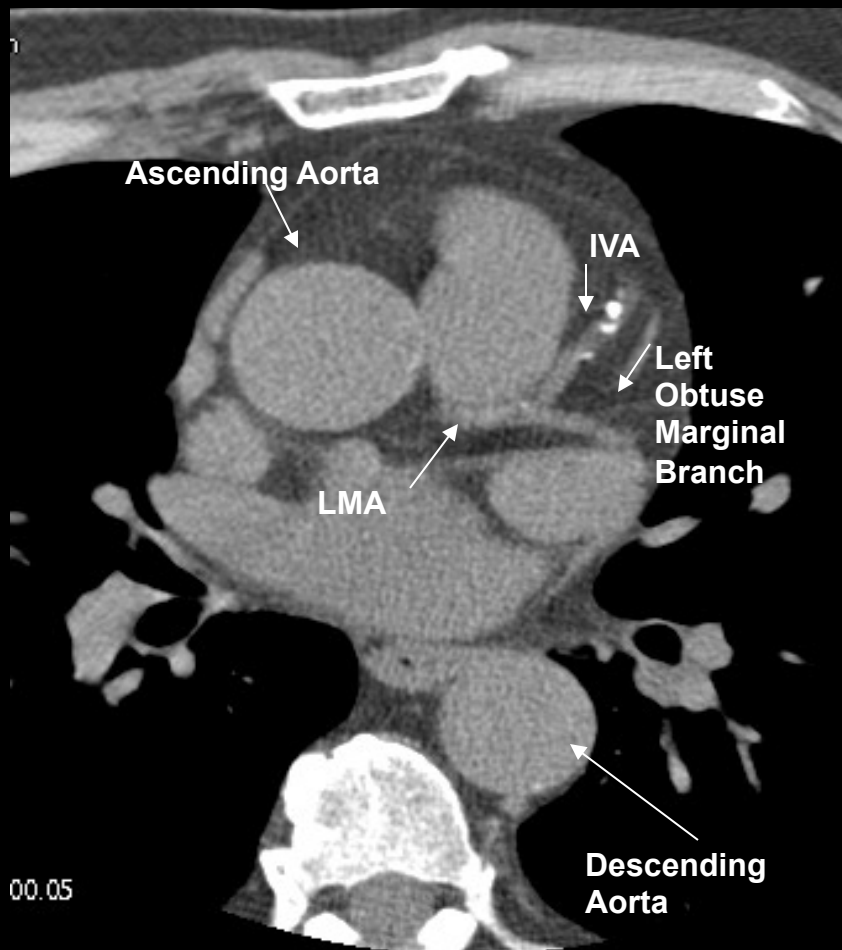


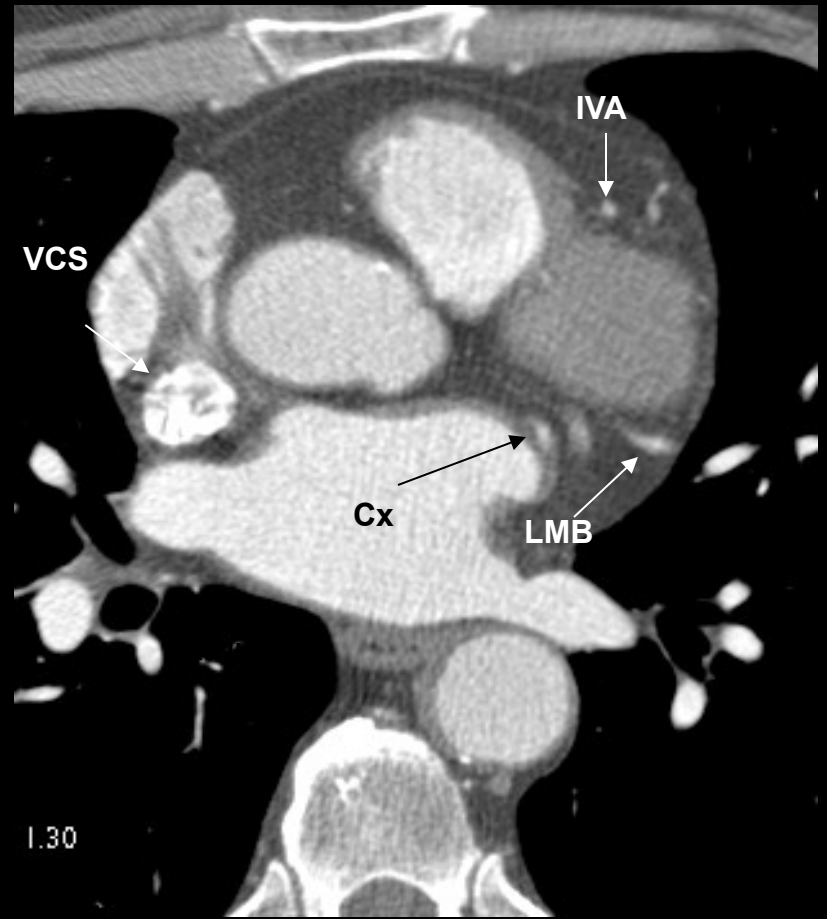
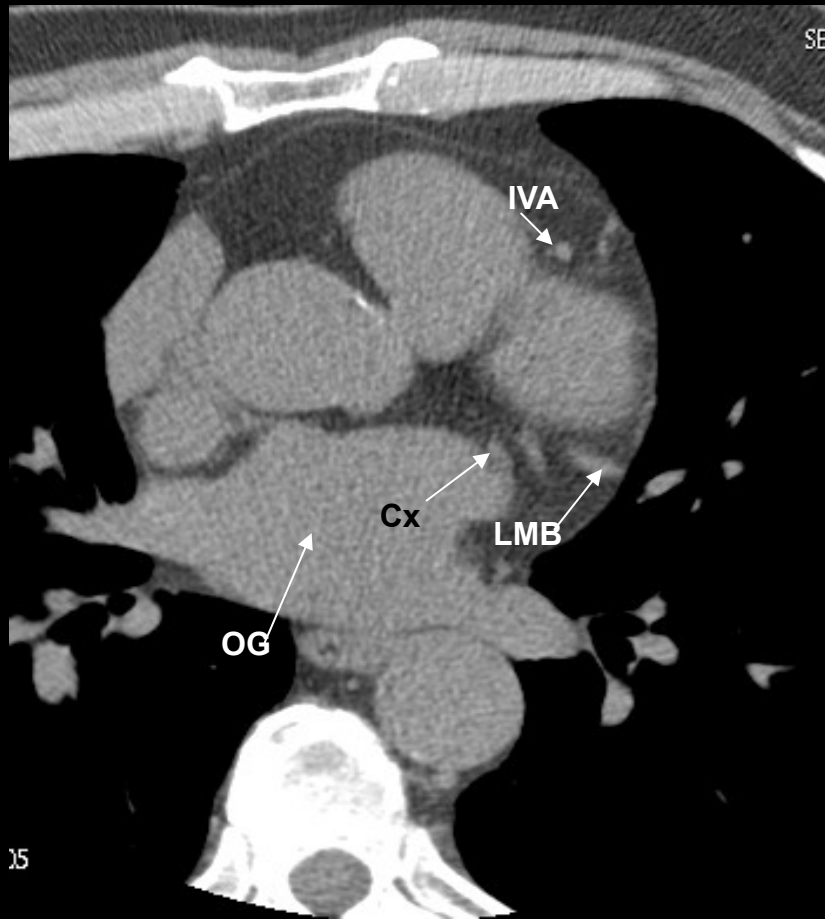
## 2/ RADIOANATOMIE DU MEDIASTIN

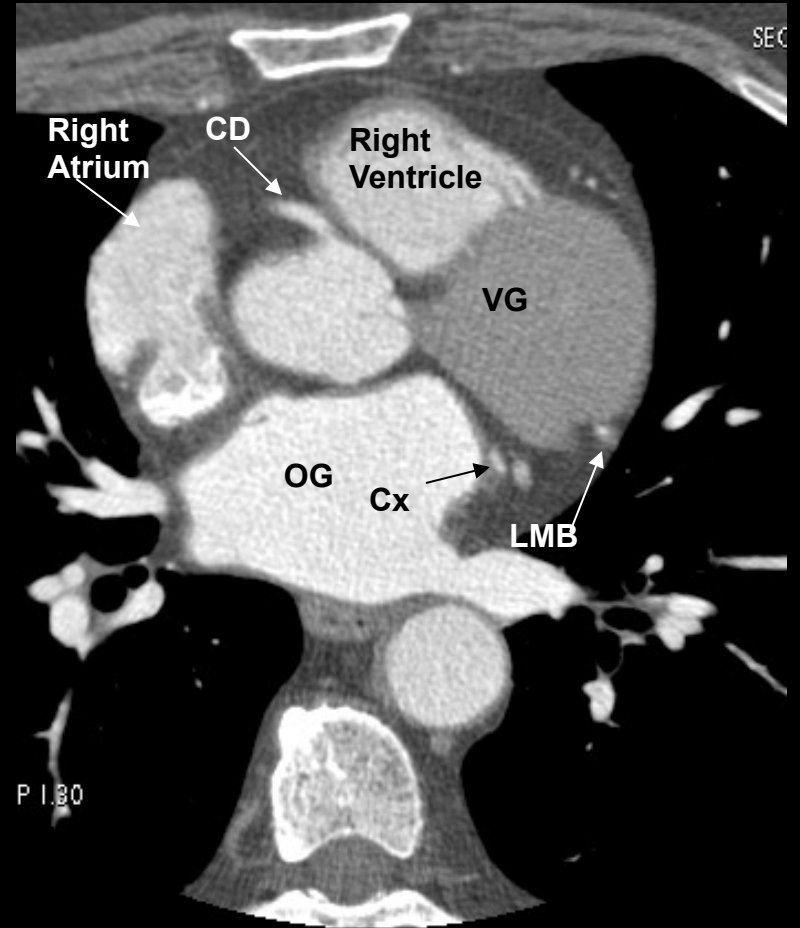
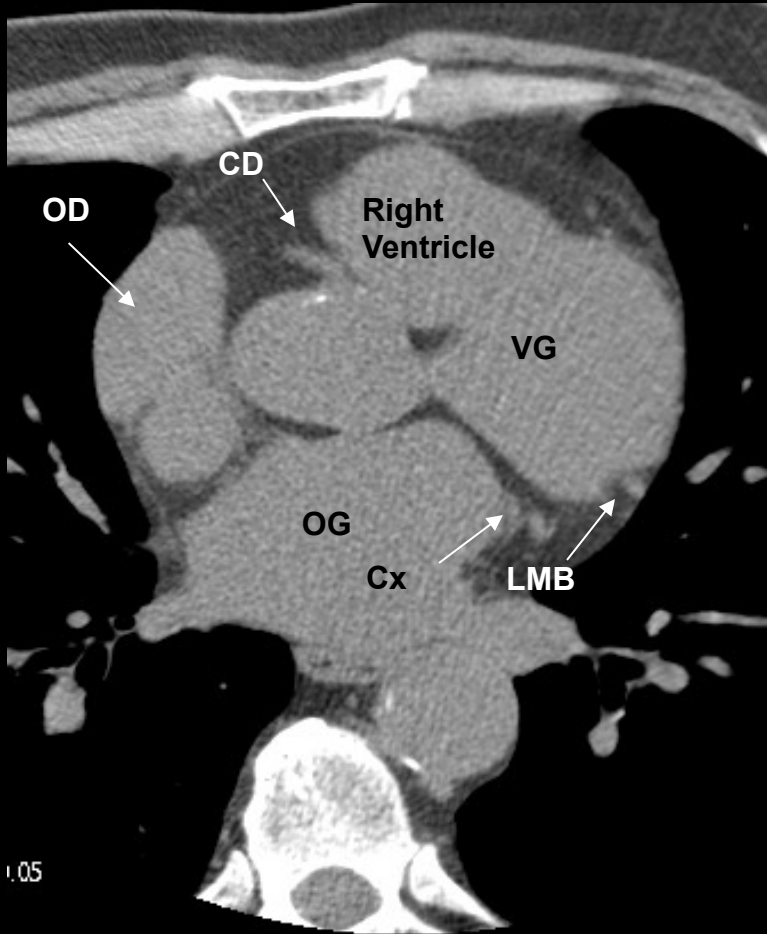
- **VAISSEAUX**
- **CŒUR**
- **ŒSOPHAGE**
- **CHAINES GANGLIONNAIRES**

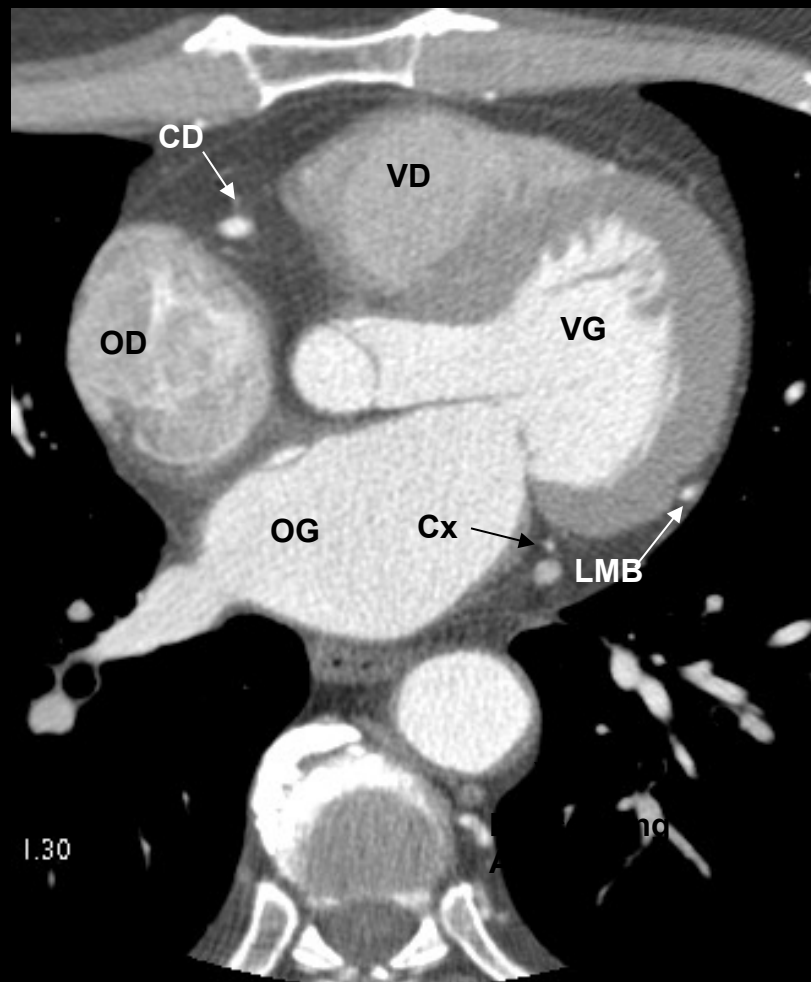
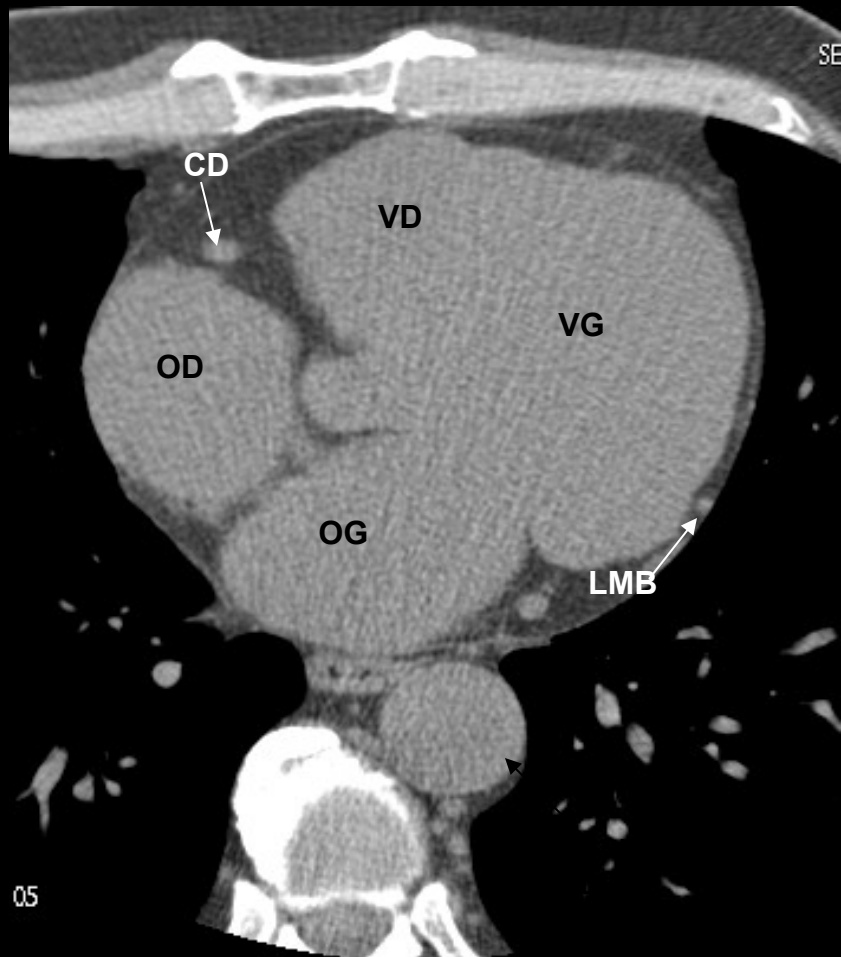


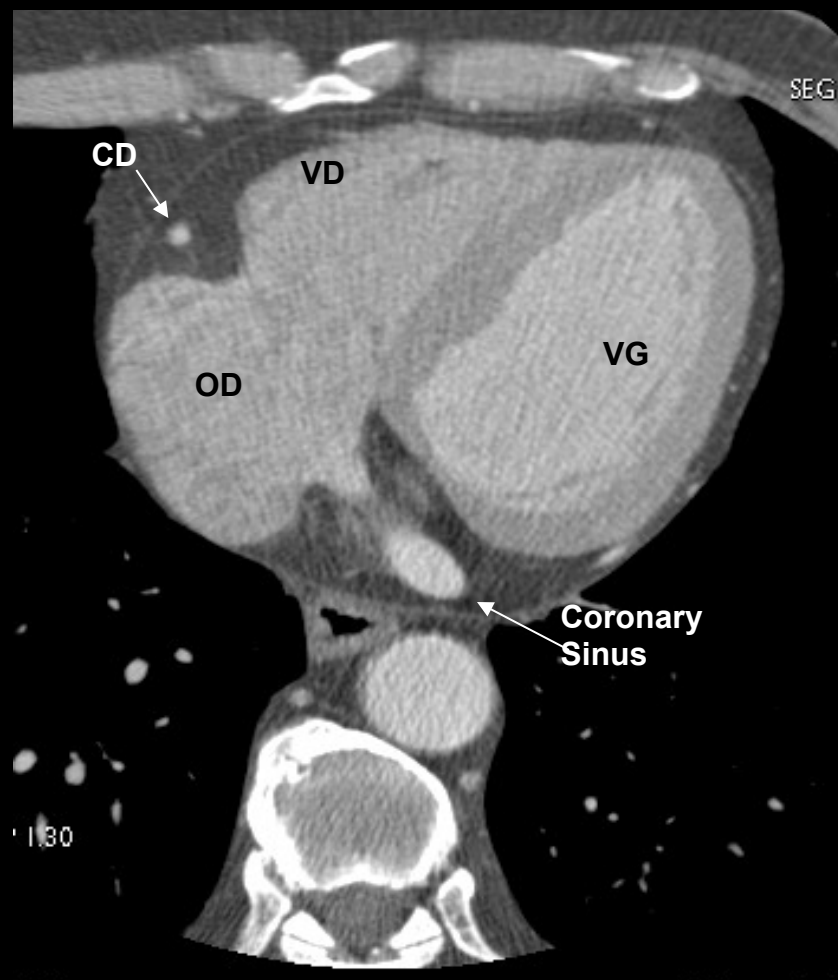
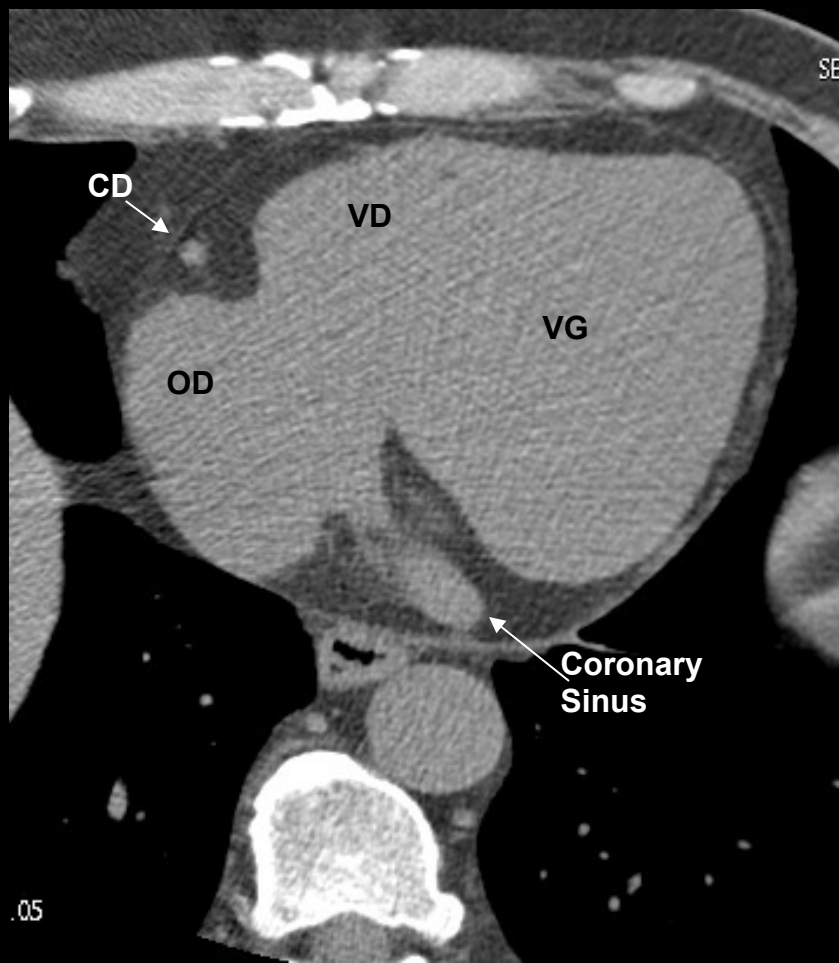**LMA - Left Main Artery (tronc commun)**  
**LAD - Left Anterior Descending Artery (inter ventriculaire IVA)**  
**LCX - Left Circumflex Artery (circonflexe)**  
**LMB - Left Obtuse Marginal Branch (branche marginale gauche)**  
**RCA - Right Coronary Artery (coronaire droite)**  
**PDA - Posterior Descending Artery (rétro ventriculaire postérieure)**

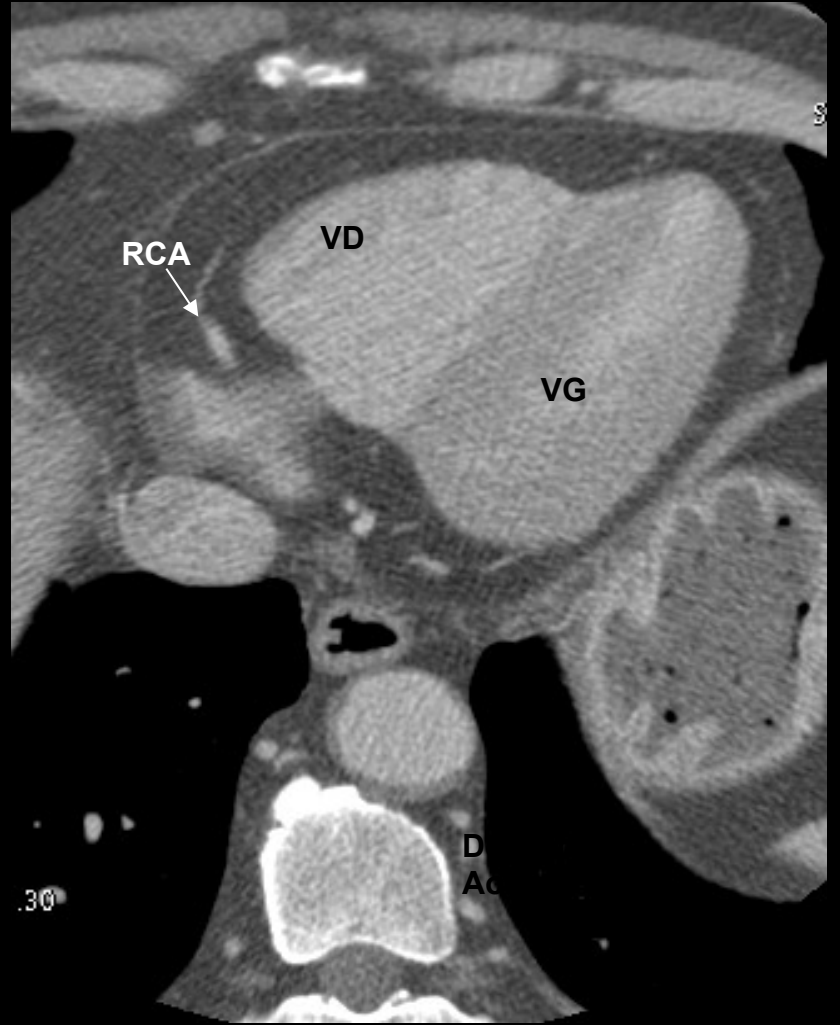
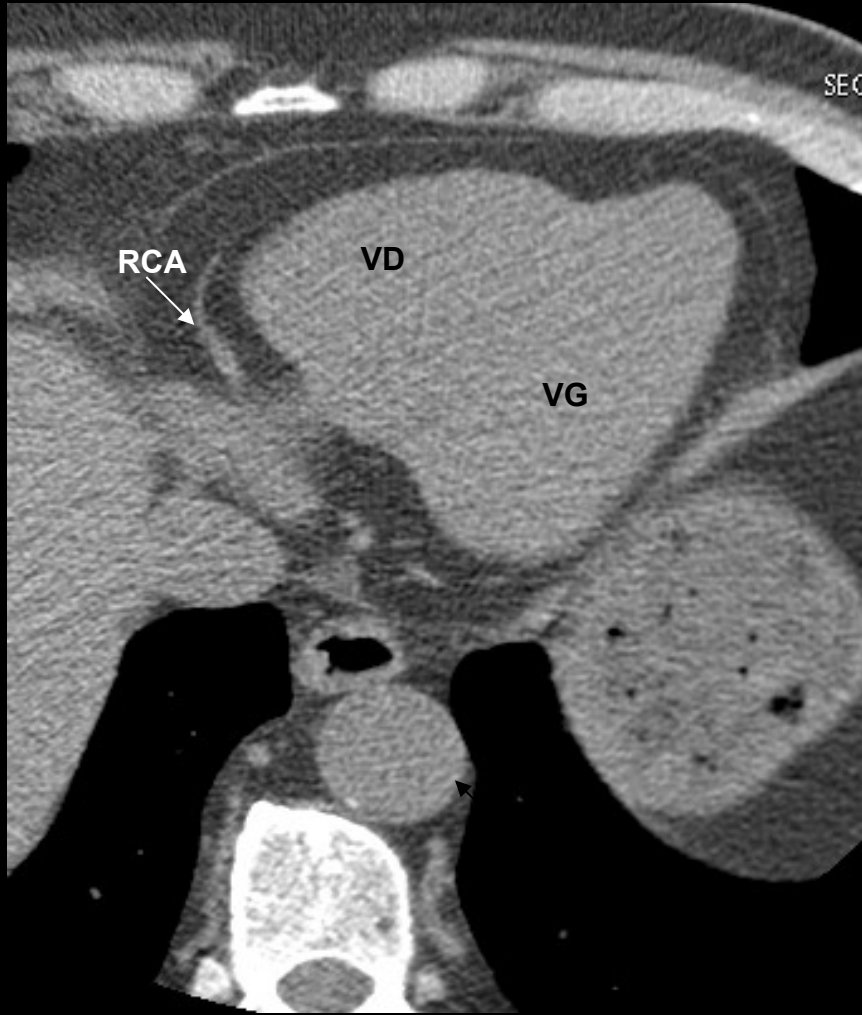


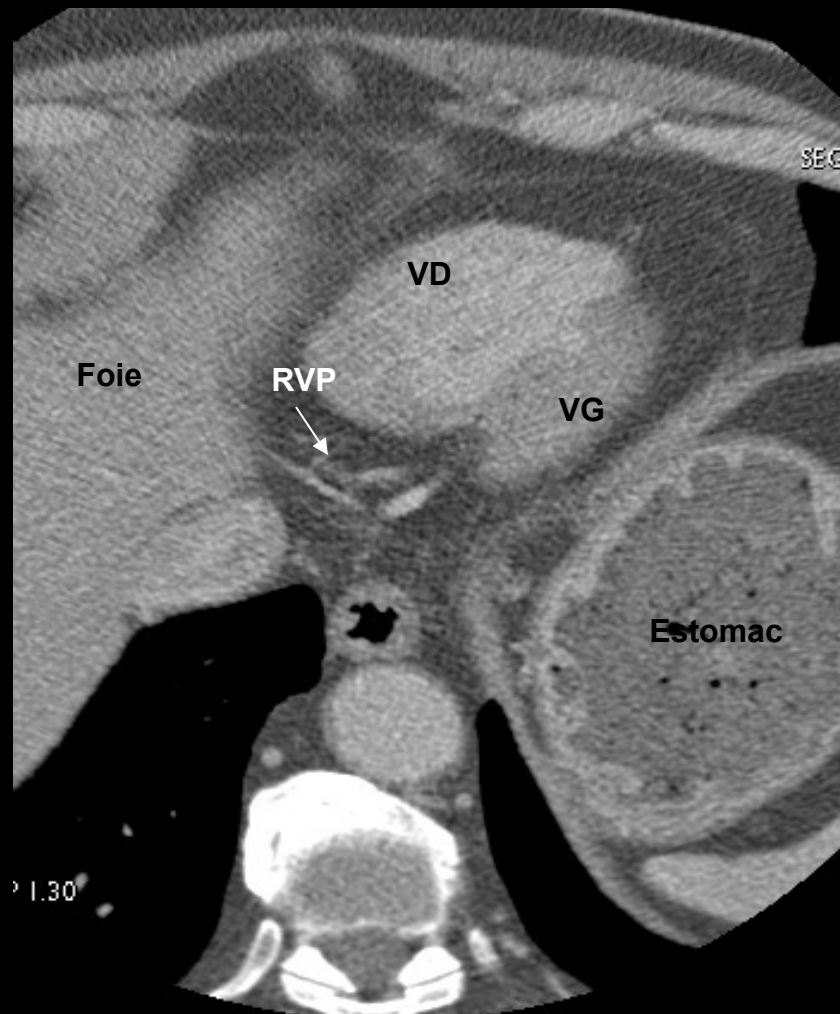
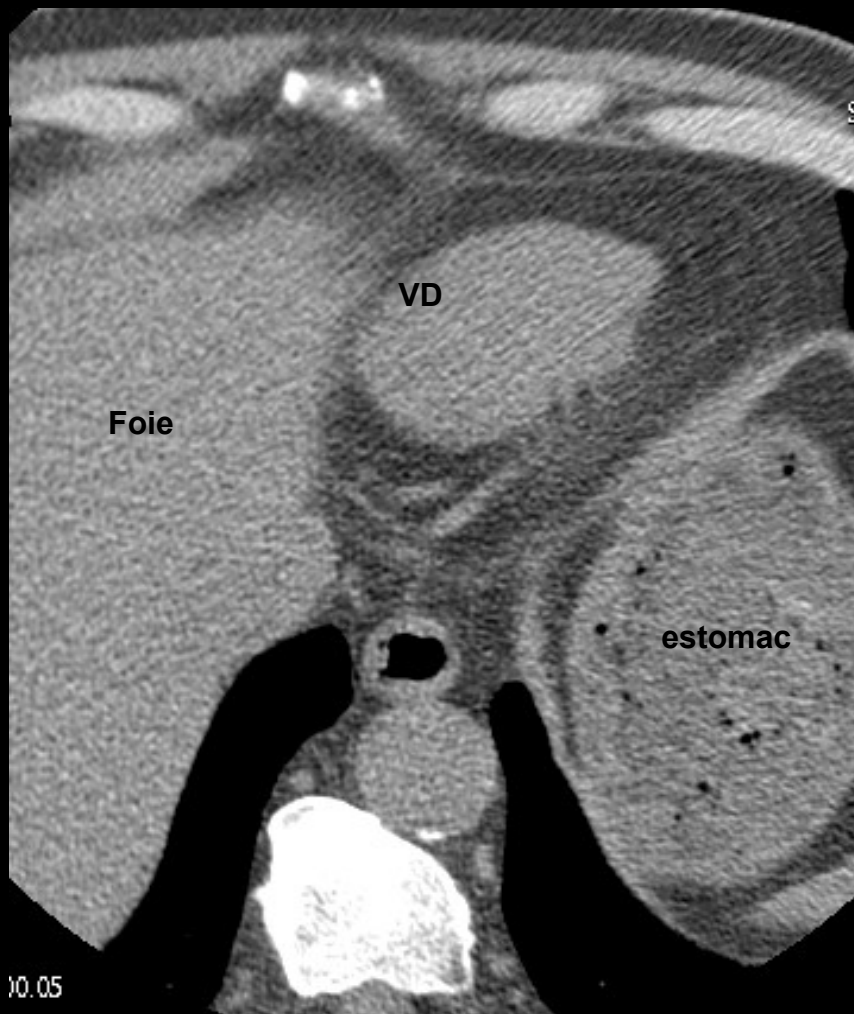



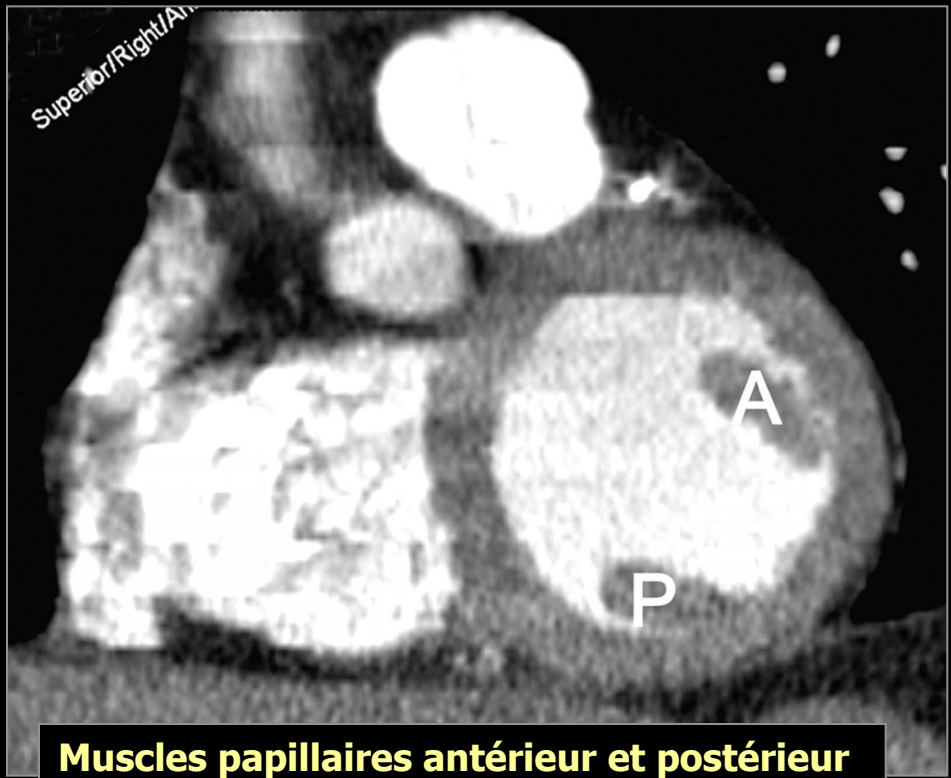

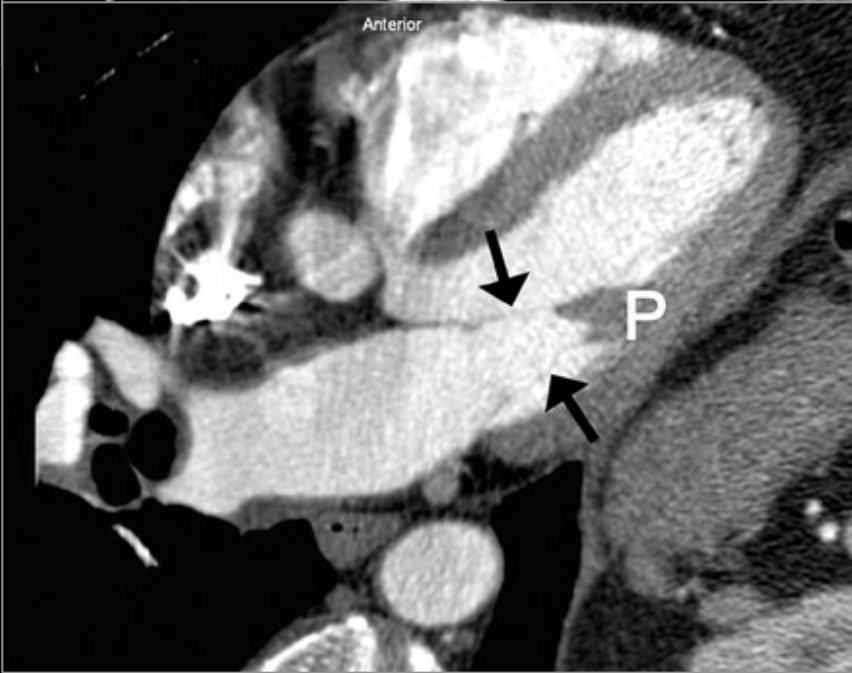
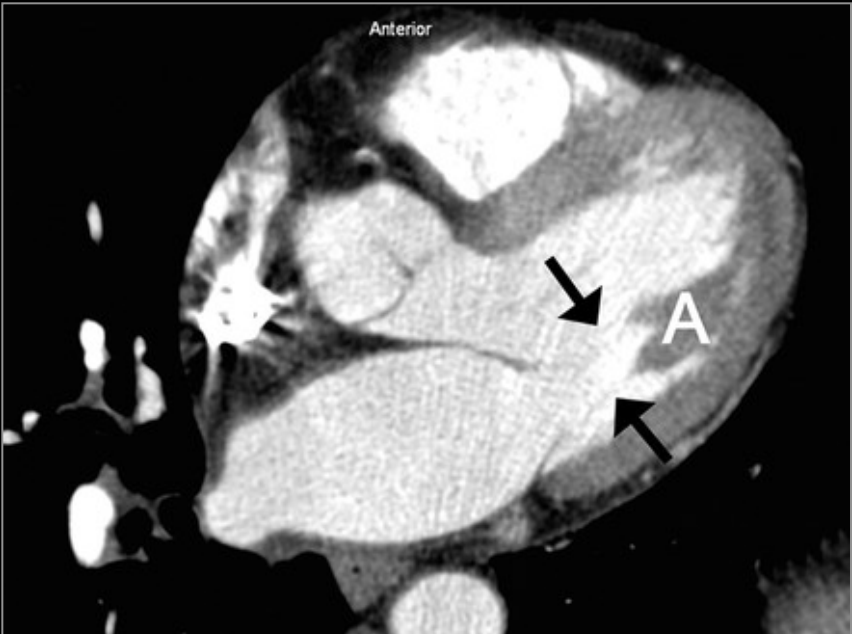

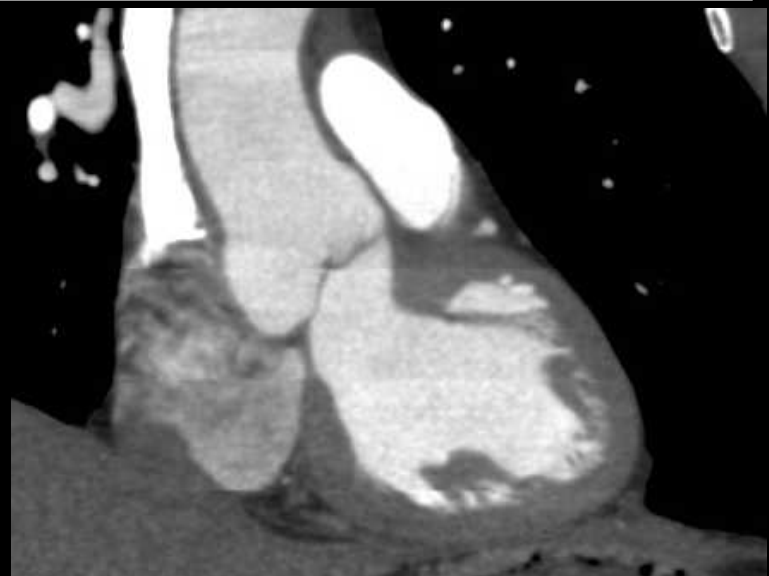




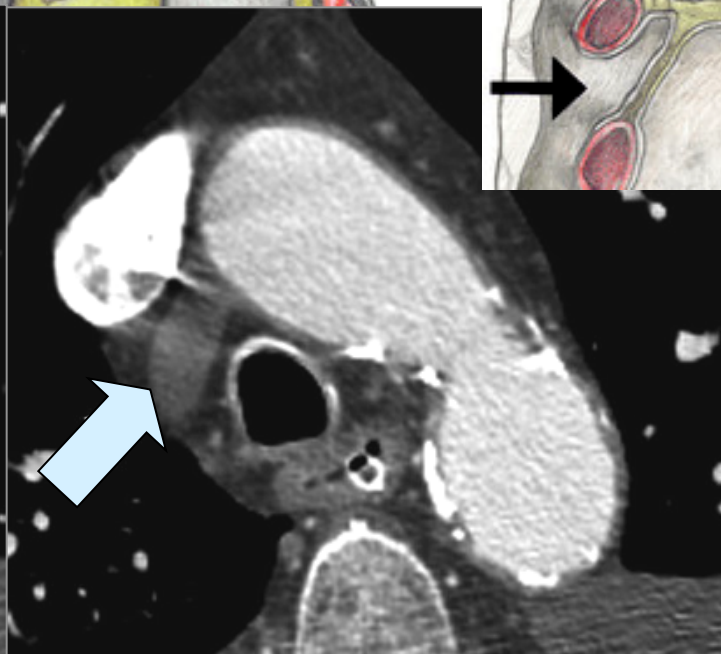
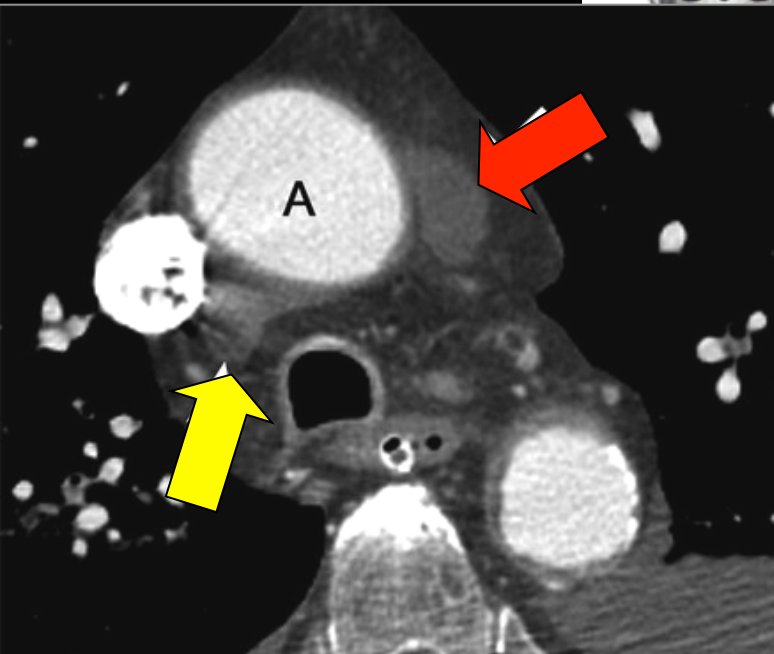
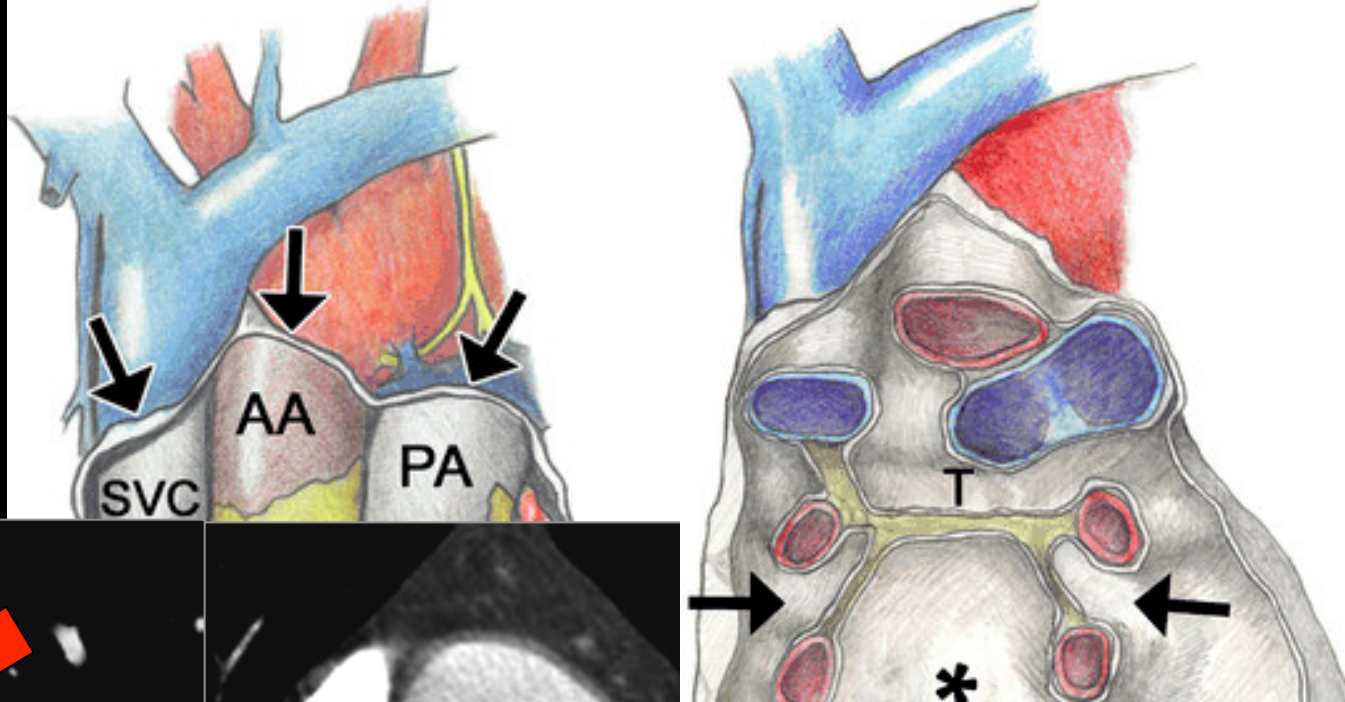
# Ventricules



**Muscles papillaires antérieur et postérieur  
Et cordages mitraux**



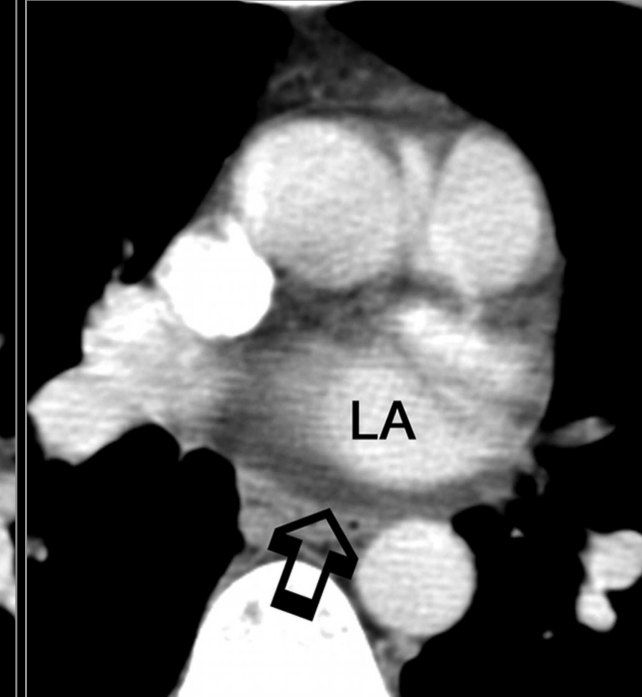
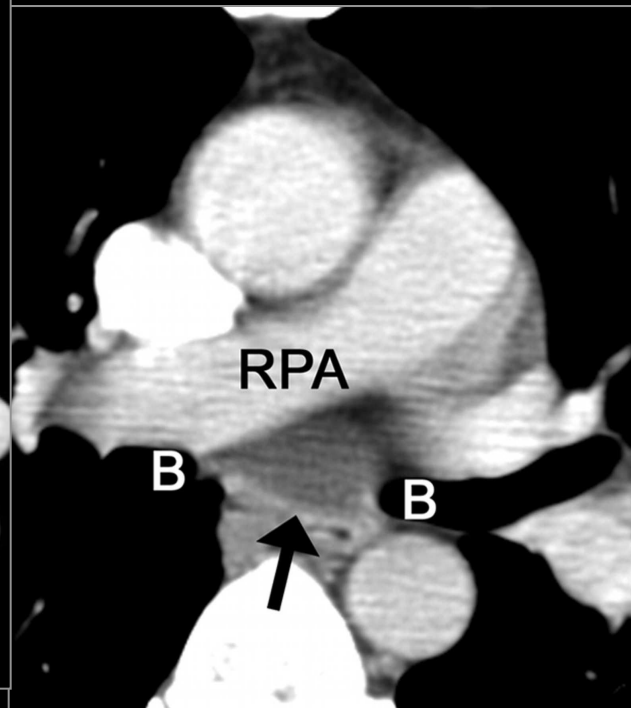
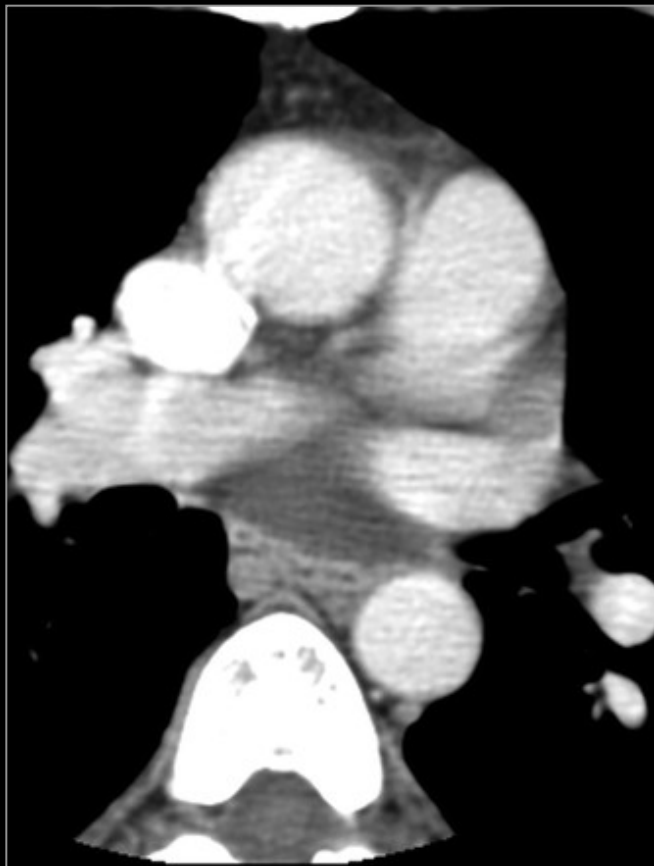
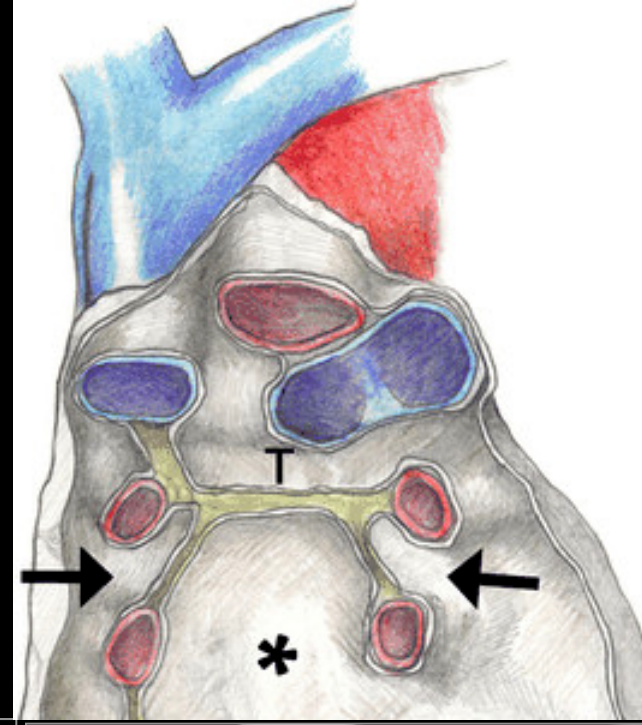
## Recessus péricardiques

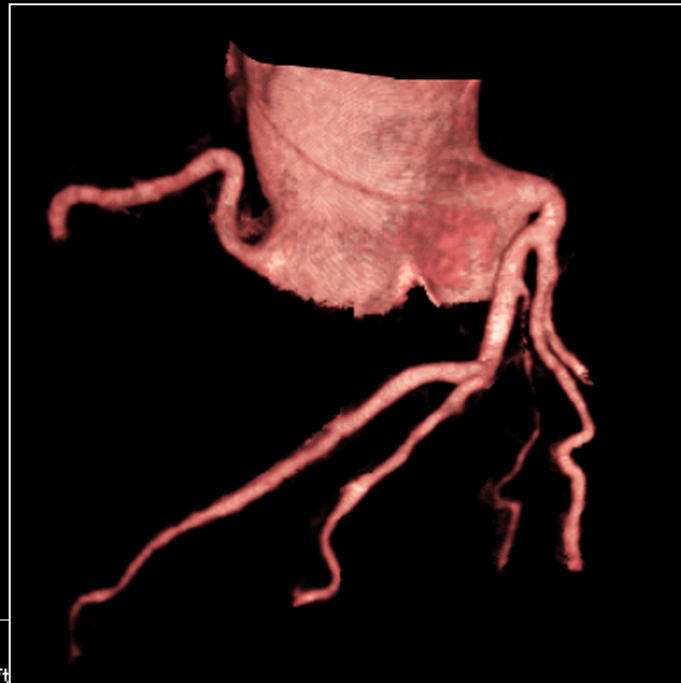
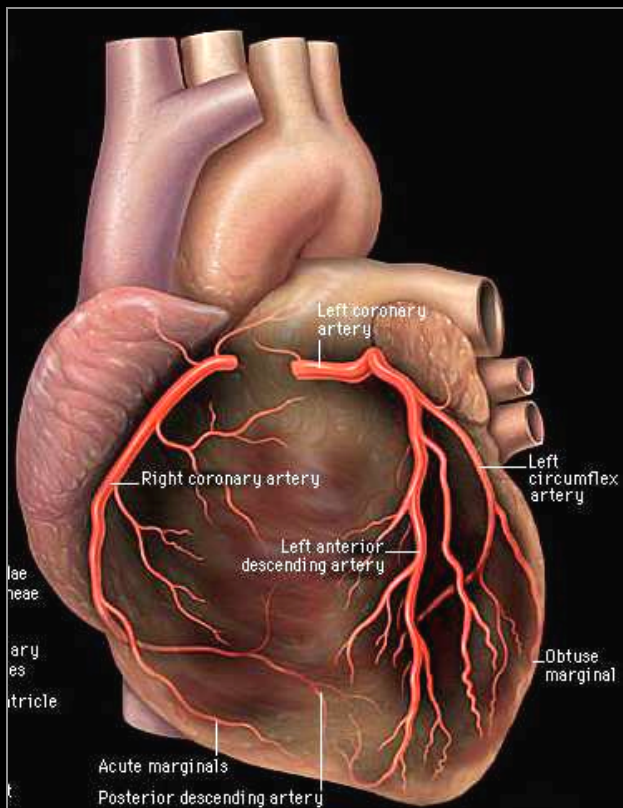


**Recessus péricardique aortique supérieur**  
provient du sinus transverse  
s' étend à la face antérieure de l' aorte ascendante avec des portions  
**antérieure, postérieure** et latérale droite

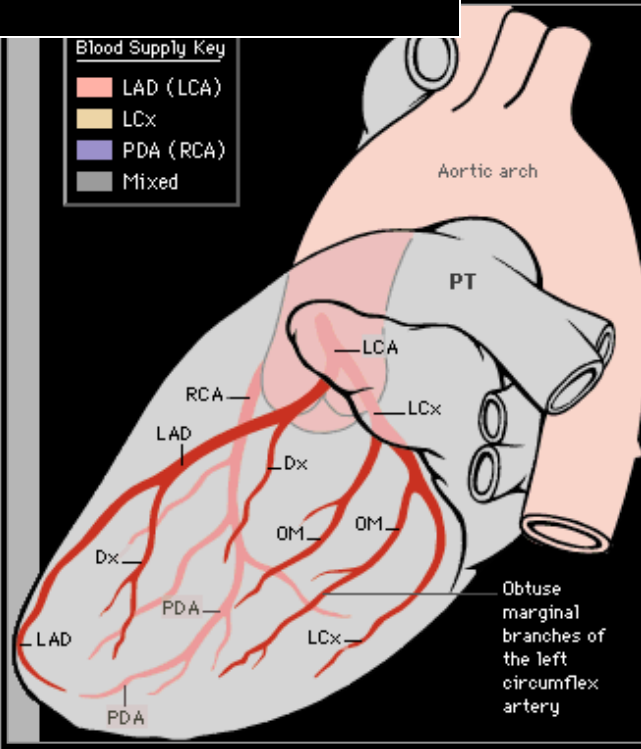
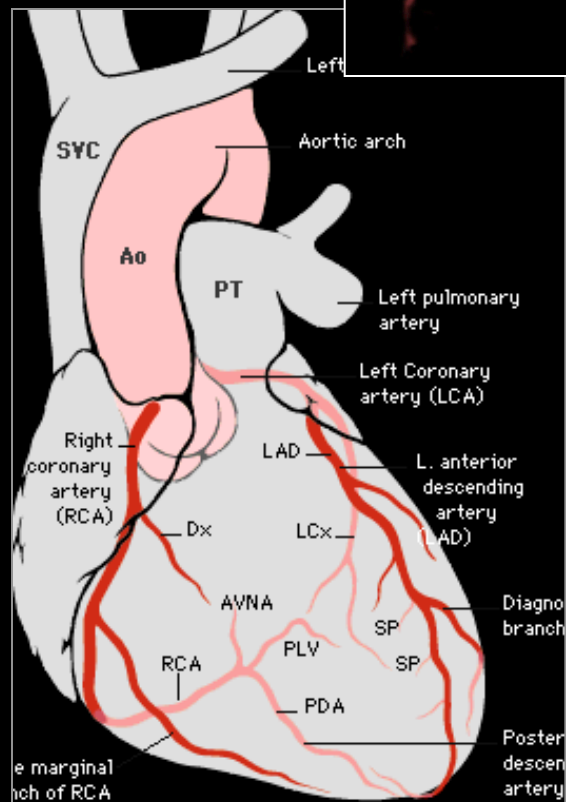
## Recessus péricardique postérieur

Extension supérieure du sinus oblique  
En arrière de l' AP droite sous carinaire



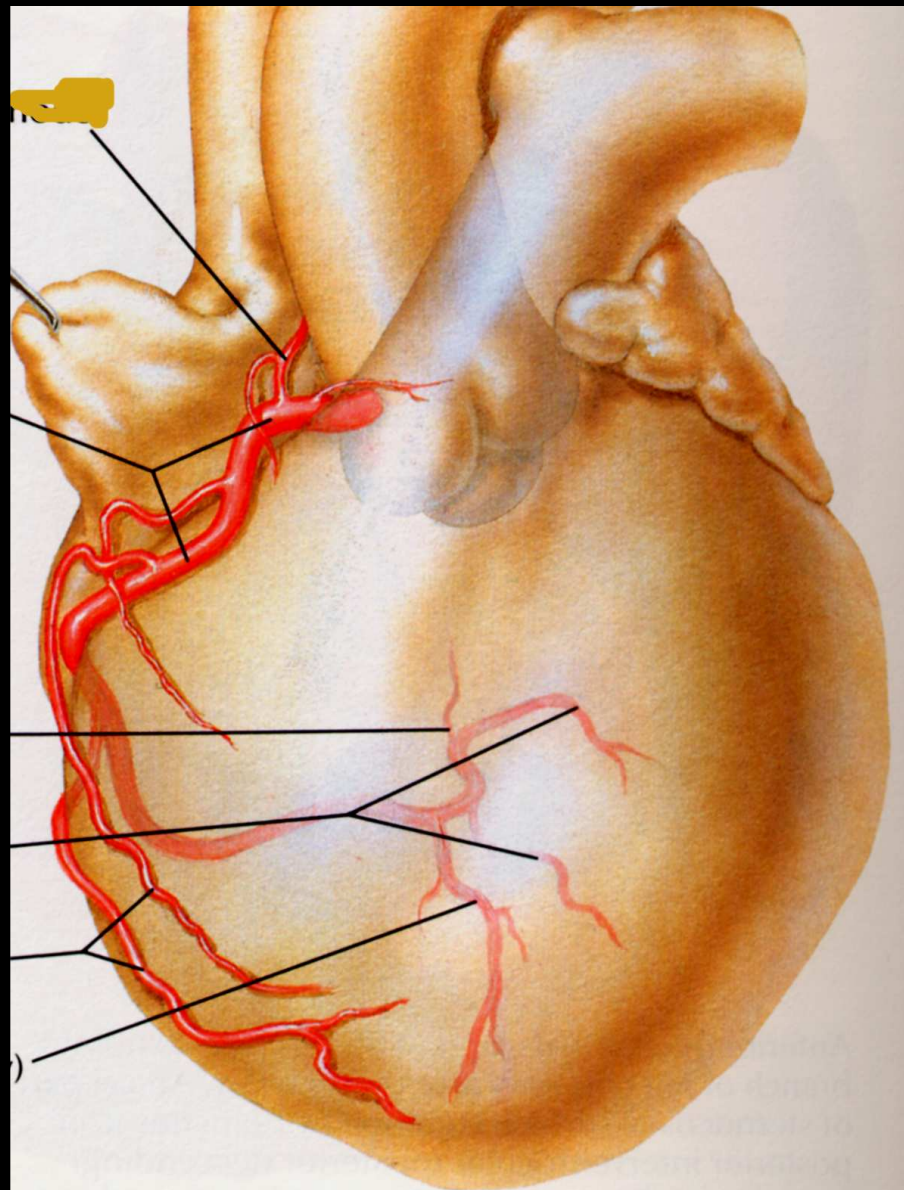
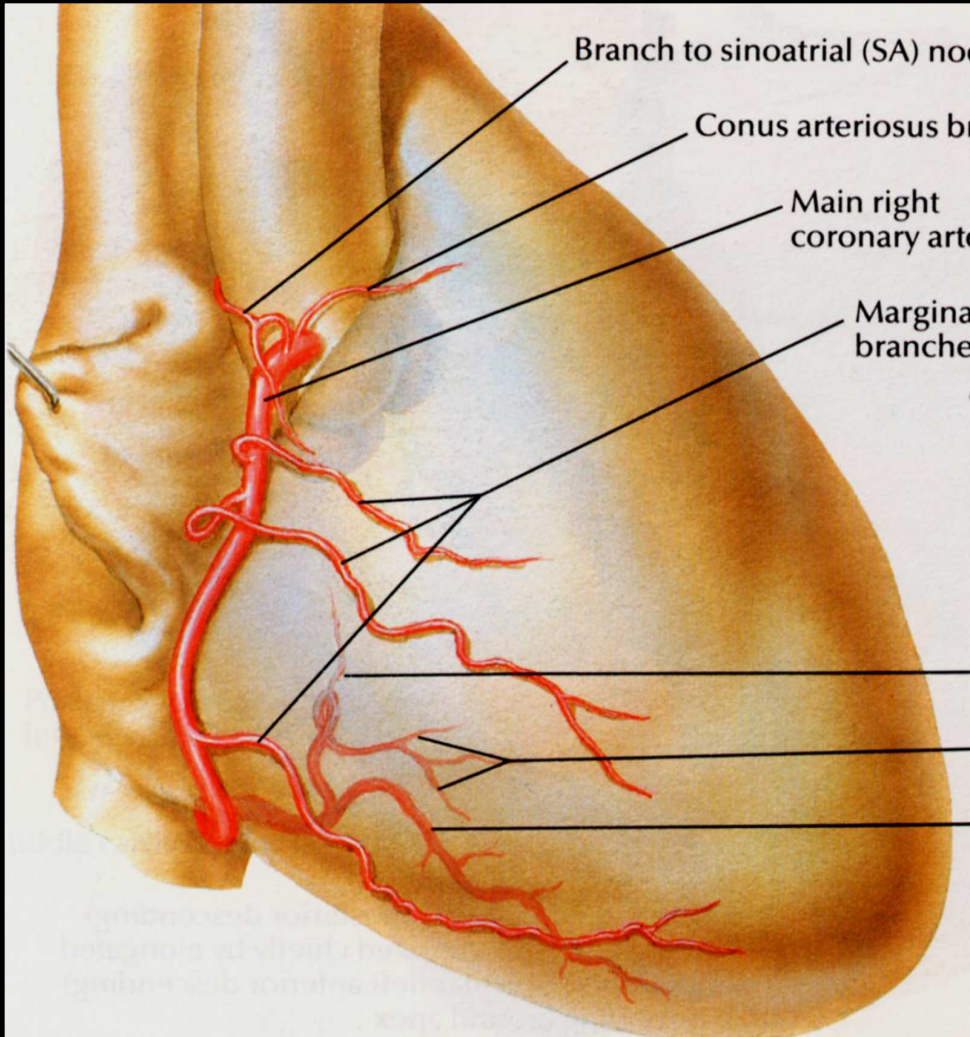


# Étude des coronaires

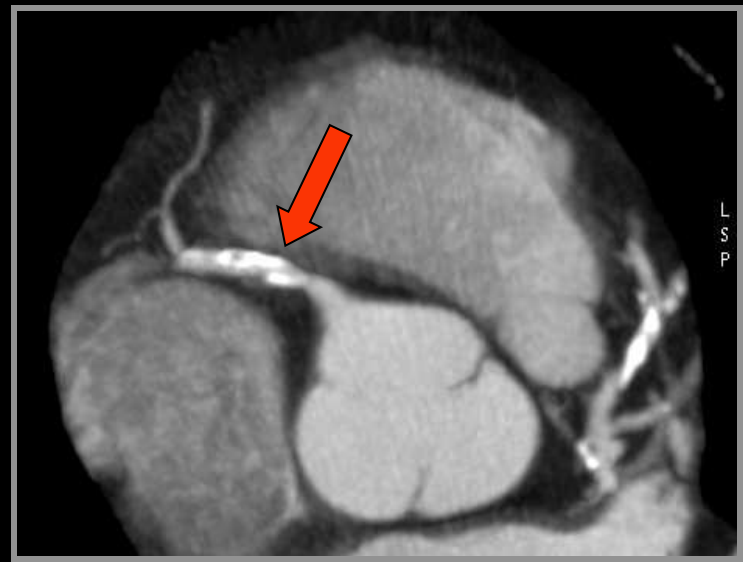
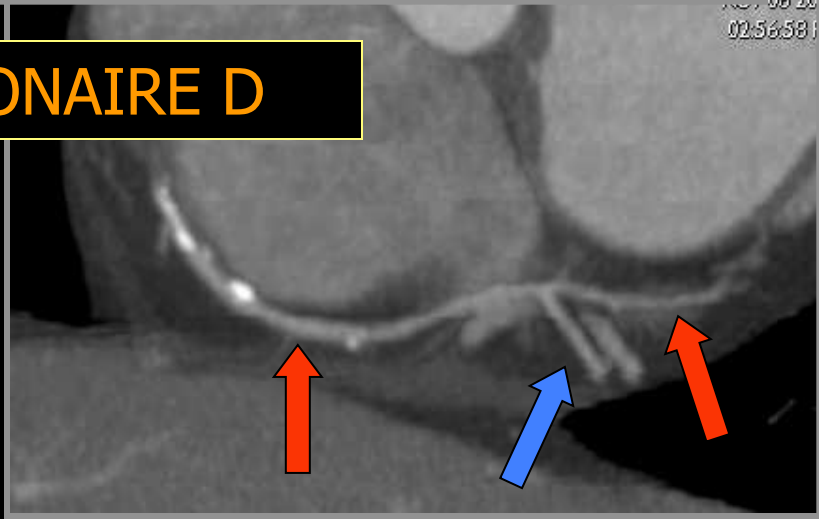
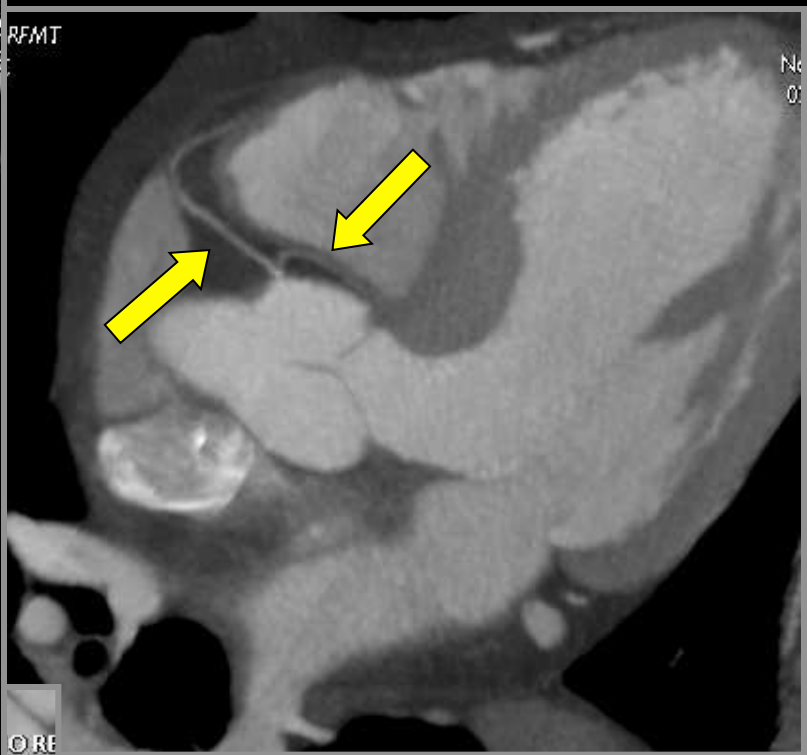
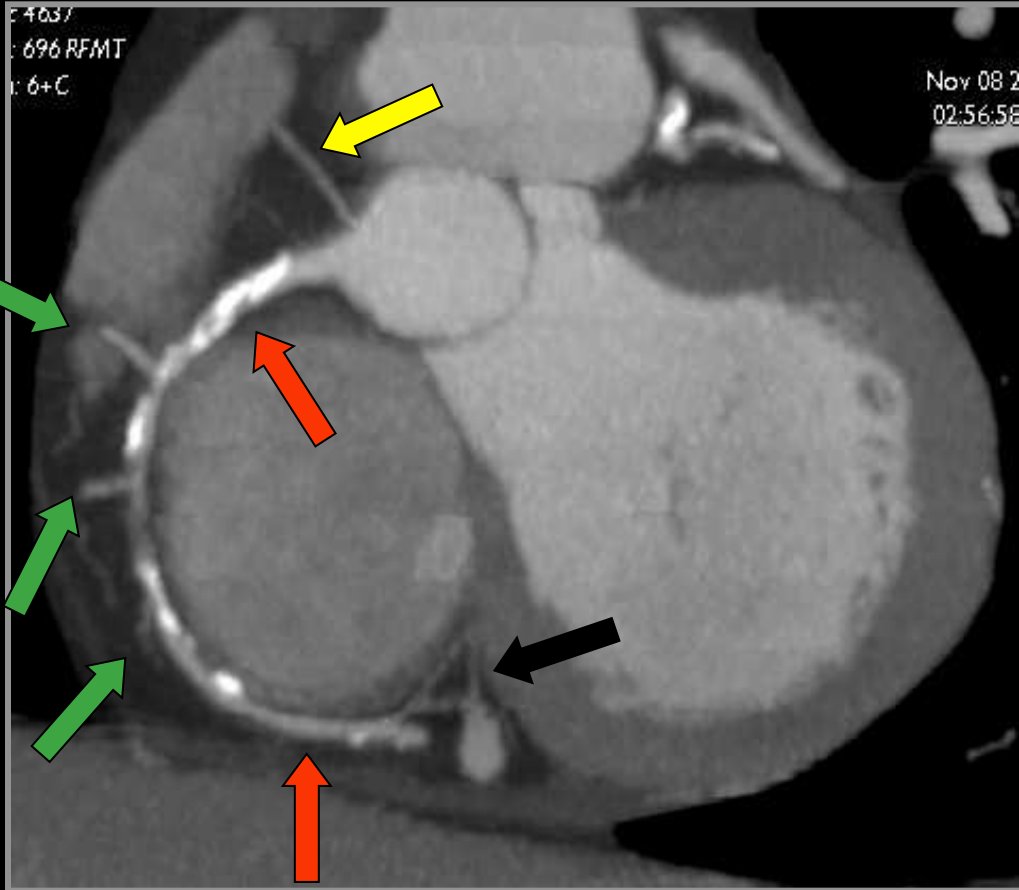


**Blood Supply Key**

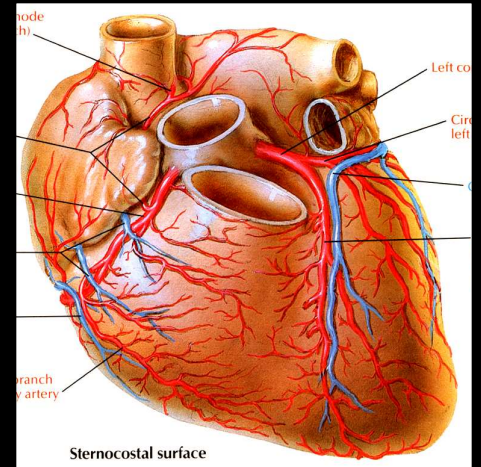
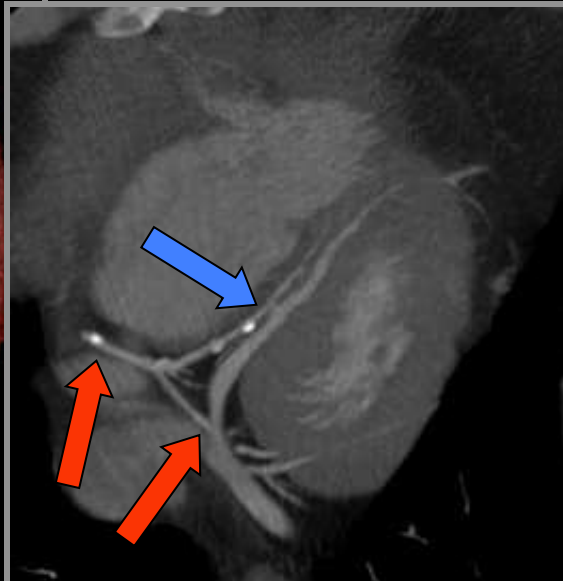
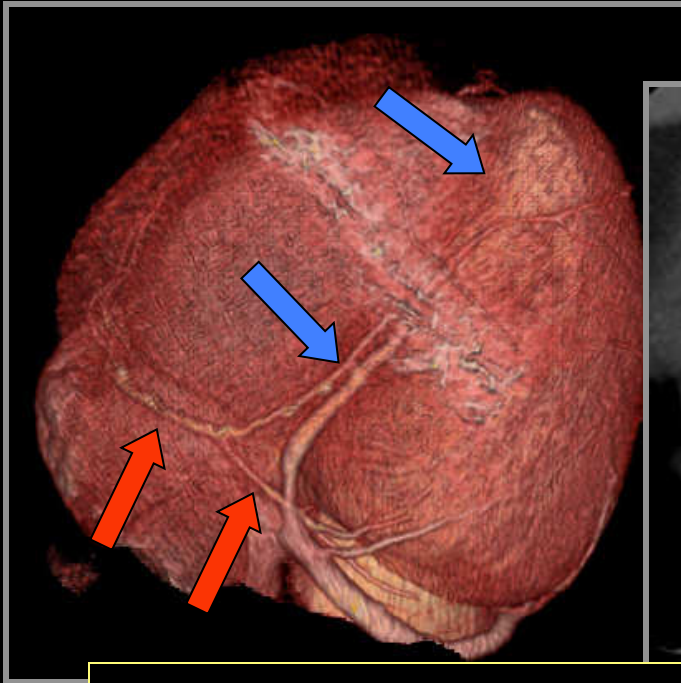
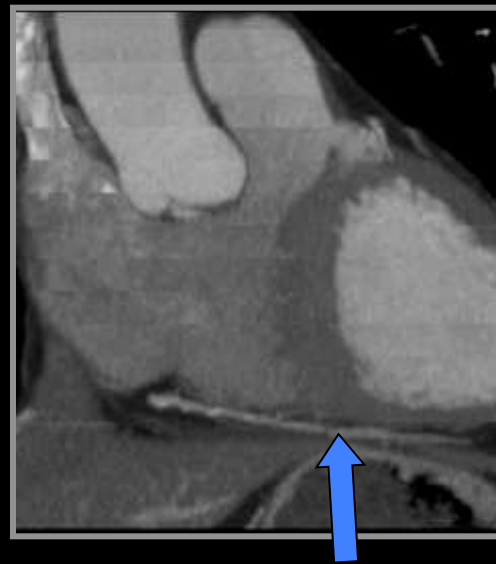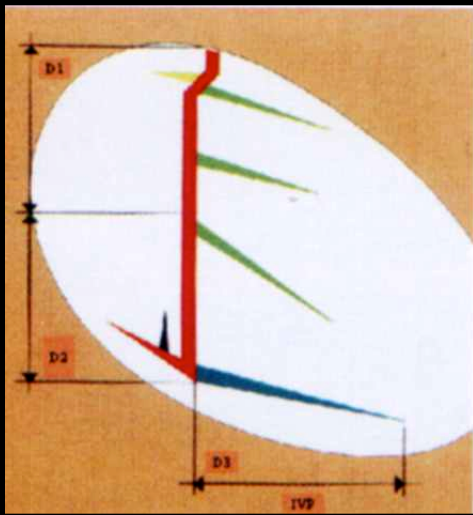
	LAD (LCA)
	LCx
	PDA (RCA)
	Mixed



**Coronaire droite**

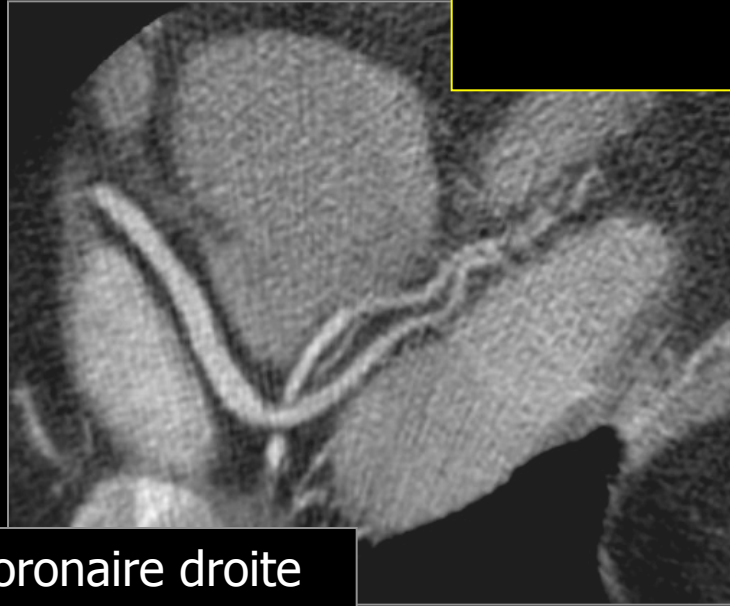
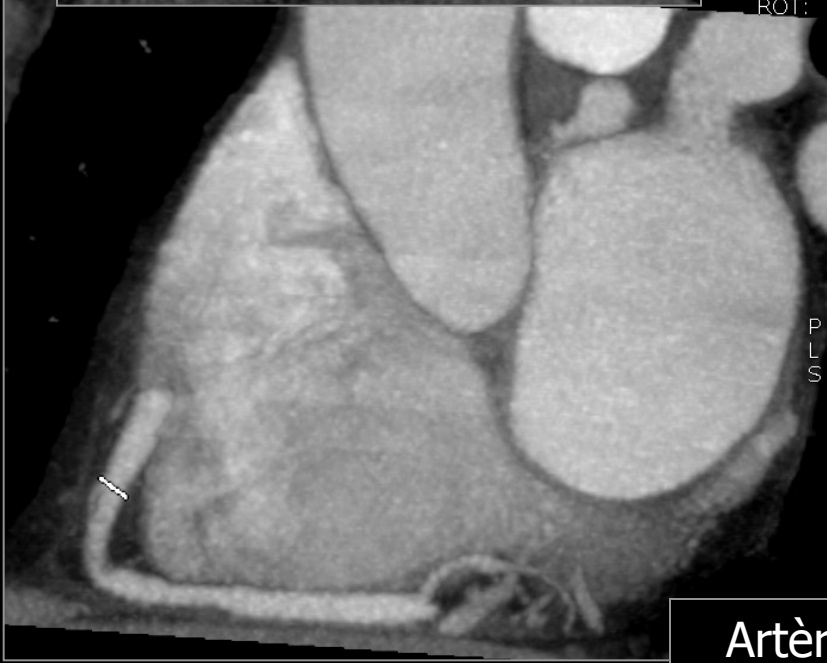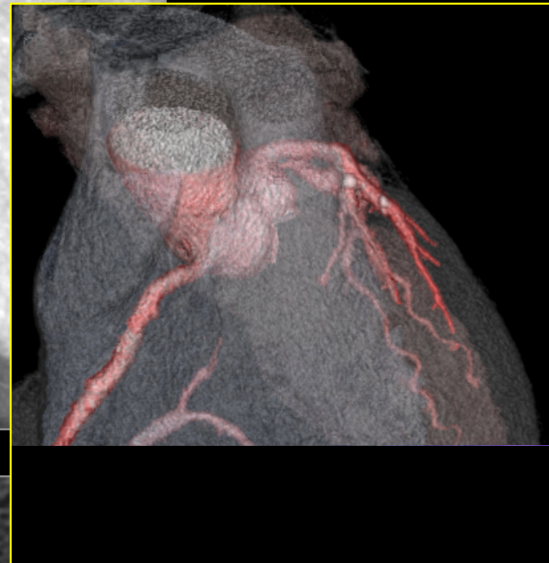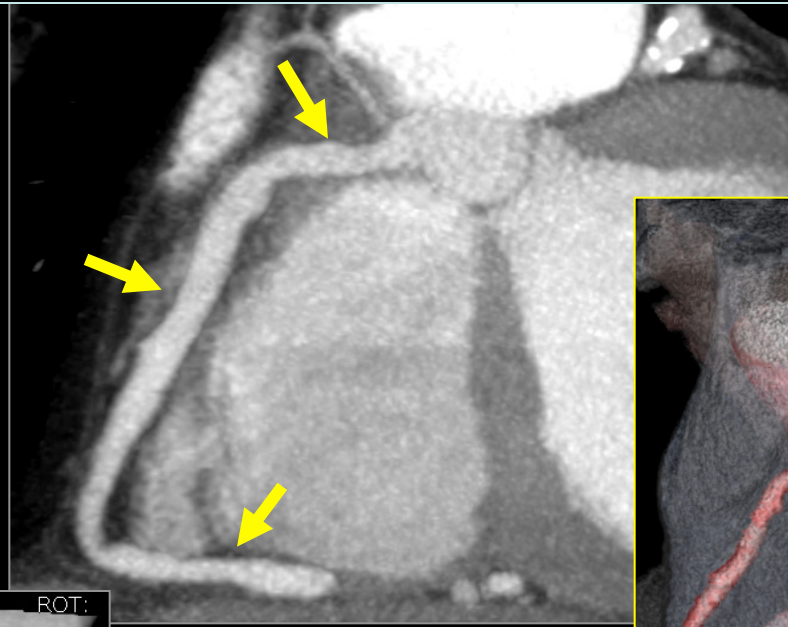


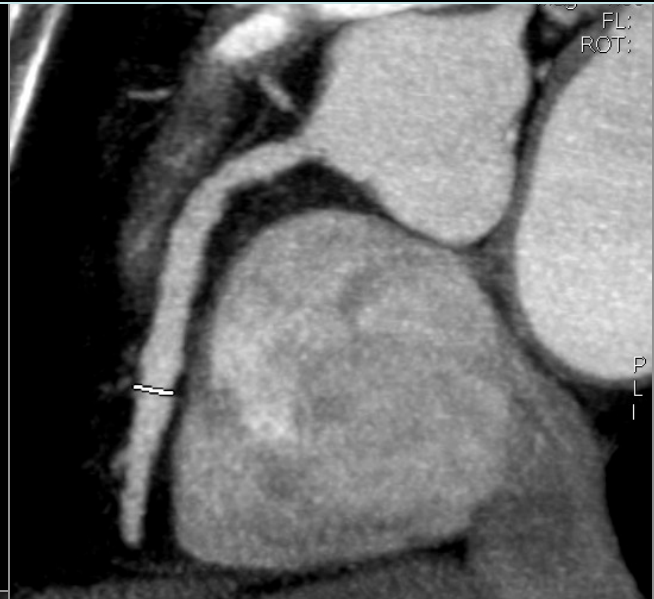**CORONAIRE D**

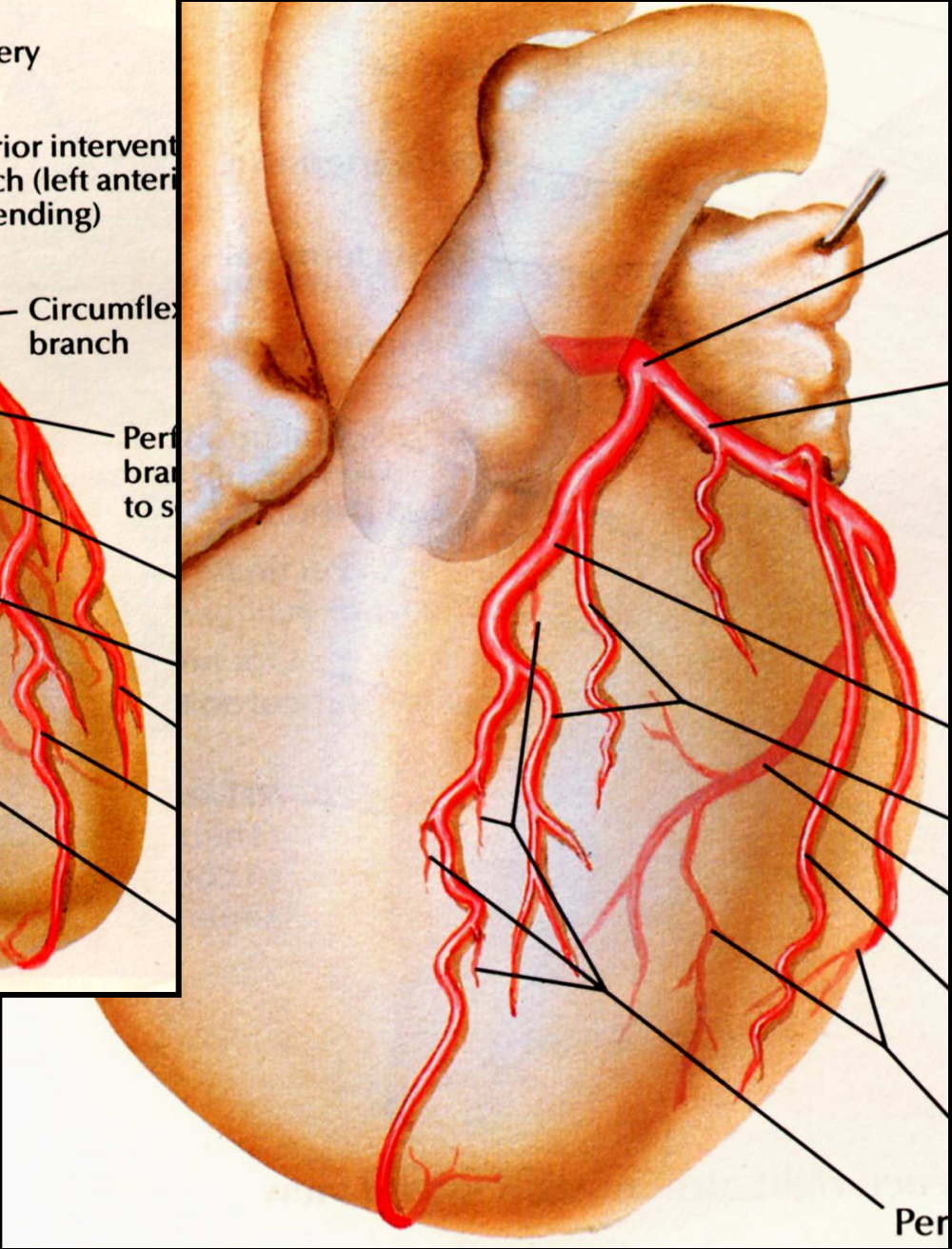
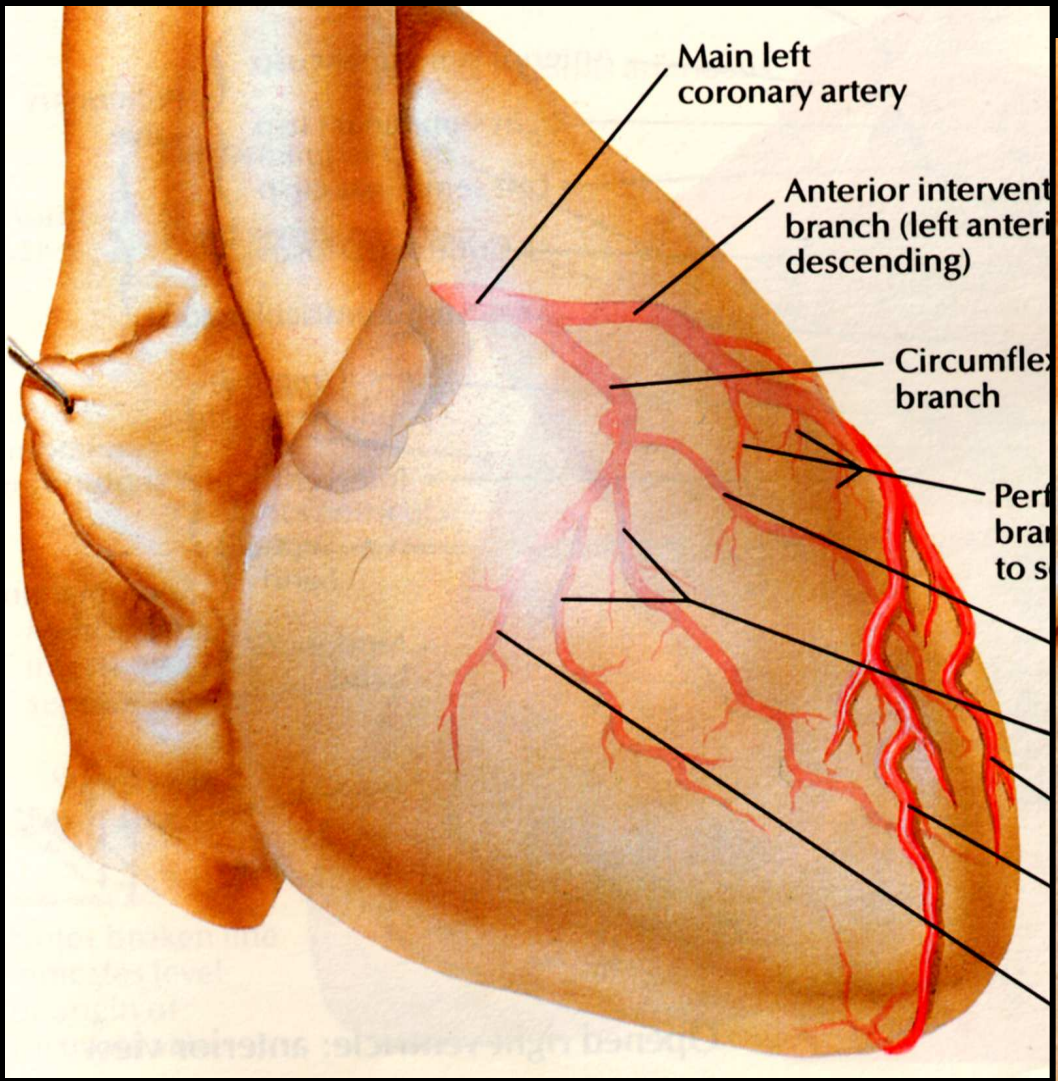


**CORONAIRE D**  
branche rétro et inter ventriculaire postérieure

**Homme de 54 ans, bilan coronarien angiographique non invasif  
angor d'effort sans ischémie authentifiée**

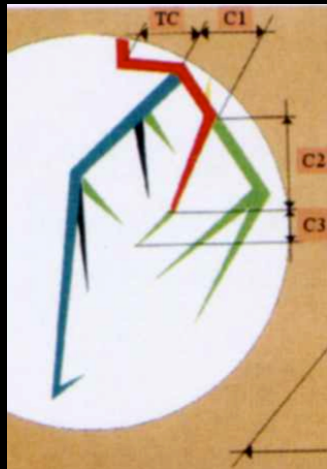
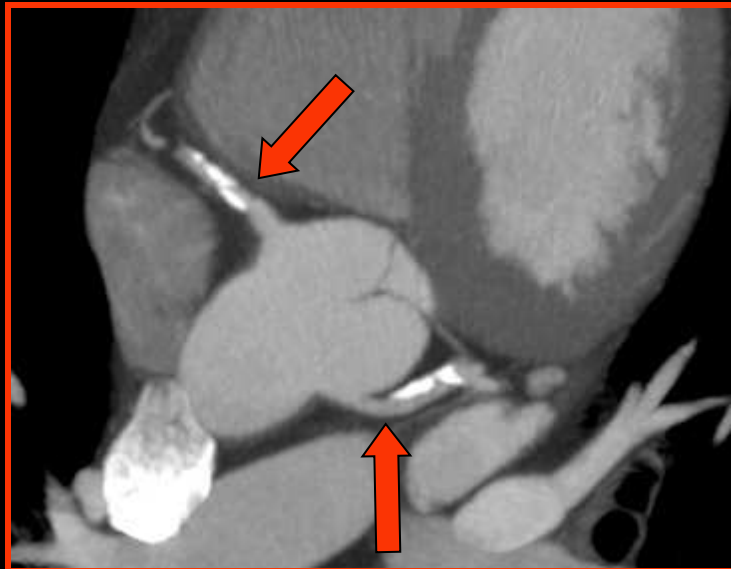
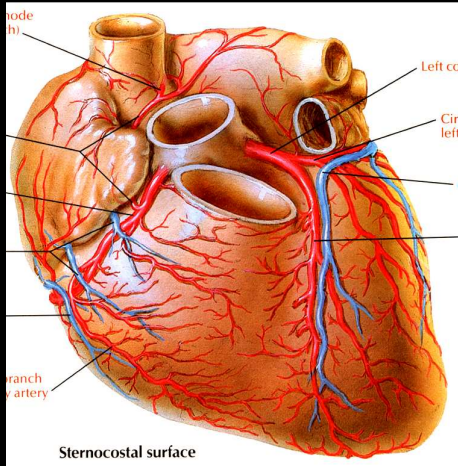
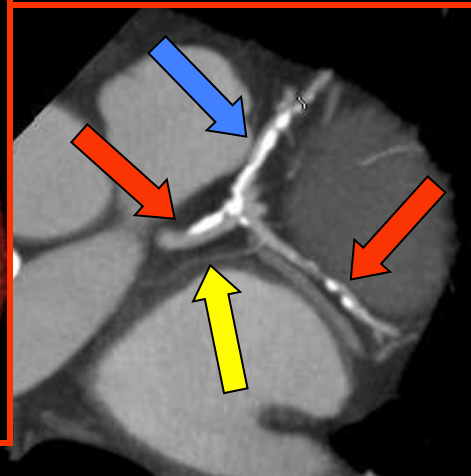
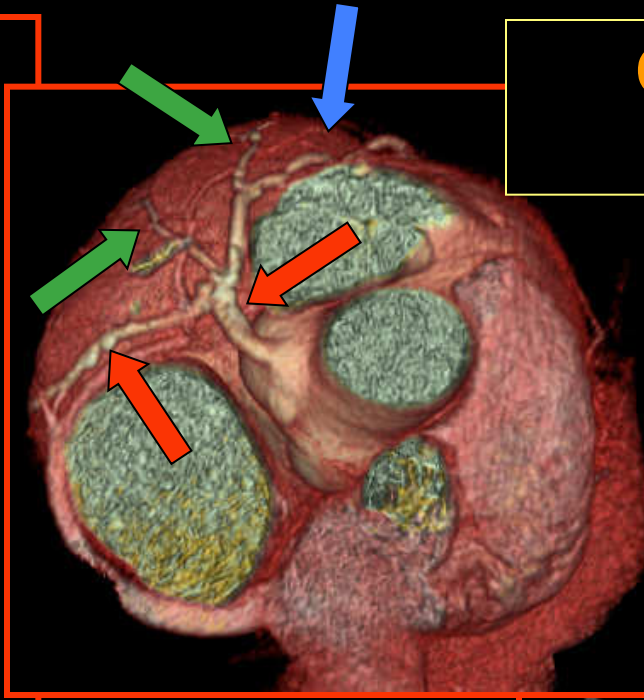
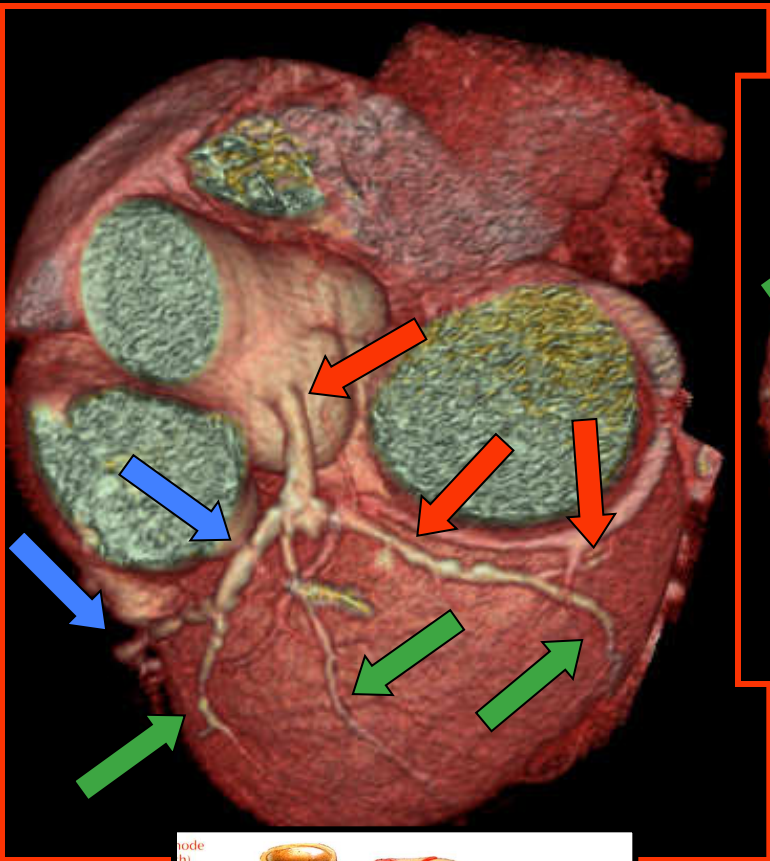


**Artère coronaire droite**

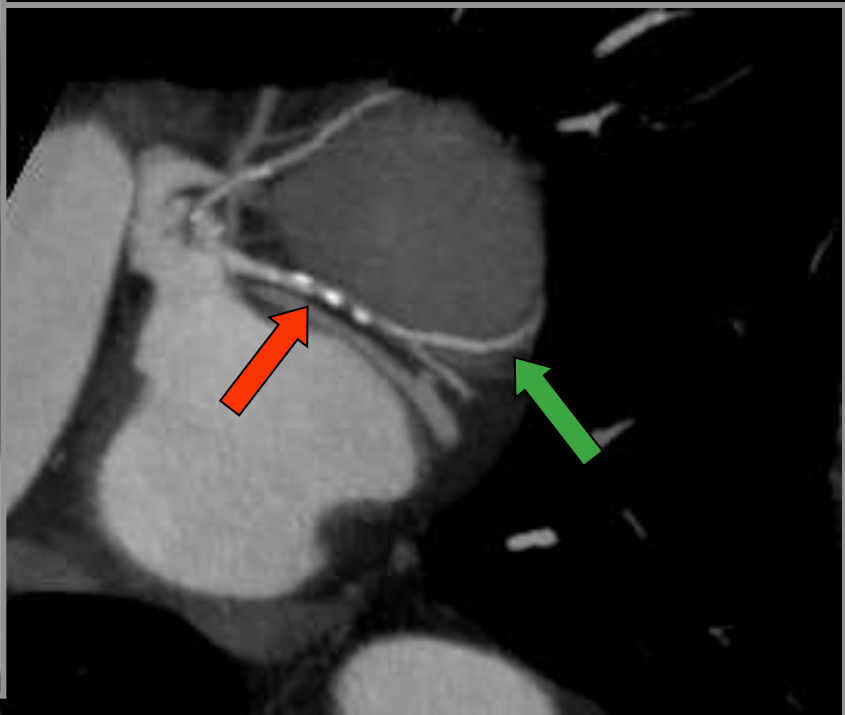
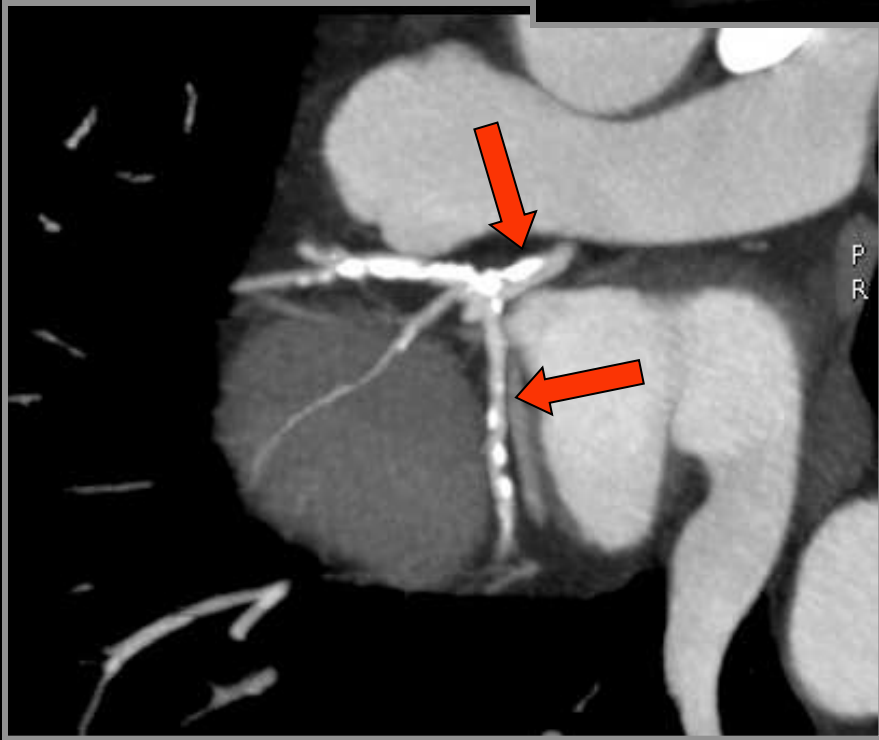
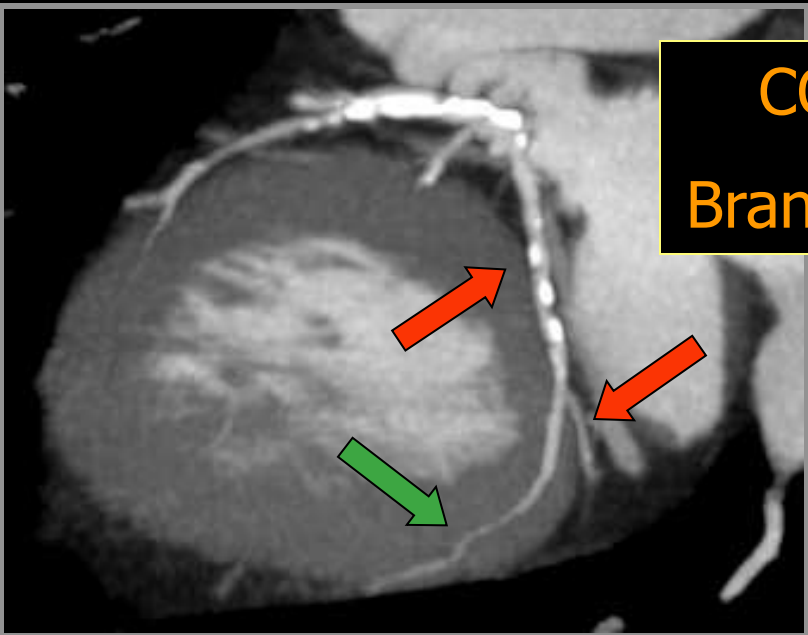


**Coronaire gauche**

# CORONAIRE GAUCHE

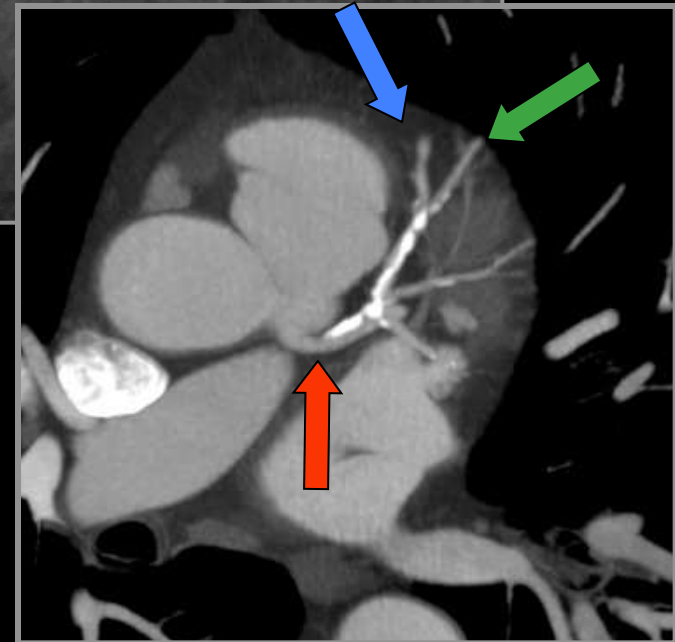
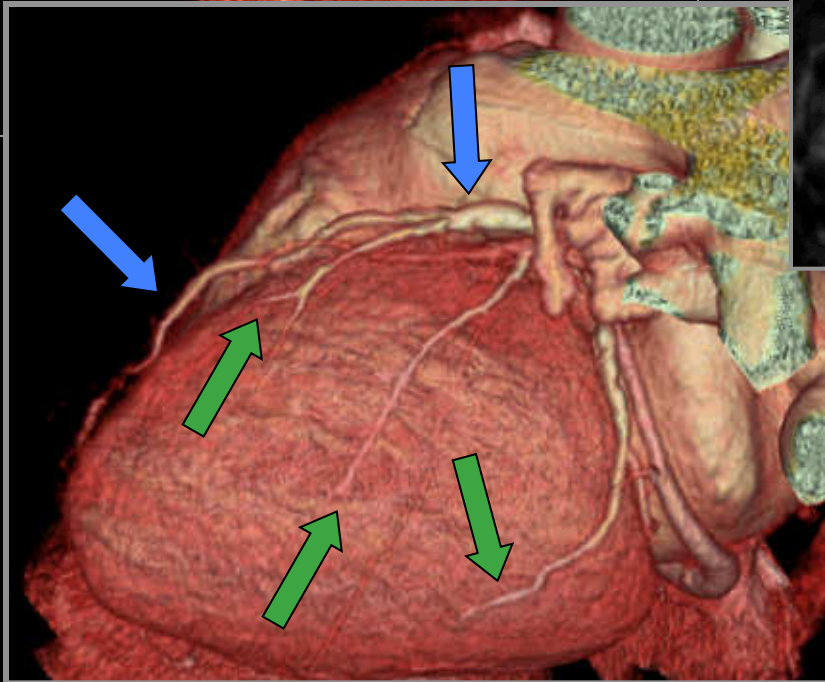
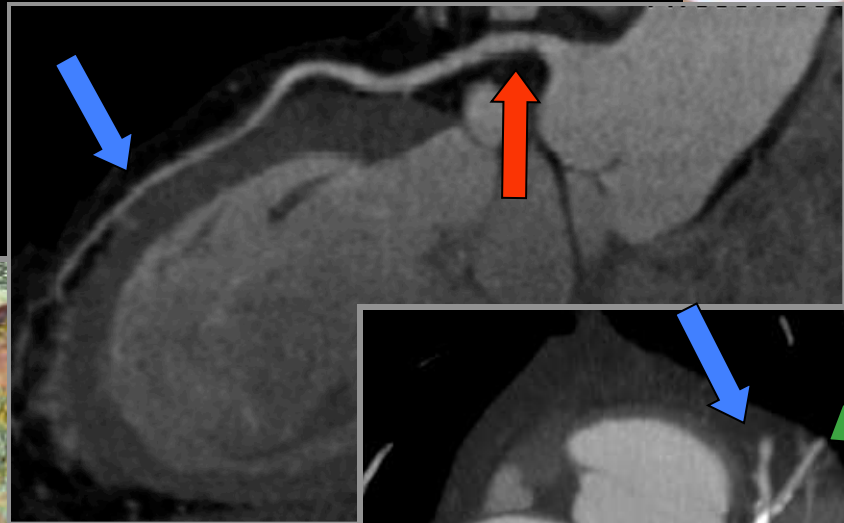
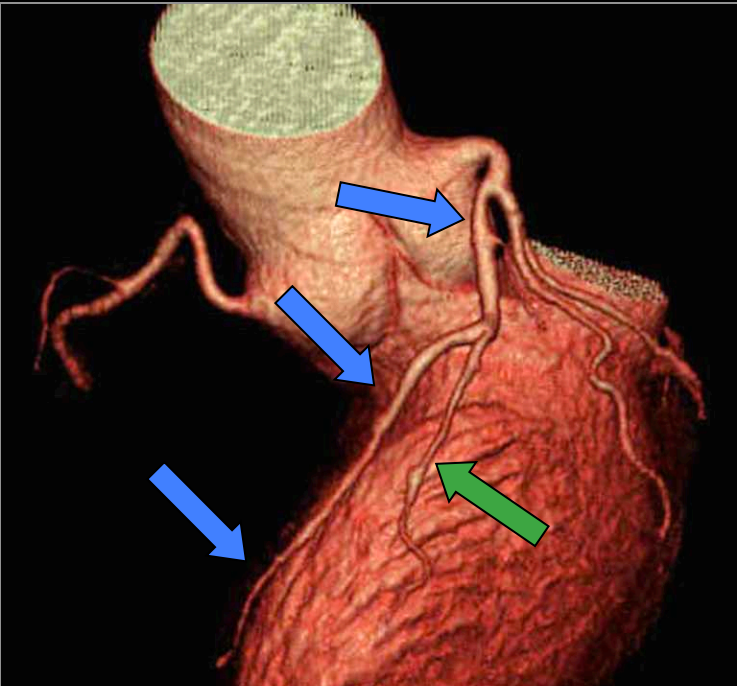
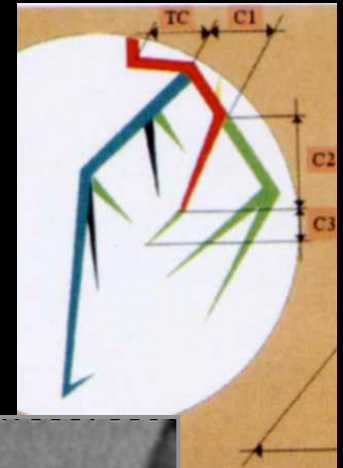


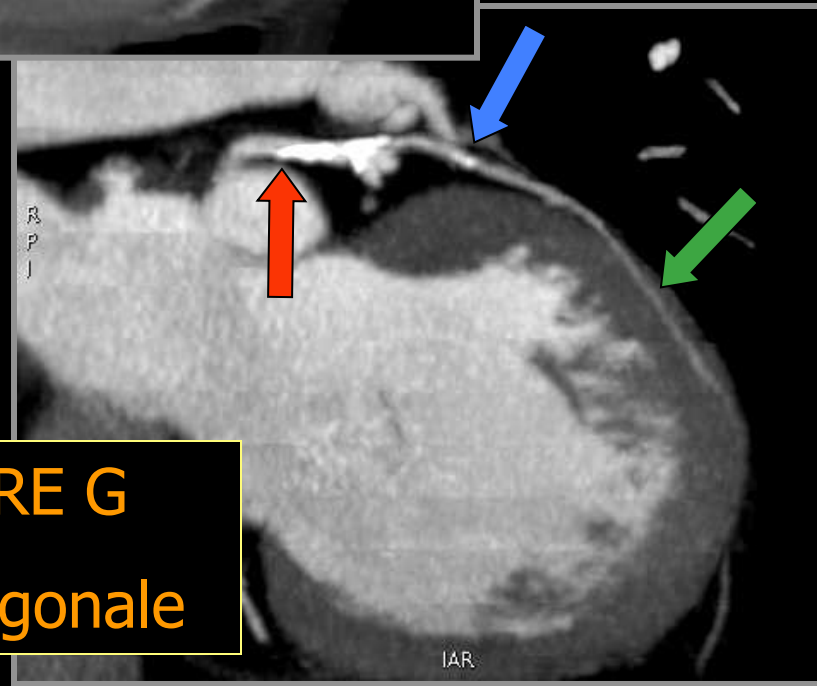
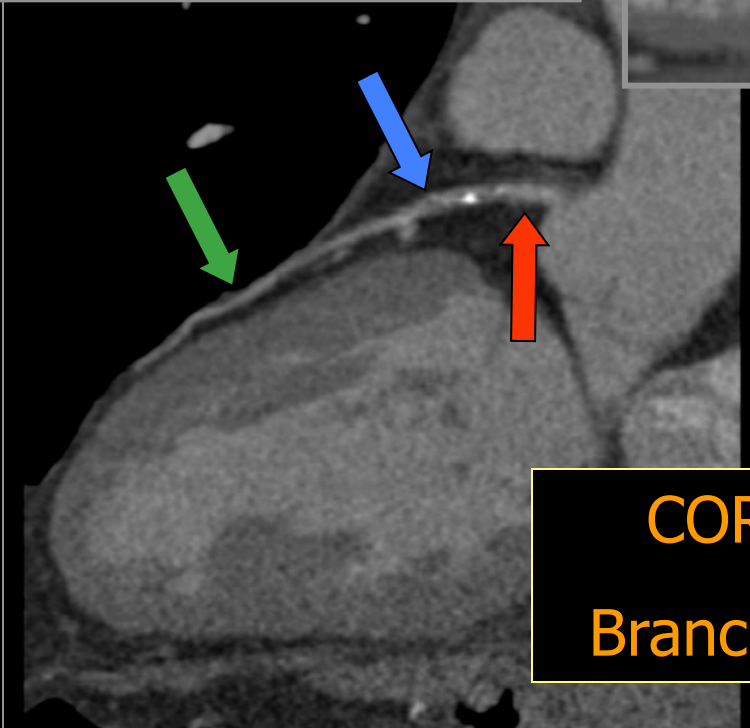
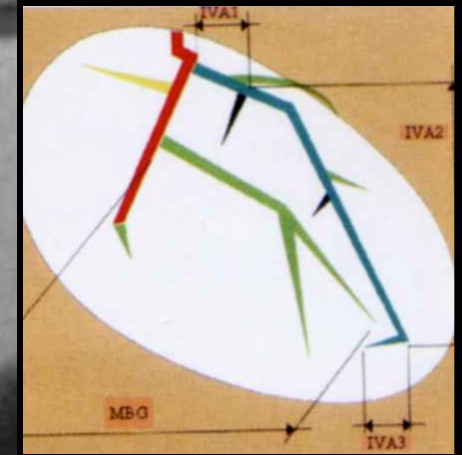
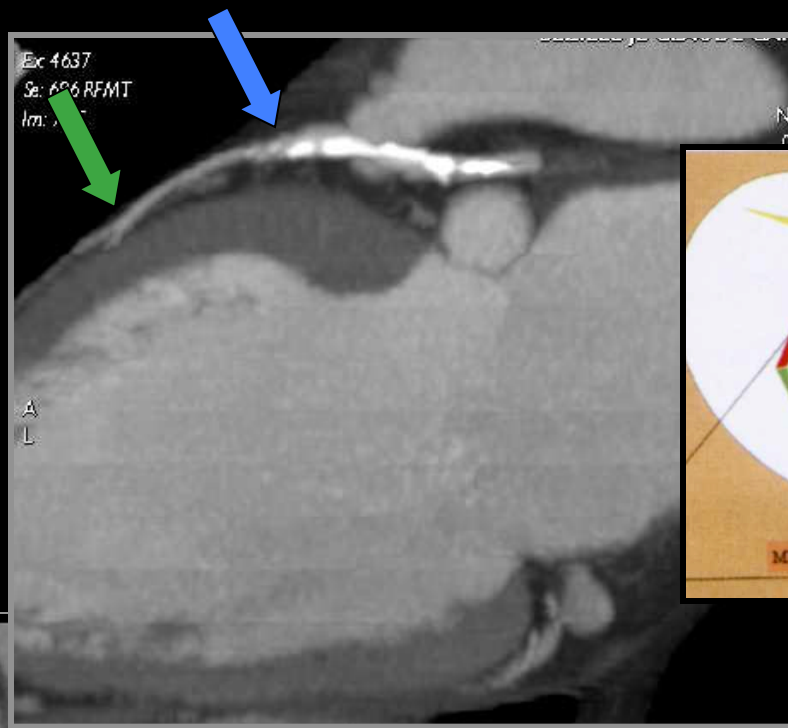
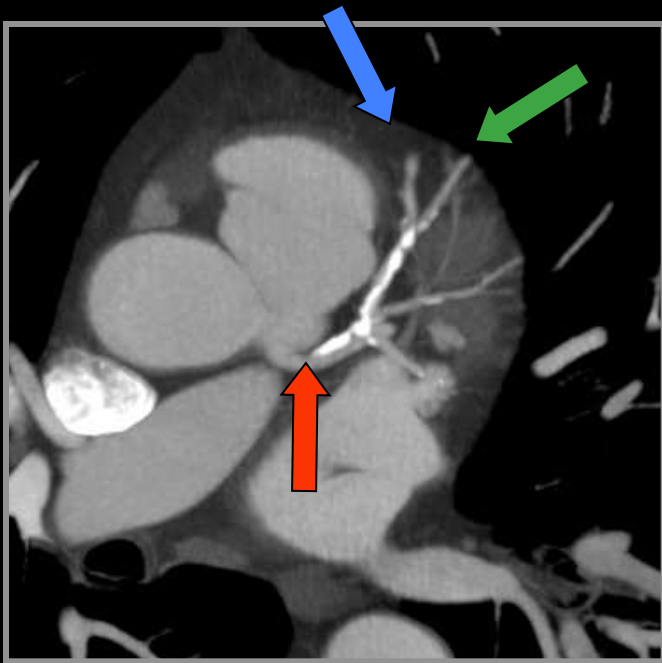
**CORONAIRE G**  
**Branche Circonflexe**



# CORONAIRE G

Branche  
interventriculaire  
antérieure



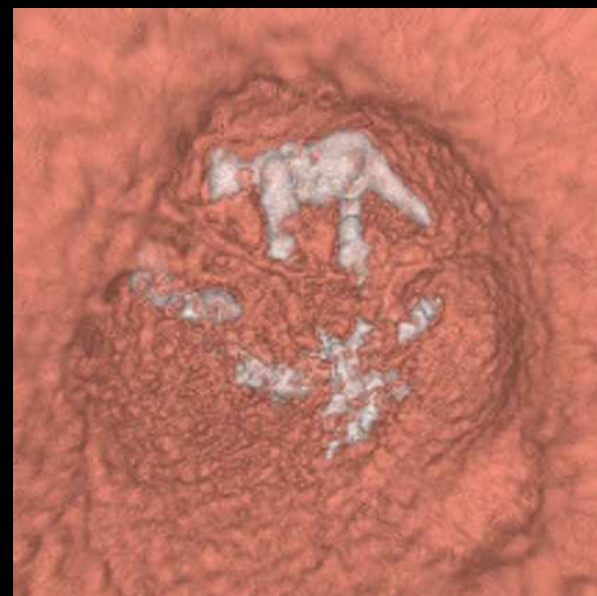
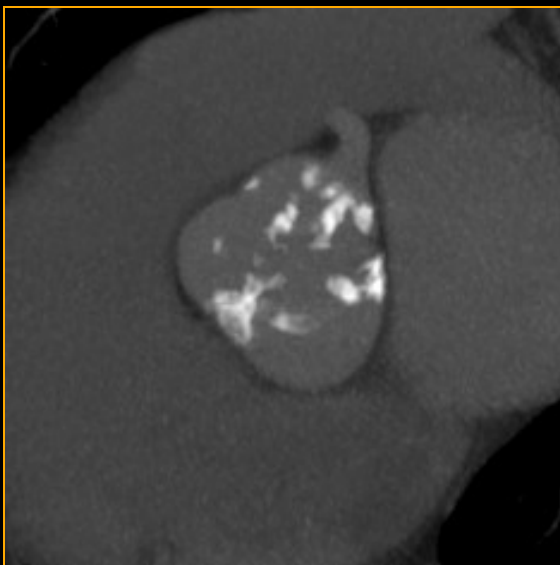
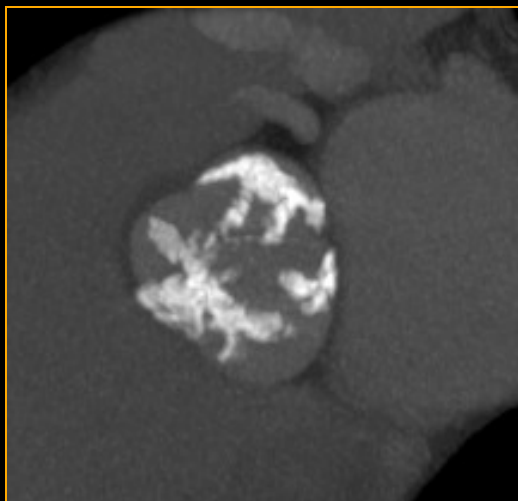
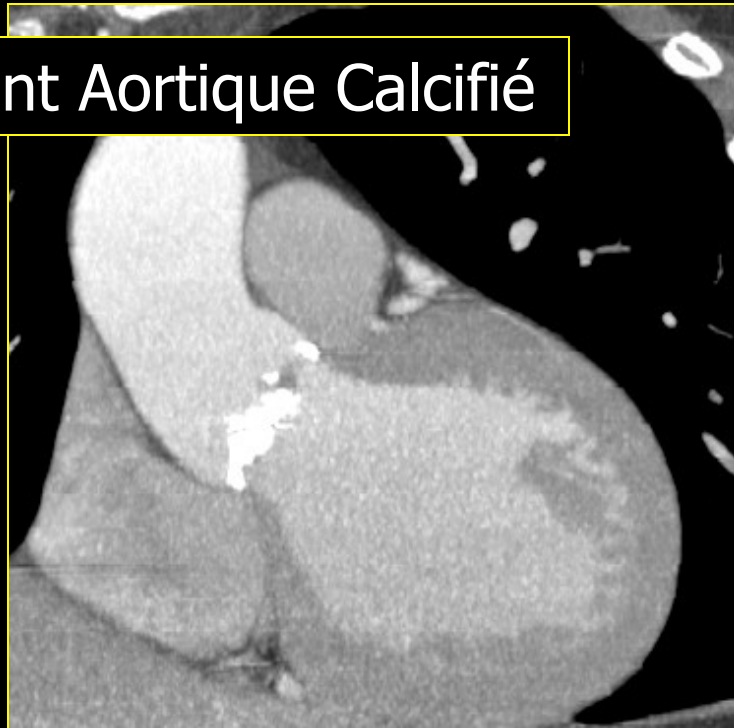
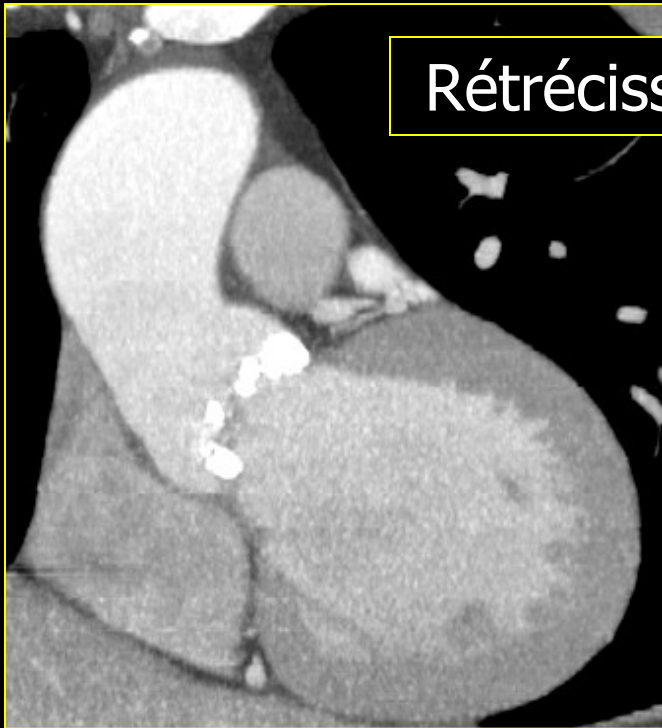

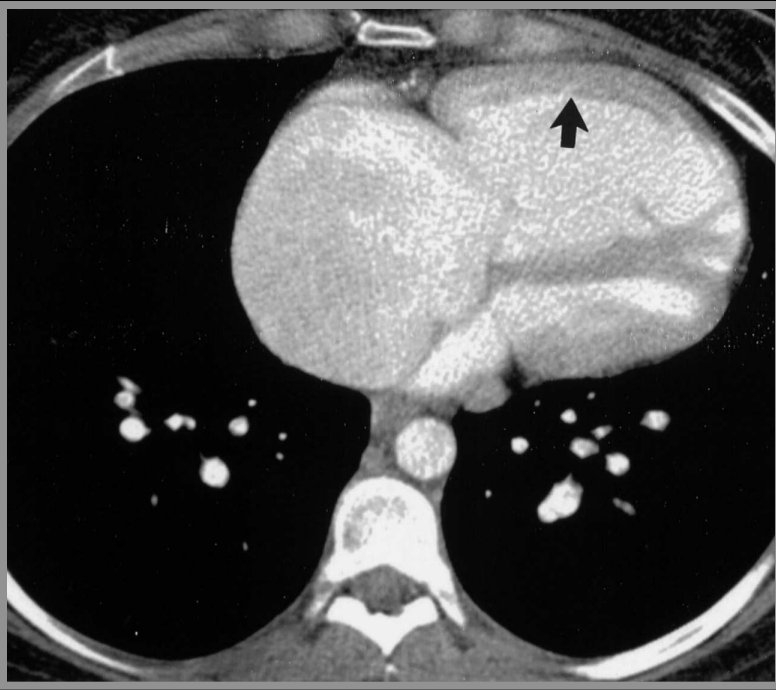
**CORONAIRE G**  
**Branche Diagonale**



**UN PEU DE PATHOLOGIE ET  
VARIATIONS ANATOMIQUES...**

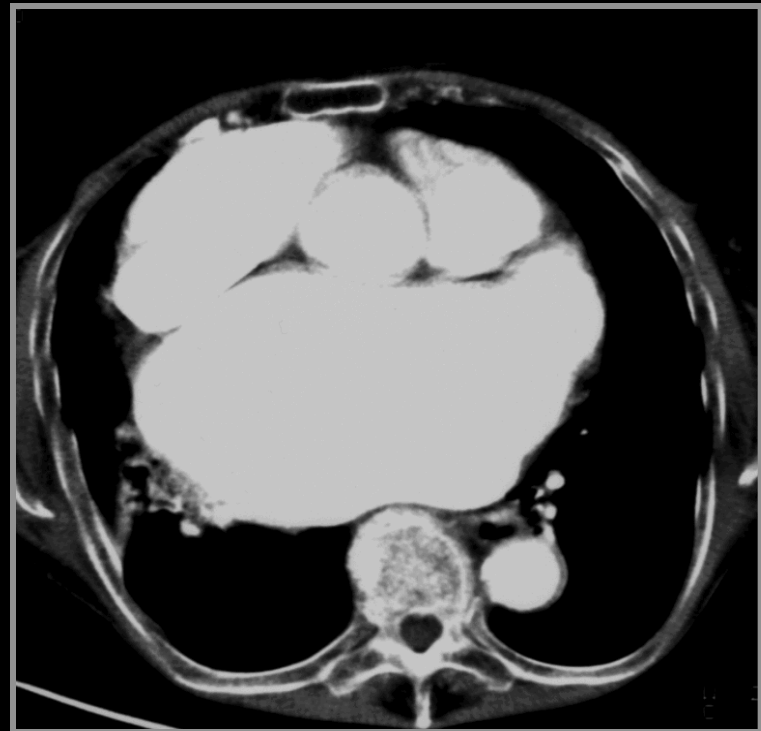# Rétrécissement Aortique Calcifié

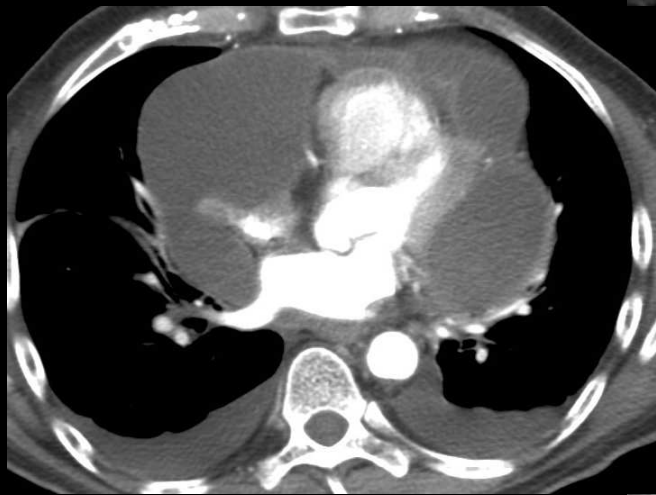




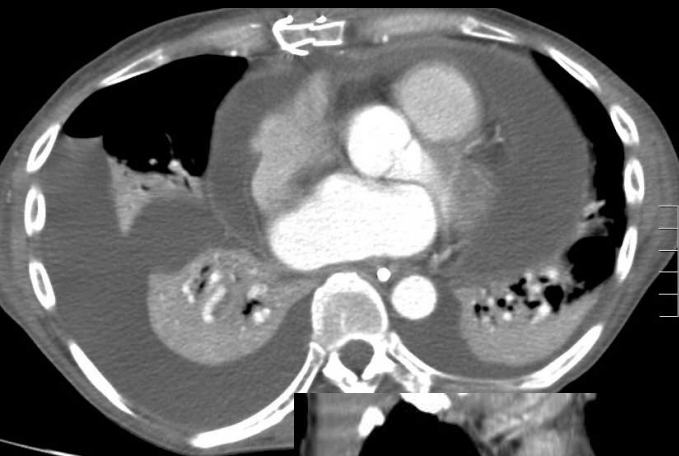
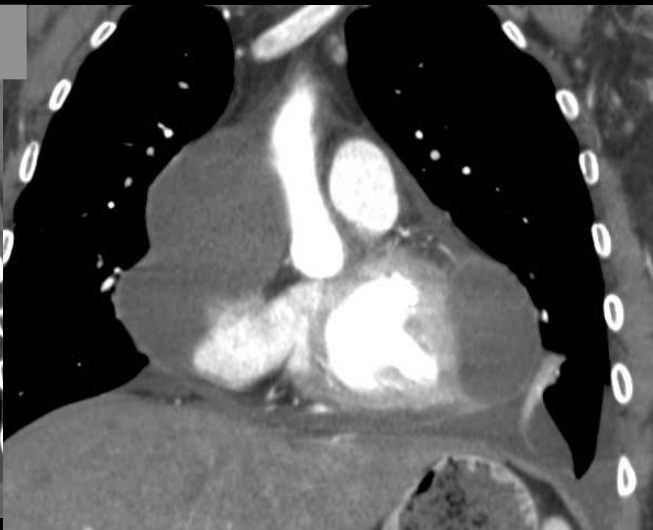
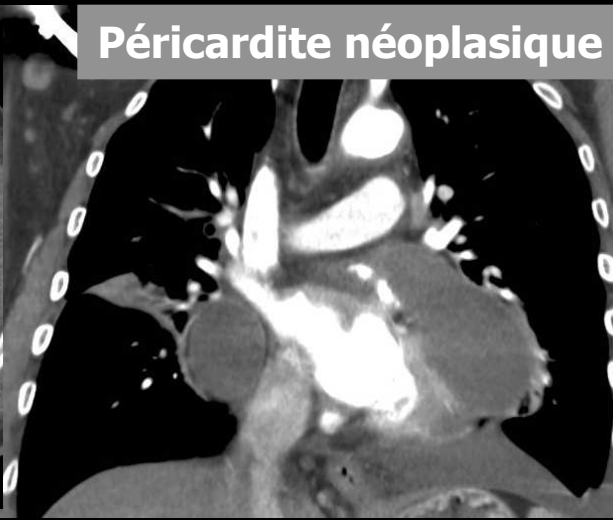
**Oreillette droite**  
**HTAP précapillaire**

**Oreillette gauche**  
**Rétrécissement mitral**

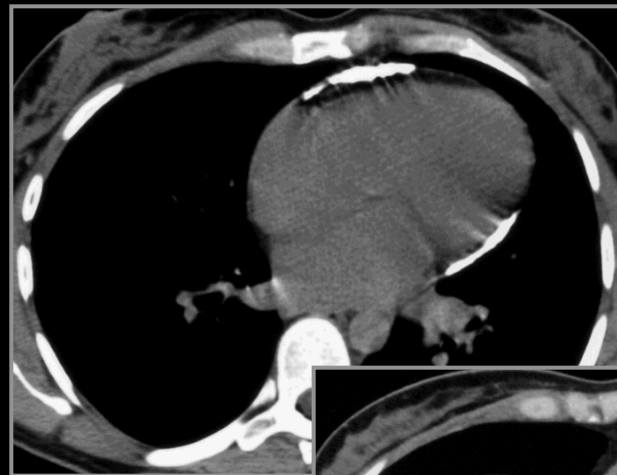
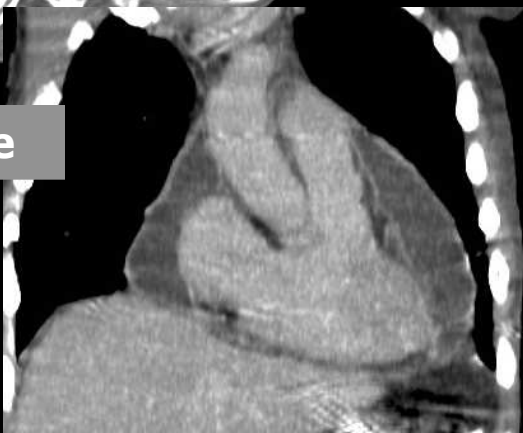




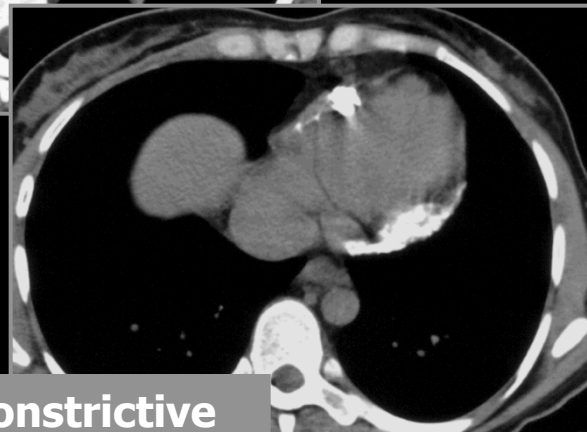**Péricardite néoplasique**



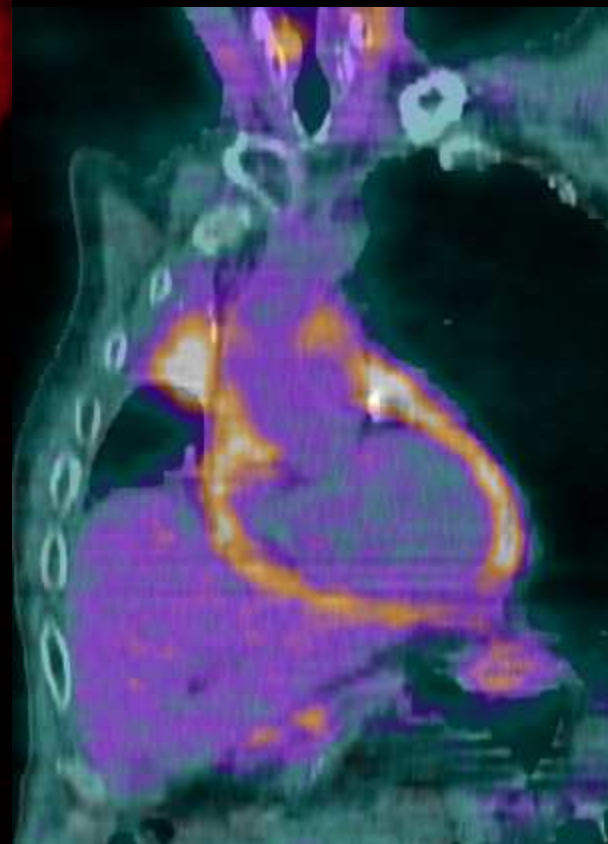
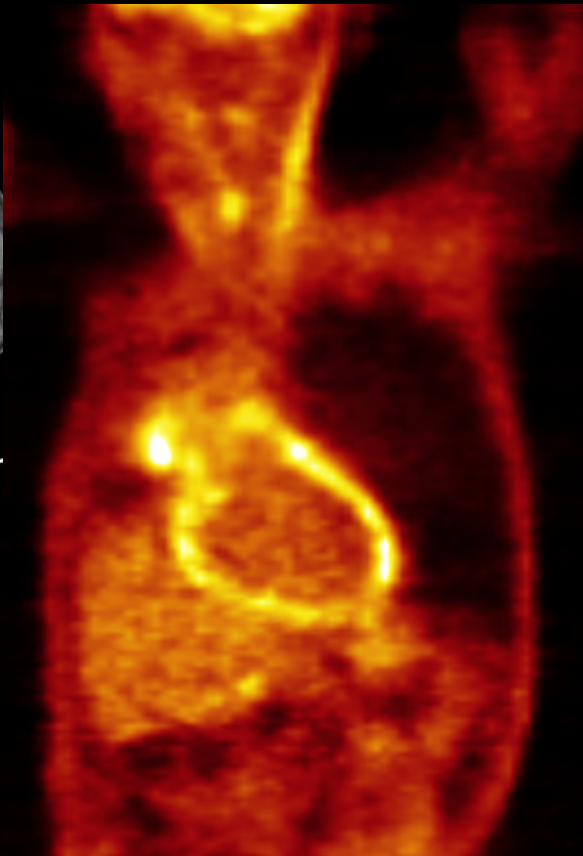
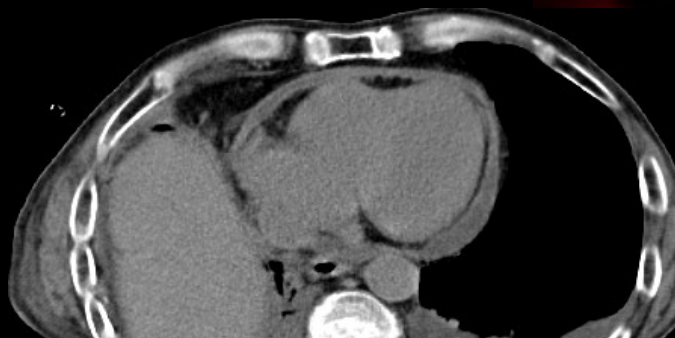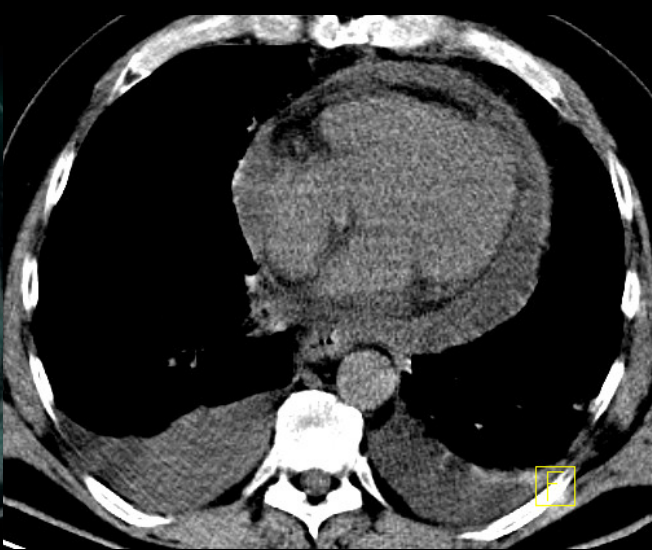
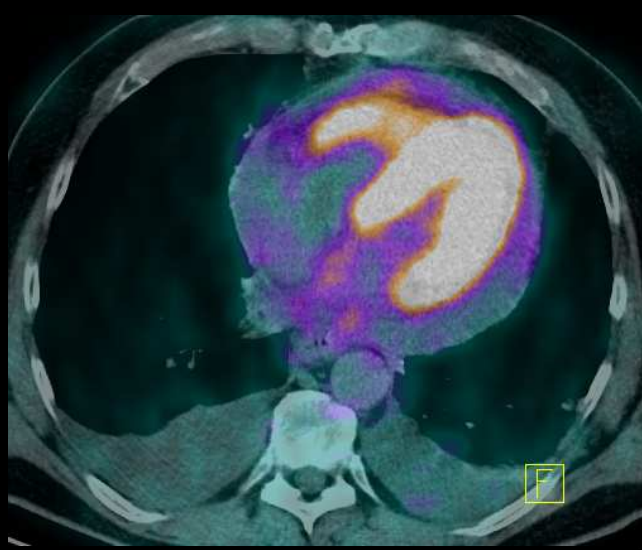**Péricardite**

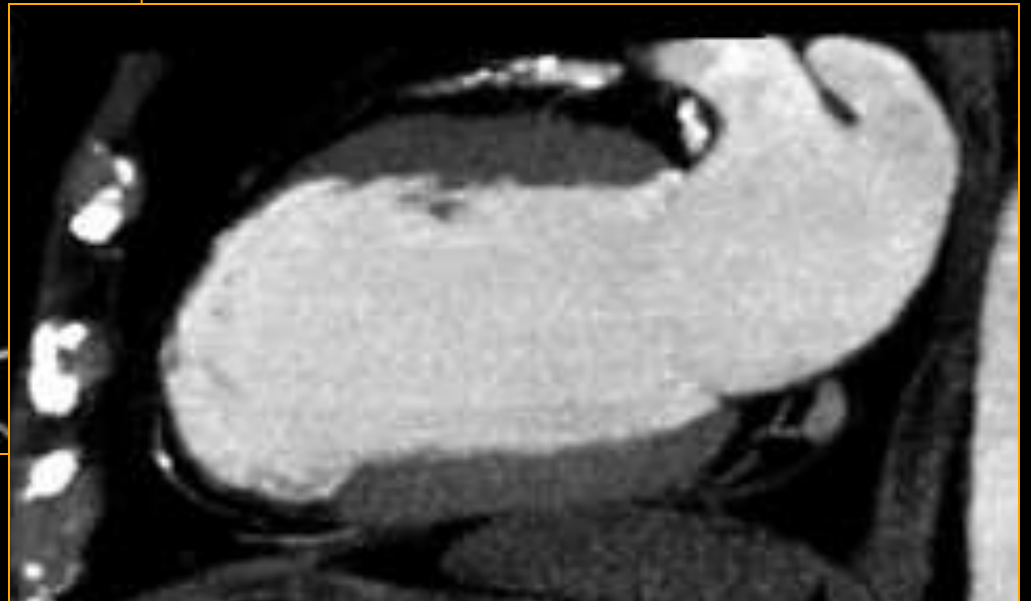
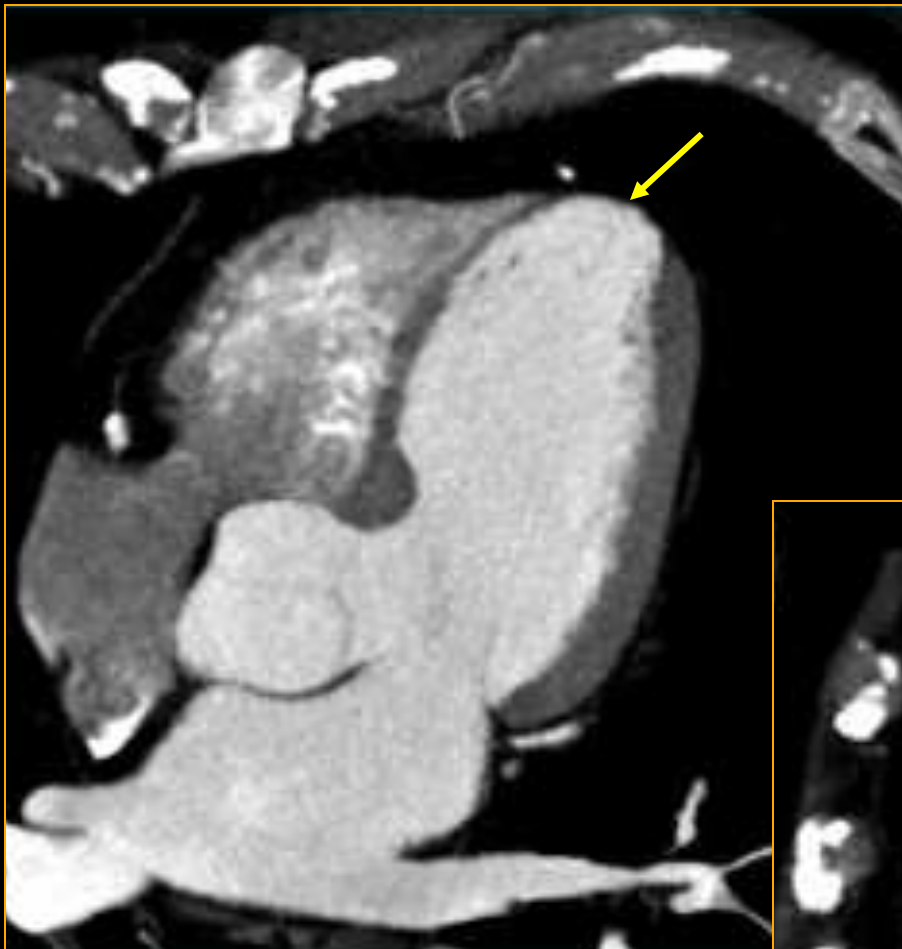

**Péricardite constrictive**

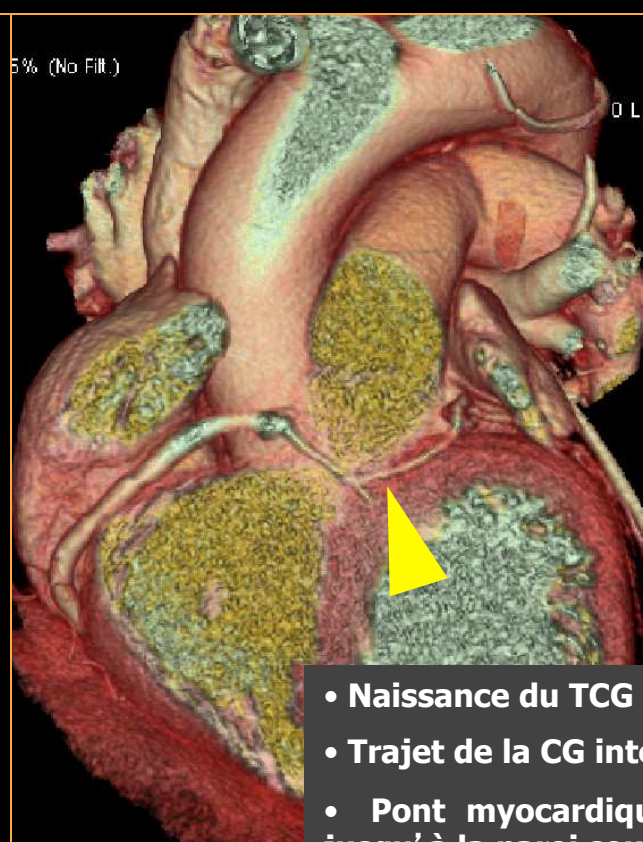
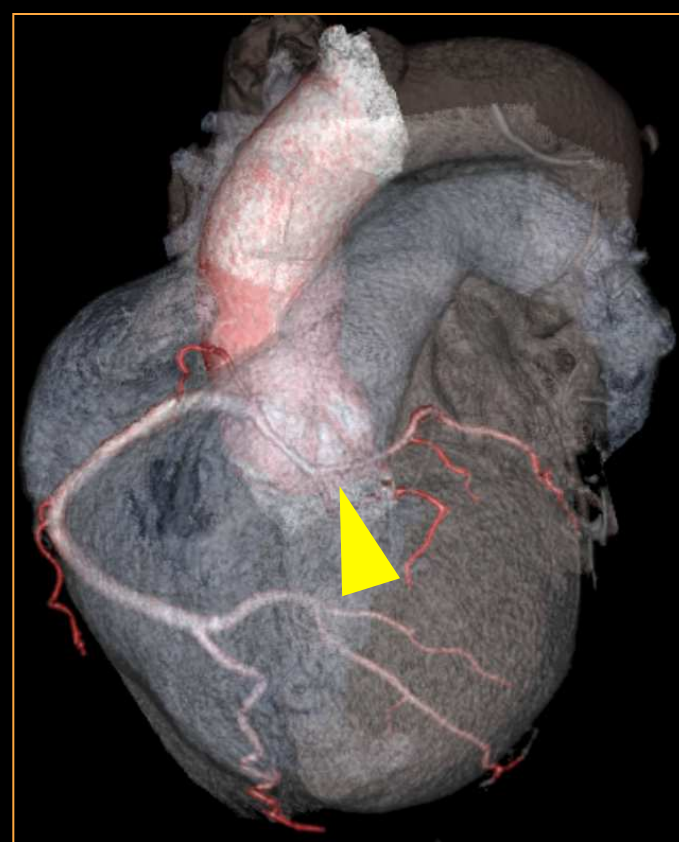
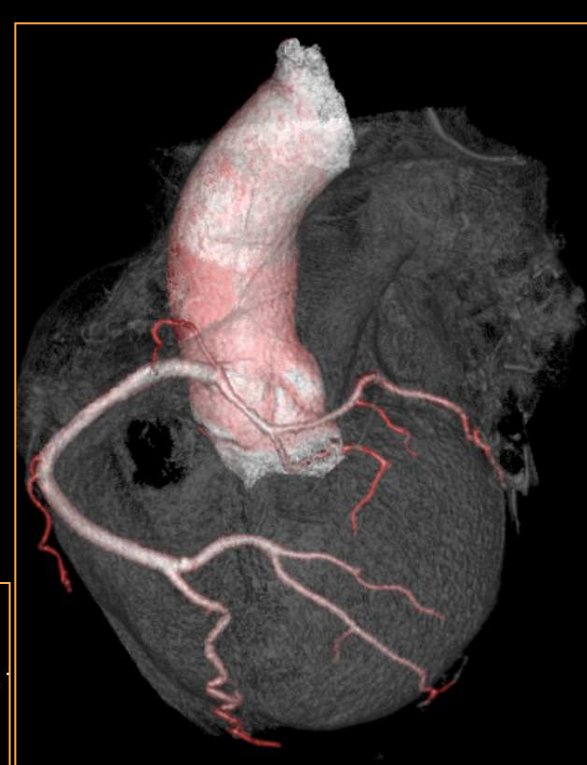
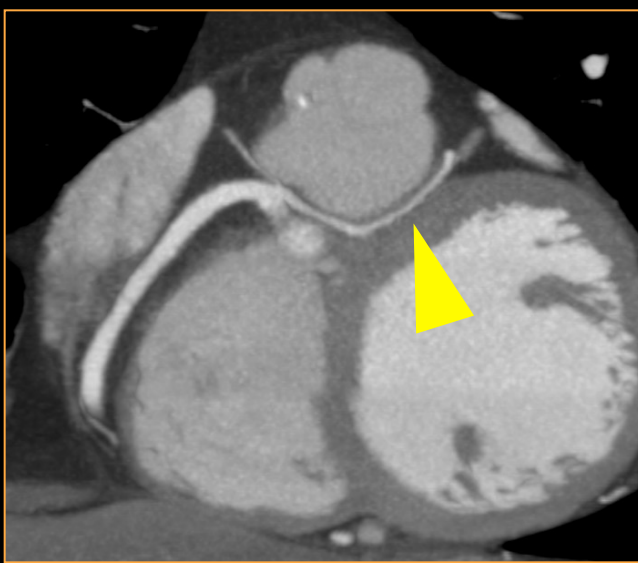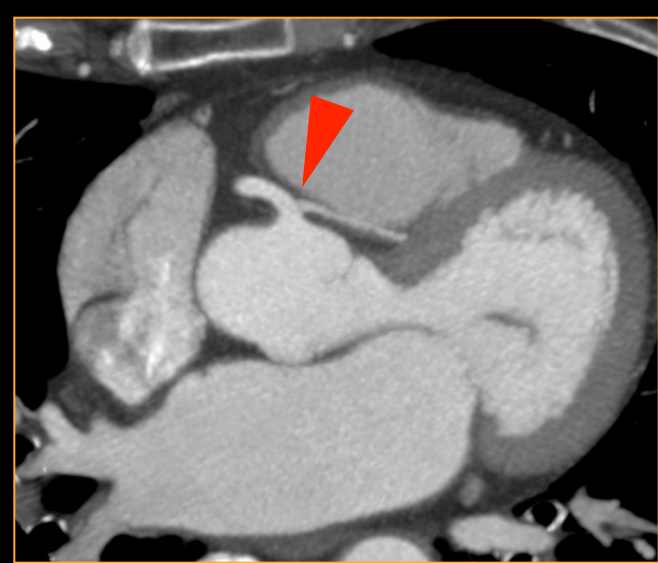


# Péricardites





Anévrisme ventriculaire



- Naissance du TCG de CD1
- Trajet de la CG interartériel, dans la paroi de l'AP
- Pont myocardique profond de l'IVA prox et moy jusqu'à la paroi sous-endocardique du VD



## 2/ RADIOANATOMIE DU MEDIASTIN

- VAISSEAUX
- CŒUR
- **ŒSOPHAGE**
- CHAINES GANGLIONNAIRES

## *Définition*

- Segment du tube digestif reliant l'hypopharynx à l'estomac
- Tube musculaire de 25 cm de longueur (de C6 à D11)
- 3 régions anatomiques : cervicale, thoracique et abdominale
- Passe en arrière de la trachée, traverse le médiastin postérieur dans toute sa hauteur, se déplace progressivement vers la gauche.
- Traverse le diaphragme à hauteur de T10 par le hiatus oesophagien ou il présente un rétrécissement

# Anatomie

Œsophage **cervical** : de C6 à T1, 16 à 21 cm des AD

Œsophage **thoracique** : T1 à T10, 21 à 37 cm des AD

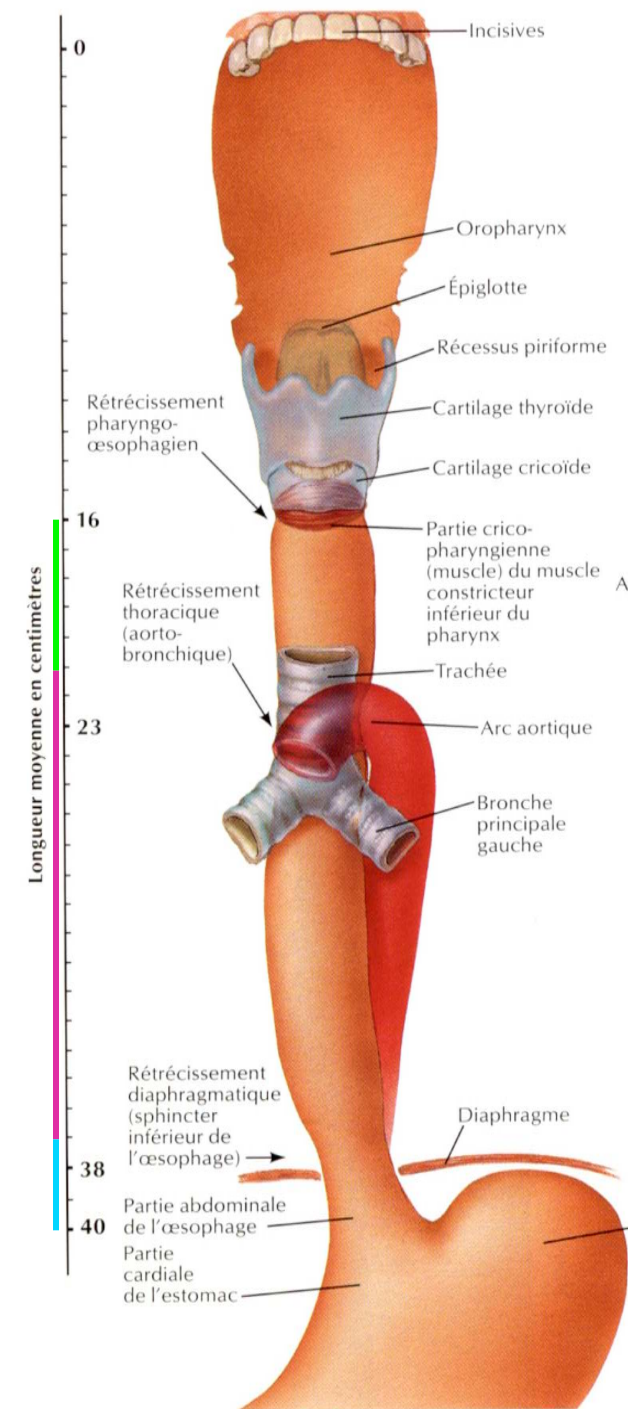
Œsophage **abdominal** : T10-11, 37 à 40 cm des AD

Œsophage intra-thoracique :

**Tiers supérieur** : de l'orifice supérieur du thorax à la bifurcation trachéale, à 24 cm approximativement des incisives supérieures

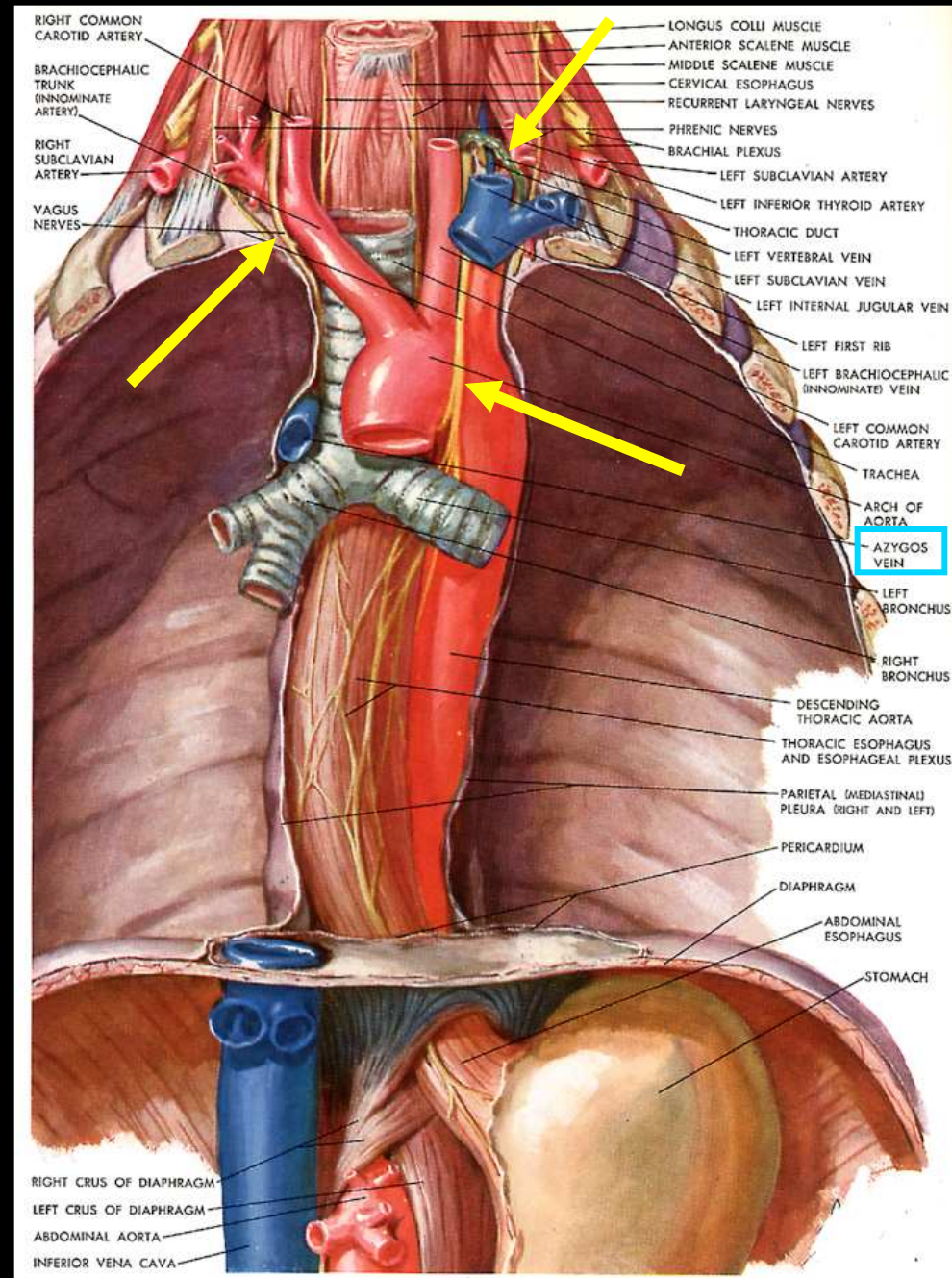
**Tiers moyen** : débutant à la hauteur de la bifurcation trachéale, de 24 à 32 cm approximativement des incisives supérieures

**Tiers inférieur** : (incluant l'oesophage abdominal), de 32 à 40 cm approximativement des incisives supérieures.



# Rapports

- **Trachée** : axe du médiastin postérieur, bifurque en T5, l'oesophage y adhère par les muscles de Luschka
- **Conduit thoracique** : monte en arrière plaqué contre l'aorte, en rapport avec l'oesophage sur une partie de son trajet.
- **Nerfs vagues** :  
droit : passe en arrière de l'oesophage  
gauche : en avant de l'oesophage
- **Chaîne orthosympathique latéro-vertébrale** et ses ganglions
- **Azygos, hémiazygos, hémiazygos accessoire**



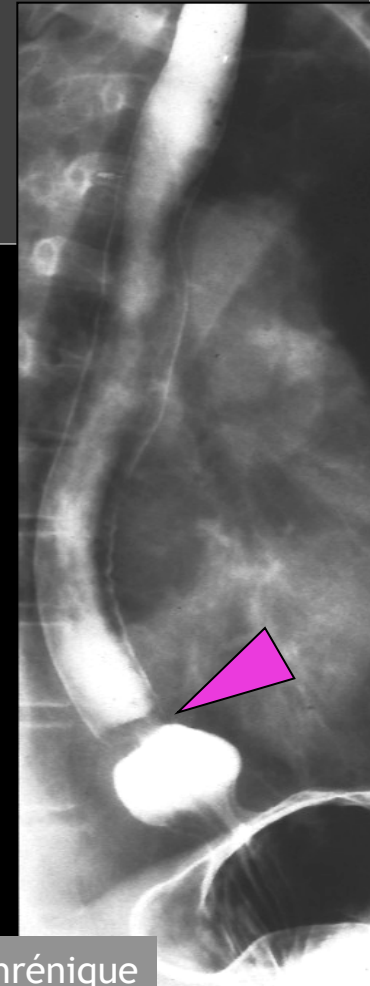
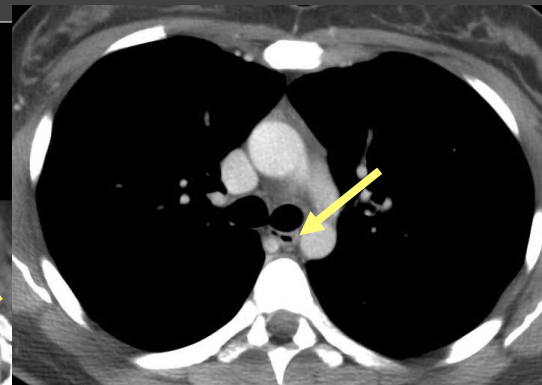
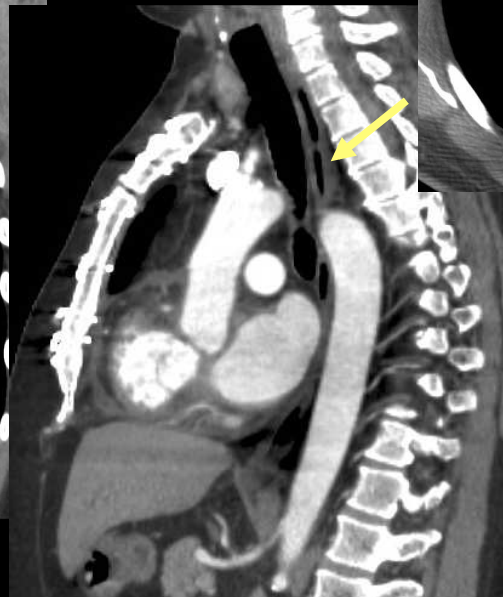
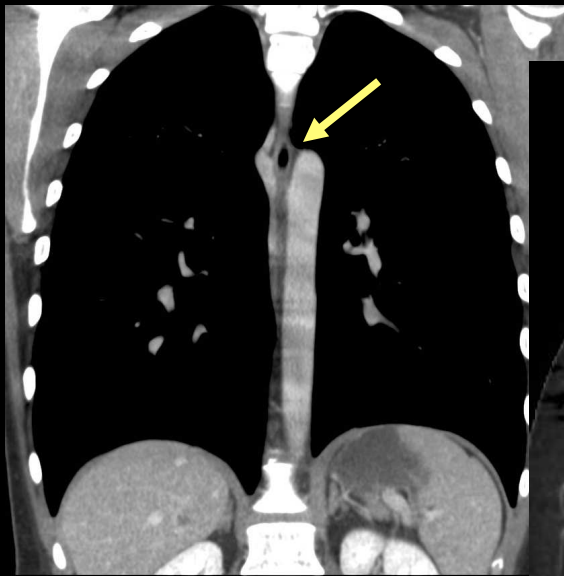
## Transit oesophagien

### - double contraste

- BaSO4 haute densité-viscosité faible
- air dégluti ou mieux **insufflé**

## Scanner: pathologie tumorale ++

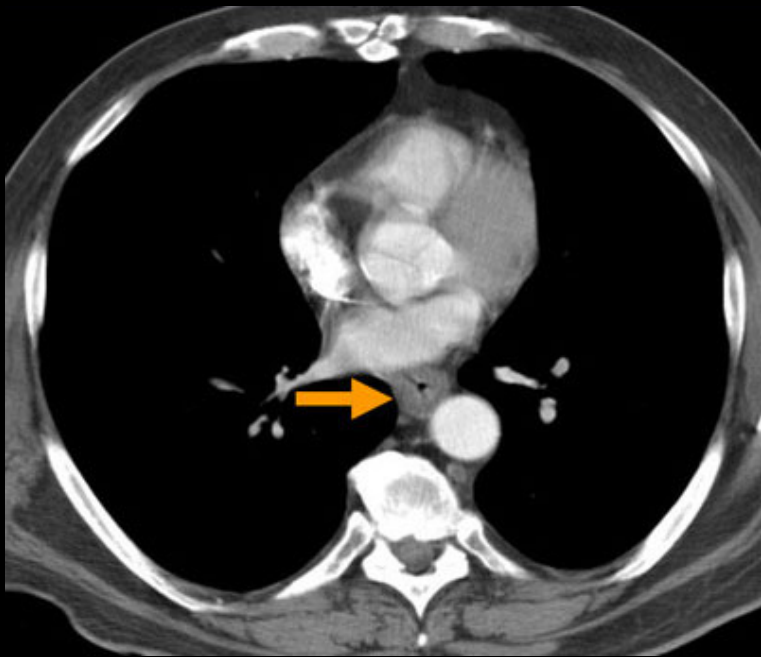
Avec ingestion d' hydrosolubles ++++



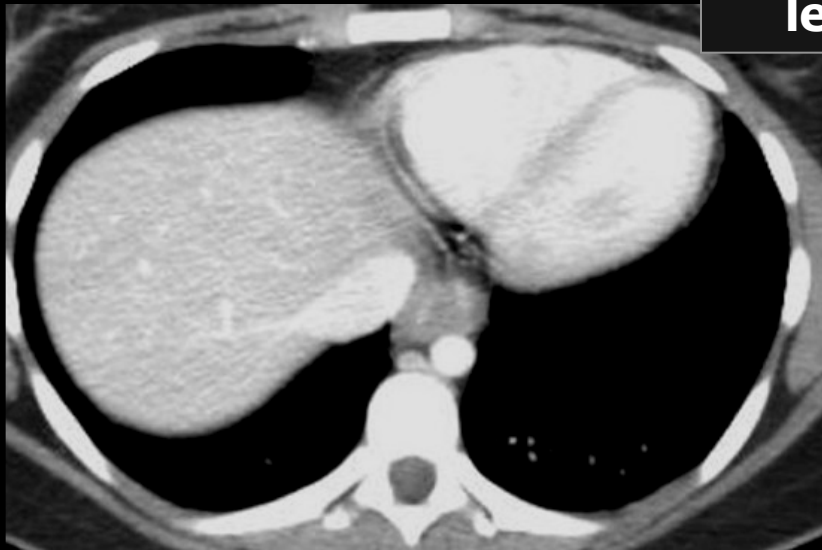ampoule épiphérique



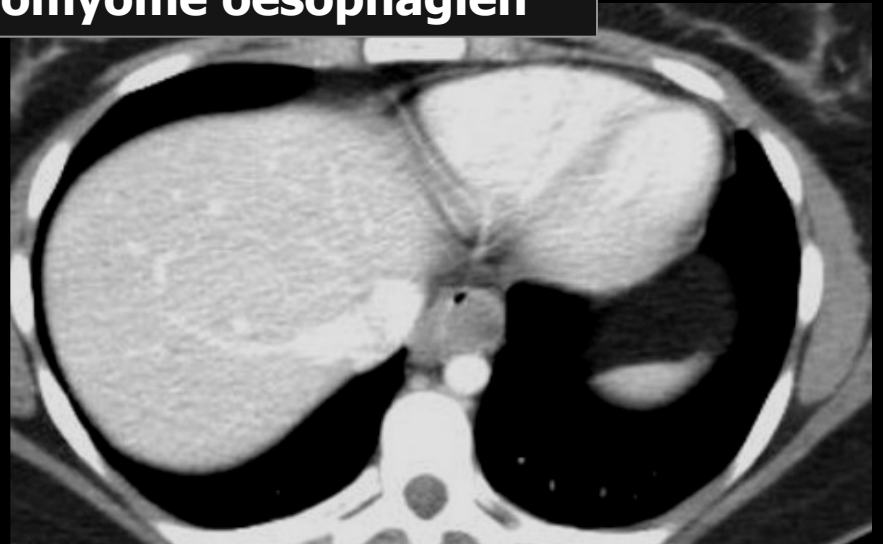
**UN PEU DE PATHOLOGIE ET  
VARIATIONS ANATOMIQUES...**



**carcinome épidermoïde  
de l'oesophage**

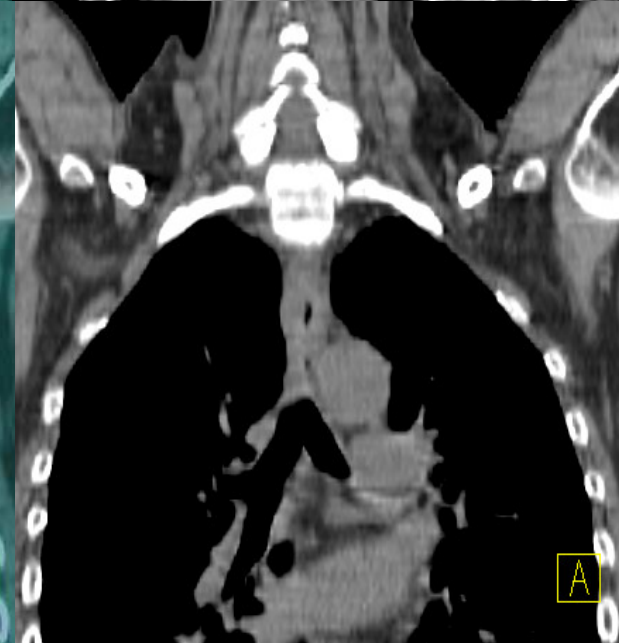
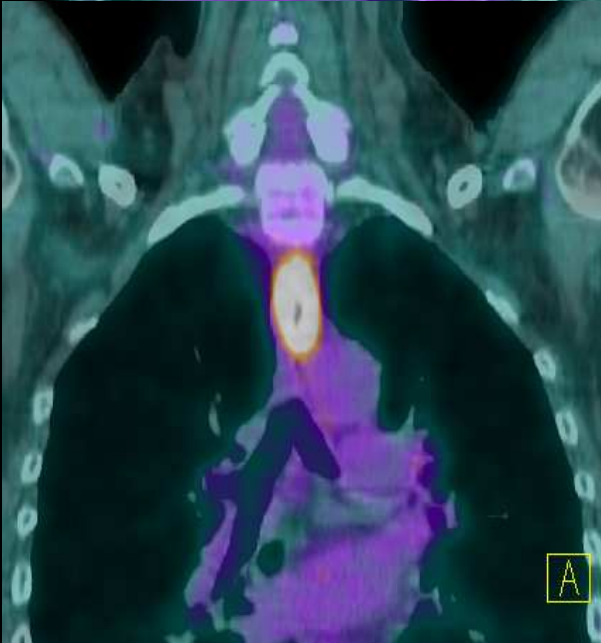
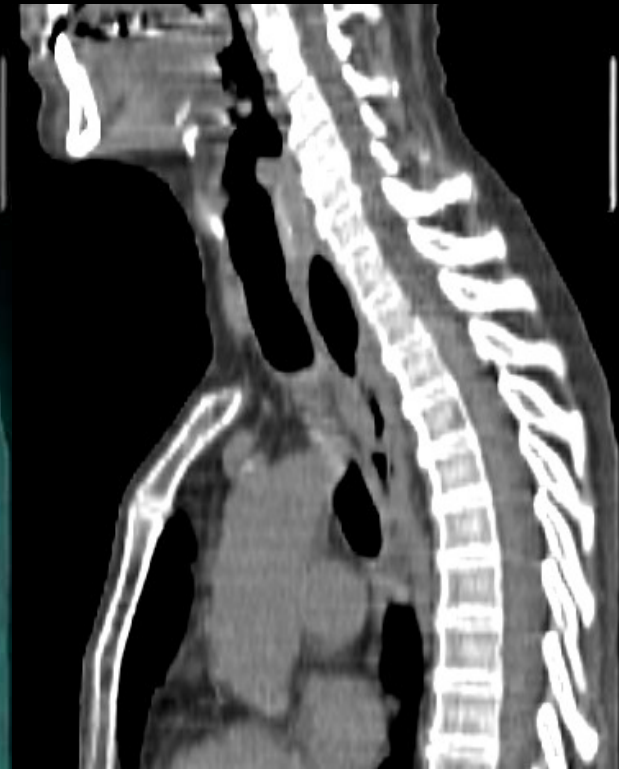
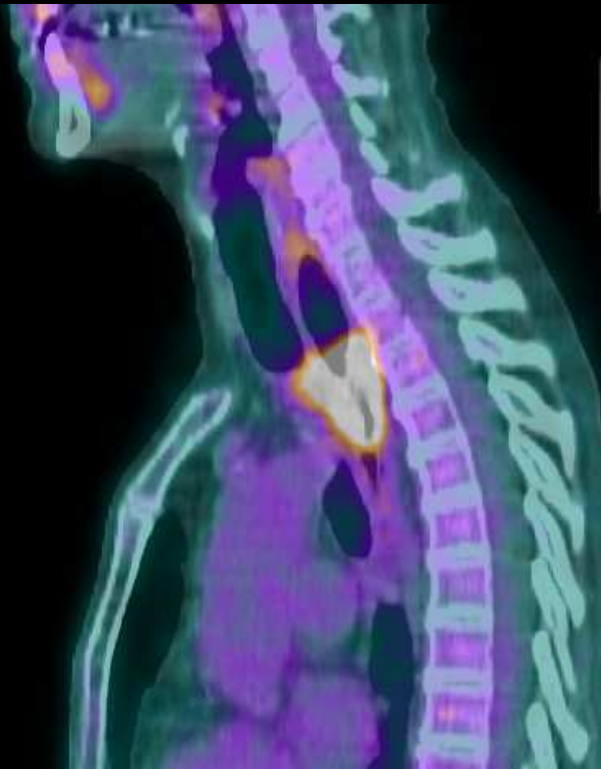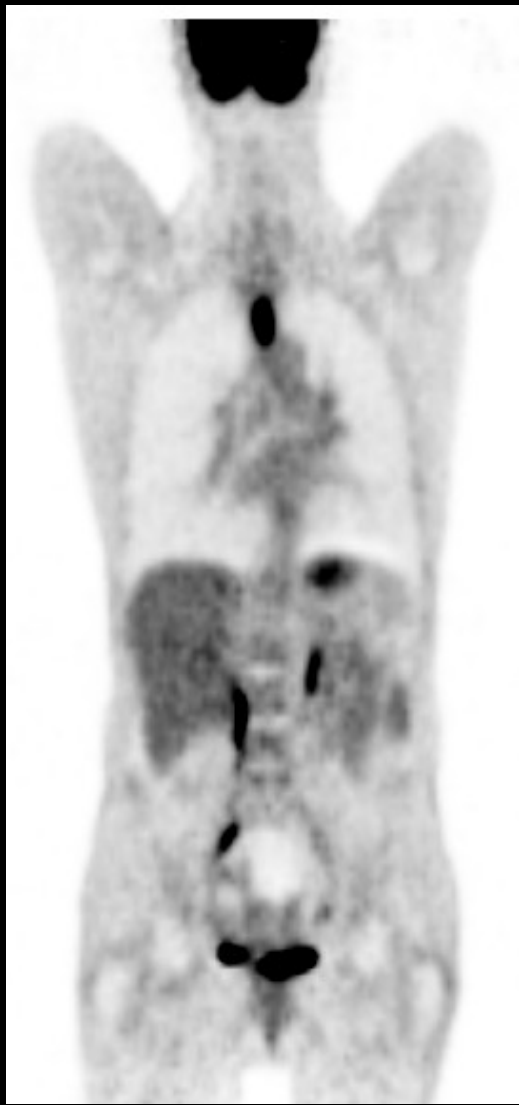**leiomyome oesophagien**



## **Cancer oesophagien TEP-FDG**

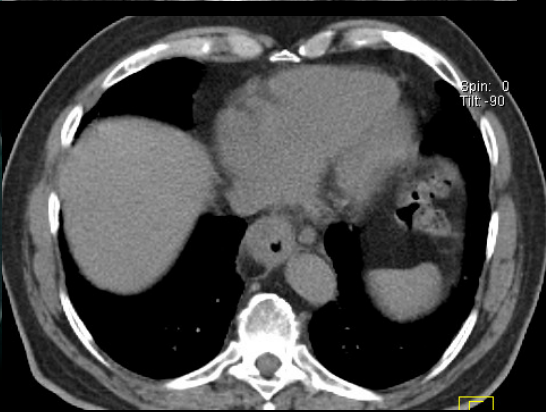
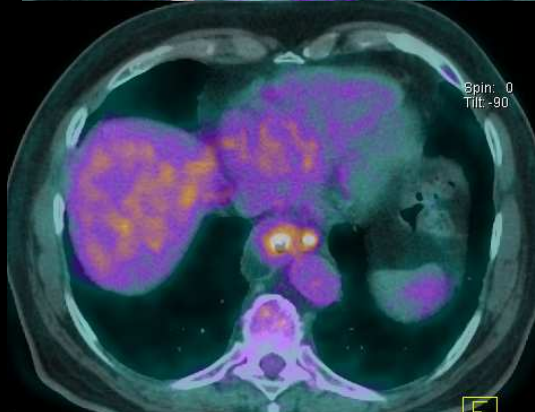
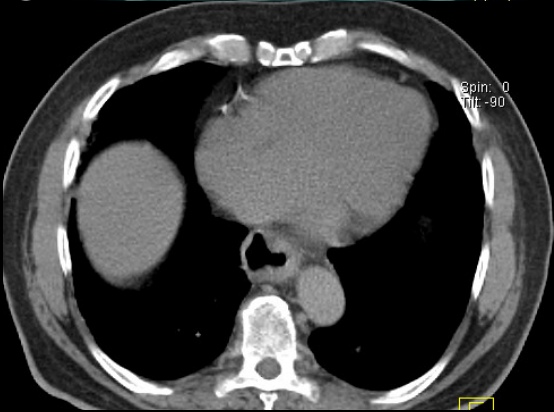
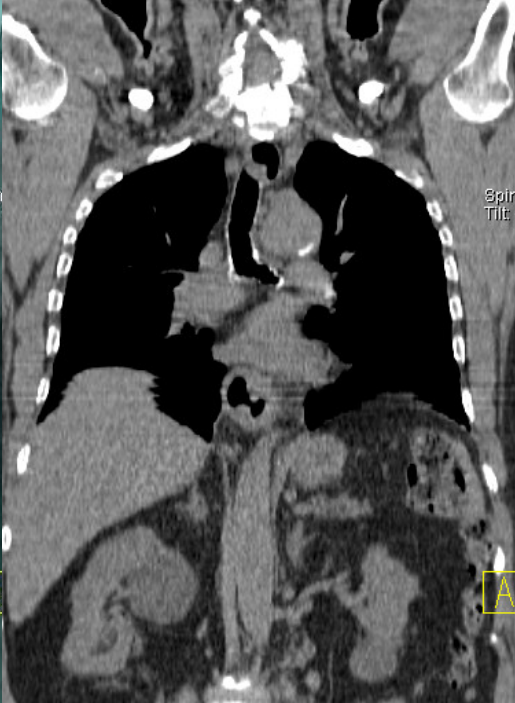
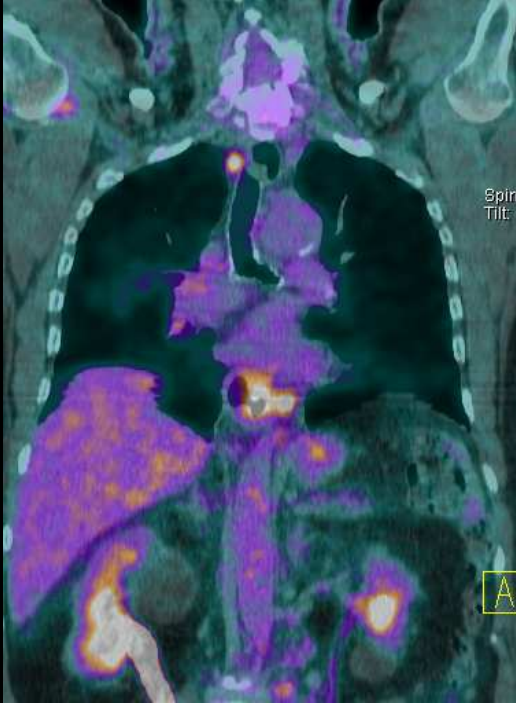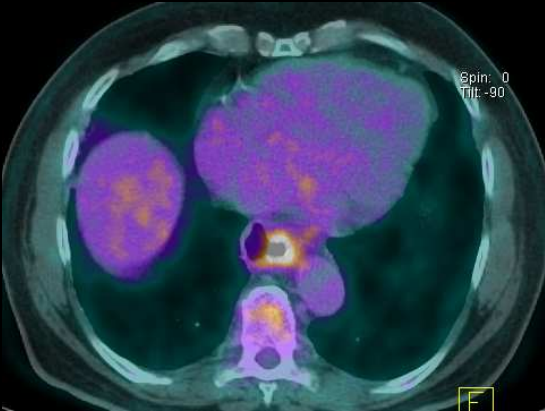- **Bilan d'extension**
  - **Ne permet pas de différencier N0 et N1 en raison de la captation très intense par la tumeur pouvant masquer les adénopathies adjacentes**
  - **Intérêt pour déterminer les stade IV (Se 69% Sp 93%)**
  - **Suivi de la réponse au traitement**



**carcinome épidermoïde  
de l'oesophage**

# Cancer oesophagien

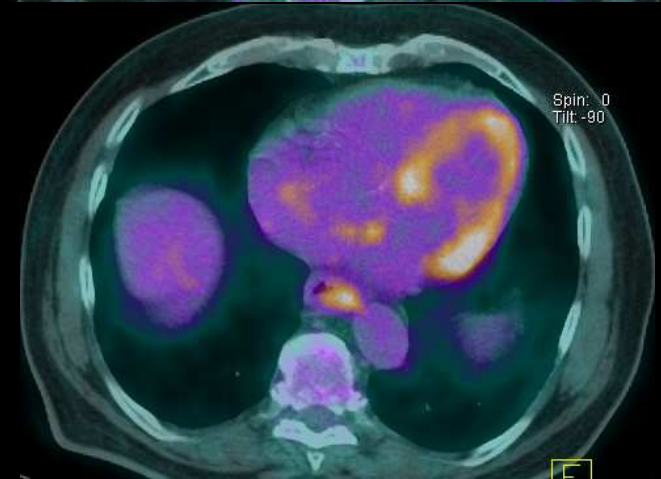
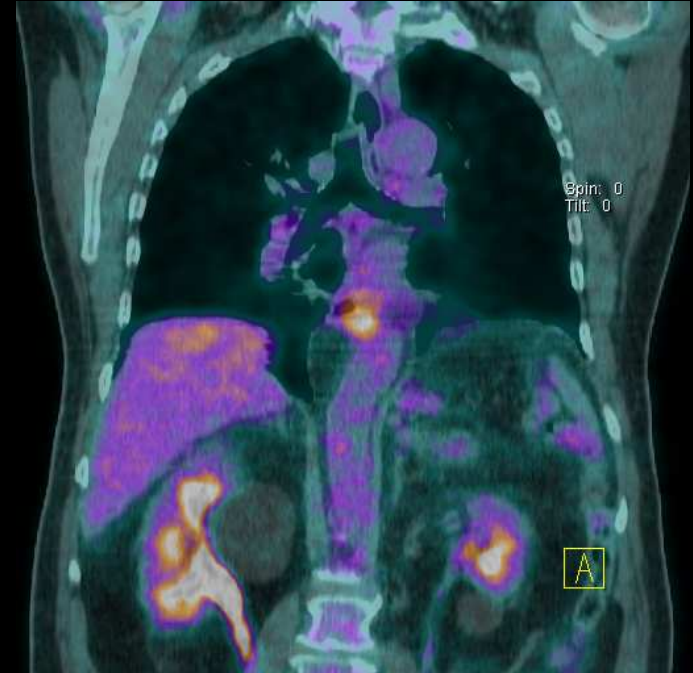
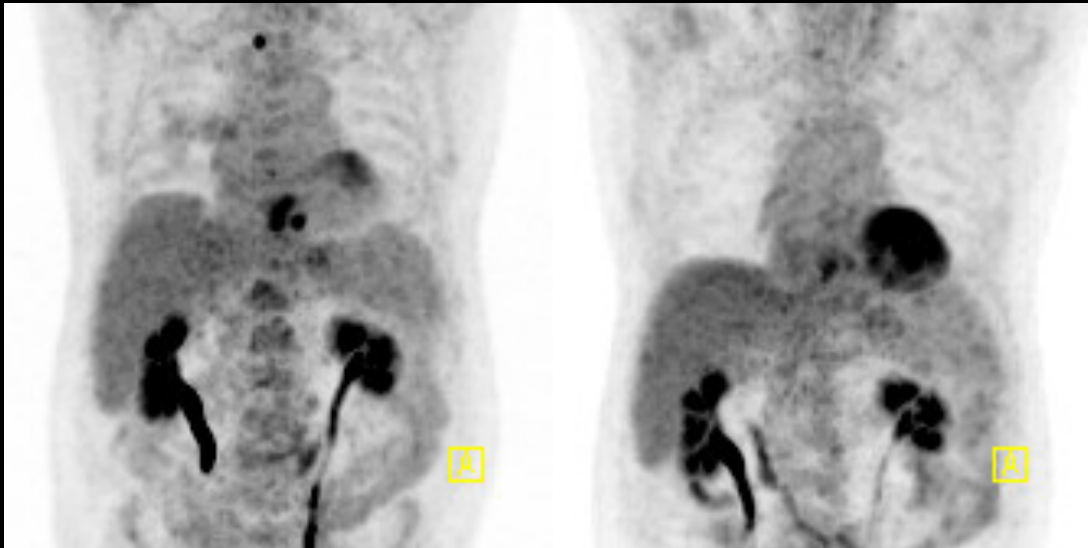
## Bilan initial, N+

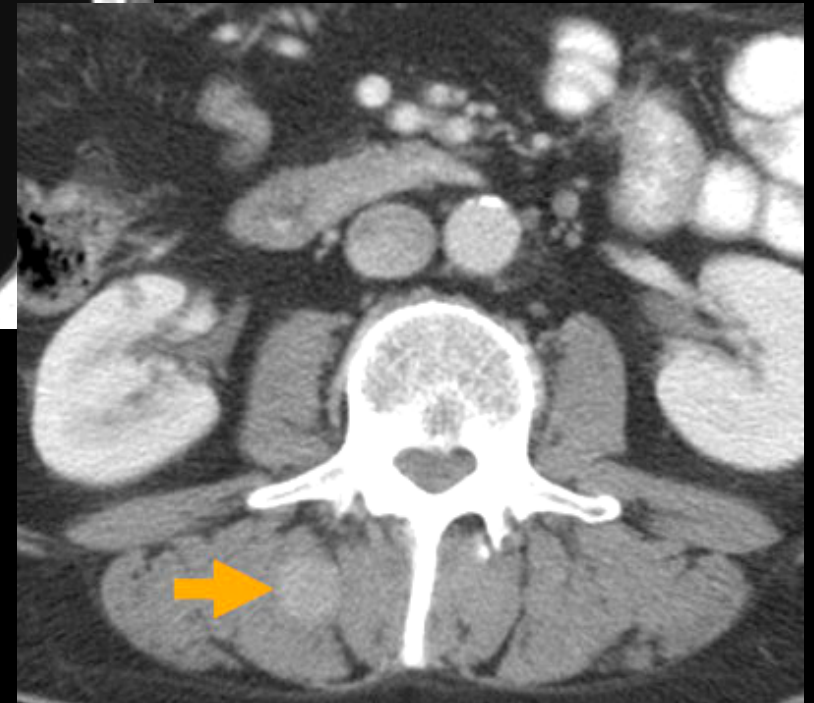
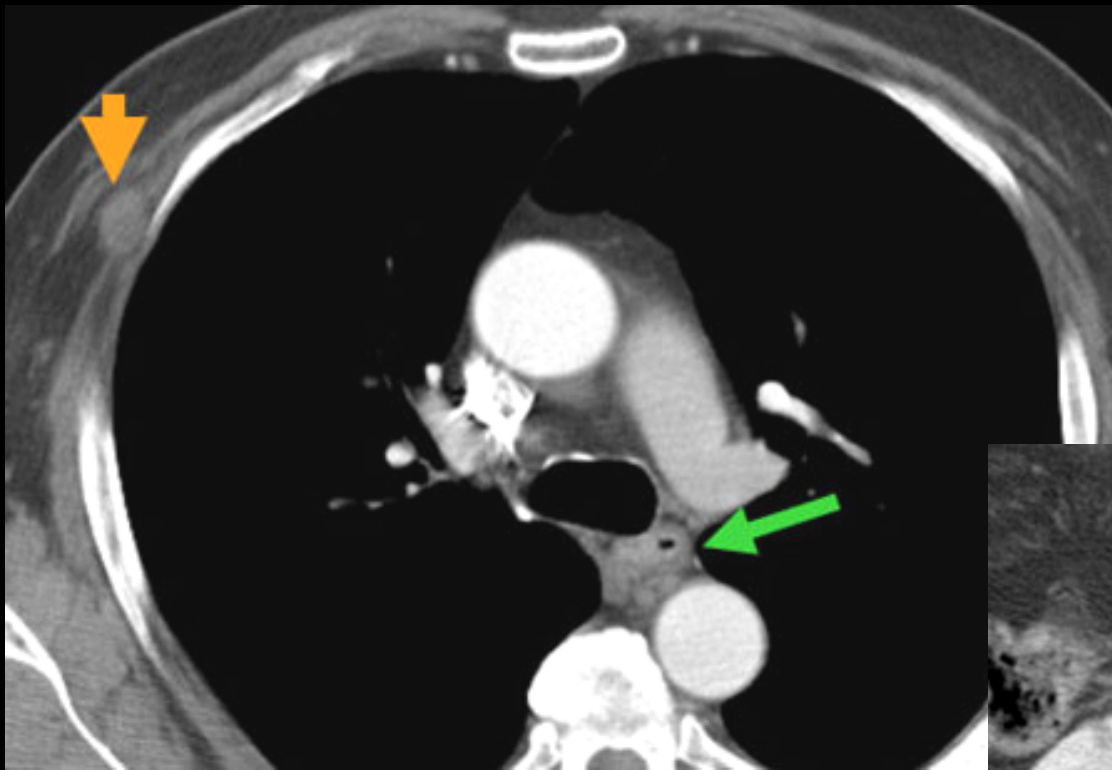


# Cancer oesophagien

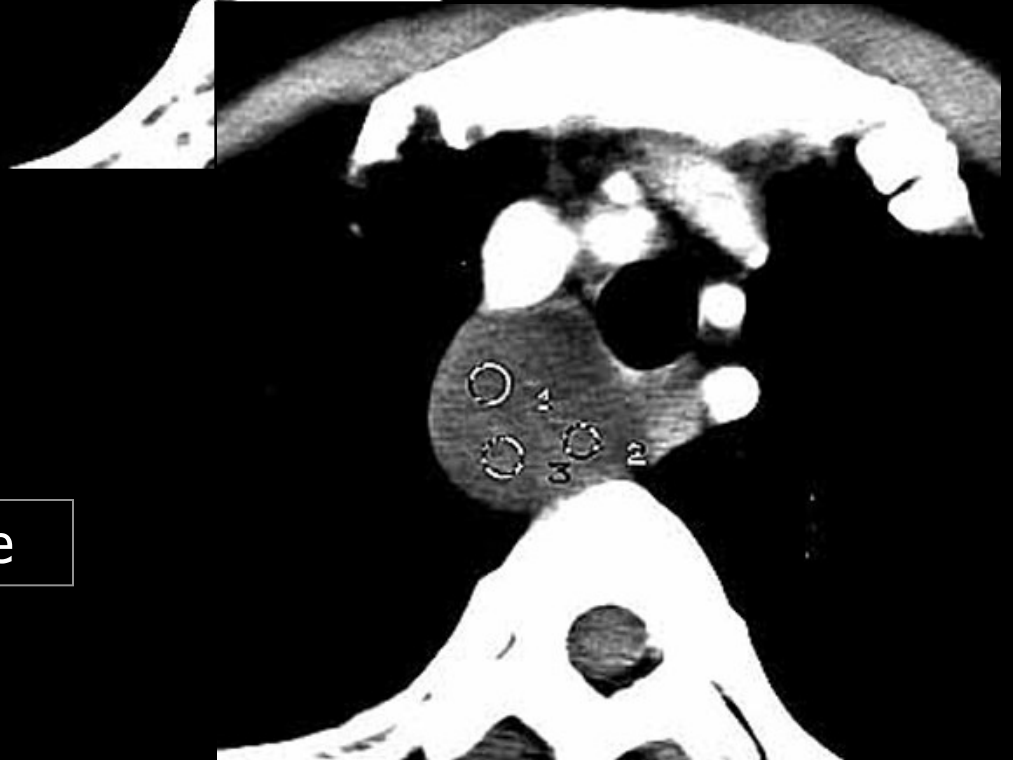
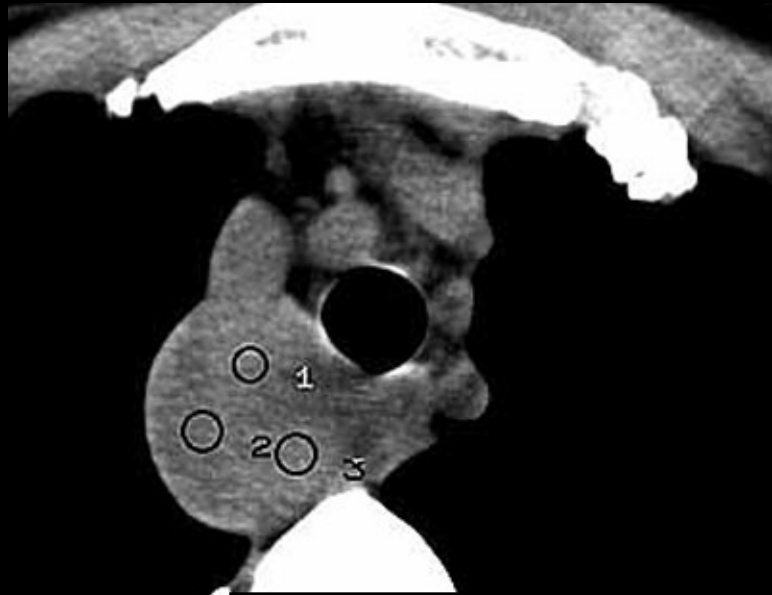
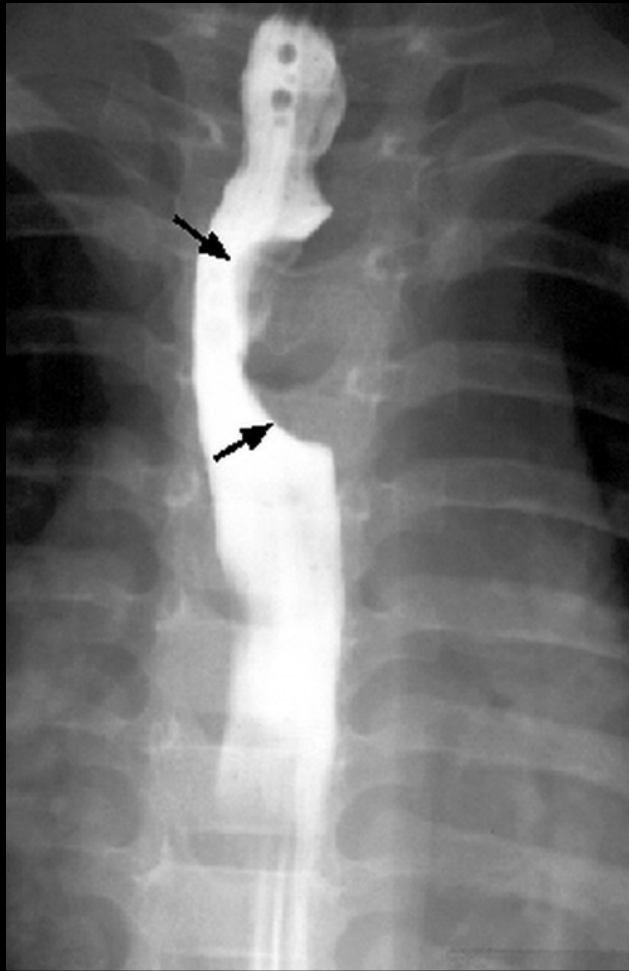
Bilan initial, N+

Après radio-chimiothérapie





Carcinome épidermoïde  
de l'œsophage  
et métastases



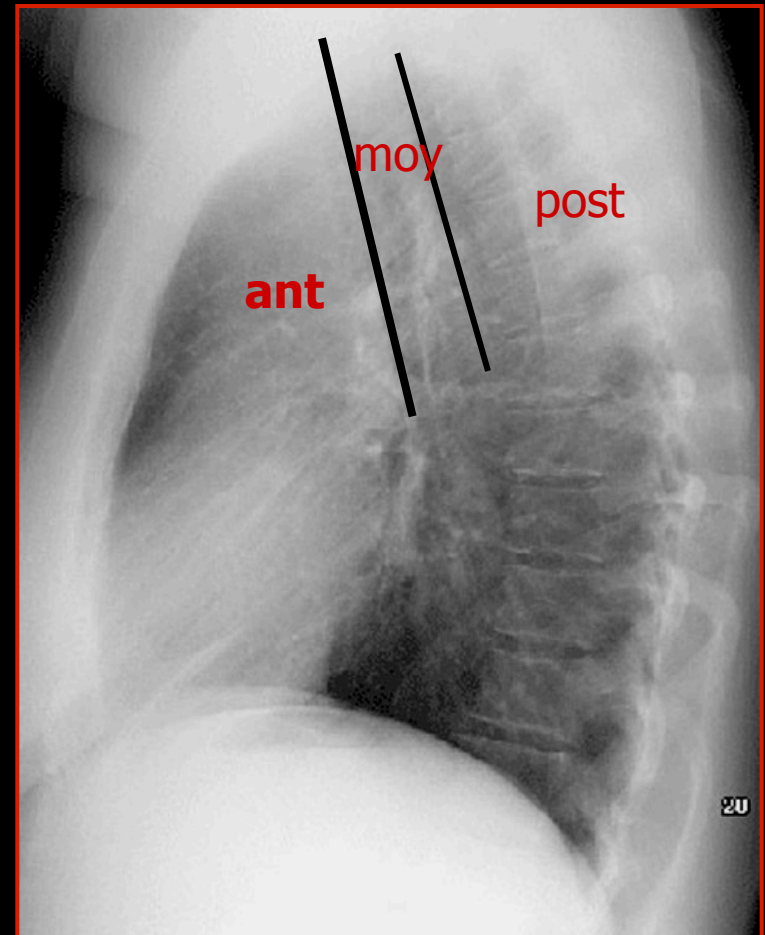
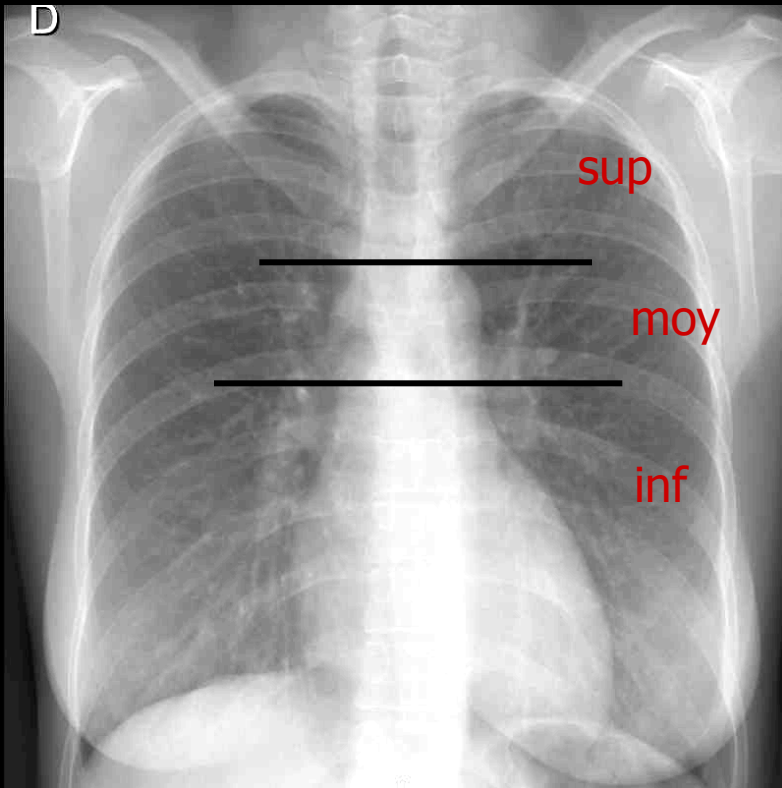
Duplication oesophagienne

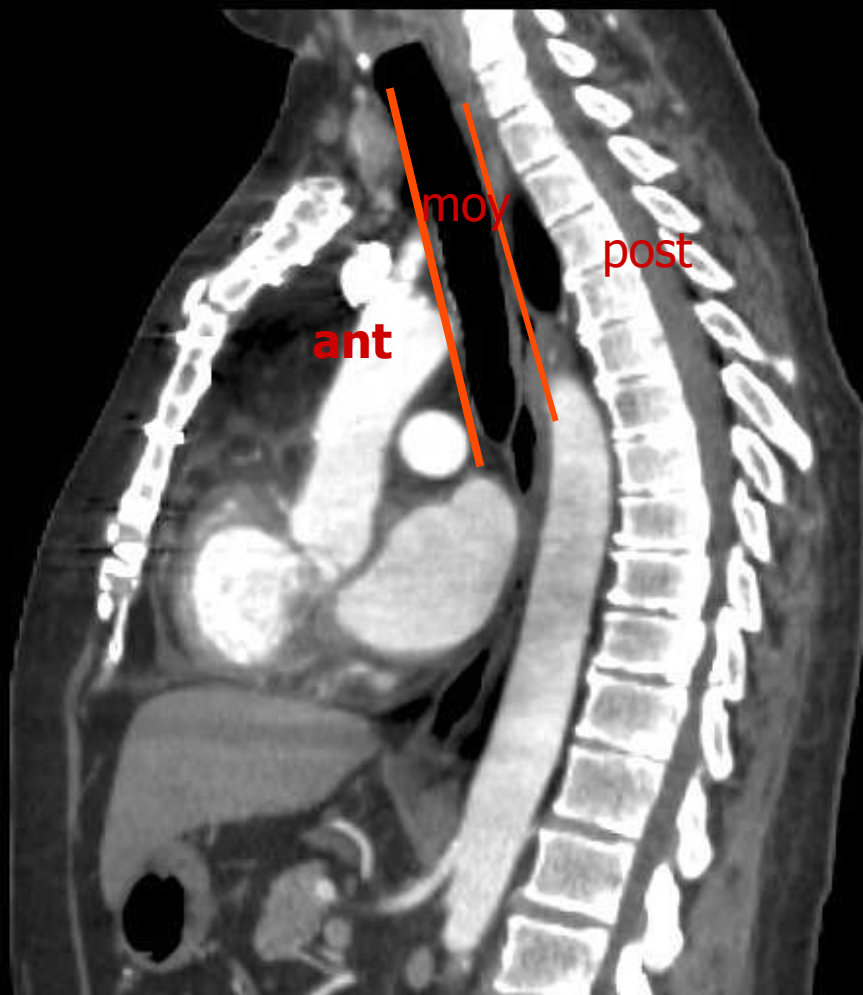
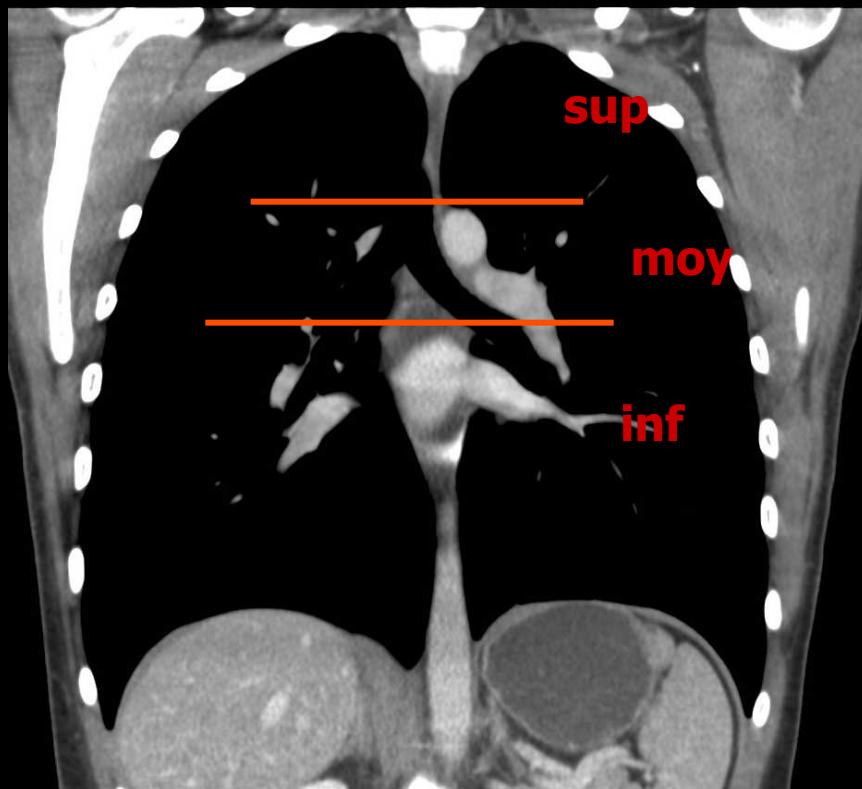


## 2/ RADIOANATOMIE DU MEDIASTIN

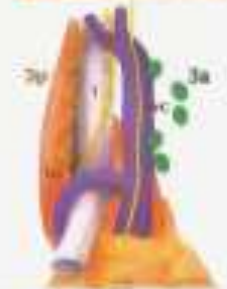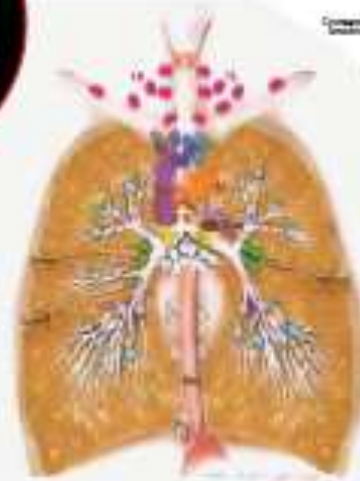- VAISSEAUX
- CŒUR
- ŒSOPHAGE
- **CHAINES GANGLIONNAIRES**

# Les régions du médiastin

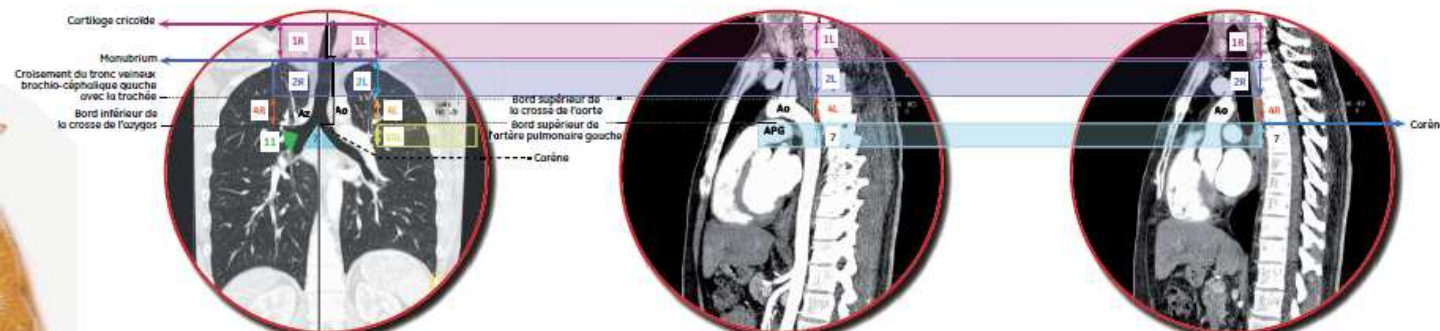




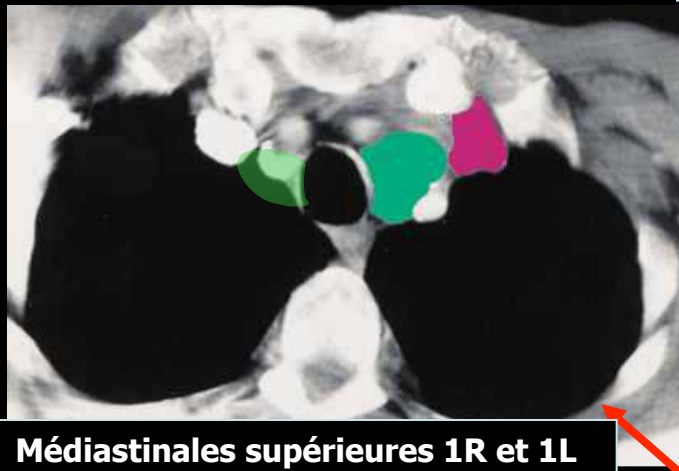
# Les loges ganglionnaires du médiastin



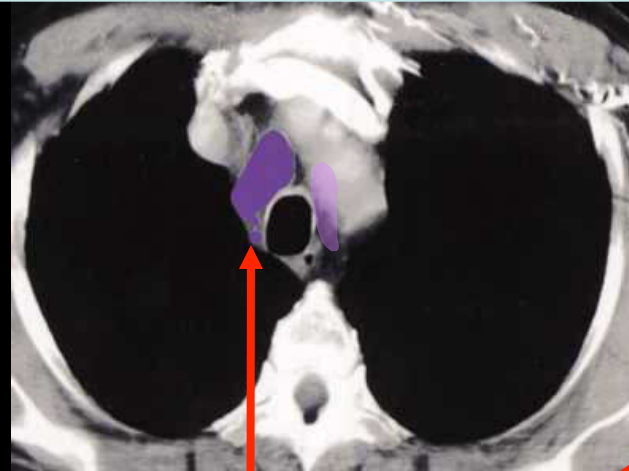
SUPRACLAVICULAR ZONE	
1	Low cervical, supraclavicular, and submandibular nodes
SUPERIOR MEDIASTINAL NODES	
Upper zone	
2a	Upper paratracheal right
2b	Upper paratracheal left
3a	Pretracheal
4a	Paratracheal
5a	Lower paratracheal right
5b	Lower paratracheal left
ARTERIC NODES	
Ar zone	
6	Subaortic
7	Para-aortic ascending aorta or pretracheal
INTRA-ARTERIAL MEDIASTINAL NODES	
Subcarinal zone	
7	Subcarinal
Lower zone	
8	Parasternal (right or left)
9	Parasternal (opposite)
HILAR MEDIASTINAL ZONE	
10	Hilar
11	Intra-aortic
PERIPHERAL ZONE	
12	Lower
13	Segmental
14	Subsegmental



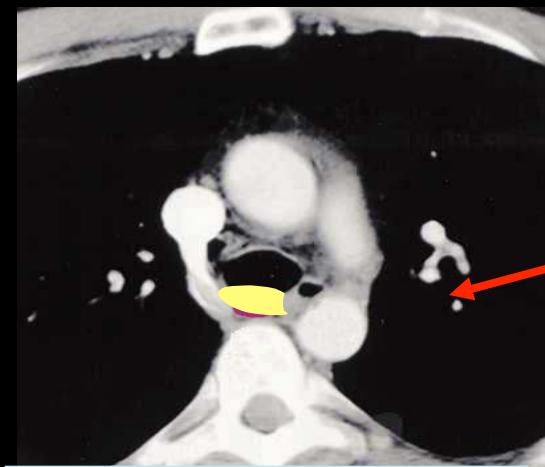
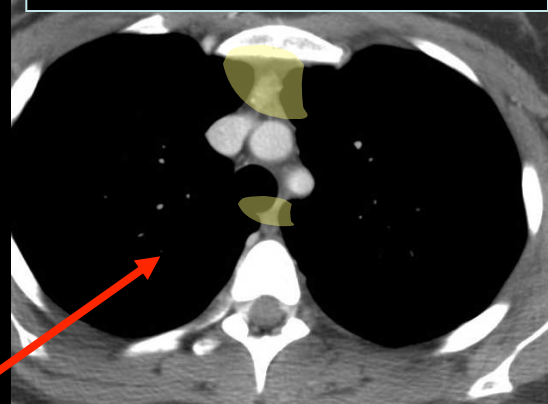
Paratrachéales supérieures 2R et 2L



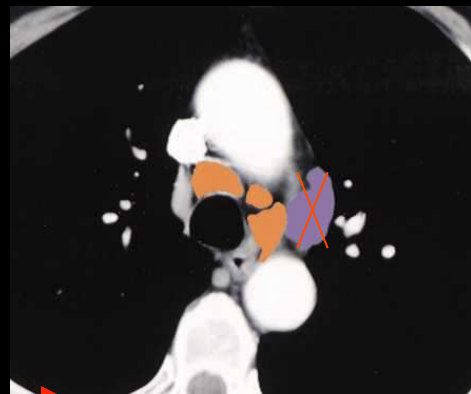
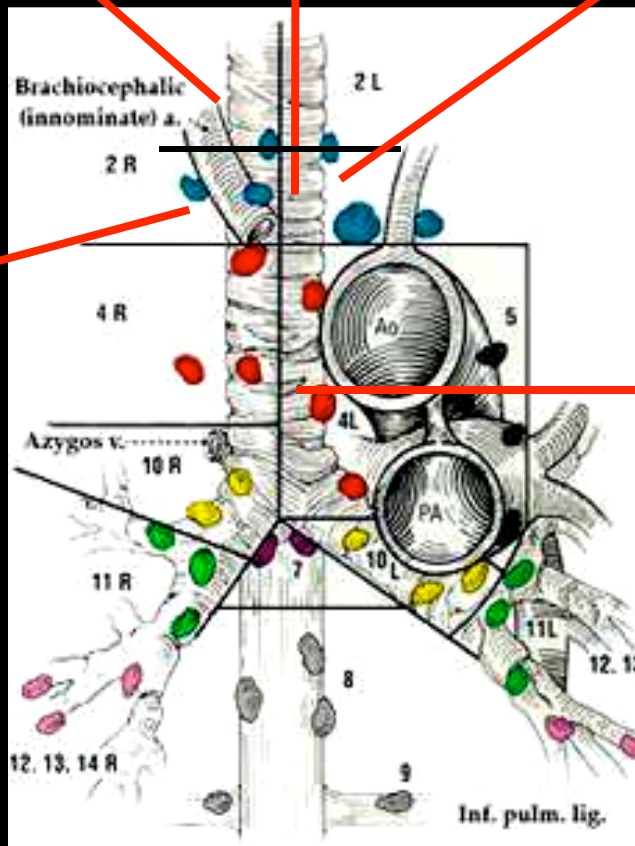
Médiastinales supérieures 1R et 1L



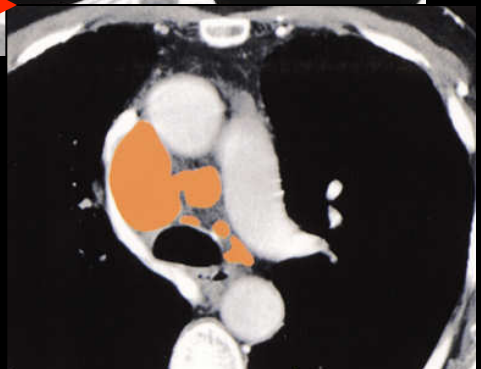Prévasculaire 3A  
rétrotrachéale 3R



rétrotrachéale 3R

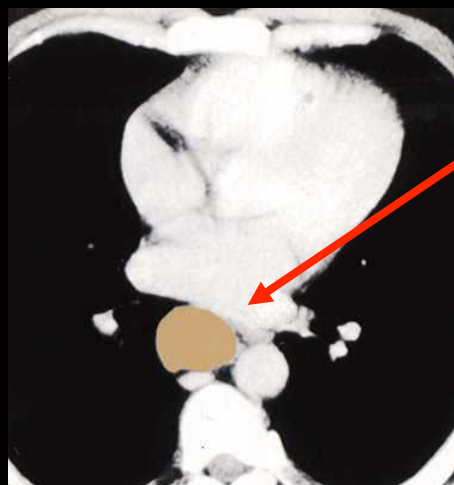
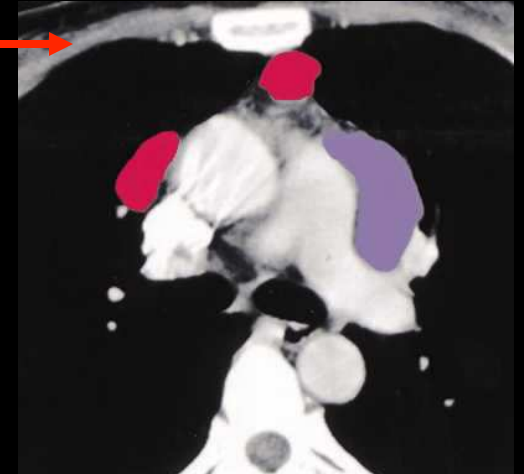
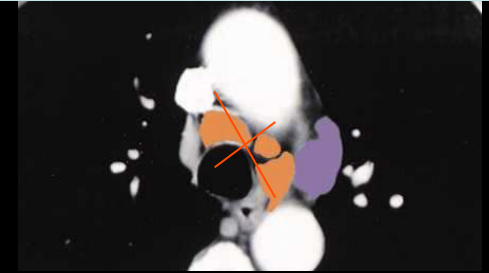
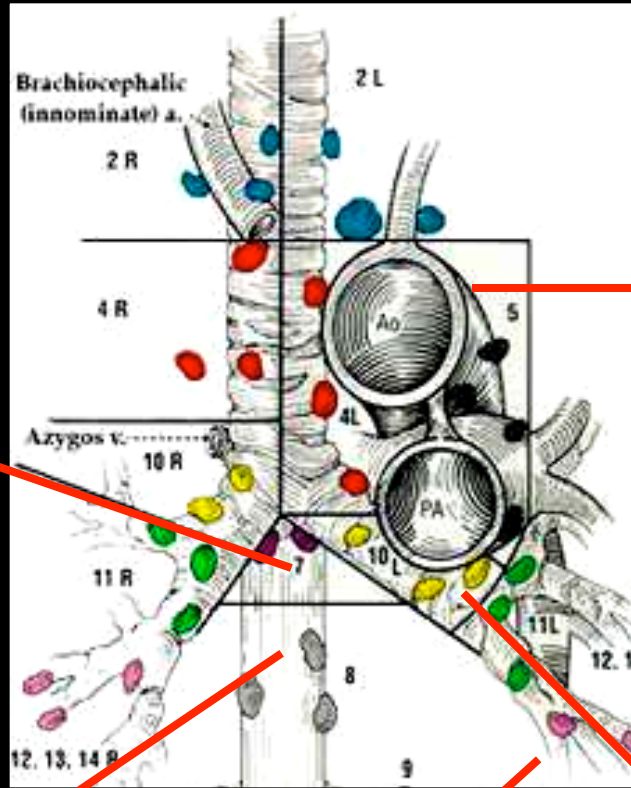
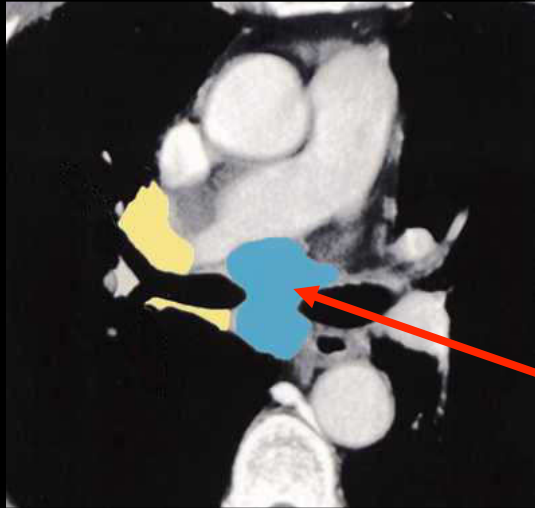


Paratrachéales inférieures  
droite et gauche 4R et 4 L

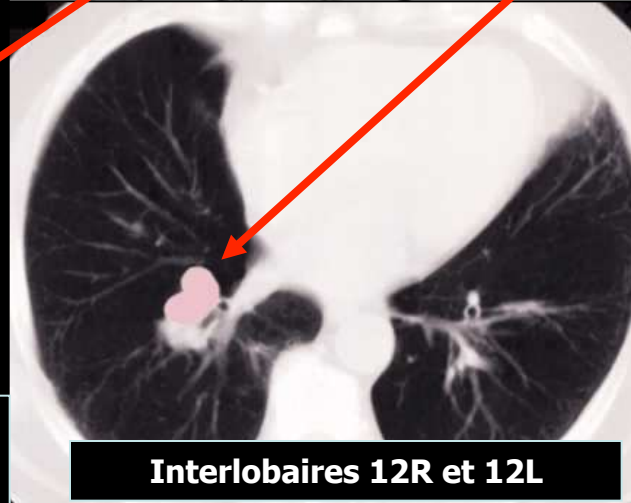


Fenêtre aorto pulmonaire 5

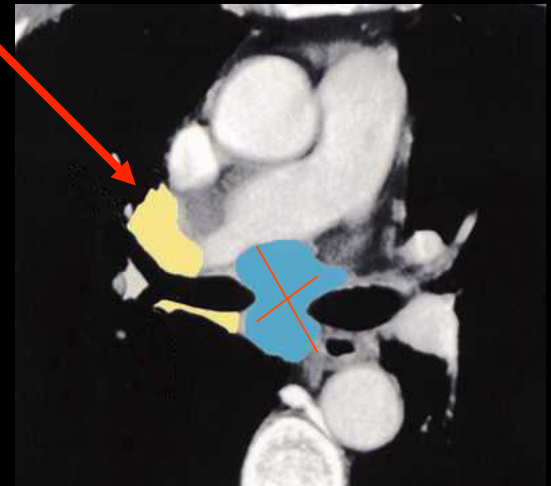
Sous carinaires 7



Para oesophagienne 8  
Œsophage sous carinaire



Interlobaires 12R et 12L









Hilaires 10R et 10L

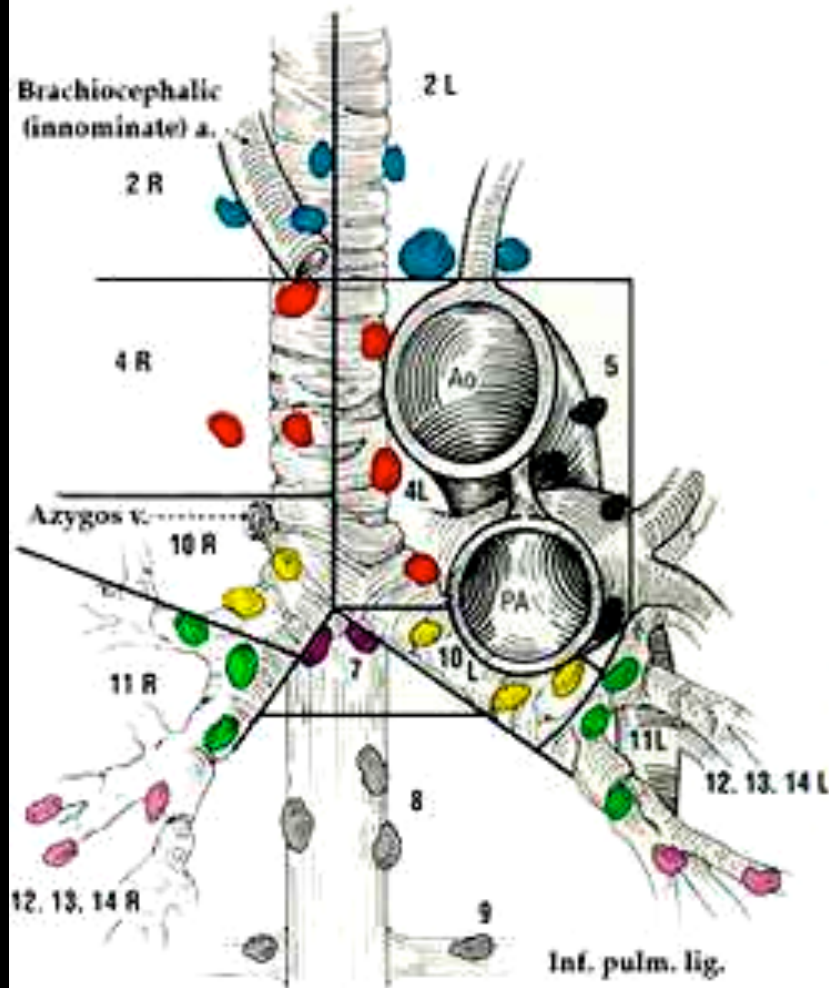
# Regional Nodal Stations For Lung Cancer Staging

## N<sub>1</sub> NODES

### SUPERIOR MEDIASTINAL NODES

### LOCATION

- |   |   |  |
|---|---|--|
|    | 2R Right upper paratracheal nodes       | Between intersection of caudal margin of innominate a. with trachea and the apex of the lung (supra-innominate nodes). |
|    | 2L Upper left paratracheal nodes        | Between top of aortic arch and apex of the lung (supra-aortic nodes).  |
|    | 4R Right lower paratracheal nodes       | Between intersection of caudal margin of innominate a. with trachea and cephalic border of azygos v.                   |
|    | 4L Left lower paratracheal nodes        | Between top of aortic arch and carina (medial to ligamentum arteriosum)  |
|    | 10R Right tracheo-bronchial angle nodes | From cephalic border of azygos v. to origin of RUL bronchus.   |
|  | 10L Left tracheo-bronchial angle nodes  | Between carina and LUL (medial to ligamentum arteriosum).  |



# CLASSIFICATION TNM

Tx	Tumeur prouvée par la cytologie bronchique, mais non visualisée ni à la radio, ni en bronchoscopie	T3	Tumeur <b>&gt;7cm</b> OU avec <b>envahissement direct</b> de: <ul style="list-style-type: none"> <li>o Paroi thoracique (y compris la tumeur de Pancoast Tobias)</li> <li>o Diaphragme</li> <li>o Nerf phrénique</li> <li>o Plèvre médiastinale</li> <li>o Péricarde pariétal</li> </ul> OU une tumeur dans la bronche souche <b>≤ 2 cm de la carène sans l'envahir</b> OU associée à une atélectasie ou une pneumopathie obstructive <b>du poumon entier</b> OU présence d'un <b>nodule(s) tumoral(s) distinct dans le même lobe</b>
T0	Pas de tumeur primaire	T4	Tumeur de toute taille envahissant <b>directement une des structures suivantes</b> : médiastin, cœur, gros vaisseaux, trachée, nerf laryngé récurrent, oesophage, corps vertébral, carène, OU nodule(s) tumoral(s) distinct <b>homolatéral dans un autre lobe</b>
Tis	Carcinome in situ		
T1	Tumeur de 3cm ou moins, entourée de parenchyme pulmonaire ou de plèvre, sans invasion des bronches lobaires proximales		
T1a	<b>≤ 2 cm</b>		
T1b	<b>2 cm et ≤ 3cm</b>		
T2	Tumeur <b>&gt;3cm</b> mais <b>≤ 7cm</b> ou tumeur <b>≤ 7cm</b> avec un des critères: <ul style="list-style-type: none"> <li>o Envahissement de la <b>plèvre viscérale</b></li> <li>o Associée à une <b>atélectasie ou pneumonie obstructive</b> pouvant s'étendre à la région hilare mais n'intéressant <b>pas tout un poumon</b></li> <li>o Tumeur envahissant la bronche lobaire principale mais <b>≥ 2cm de la carène</b></li> </ul>		
T2a	<b>&gt;3cm</b> mais <b>≤ 5cm</b>		
T2b	<b>&gt;3cm</b> mais <b>≤ 7cm</b>		



# Détermination du N

- Nx: non évalué
- N0: absence d'envahissement ganglionnaire
- N1: Envahissement ganglionnaire **intra-pulmonaire, péribronchique et/ou hilair homolatéral** y compris par envahissement direct
- N2: Envahissement ganglionnaire **médiastinal homolatéral et/ou sous carénaire**
- N3: Envahissement ganglionnaire **médiastinal et hilair controlatéral, sus claviculaire, scalène, homo- ou controlatéral**

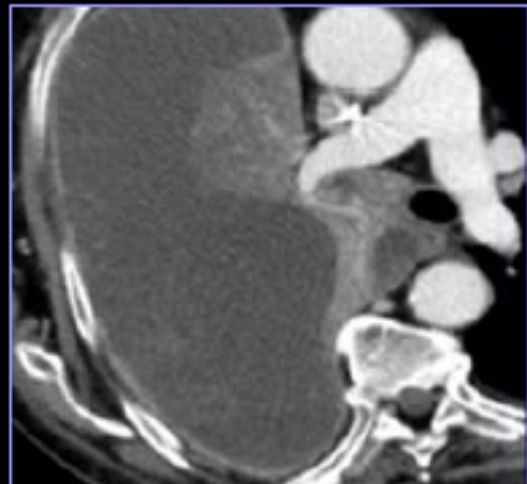Rusch VW, The IASLC Lung Cancer Staging Project: proposals for the revision of the N descriptors in the forthcoming seventh edition of the TNM classification for lung cancer. J Thorac Oncol 2007 ; 2 : 603-12

**Rôle respectifs du PET CT +++ et de la médiastinobiopsie pour le diagnostic d'envahissement des ganglions contro-latéraux**



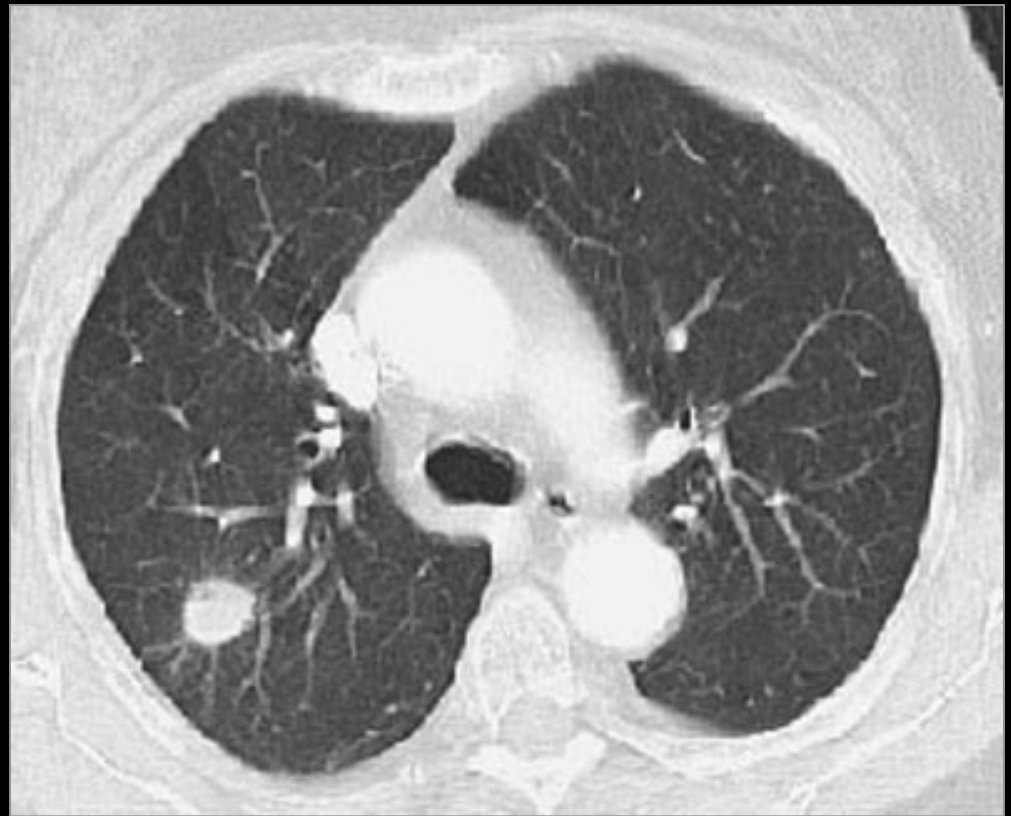
# Détermination du M

- Peu modifiée
- M0: pas de métastase
- M1: métastase à distance
- Distinction entre:
  - M1a: métastases pulmonaires
    - Tumeur avec nodules pleuraux ou épanchement pleural ou péricardique malin
    - Nodule(s) tumoral distinct dans un lobe controlatéral,
  - M1b: métastases extra-pulmonaires

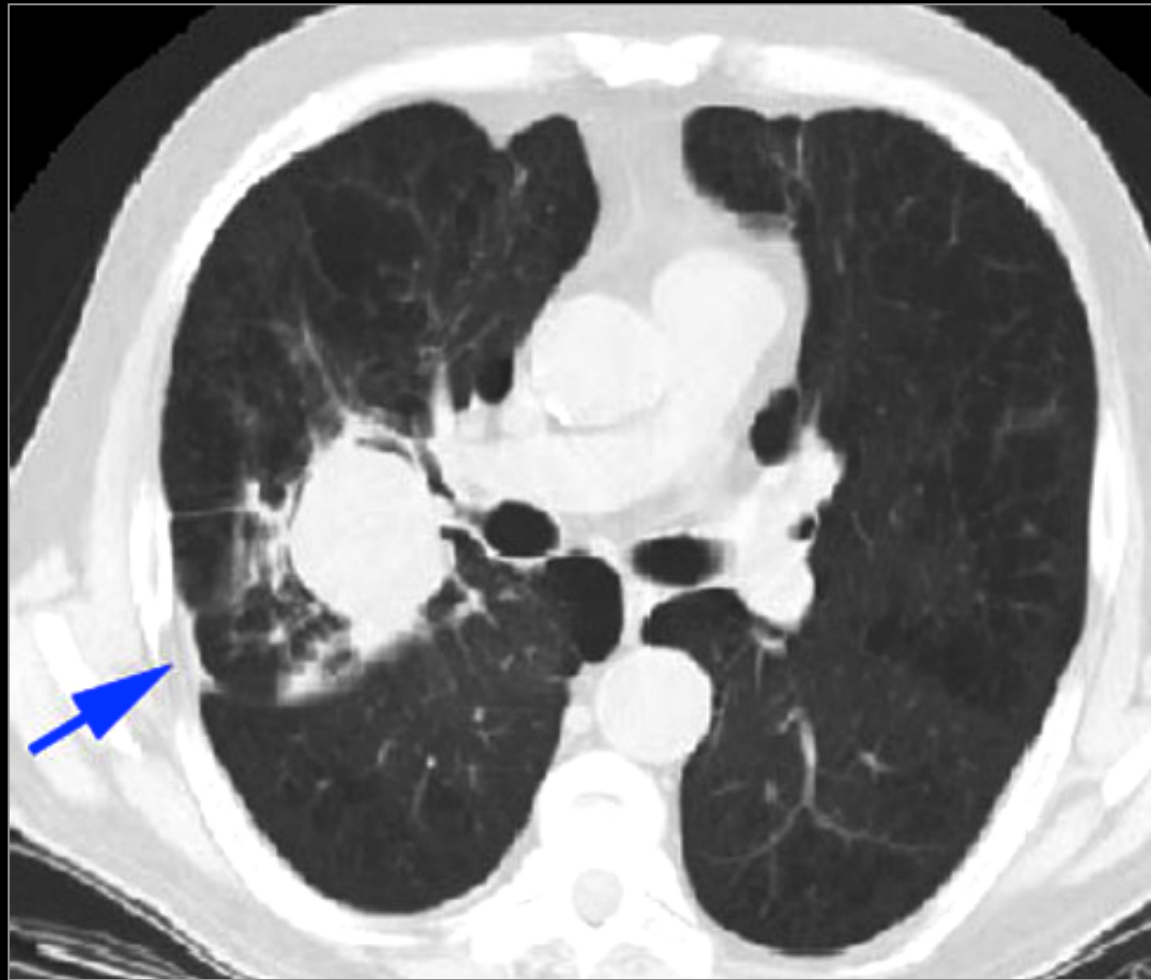


# Quelques exemples

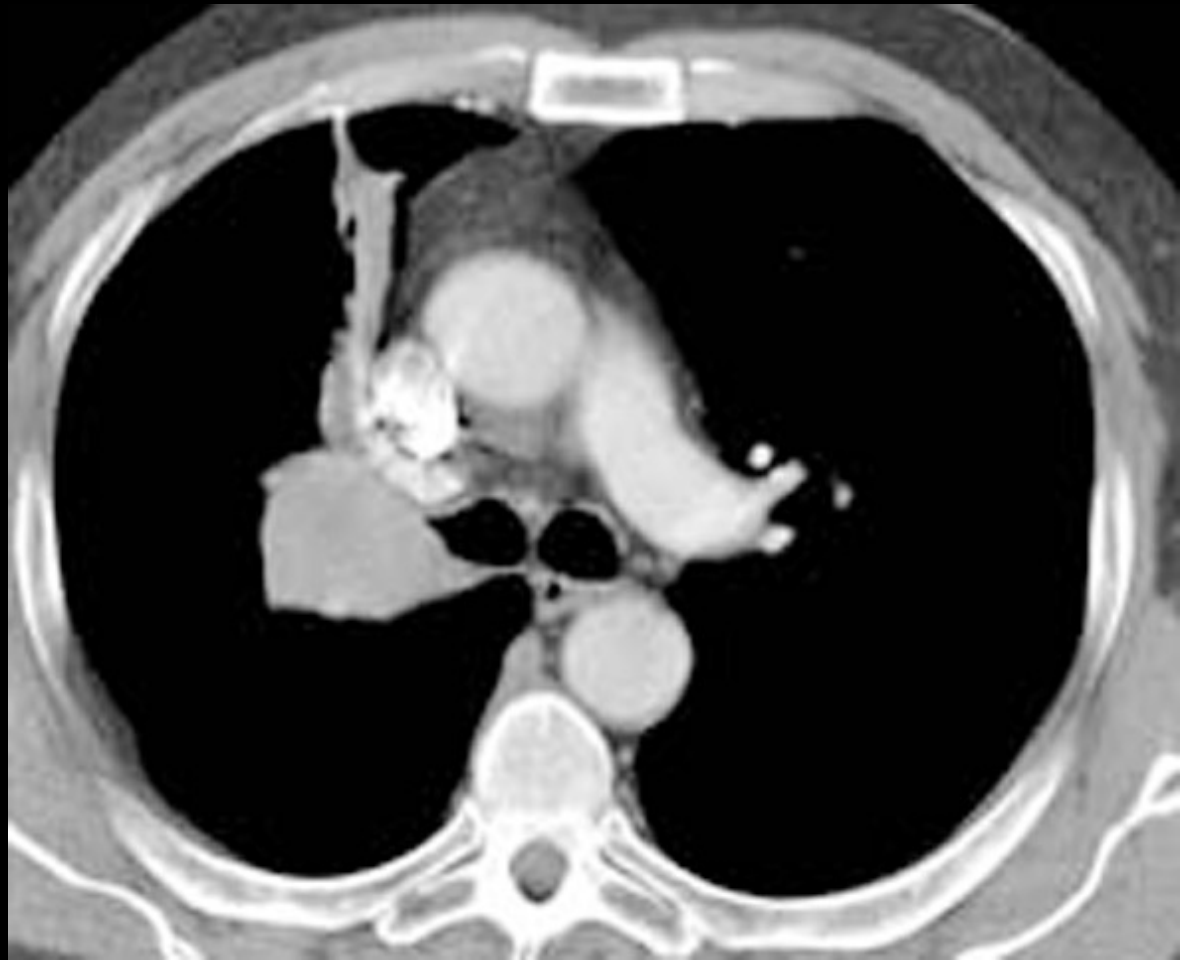**T1a**



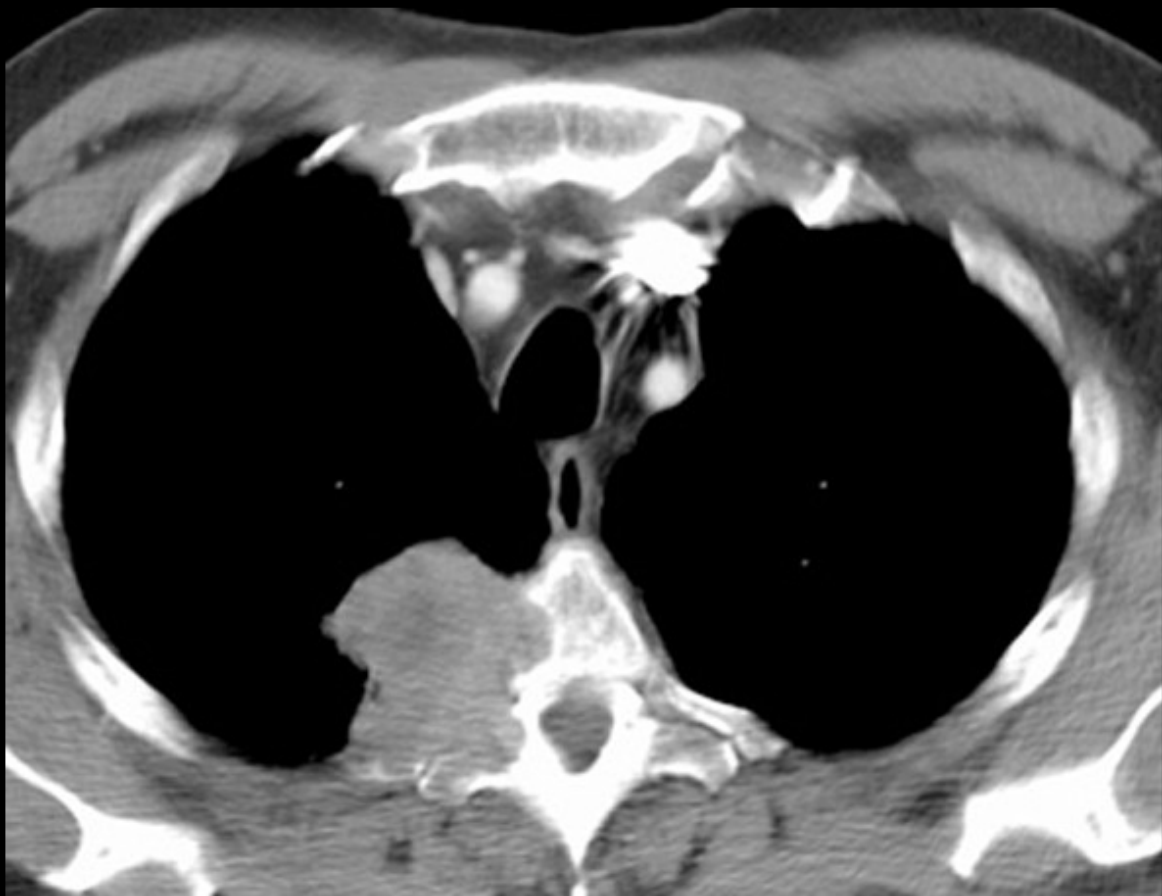
**T2b**

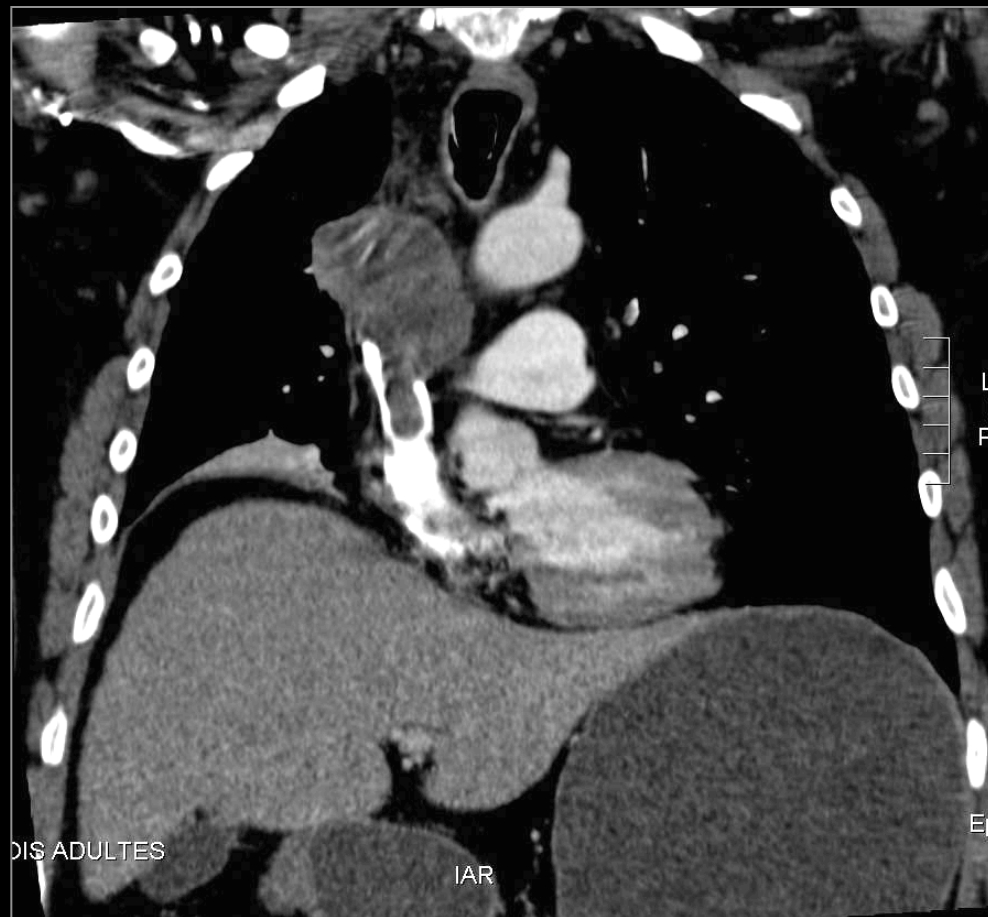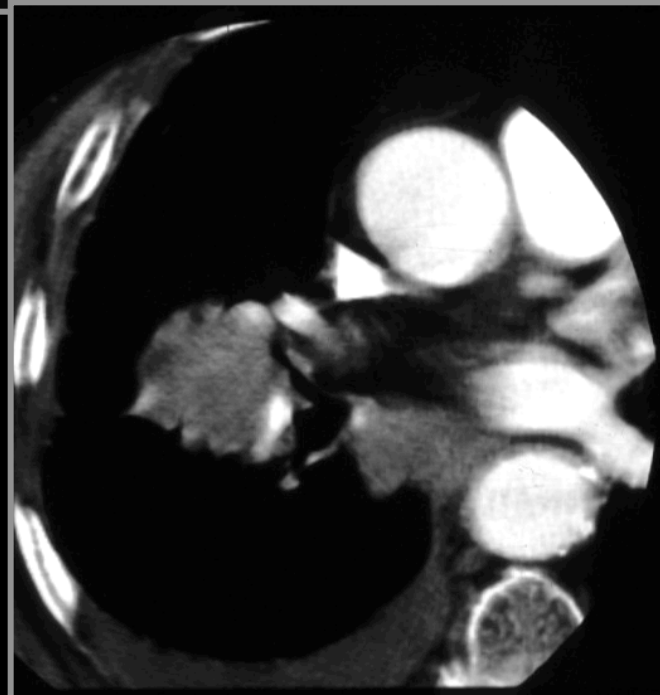
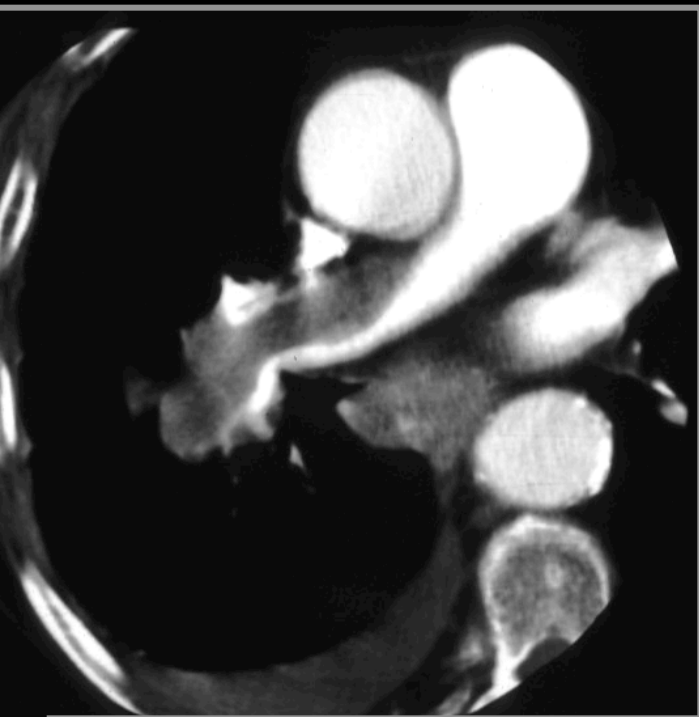


**T3**



**T4**





**Extension vasculaire T4**

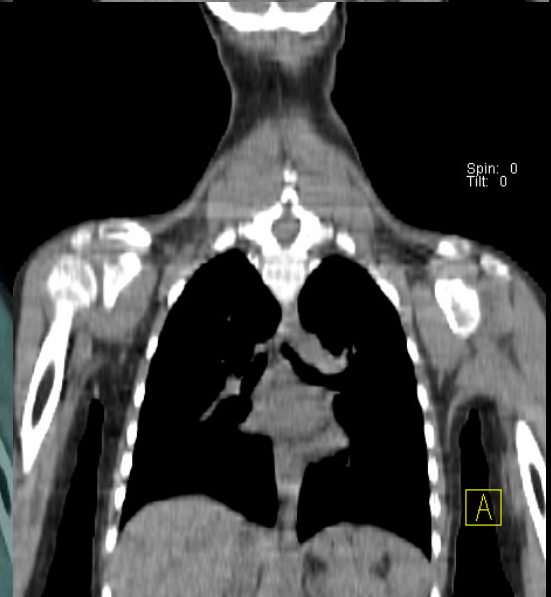
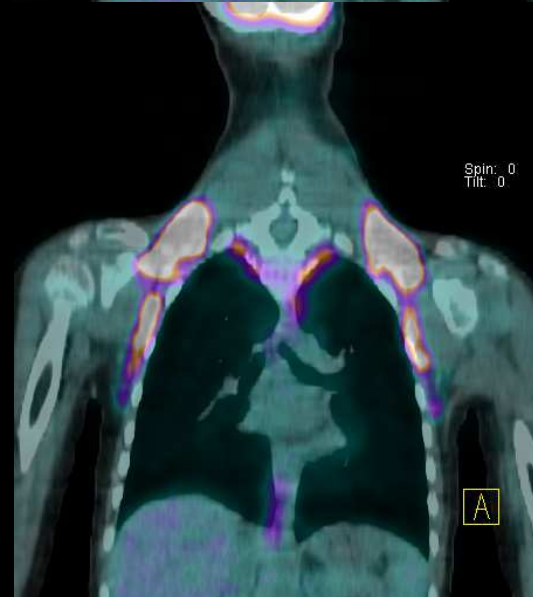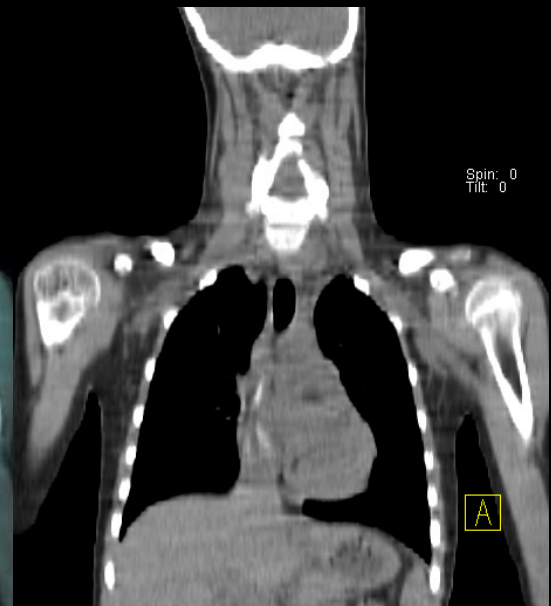
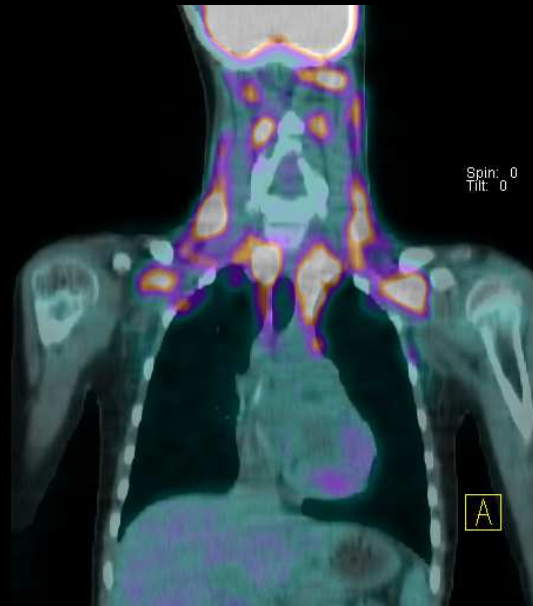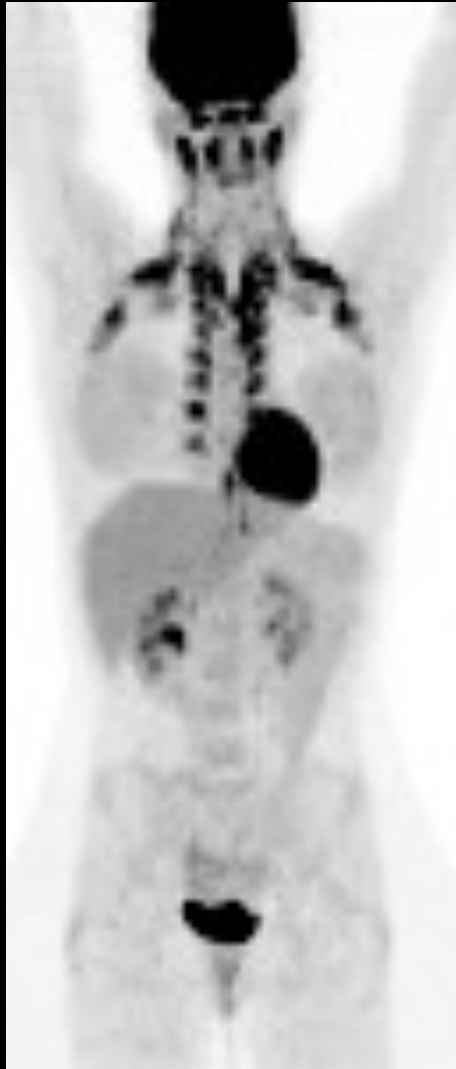## Principaux changements 1997 vs 2009 :

1. **T4 nodule même lobe → T3**
2. **T4 dissémination pleurale ou péricardique → M1**
3. **M1 nodule supplémentaire autre lobe ipsilatéral → T4**

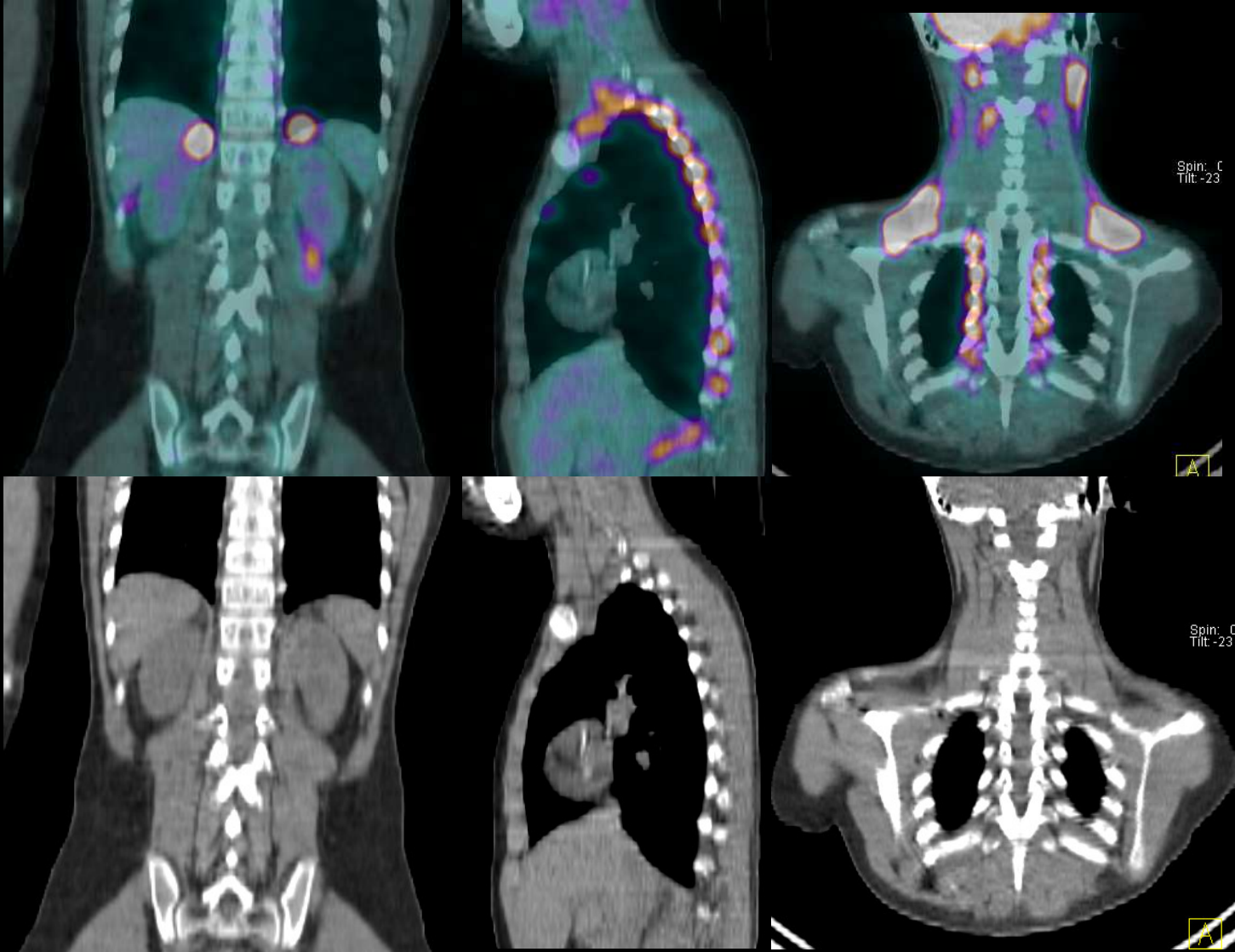
- **Reclasser la dissémination pleurale de T4 à M1a**
- **Classer la présence de nodules controlatéraux en M1a**
- **Classer la présence de métastases à distance en M1b**

# Pitfalls

## Graisse brune

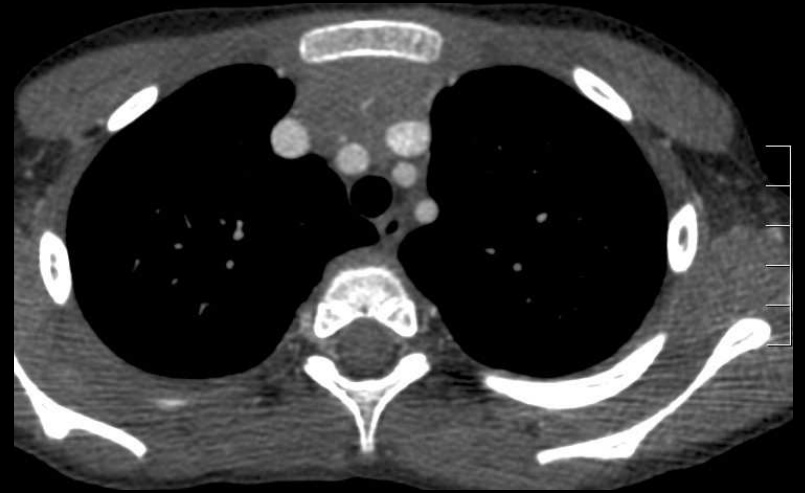
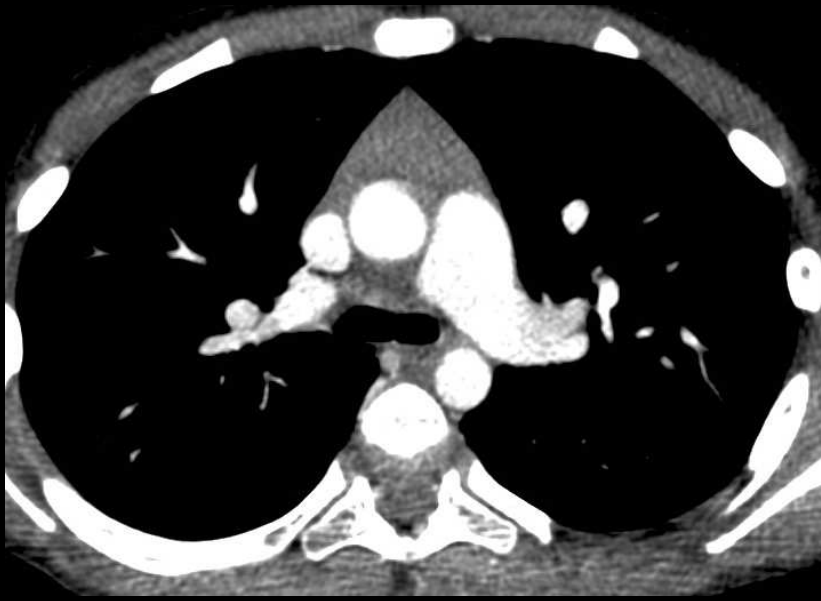
# Graisse brune

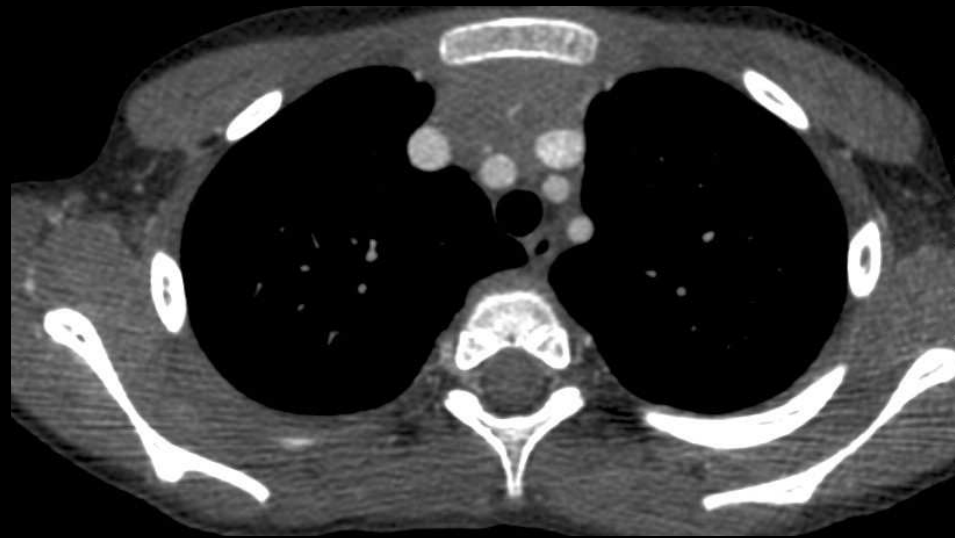

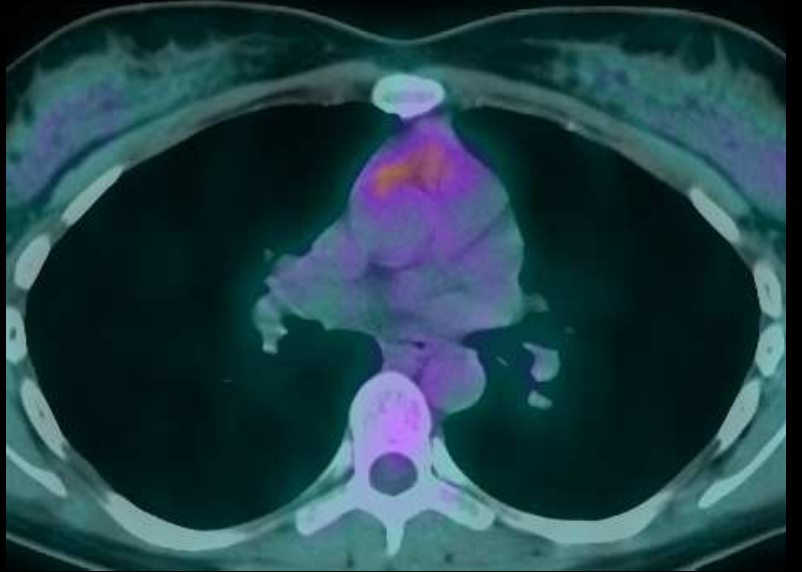
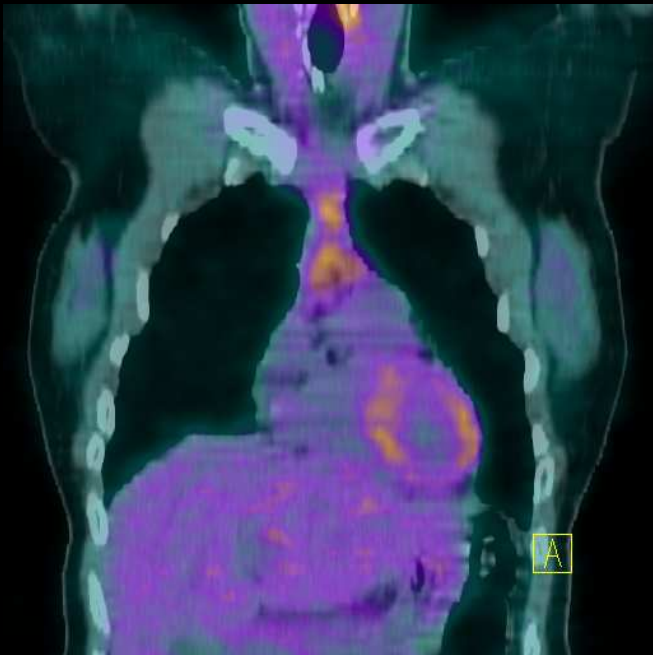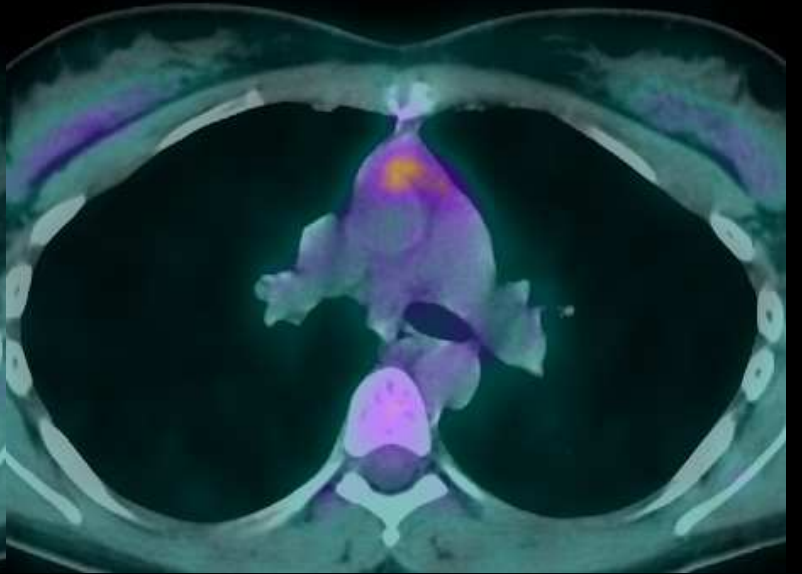
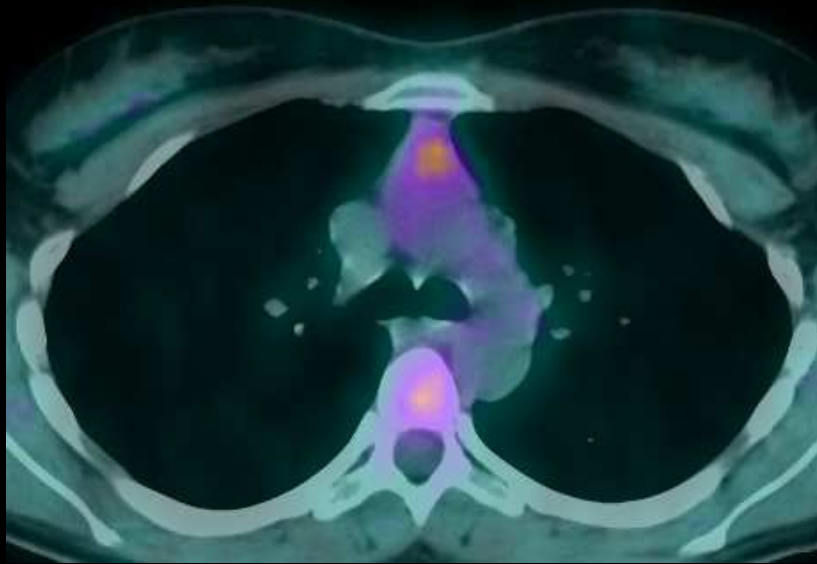


**UN PEU DE PATHOLOGIE ET  
VARIATIONS ANATOMIQUES...**



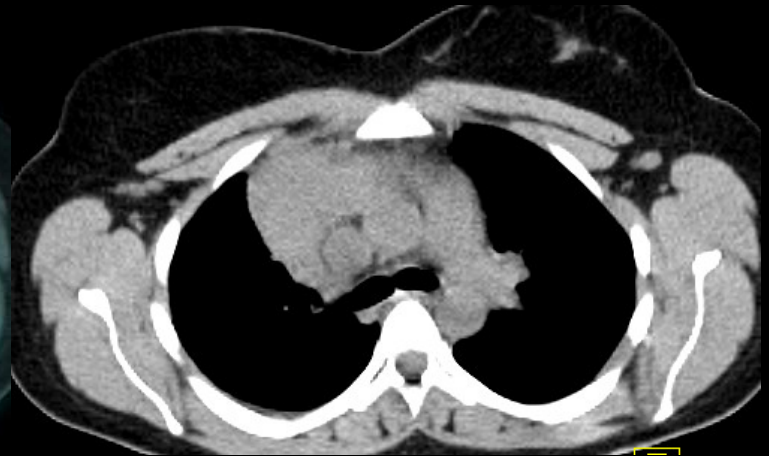
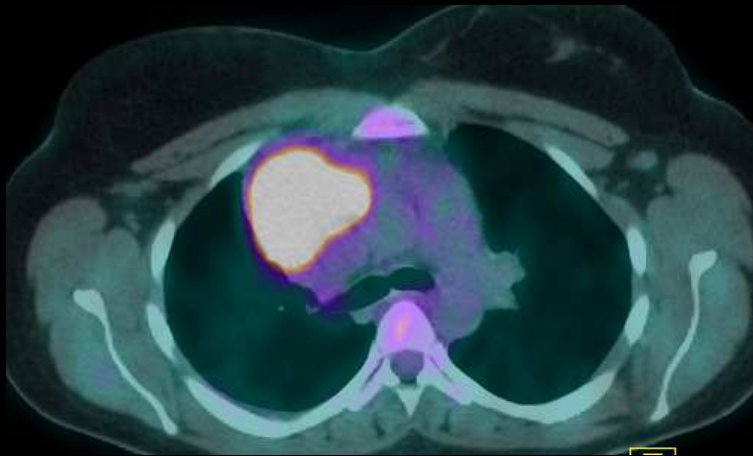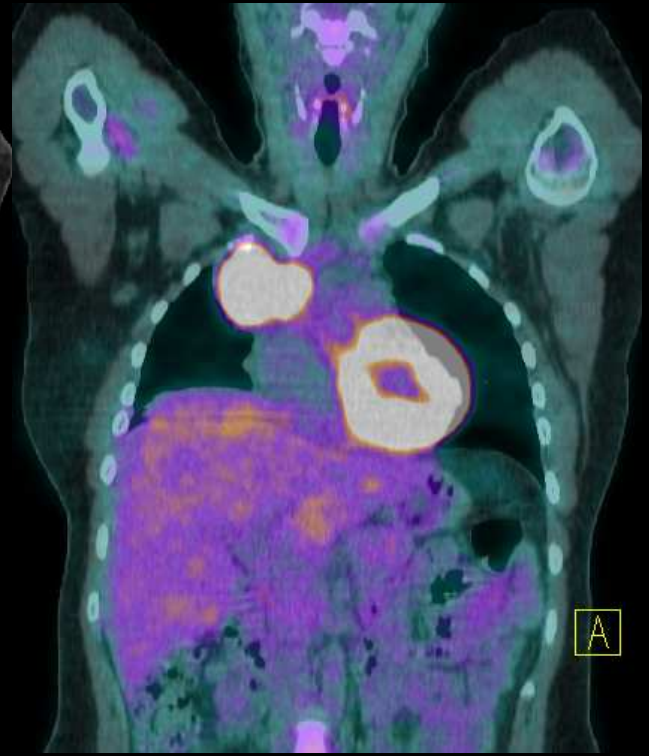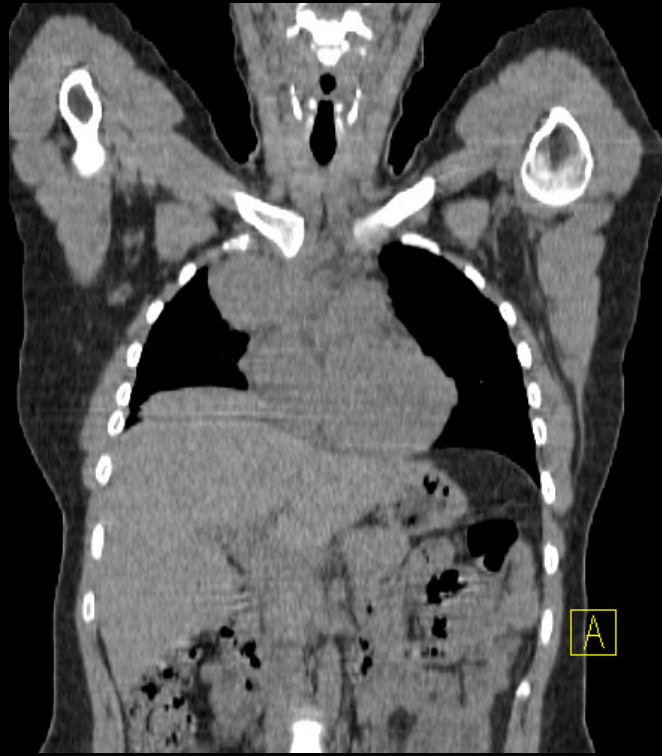
**Thymus**

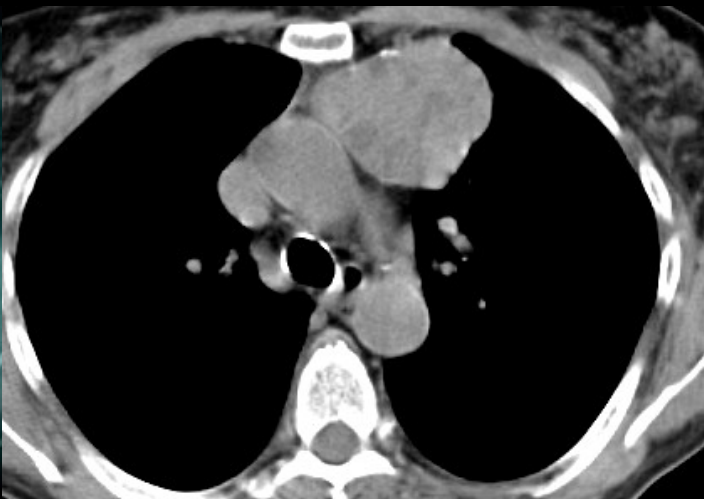
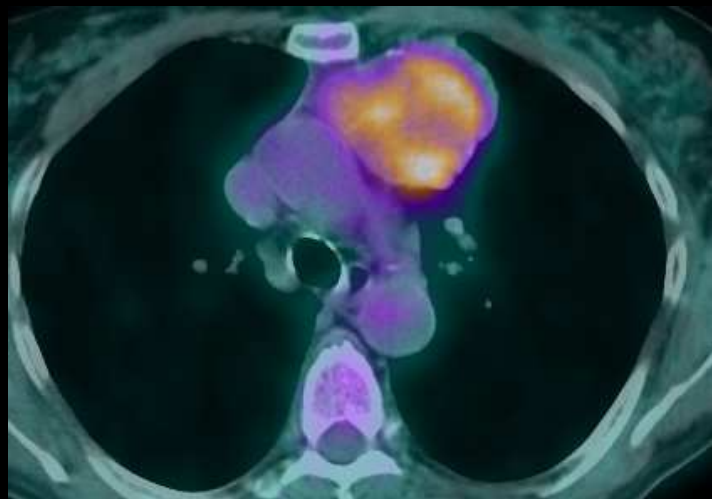
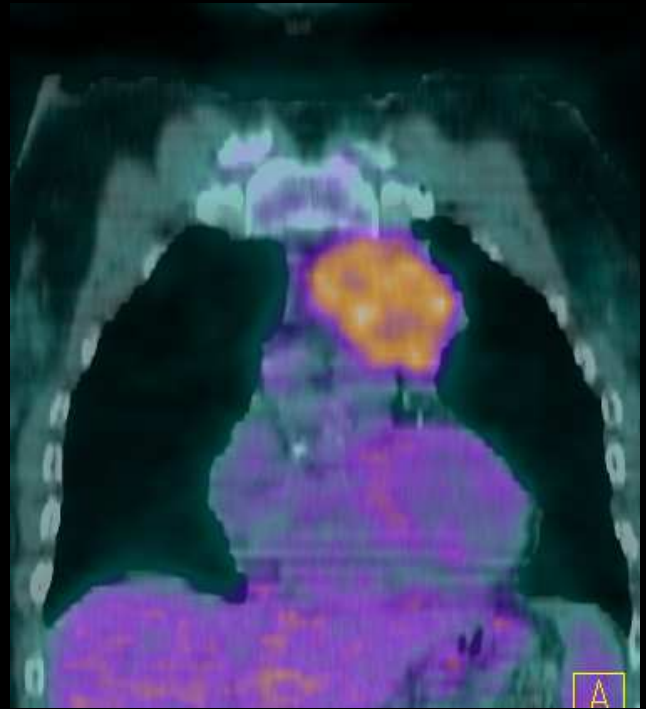
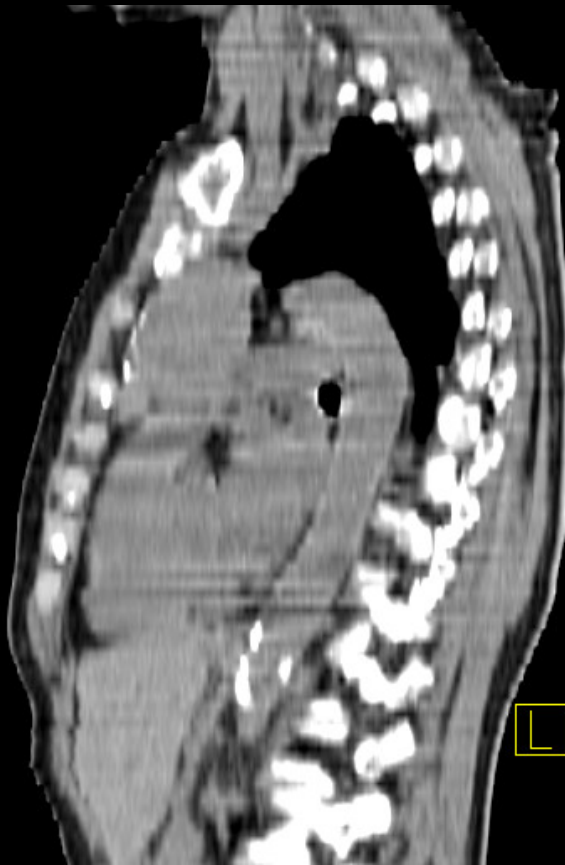
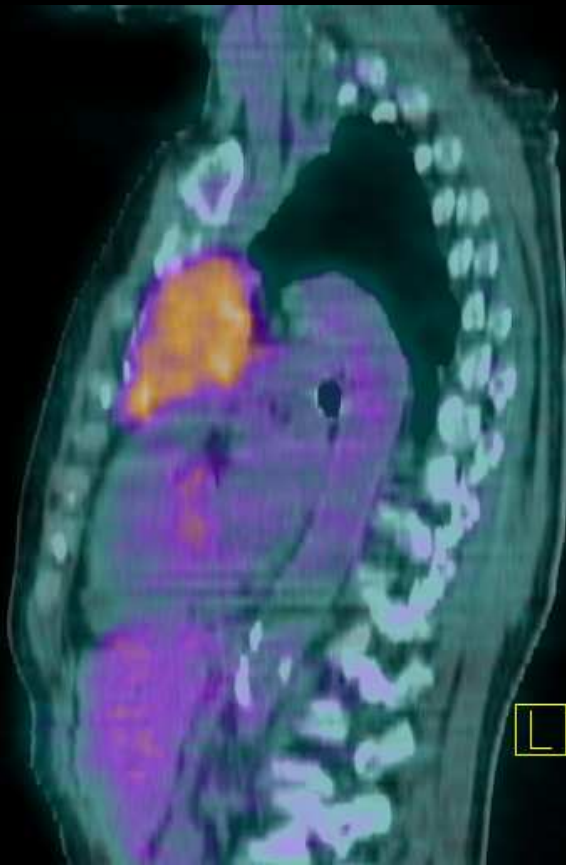



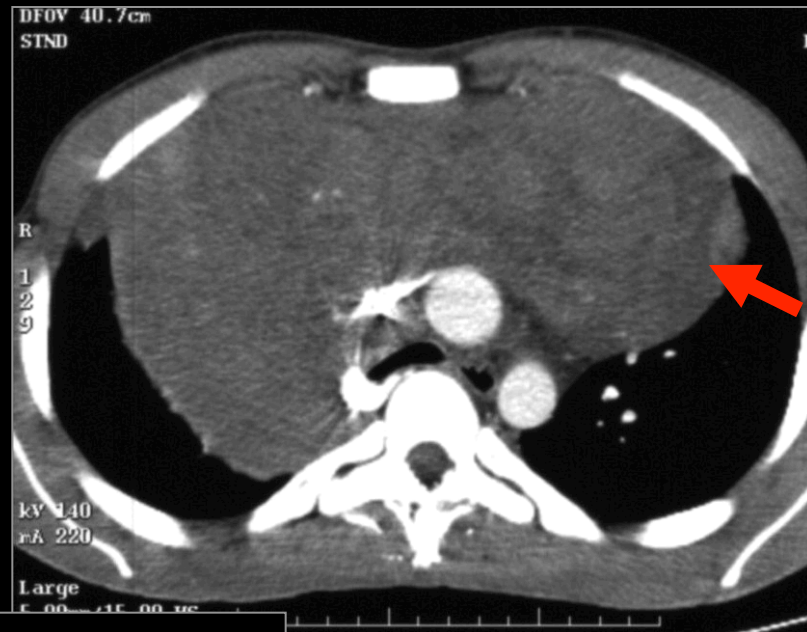
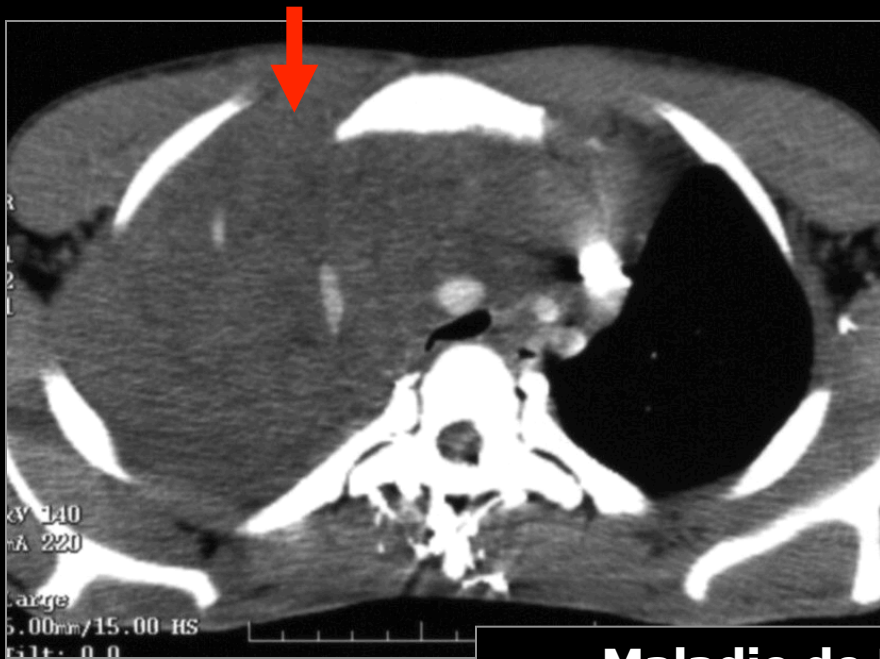**Reliquat thymique**

**Thymome**

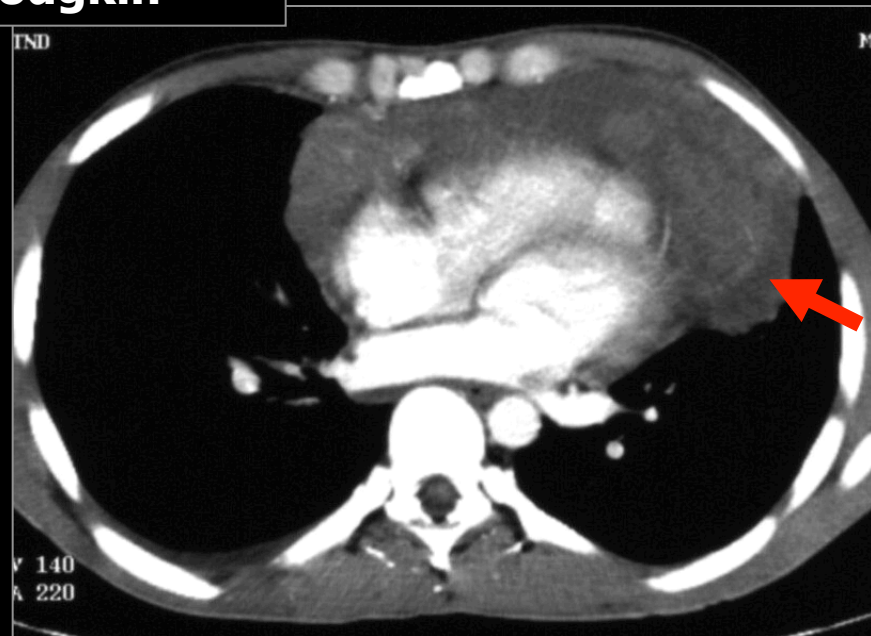
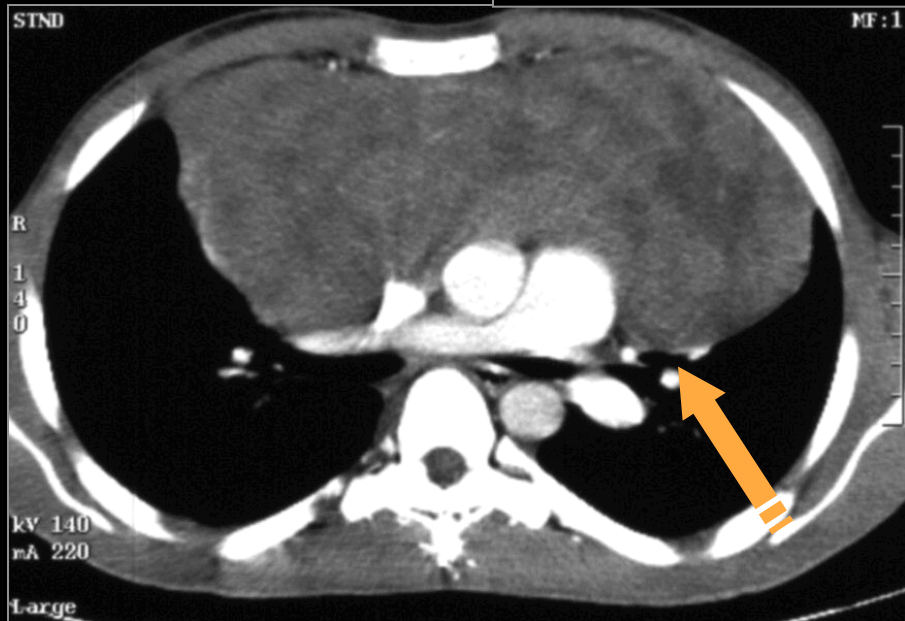


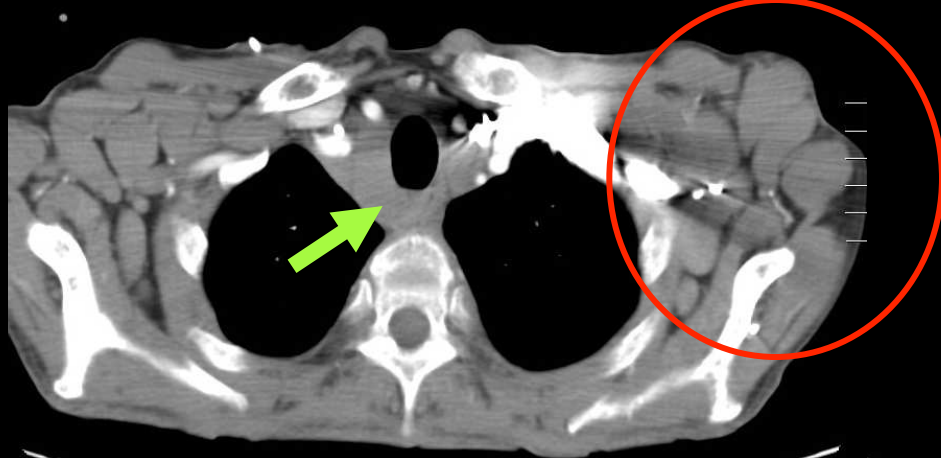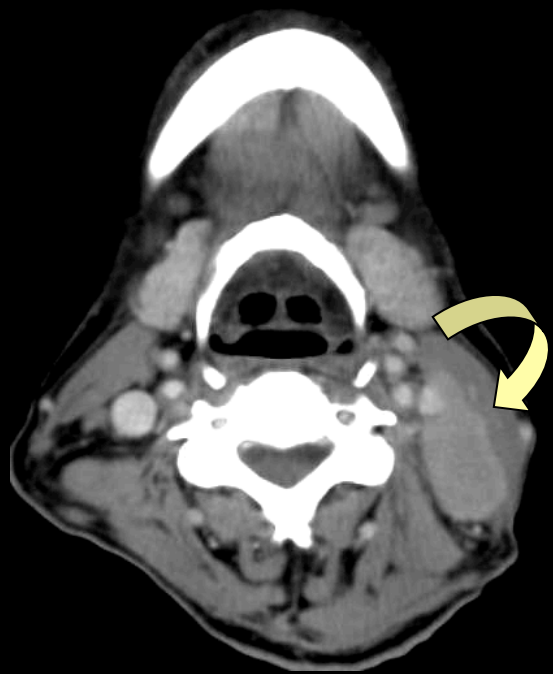


**Thymome**

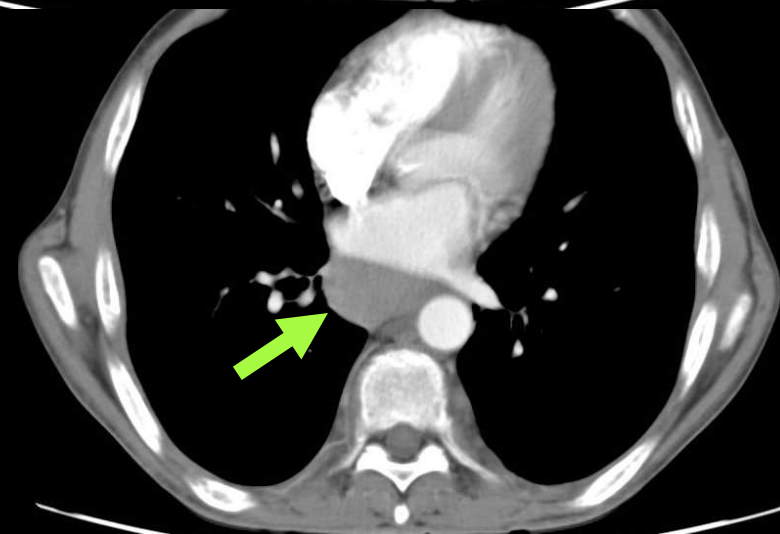
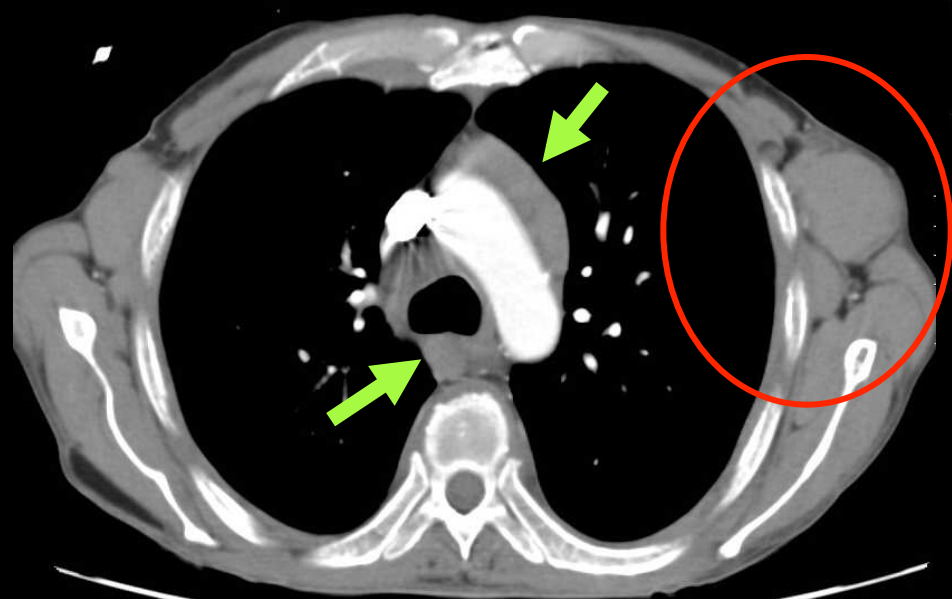
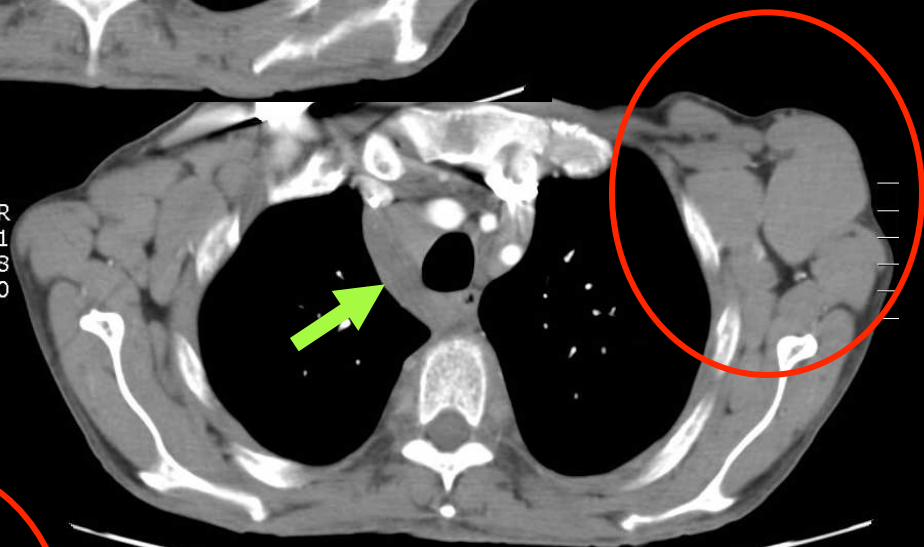


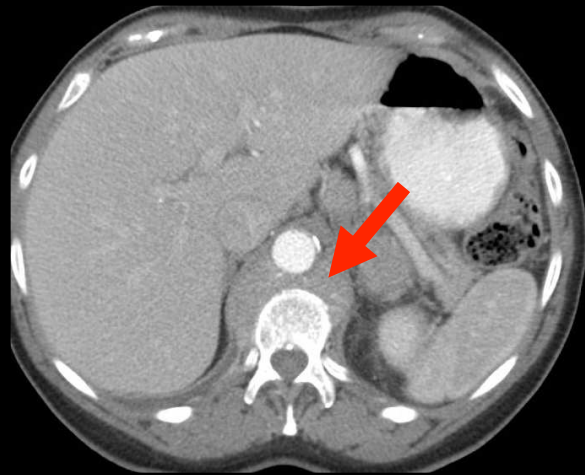
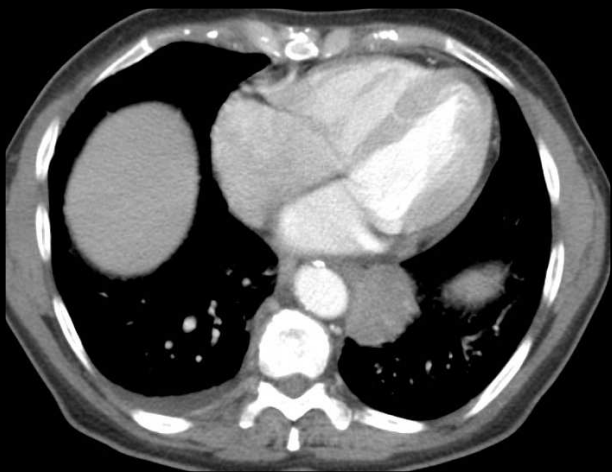
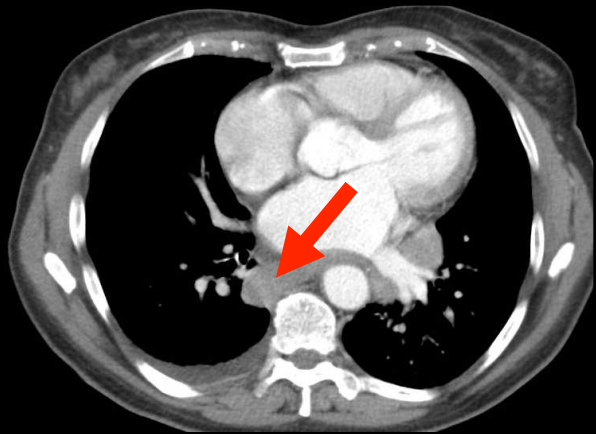
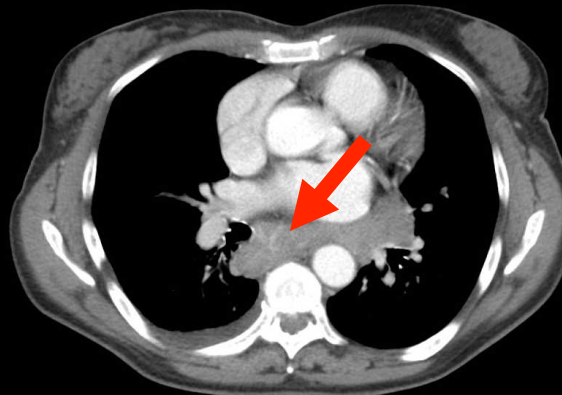
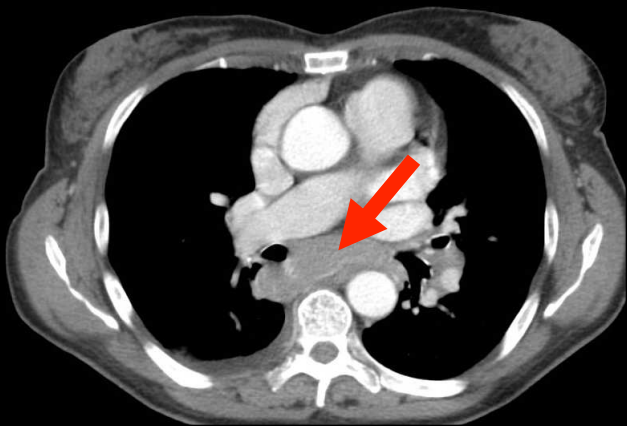
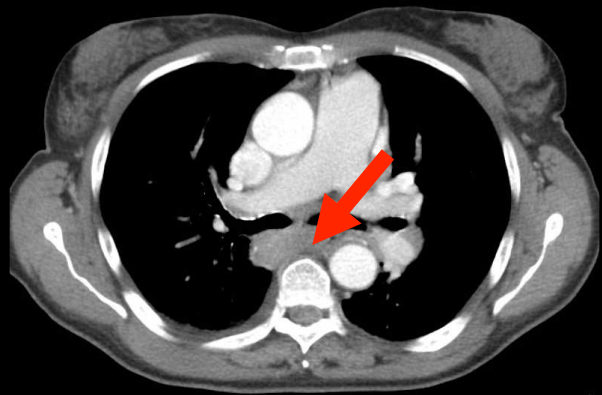
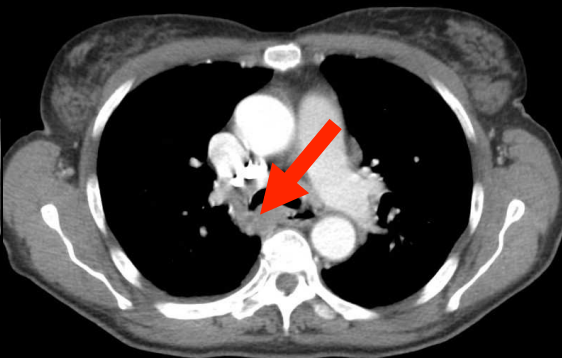
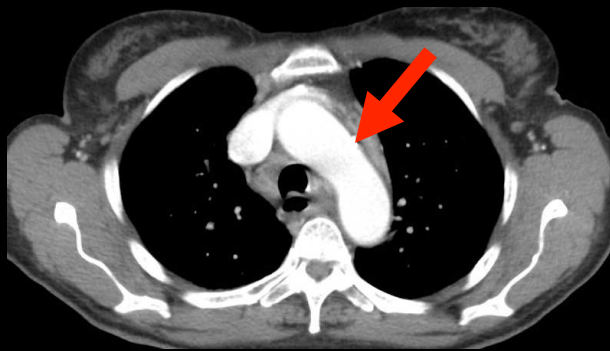
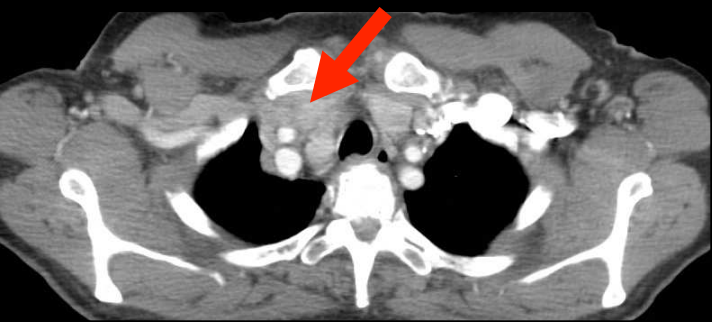
## Maladie de Hodgkin

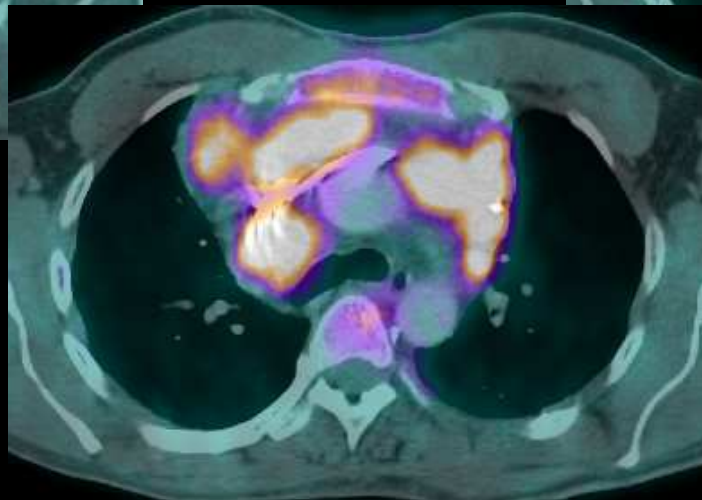
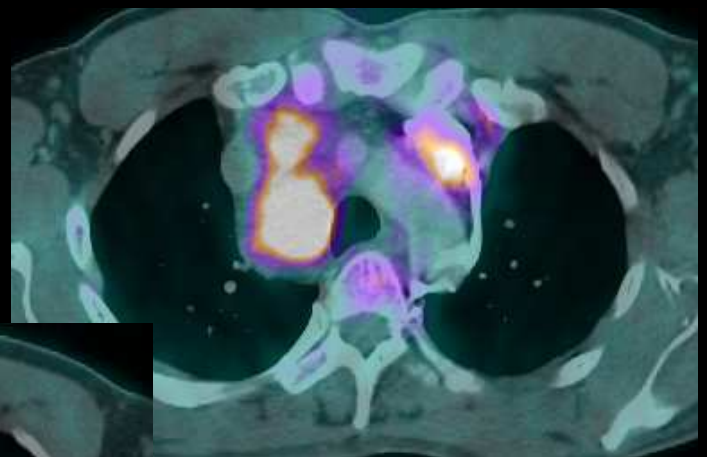
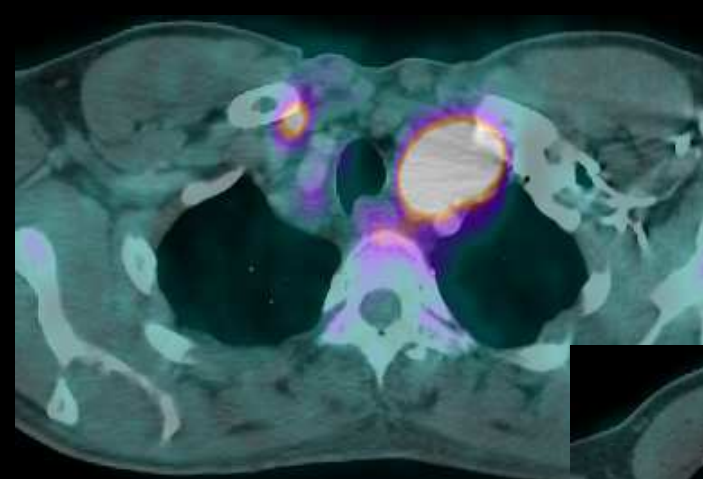




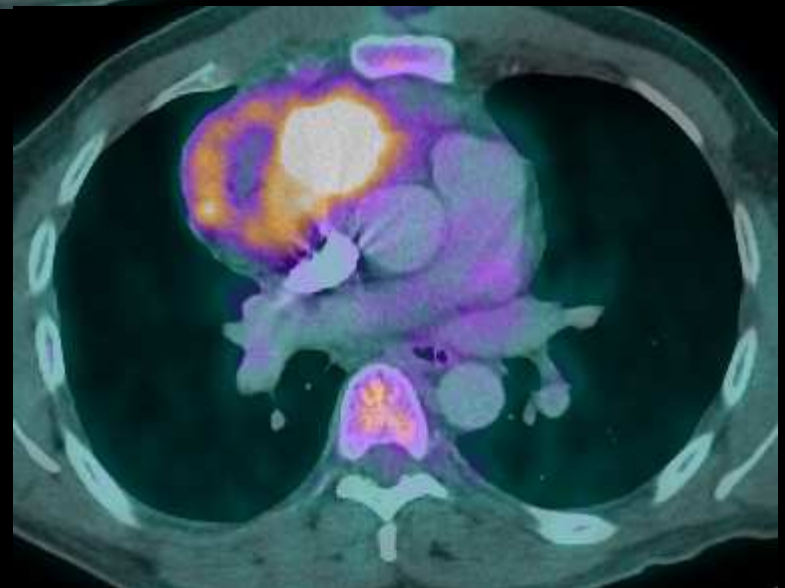
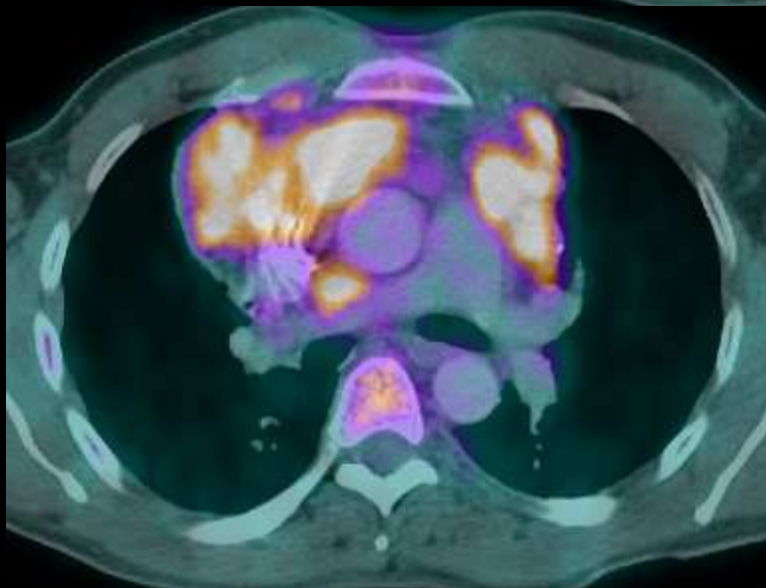
R  
1  
8  
0

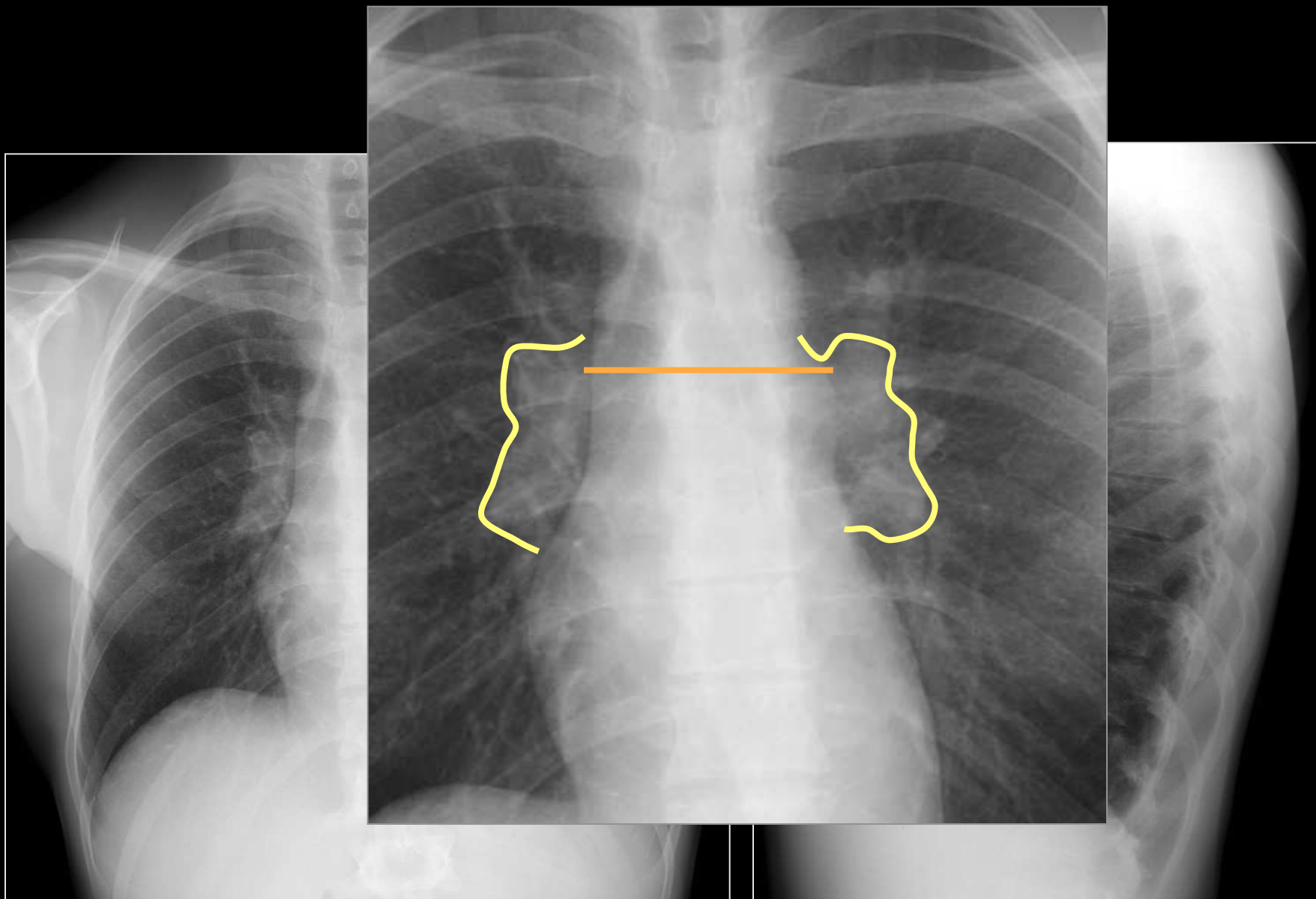




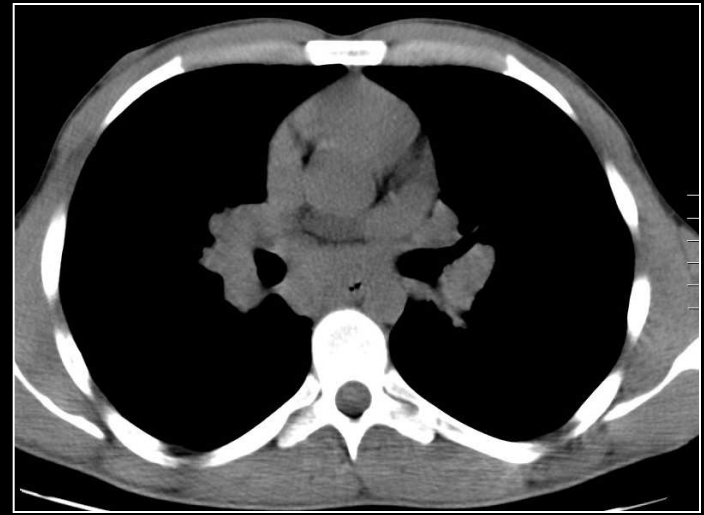
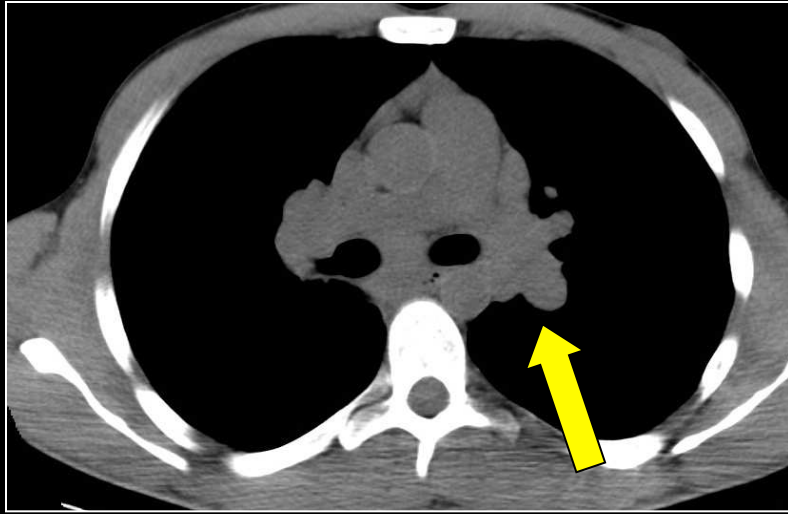


**Maladie de  
Hodgkin**

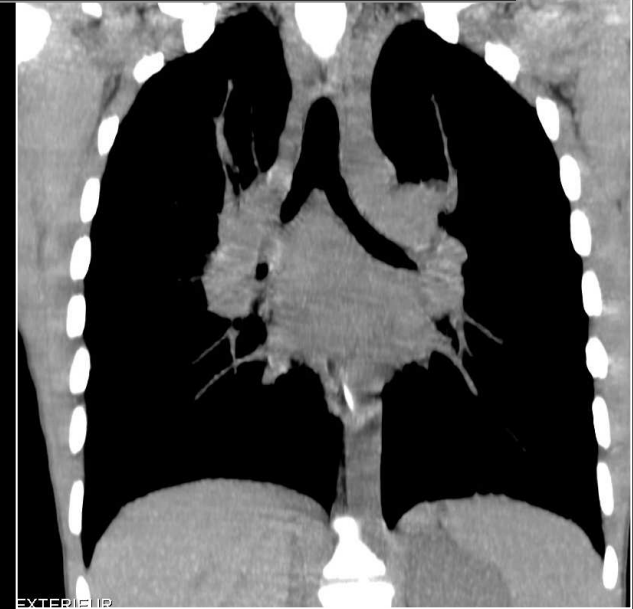
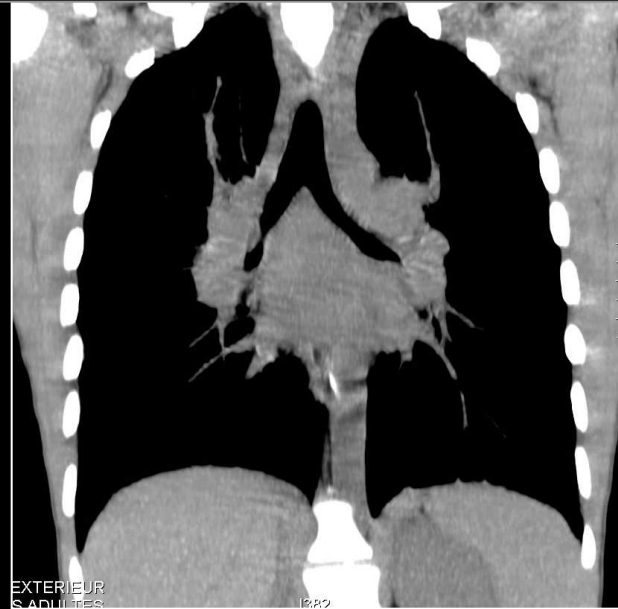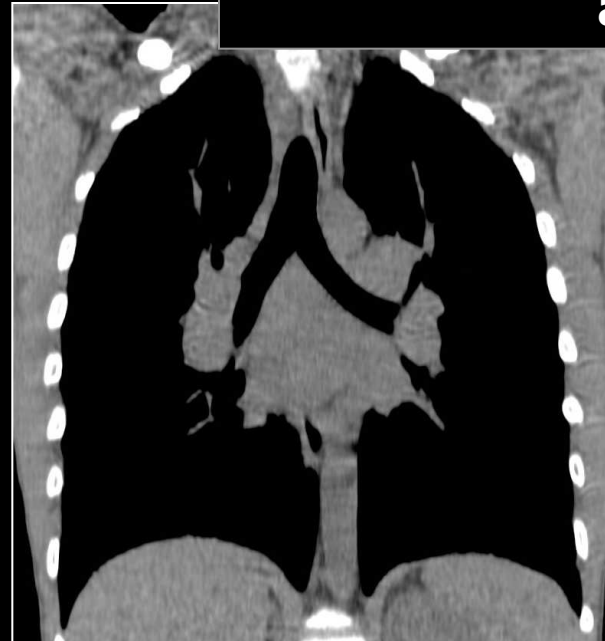




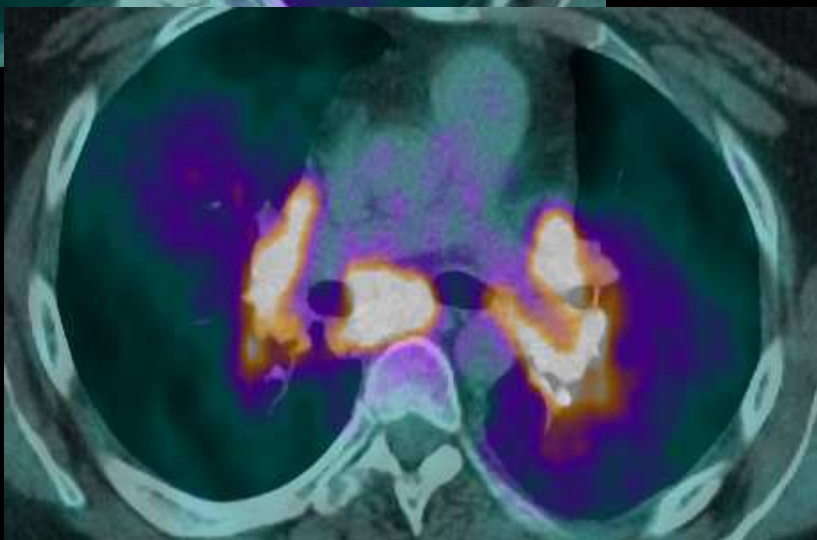
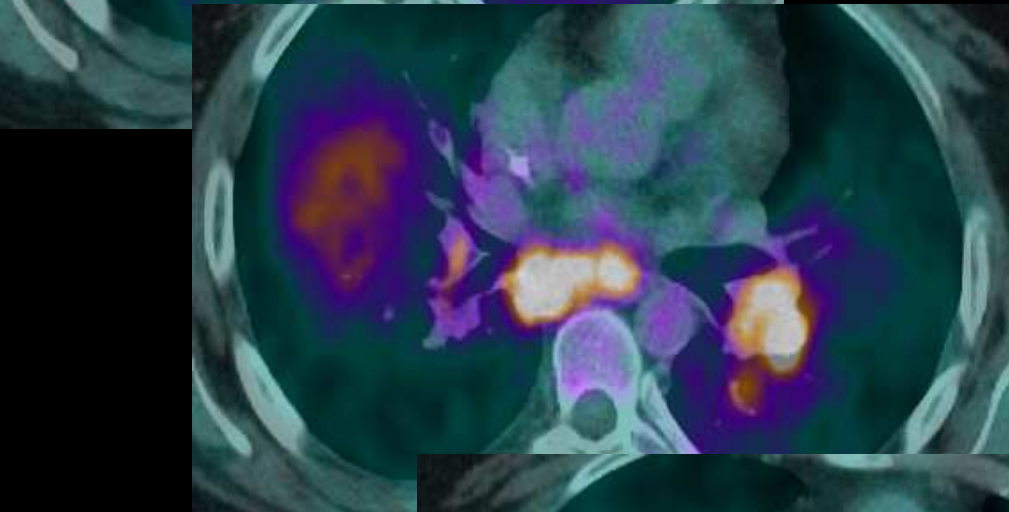
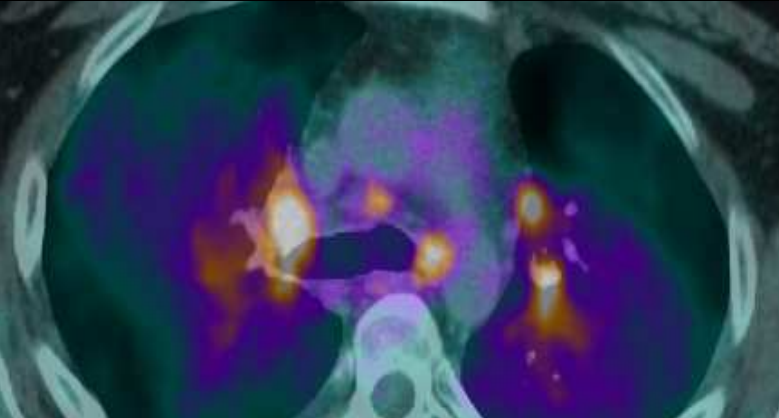
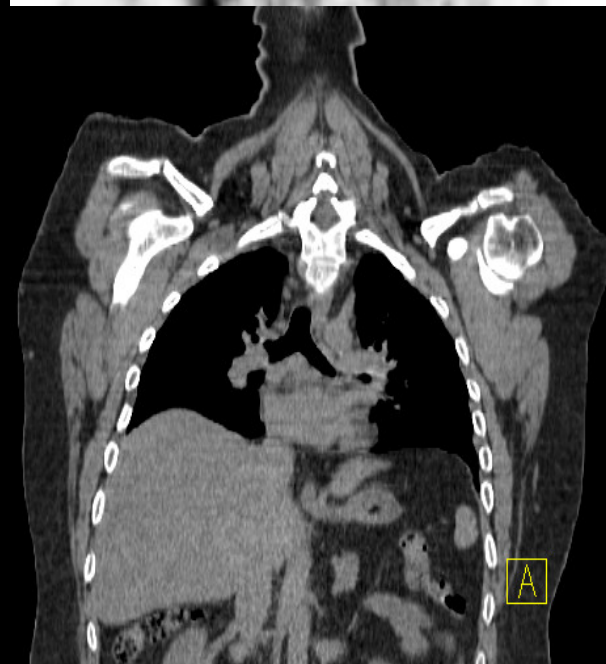
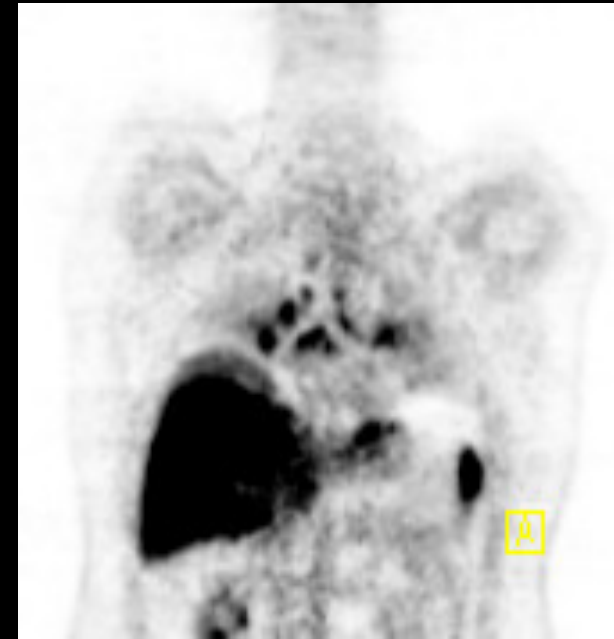**ADENOPATHIES ET GANGLIONS MEDIASTINAUX à  
prédominance inter bronchique**

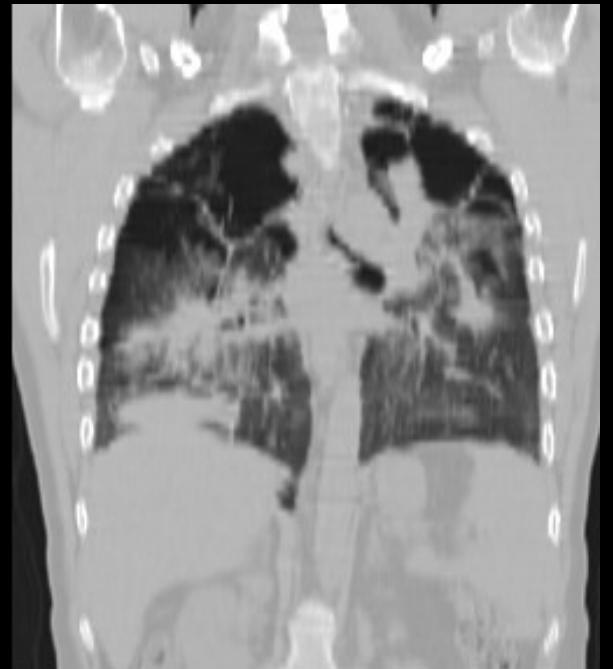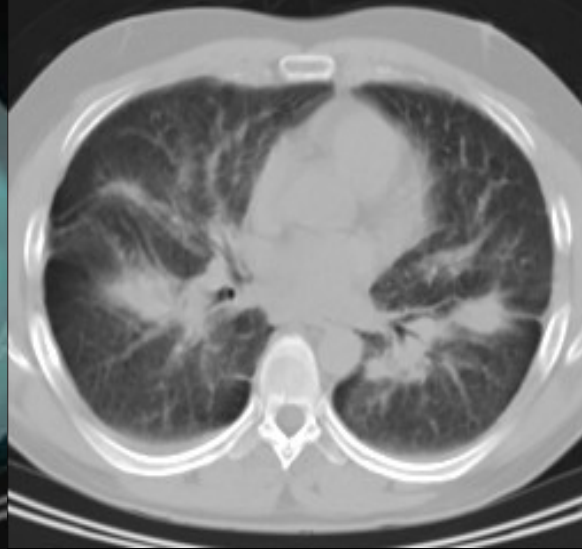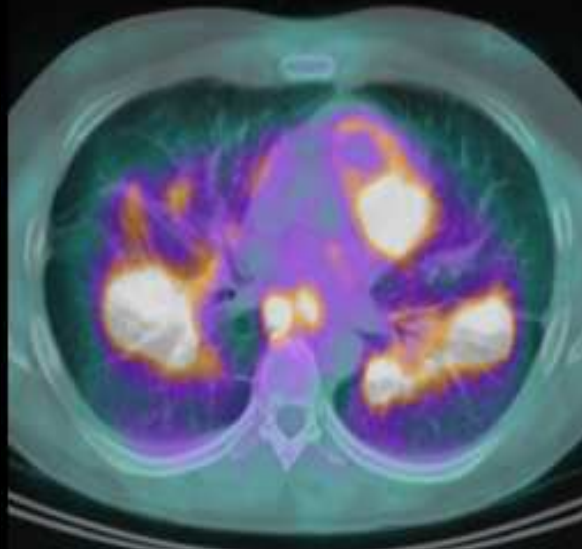
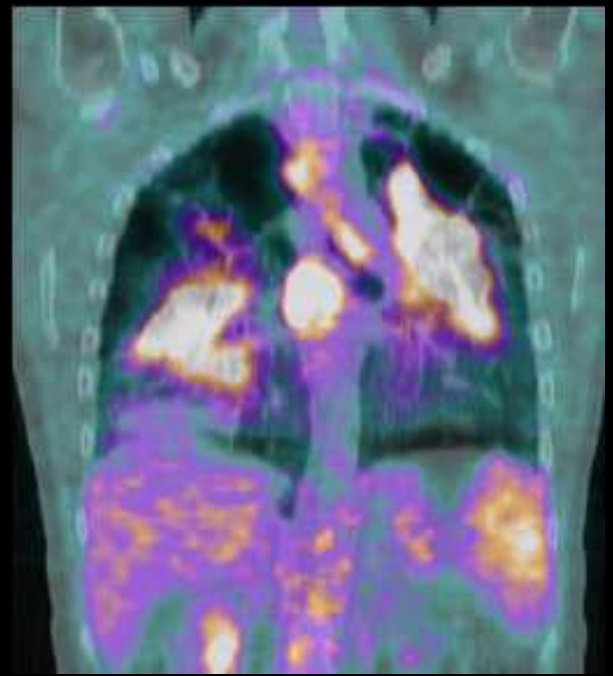
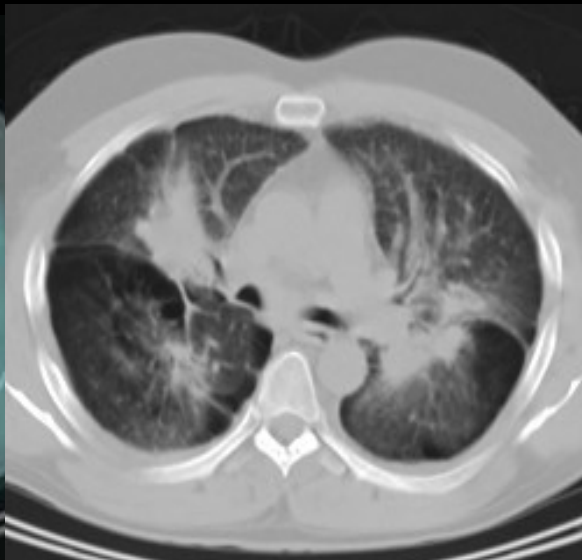
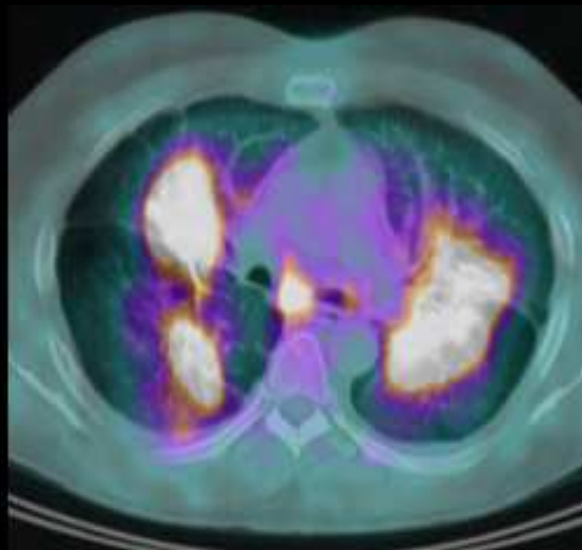


**ADENOPATHIES ET GANGLIONS MEDIASTINAUX  
à prédominance inter bronchique**

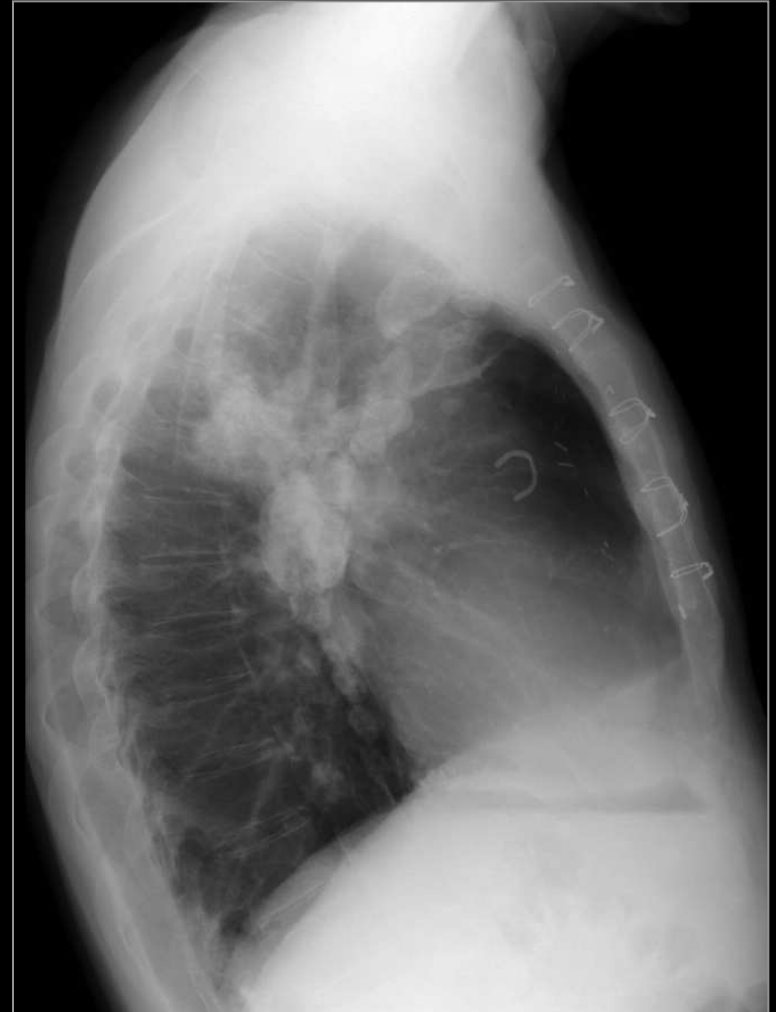
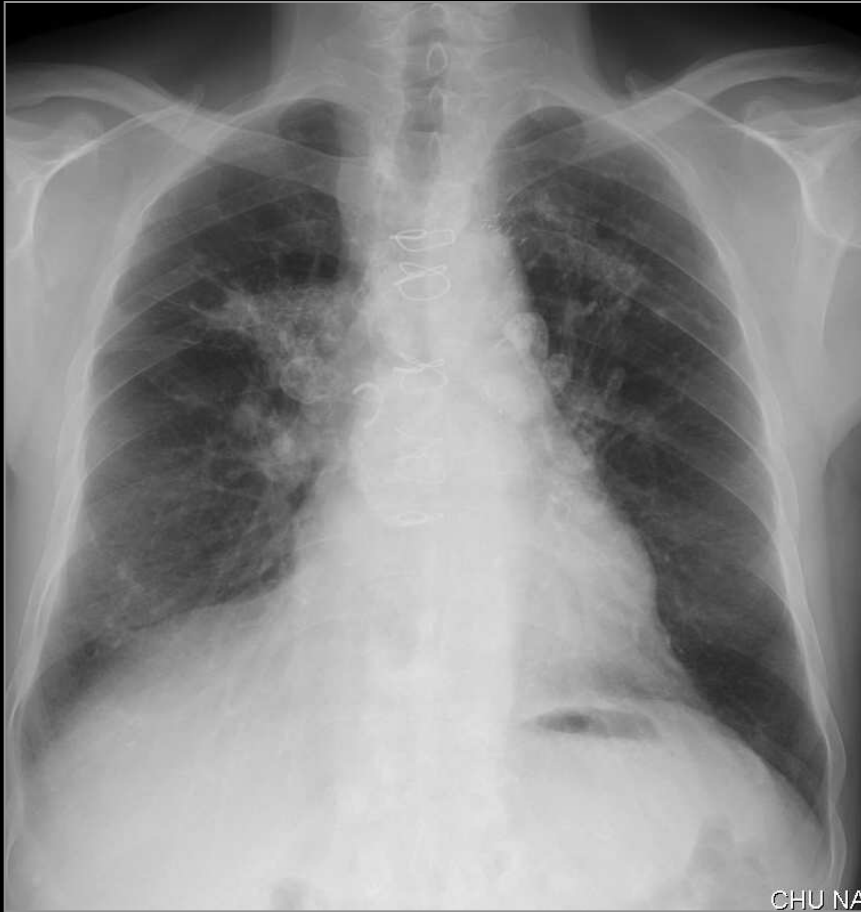
# Sarcoïdose

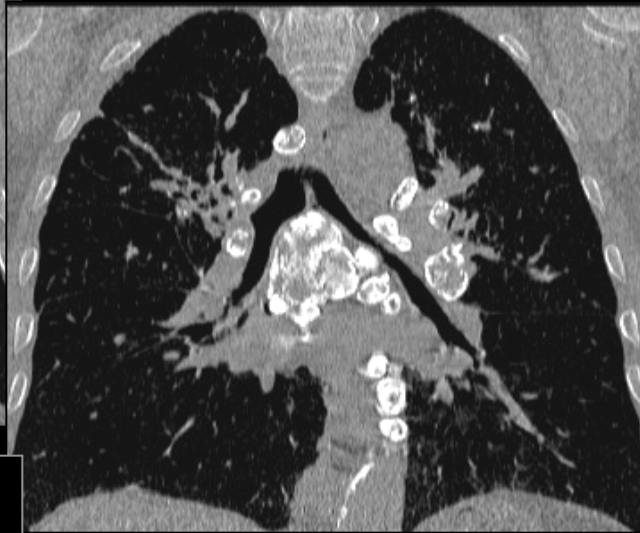
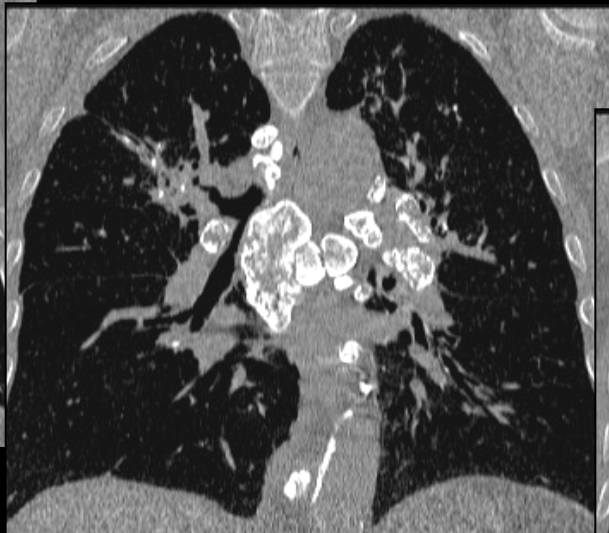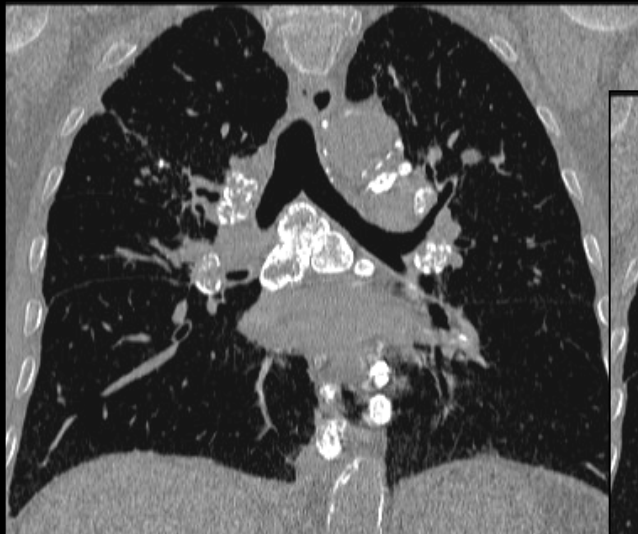

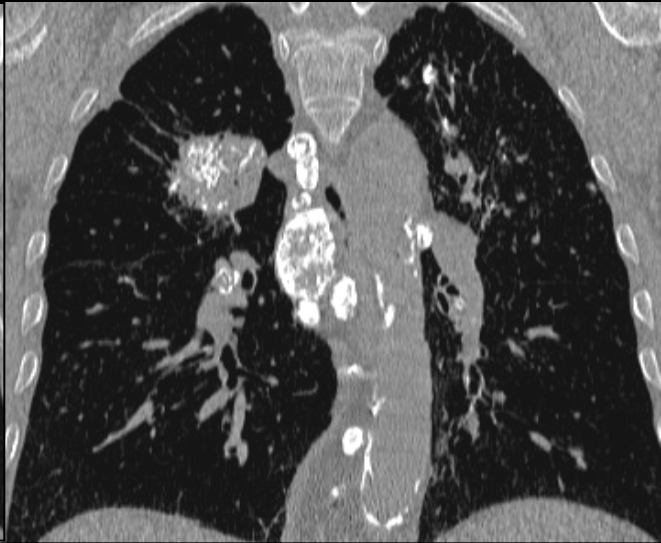
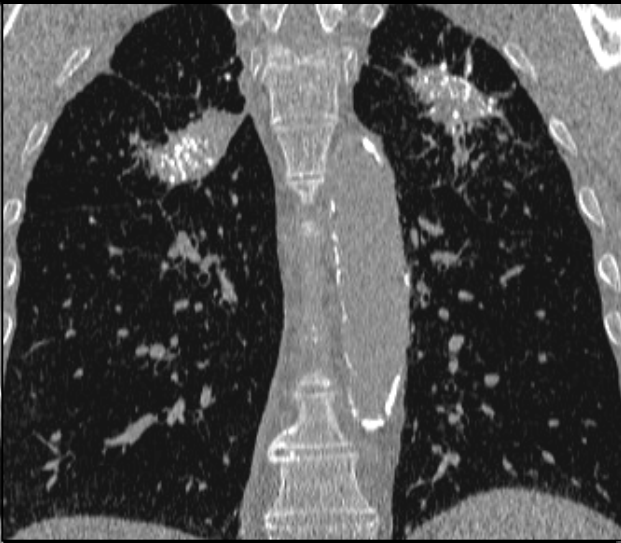
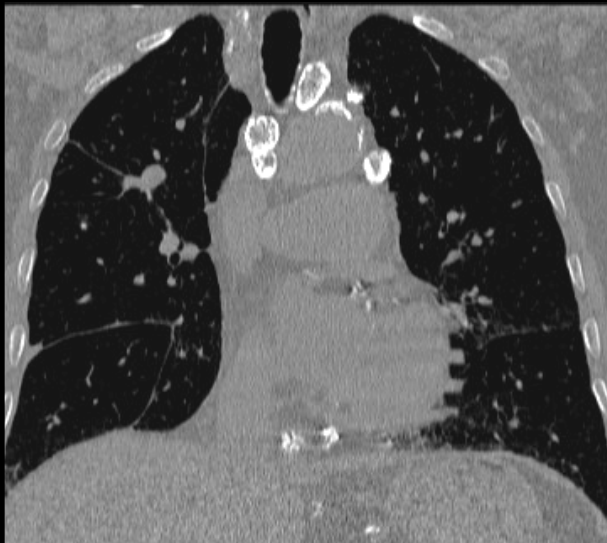
**Sarcoïdose avec atteinte parenchymateuse**

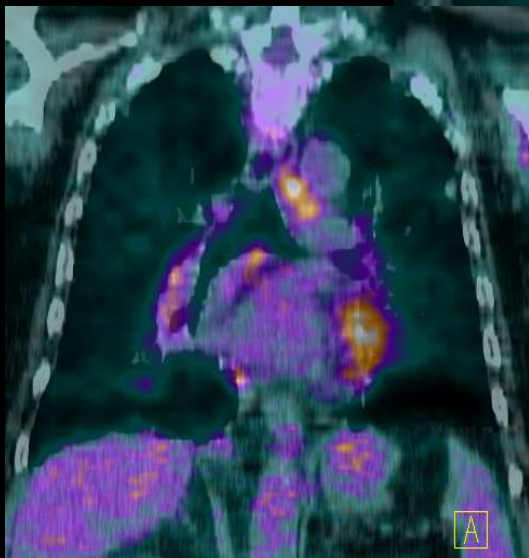
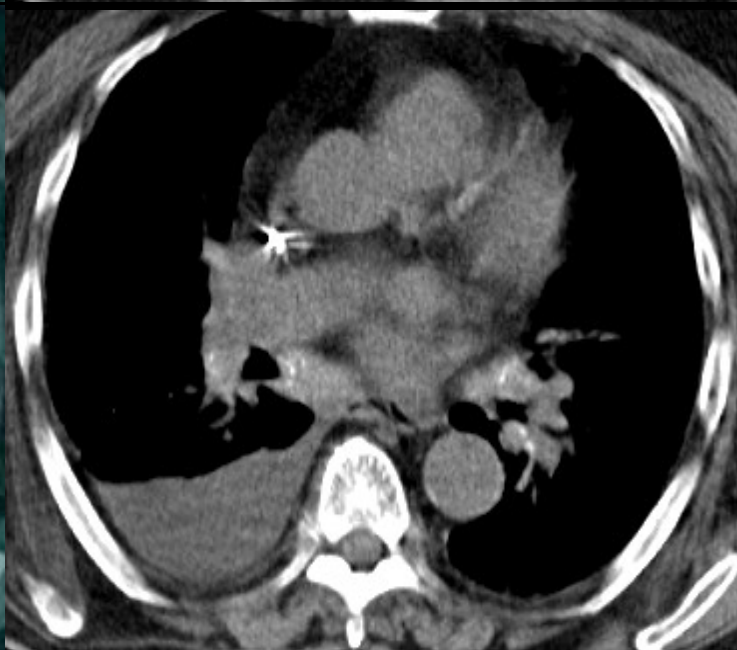
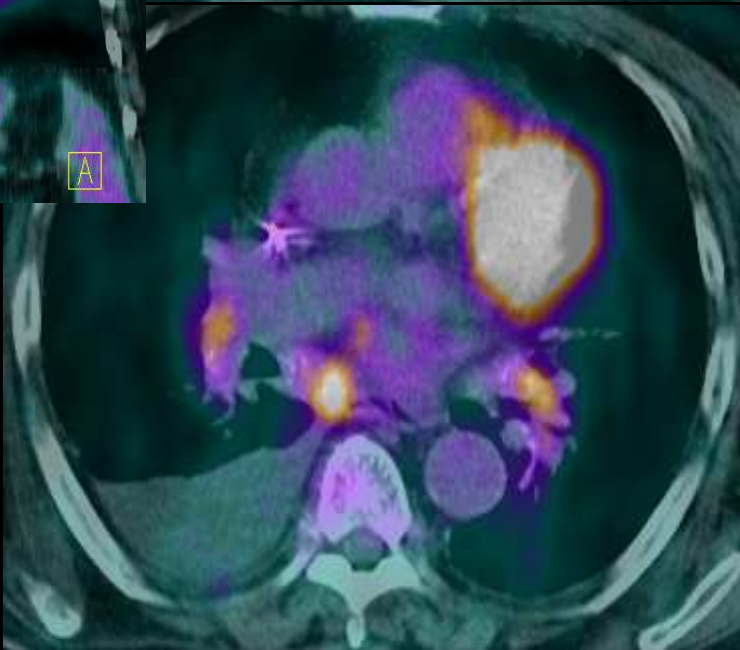
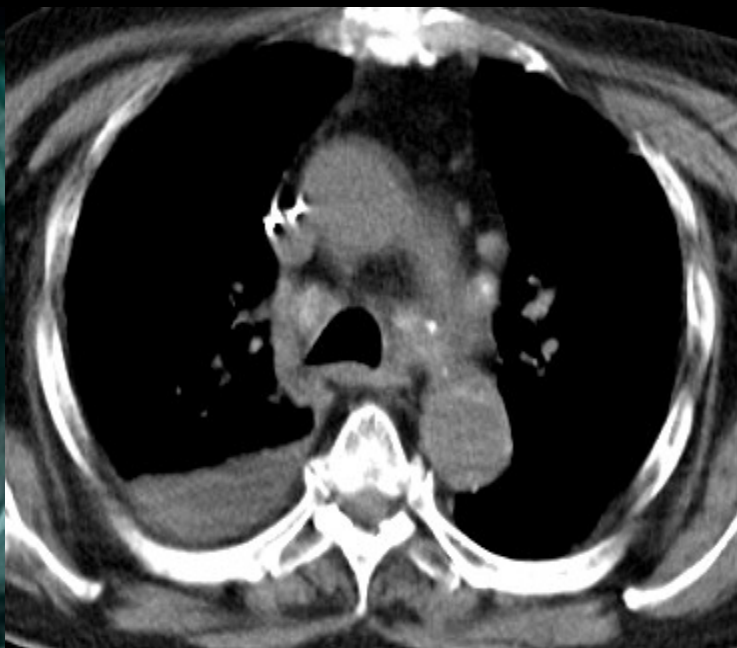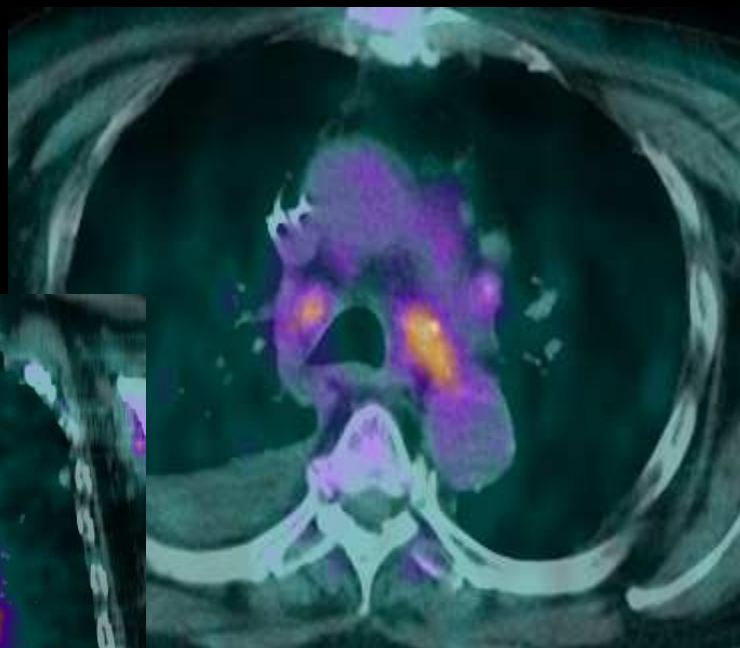


**Élargissement hilare droit et médiastin**

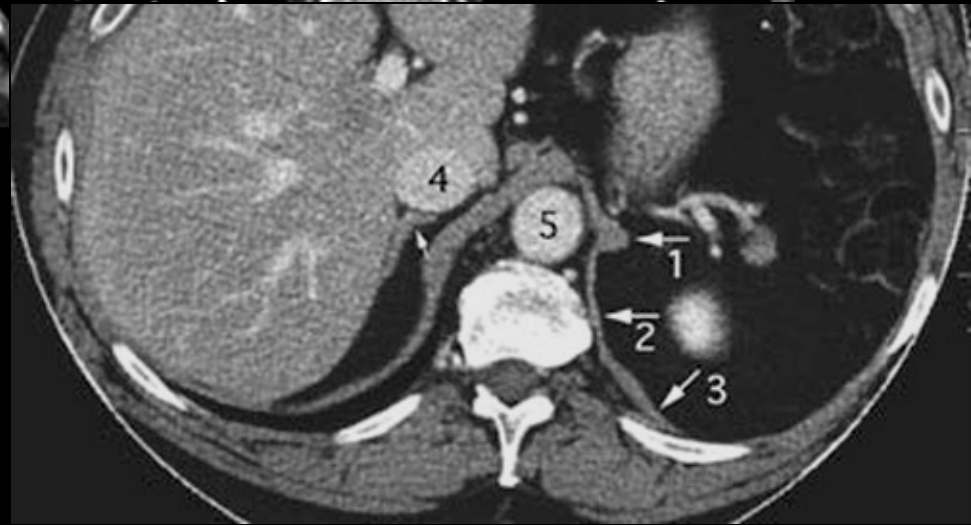
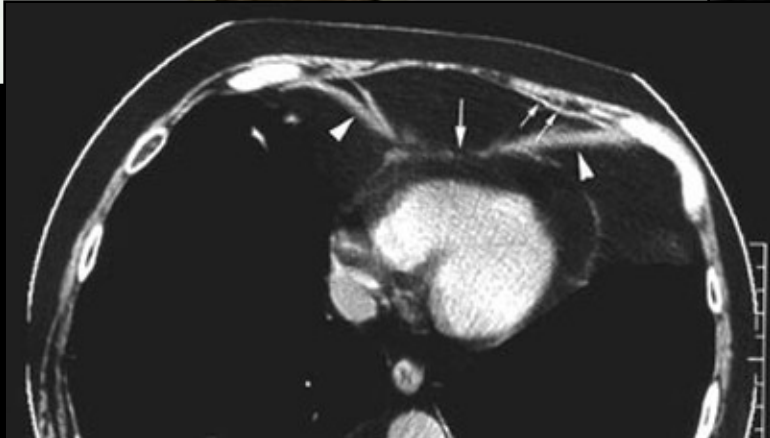
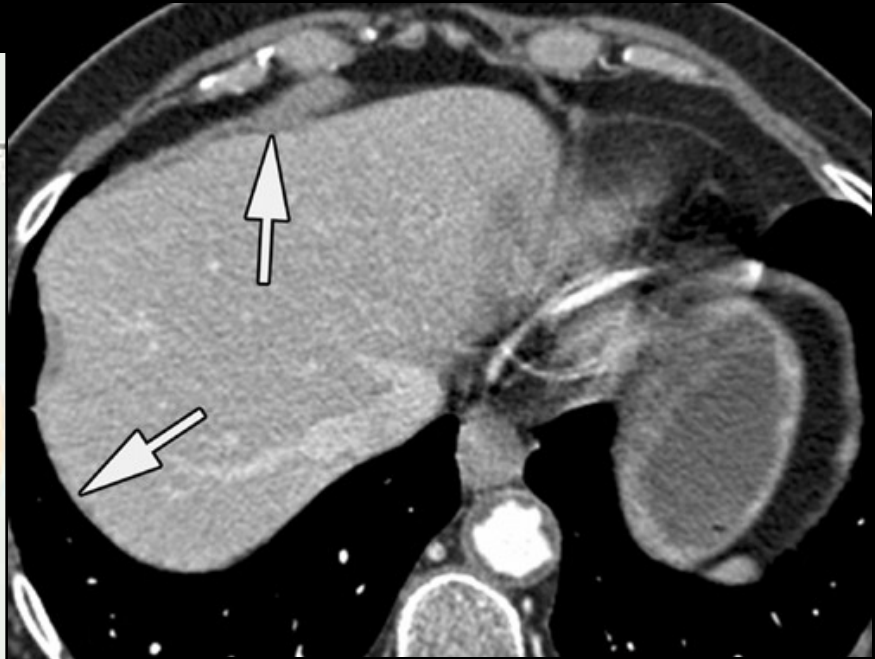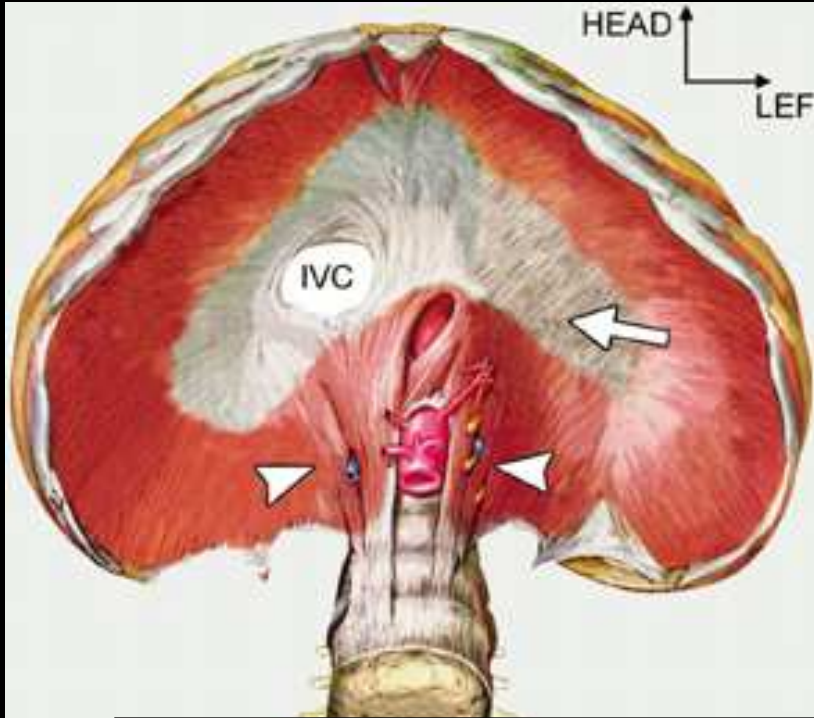


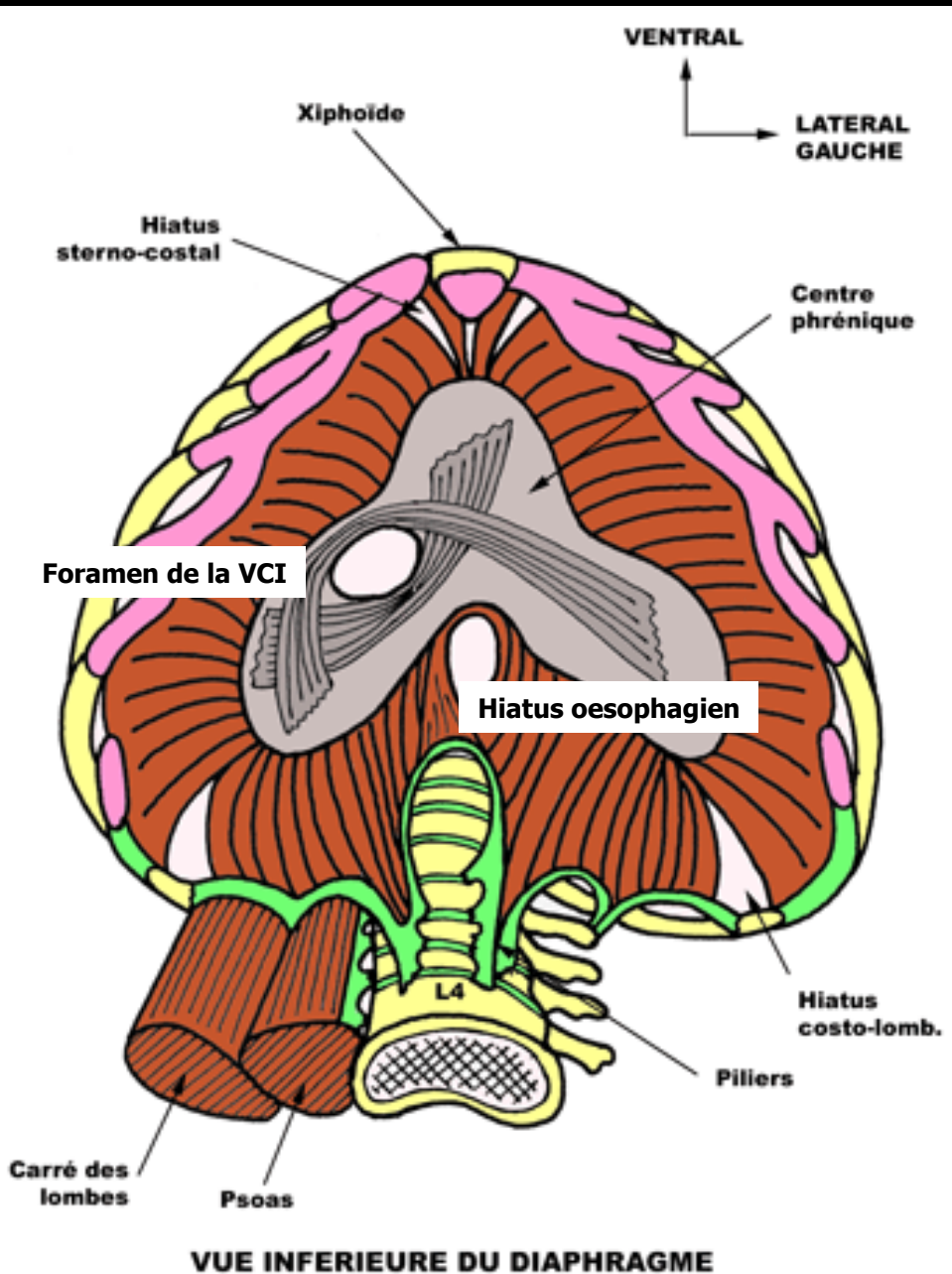
**ADP calcifiées et masses biapicales : silicose**

# Silicose



# DIAPHRAGM





## Orifices :

### • T12 :

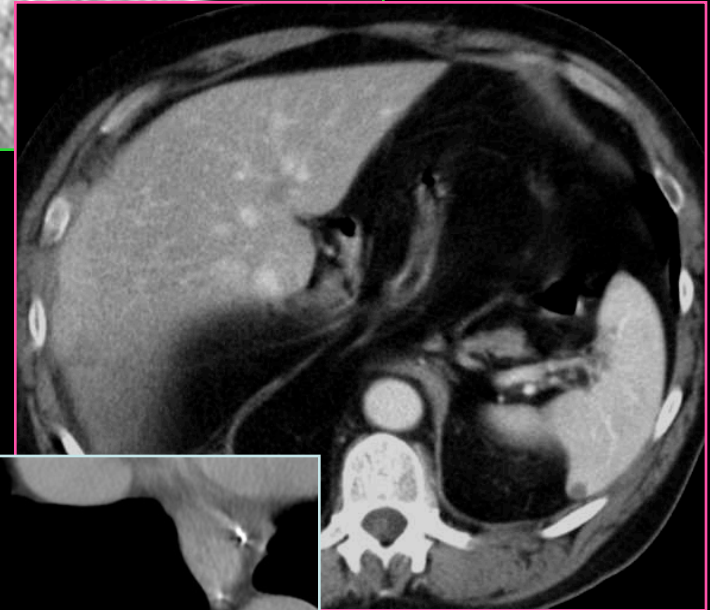
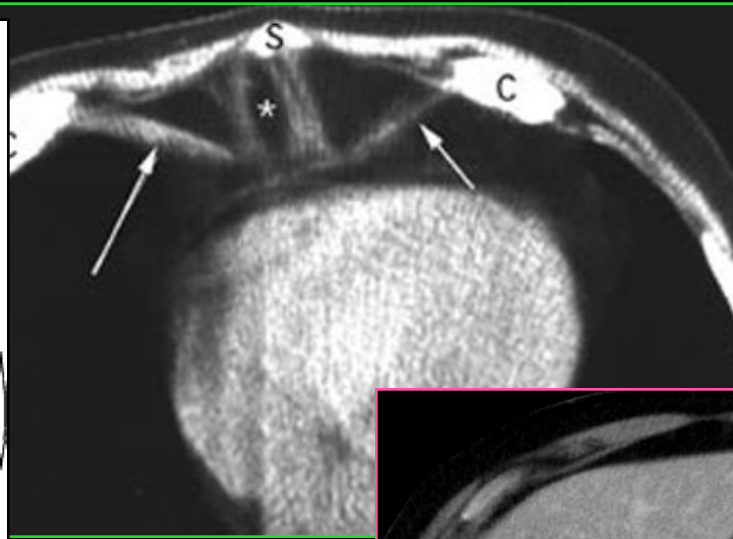
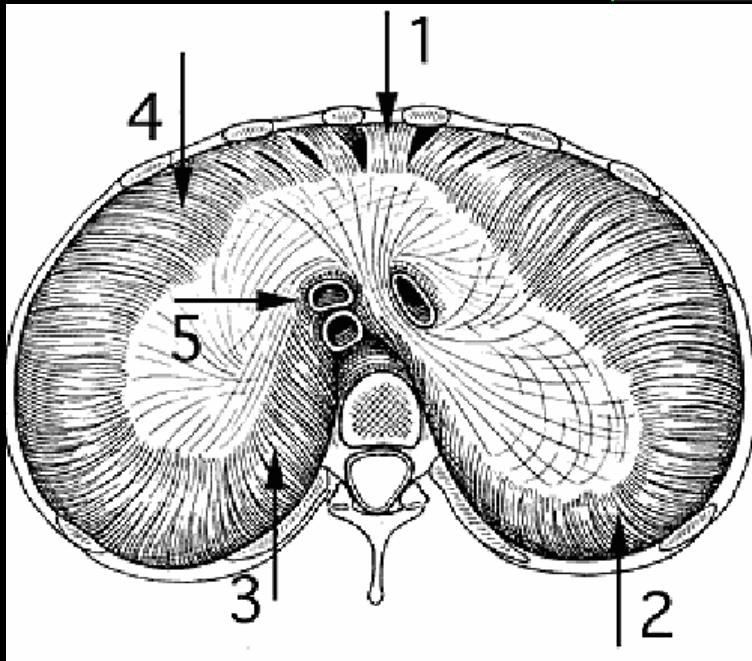
- AO
- Canal thoracique

### • T10 :

- œsophage
- Nerfs X

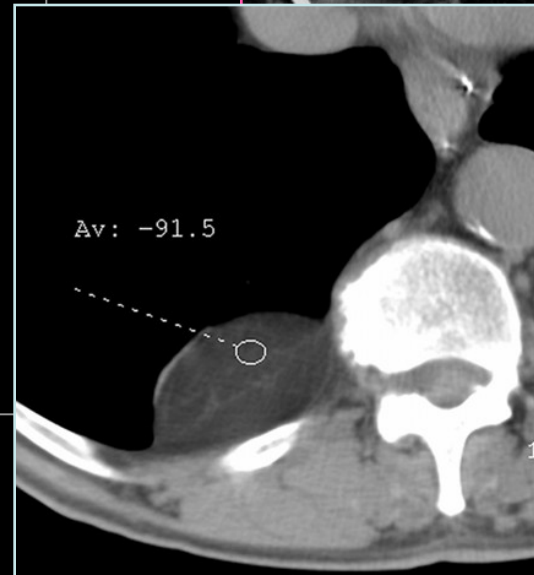### • T9 :

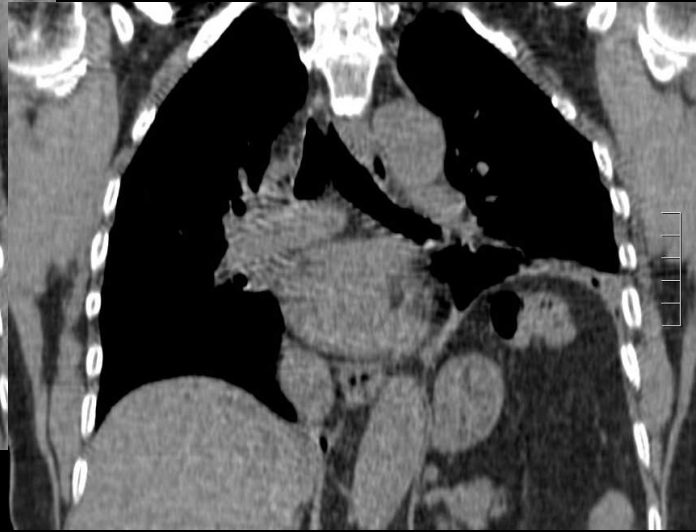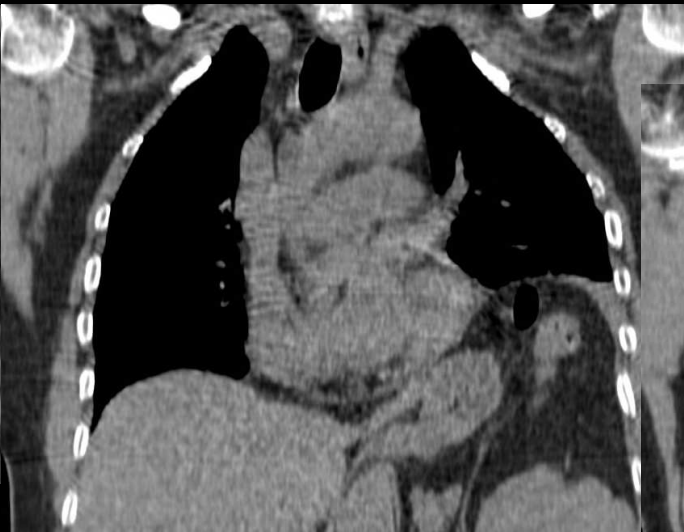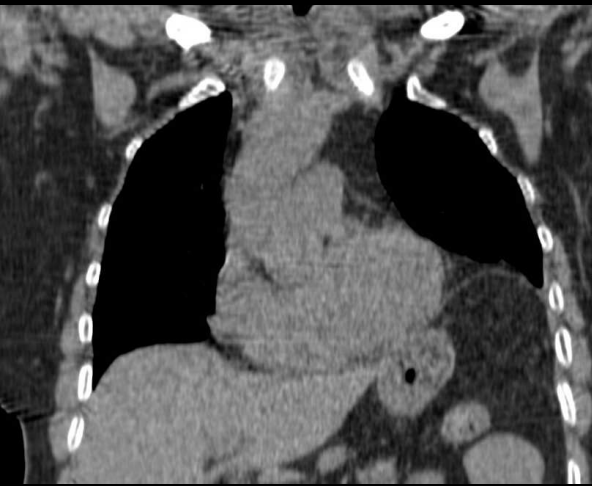- VCI
- N. phrénique D



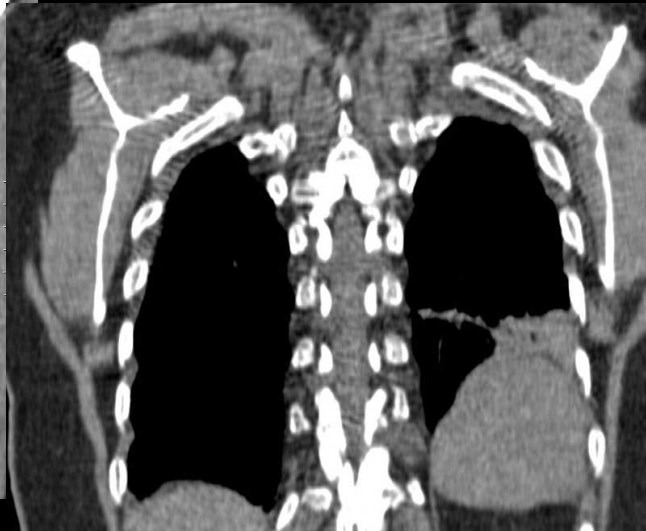
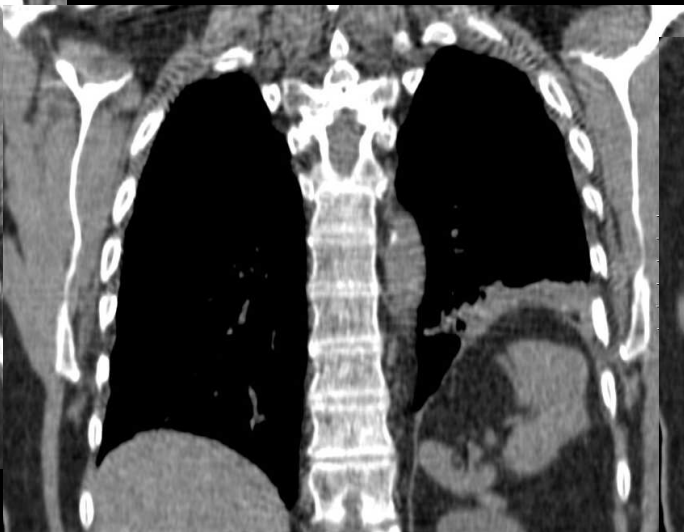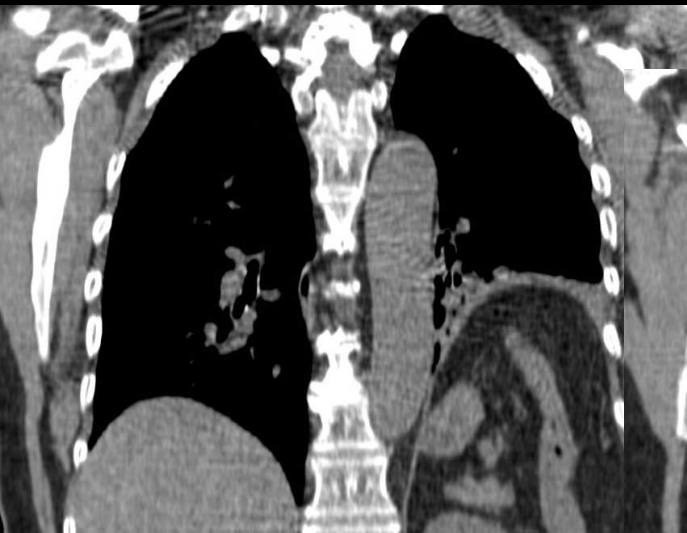
### Points de faiblesse :

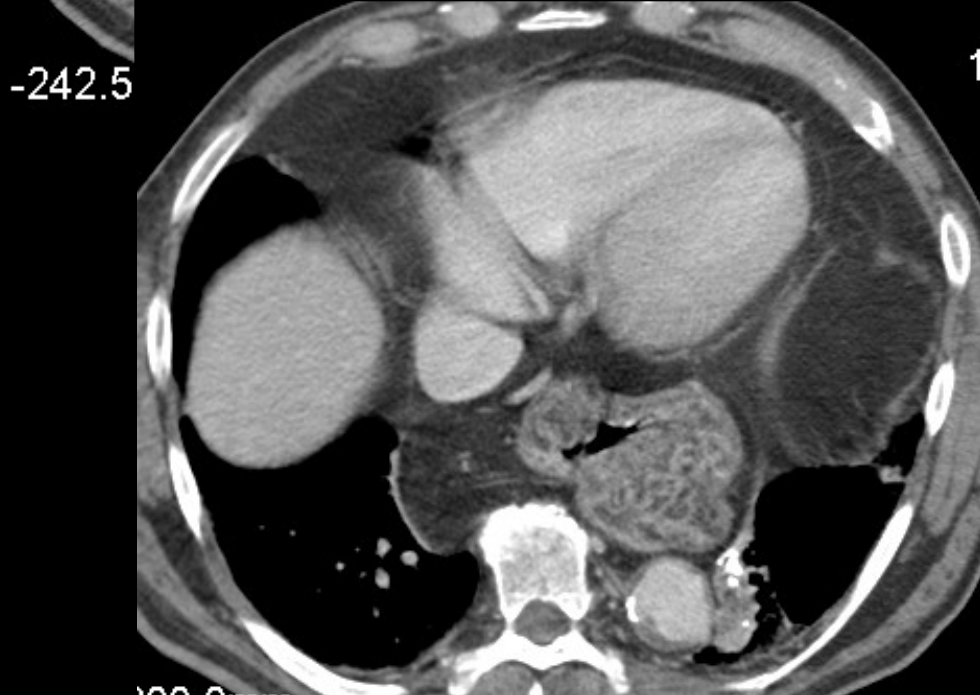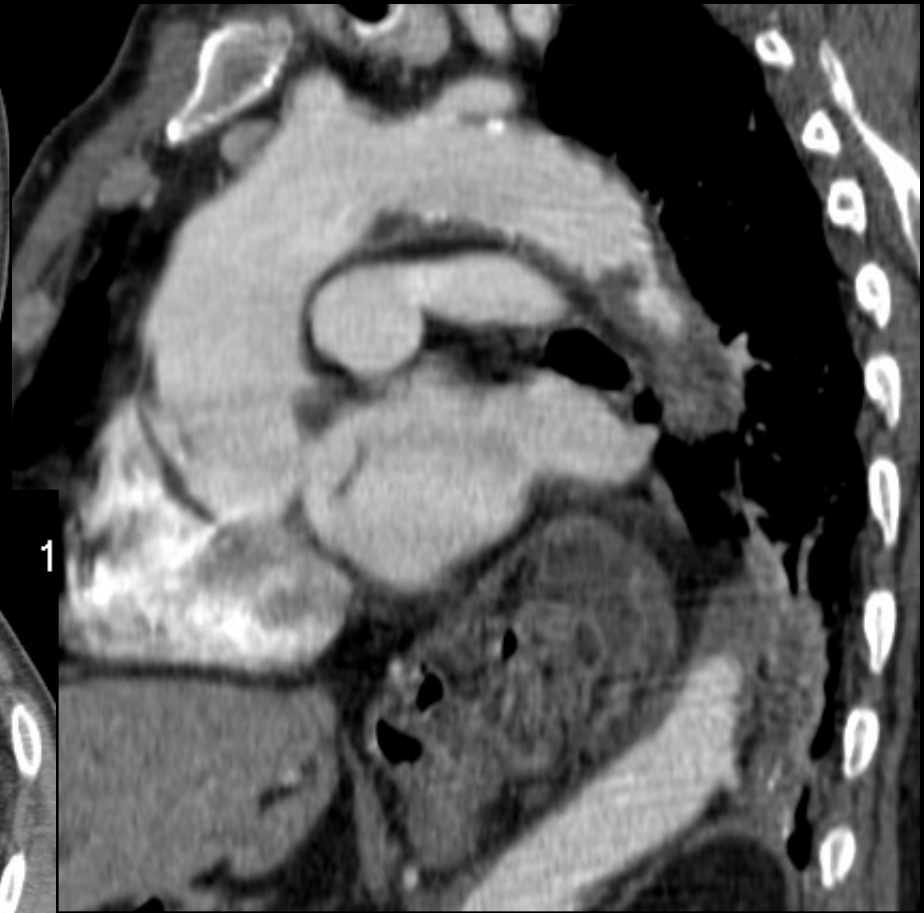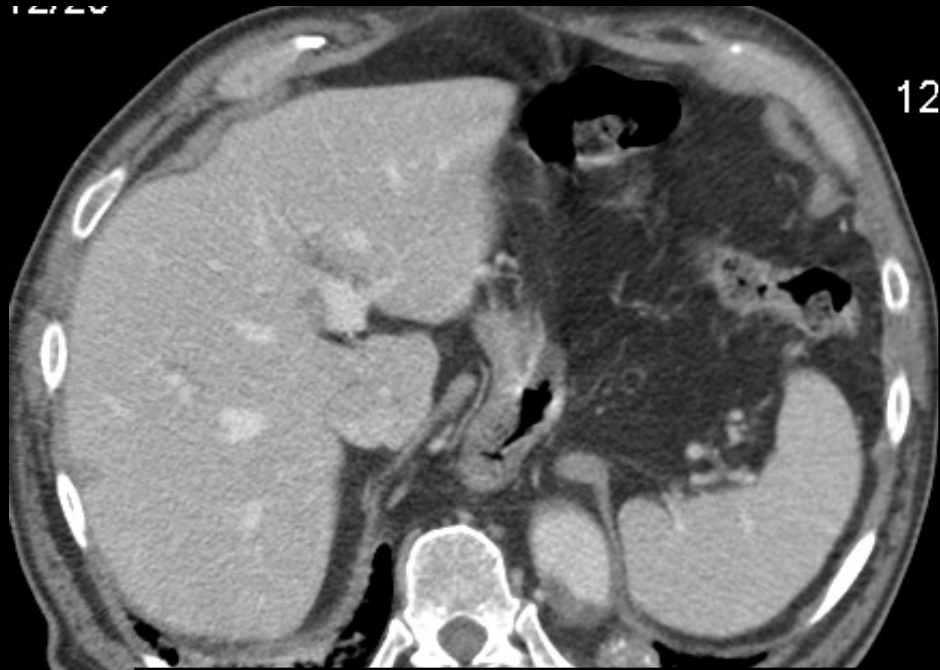- Hiatus postérieur : Bochdalek
- Hiatus rétro-costo-xyphoïdiens
  - lat : Morgani
  - médian : fente de Larrey
- Hiatus oesophagien





Paralysie phrénique

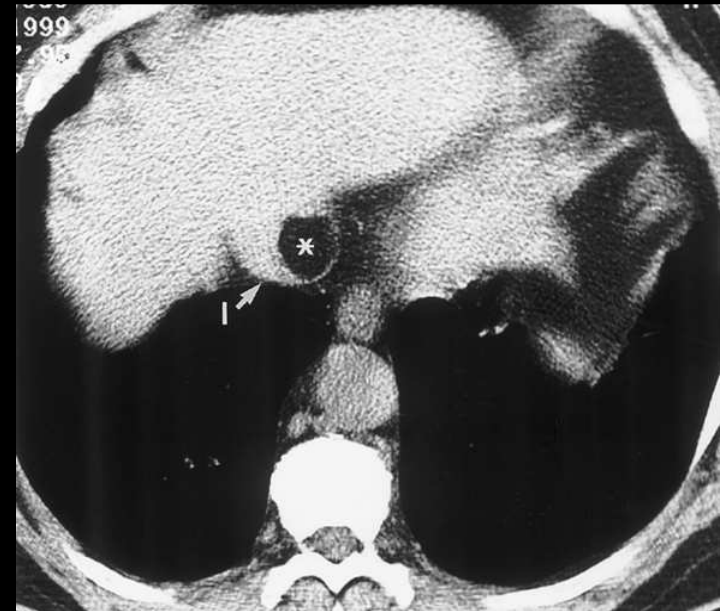
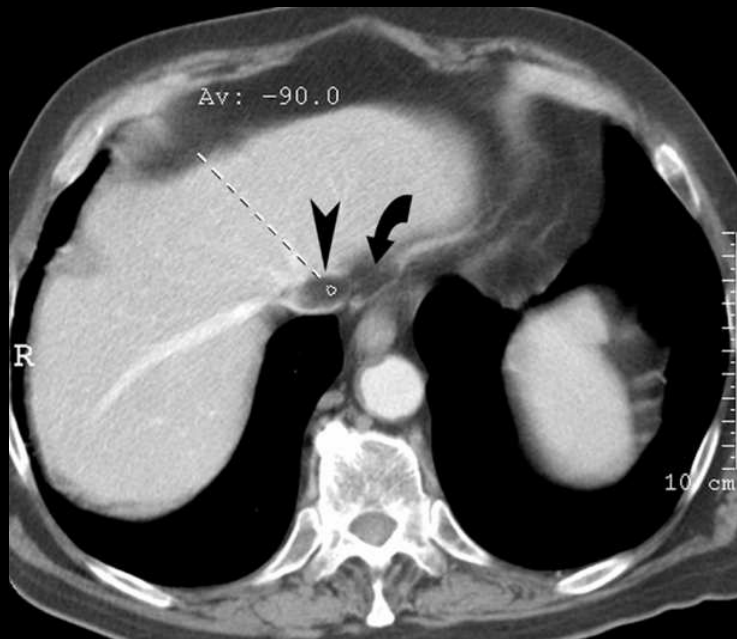
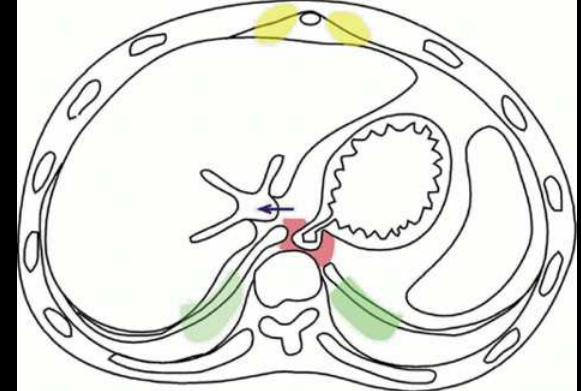




HH par glissement

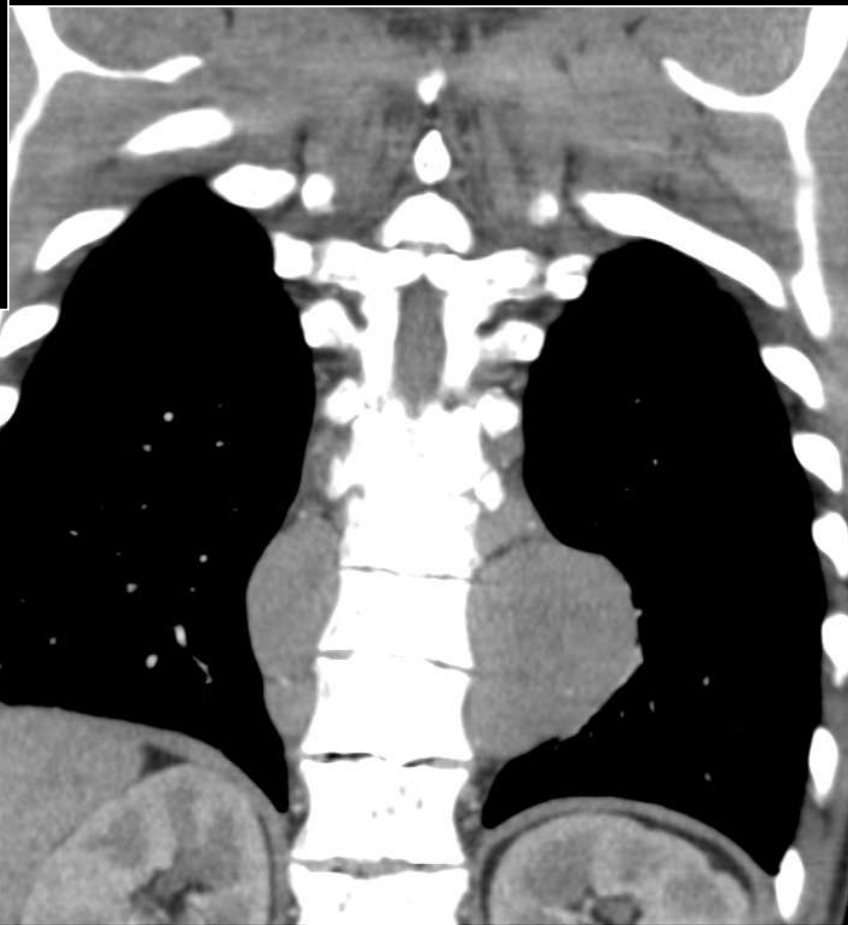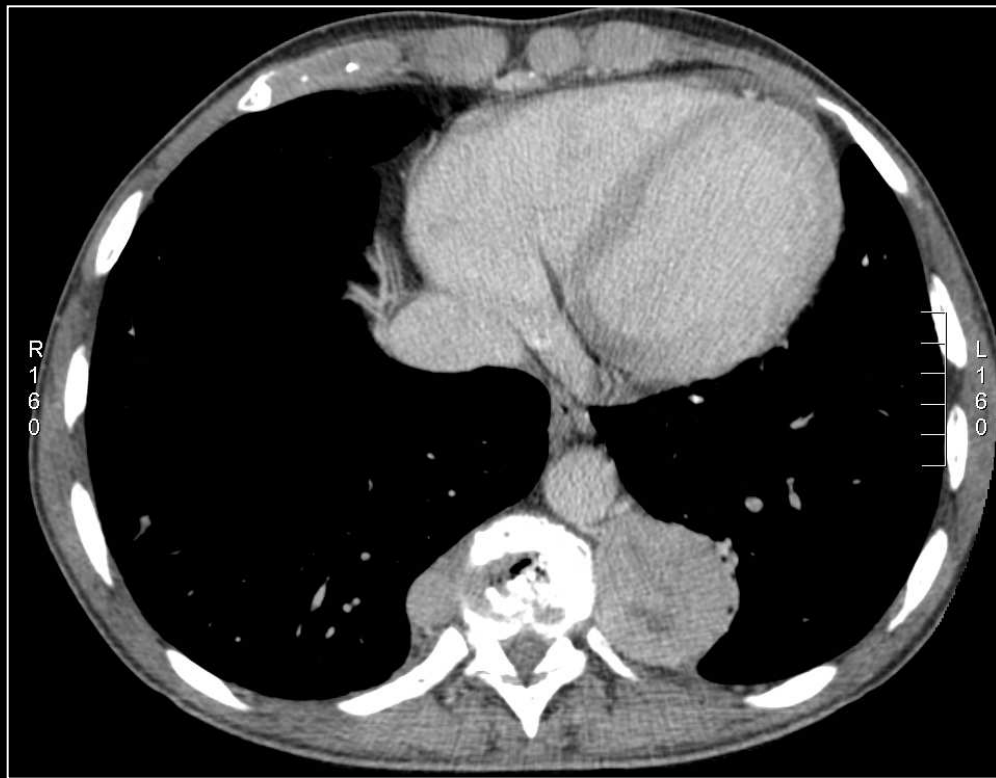
# PSEUDO-LIPOME INTRA-CAVE

- confluence v sus-hép/VCI
- en continuité avec graisse péri-oesophagienne
- IIaire angulation et rétrécissement portion médiale de la VCI
- image variable selon la respiration



# A retenir

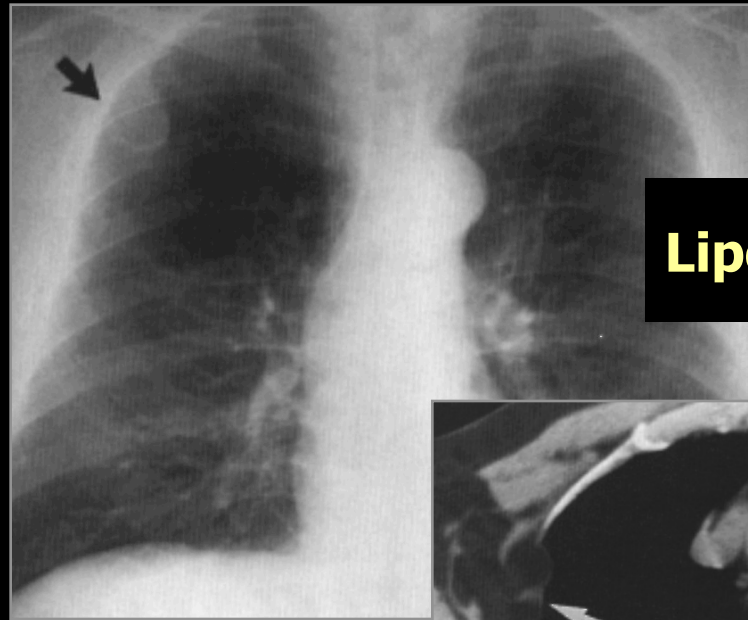
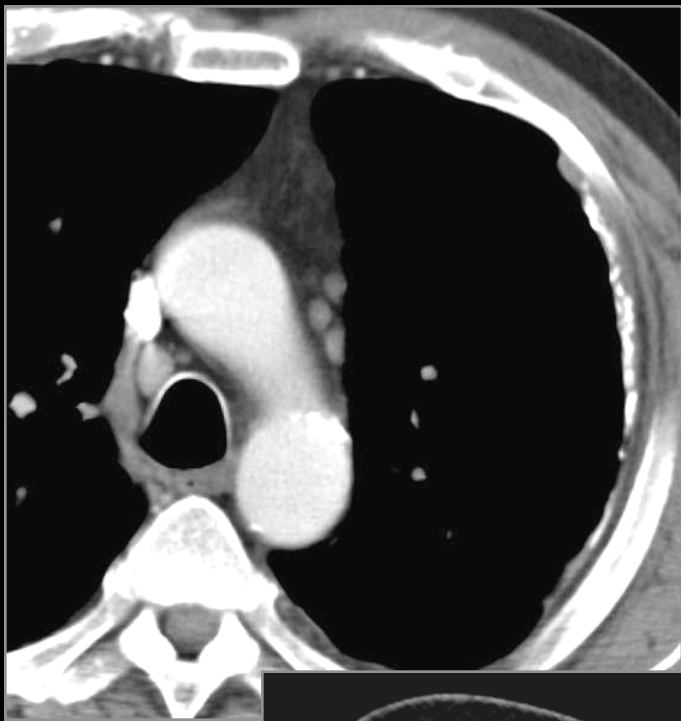- Lésions du médiastin antérieur :
  - Thyroïde
  - Thymus
  - Lymphome
  - Tumeur germinale
- Lésions du médiastin antéro-inférieur :
  - Kyste pleuro-péricardique
  - hernie de la fente de Larrey
  - Lipome, hémangiome, lymphangiome
- Lésions du médiastin moyen :
  - Adénopathies
  - Kyste bronchogénique
  - Œsophage
  - Vasculaire
- Lésions du médiastin postérieur :
  - Hématopoïèse extramédullaire
  - Tumeurs neurogènes
  - Kyste bronchogénique
  - Abscès juxta-osseux (BK, etc)



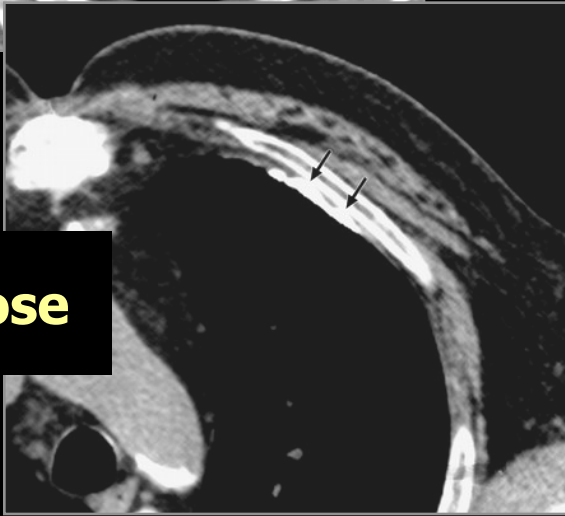
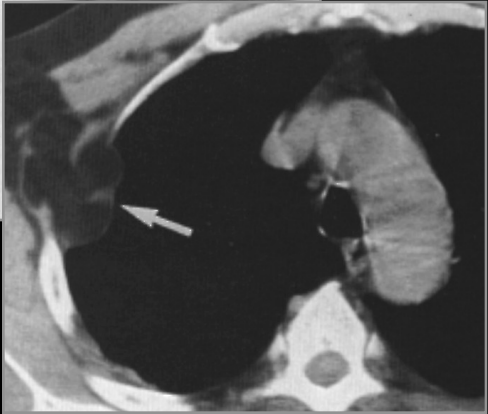
**Hématopoïèse  
extramédullaire**

### 3/ PAROI THORACIQUE

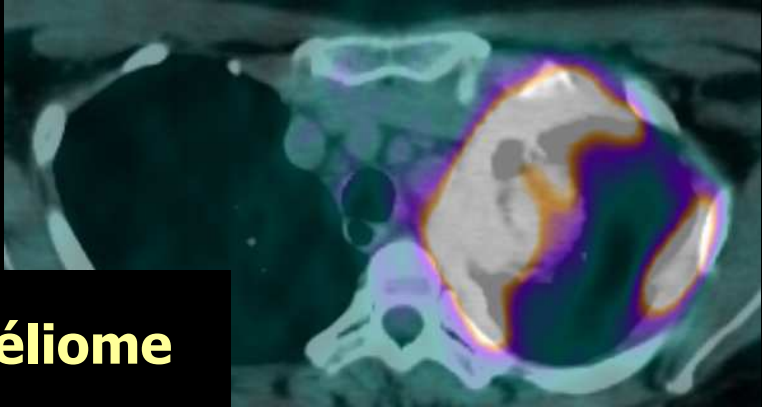
- **PLEVRE**
- **CÔTES**



**Lipome**

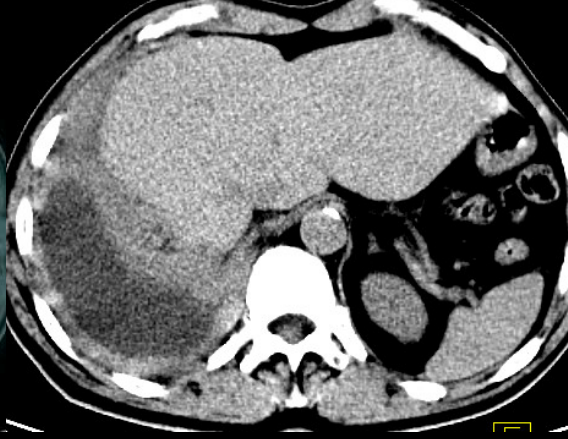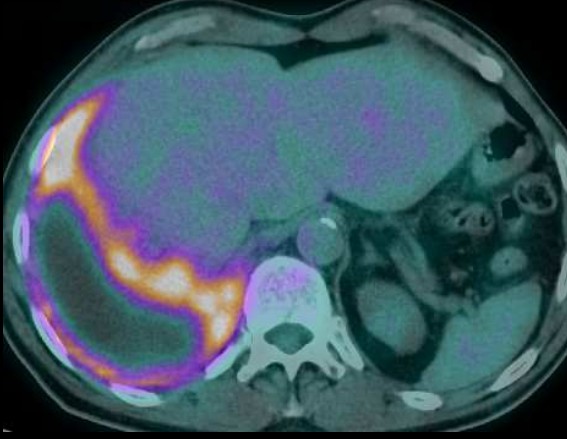
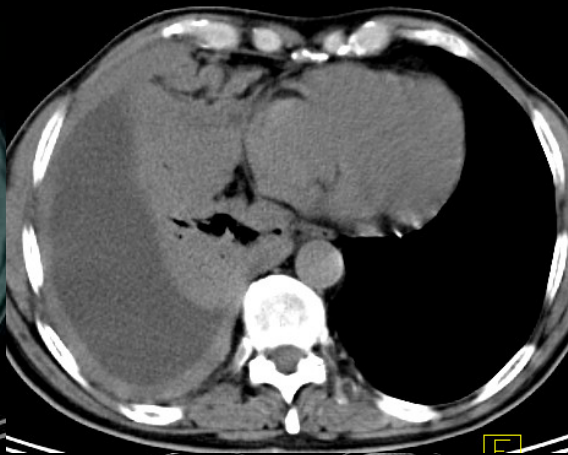
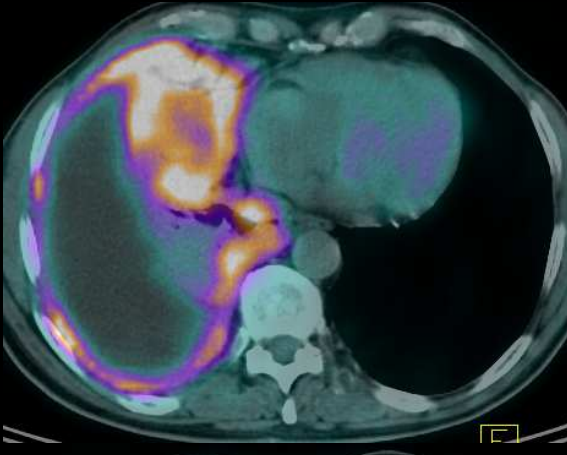
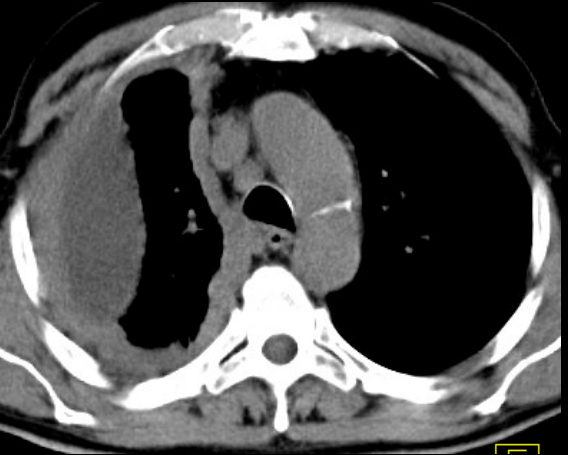
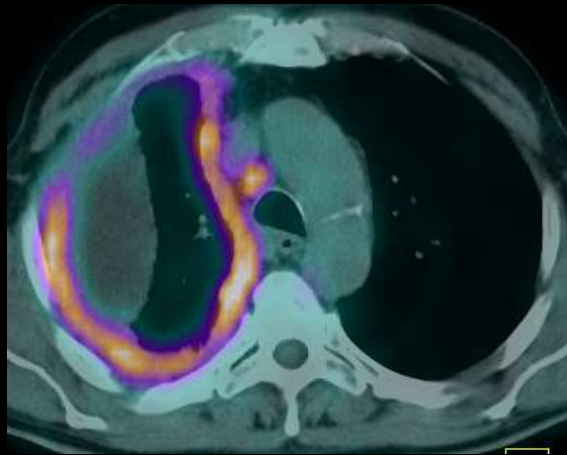
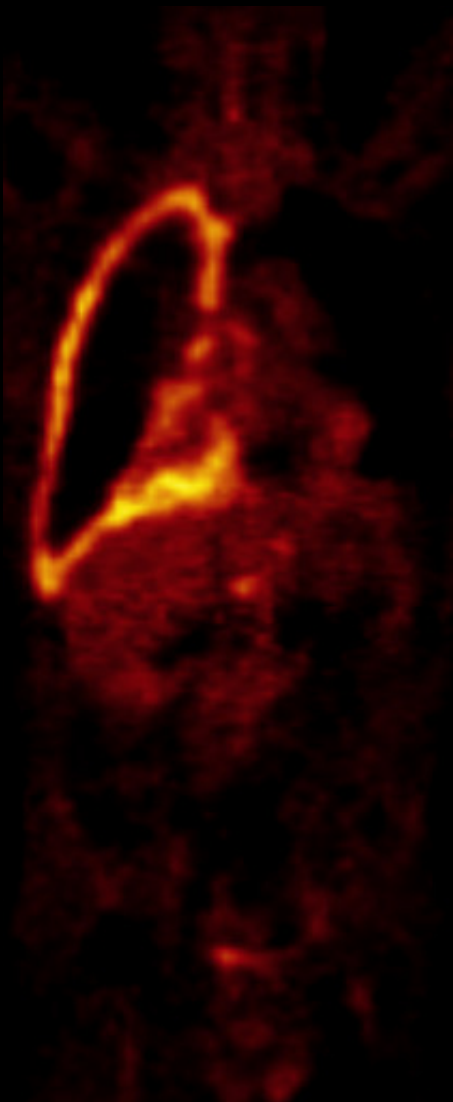


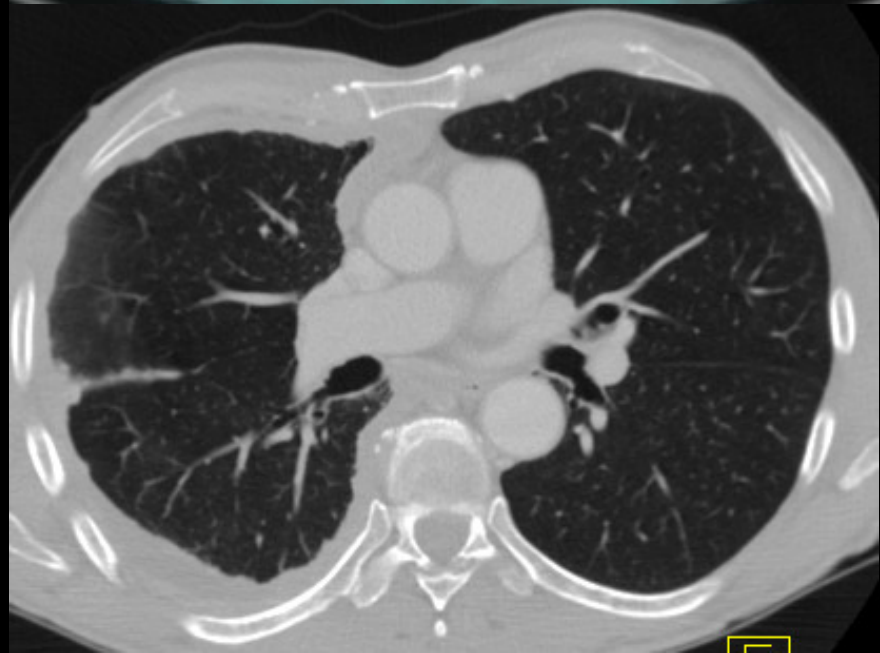
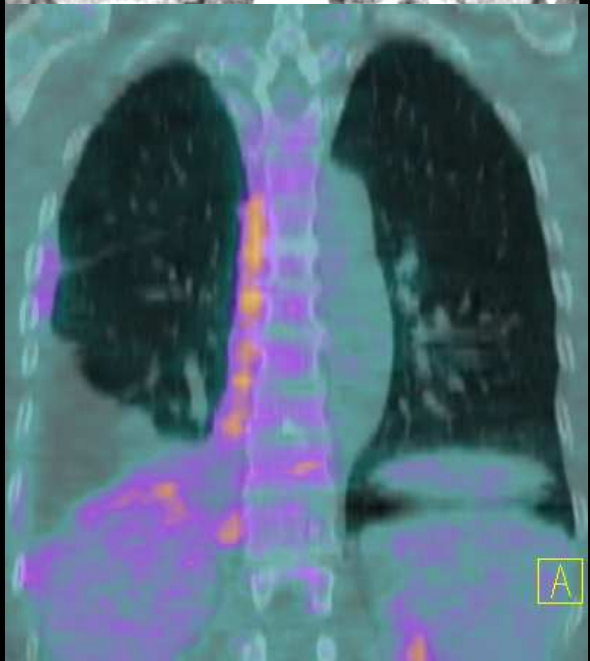
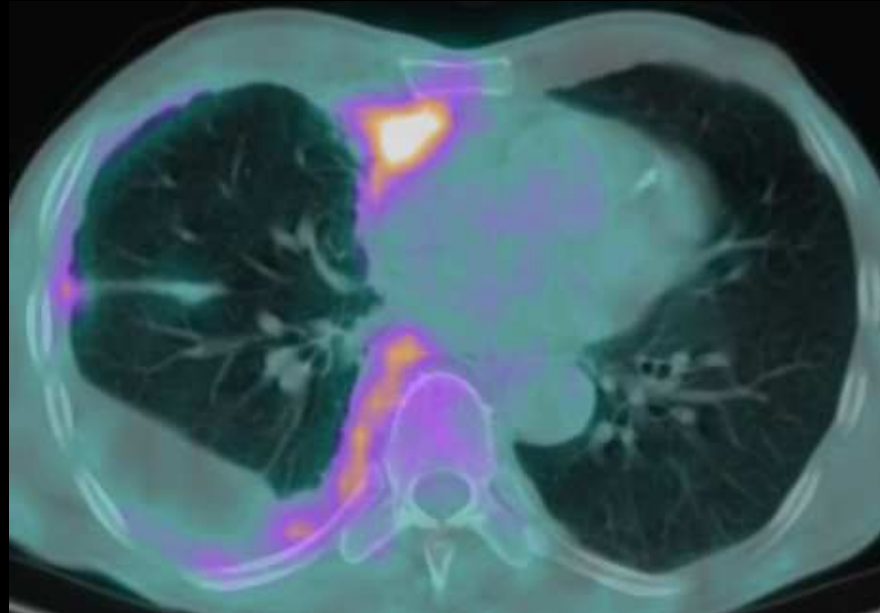
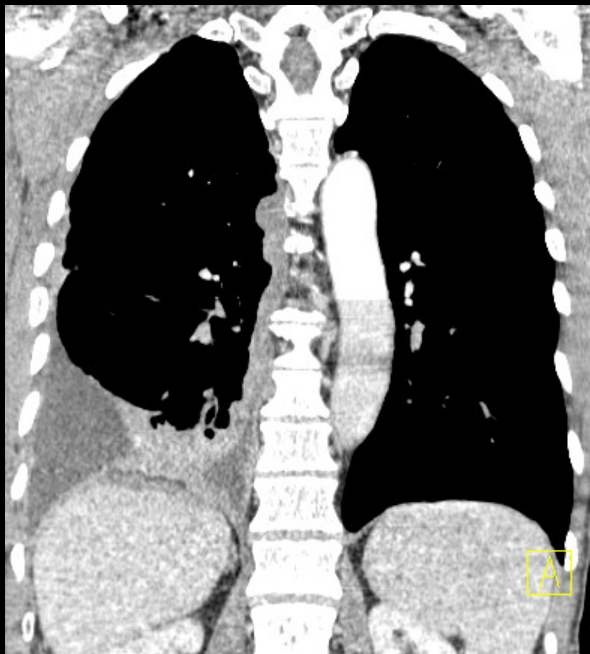
**Asbestose**



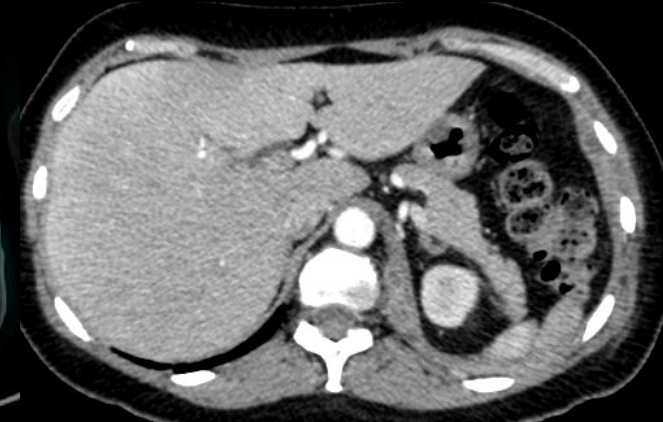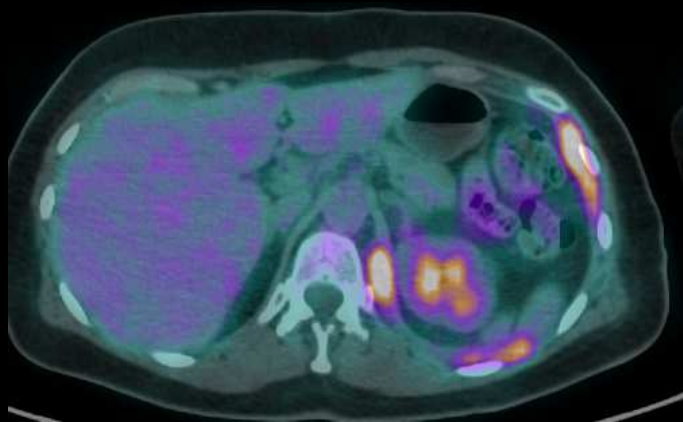
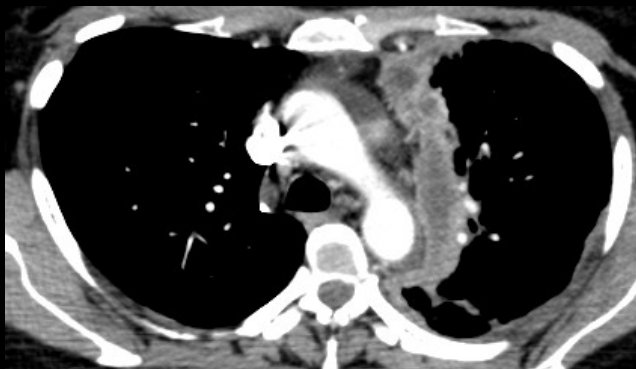
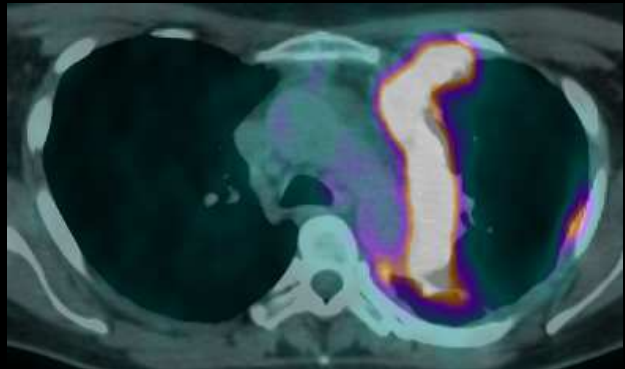
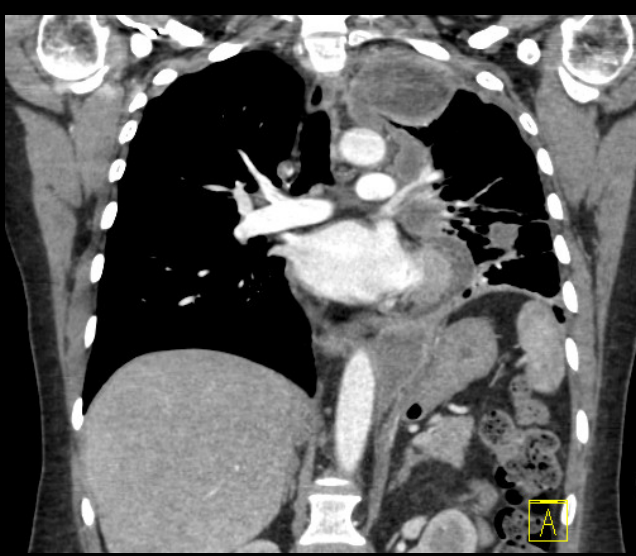
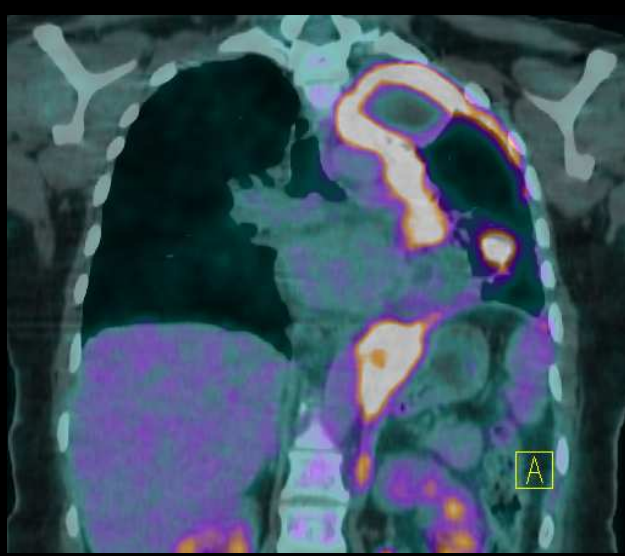
**Mésothéliome**

**Pachypleurite**

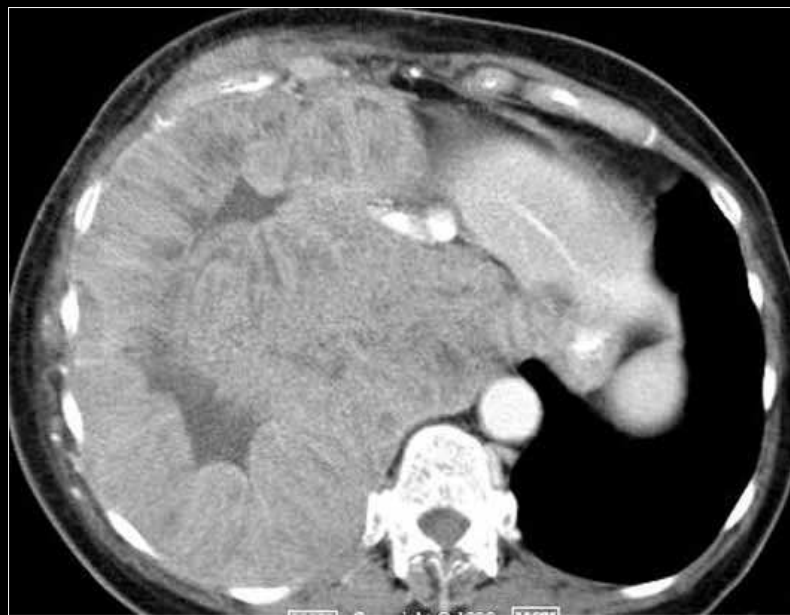
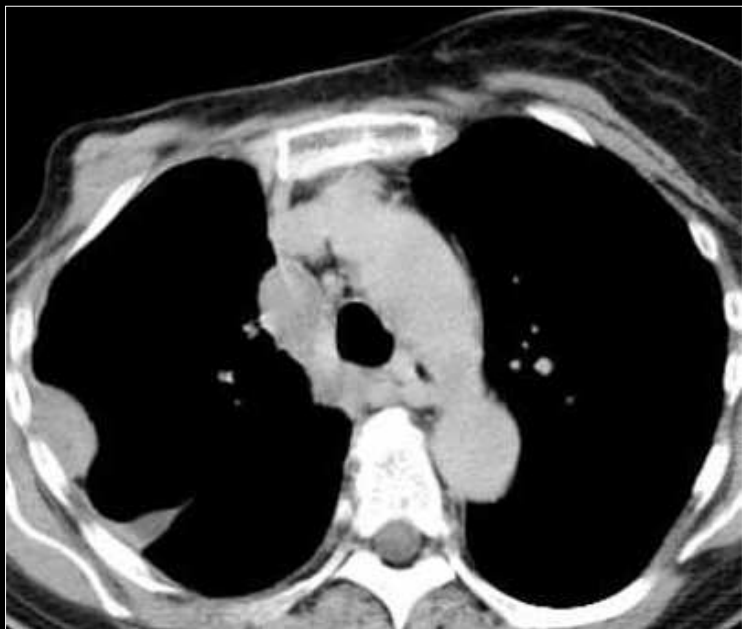


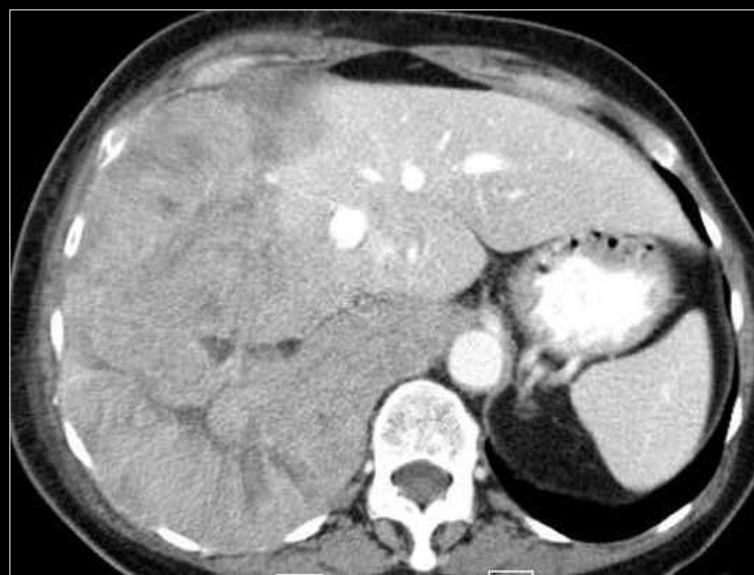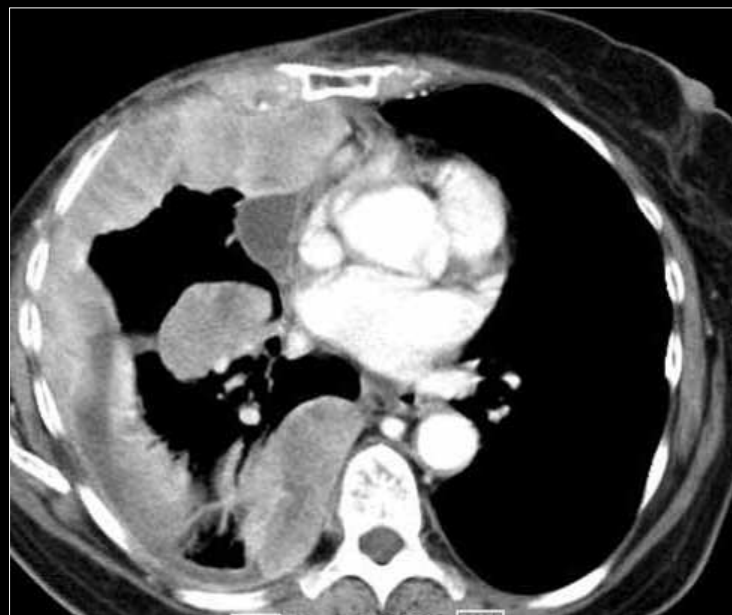
**Mésothéliome**



**Mésothéliome**



**Métastases K sein**

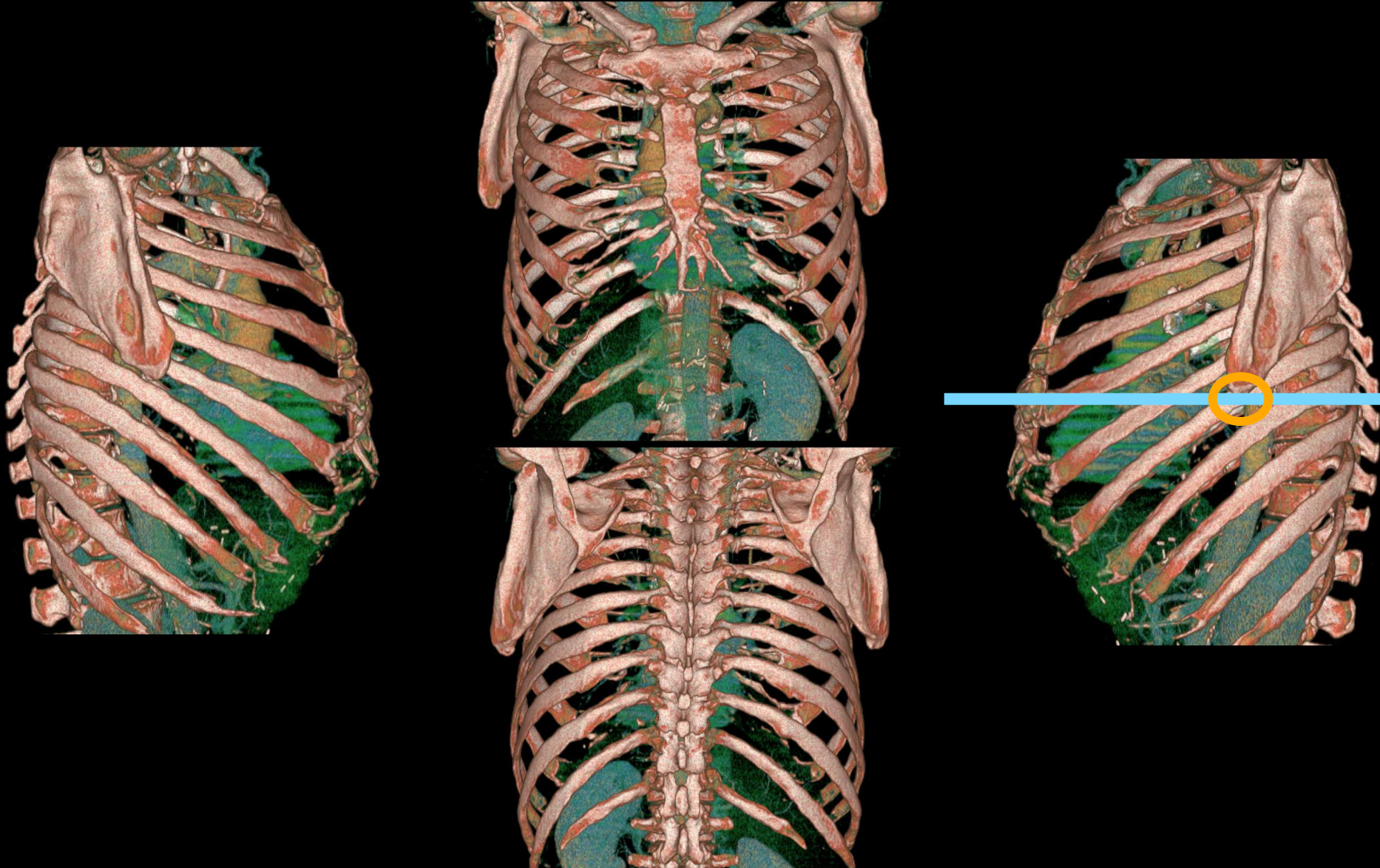


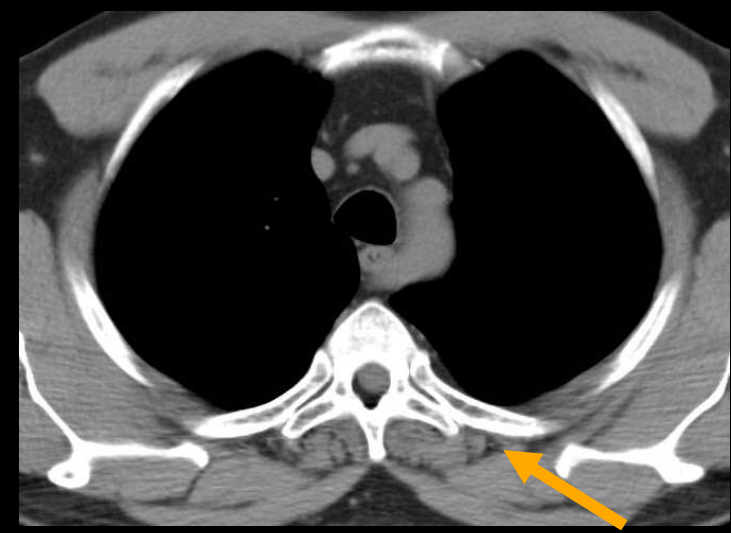
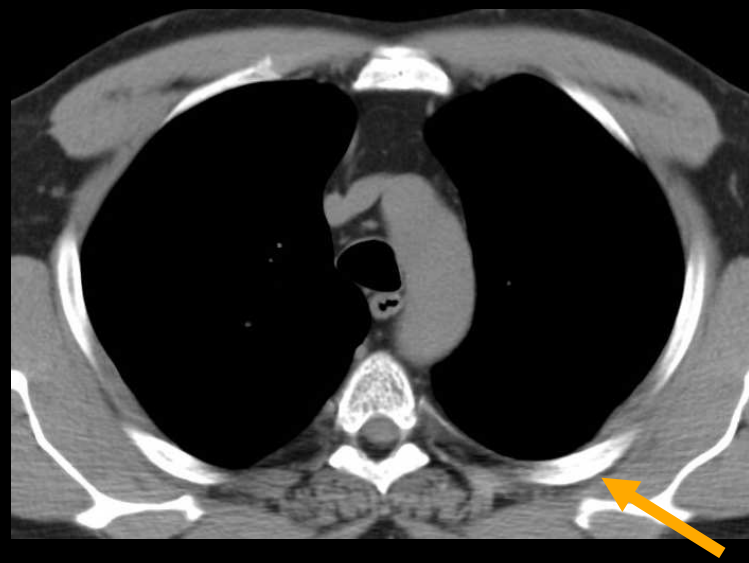
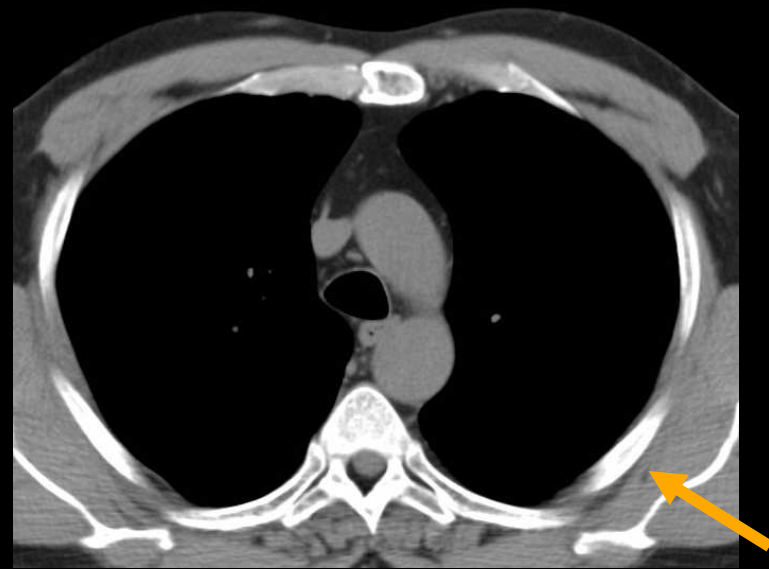
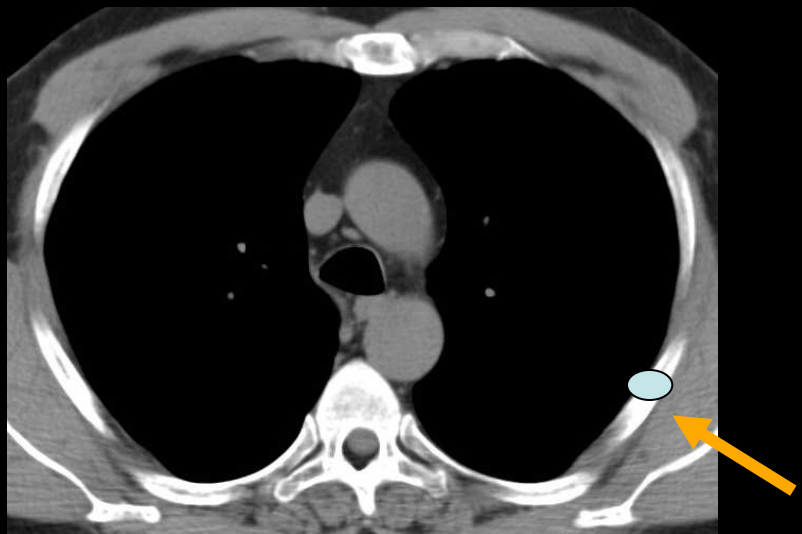


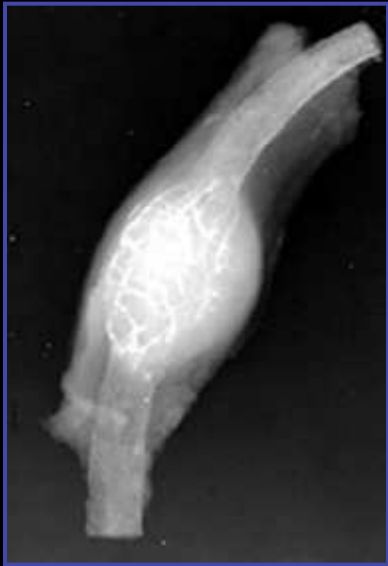
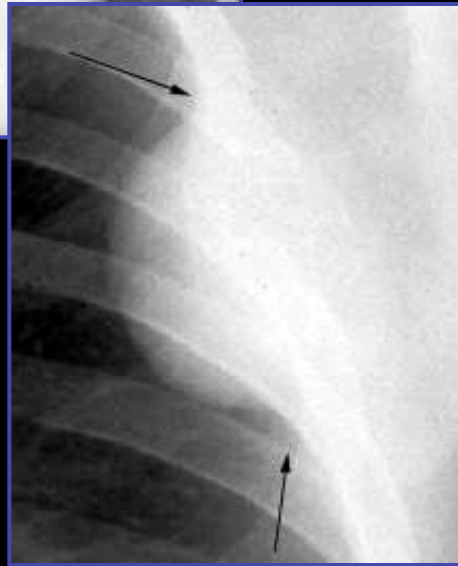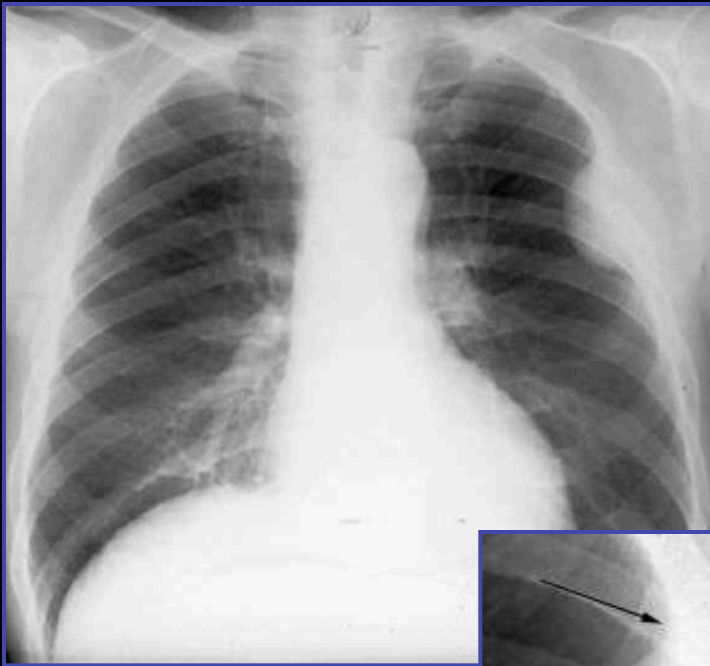
## 3/ PAROI THORACIQUE

- PLEVRE
- **CÔTES**

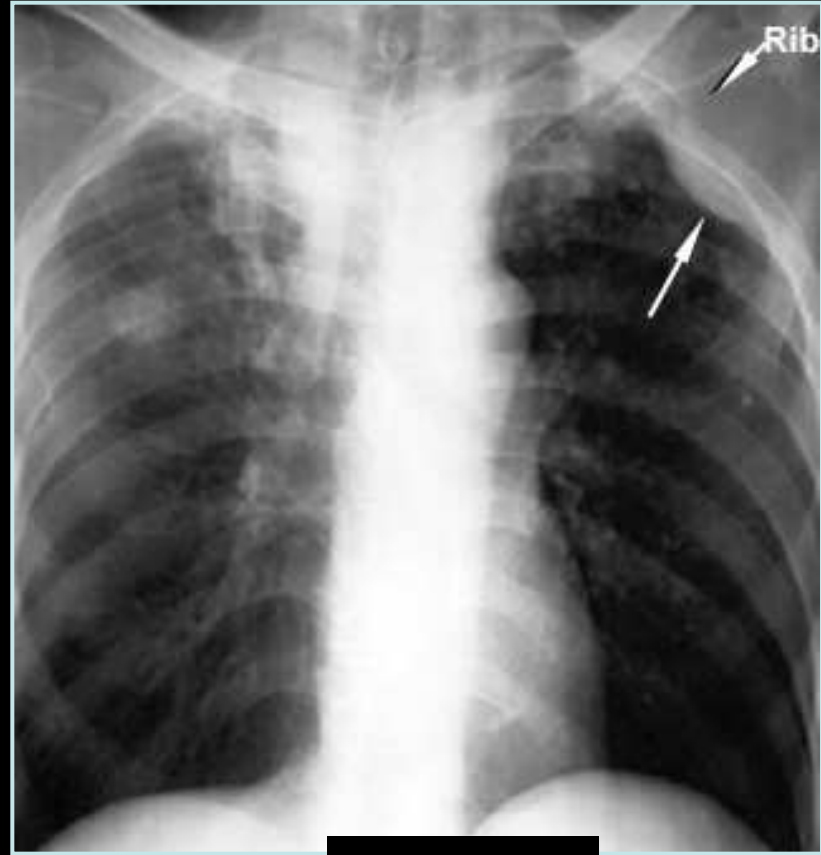# Les côtes



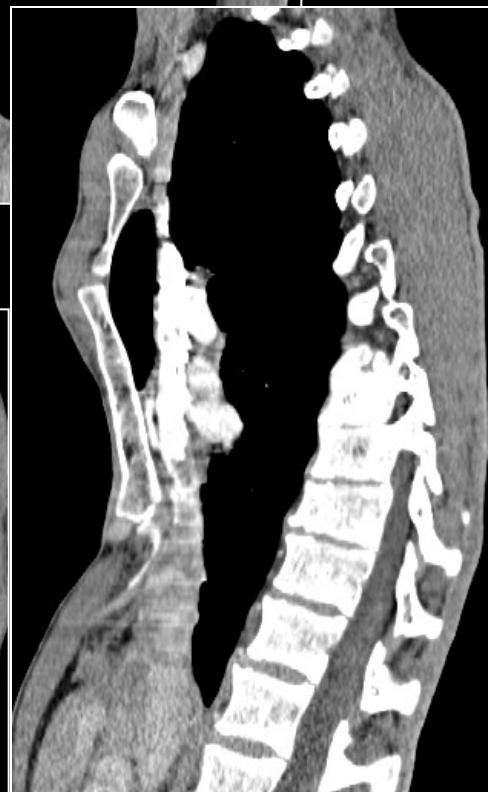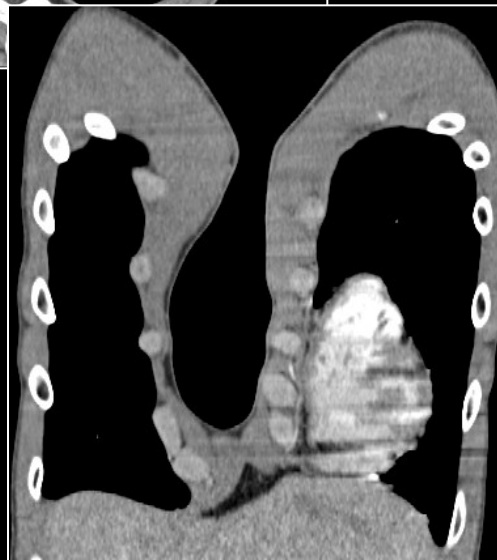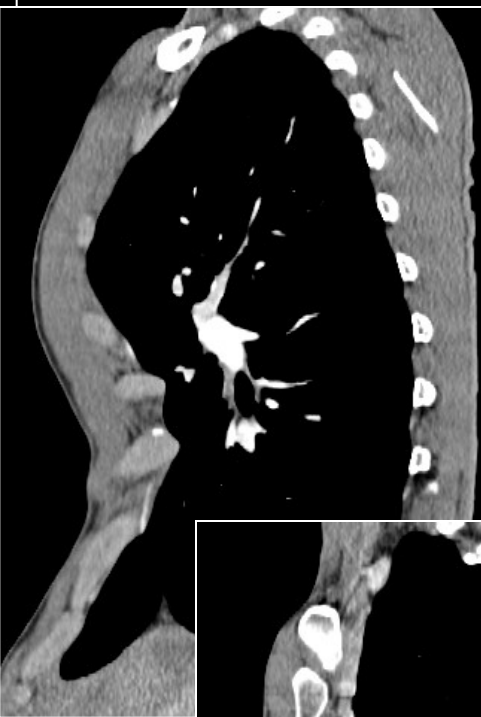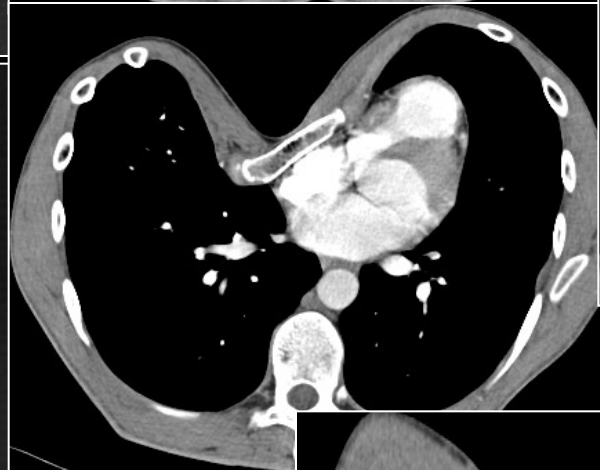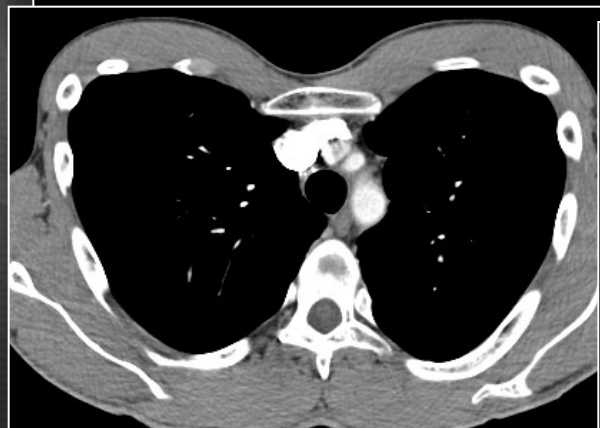
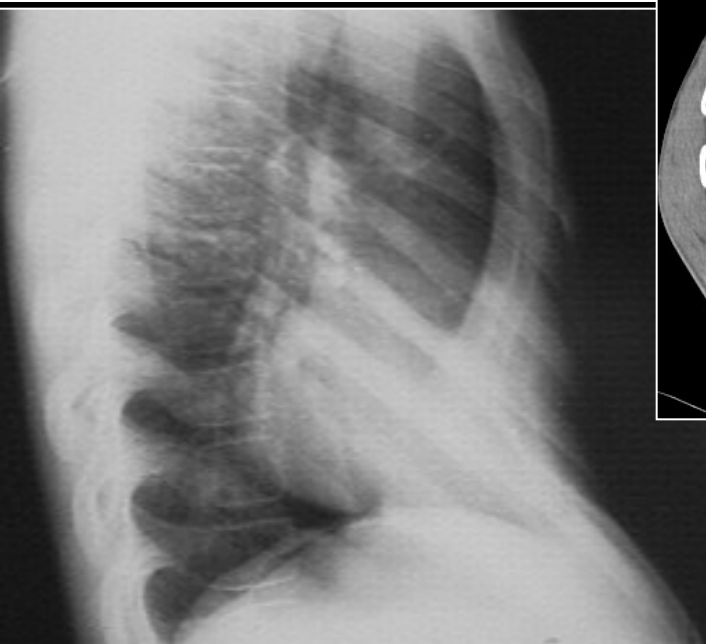
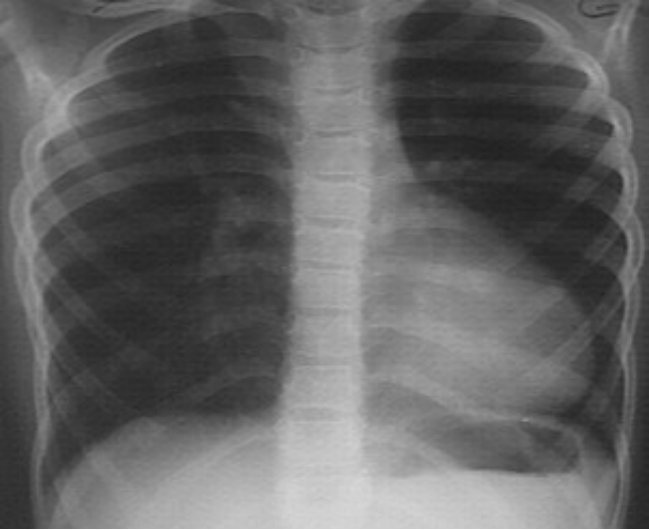




**Plasmocytome**

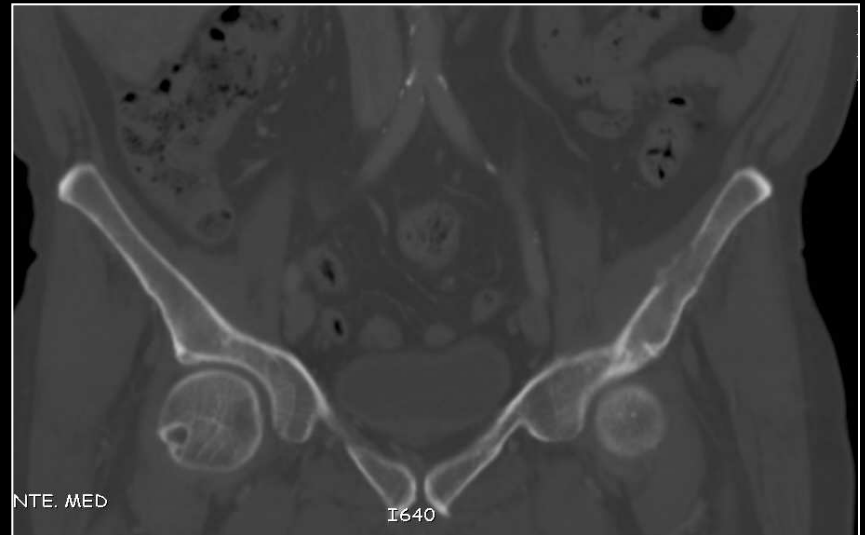
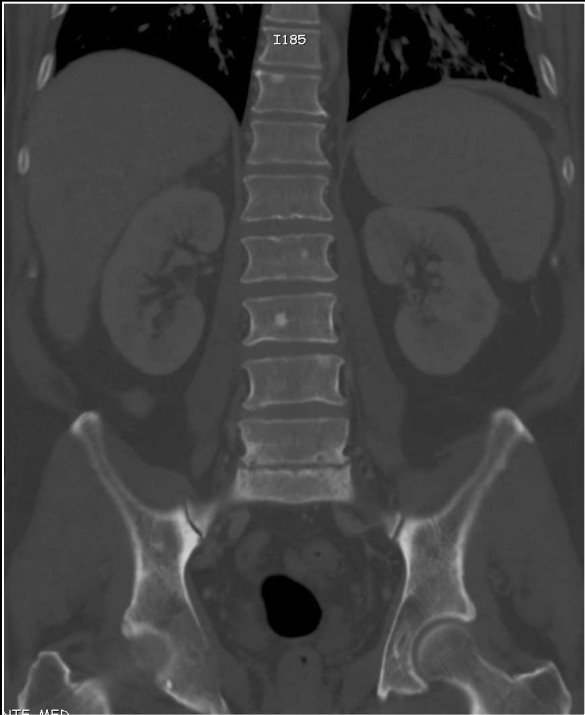
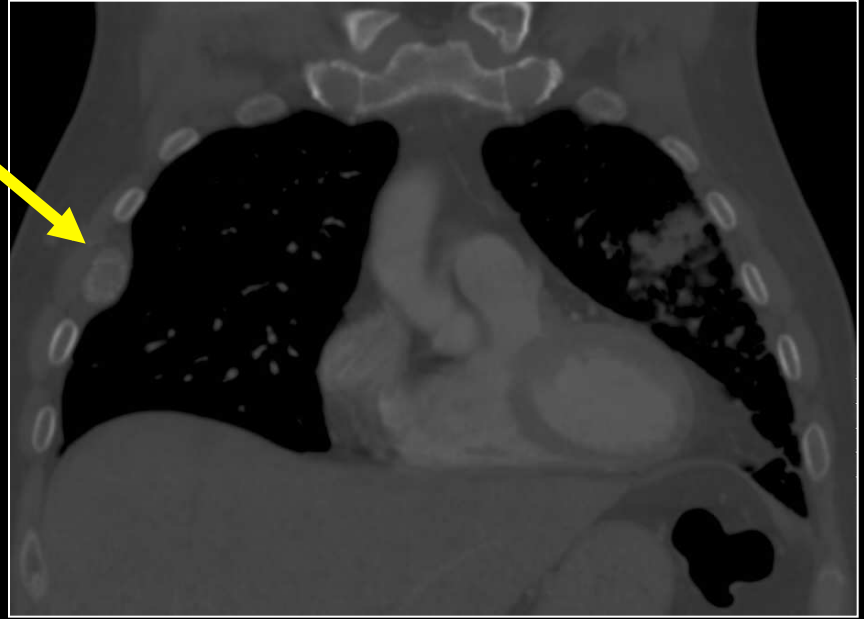
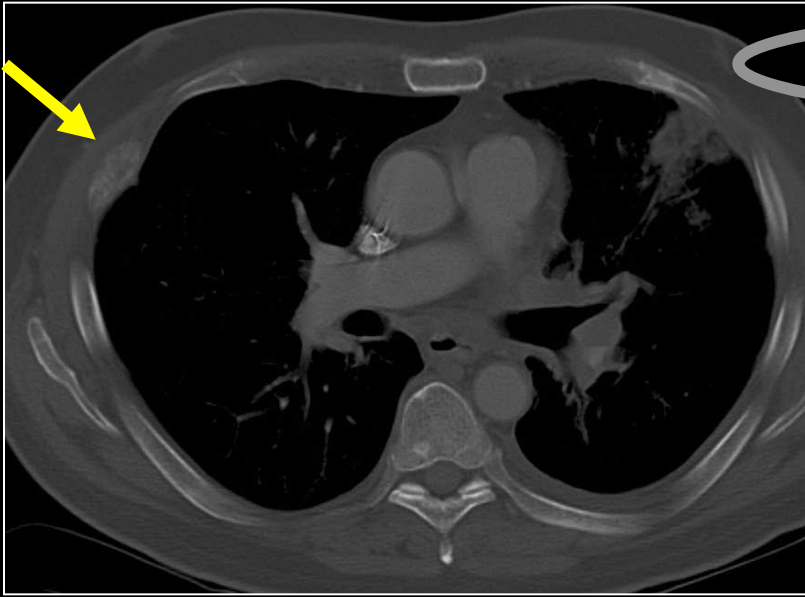


**Métastase**



**Pectus excavatum**

# Métastase de carcinome bronchique



# Autres traceurs TEP

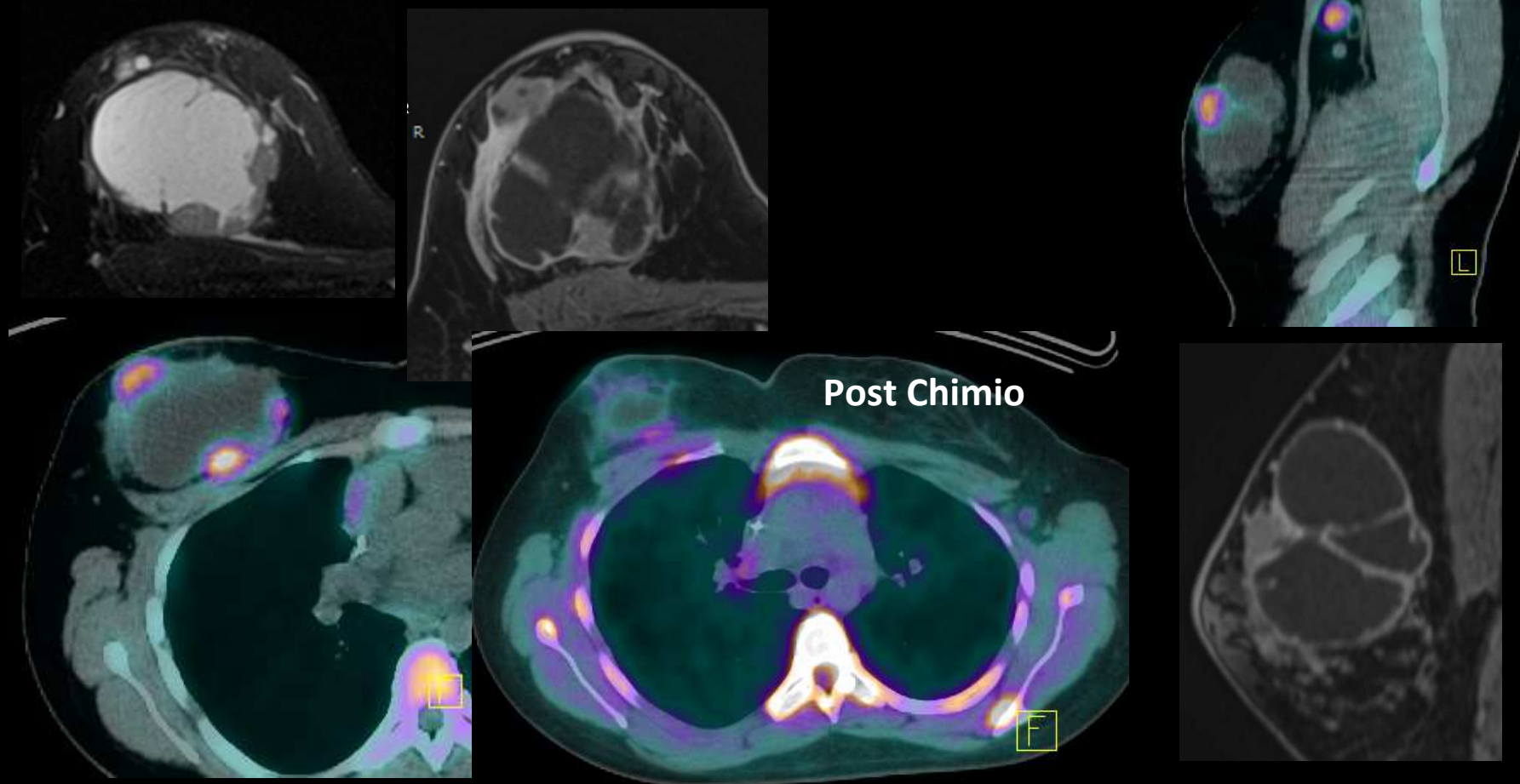
## **$^{18}\text{F}$ -Fluorodésoxythymidine**

## **$^{18}\text{F}$ -FLT**

- **Analogue de la thymidine**
- **Marqueur de la synthèse d'ADN et donc traceur de la prolifération cellulaire**
- **Essais cliniques chez l'homme, en particulier dans les cancers du sein, poumon, lymphomes, les tumeurs primitives cérébrales...**
- **Fixation très importante au niveau hépatique et ostéo médullaire rendant la détection de lésion peu sensible à ce niveau**
- **Traceur prometteur pour déterminer la réponse précoce au traitement**

# TEP $^{18}\text{F}$ -FLT

Récidive multifocale d'un carcinome mammaire infiltrant de grade III triple négatif



***Merci de votre attention!!!***