

Syndromes douloureux et fébriles de l'étage sous-mésocolique

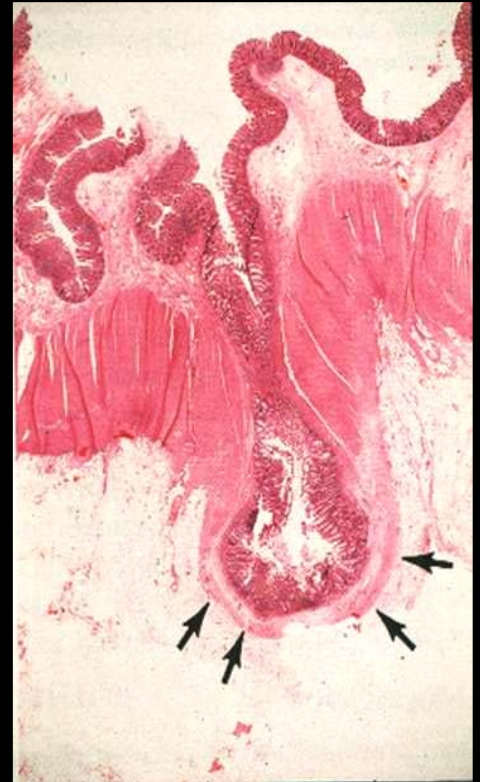
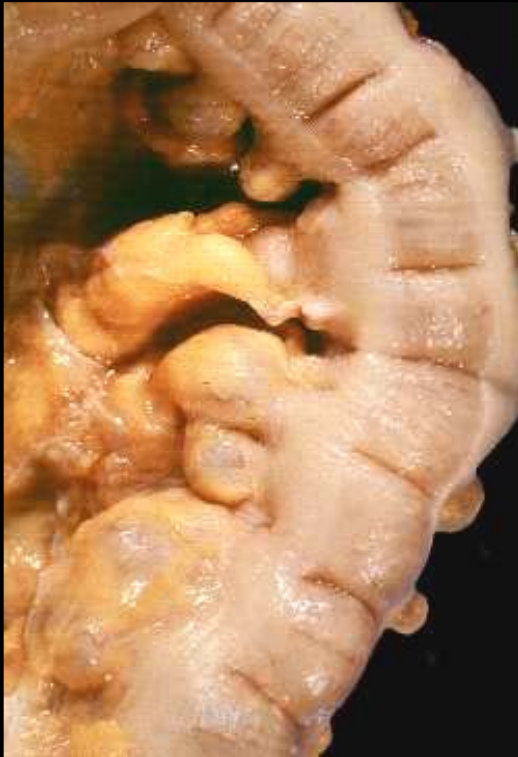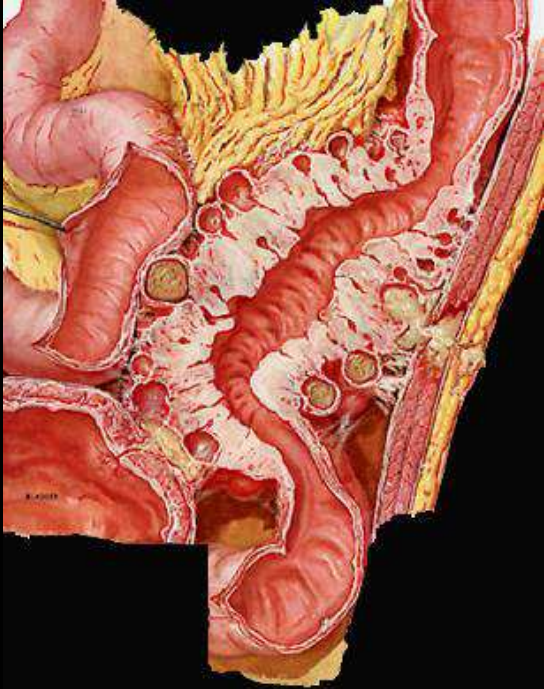
Les complications de la maladie diverticulaire du colon

Les appendagites

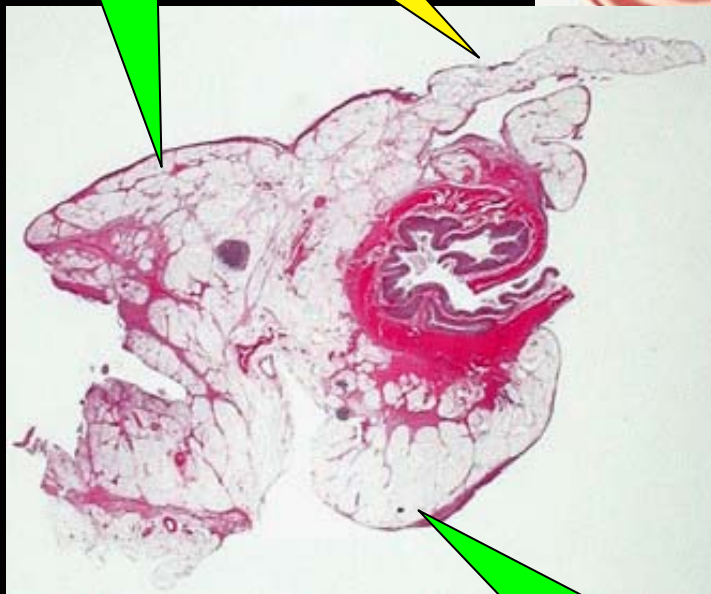
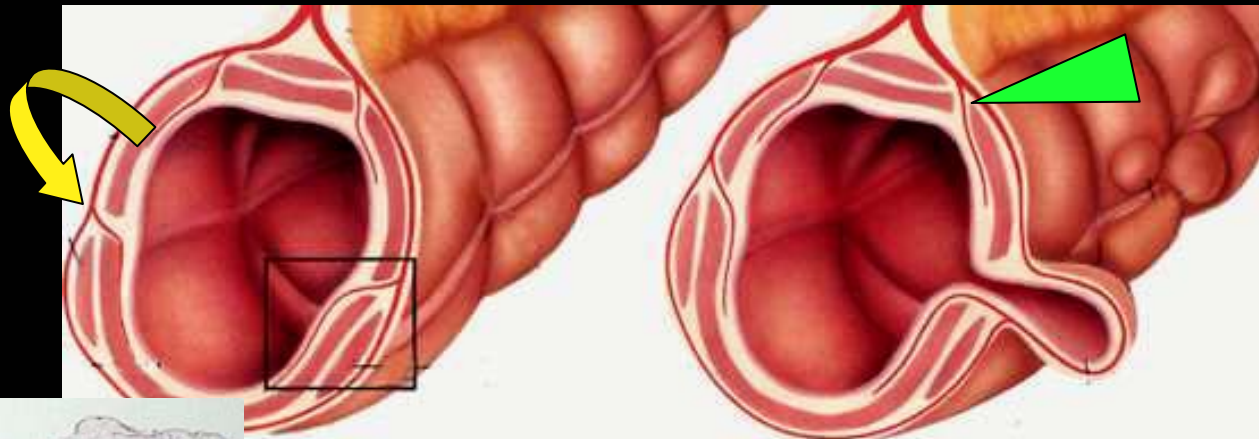
Les appendicites

Les complications du diverticule de Meckel

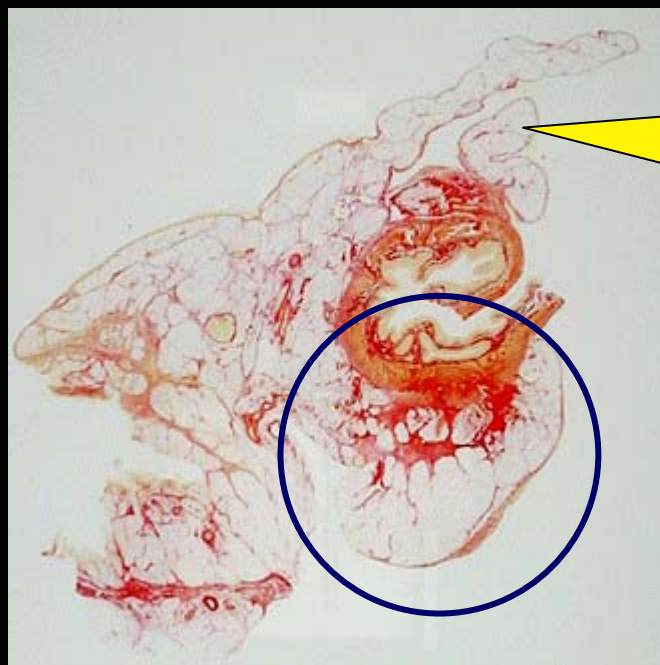les complications de la maladie diverticulaire du colon

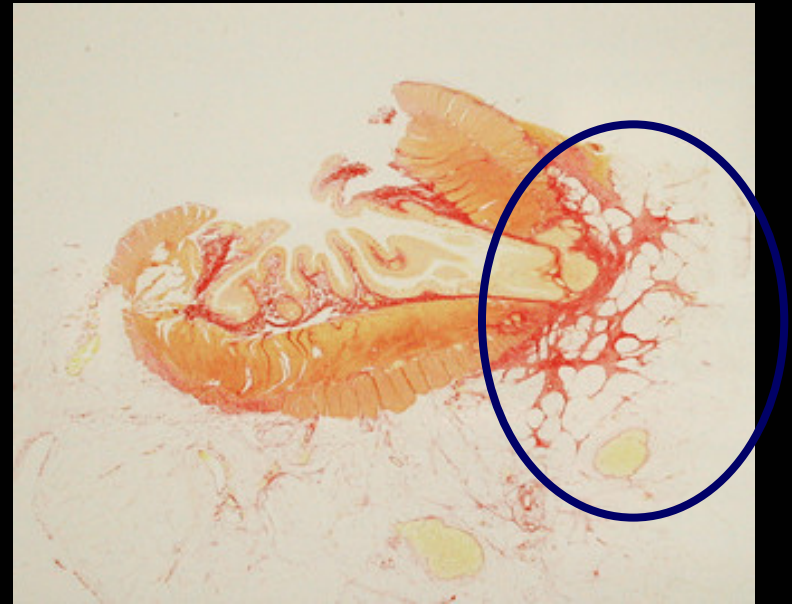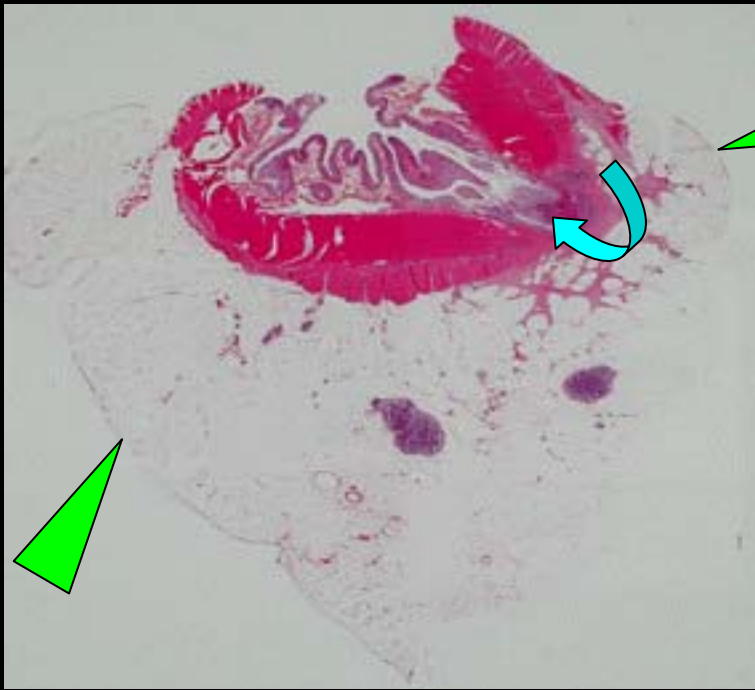

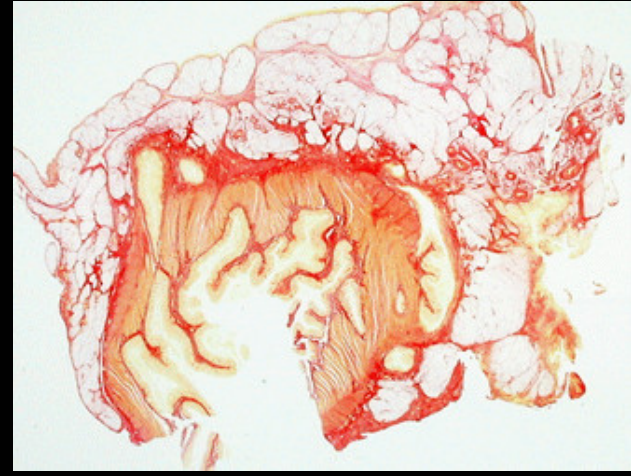
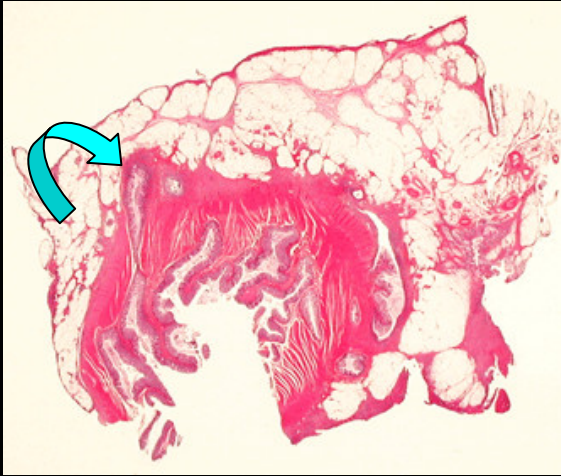appendice
épiploïque;
"appendage"

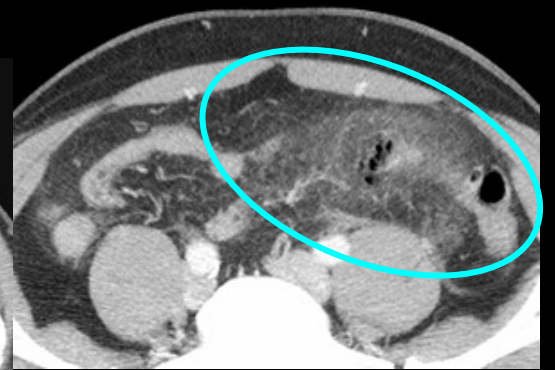
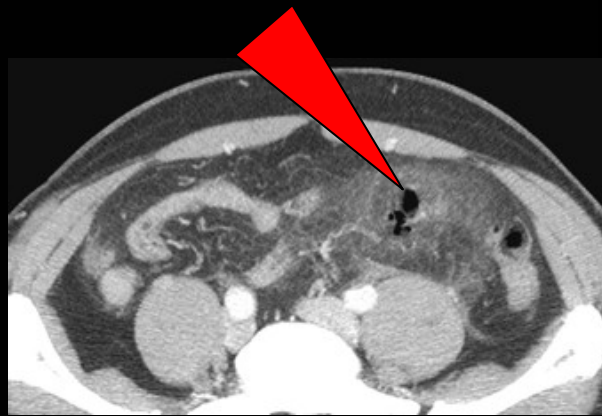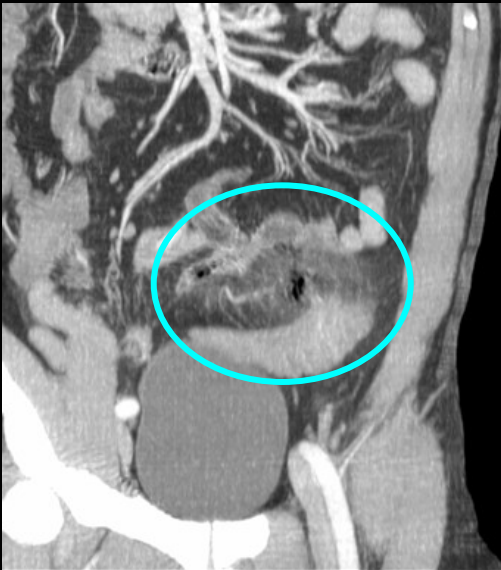
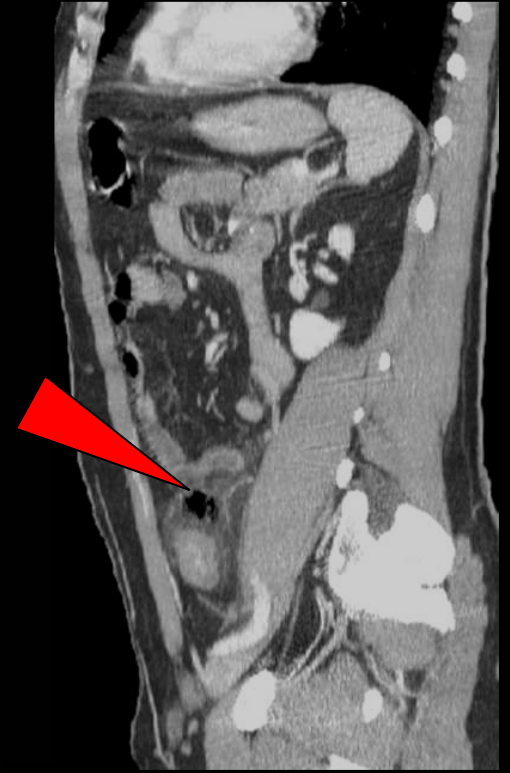
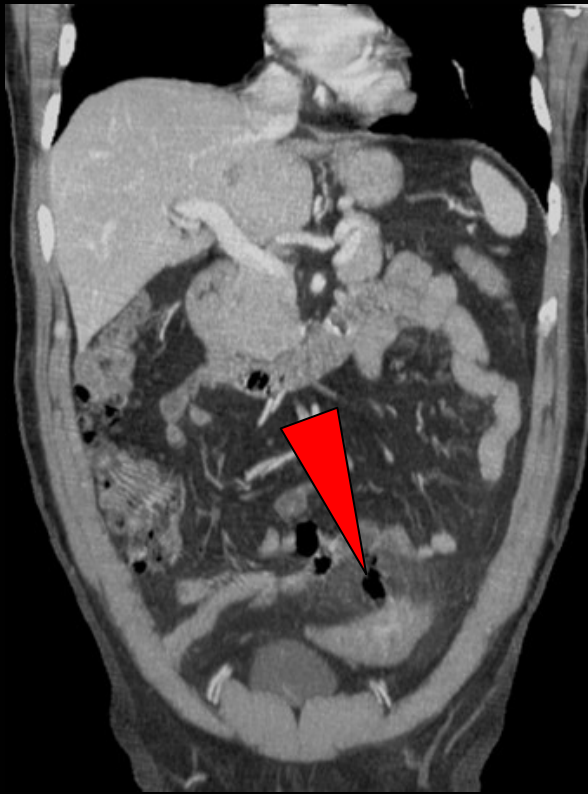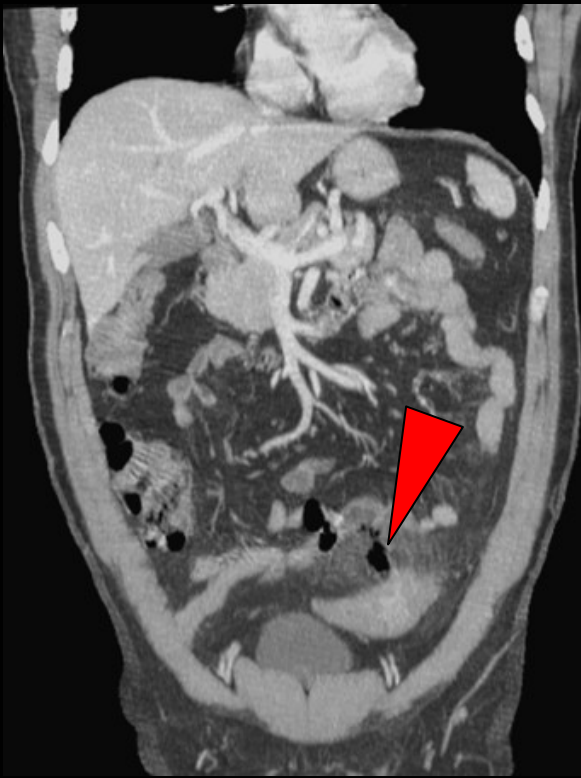


Le **mésosigmoïde** entoure le **sigmoïde** sur **270°** ou plus chez les sujets porteurs d'une maladie diverticulaire et obèses

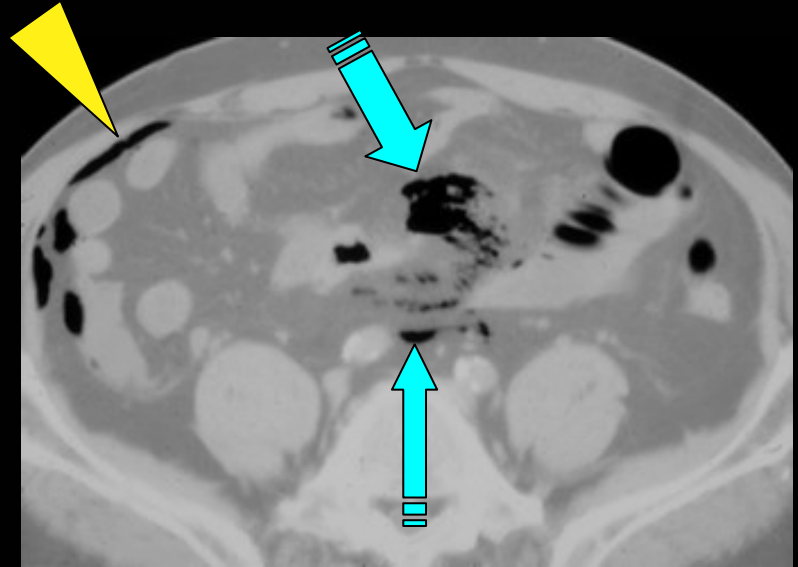
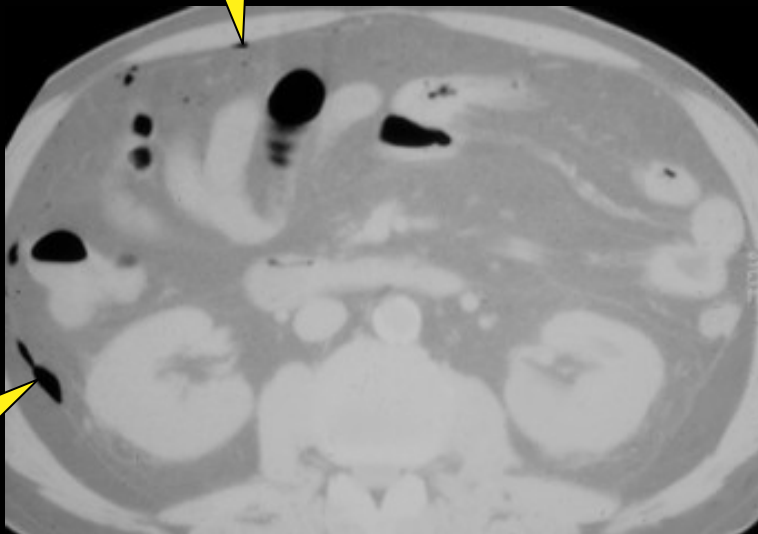
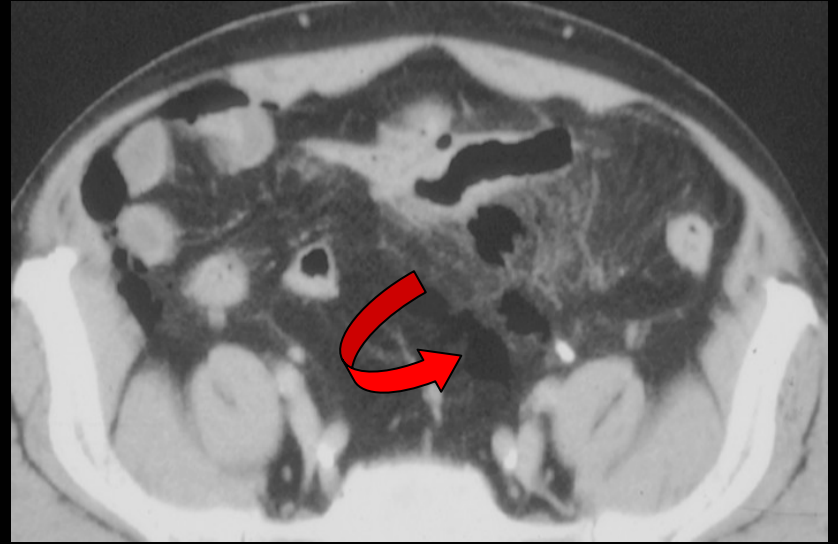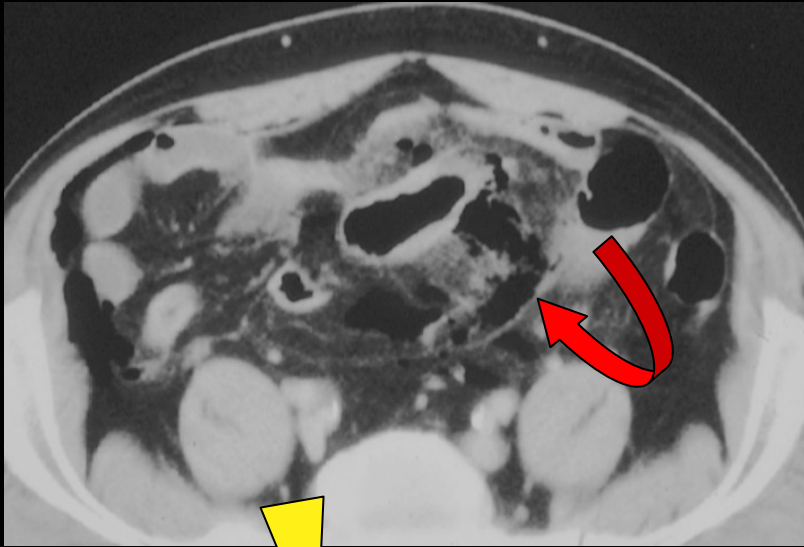




les diverticules sigmoïdiens ont beaucoup plus de chances de se perforer dans la graisse du méso qu'en péritoine libre !!!

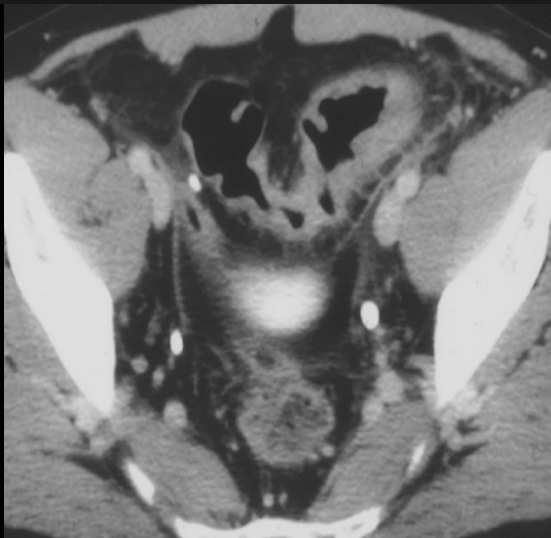


diverticulite perforée bouchée dans le mésosigmoïde

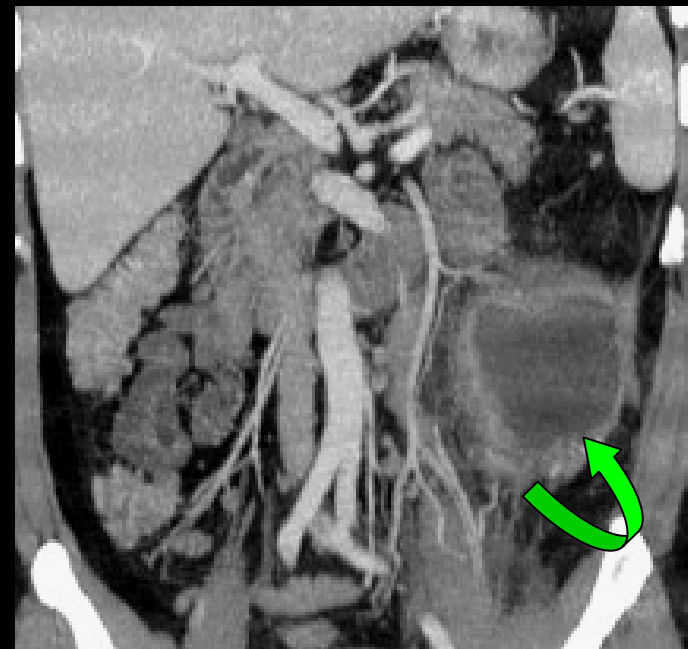
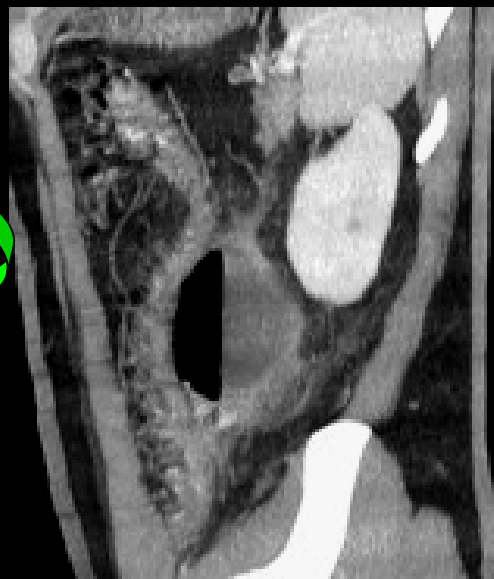
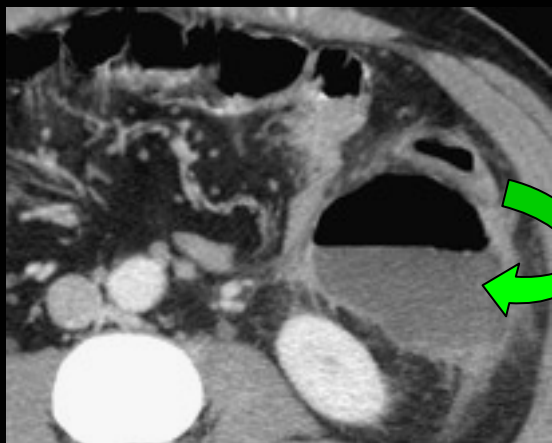
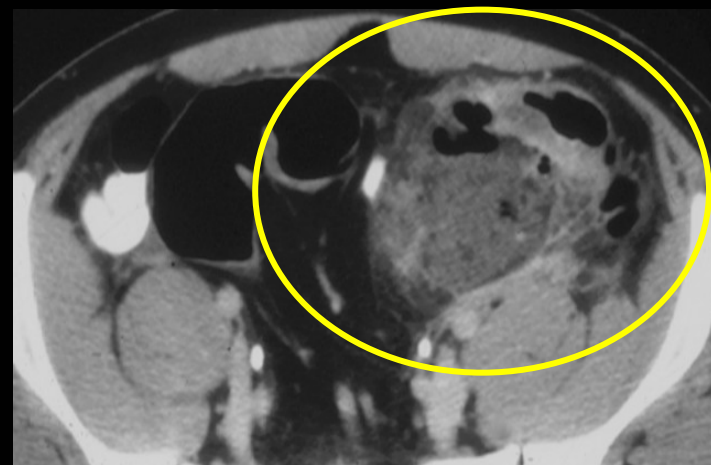


rétro pneumopéritoine sur perforation diverticulaire ; pas d'intervention immédiate !!

Quand faut-il drainer les infections péri-coliques ?

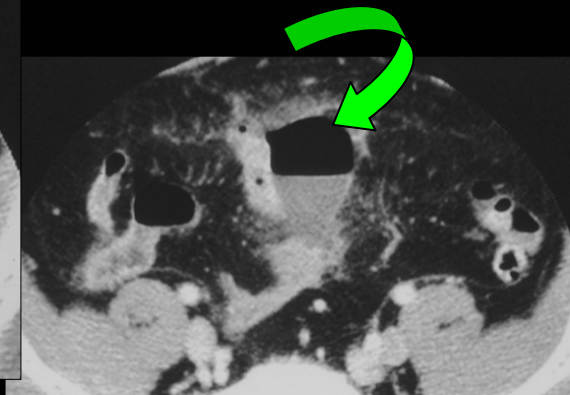
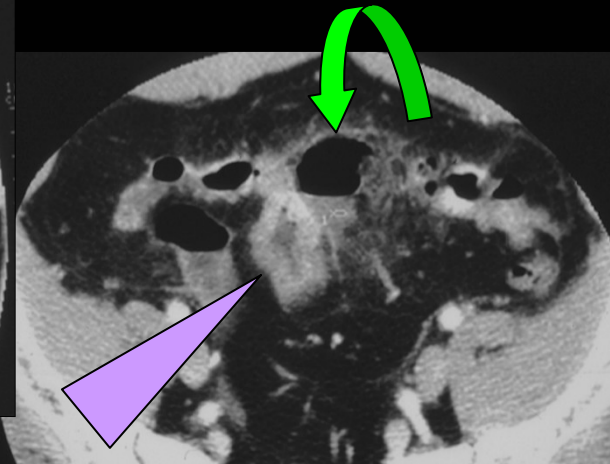
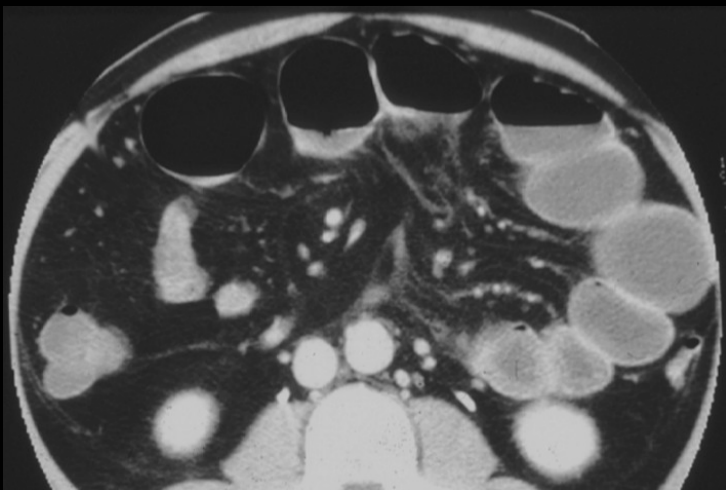
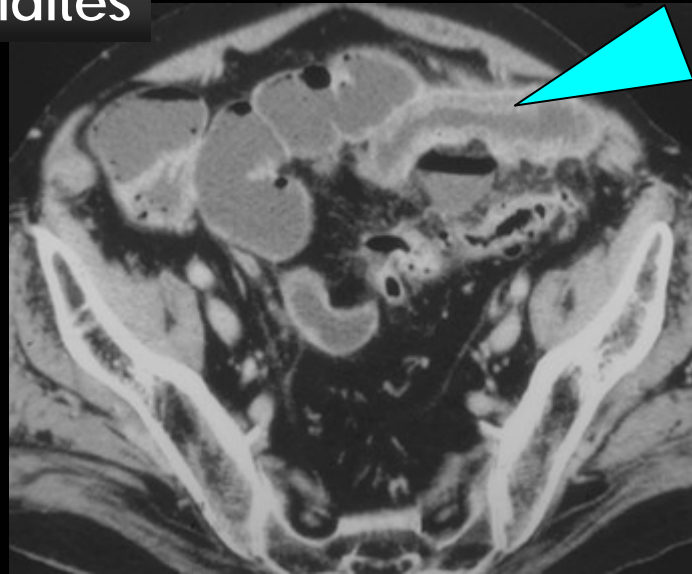
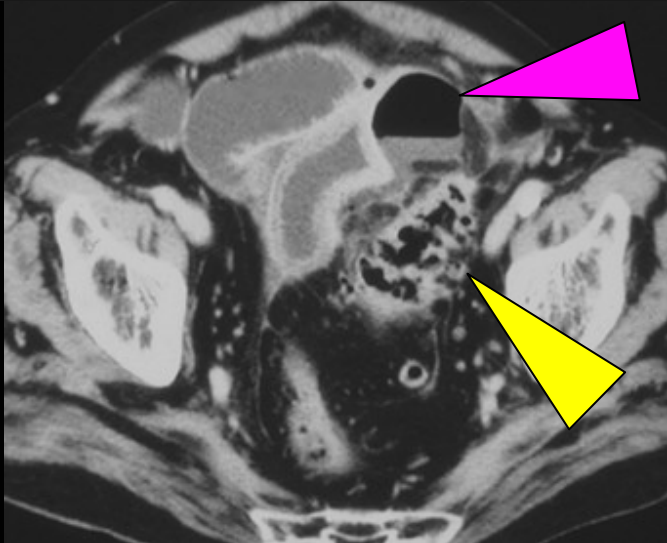


" phlegmon " du
mésosigmoïde :
traitement médical



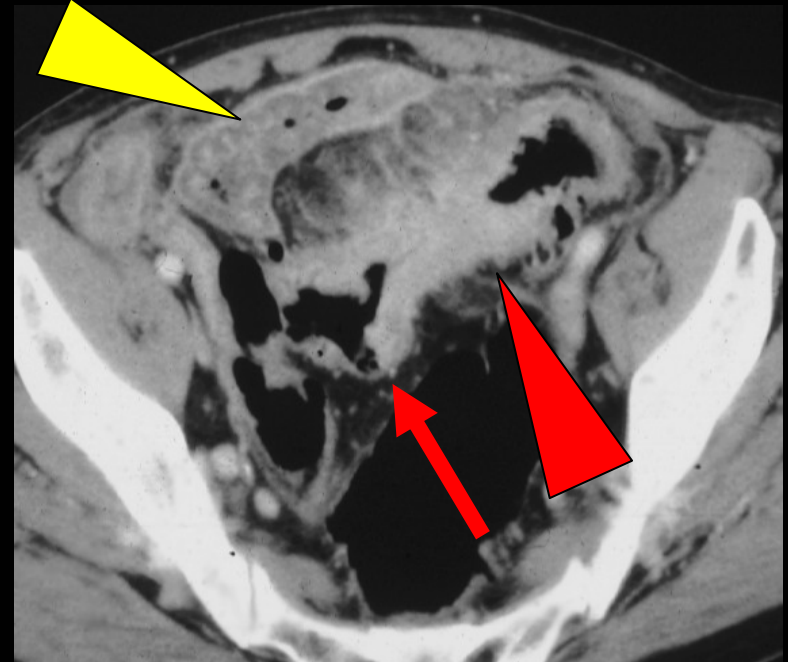
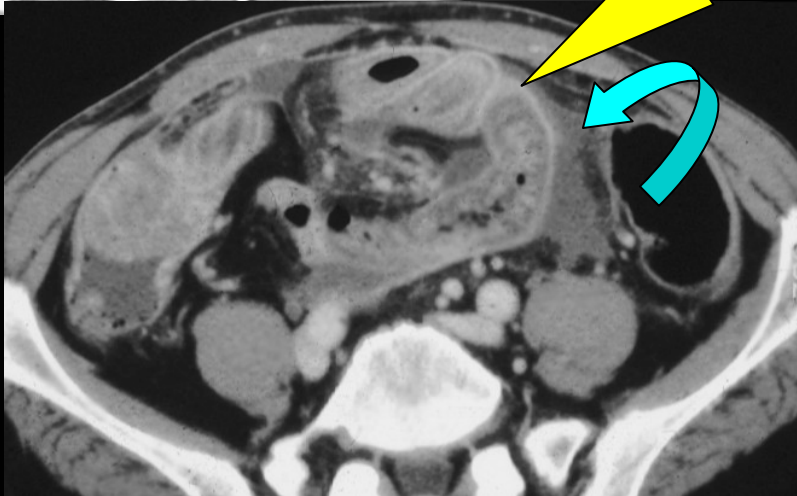
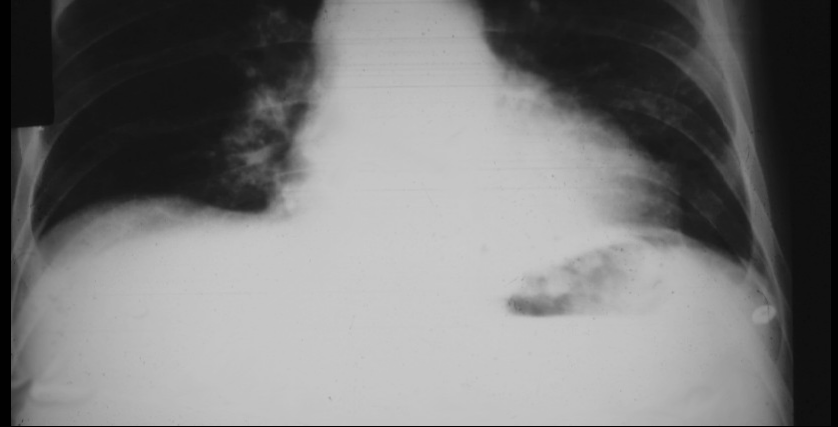
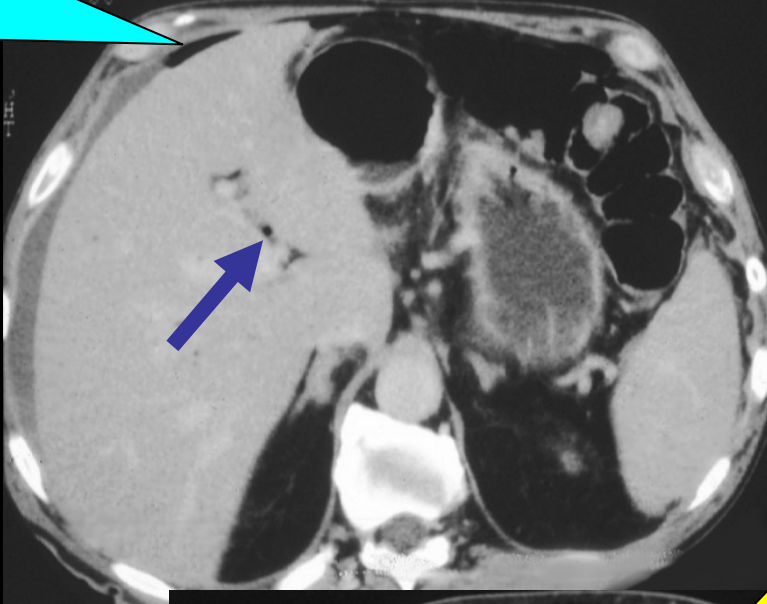
abcès para colique gauche : drainage

formes occlusives fébriles des sigmoïdites

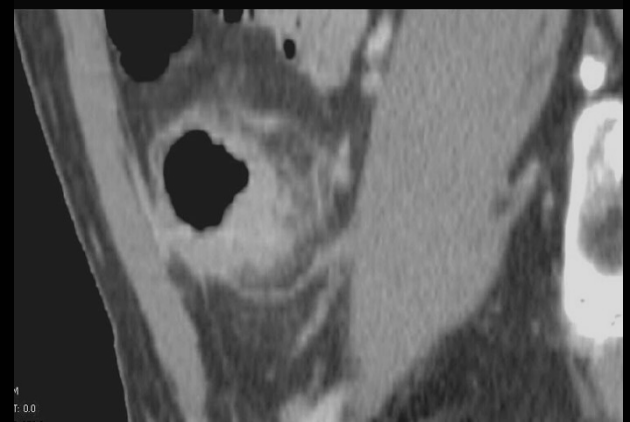
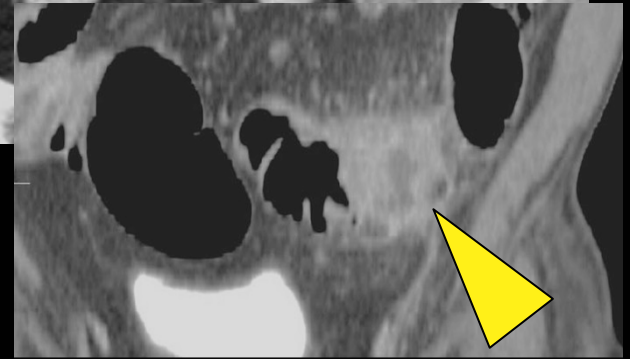
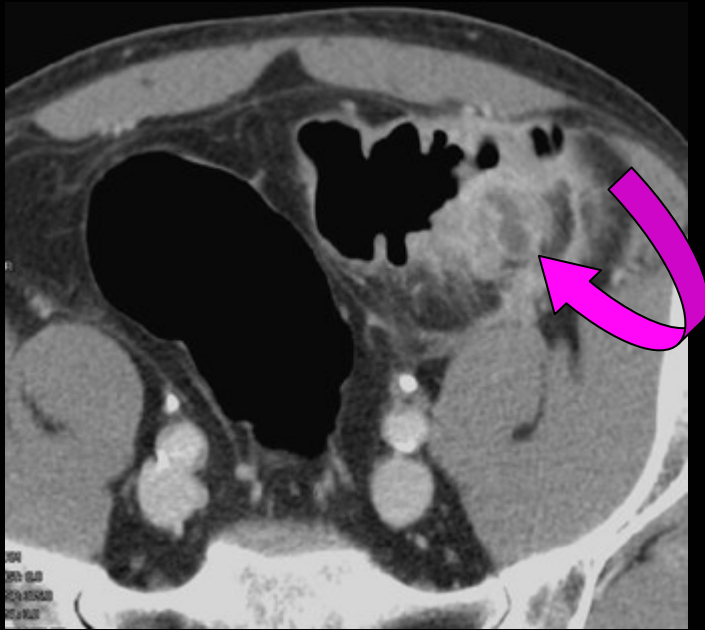
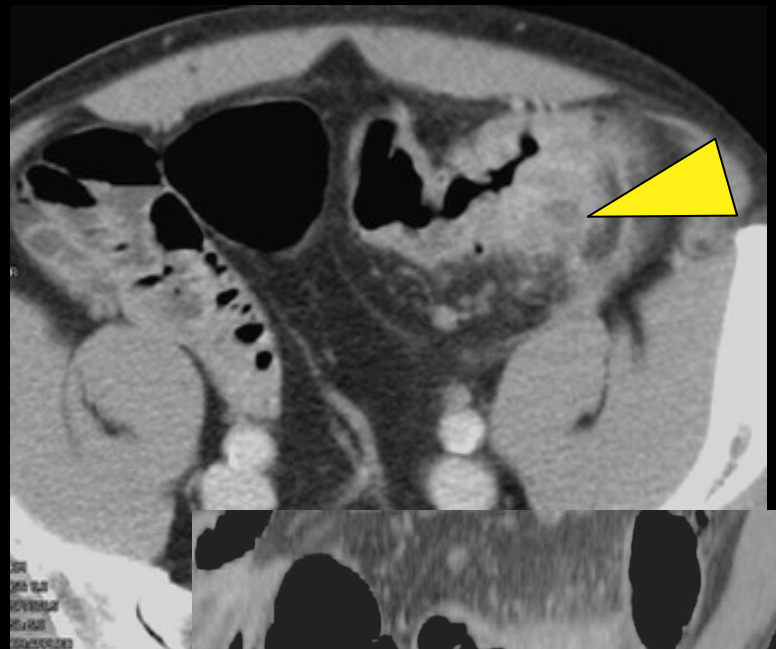
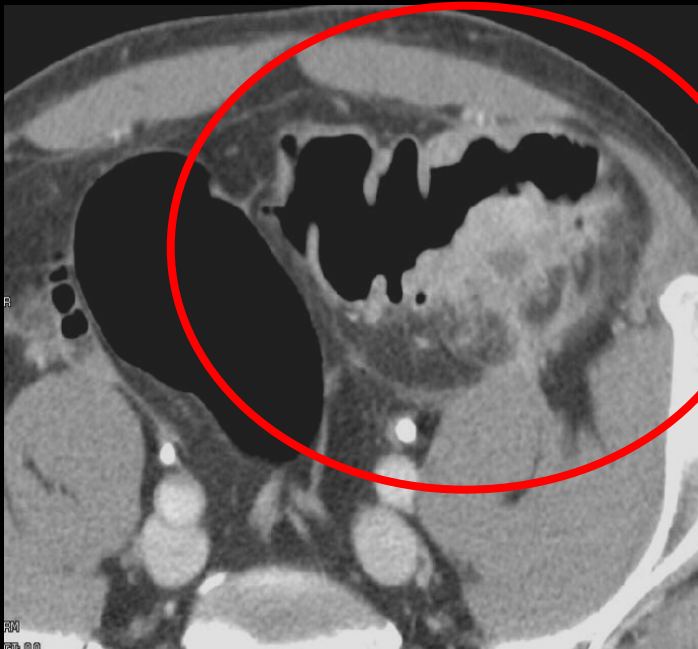

occlusion fébrile sur sigmoïdite : le plus souvent c'est le grêle qui est en cause !!!

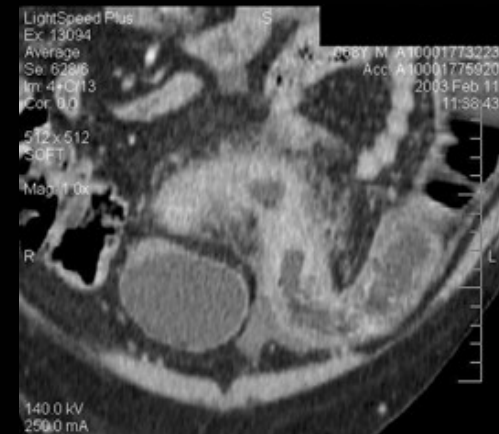
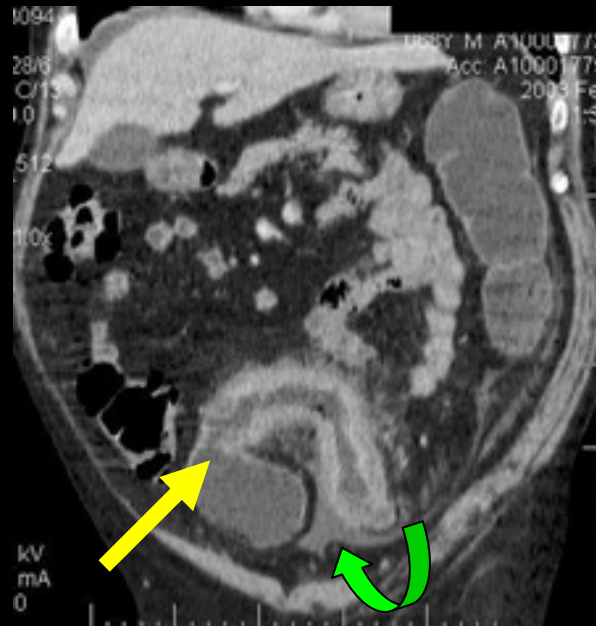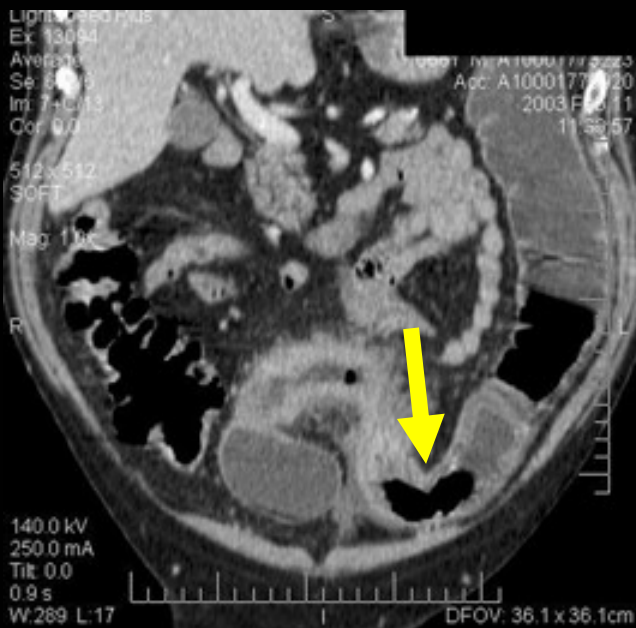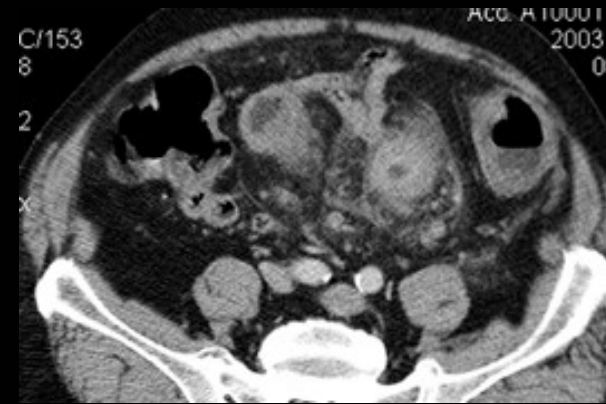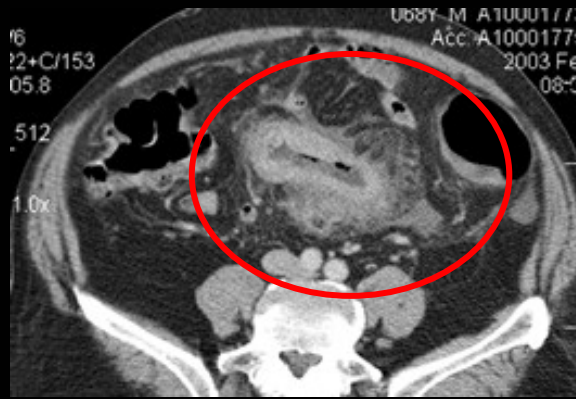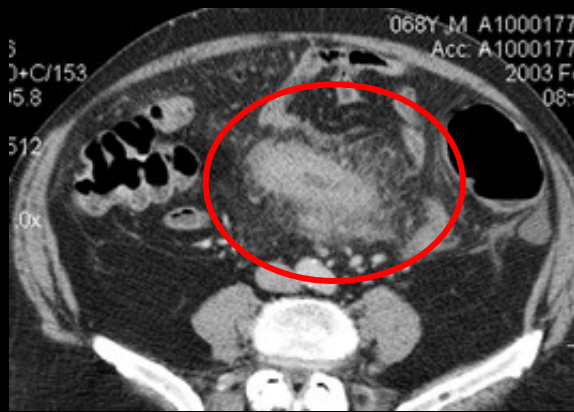
Sigmoidite ou cancer ou sigmoidite + cancer



adénocarcinome sigmoïdien
perforé



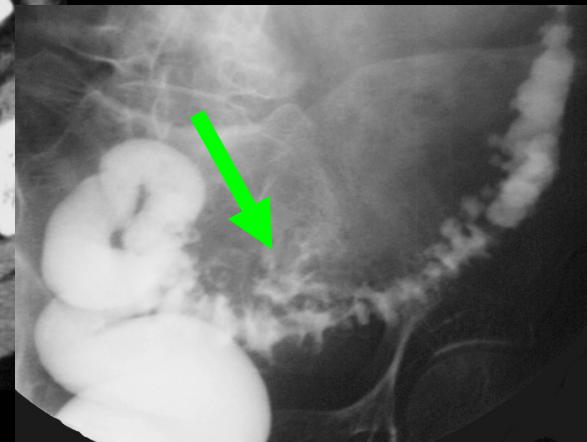
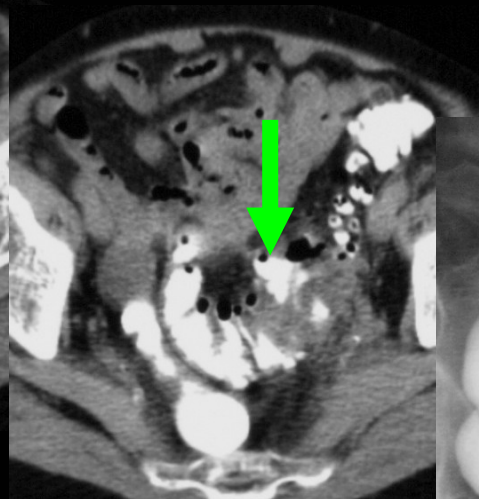
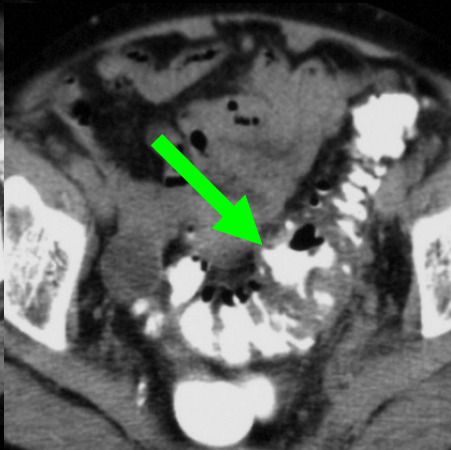
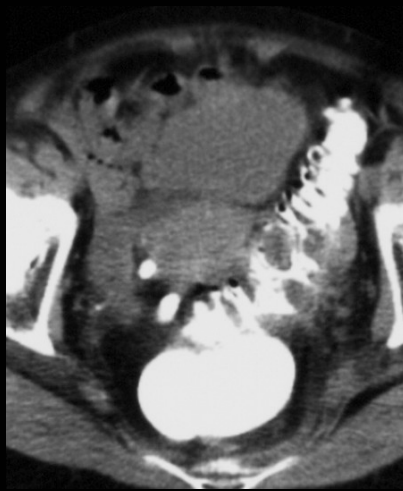
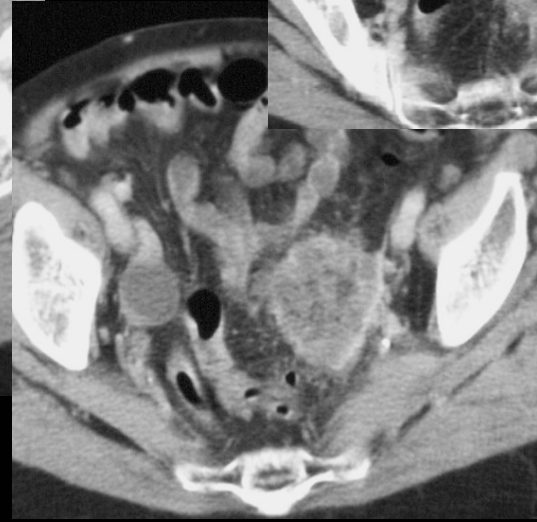
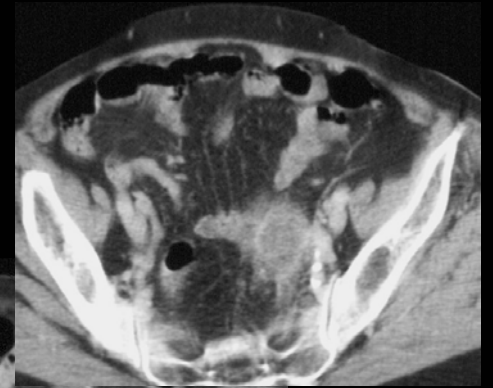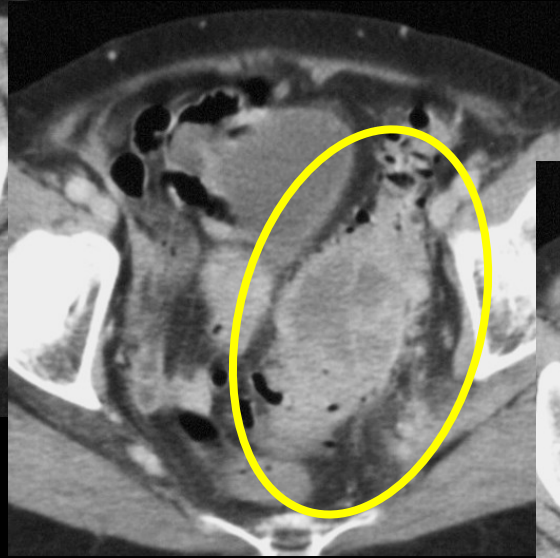
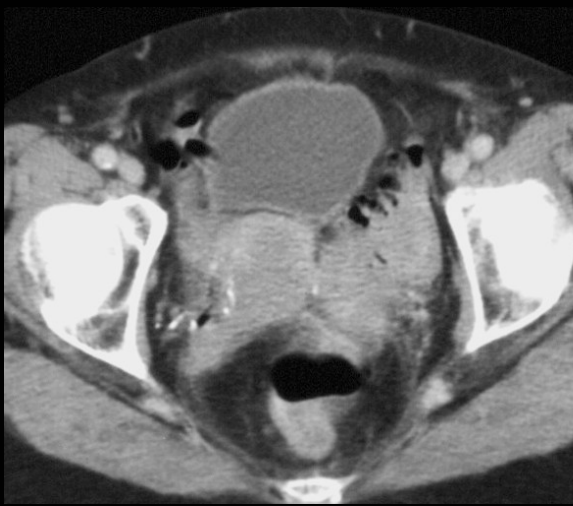sigmoïdite diverticulaire !!!



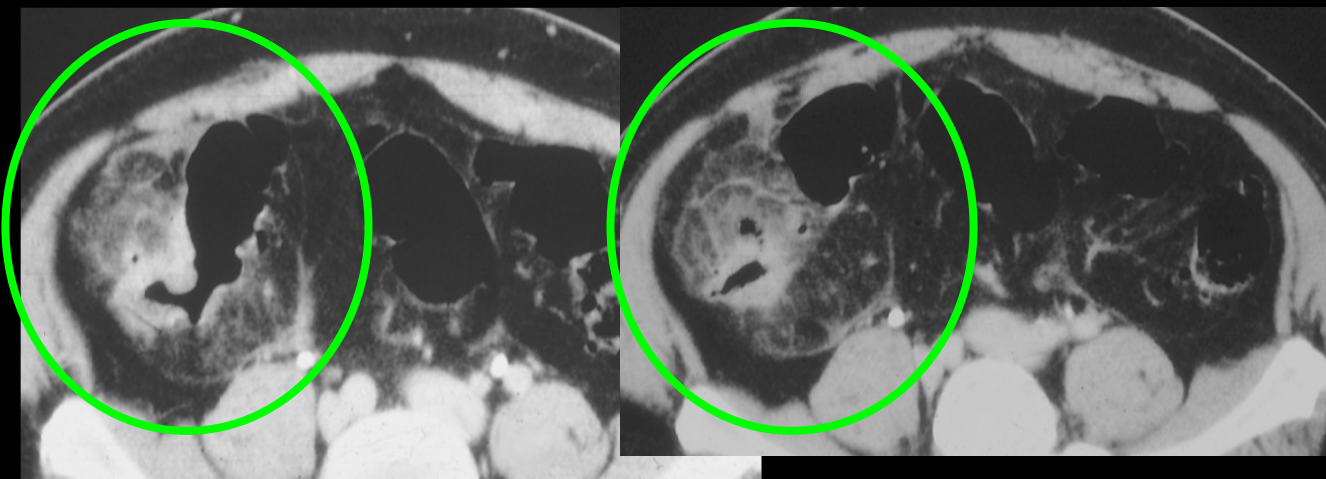
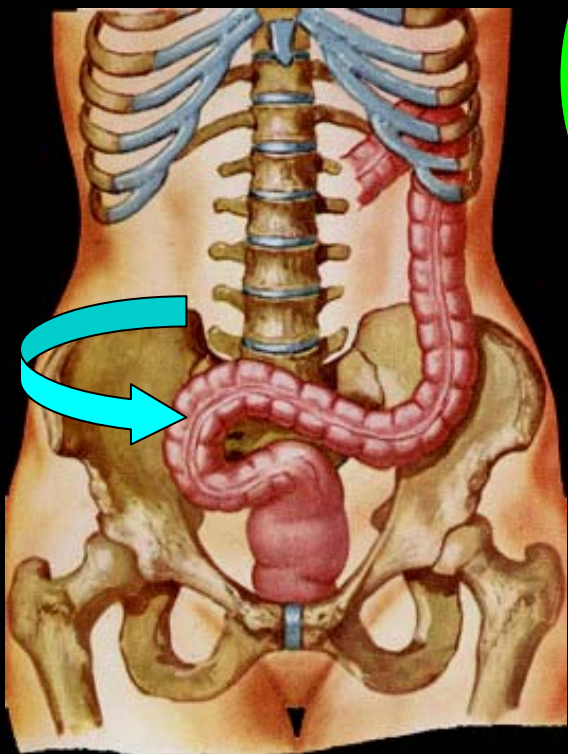
obs.M Zins Hop St Joseph Paris

adénocarcinome sigmoïdien infecté !!!

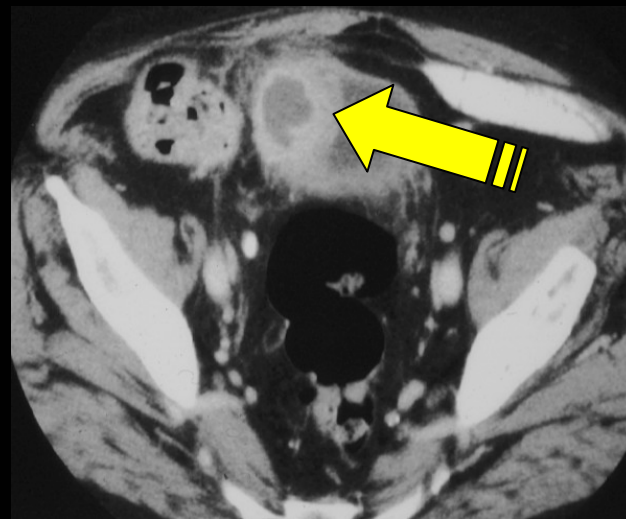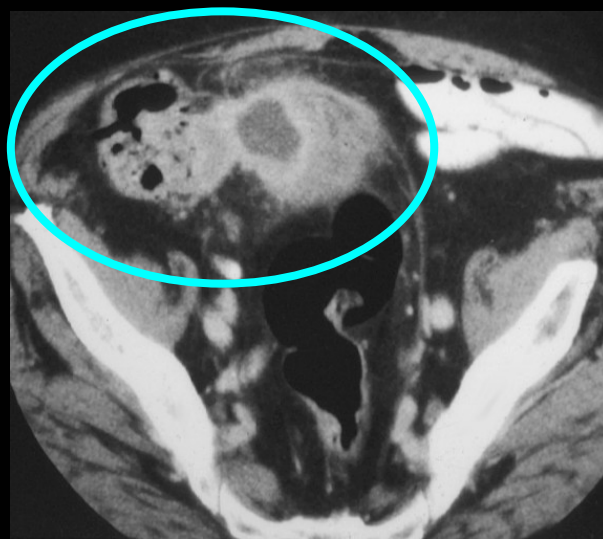
ne pas annoncer le diagnostic de sigmoïdite avant d'avoir vérifié la lumière sigmoïdienne +++: **endoscopie** ou **colo CT opaque**



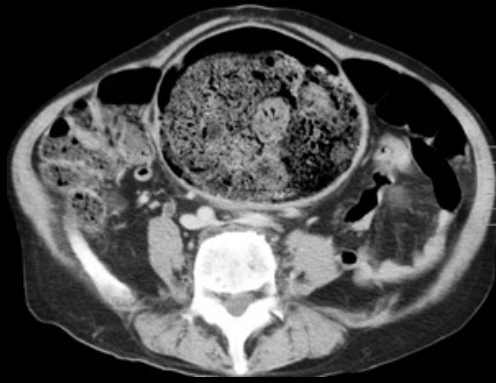
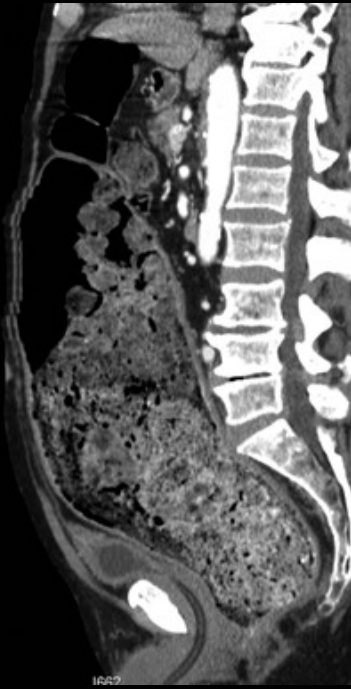
sigmoïdite pseudo-tumorale
intérêt du colo CT opaque



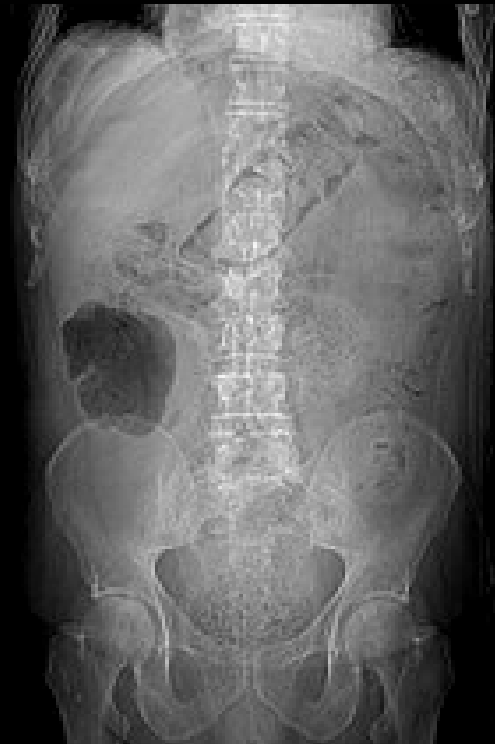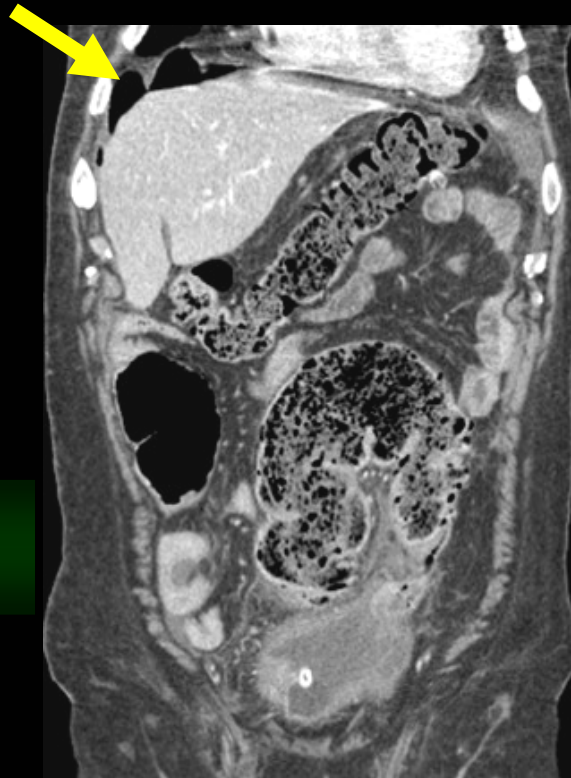
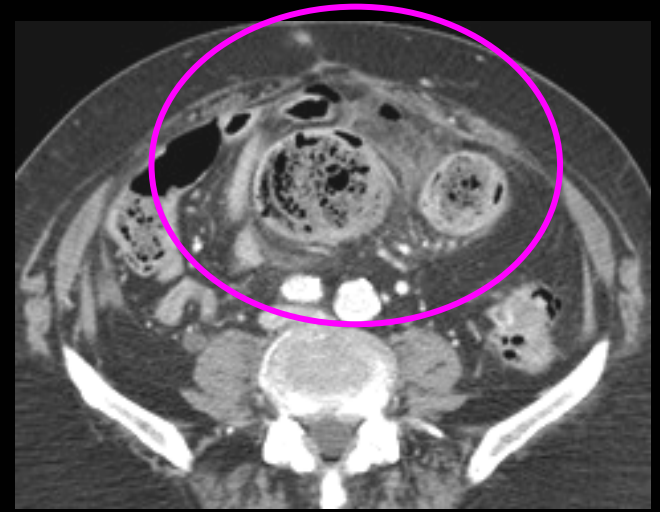
diverticulite de la FID sur dolichosigmoïde



abcès inter sigmoïdo-vésical sur diverticulite de la FID ; dolichosigmoïde

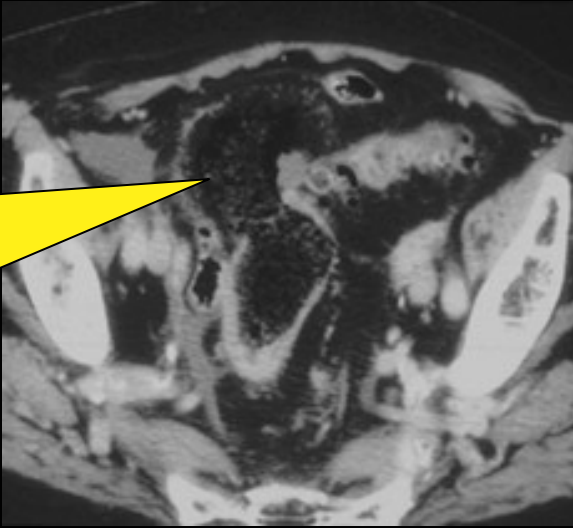


*fécalome
recto-sigmoïdien*

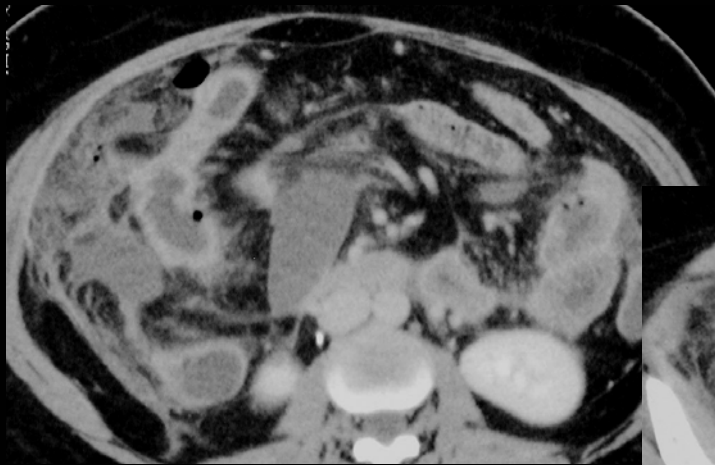
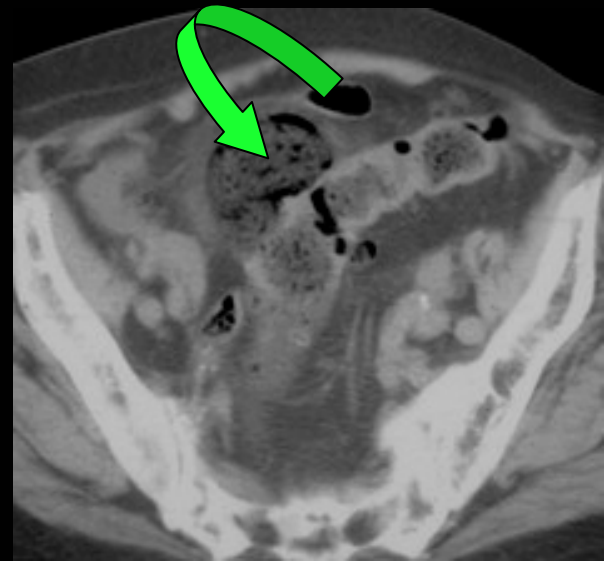


**perforation stercorale
sur impaction fécale**

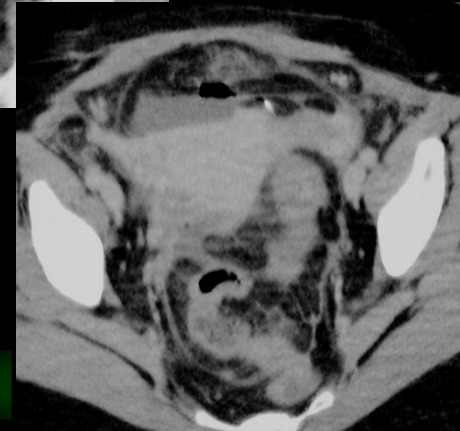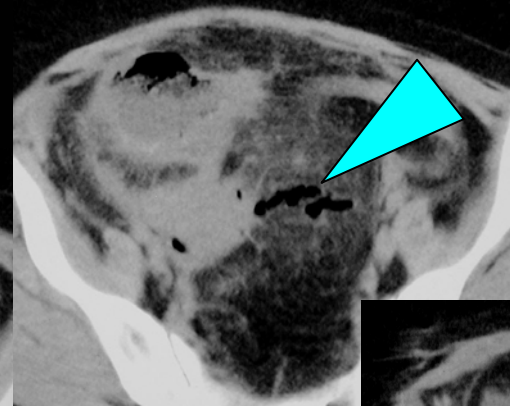
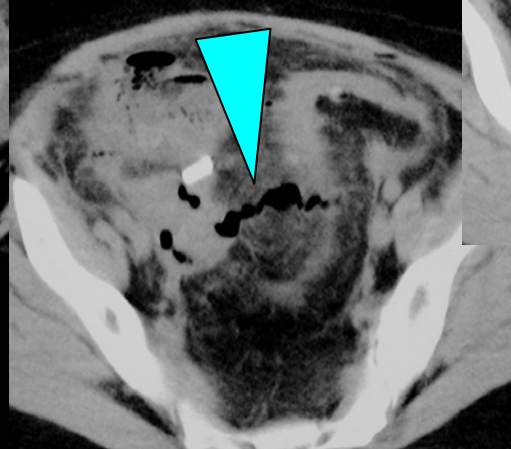
*obs. P Taourel
Montpellier*



femme
e 83
ans

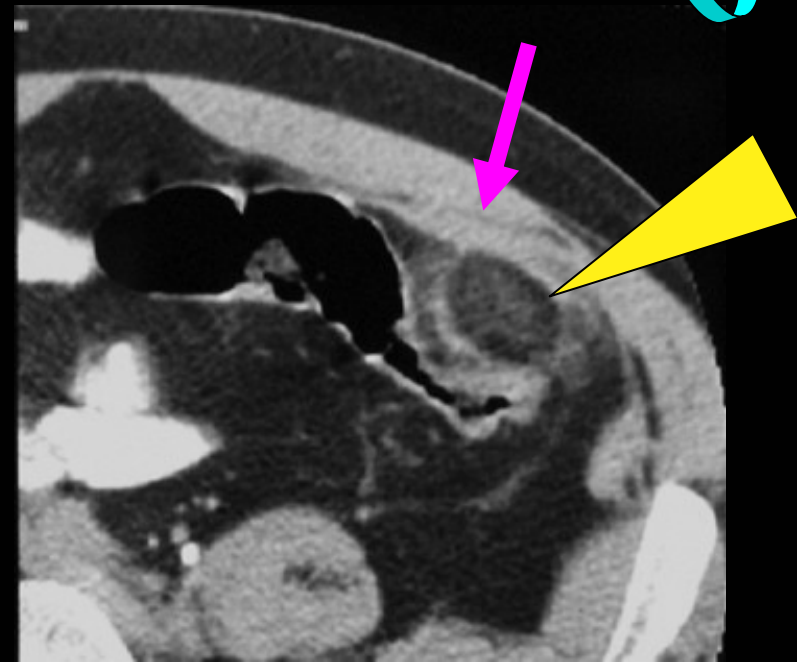
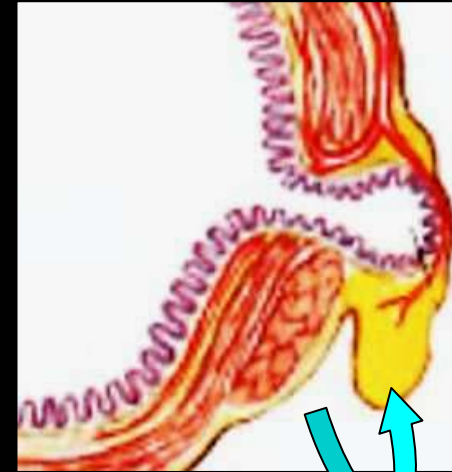
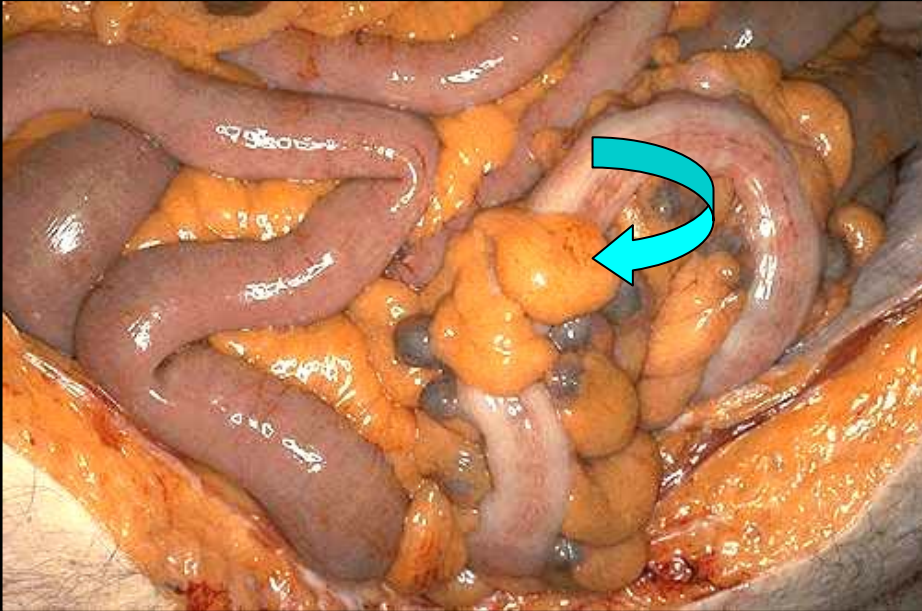


femme 34 ans

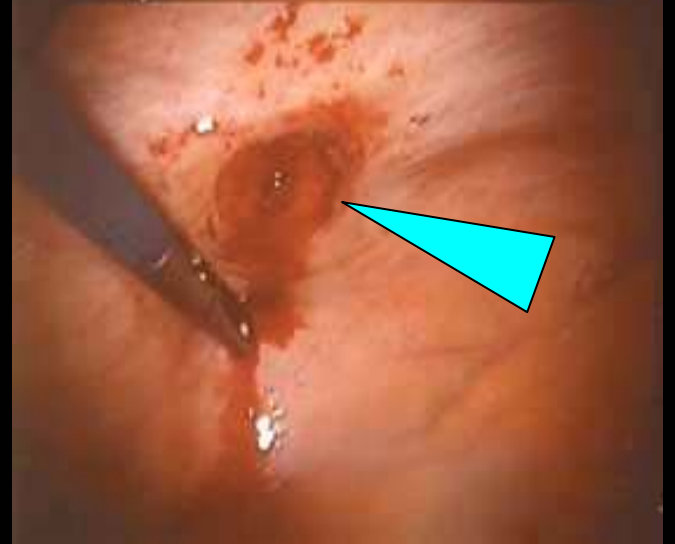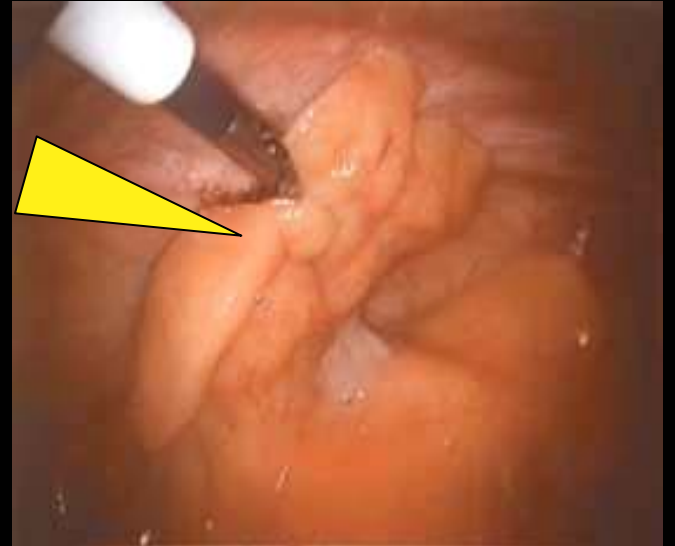
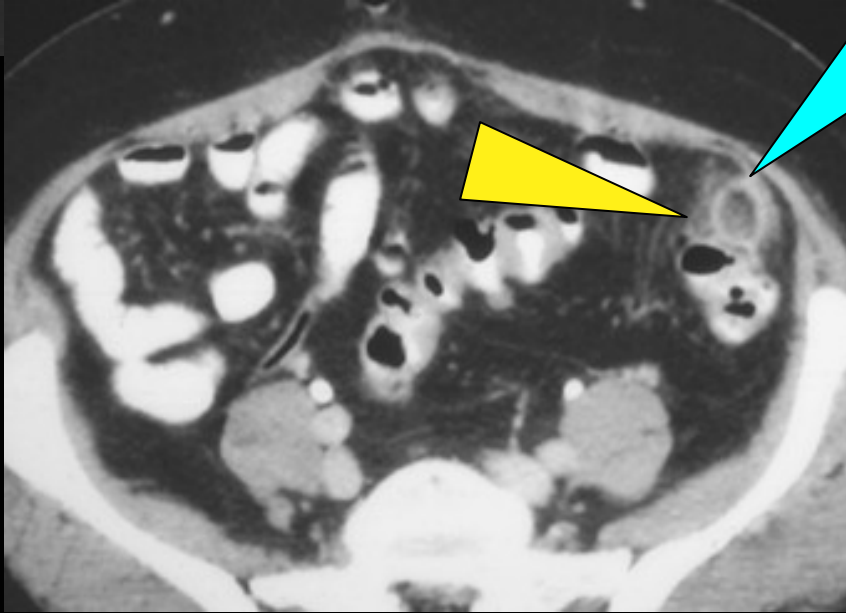
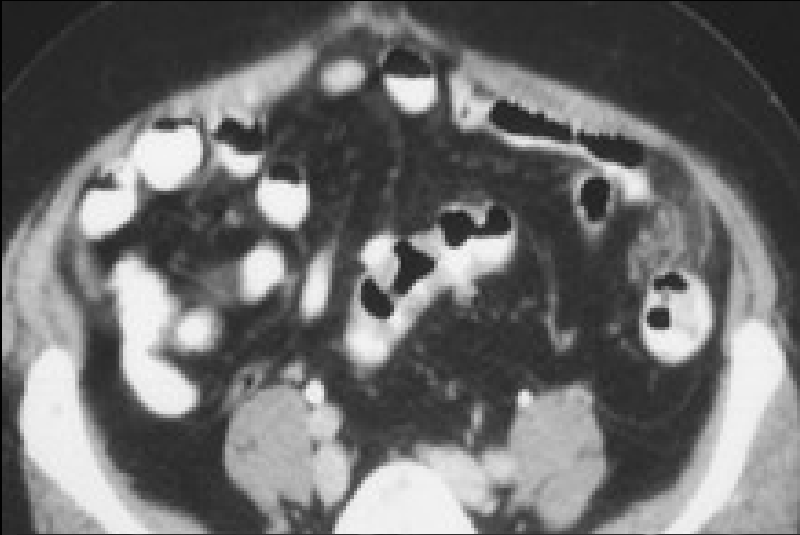


perforations "spontanées" du recto-sigmoïde "impactions fécales"

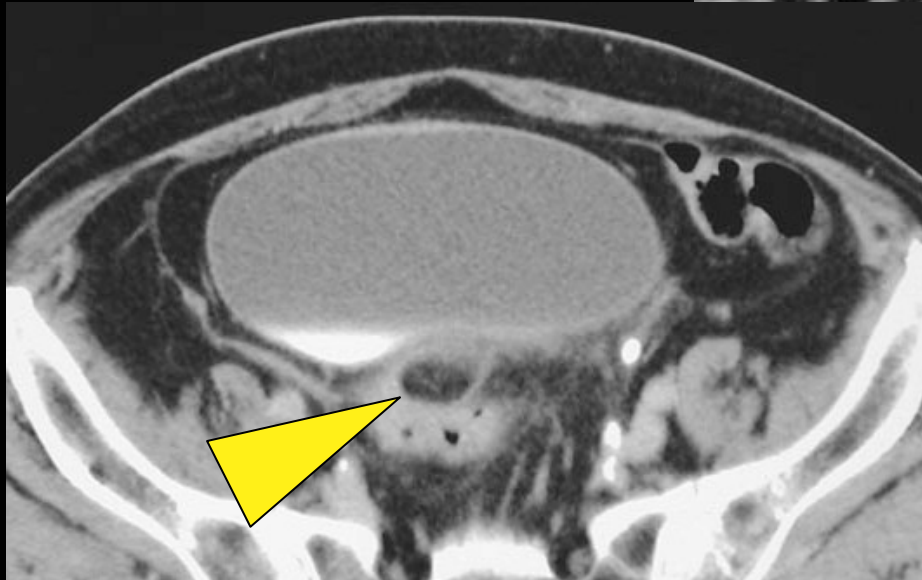
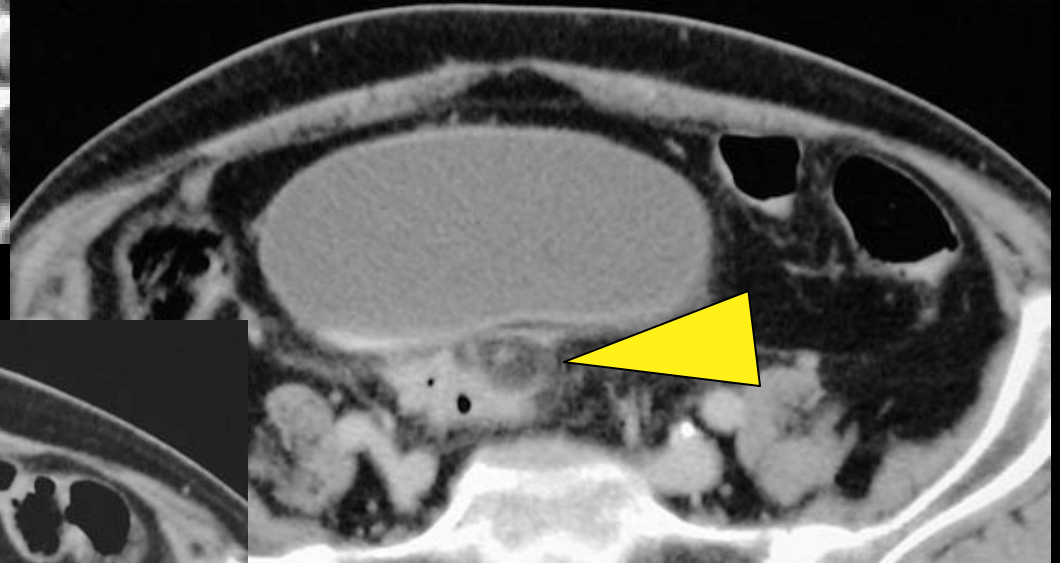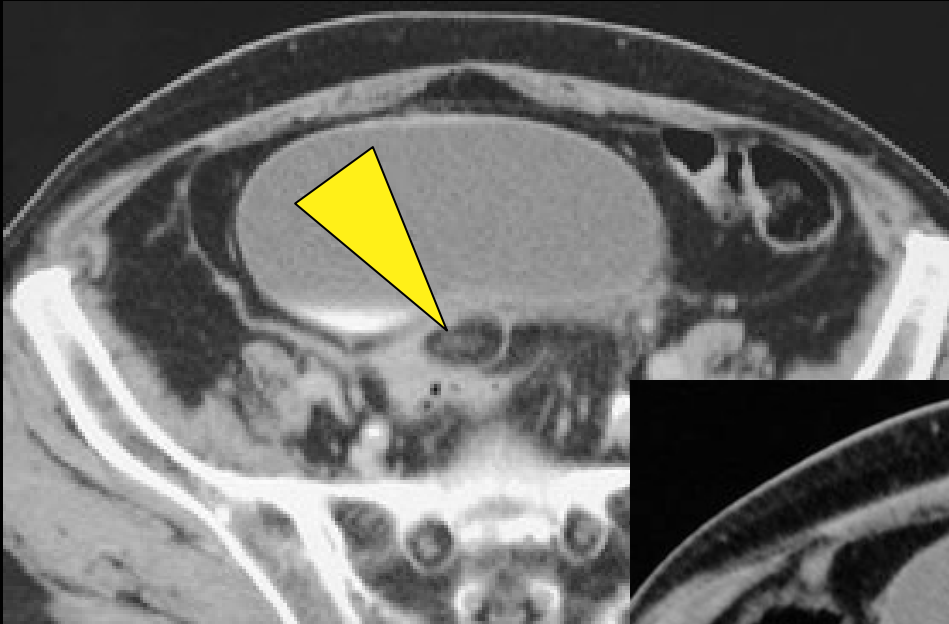
un diagnostic différentiel de la diverticulite , chez le sujet jeune +++ : la torsion d'appendice épiploïque ou « appendagite » primitive !!!



"appendagite" primitive typique; 24 ans

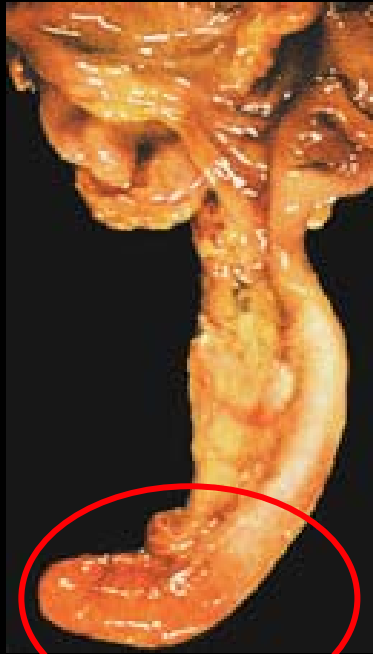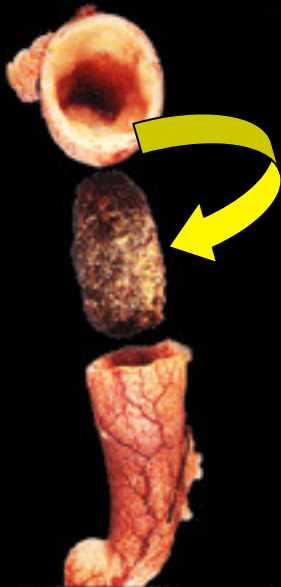


torsion d'appendice épiploïque ; " appendagite " primitive



"appendagite" du cul de sac de Douglas

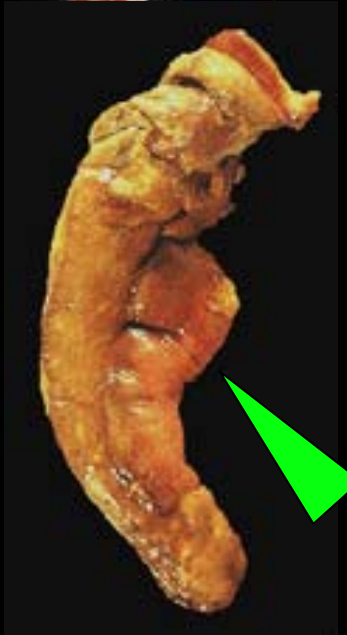2b.les appendicites aiguës et leurs complications



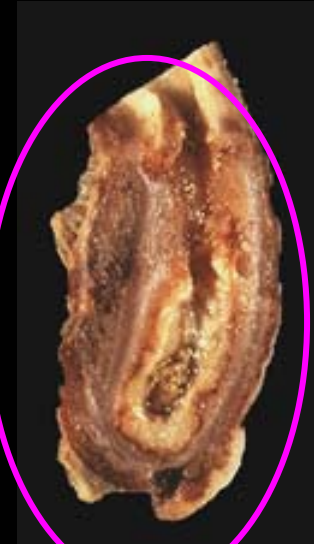- éléments anatomiques importants

participation du méso-appendiculaire à la réaction inflammatoire régionale

prédominance distale fréquente de l'atteinte inflammatoire

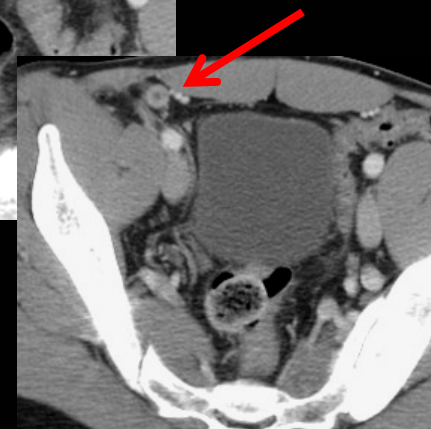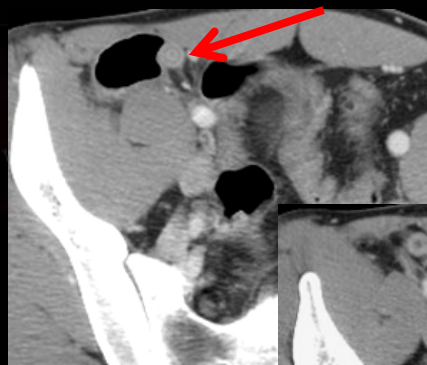

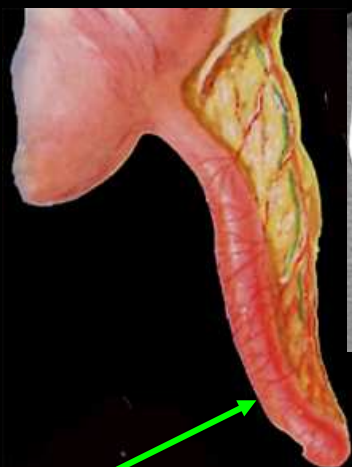
l'appendicite distale épargne les 3 centimètres proximaux de l'appendice : difficulté potentielle de l'imagerie

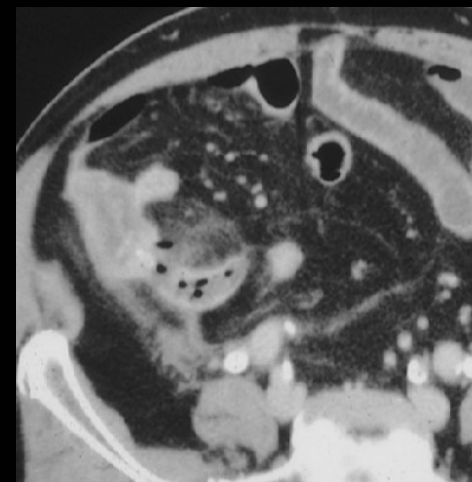
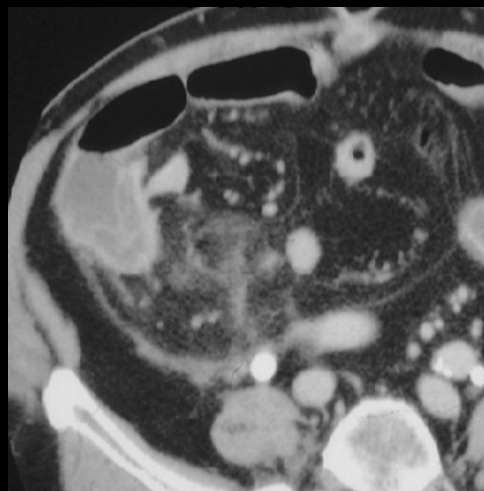
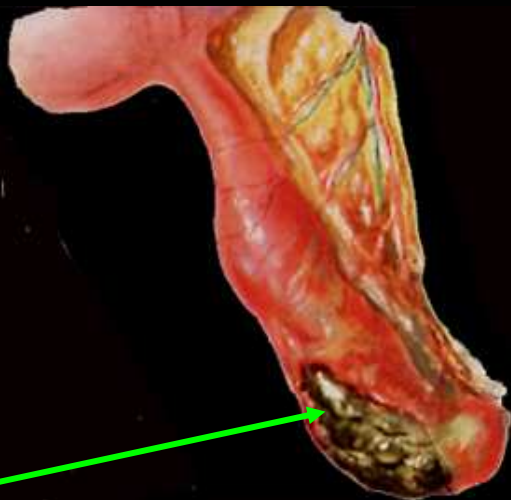
-les formes anatomo-cliniques de l'appendicite aiguë sont très variées ; l'imagerie CT permet de mieux les diagnostiquer et d'optimiser leur prise en charge thérapeutique

-30 à 50 % des tumeurs appendiculaires se manifestent cliniquement par un tableau d'appendicite aiguë conduisant la réalisation d'un scanner

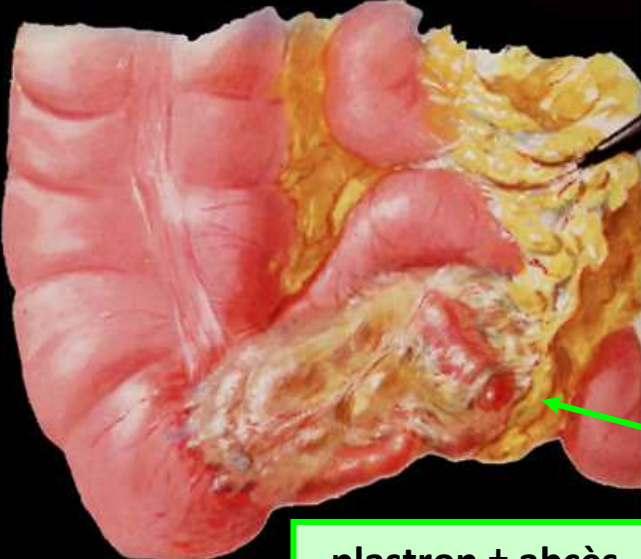


appendicite aiguë catarrhale

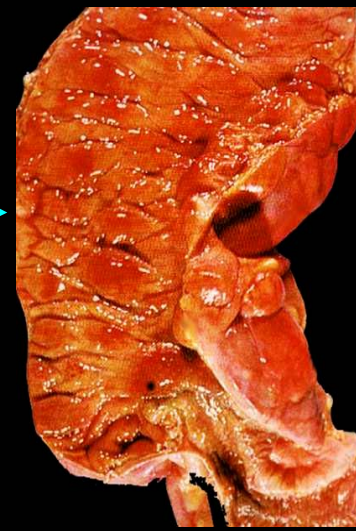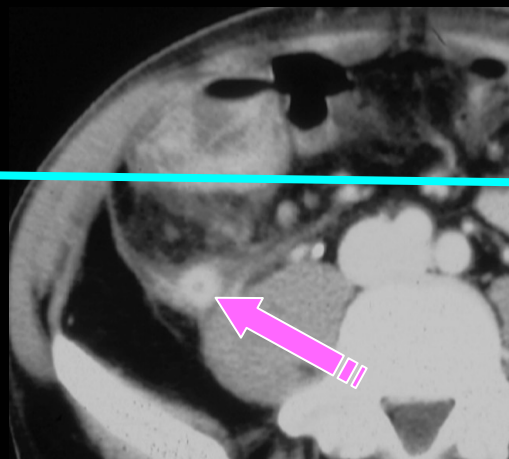
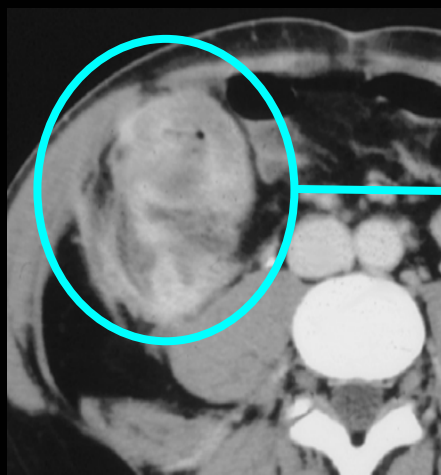
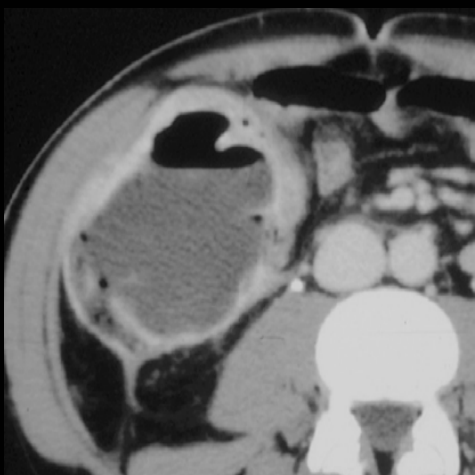
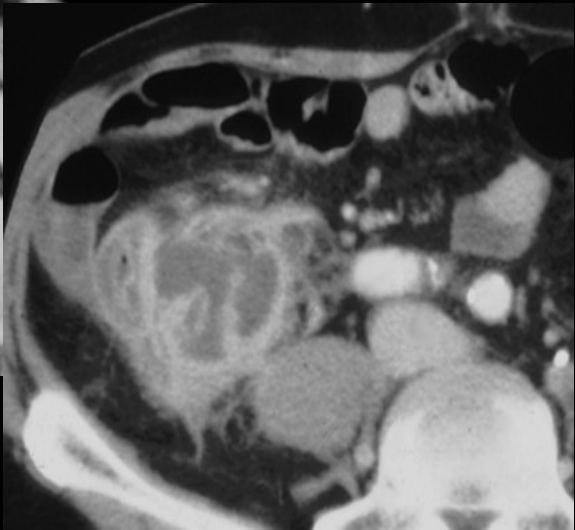
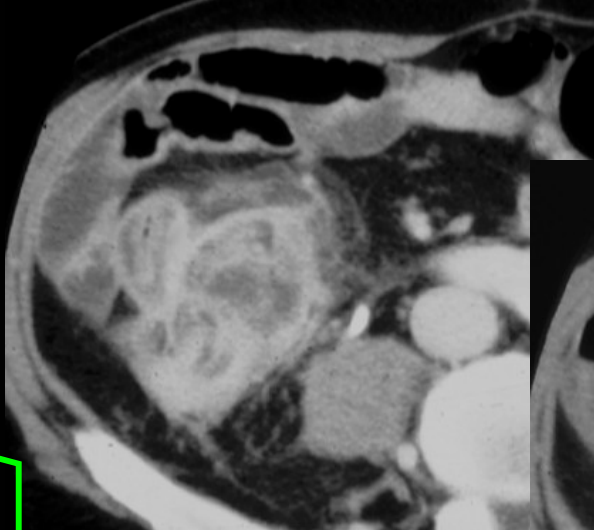


appendicite perforée (gangréneuse))

*Mason RJ Surgery for appendicitis ; is it necessary?
Surg. Infect 2008;9:481-8*



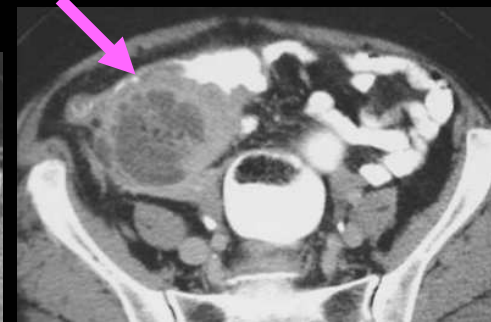
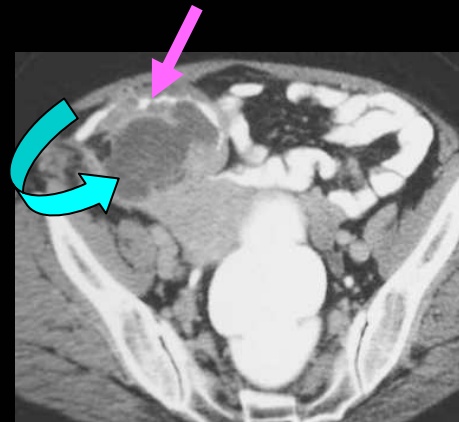
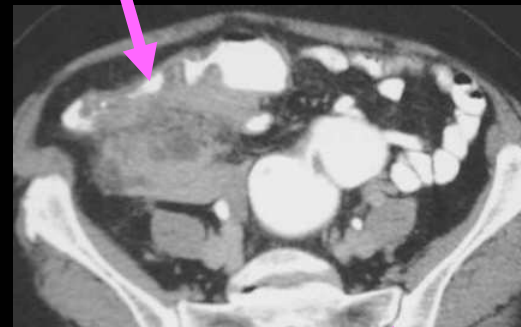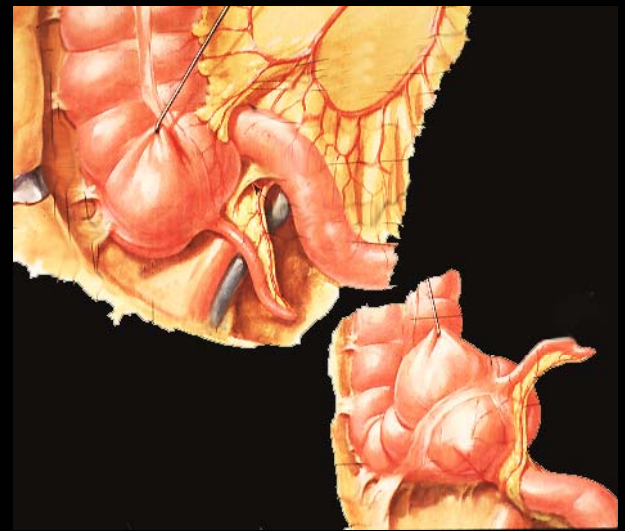
plastron ± abcès
appendiculaire



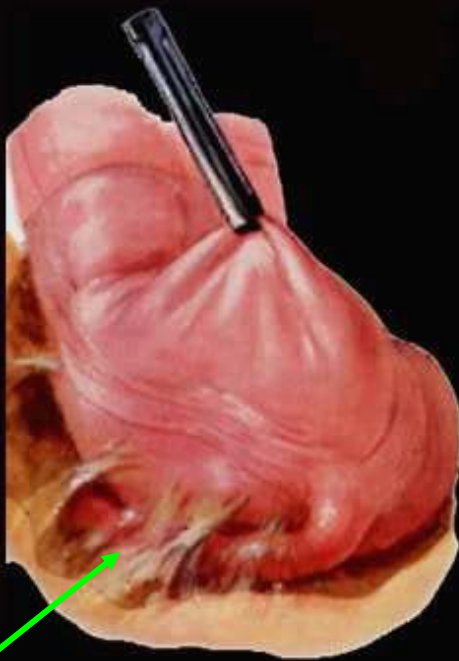inflammation trans séreuse de la paroi caecale ; "typhlite" réactionnelle associée à un abcès appendiculaire; appendice rétro-caecal

- éléments anatomiques importants

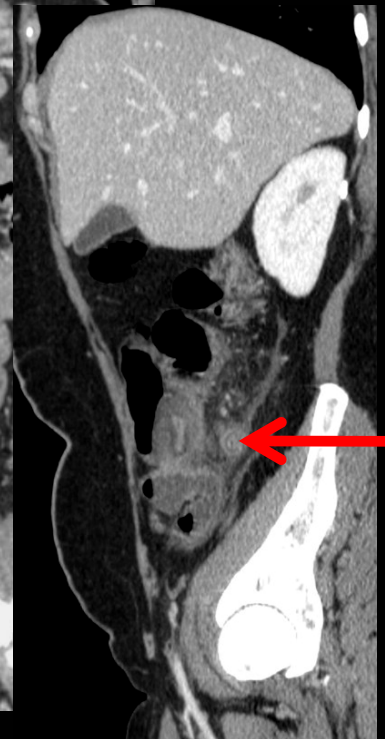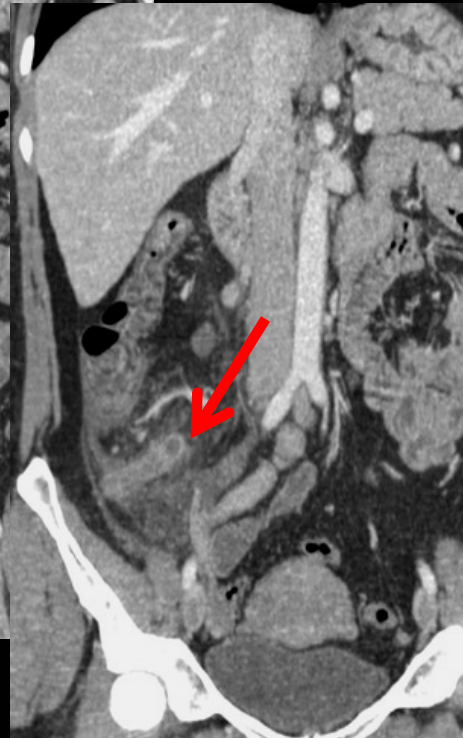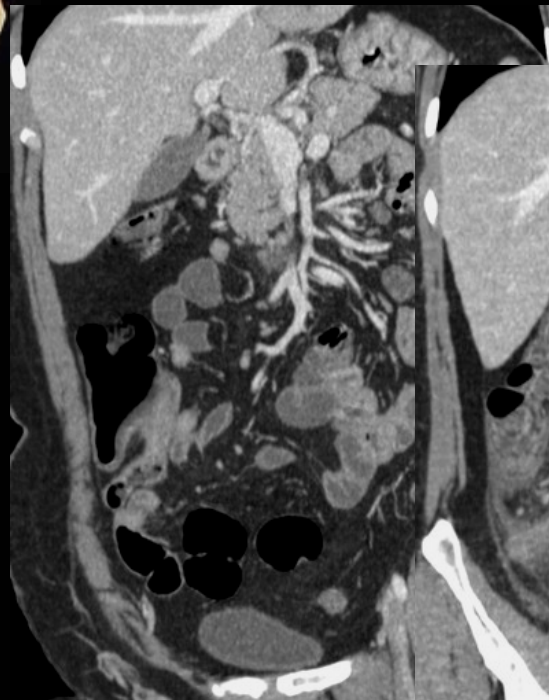
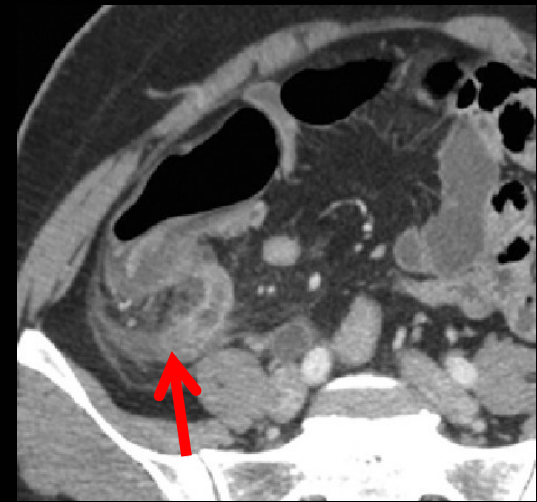
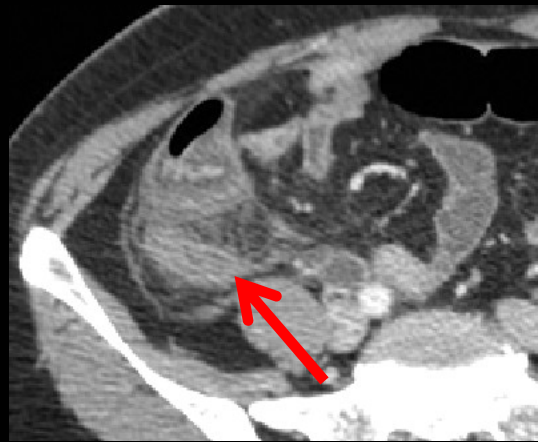le type de complication rencontré en cas de retard diagnostique dépend de la **situation anatomique de l'appendice inflammatoire** (en particulier de son extrémité distale)

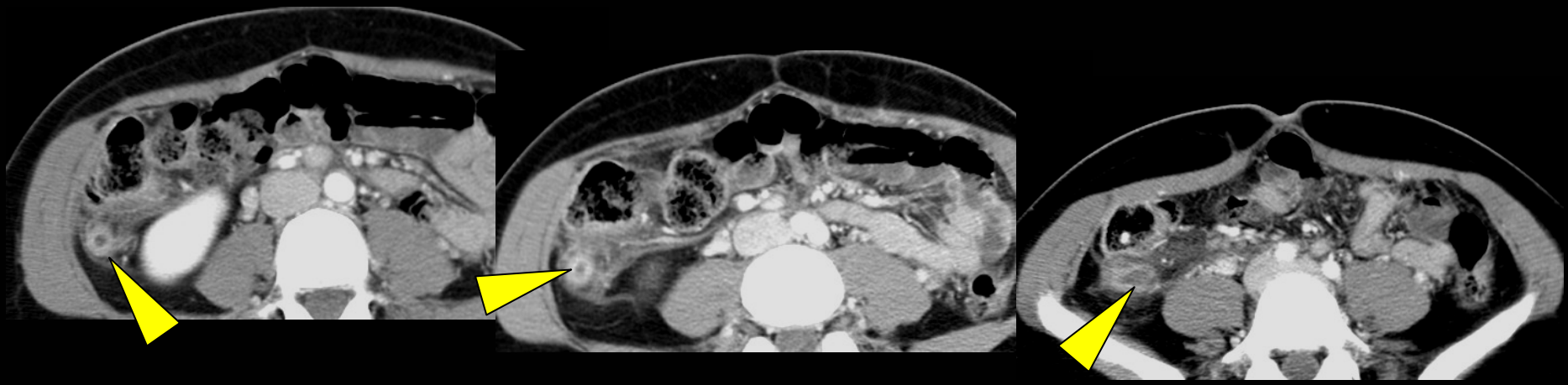


abcès appendiculaire rétro-caecal

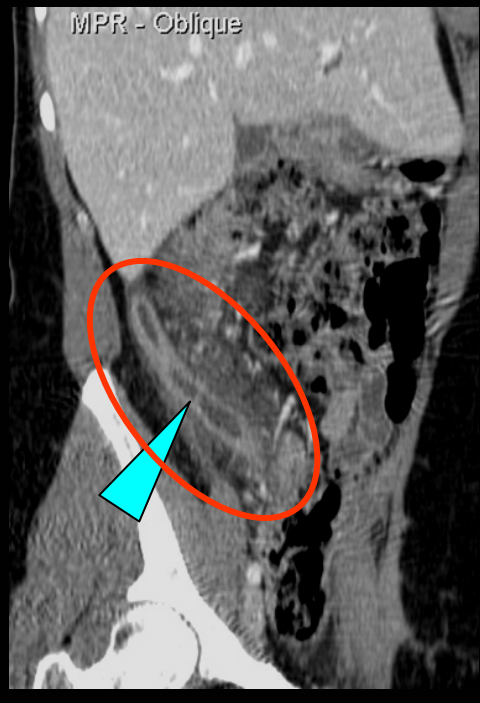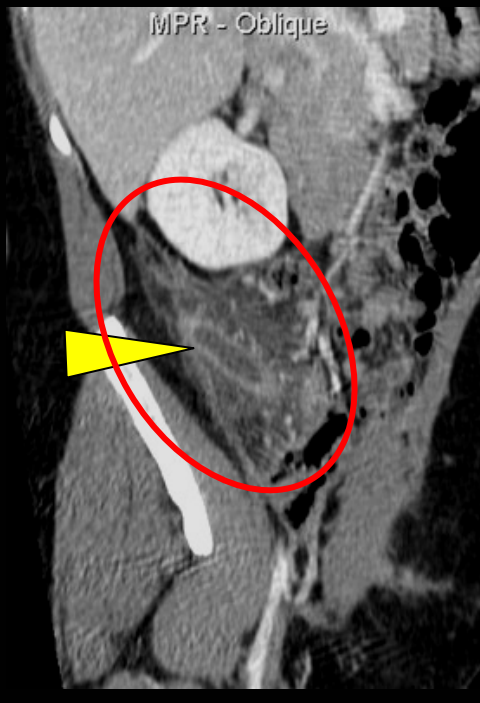
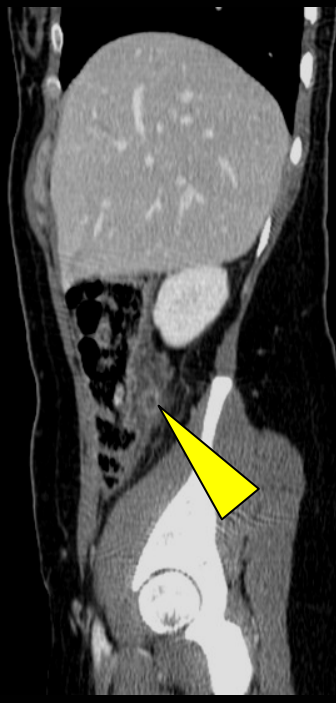
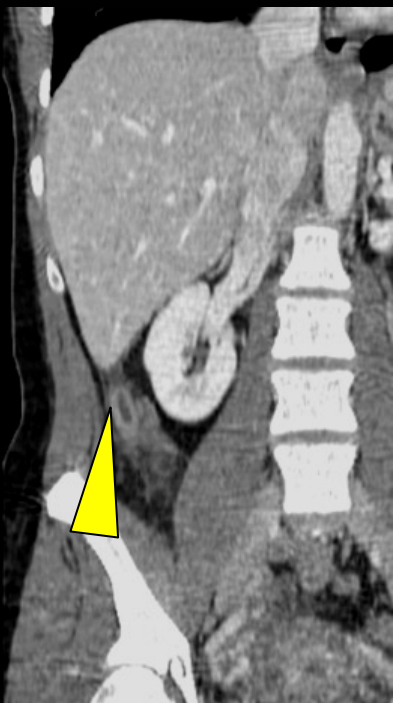


appendicite aiguë
rétro caecale

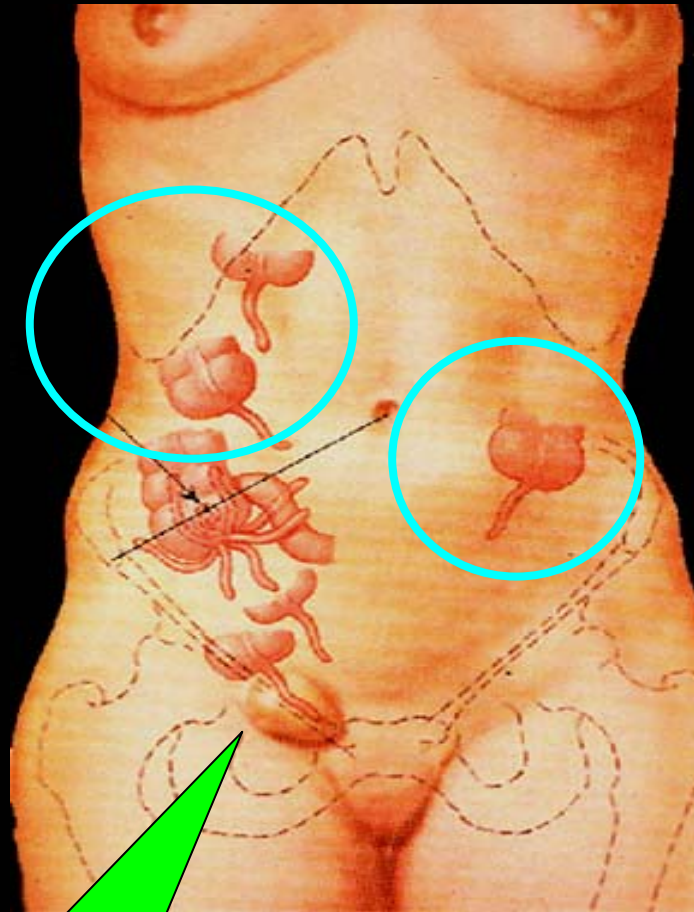




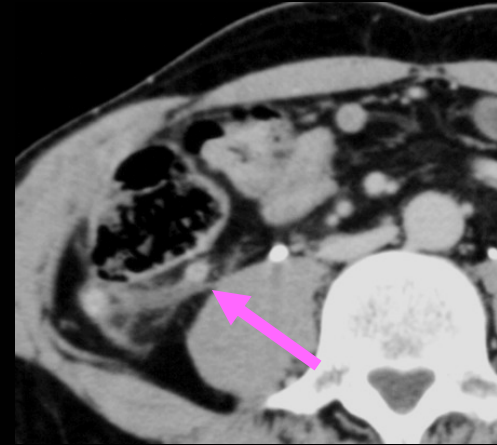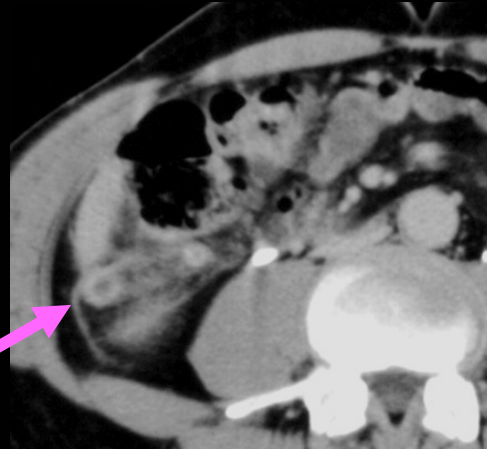
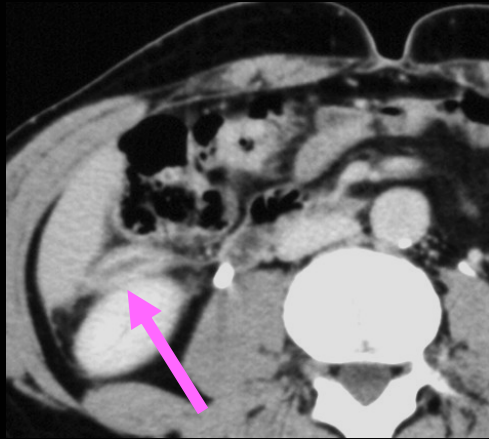
appendicite **rétro-caecale** , sous hépatique



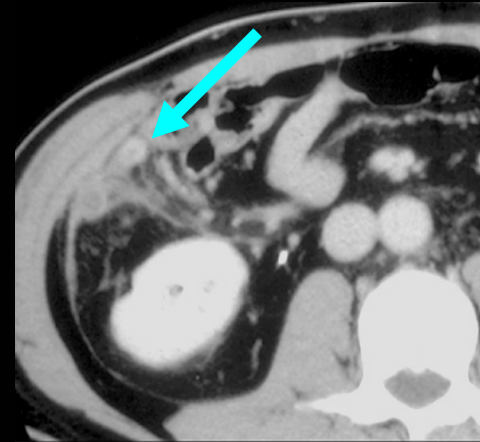
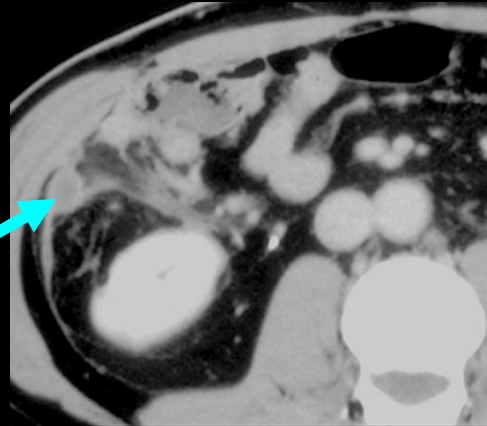
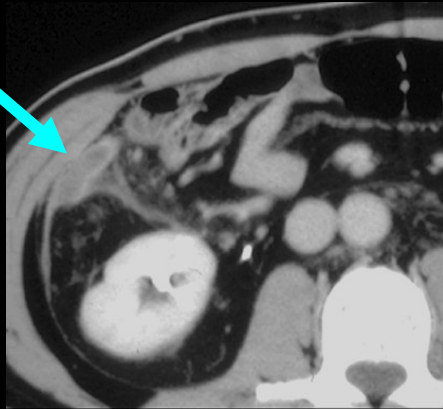
- défauts d'accolement des fascias péritonéaux et malrotations de l'anse intestinale primitive ; conséquences sur la situation de l'appendice vermiculaire



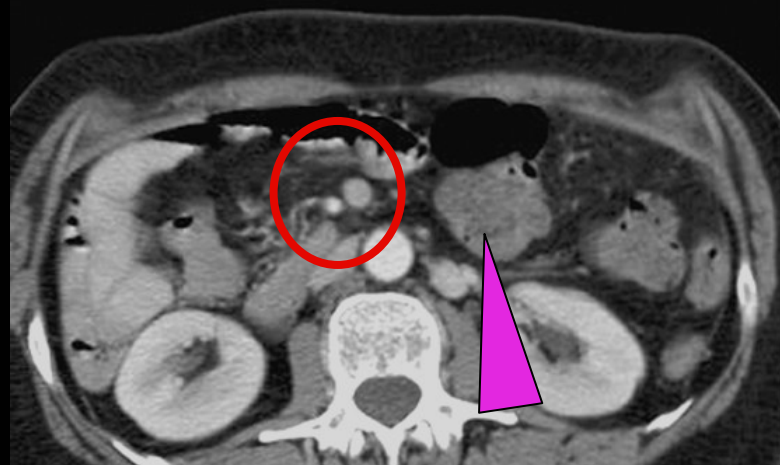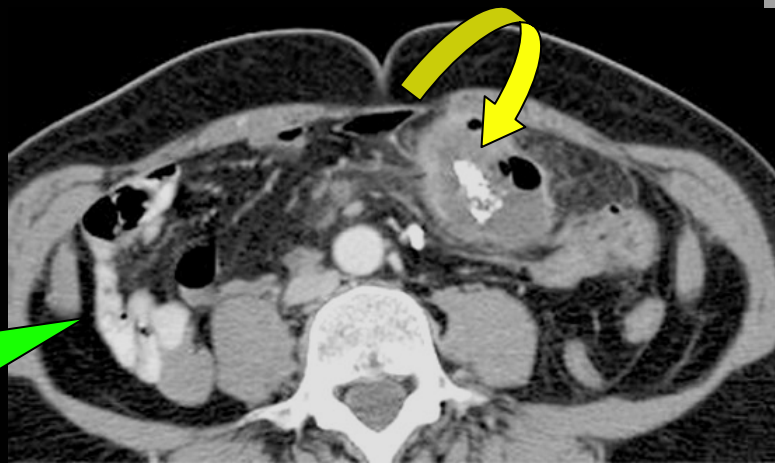
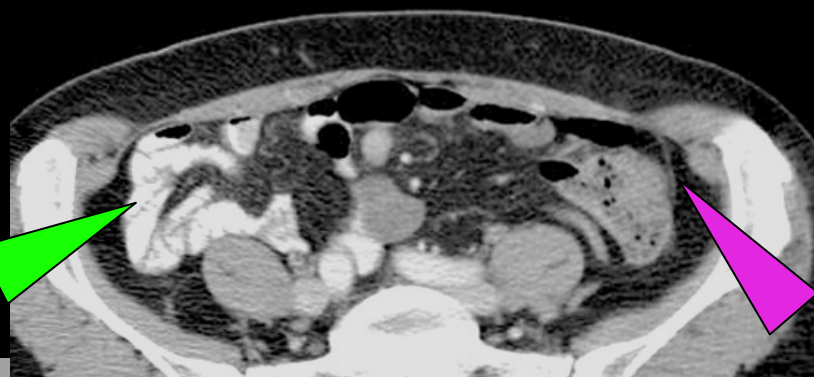
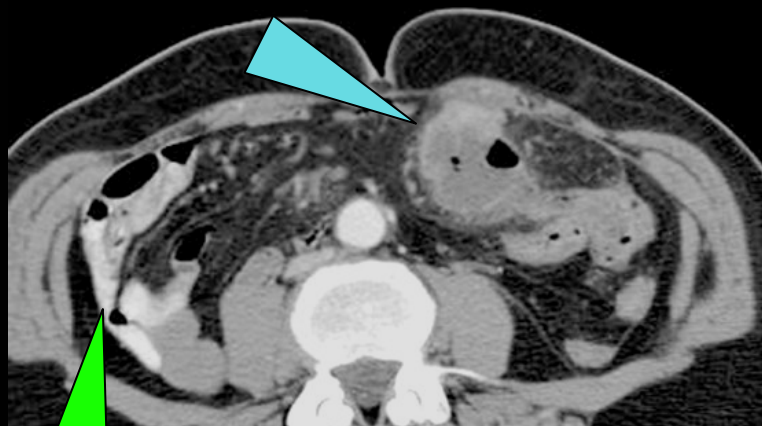
diagnostic



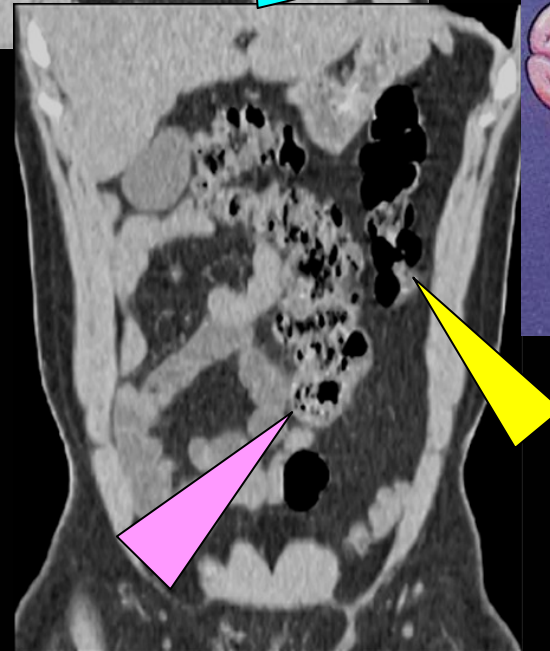
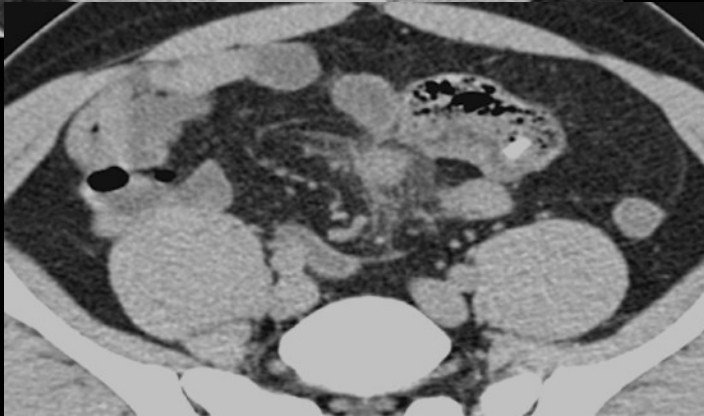
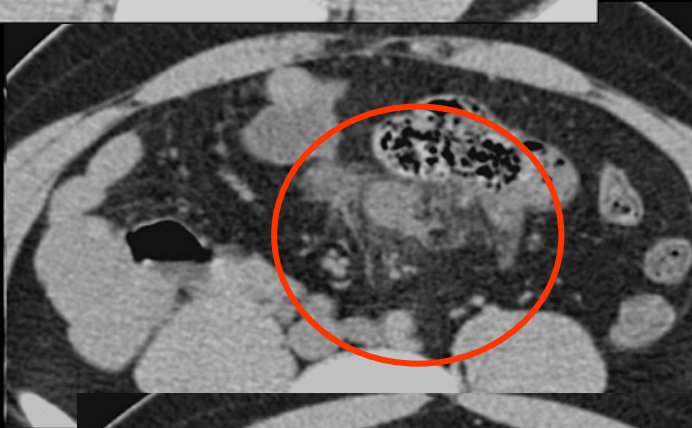
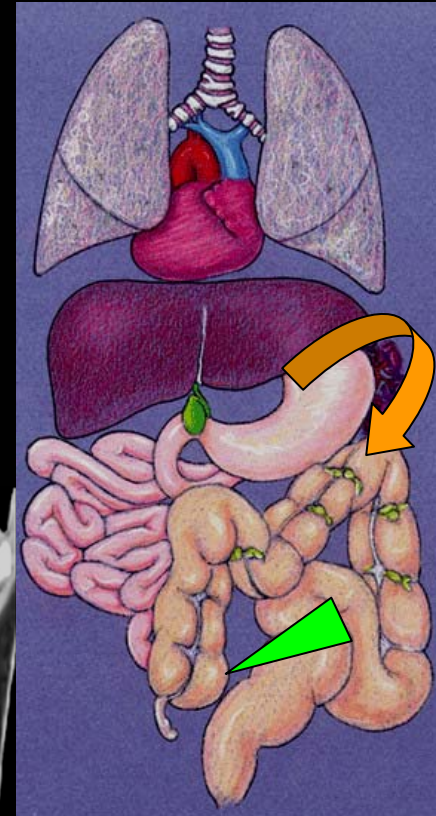
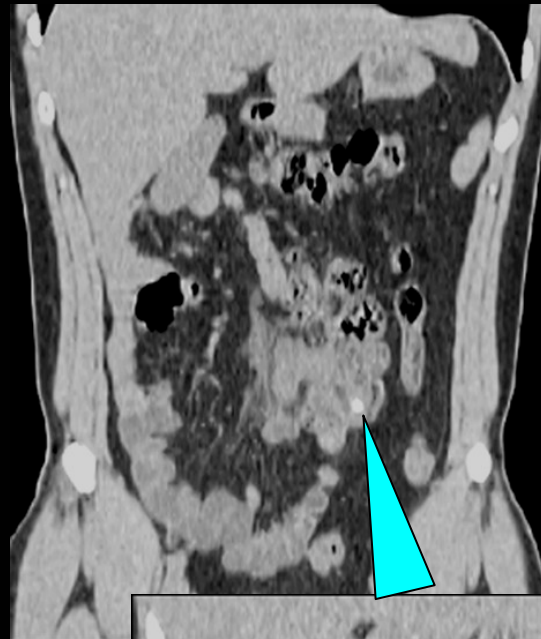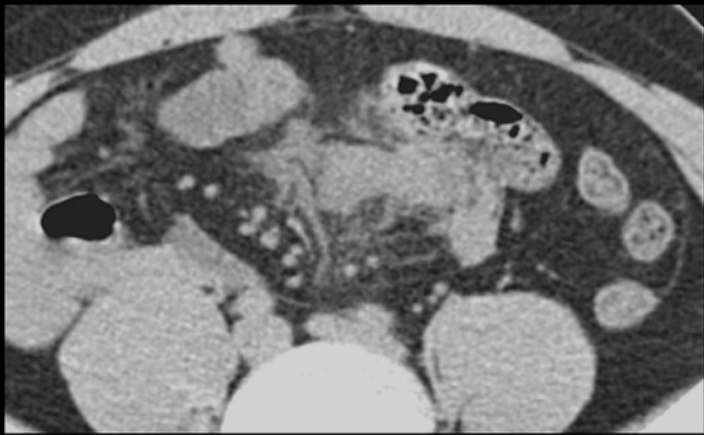
appendicite sous-hépatique **rétro-colique**



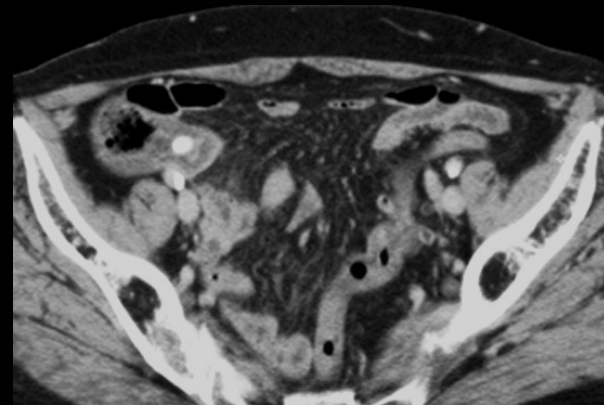
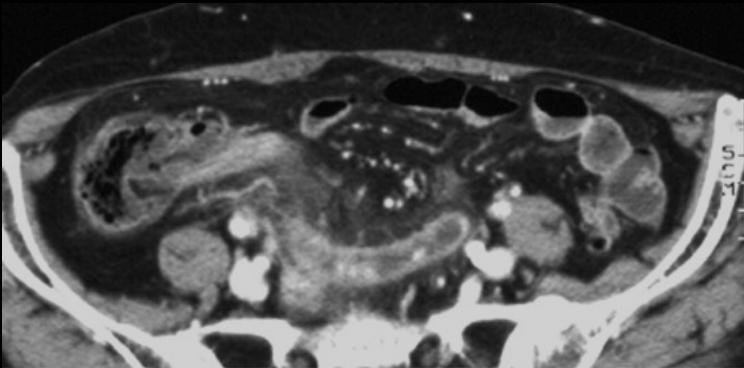
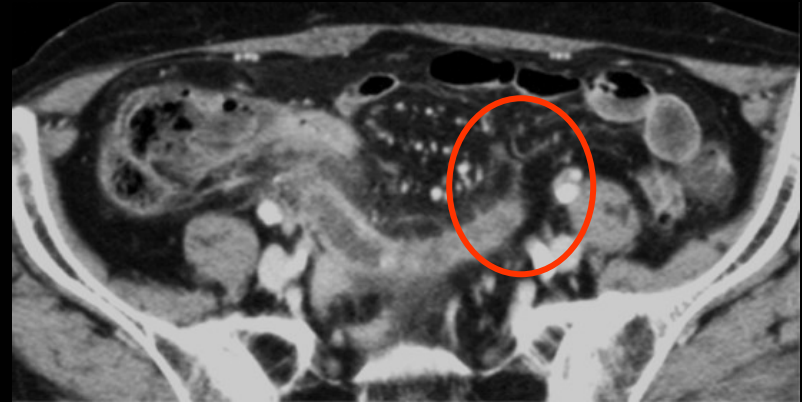
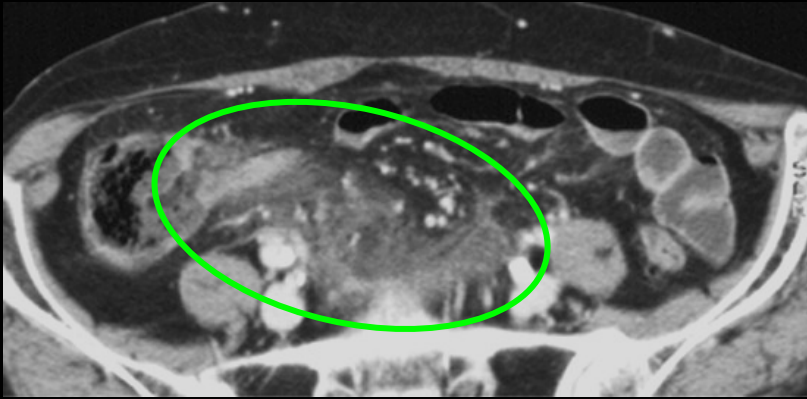
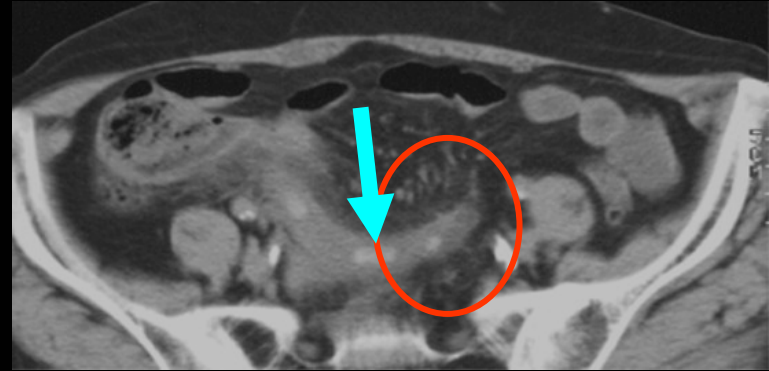
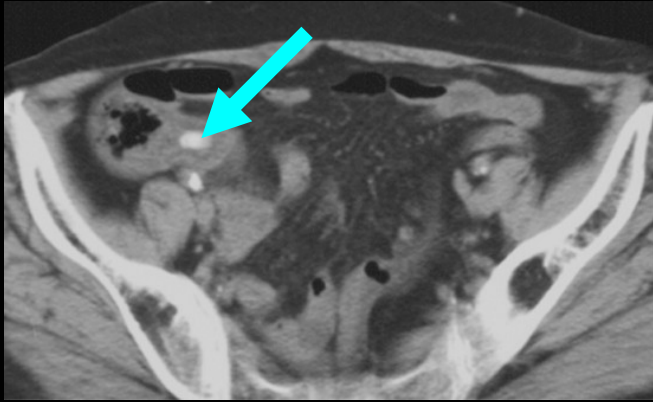
appendicite sous-hépatique **pré-colique**



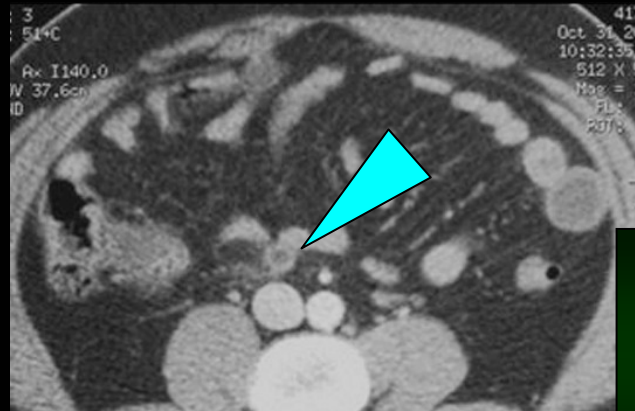
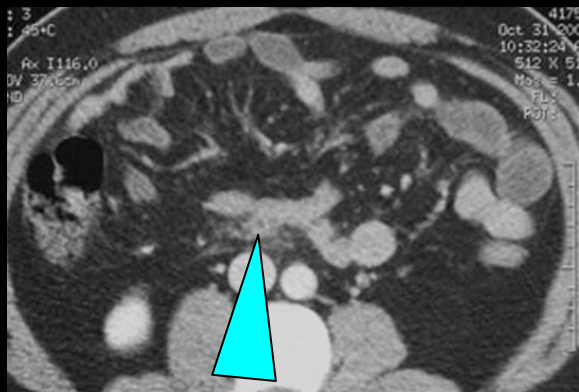
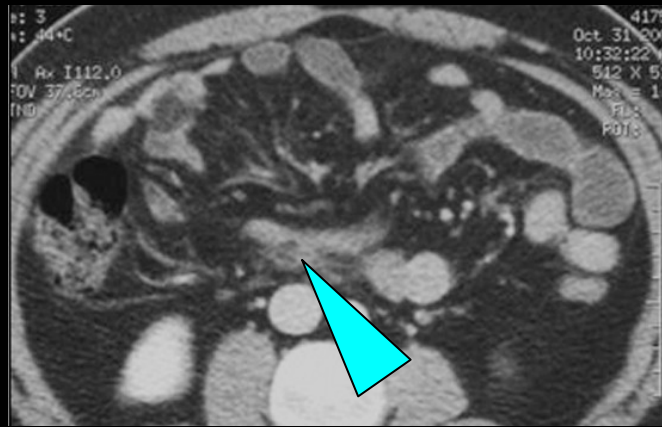
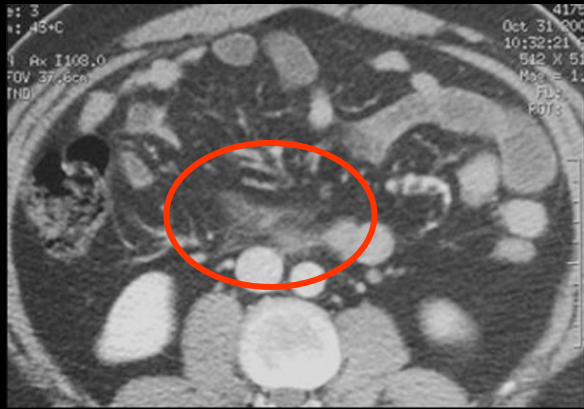
cæcum ectopique : appendicite méso-coélique sur **mésentère commun**



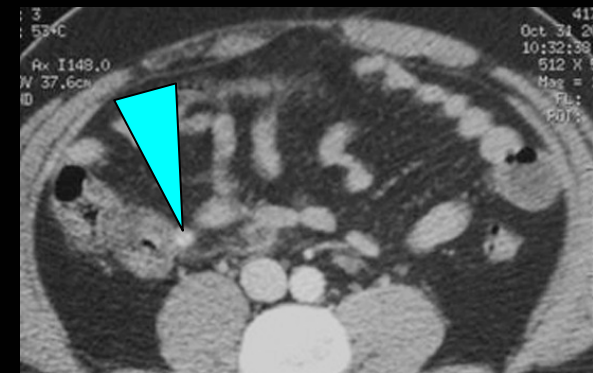
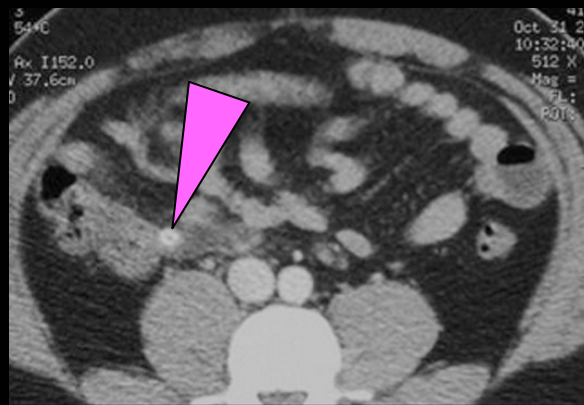
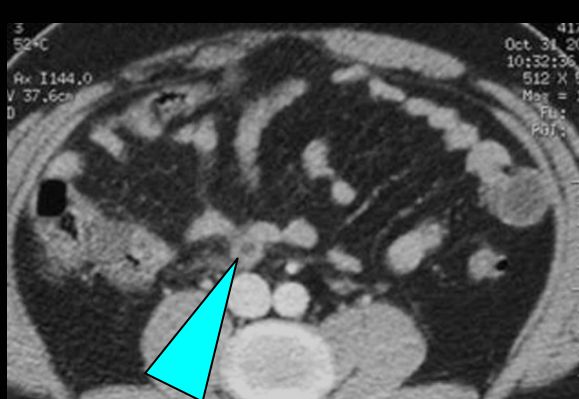cæcum ectopique : appendicite méso-coélique sur **mésentère commun**

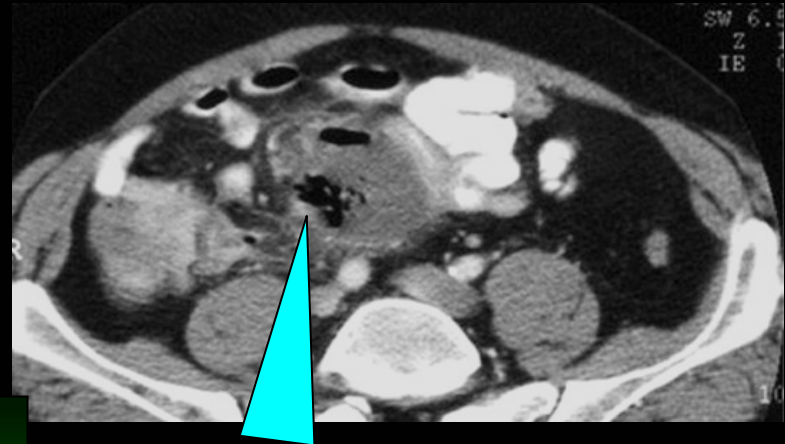
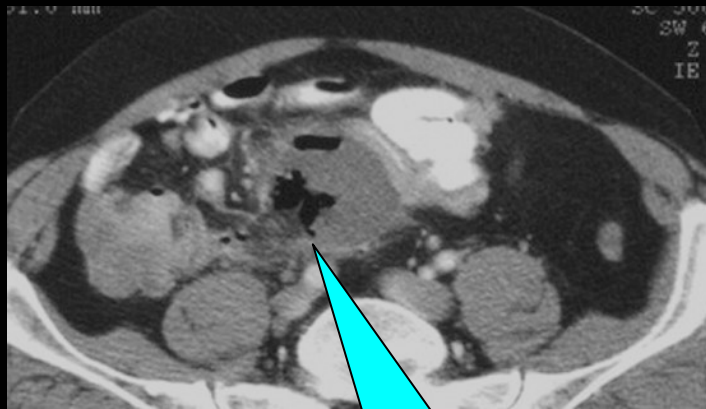
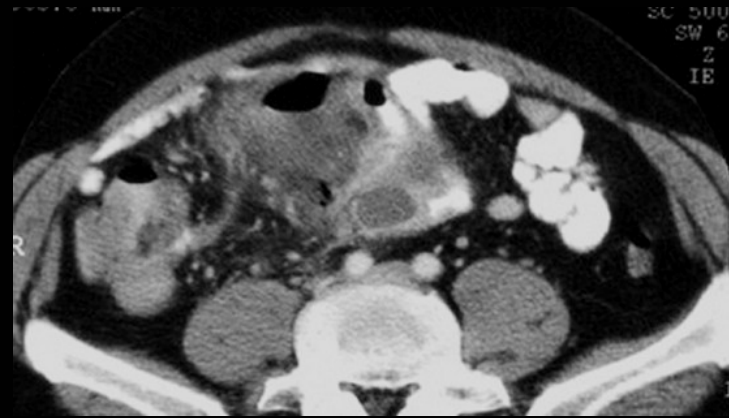
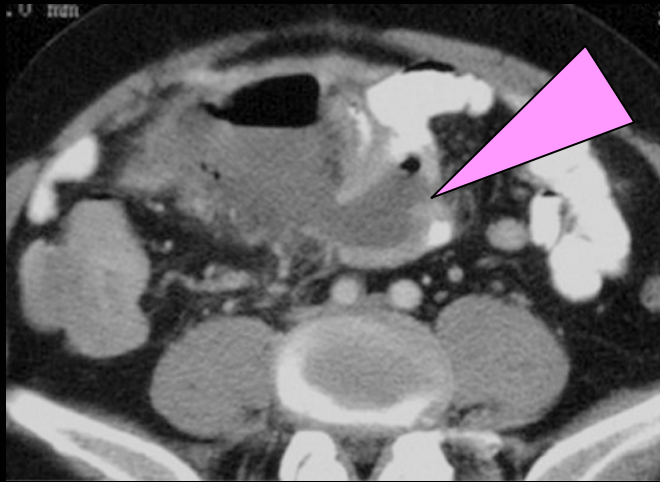


cæcum orthotopique : appendicite méso-coélique sur **appendice très long**

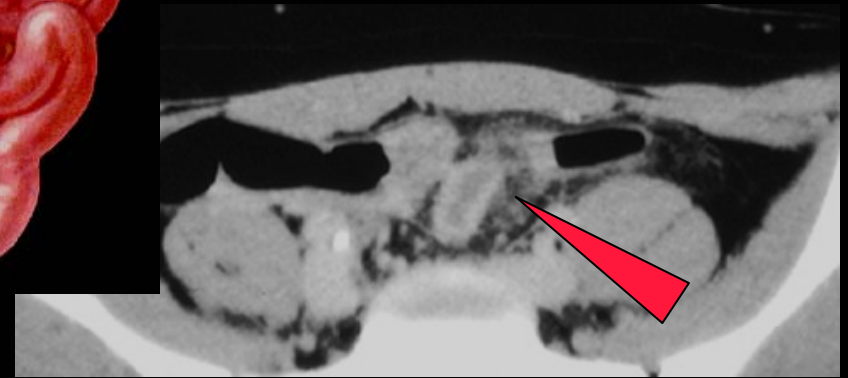
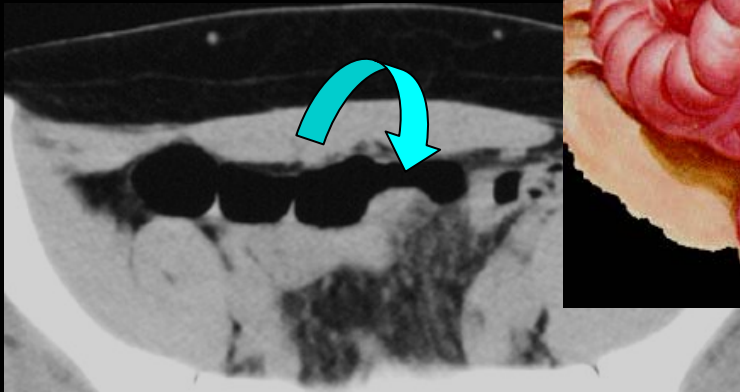
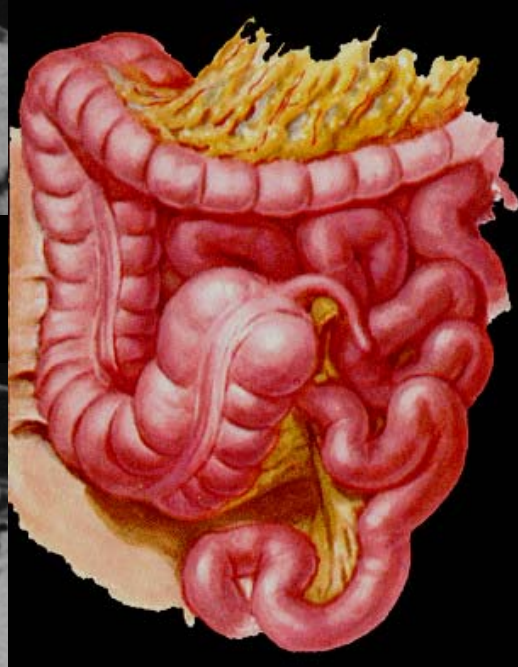
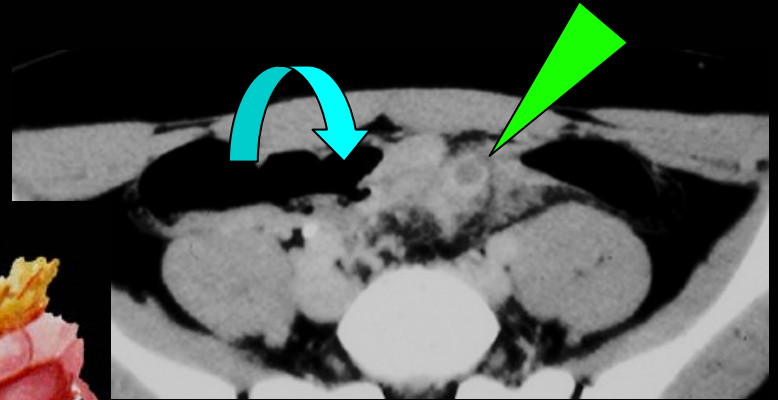
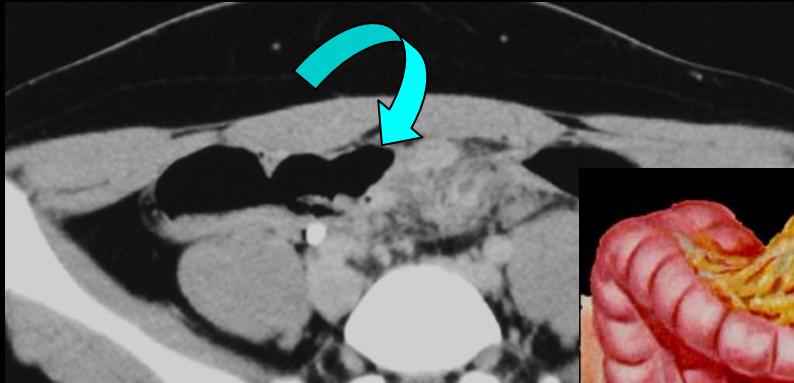


cæcum orthotopique :
appendicite méso-
coeliaque sur **appendice
long**





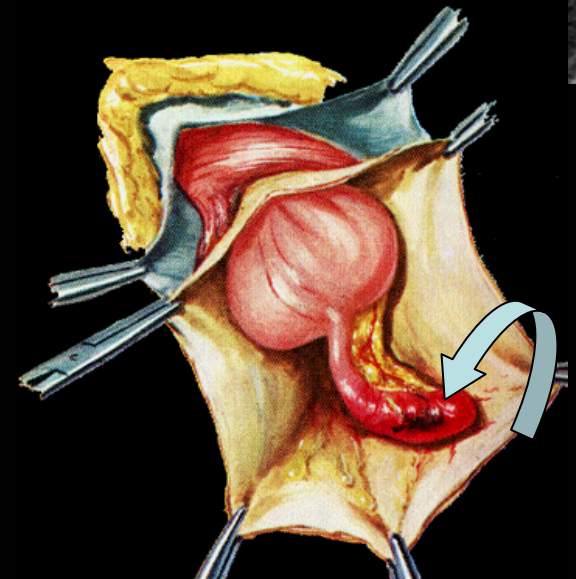
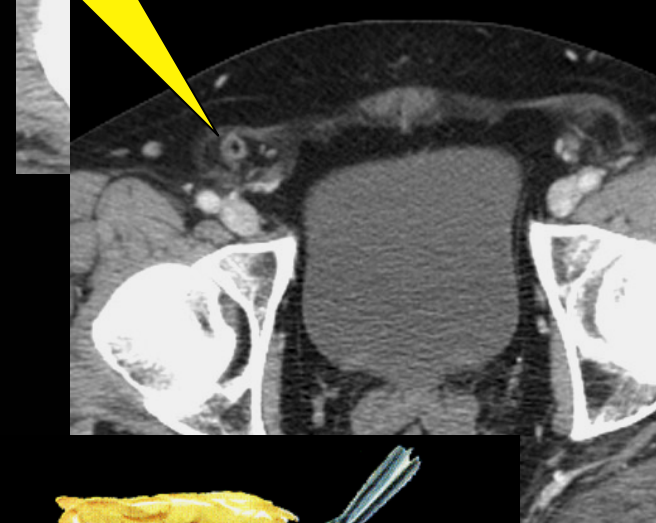
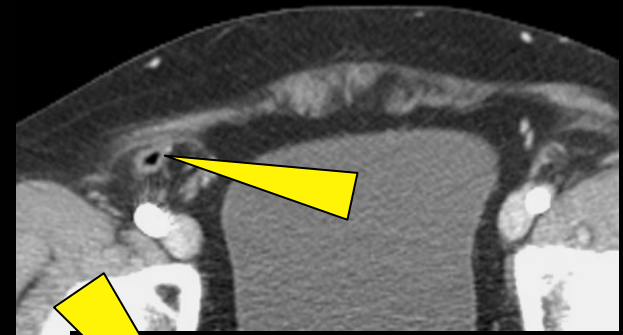abcès appendiculaire méso-
coélique
caecum orthotopique
appendice long



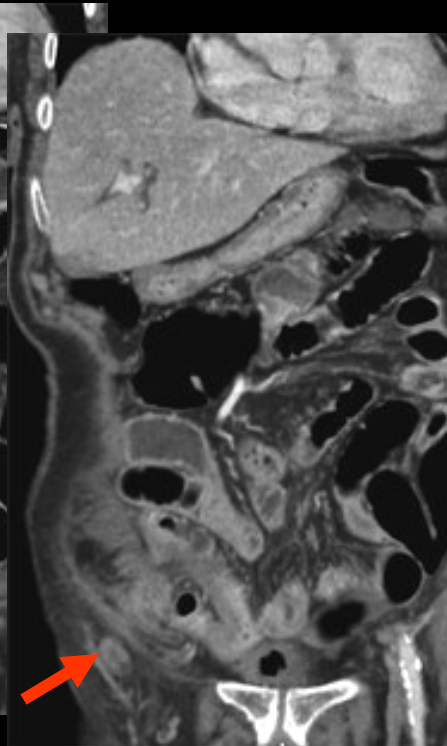
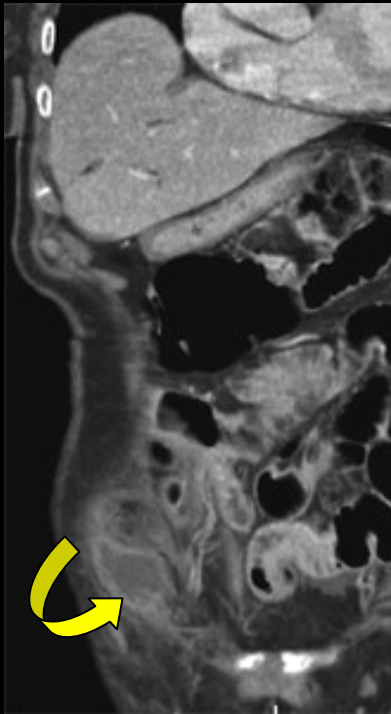
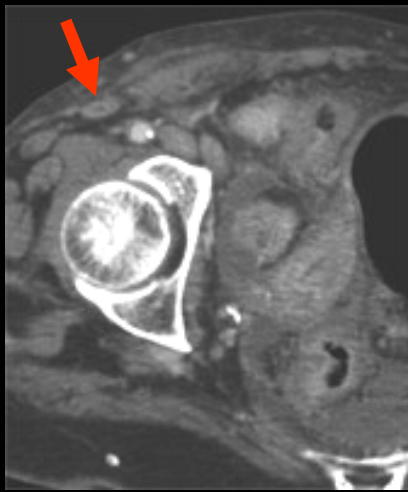
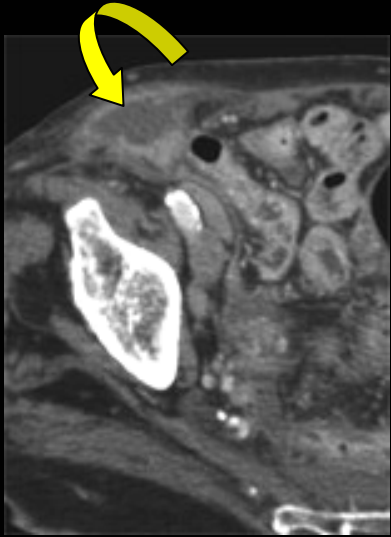cæcum ectopique : appendicite méso-coeliaque sur défaut d'accolement du fascia de Toldt droit (cæcum mobile)

Claudius Amyand (1680-1740) ,réalisa en 1735 la première appendicectomie .

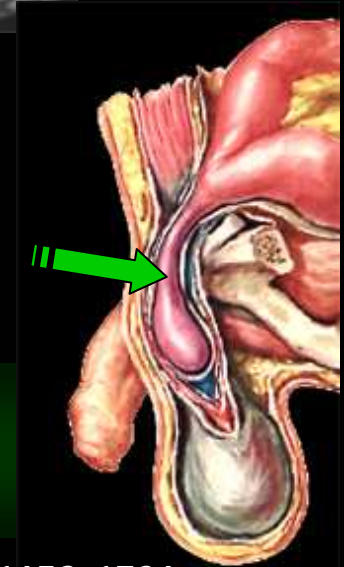
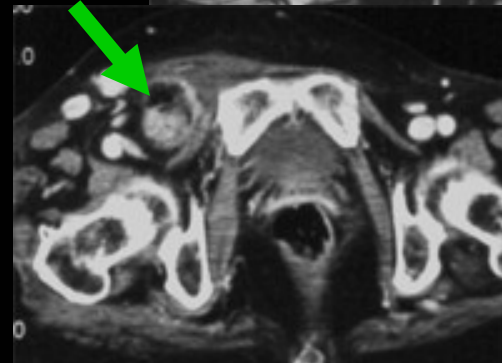
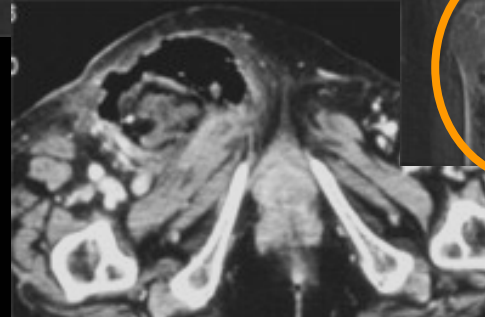
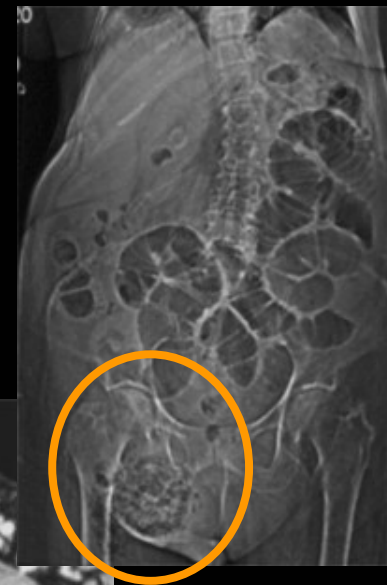
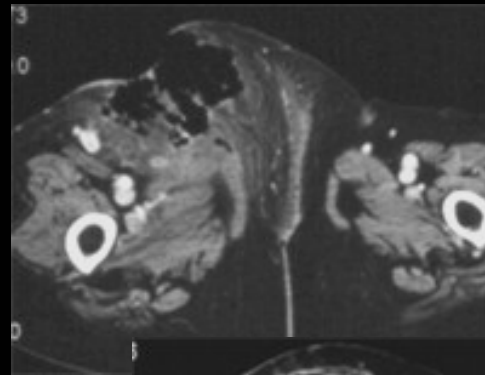
RH Fitz , anatomo-pathologiste, n'individualisa l'appendicite comme cause des "pérityphlites" qu'en 1886 !



appendicite herniaire
(hernie de
Claudius Amyand)

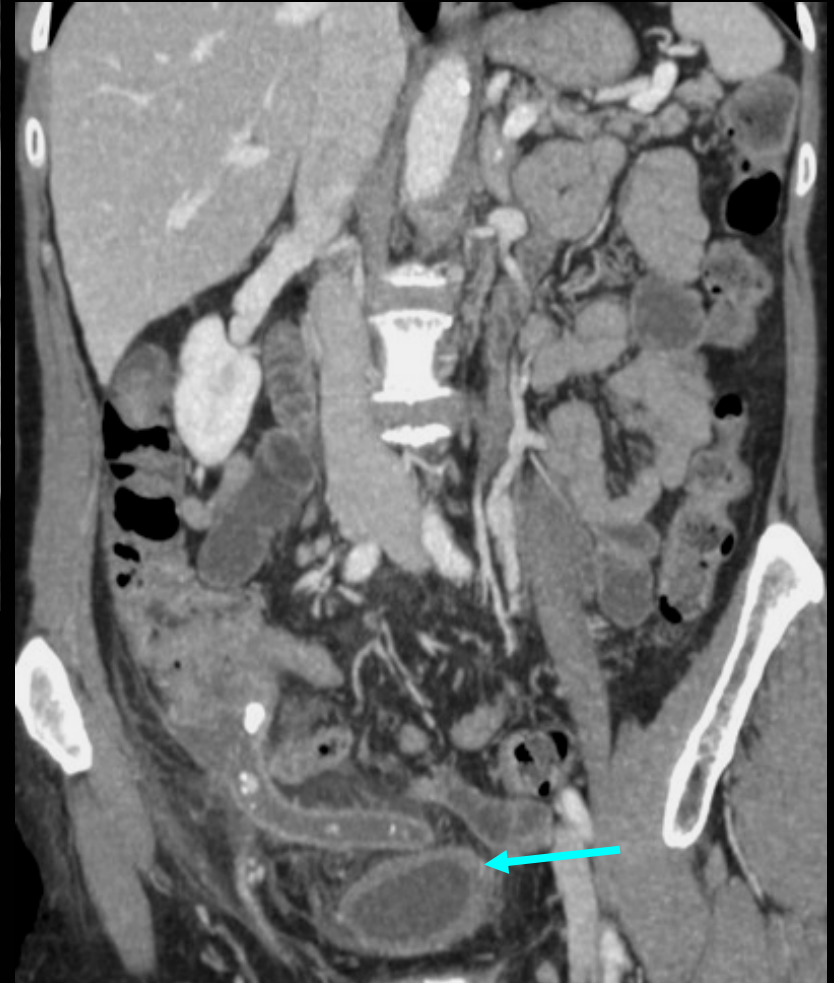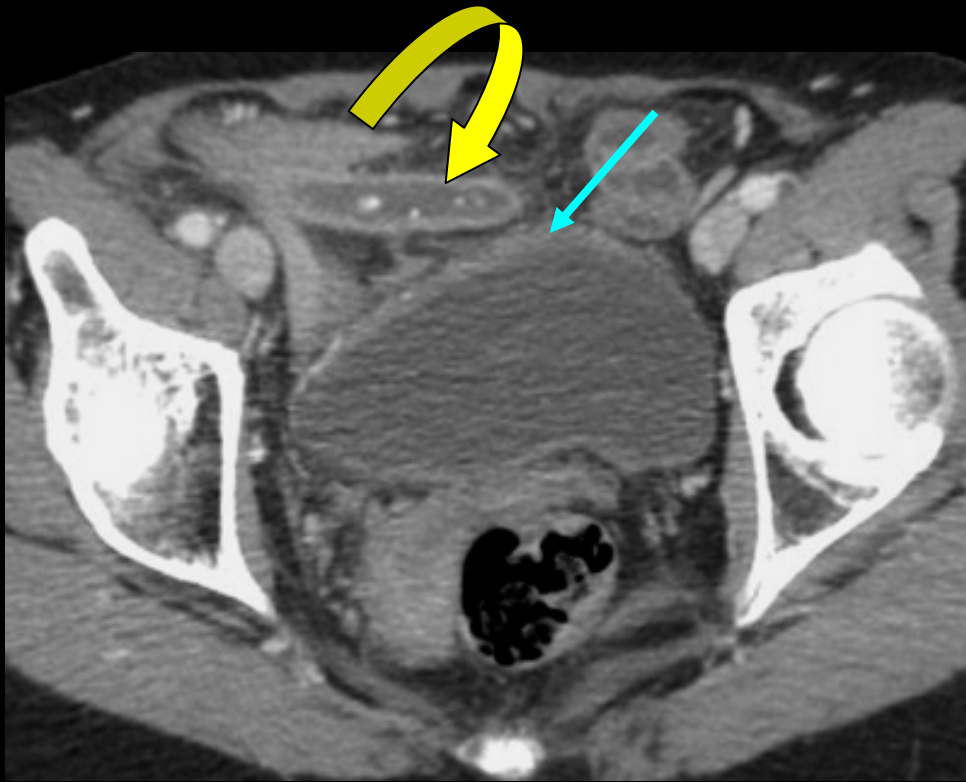


abcès appendiculaire sur
hernie de Claudius Amyand !

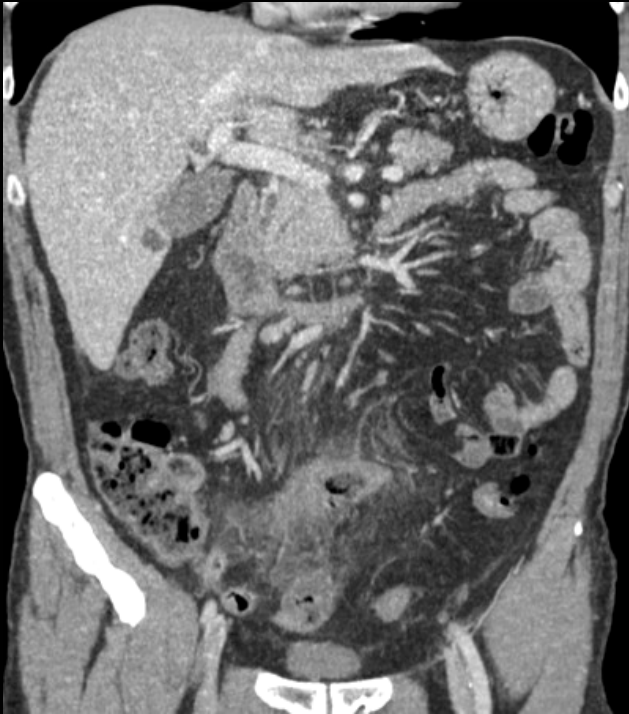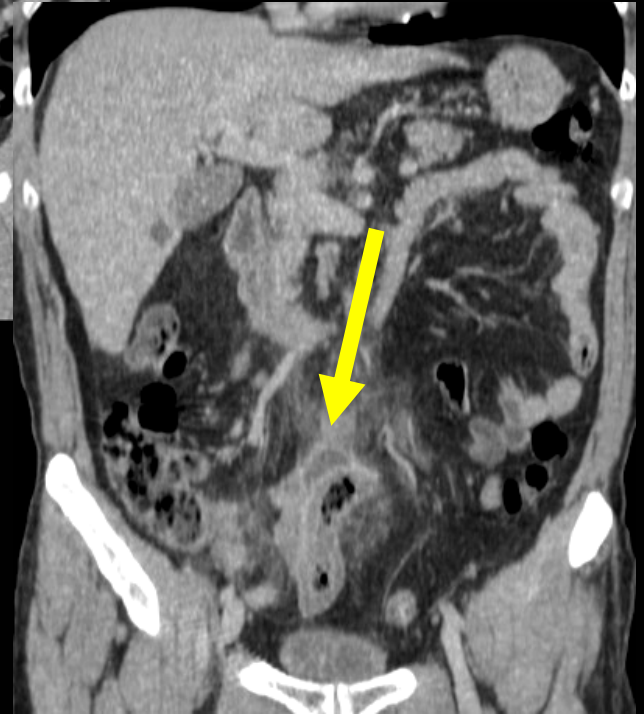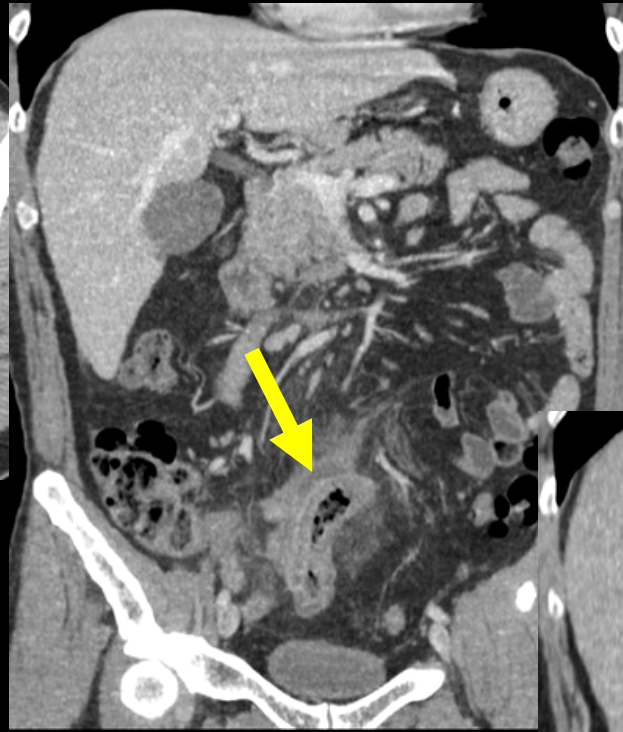


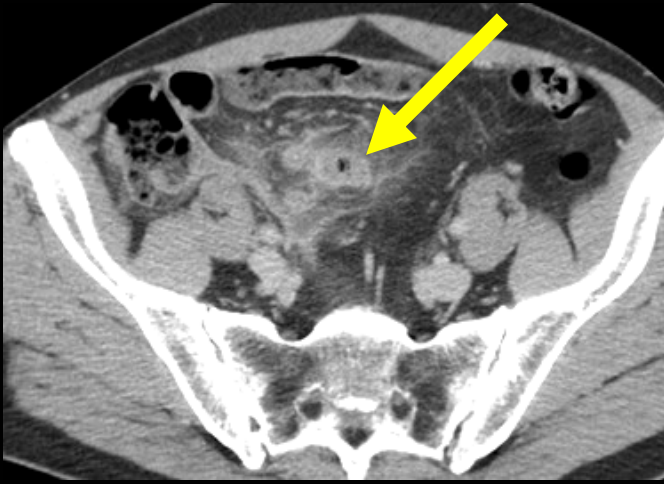abcès sur diverticule de Meckel intra herniaire
hernie de Littre (Alexis)

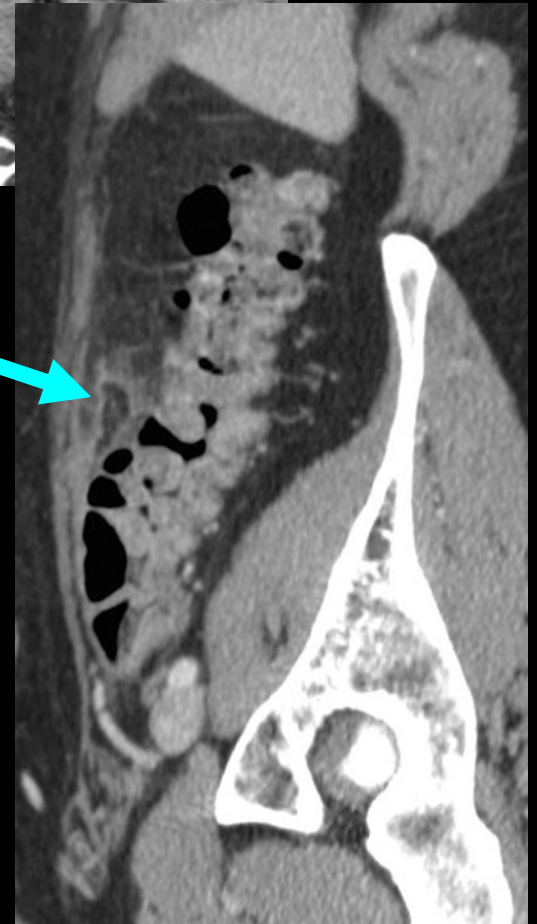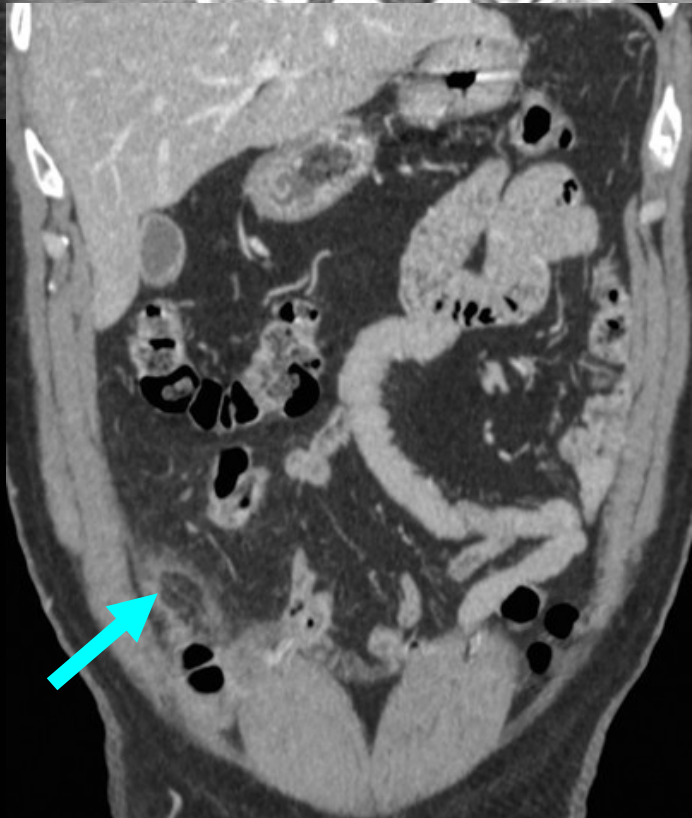
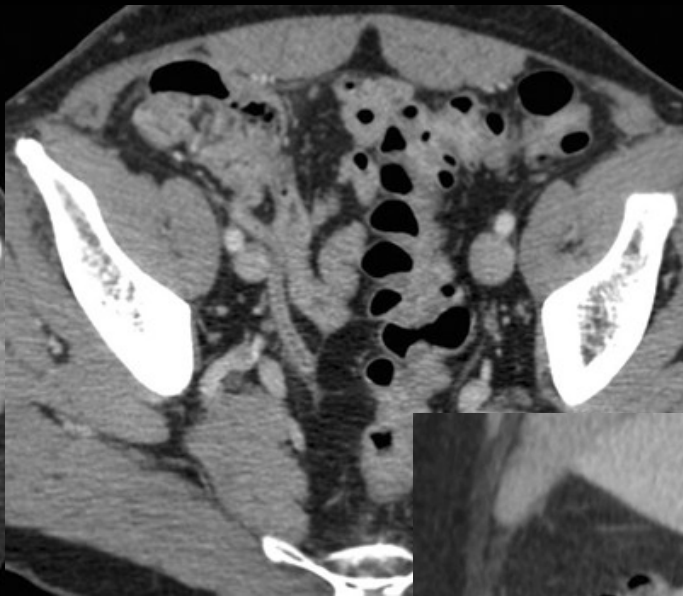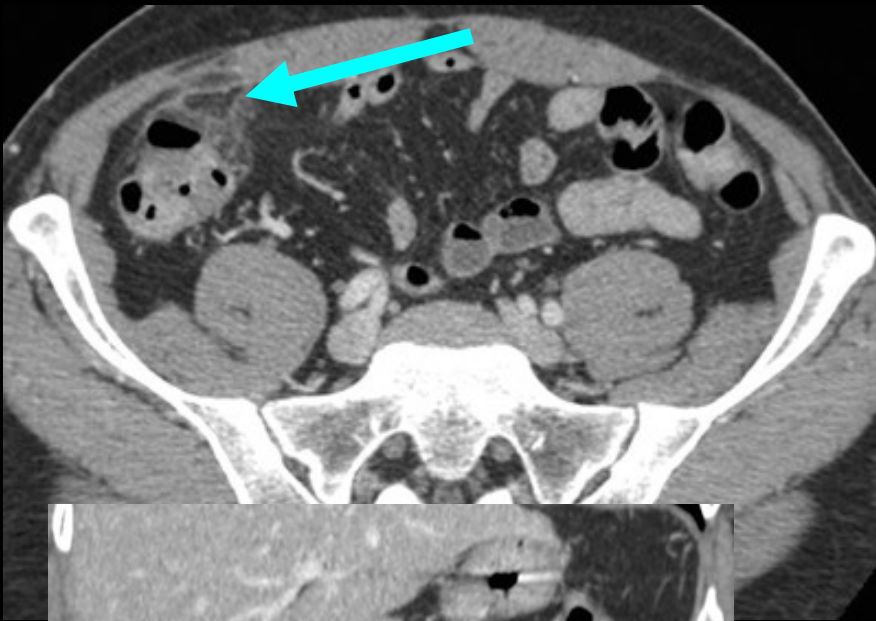
Professeur d'anatomie à Paris 1658-1726 .
Membre de l'Académie des Sciences



Appendicite sur appendice long ; multiples stercolithes ; épaissement de la paroi vésicale en regard de l'extrémité de l'appendice

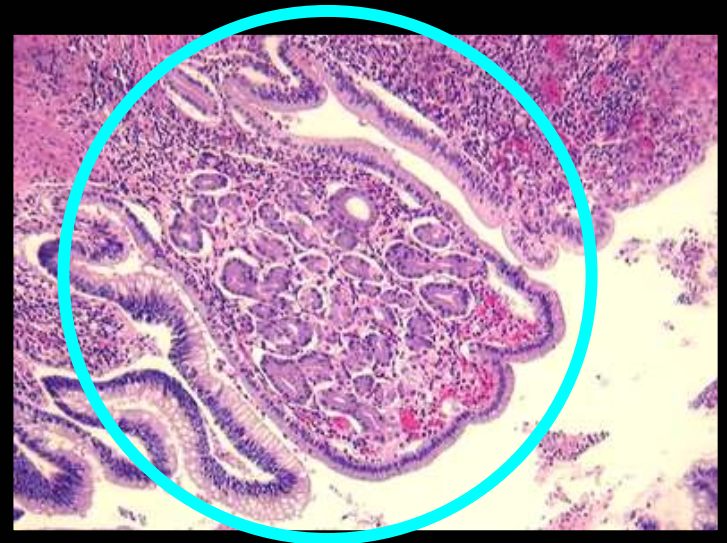
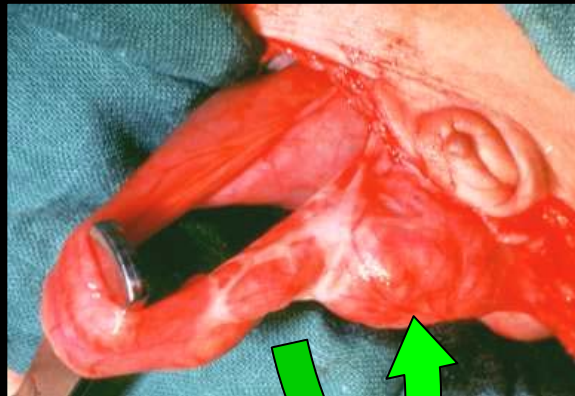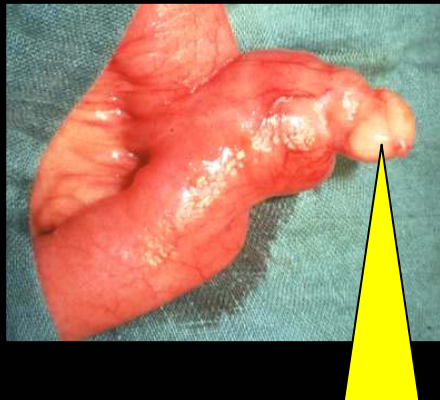
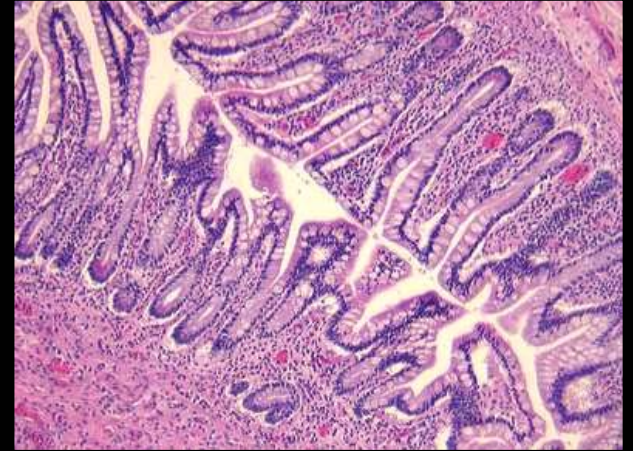
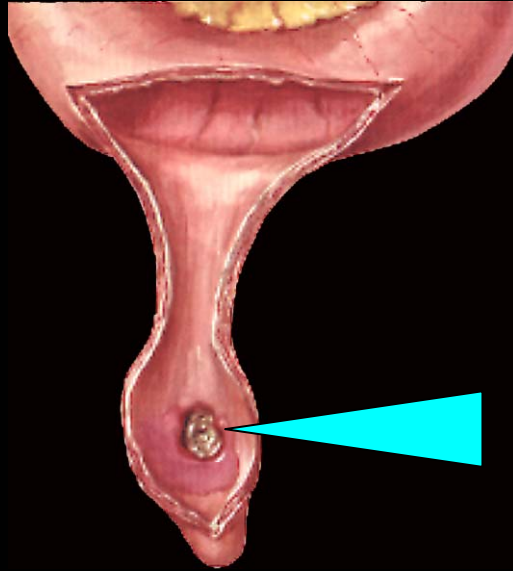

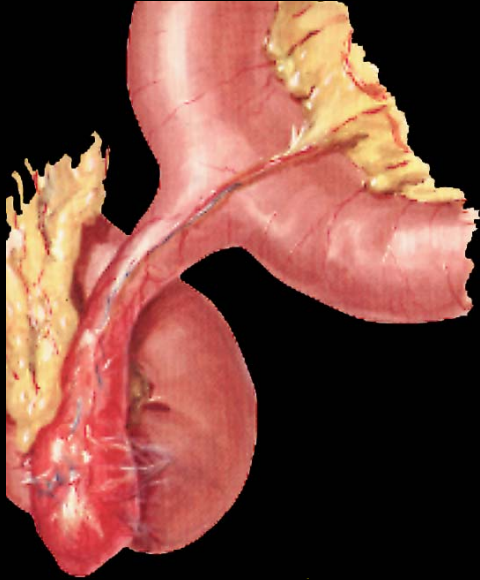
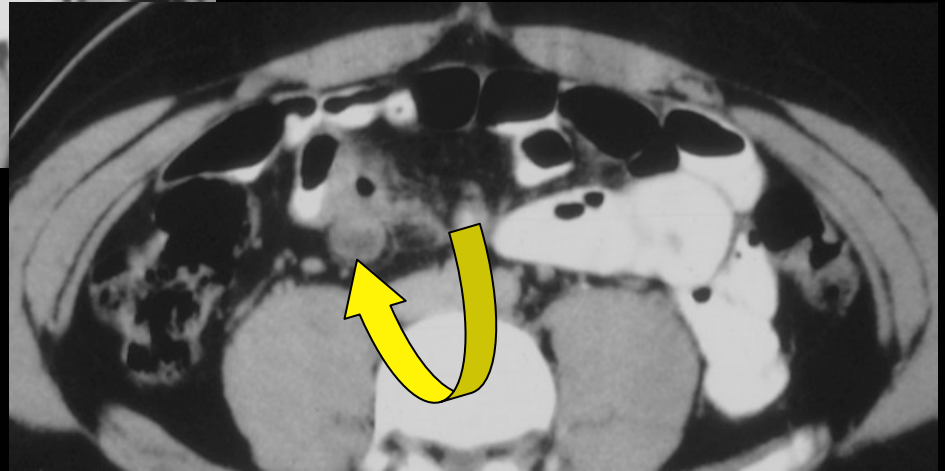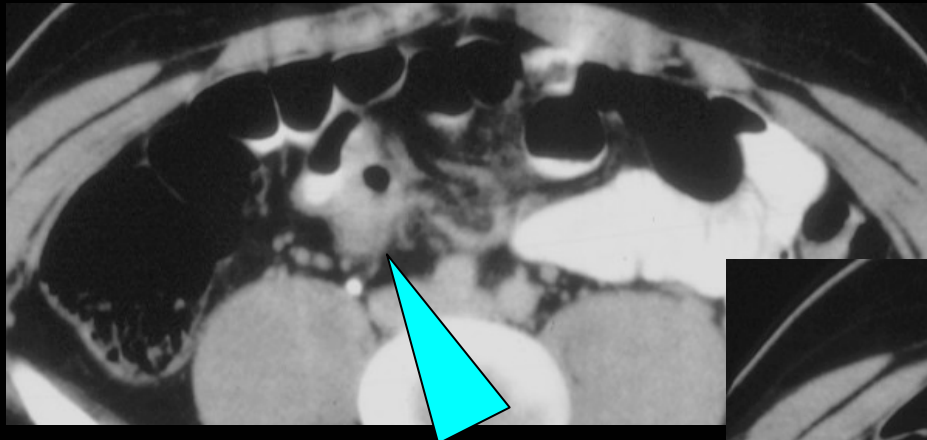
appendicite méso coeliaque sur appendice long, venant au contact du sigmoïde



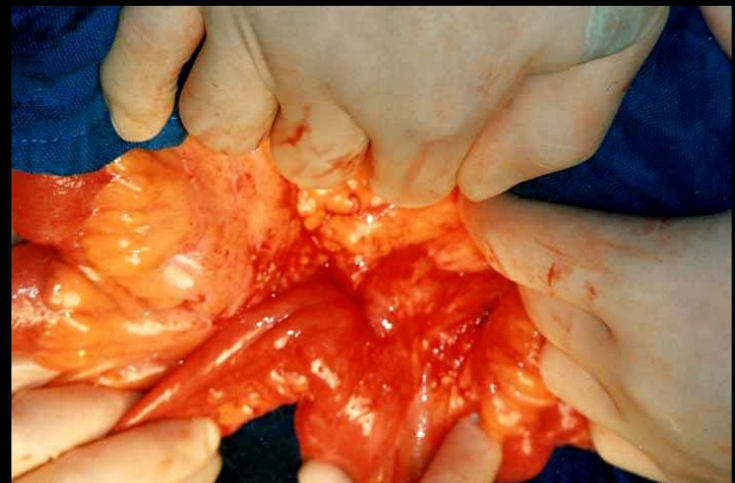
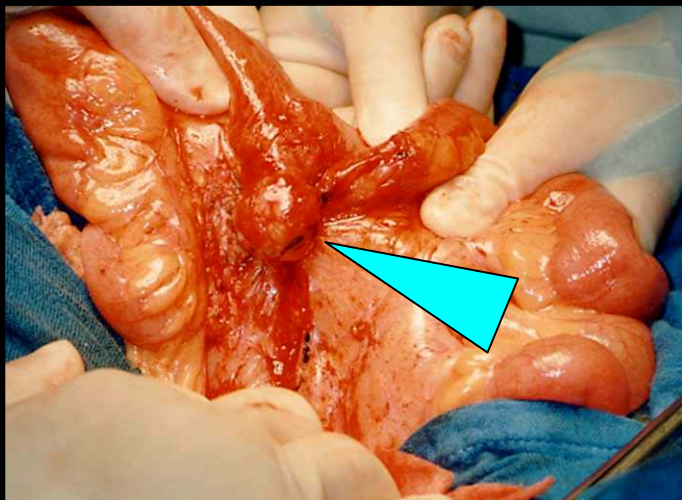
"appendagite" droite

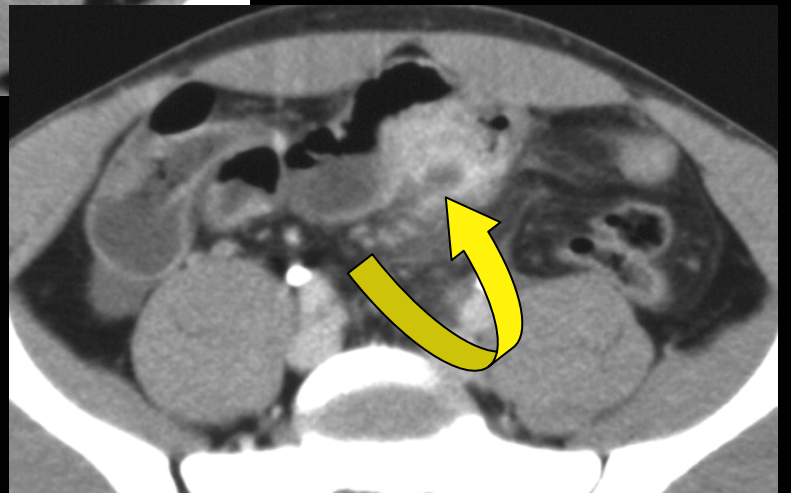
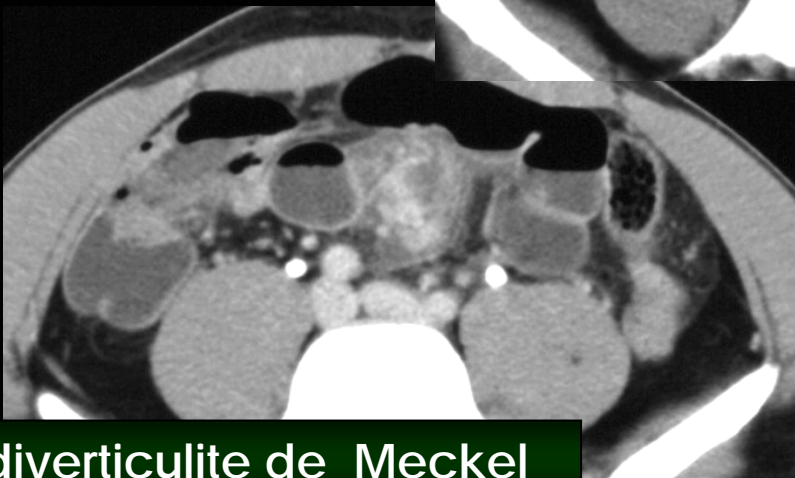
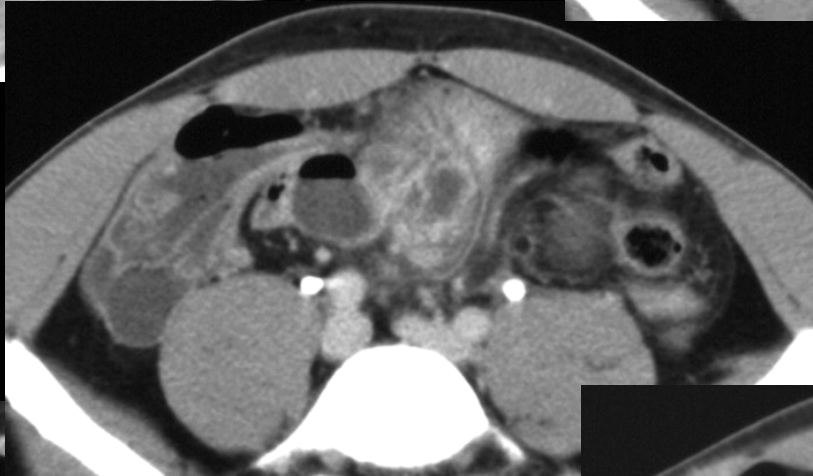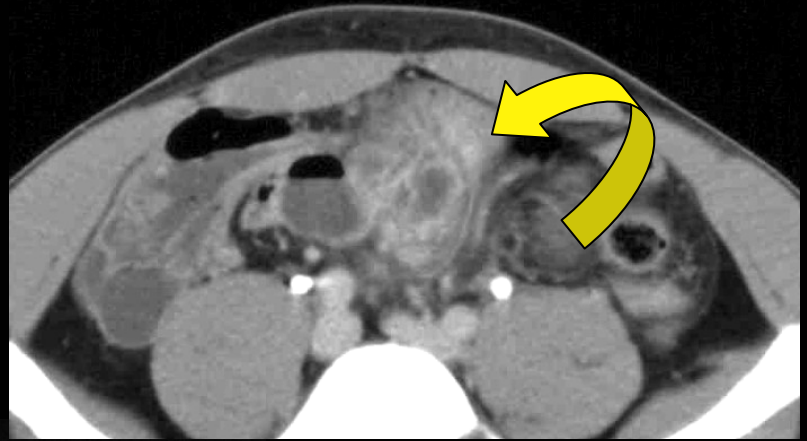
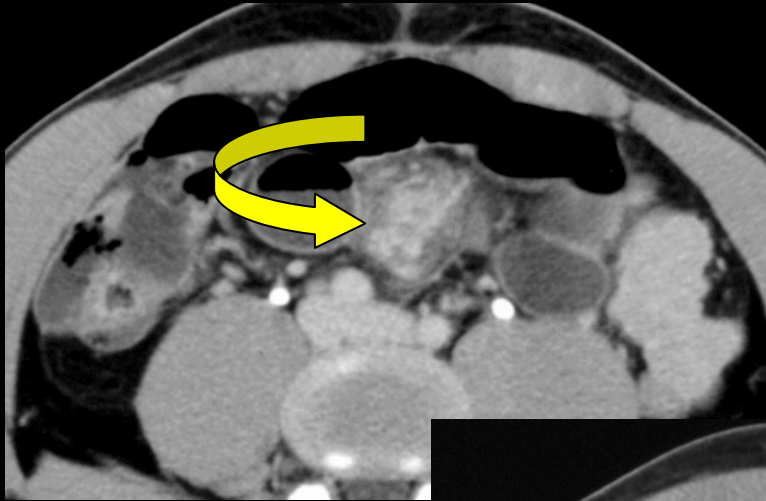
2c.les complications du diverticule de Meckel



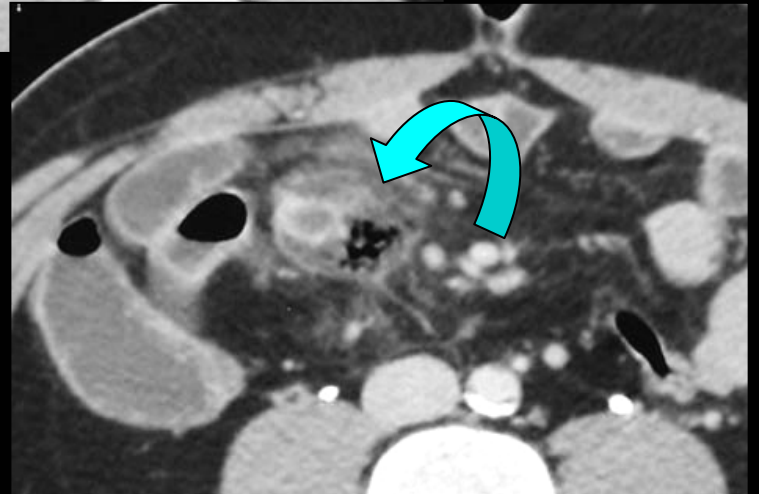
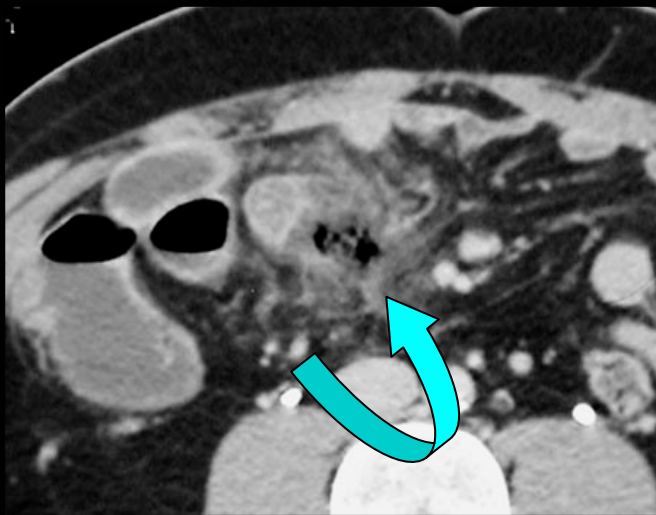
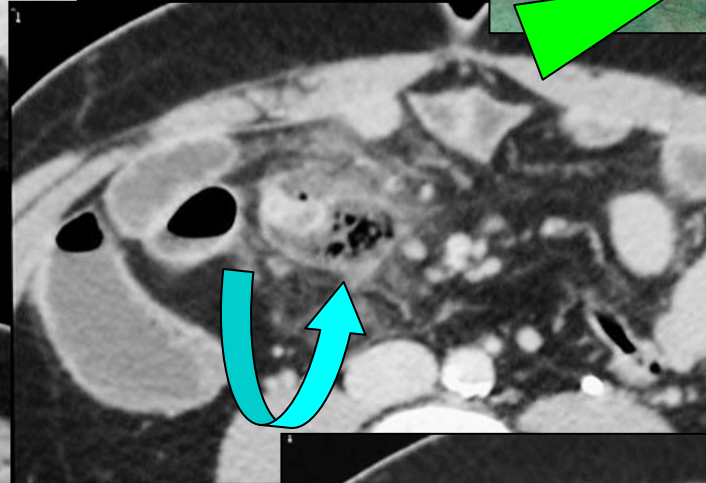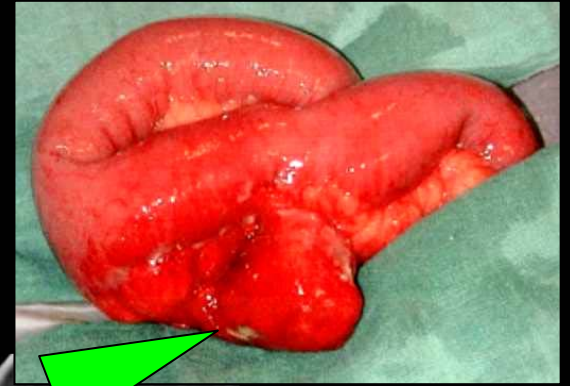
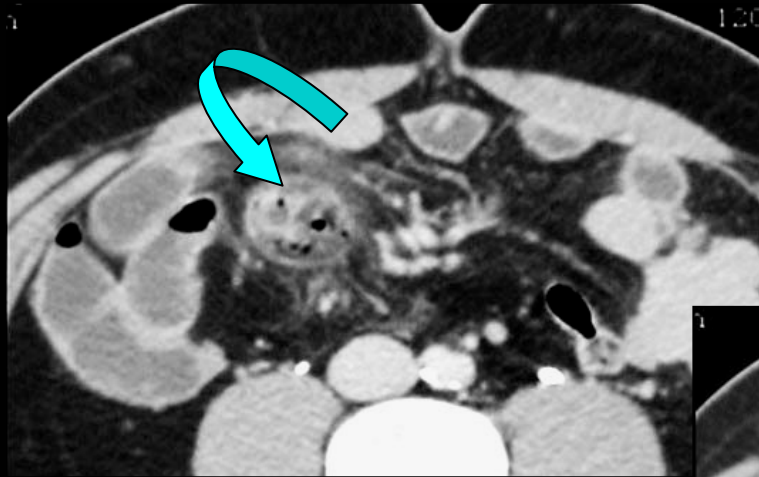


"diverticulite" de Meckel

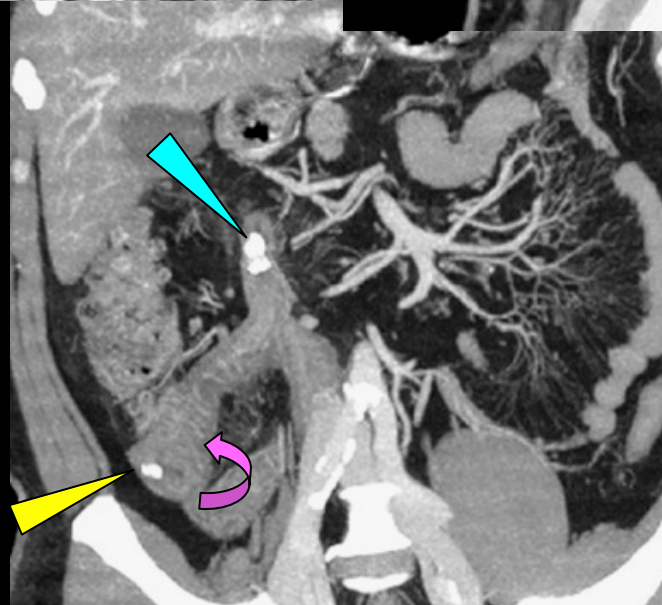
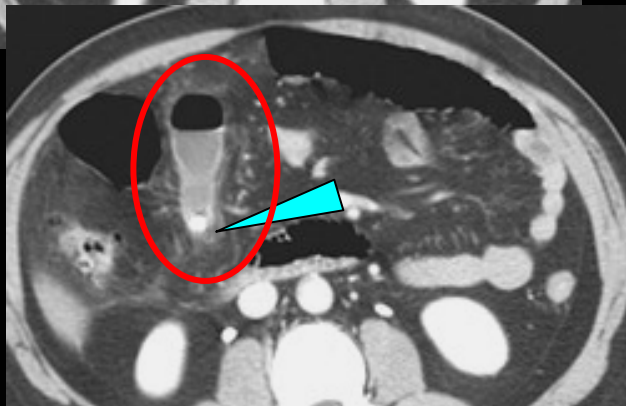
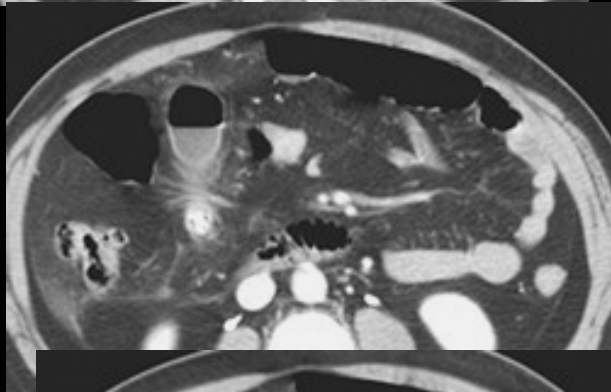
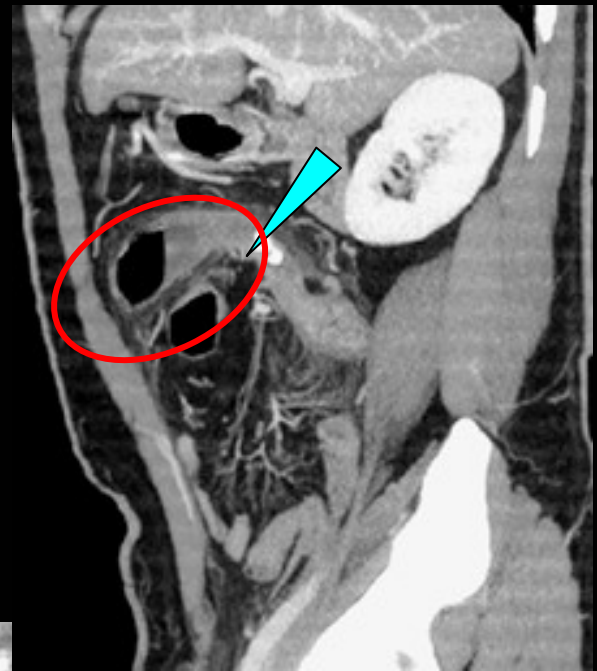
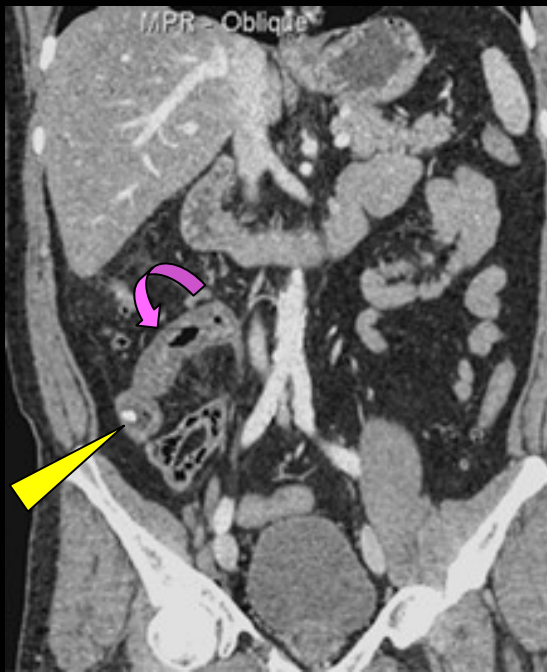
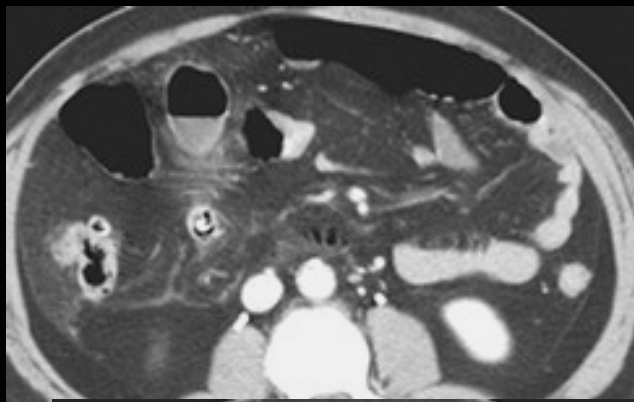




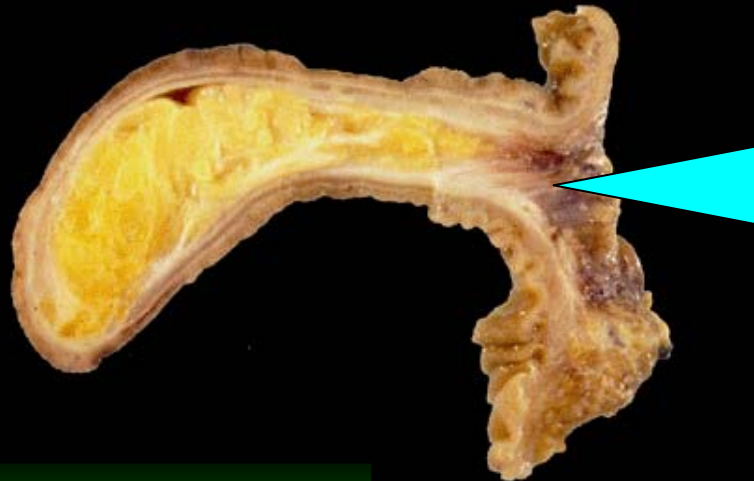
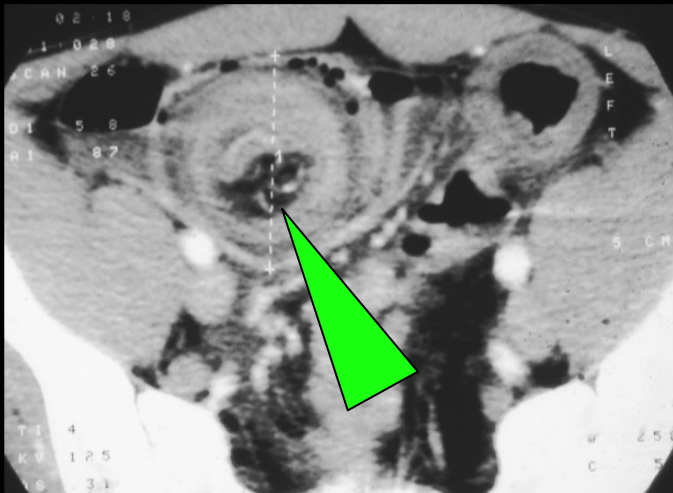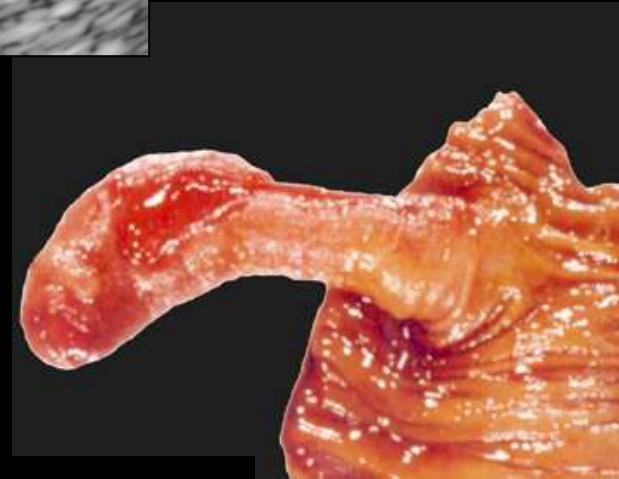
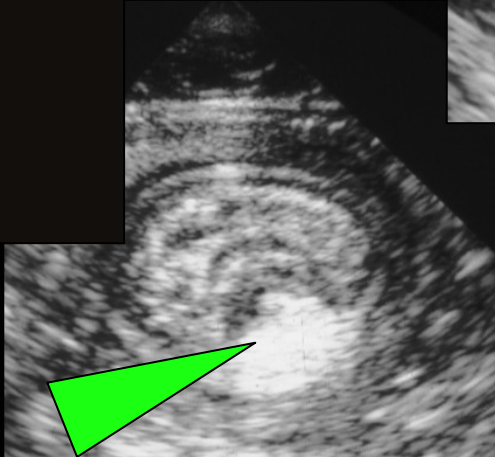
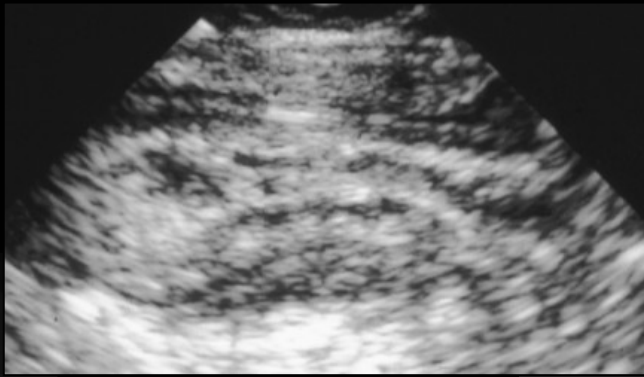
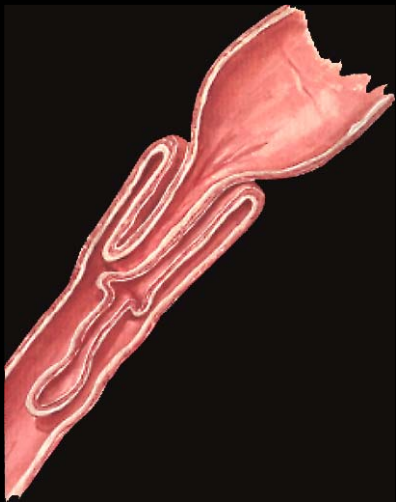diverticulite de Meckel



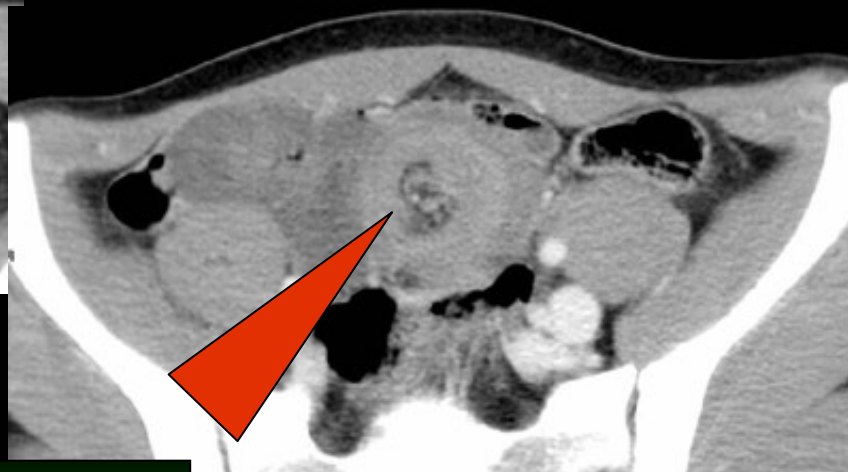
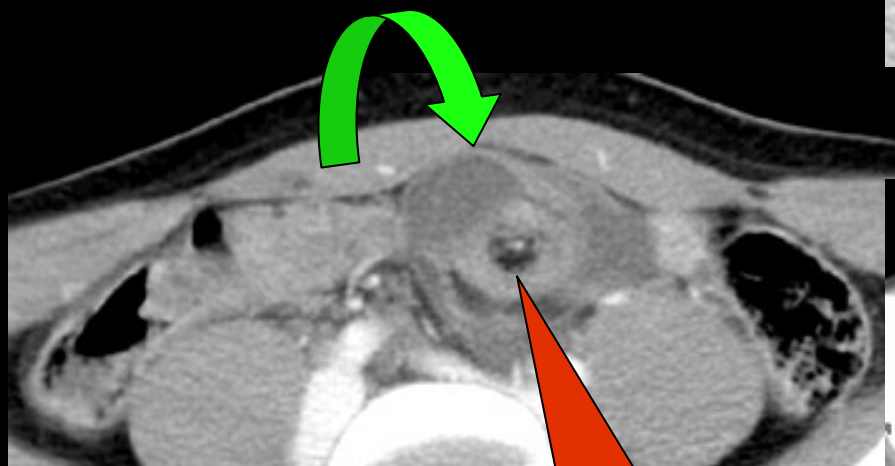
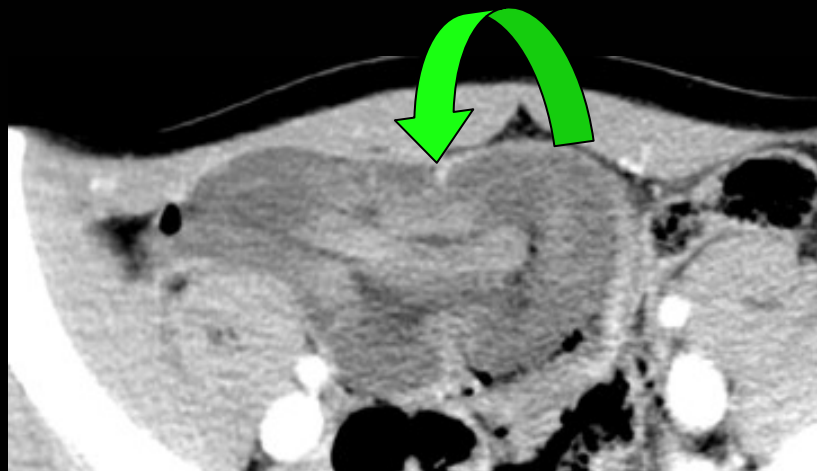
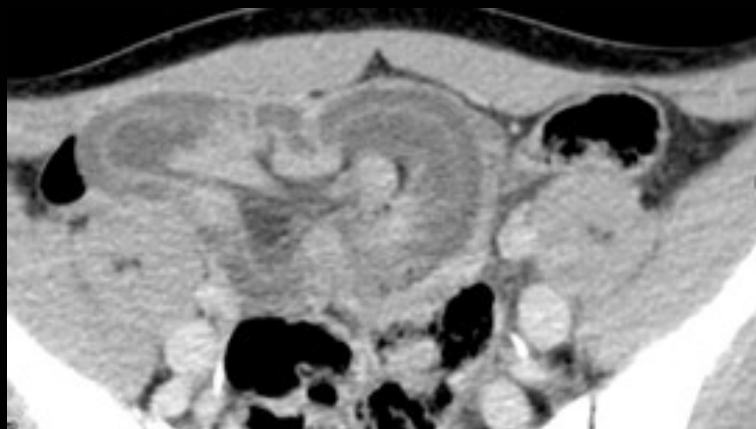
diverticulite de Meckel



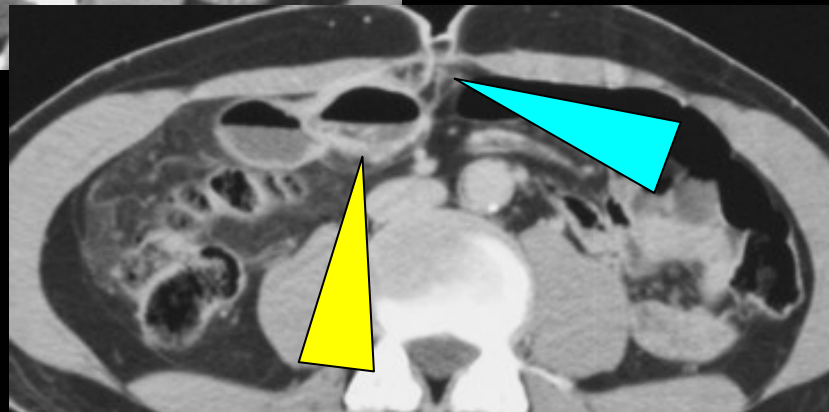
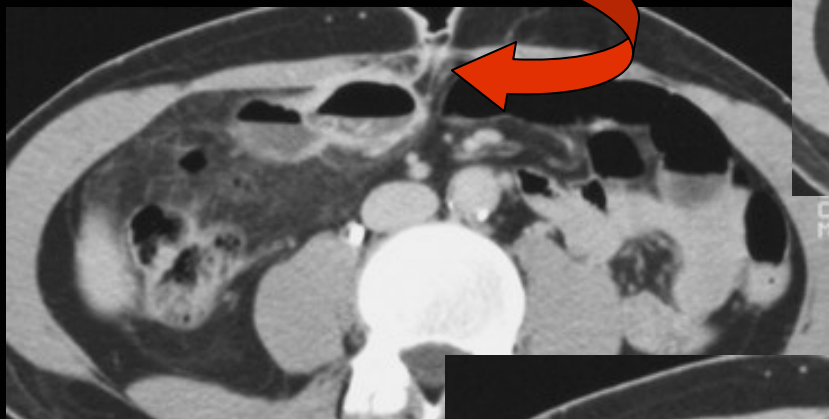
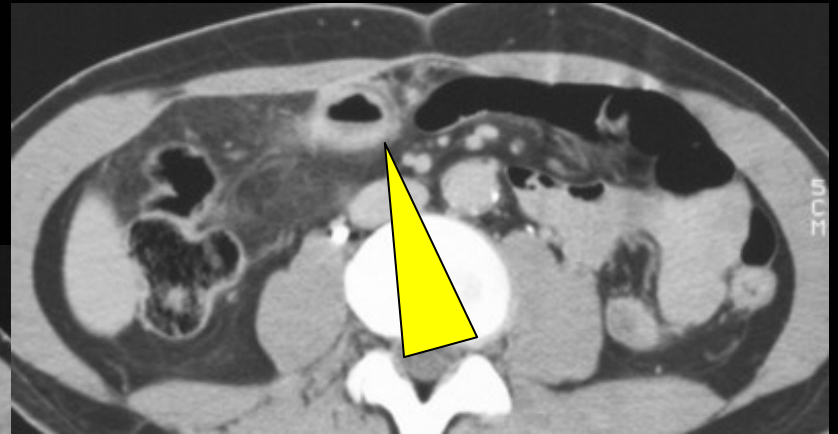
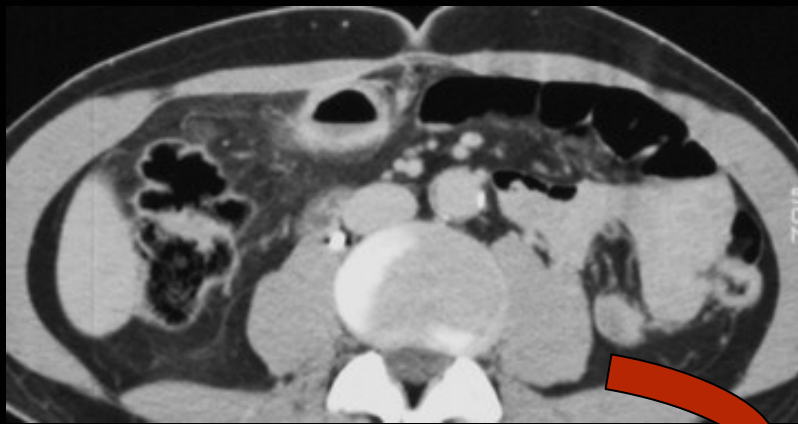
diverticulite de Meckel et
épisode occlusif par
migration d'un entérolithe



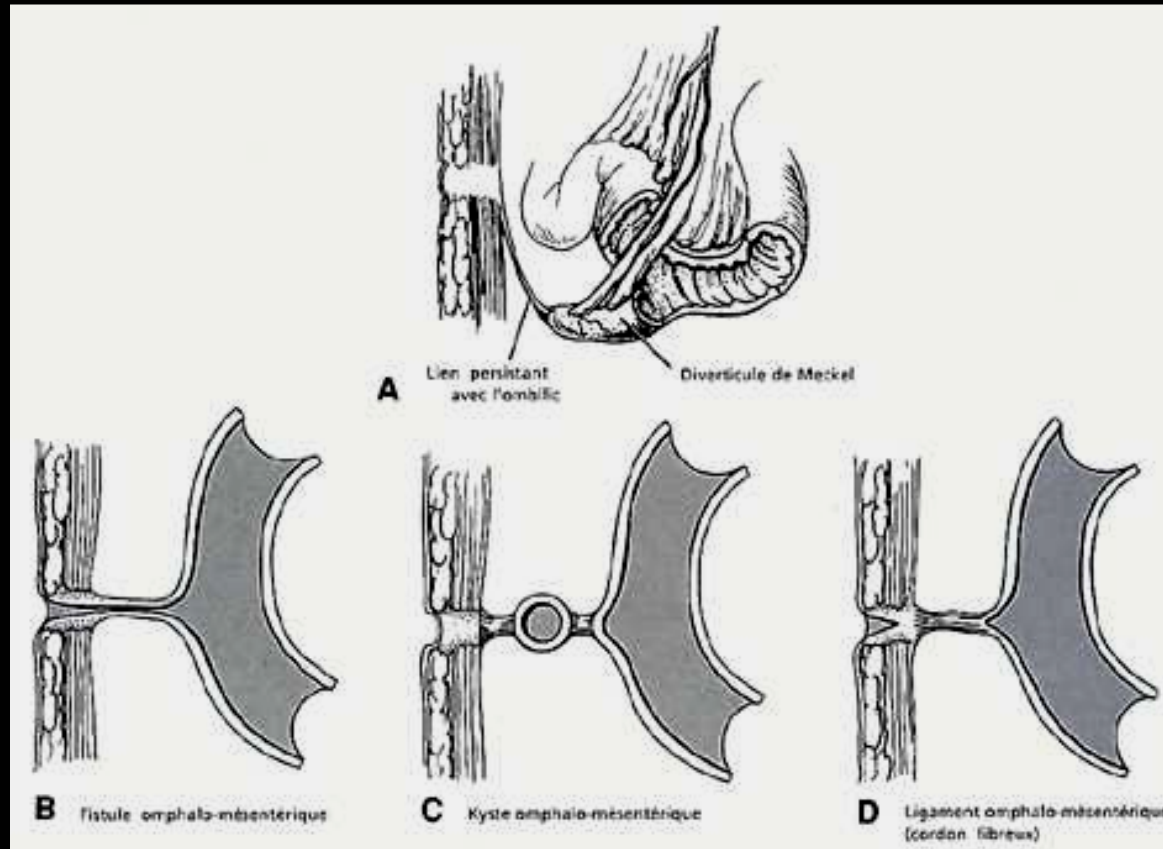
invagination sur diverticule de Meckel inversé



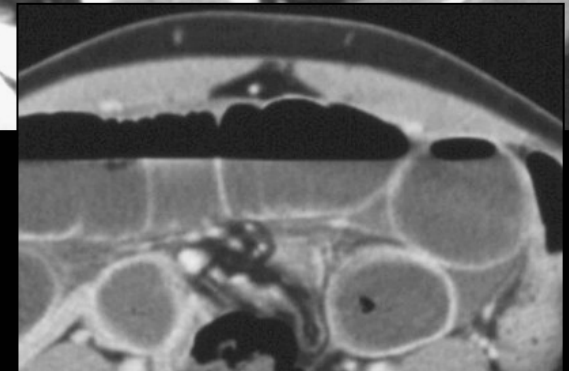
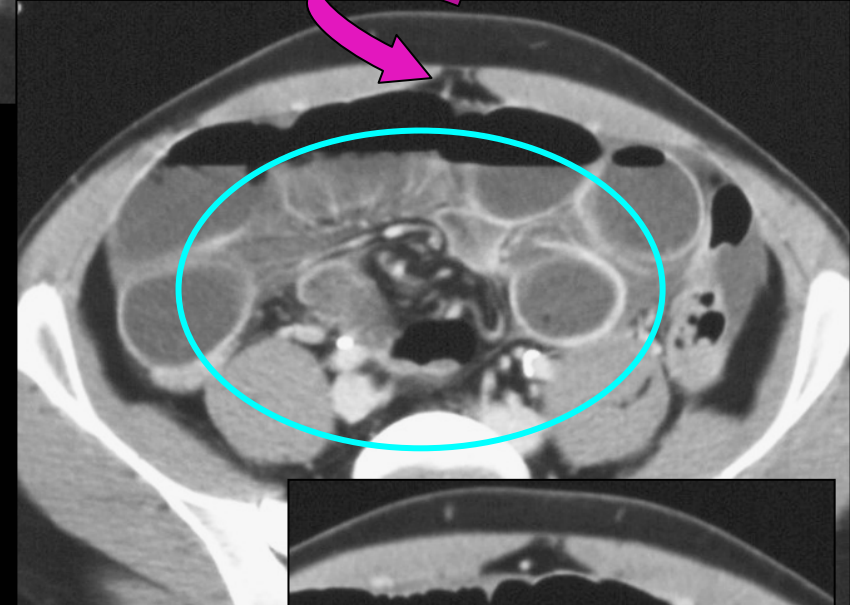
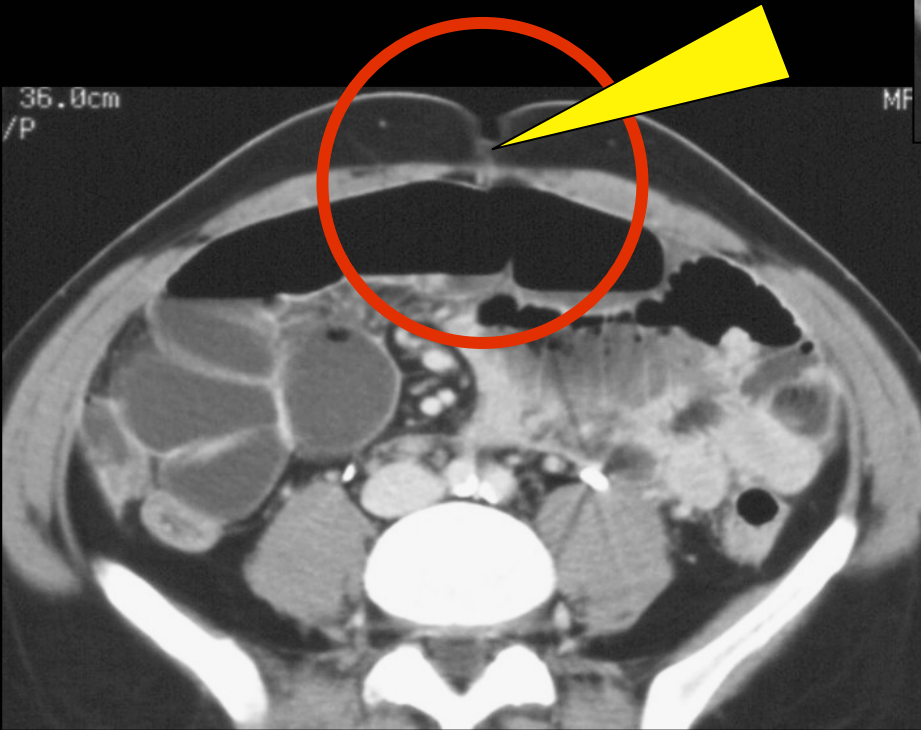
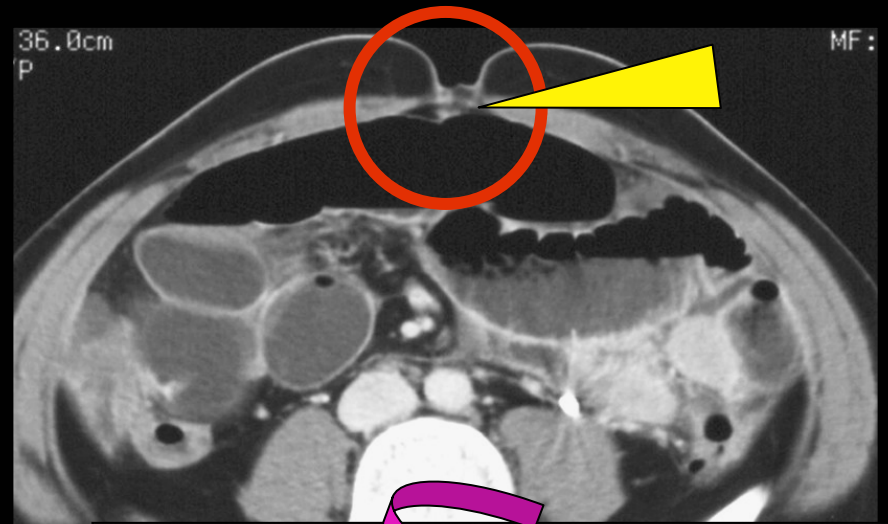
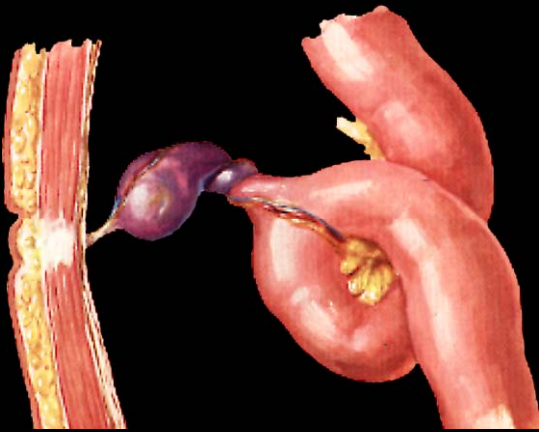invagination sur diverticule de Meckel inversé



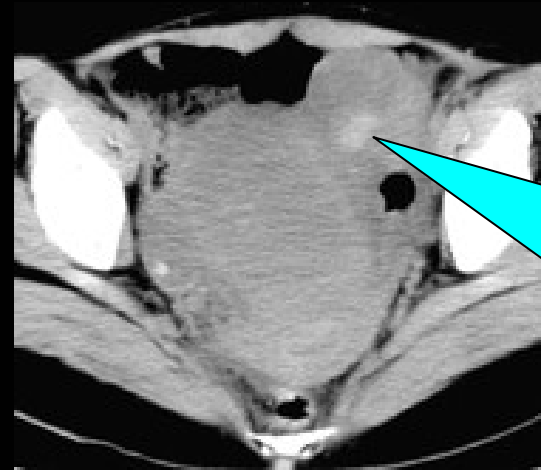
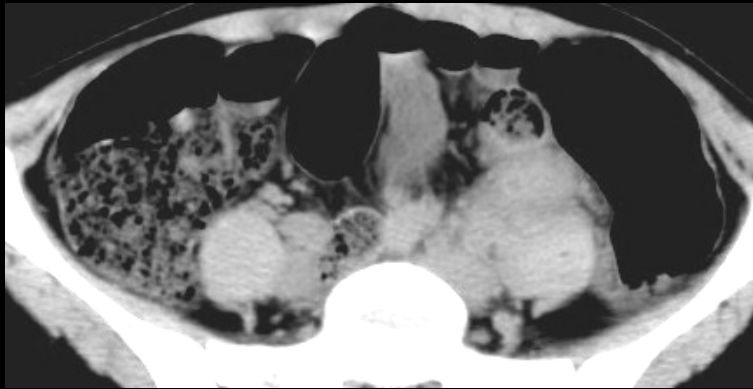
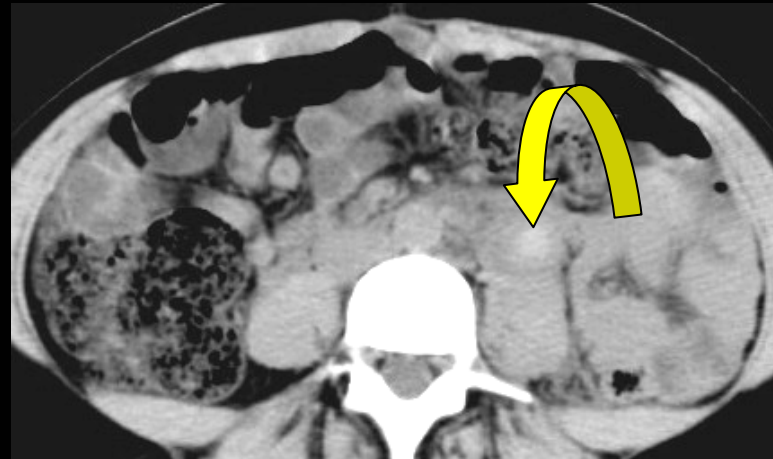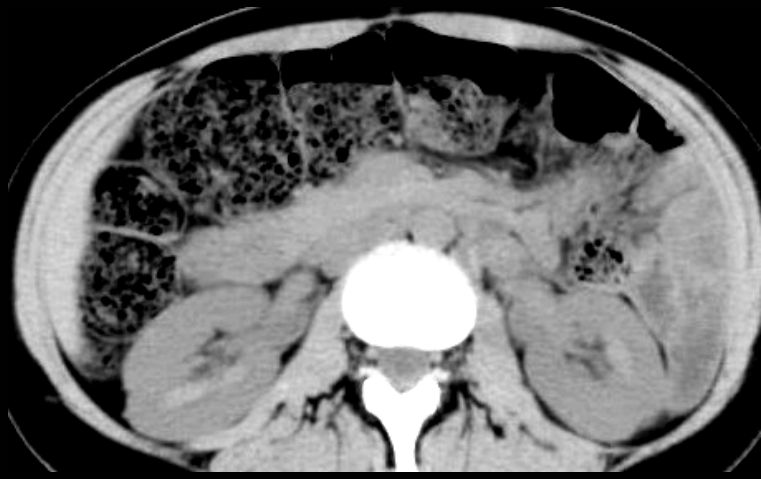diverticule de Meckel ; ligament omphalo-mésentérique



diverticule de Meckel ; pathologie du ligament omphalo-mésentérique



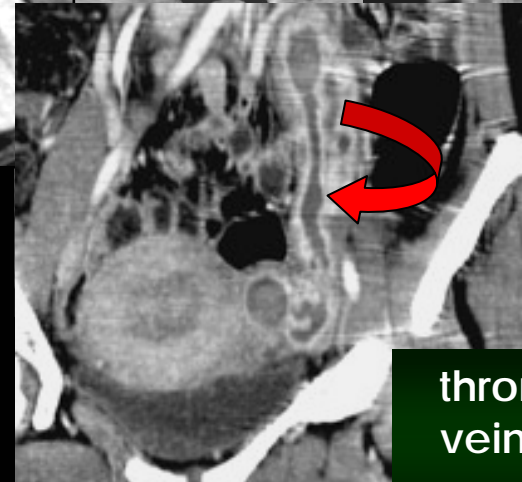
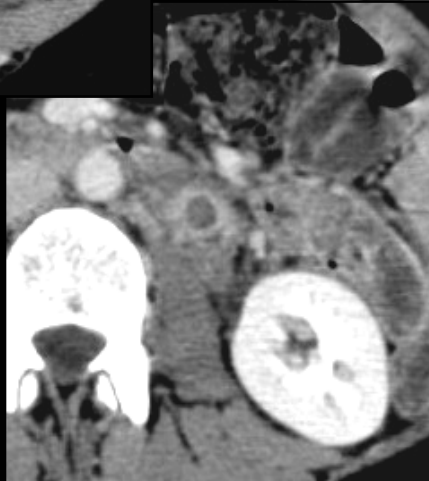
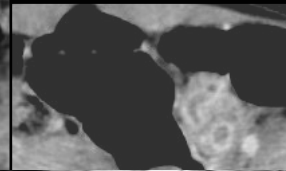
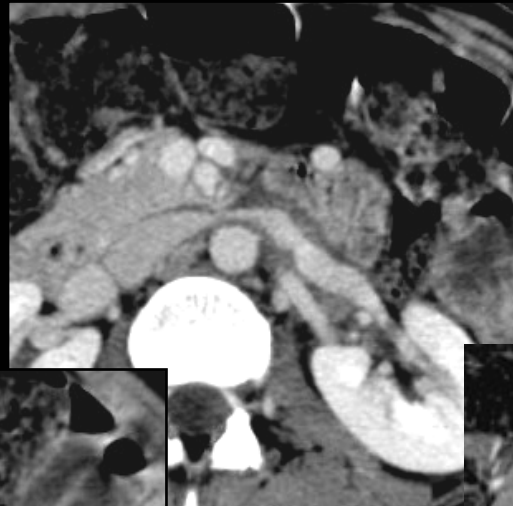
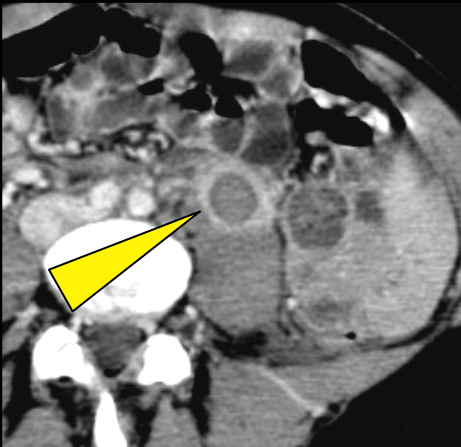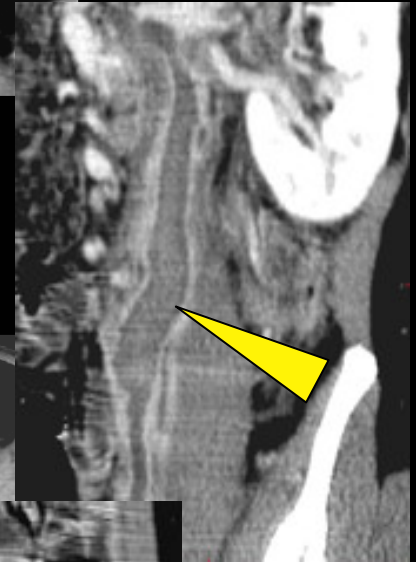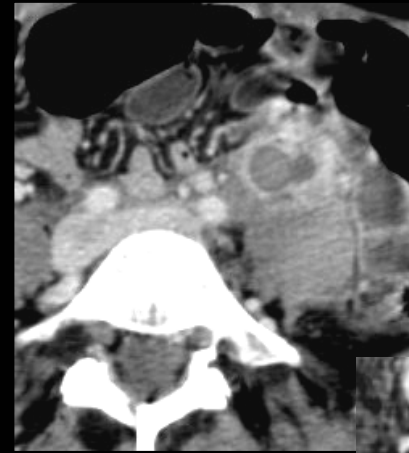
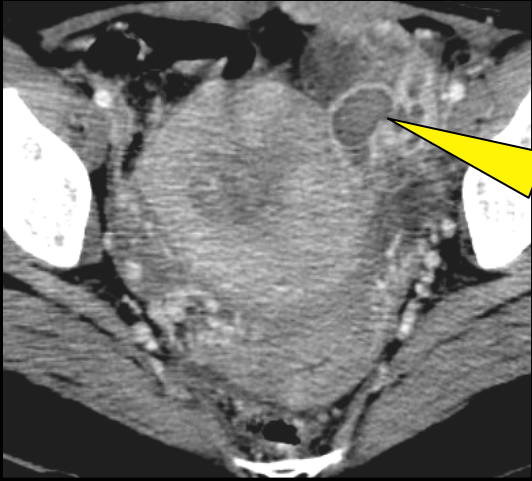occlusion sur bride sur diverticule de Meckel



femme / 30 ans
fièvre, DA, psoïtis
post-partum



dans la recherche d'une **cause de fièvre** ; en particulier après intervention chirurgicale ; n'oubliez pas les **thromboses veineuses profondes !!!**



thrombose de la
veine ovarienne
gauche

Points clés et pièges de l'imagerie scanographique des urgences abdominales

1. points clés et pièges du diagnostic des perforations intestinales



2. points clés et pièges du diagnostic des syndromes douloureux et fébriles de l'étage sous-mésocolique



3. points clés et pièges du diagnostic des ischémies intestino-mésentériques



4. points clés et pièges du diagnostic des occlusions intestinales



5. points clés et pièges du diagnostic des syndromes douloureux et fébriles de l'étage sus-mésocolique

