

3-imagerie des occlusions colo-rectales

3-1 bases étio-pathogéniques

3-1-1 occlusions colo-rectales d'origine extrinsèque

3-1-1-1 volvulus coliques

3-1-1-1-1 volvulus du sigmoïde

3-1-1-1-2 volvulus du caecum

3-1-1-1-3 double volvulus

3-1-1-1 hernies internes

3-1-1-2 hernies pariétales

3-1-2 occlusions colo-rectales d'origine pariétale

3-1-2-1 lésions pariétales sténosantes colo-rectales tumorales

3-1-2-2 lésions pariétales sténosantes colo-rectales non tumorales

3-1-3 occlusions colo-rectales d'origine endoluminale

3-1-3-1 corps étrangers endoluminaux

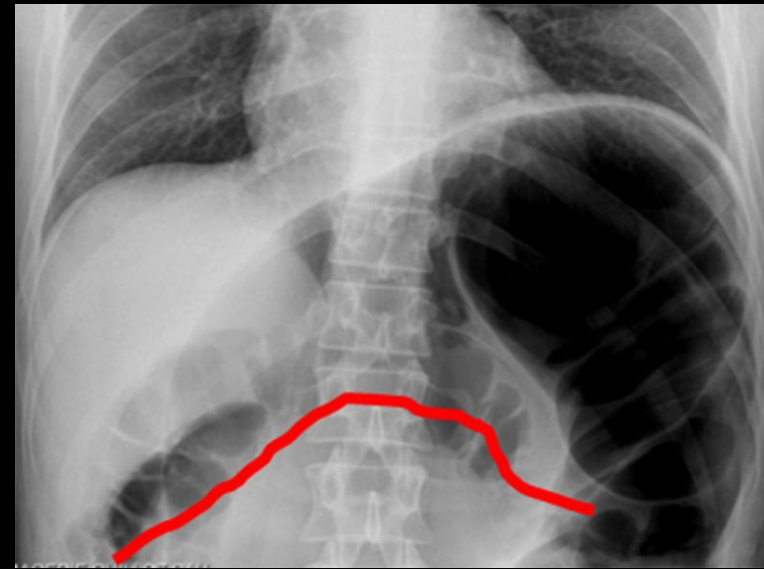
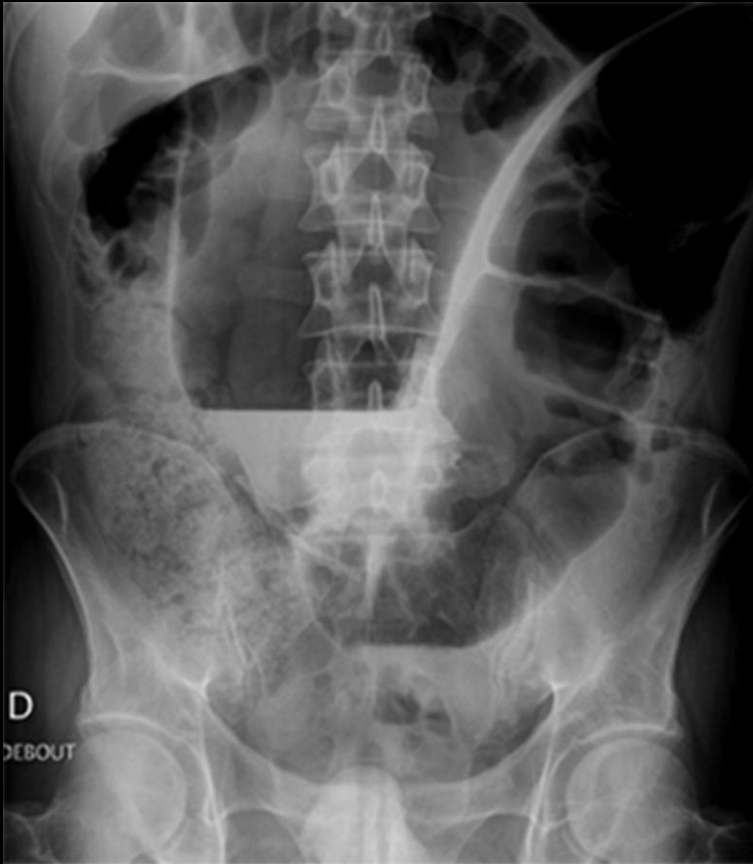3-1-3-2 invaginations coliques

3-1-4 occlusions colo-rectales fonctionnelles

3-2 bases techniques d'exploration

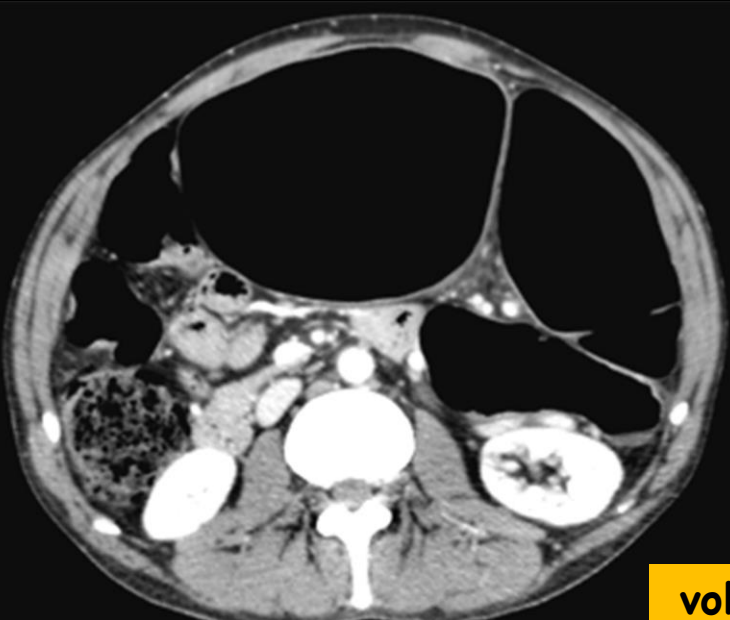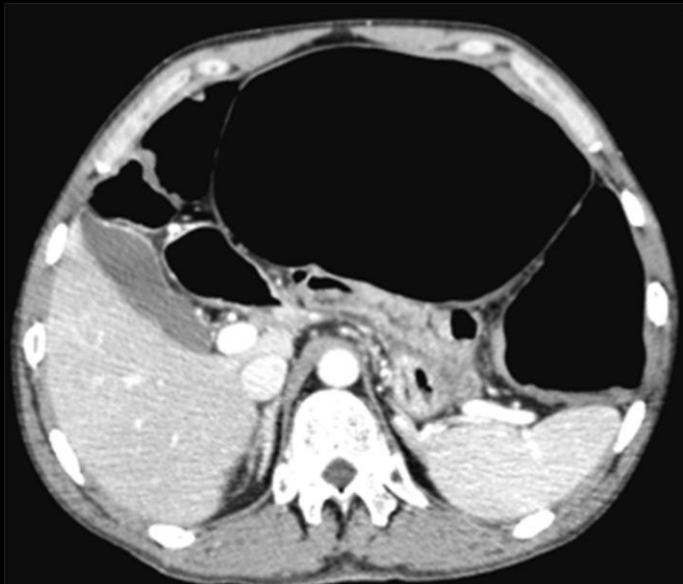
3-3 bases sémiologiques d'exploration

3-1-1-1 volvulus du sigmoïde

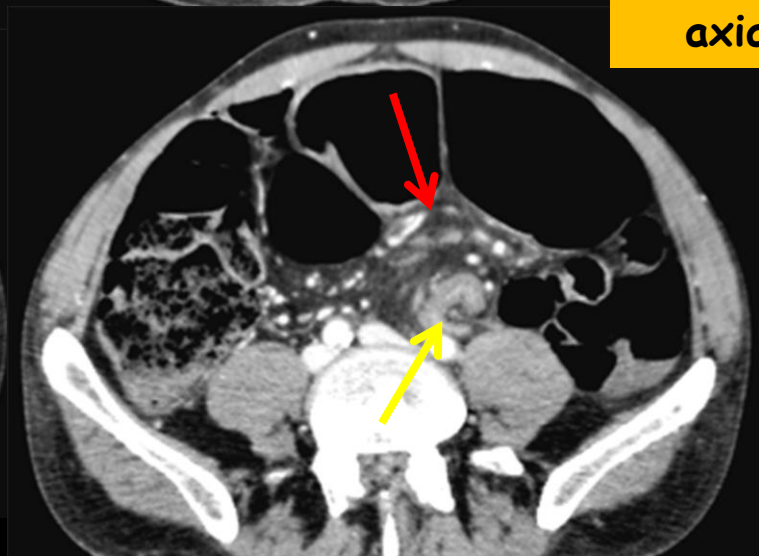
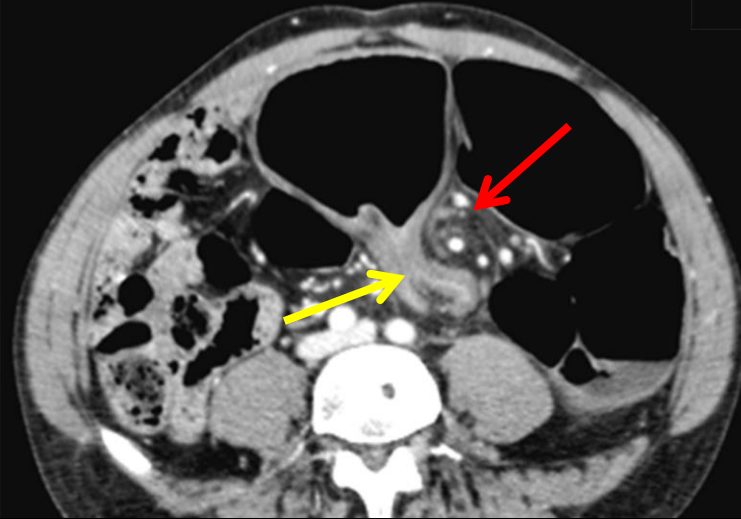


volvulus **mésentérico-axial** du sigmoïde:

- image "en grain de café" (juxtaposition des parois médiales des 2 jambages) -
- croisement des 2 jambages à l'étage pelvien
- "northern exposure sign" le sommet du dolichosigmoïde dépasse le colon transverse

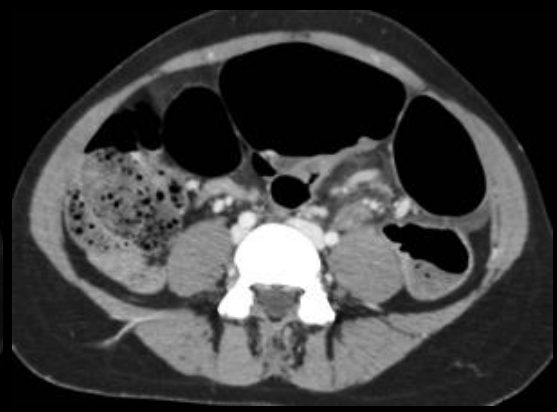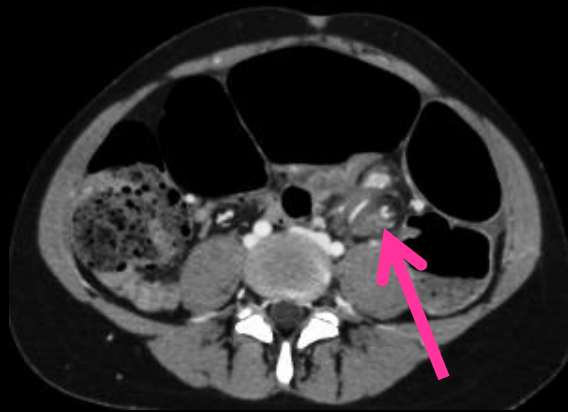
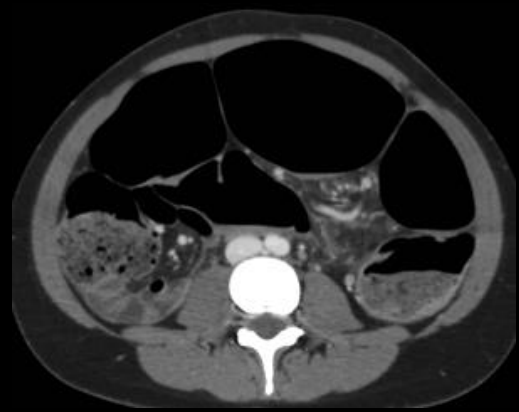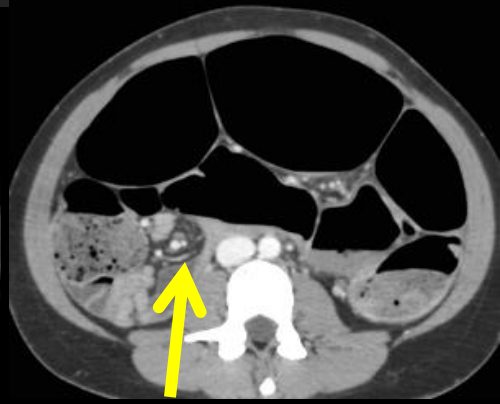
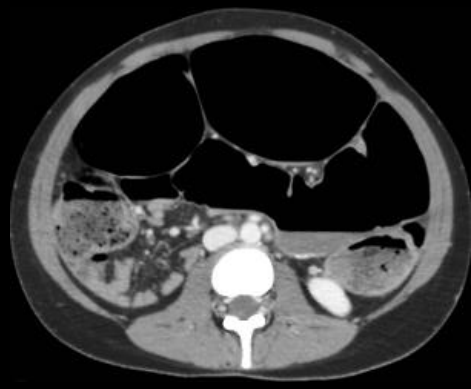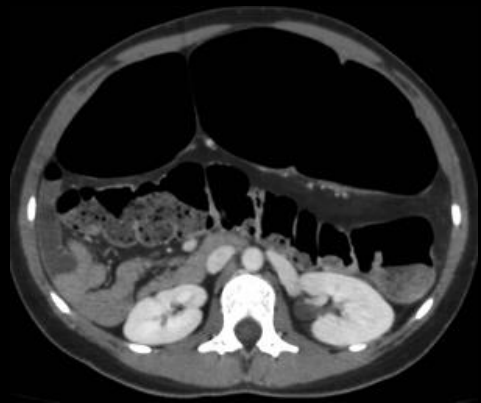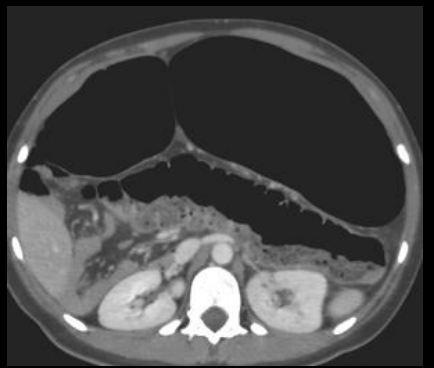


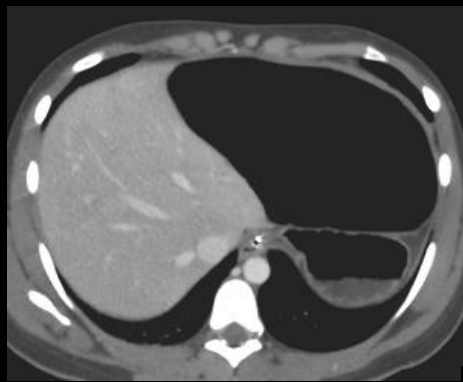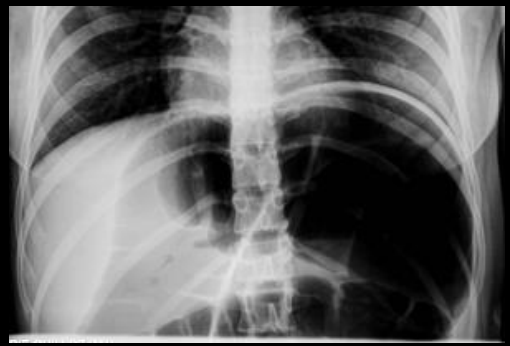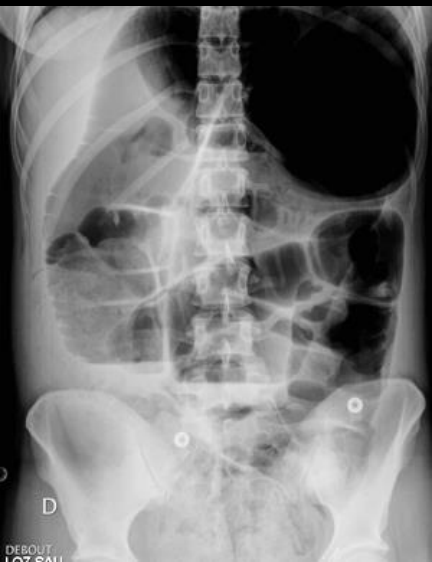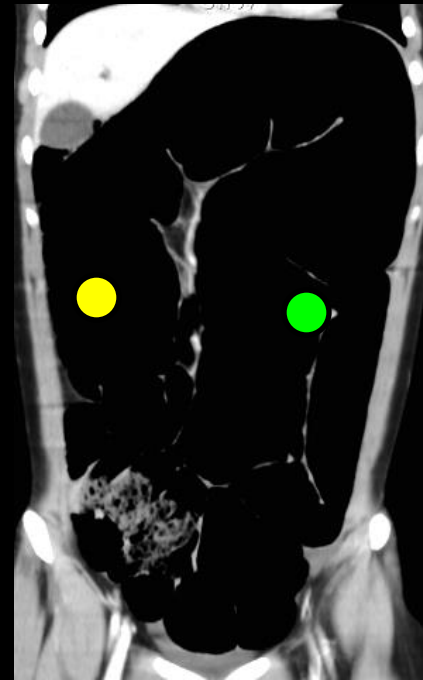
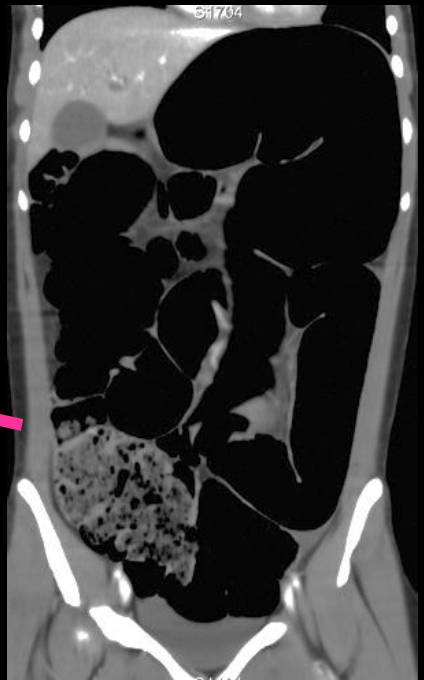
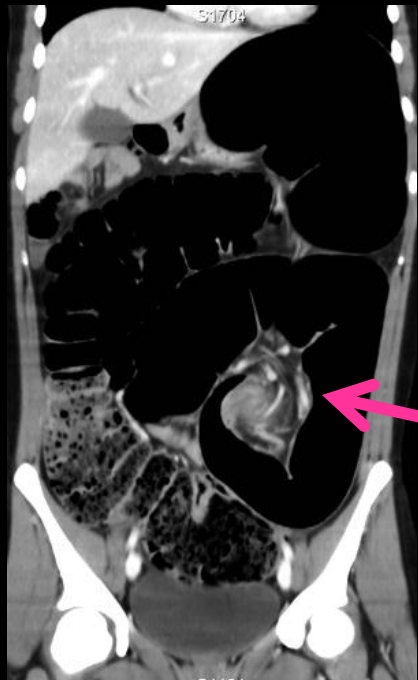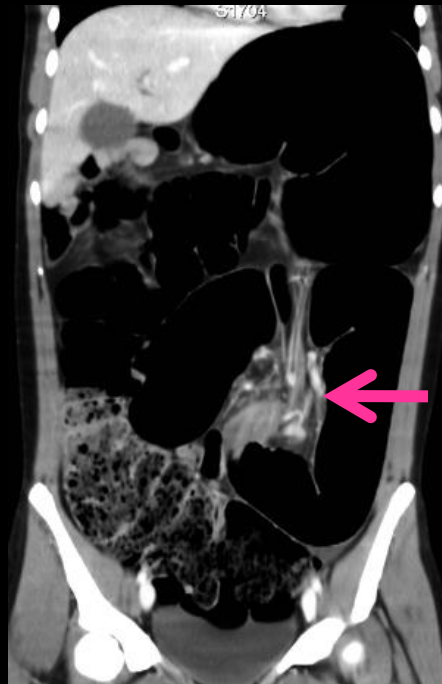
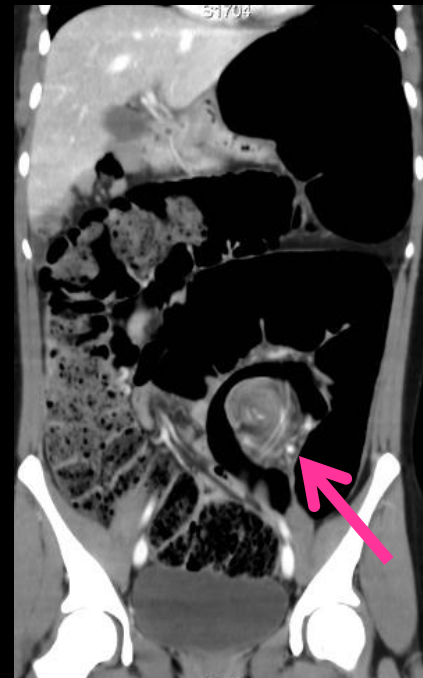
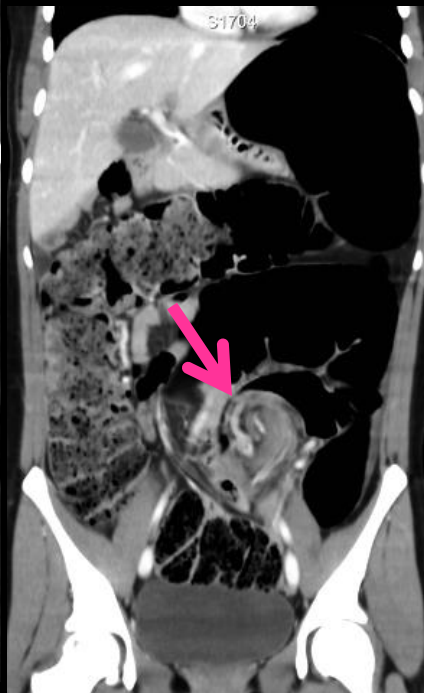
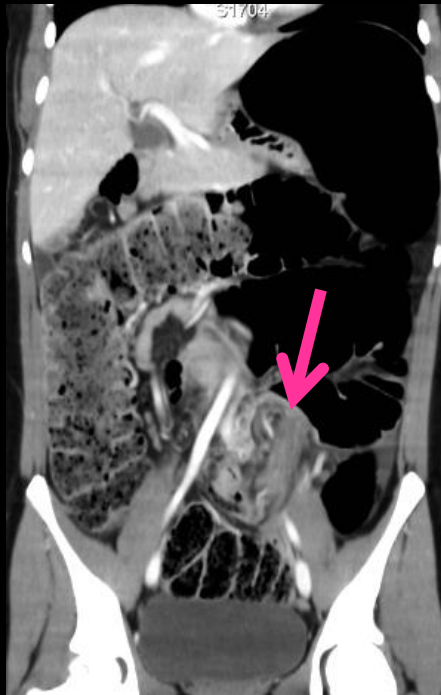
volvulus mésentérico-axial du sigmoïde



- croisement des 2 jambages à l'étage pelvien
- signe du tourbillon (whirl sign)
- bon rehaussement des parois

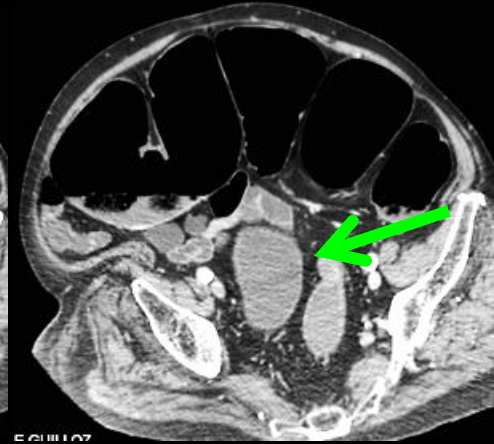
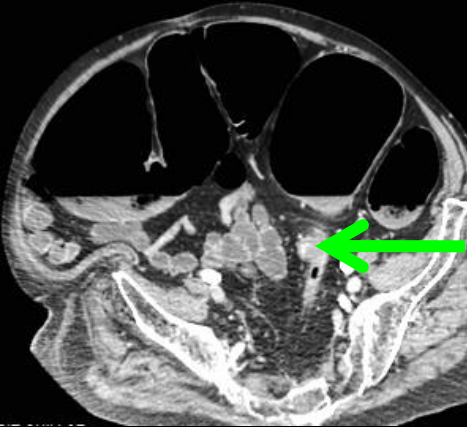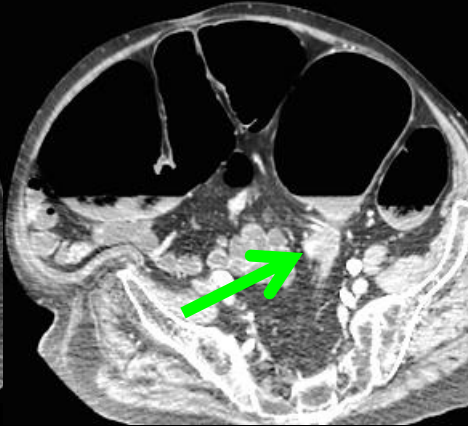
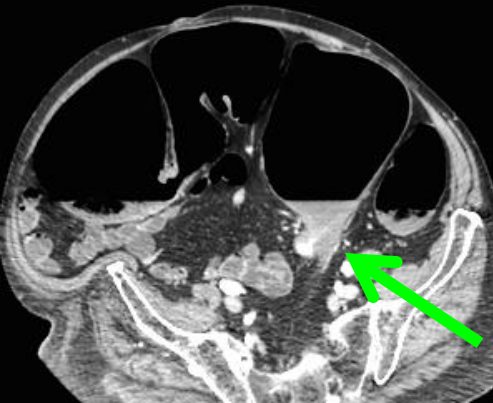
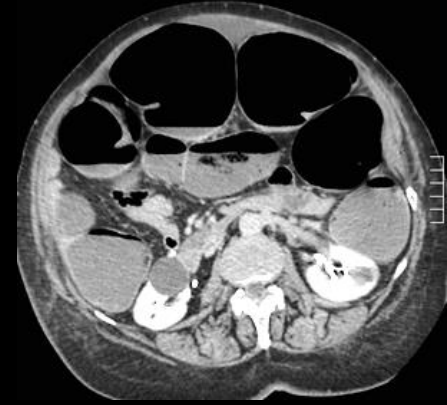
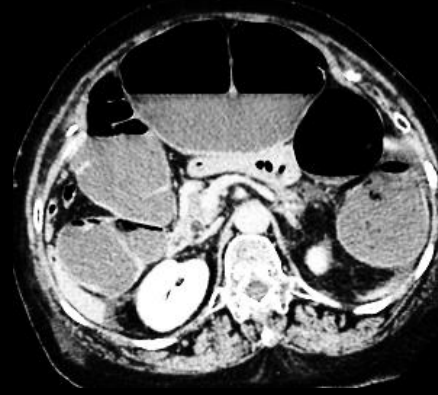
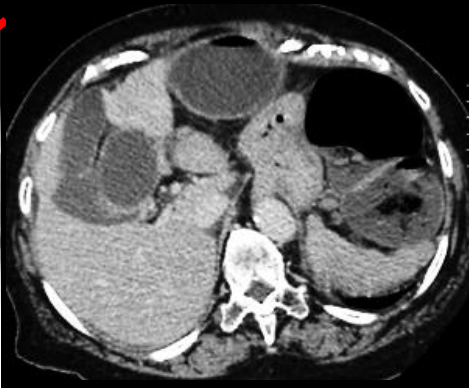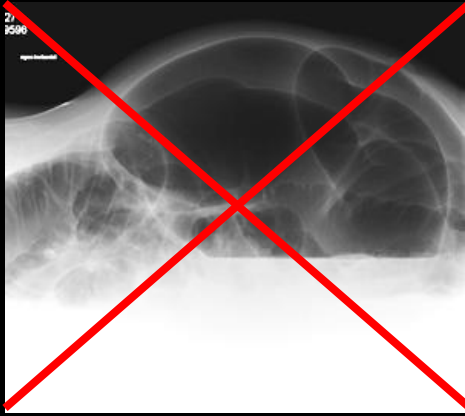
jeune femme 20 ans , syndrome occlusif avec ballonnement abdominal





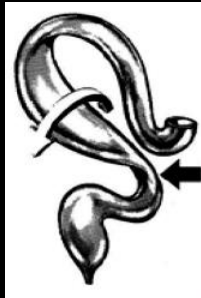volvulus mésentérico
-axial

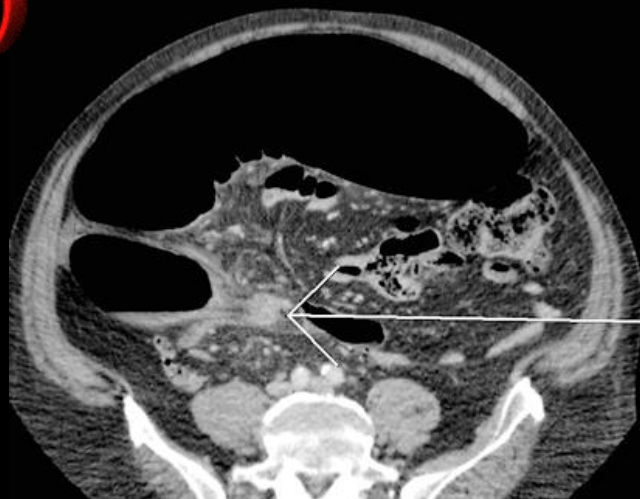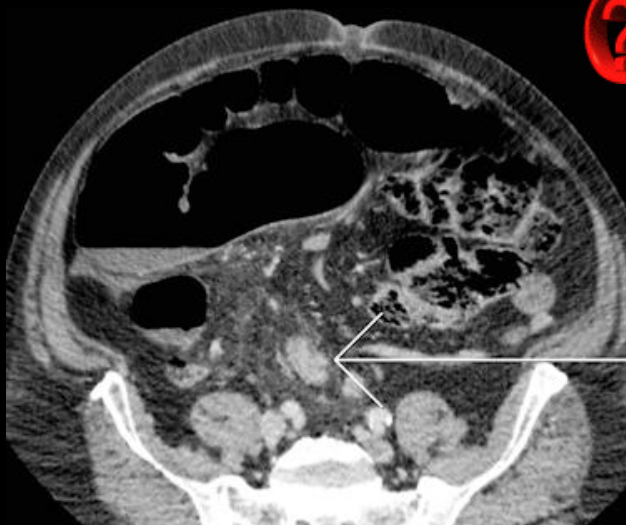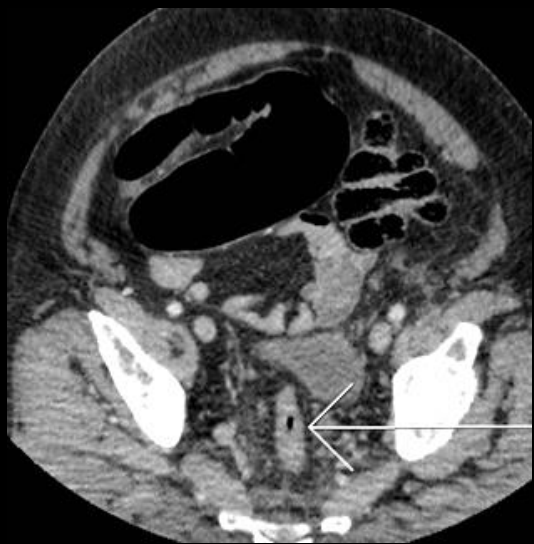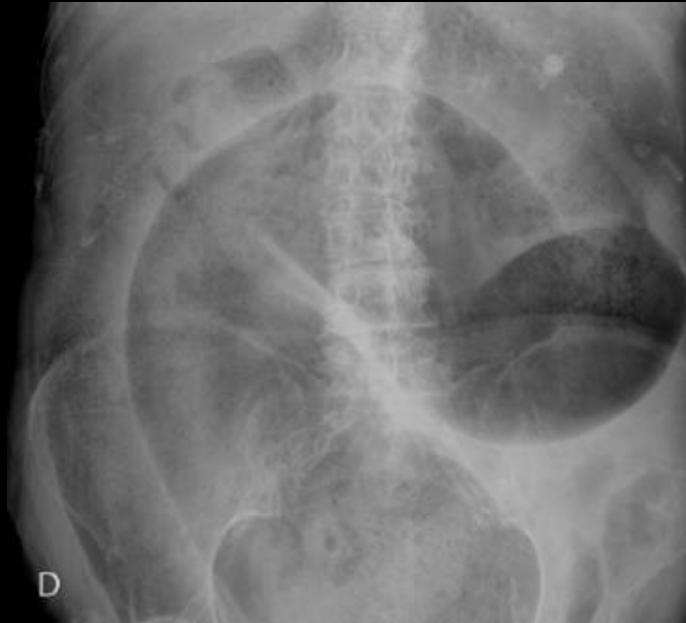
homme 83 ans , météorisme abdominal douloureux , arrêt des matières et des gaz , vomissements fécaloïdes

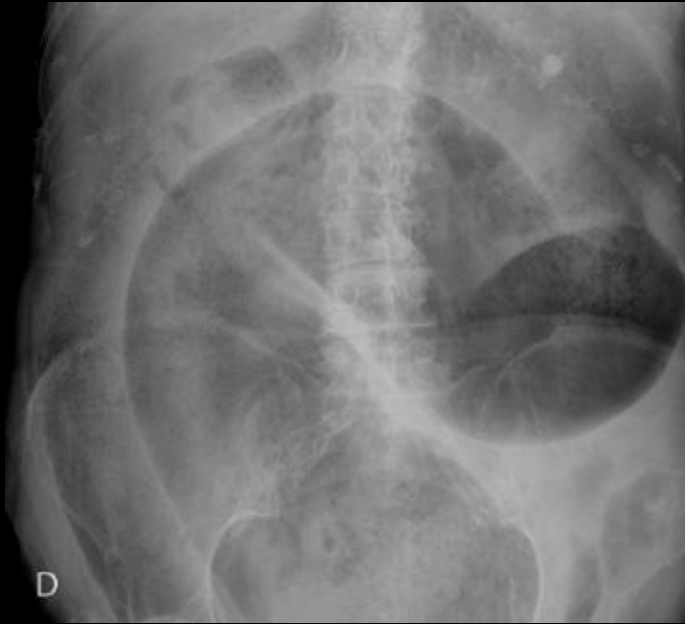


une seule image "en bec d'oiseau"
pas de croisement de jambes à l'étage pelvien

volvulus organo-axial



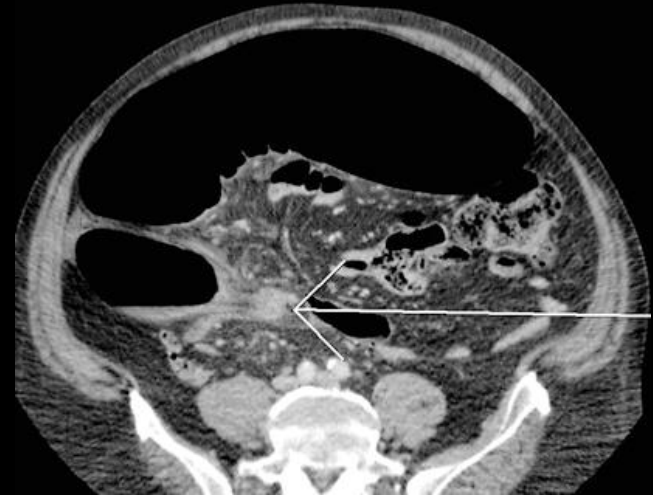
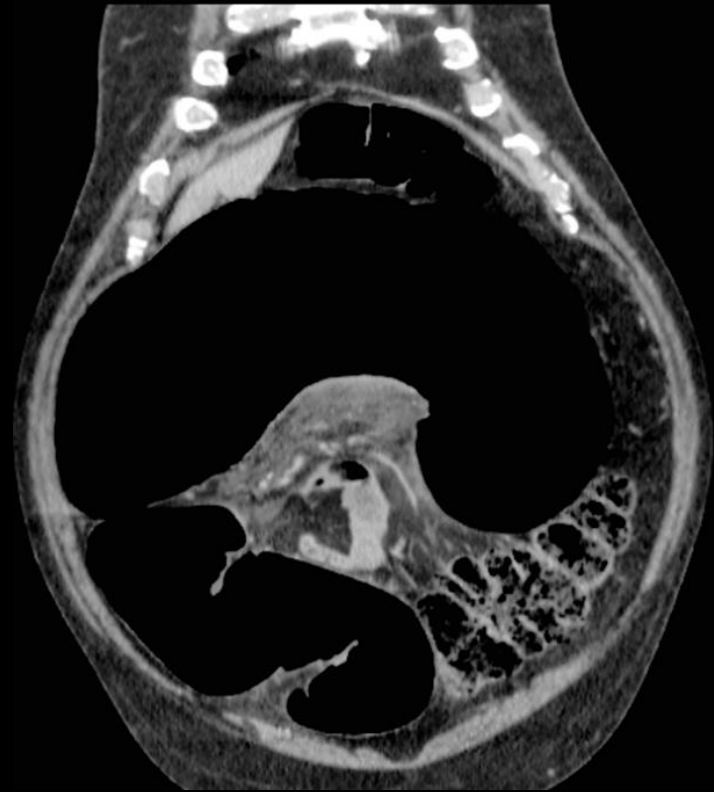


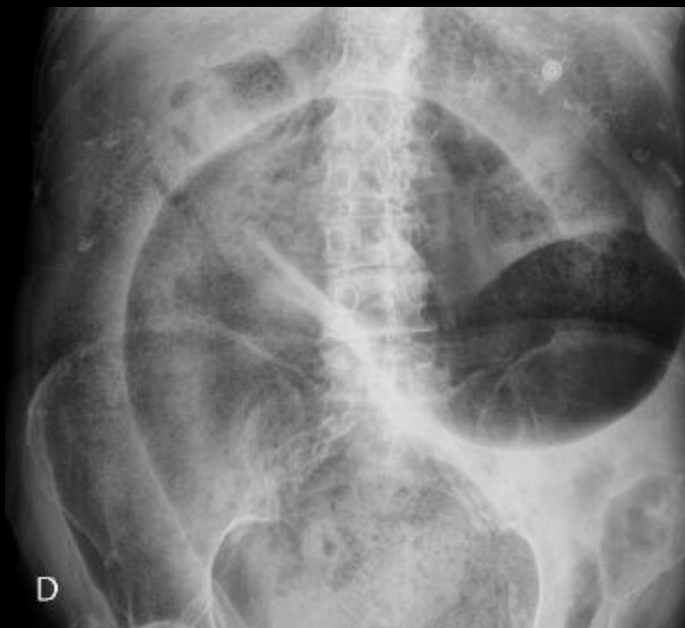


- pas de "grain de café"
- pas de northern exposure sign
- pas de croisement des jambes qui restent distantes au niveau pelvien

-

**volvulus organo-axial
du sigmoïde**

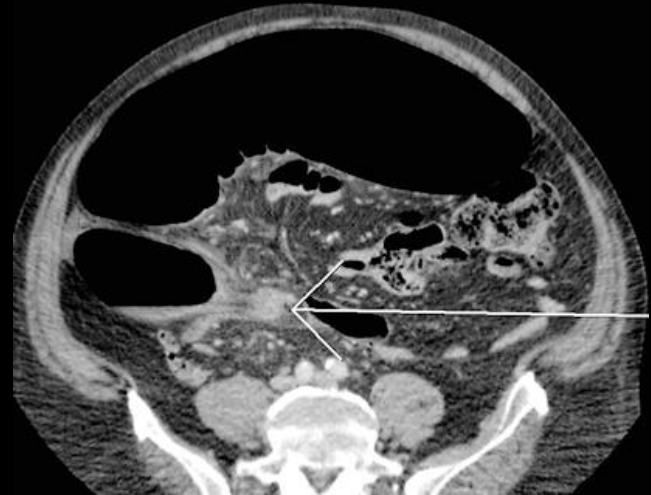
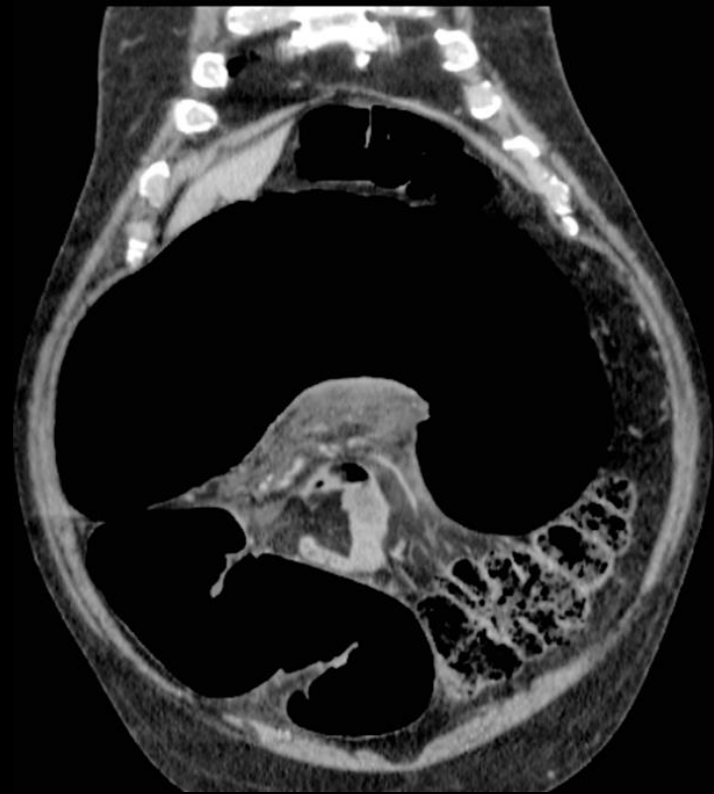




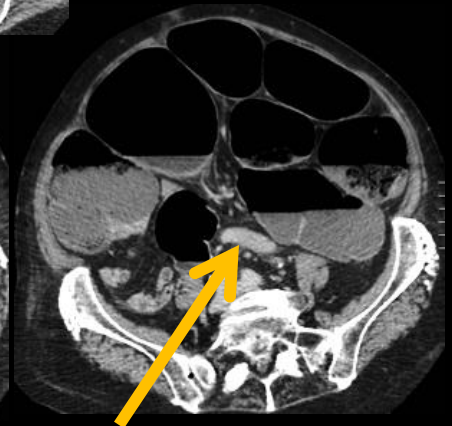
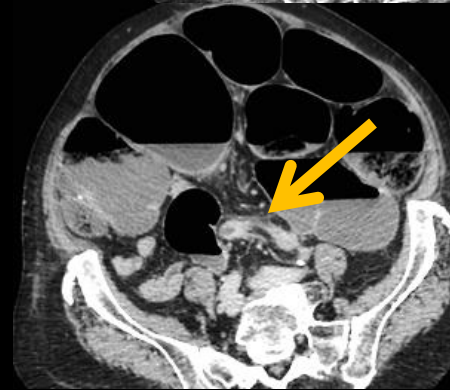
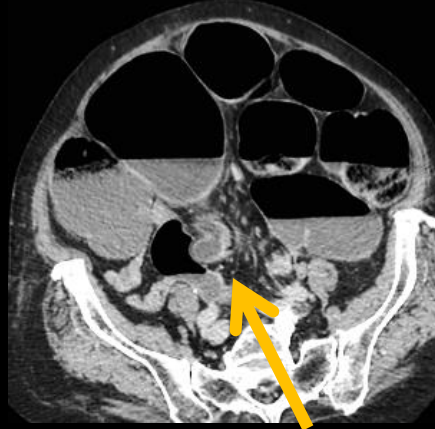
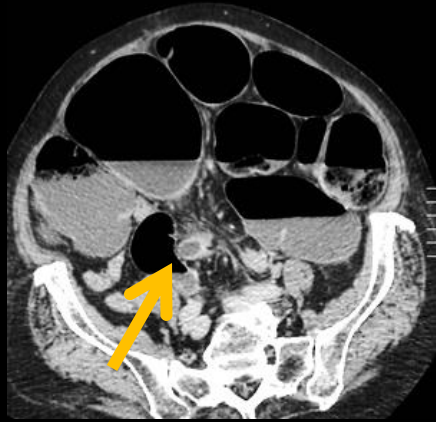
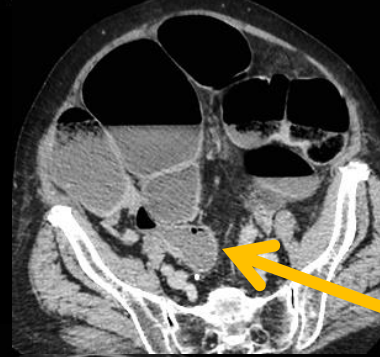
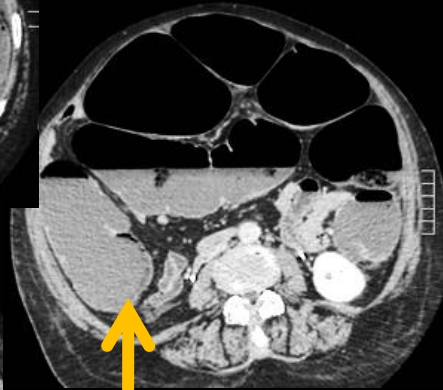
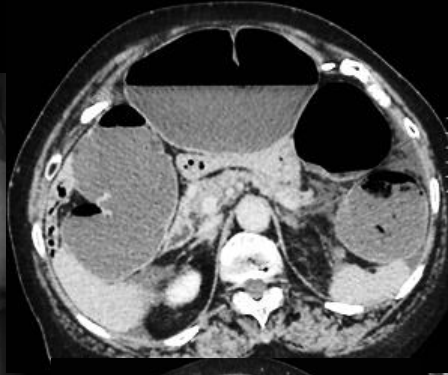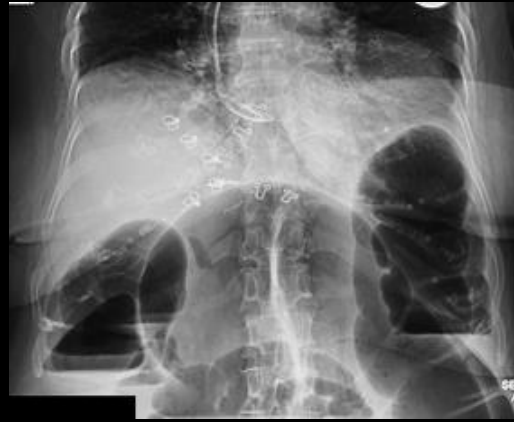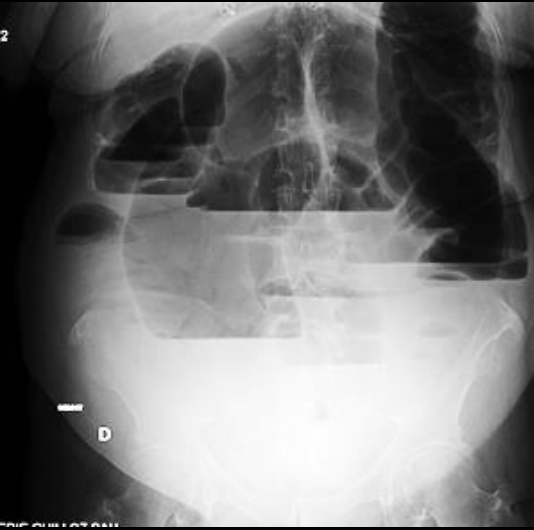- pas de "grain de café"
- pas de northern exposure sign
- pas de croisement des jambes qui restent distantes au niveau pelvien

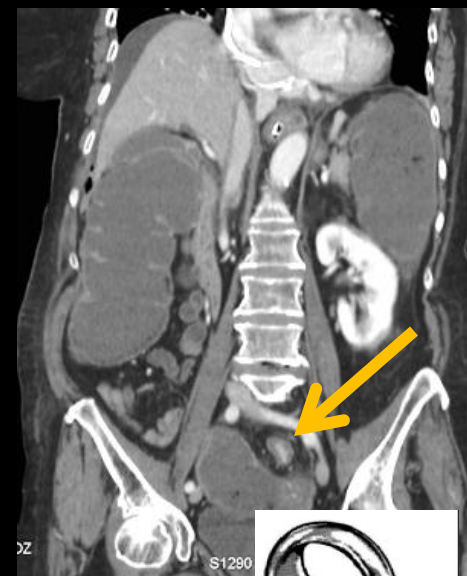
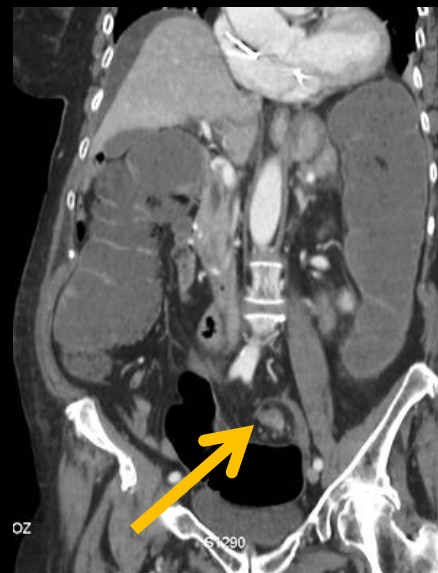
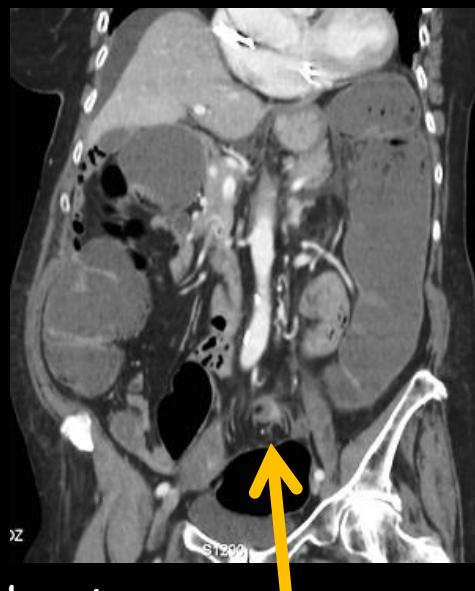
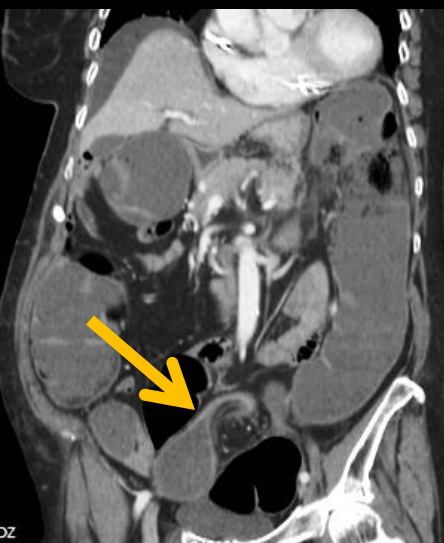
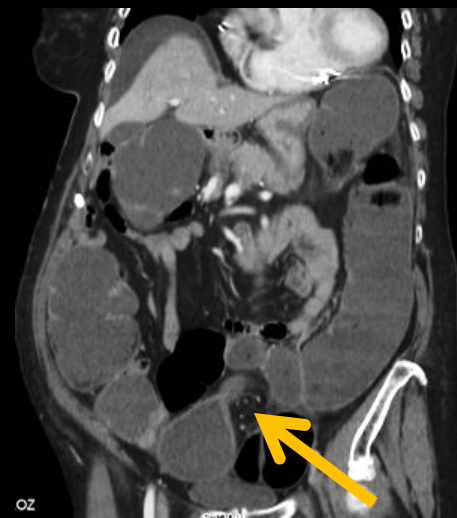
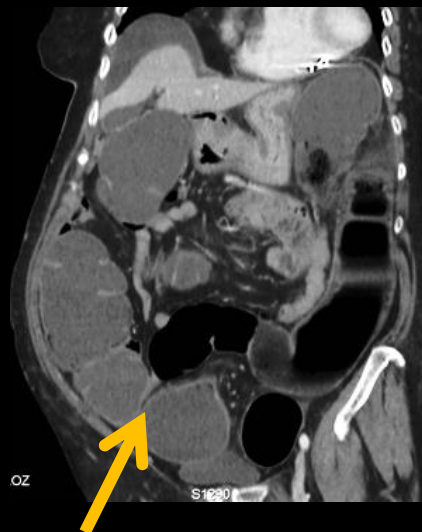
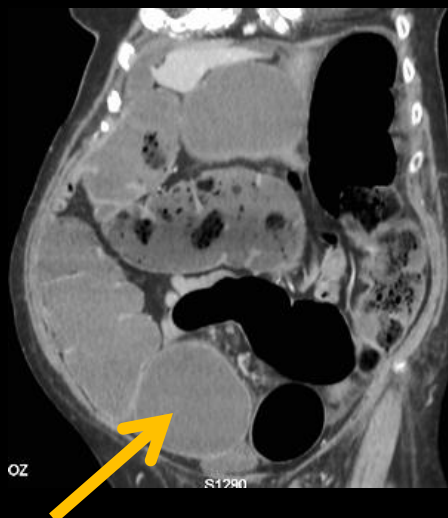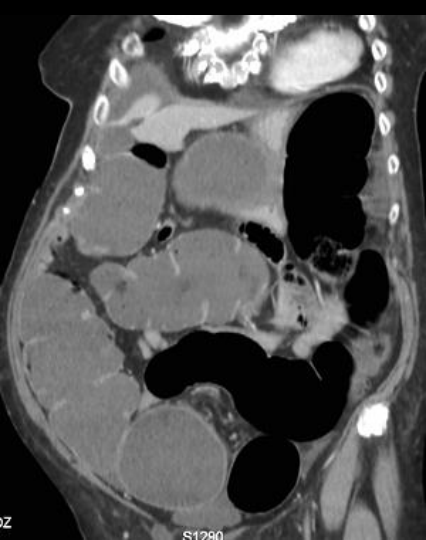-

**volvulus organo-axial
du sigmoïde**



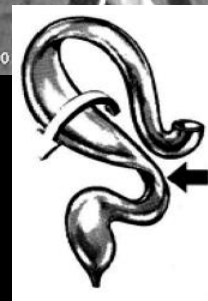femme 85 ans , météorisme abdominal douloureux , arrêt des matières et des gaz , vomissements fécaloïdes



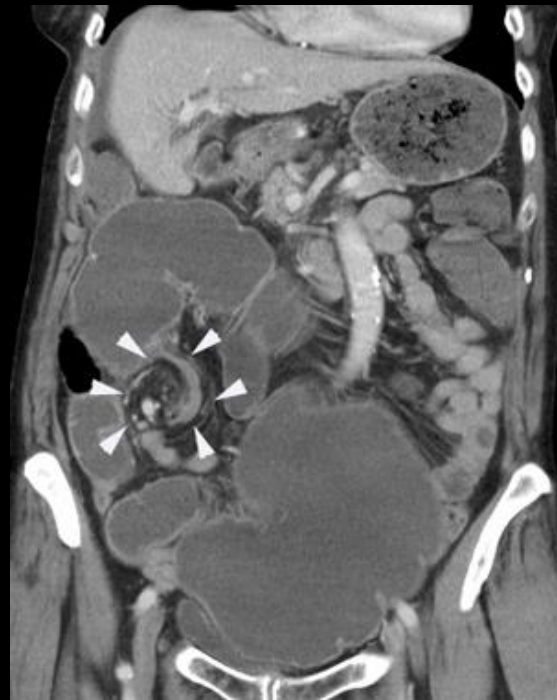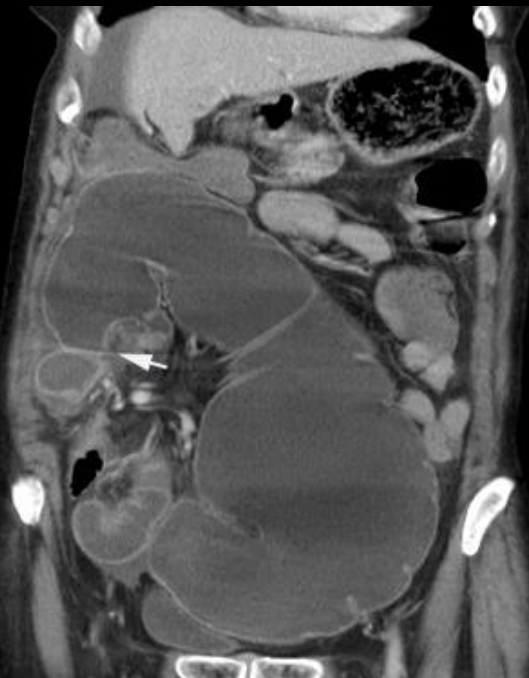
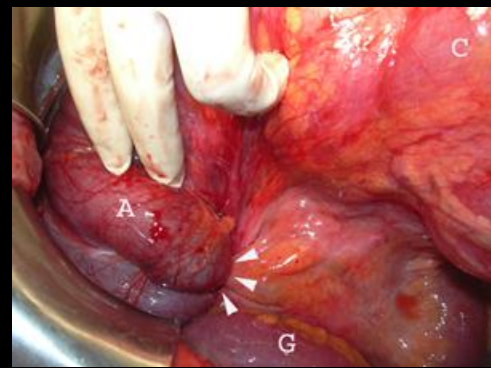
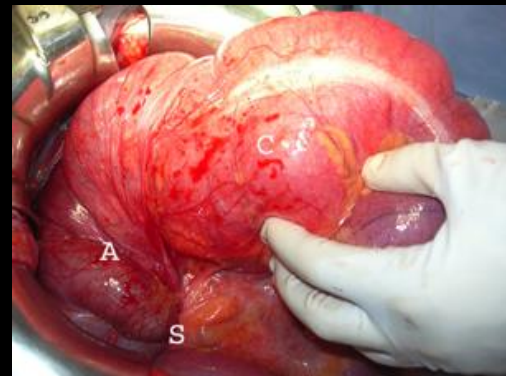
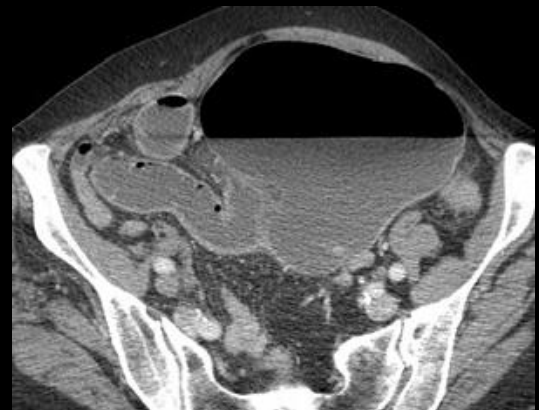
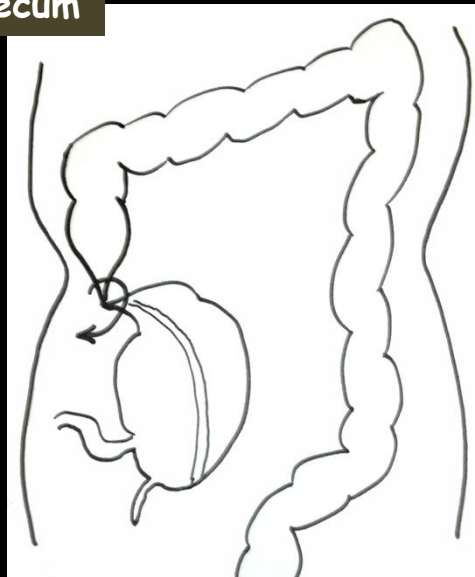
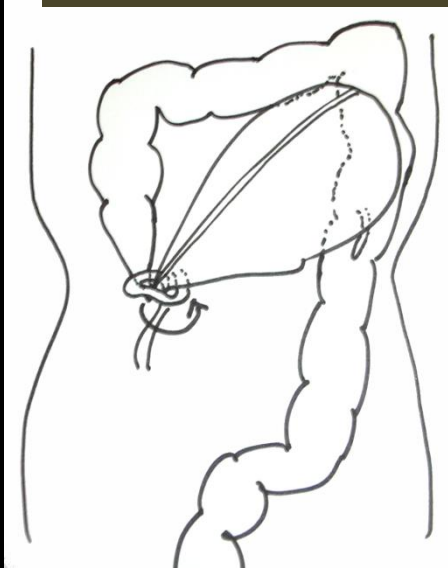


northern exposure sign absent
pas de grain de café
pas de croisement des jambes à l'étage pelvien
dolichocolon gauche "traversant l'abdomen"

volvulus organo-axial du sigmoïde



3-1-1-2 volvulus du caecum



obs. Dr LE chirurgien , Montargis

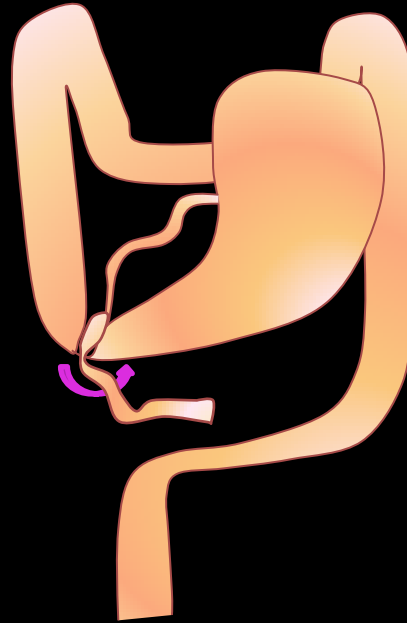
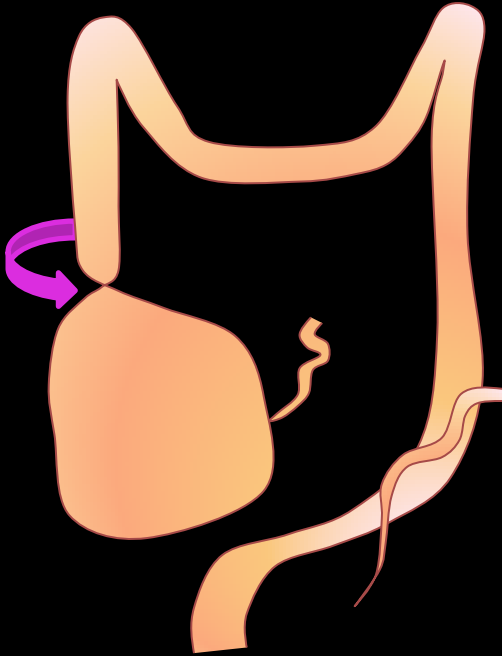
PLE@ch-montargis.fr

volvulus méésentérico-axial du caecum

Volvulus du caecum : type organo-axial

Volvulus du caecum : type mésentérico-axial (loop type)

Volvulus du caecum : type bascule



45 %

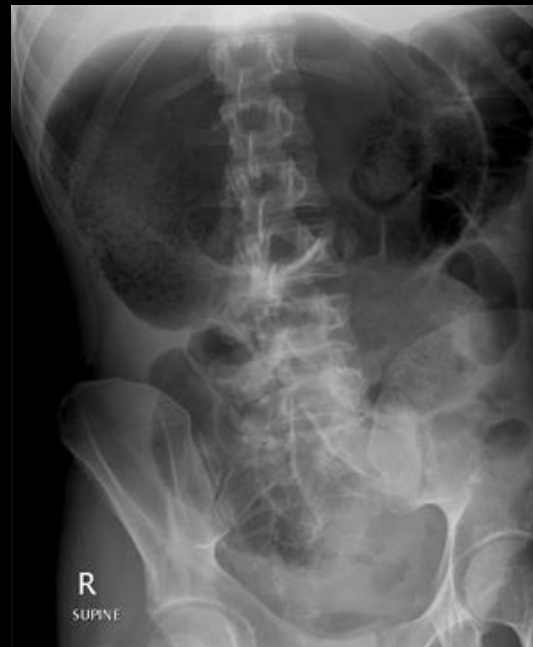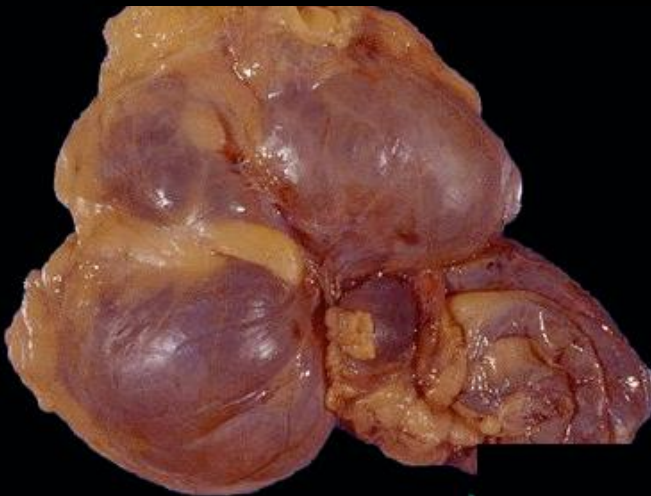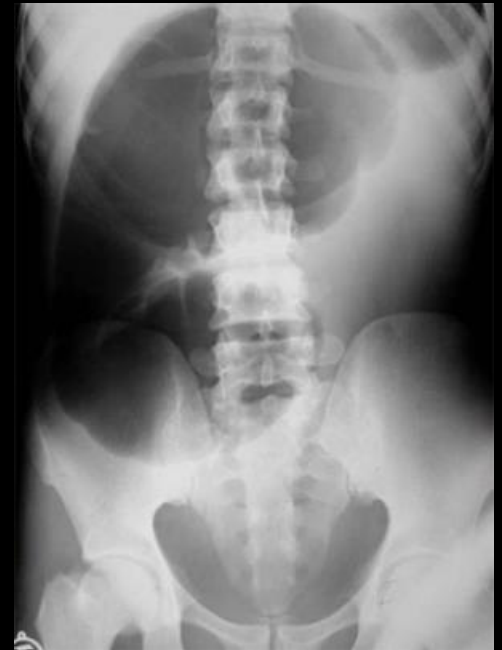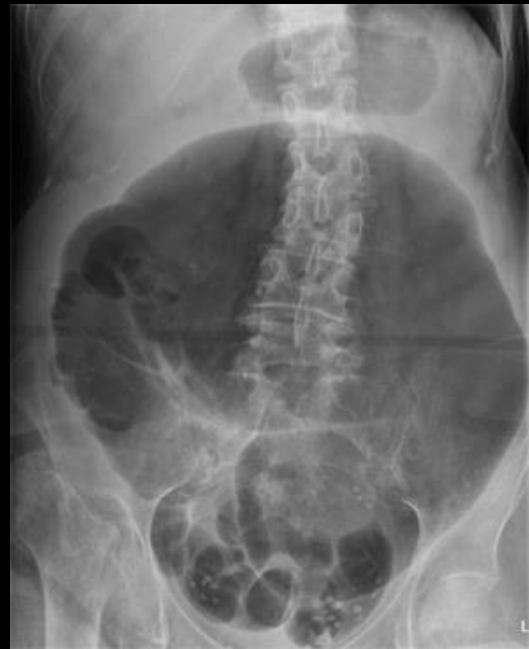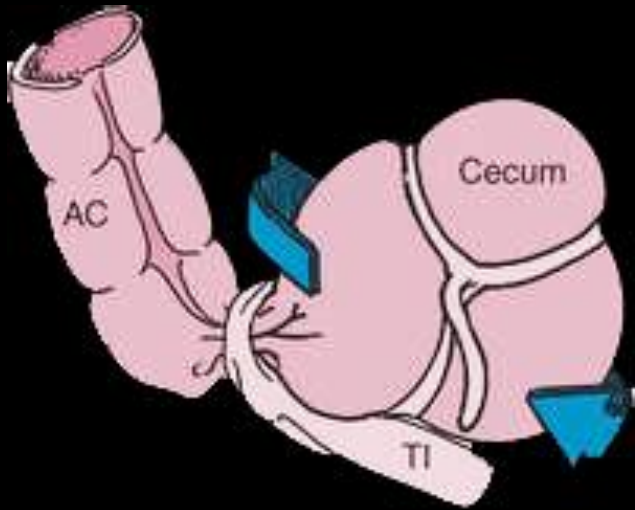
Caecum reste en fosse iliaque droite

45 %

**Bascule antérieure du caecum qui se projette à gauche.
Iléon entoure souvent le caecum**

10%

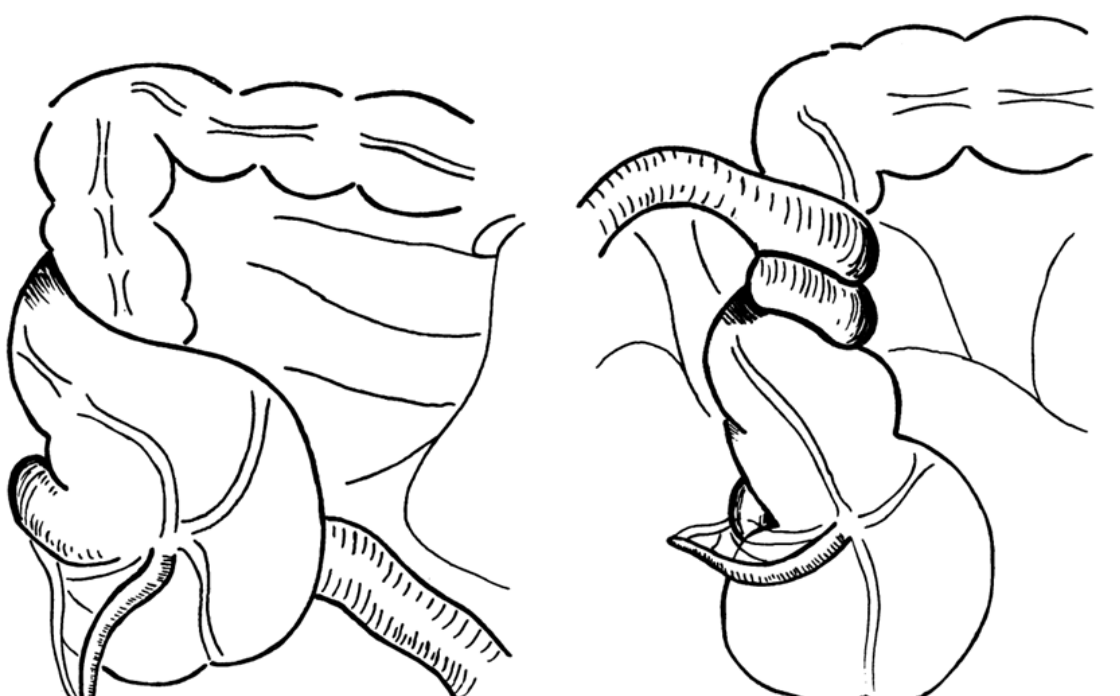
**Pas de torsion
Simple bascule antérieure**



**volvulus caecal
mésentérico
axial**

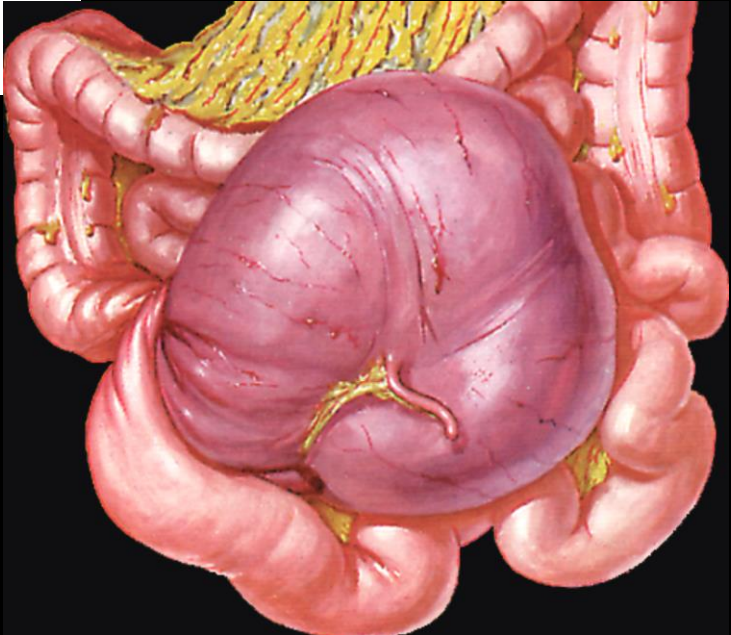
loop type

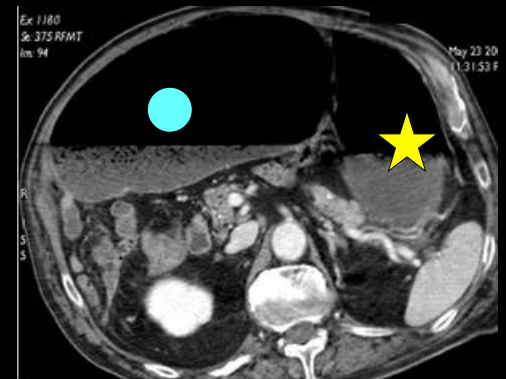
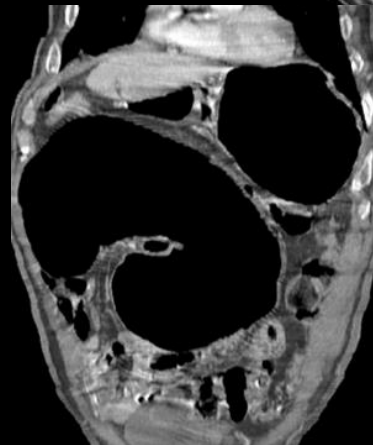
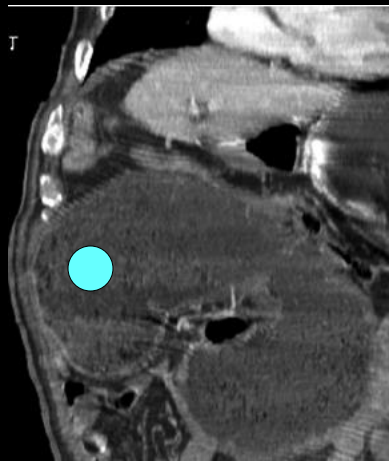
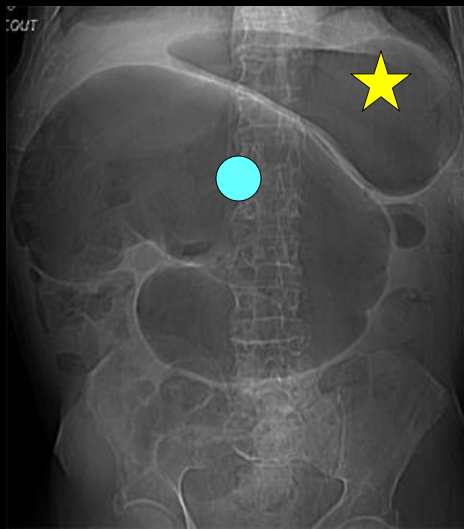
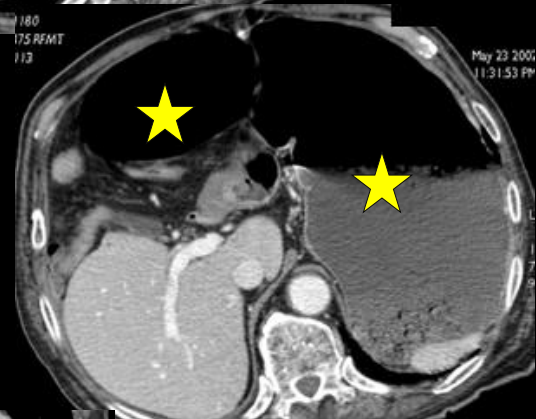
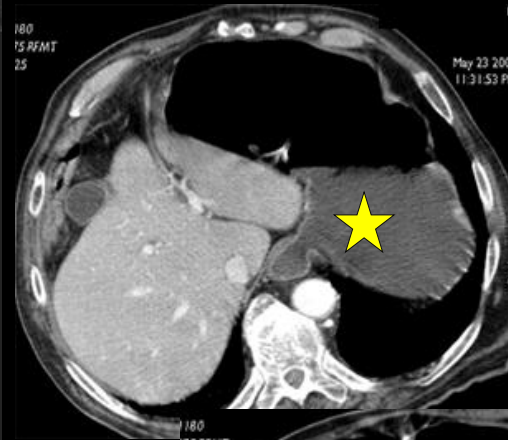
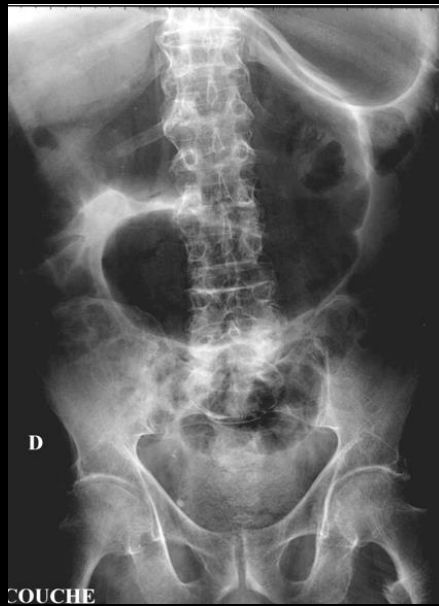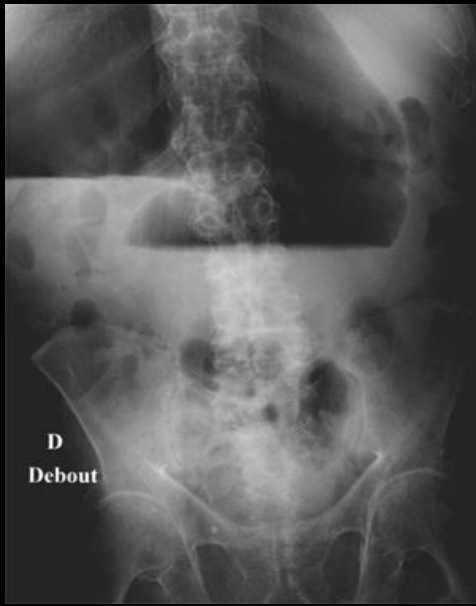
le plus fréquent

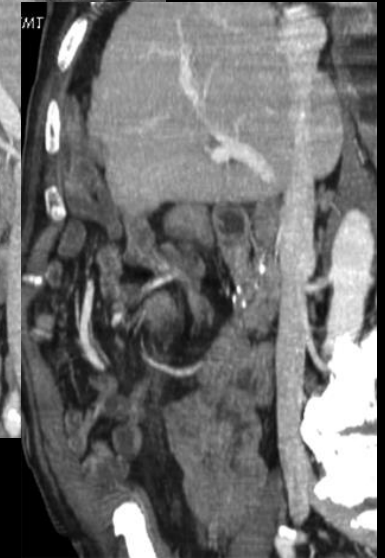
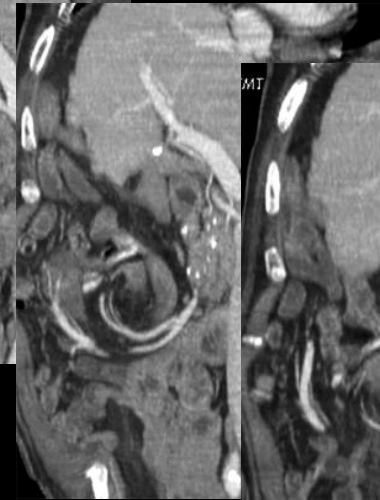
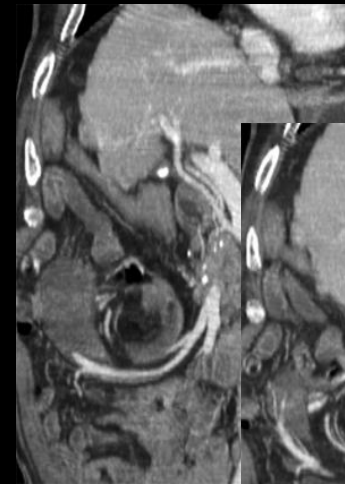
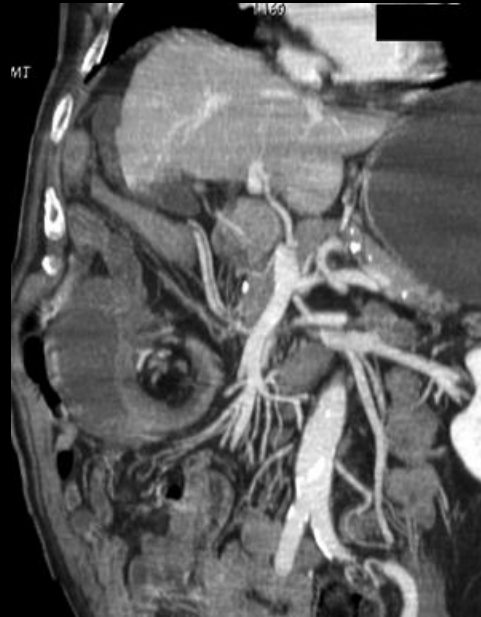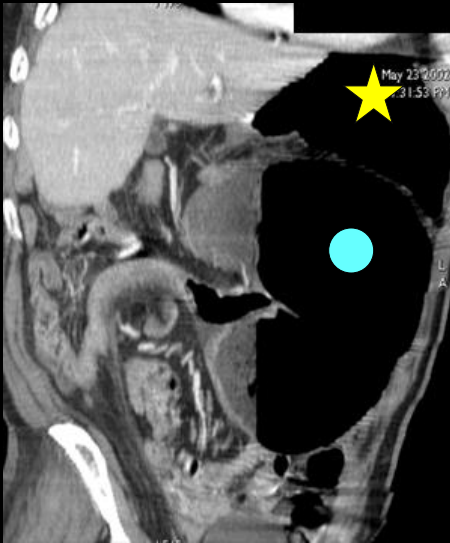
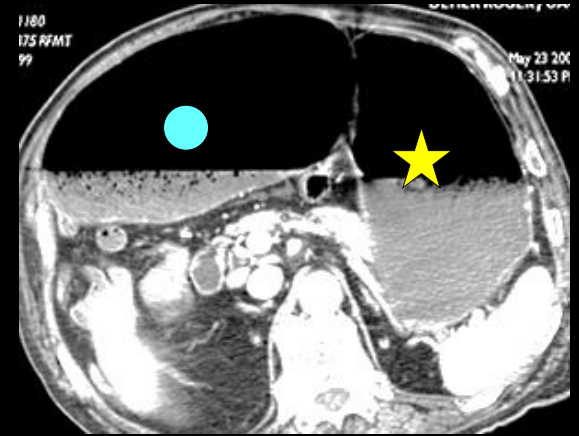
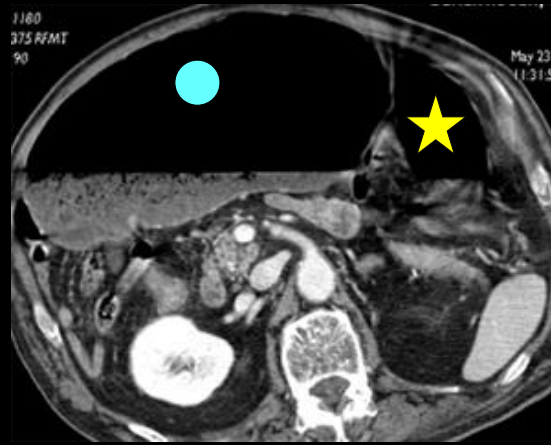

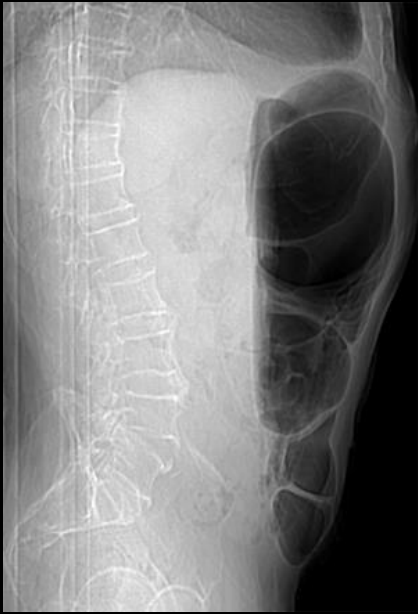
Axial rotation (uncommon).

'Loop' type (commonest).

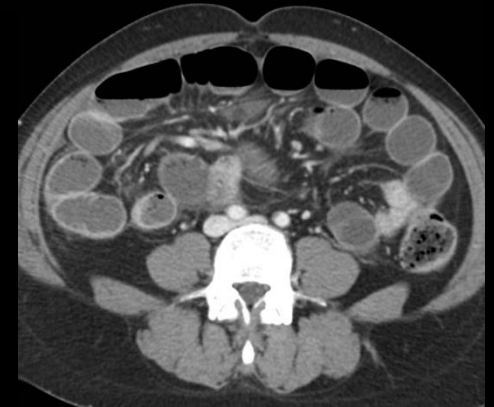
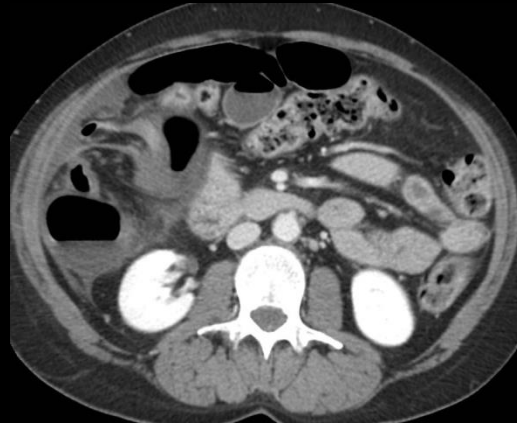
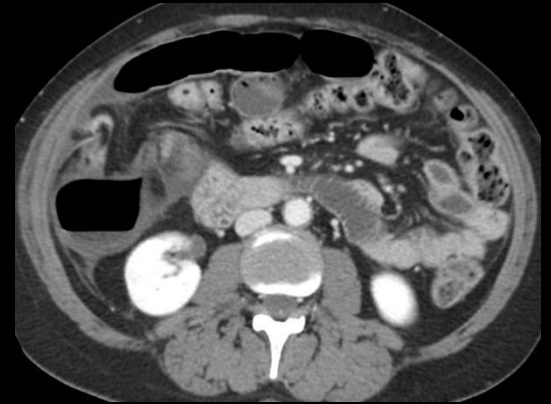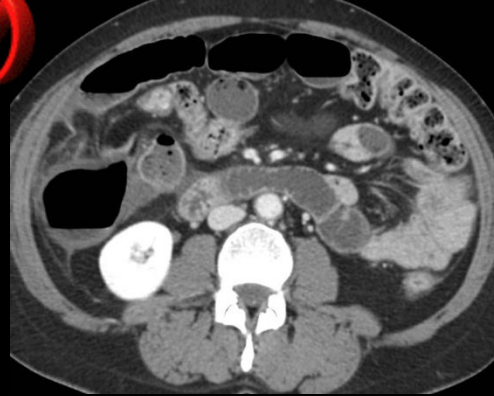
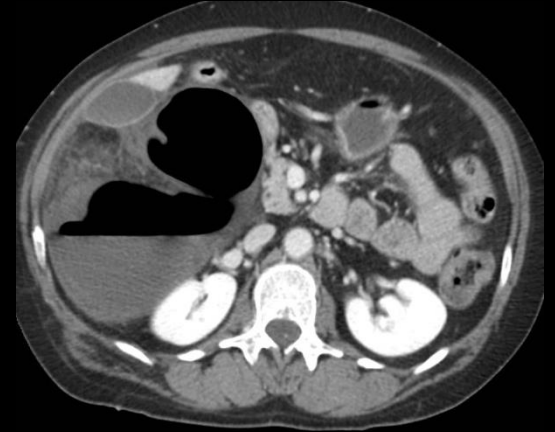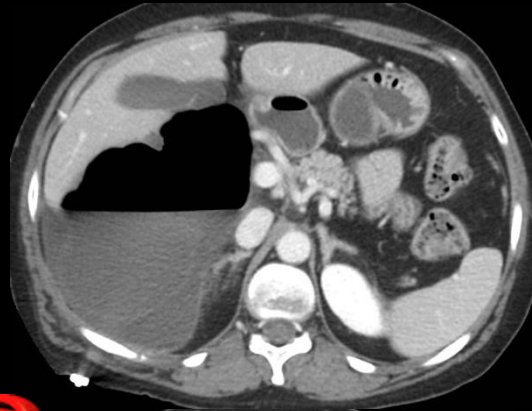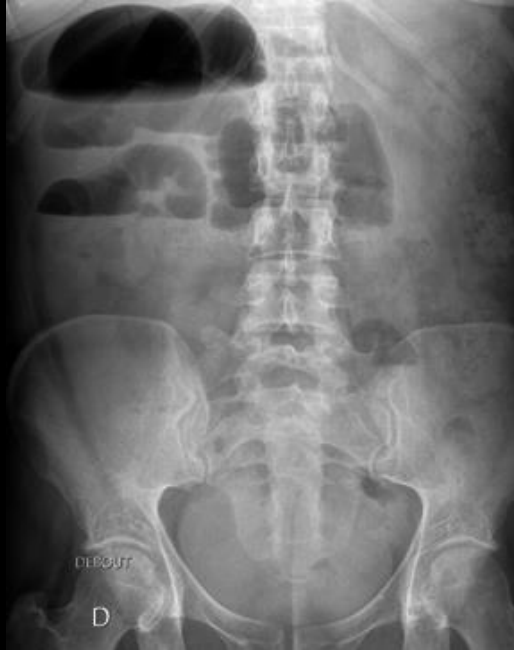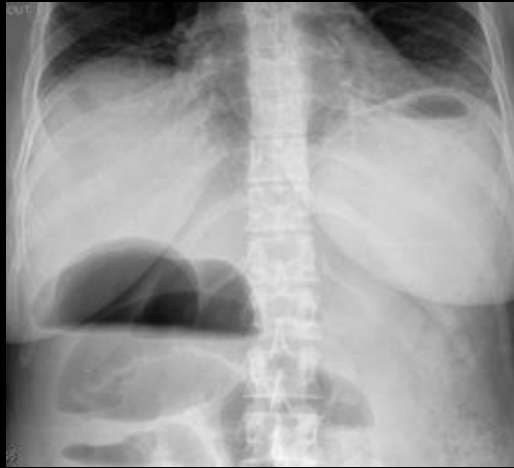


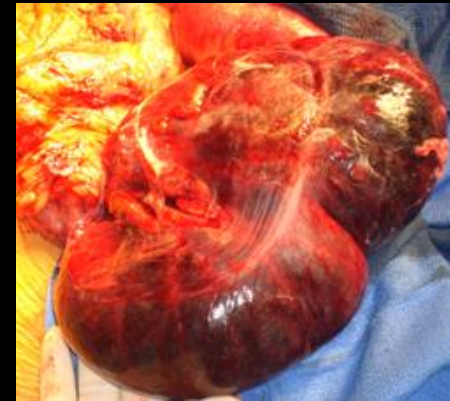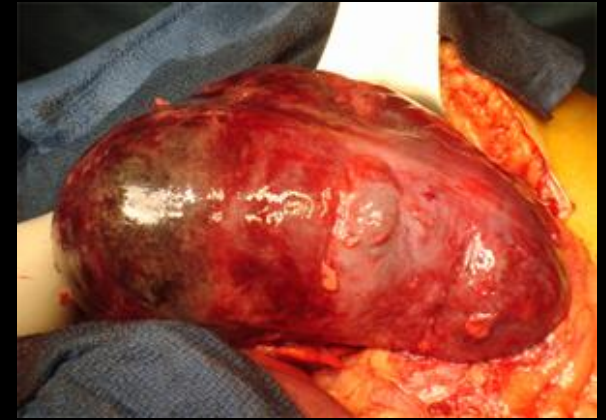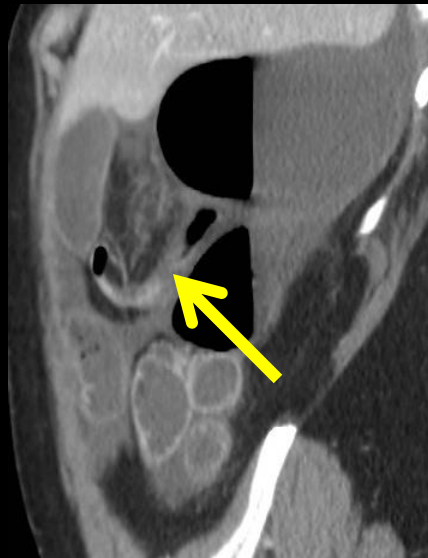
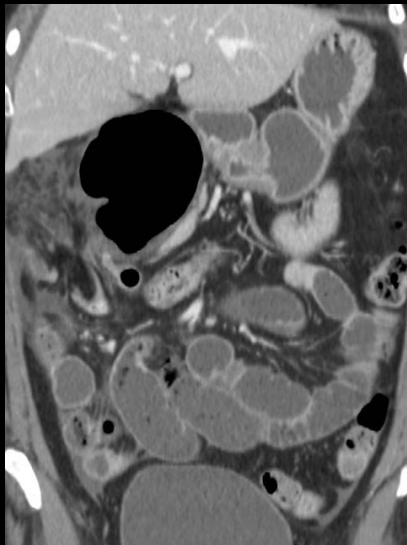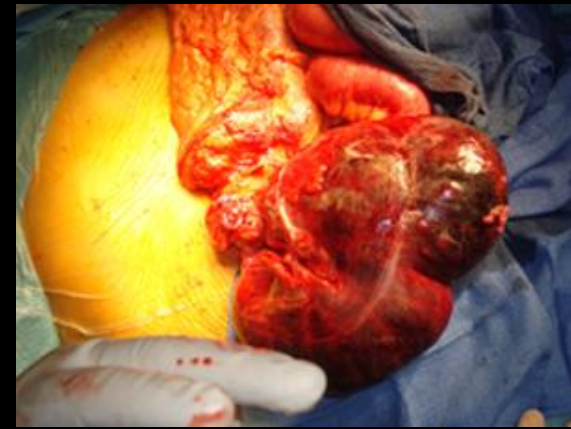
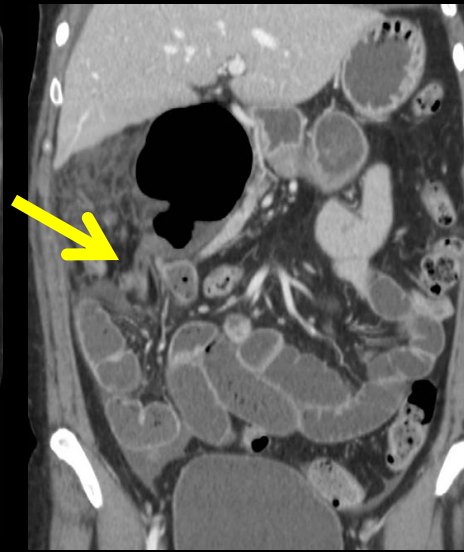
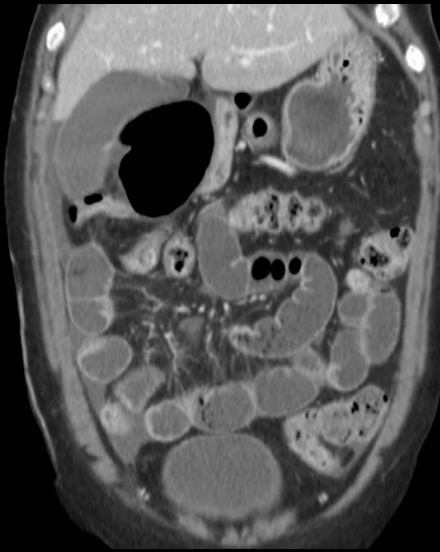




volvulus organo-axial du caecum

femme 43 ans , douleurs abdominales aiguës insomniantes et arrêt des matières et des gaz depuis 48 heures ; intoxication éthylique chronique



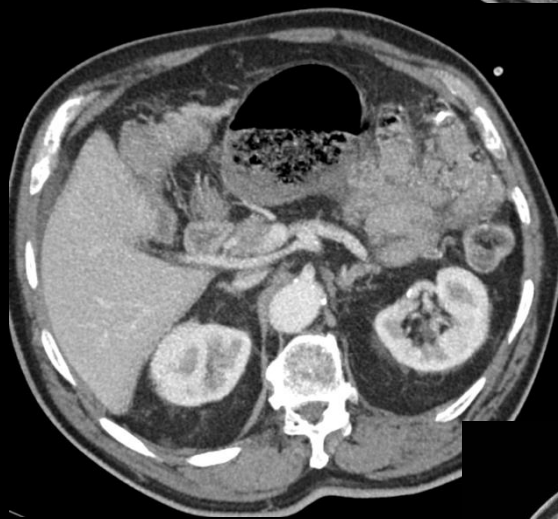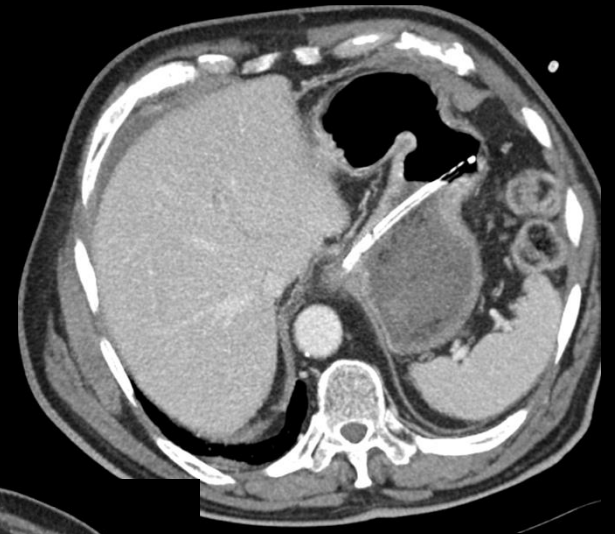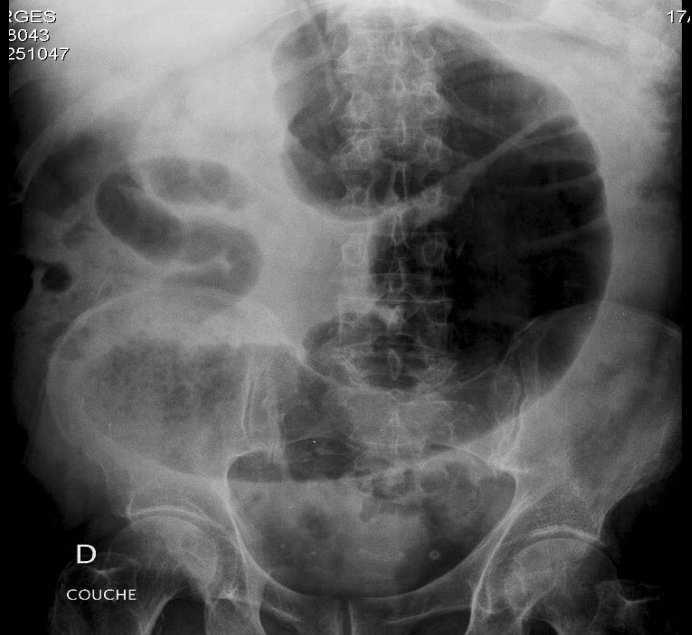


whirl sign sous angulaire droit

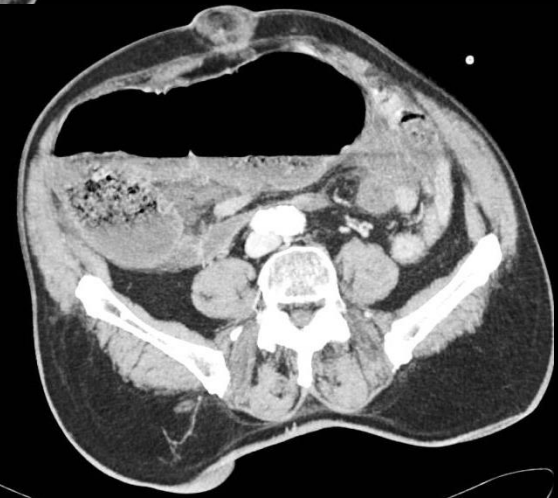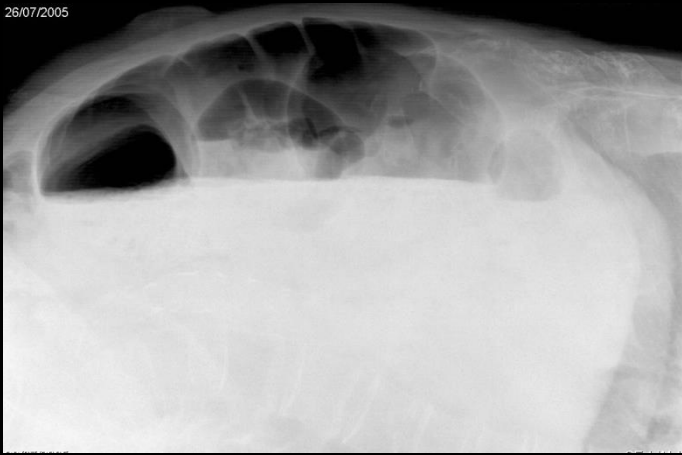volvulus organo -axial du caecum

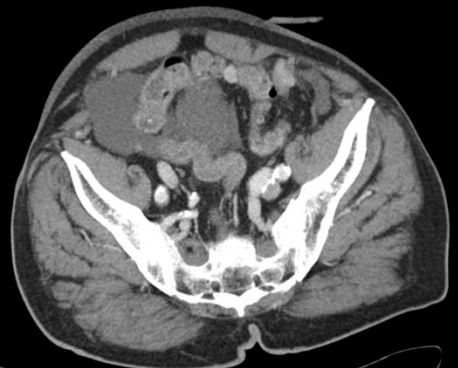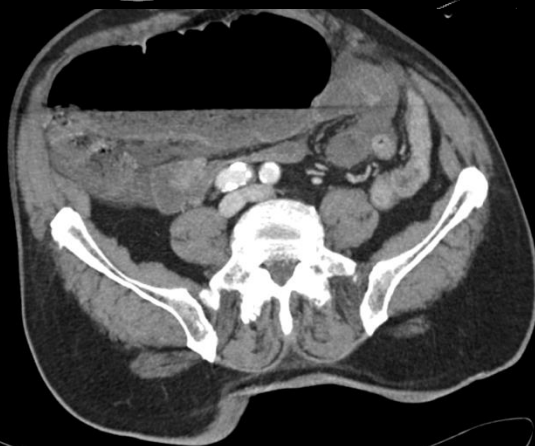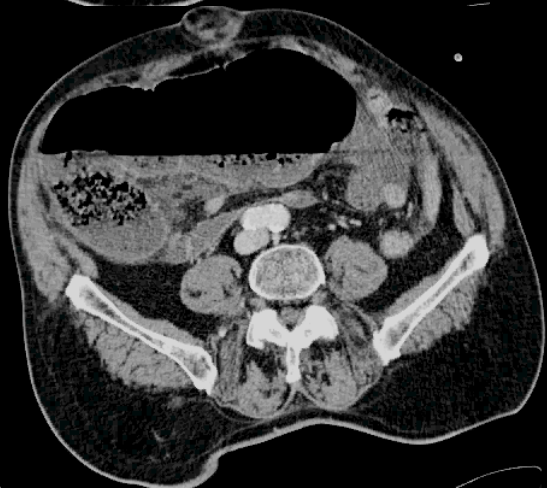
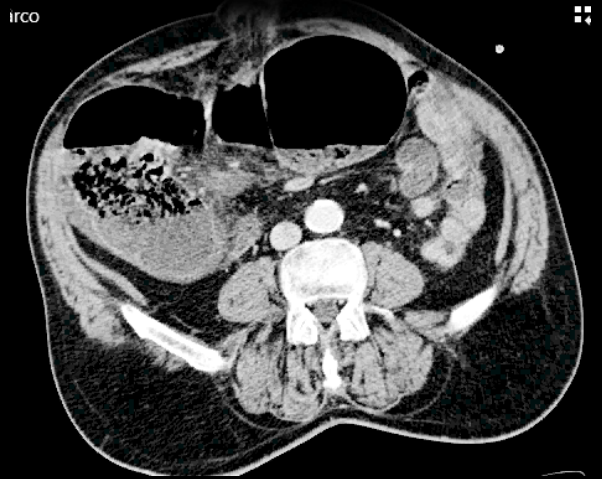
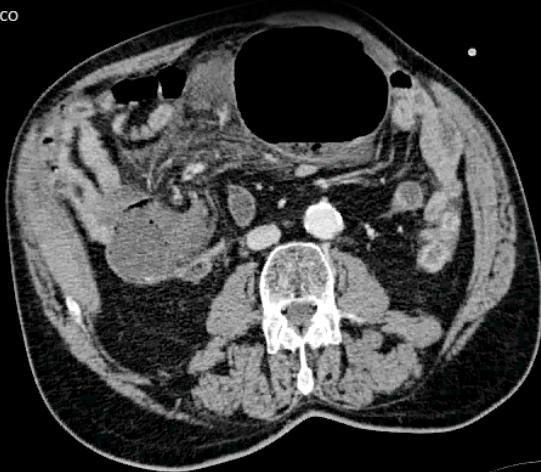
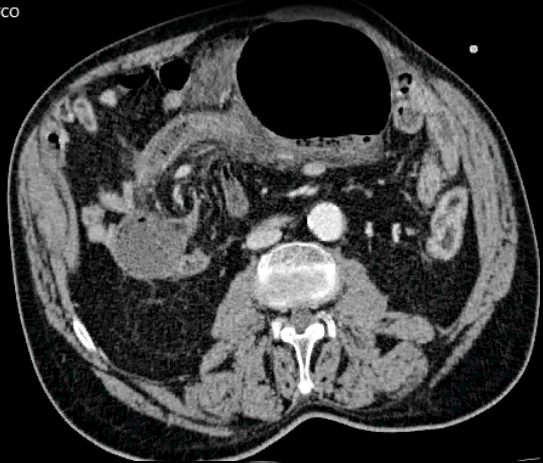
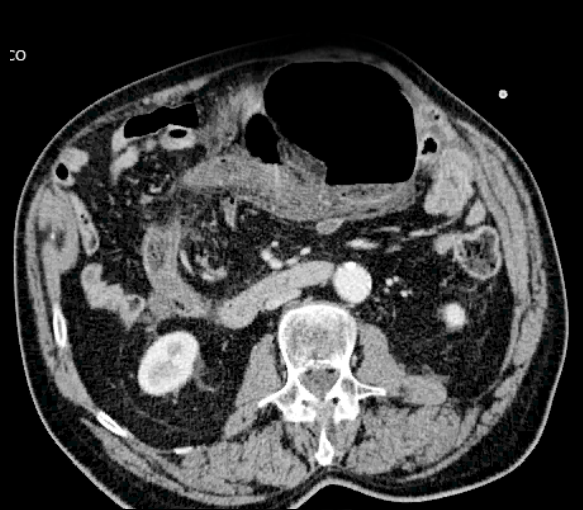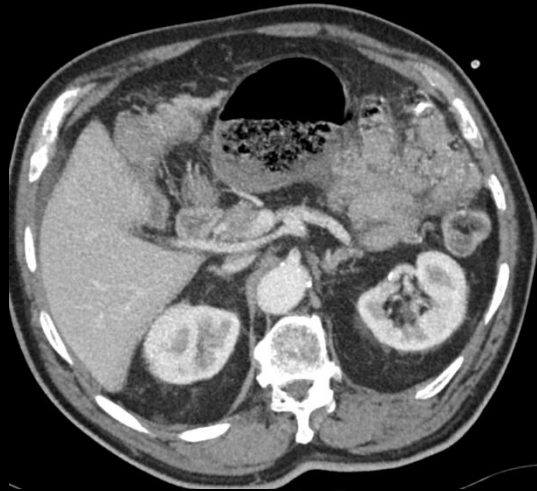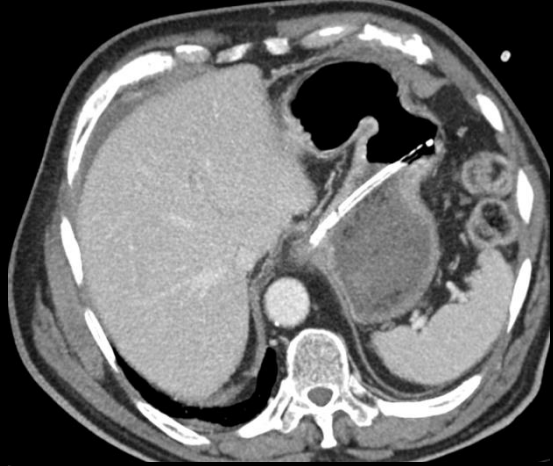GES
8043
251047

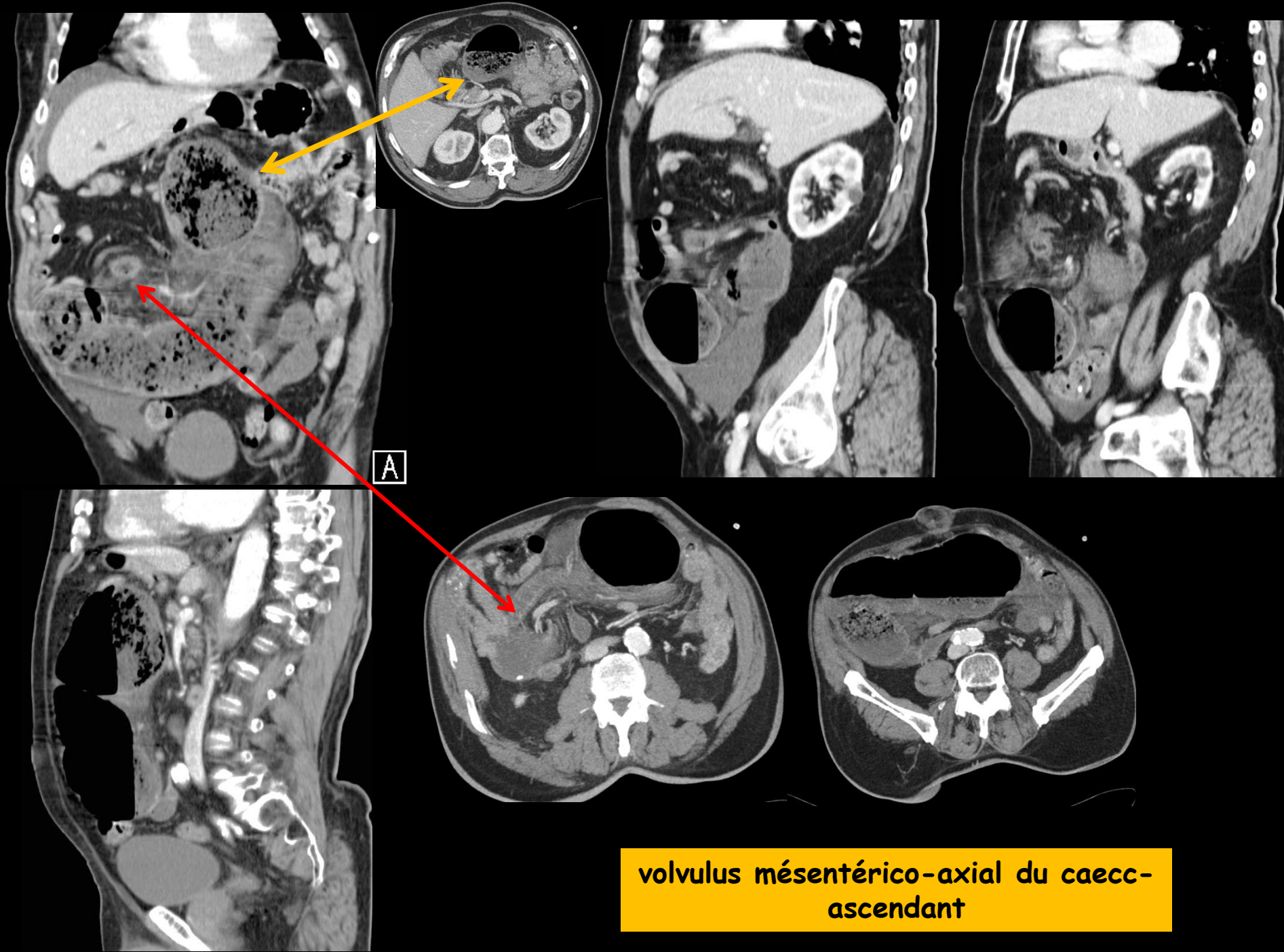
17



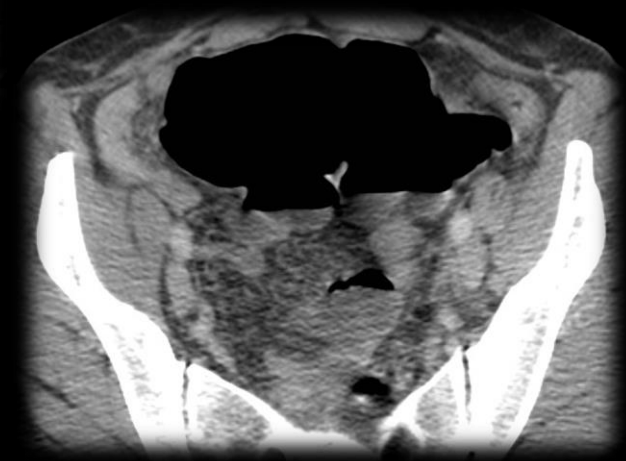
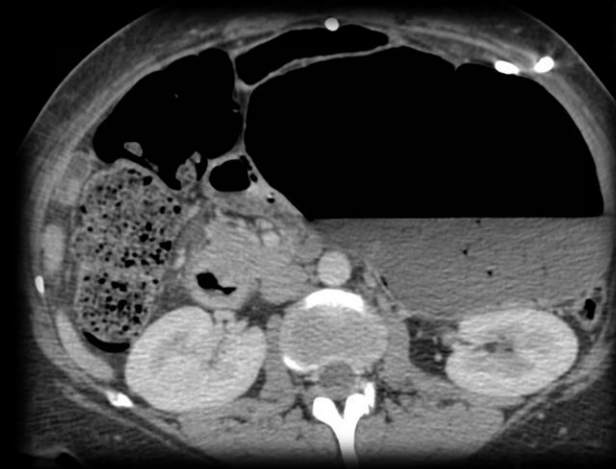
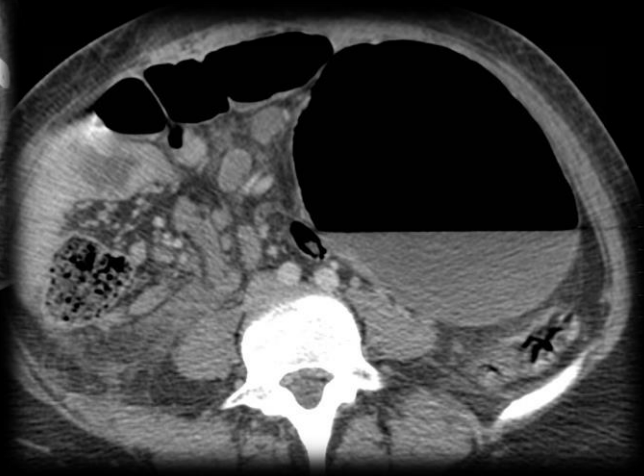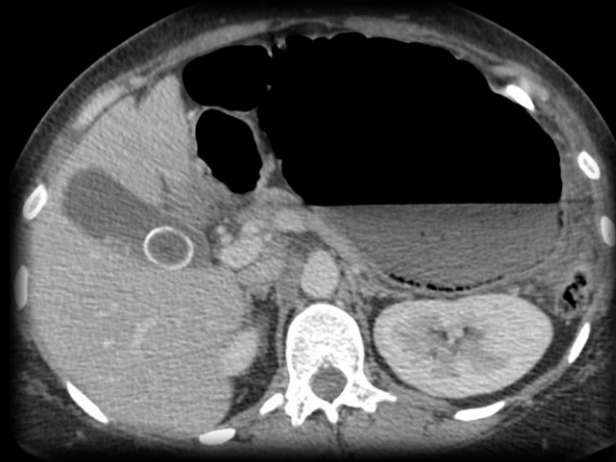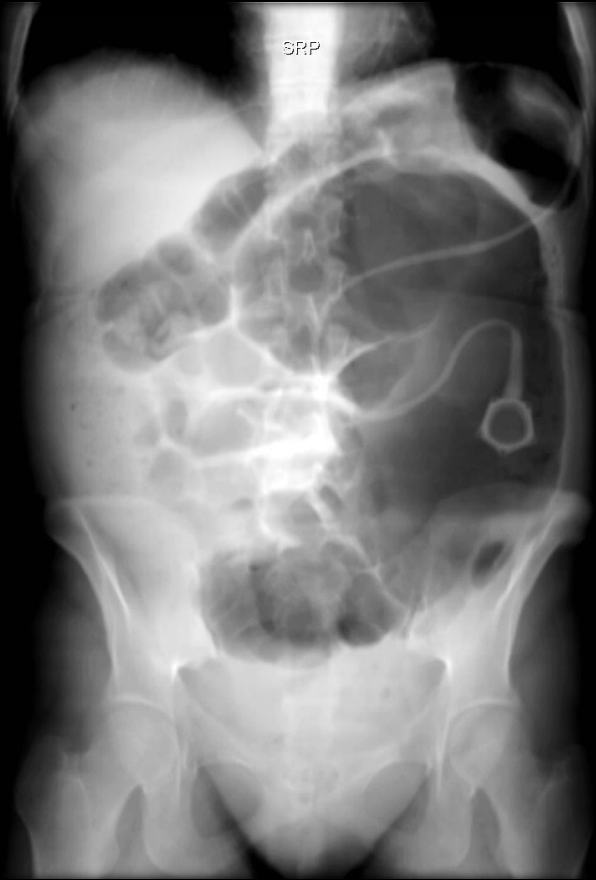28/07/2005

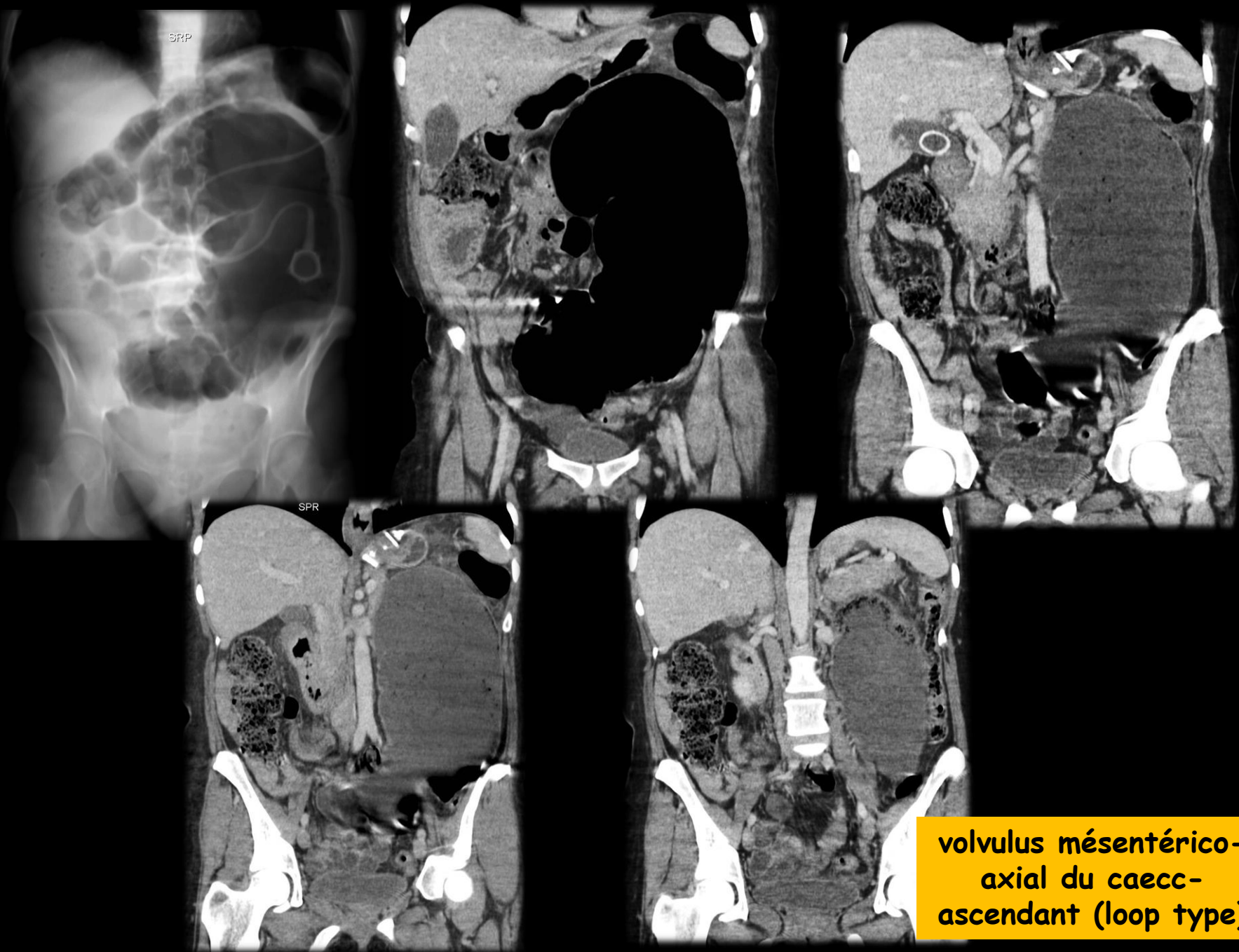






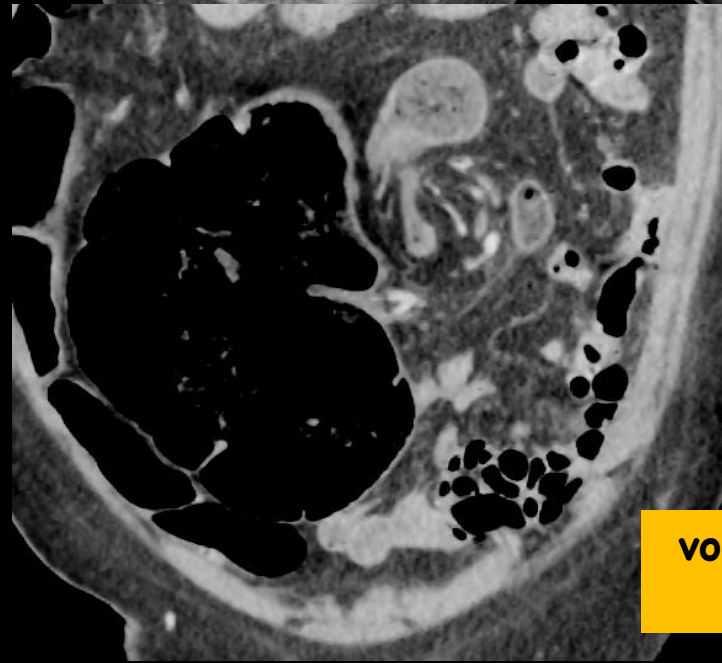
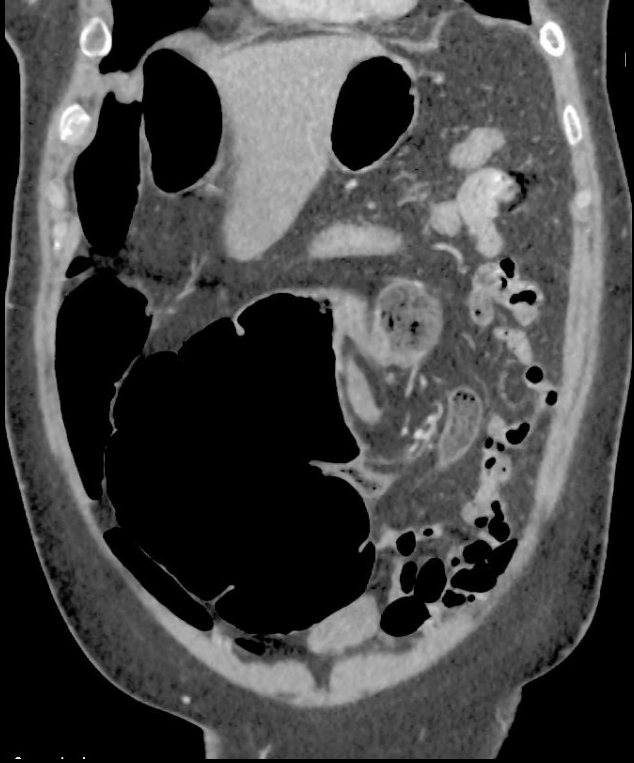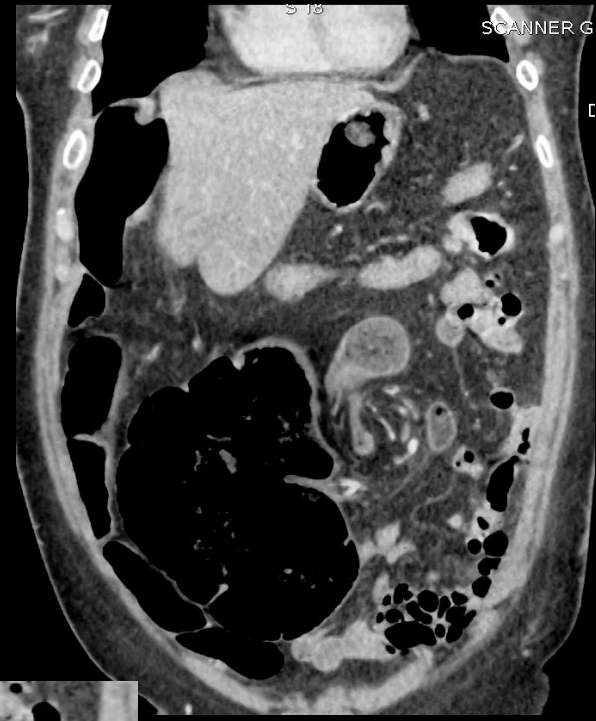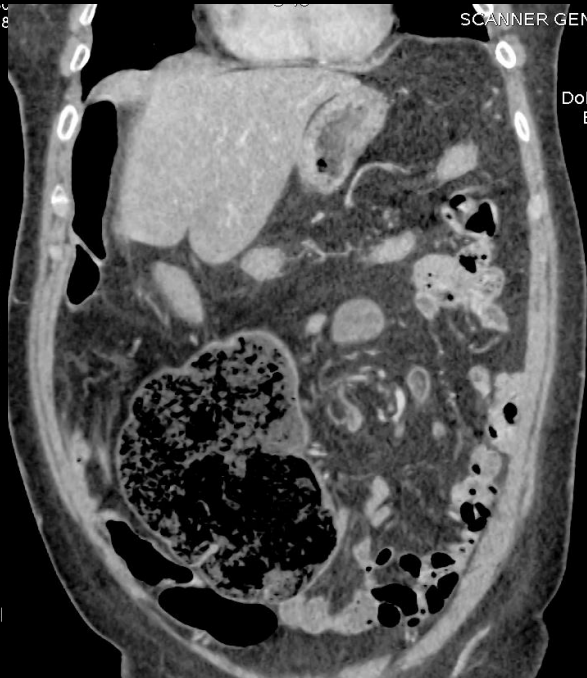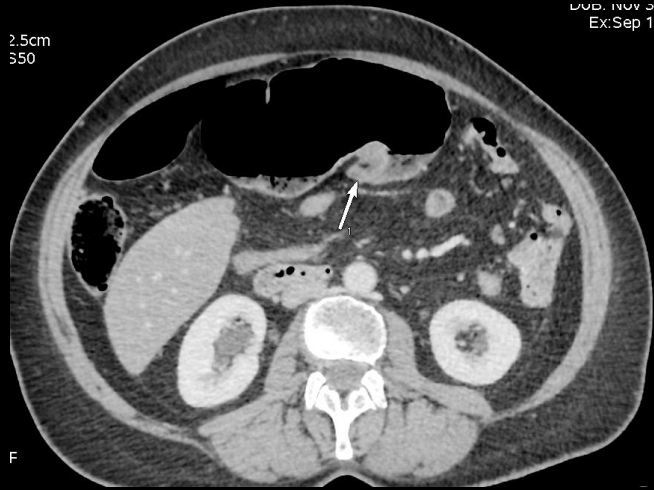**volvulus mésentérico-axial du caec-
ascendant**



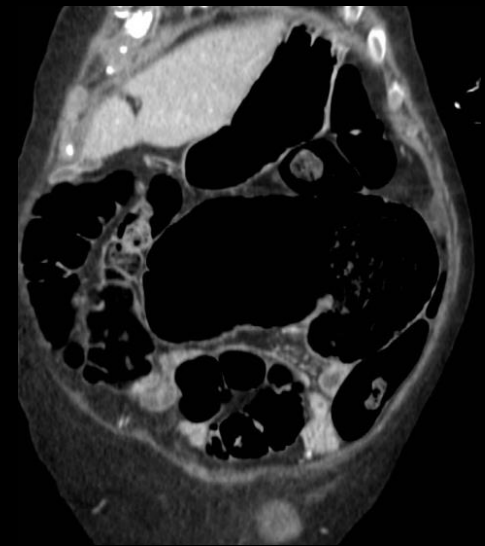
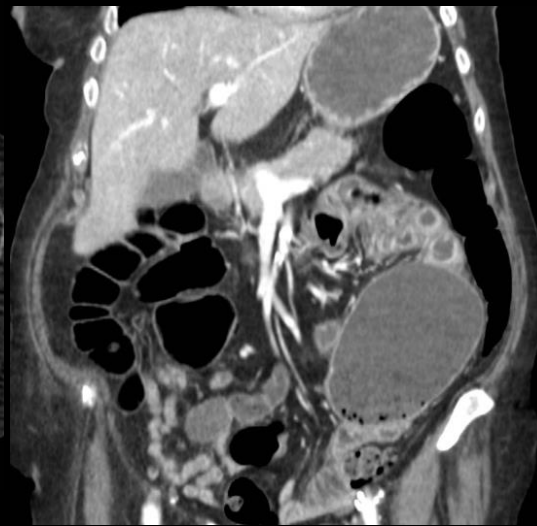
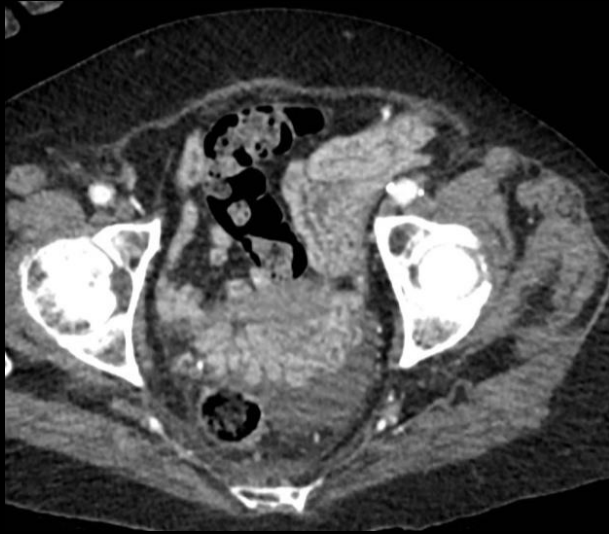
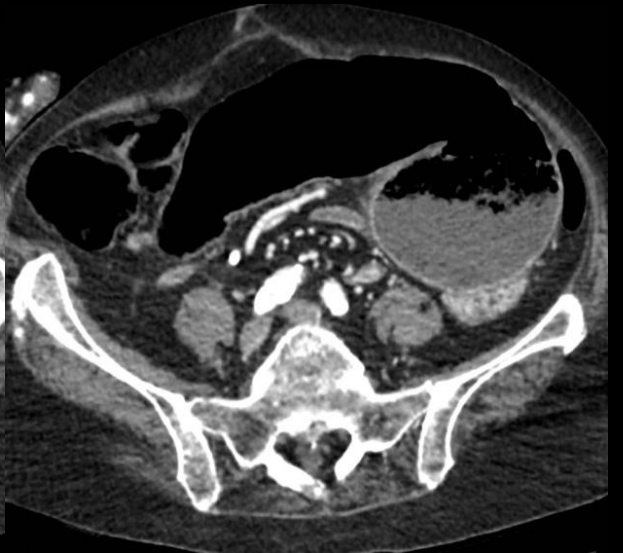
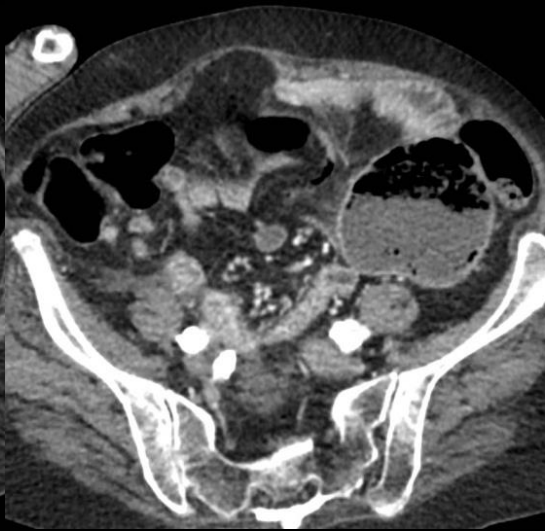
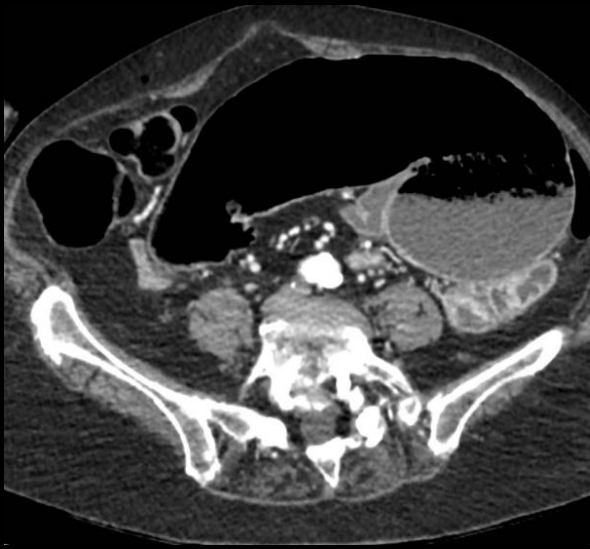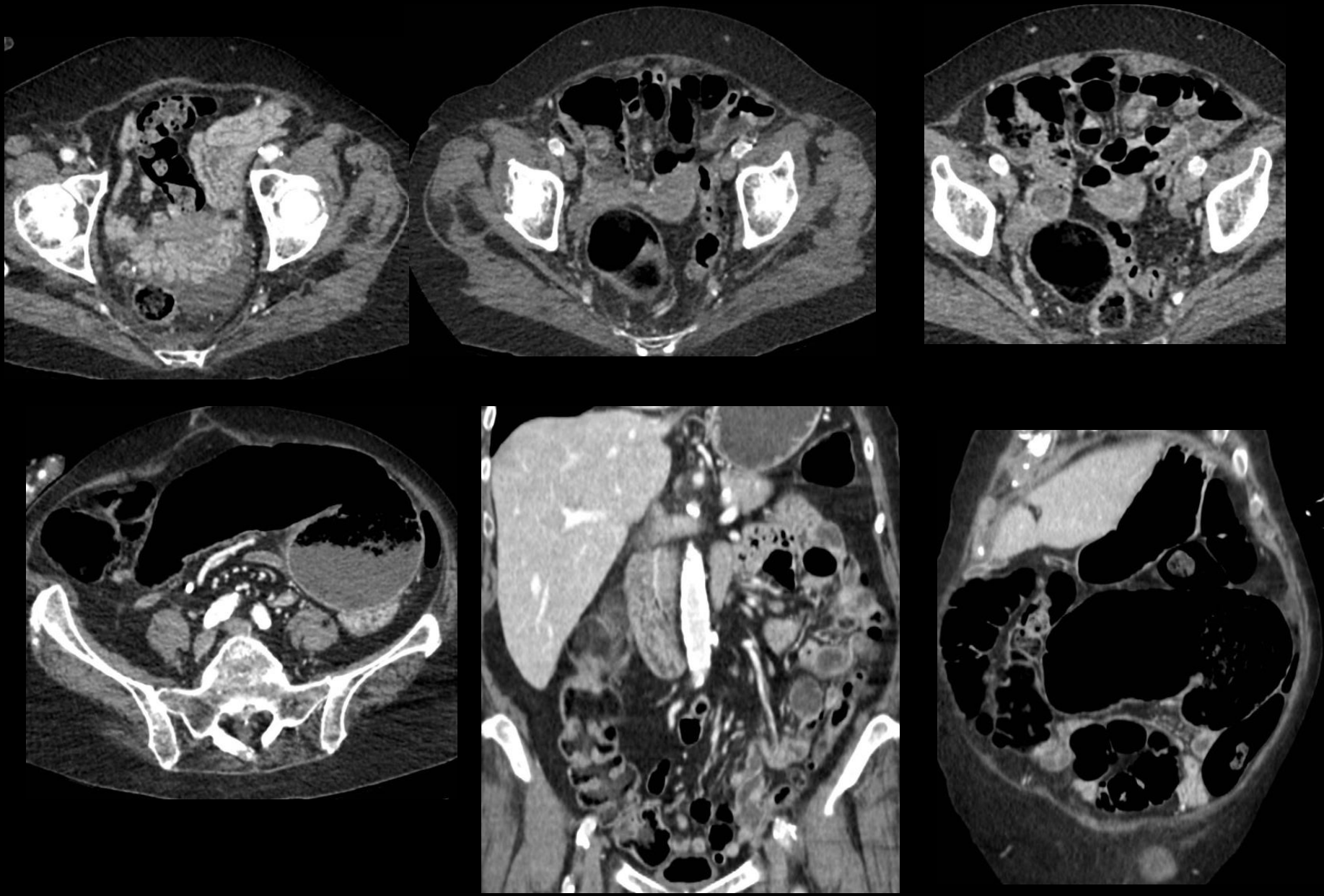
volvulus mésentérico-axial du caecc-ascendant (loop type)

2.5cm
350

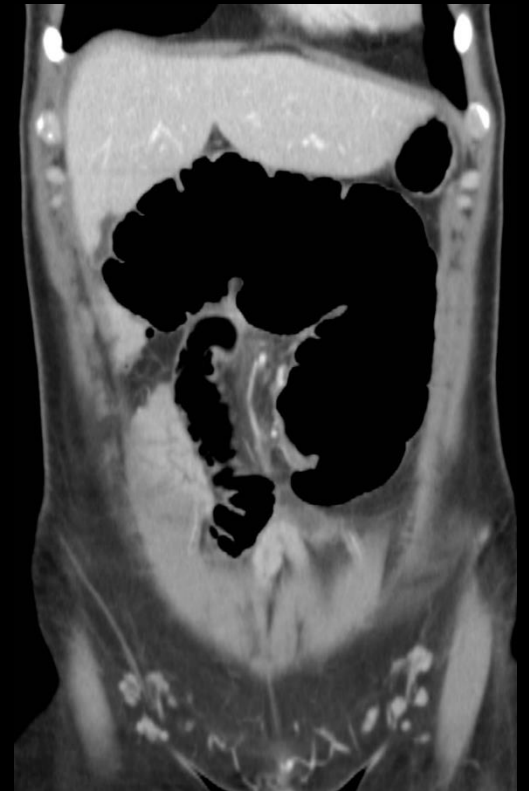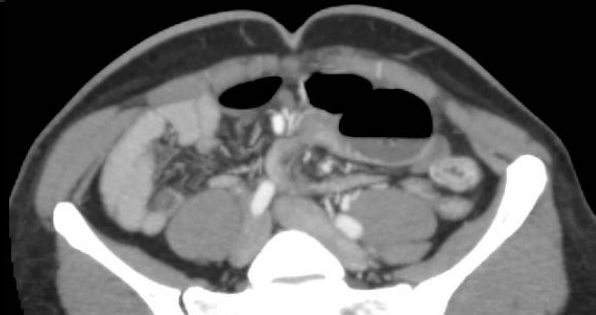
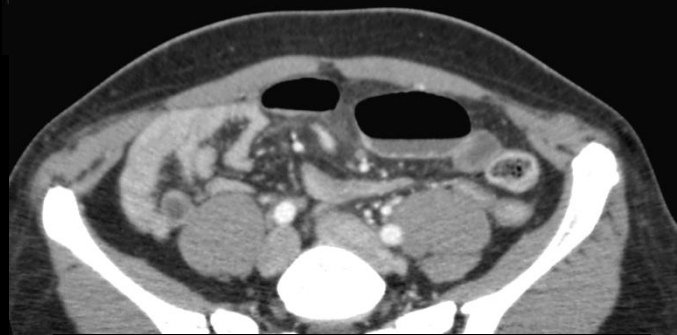
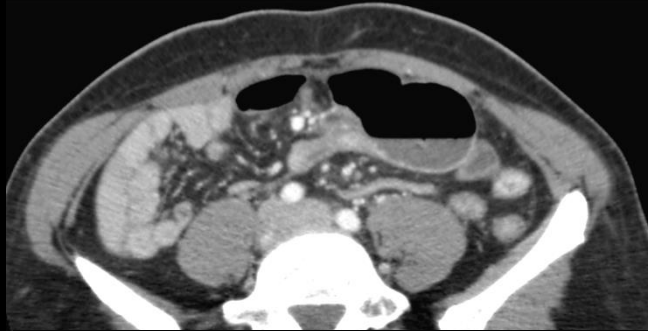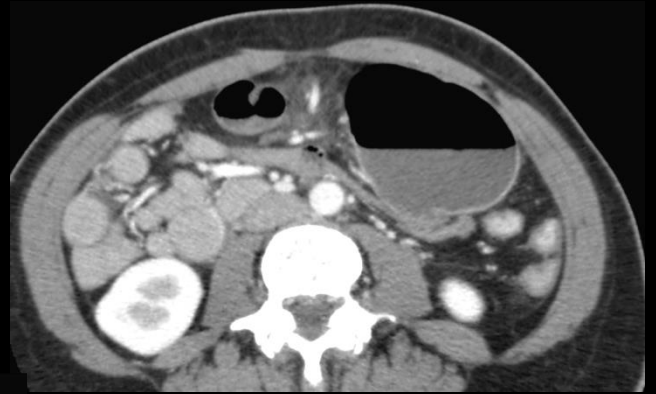
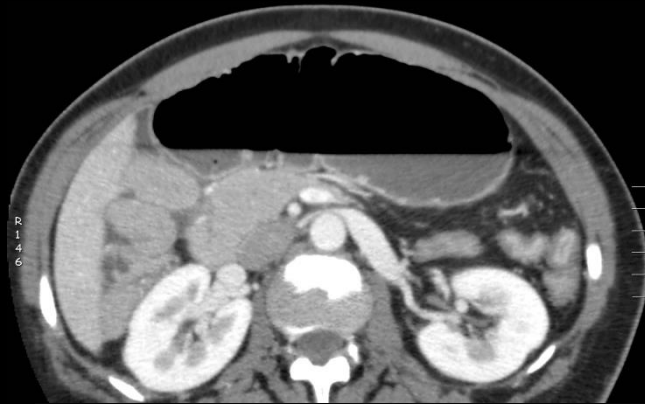


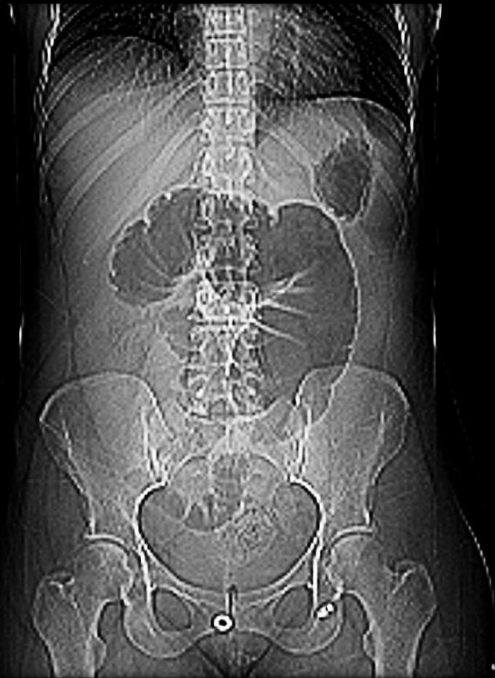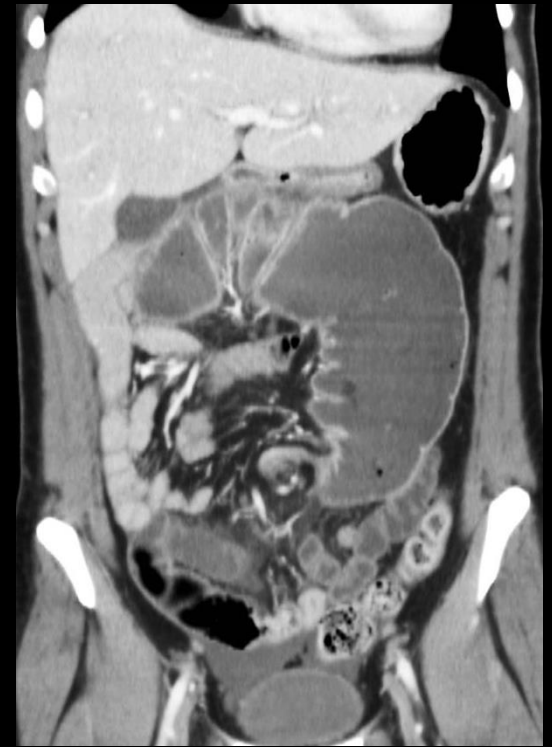
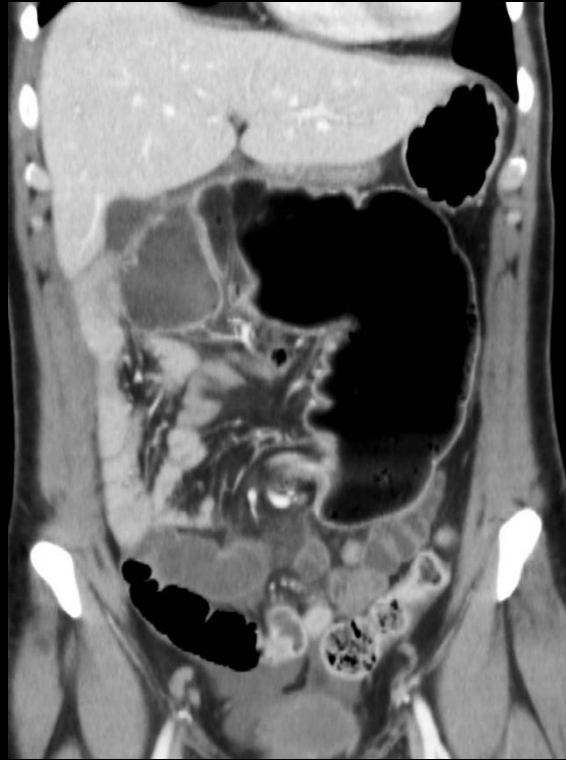
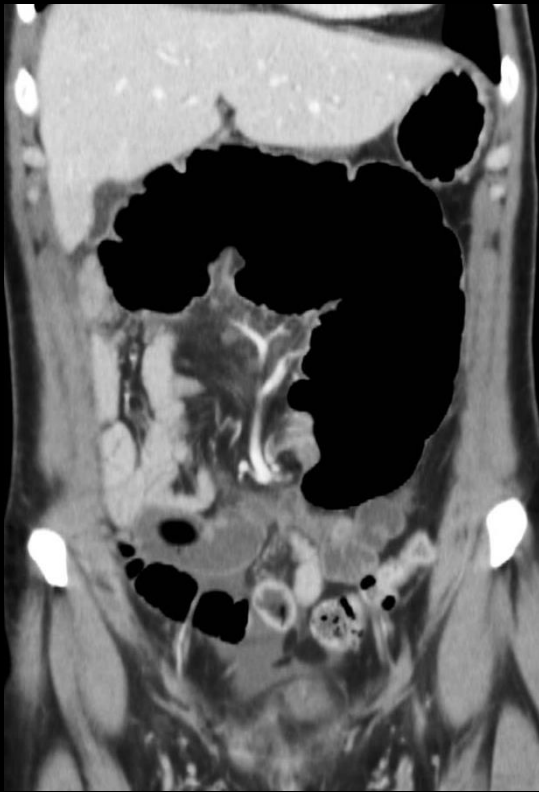**volvulus organo-axial
du caecum**



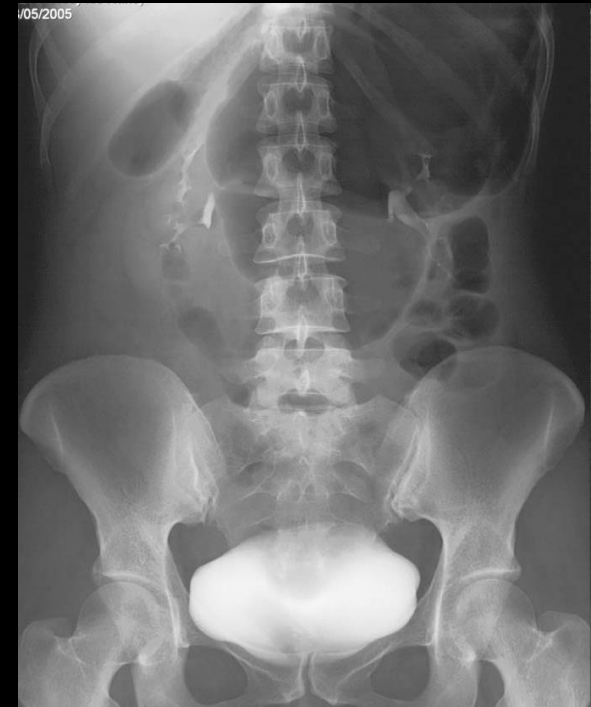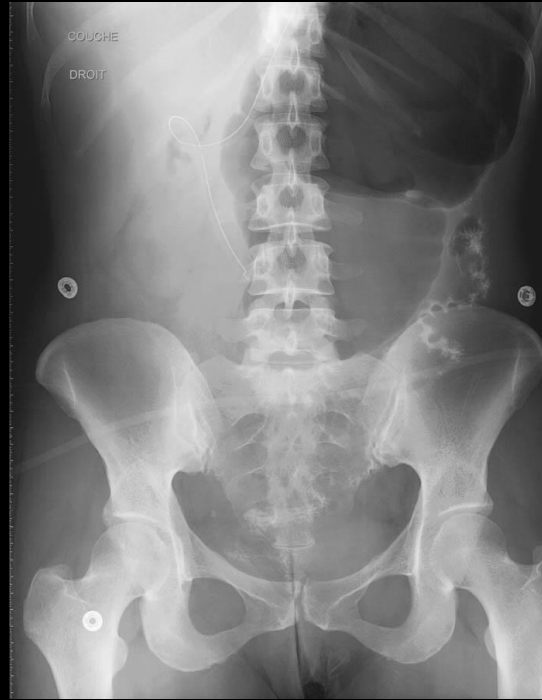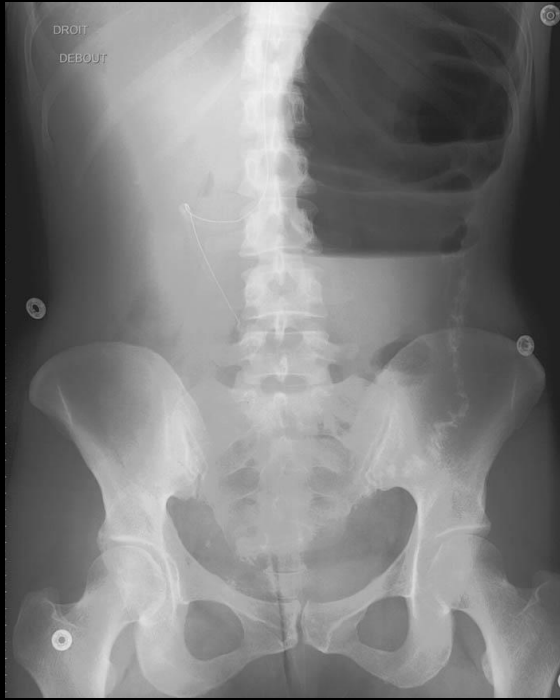


pas de whirl sign ; plicature caecale

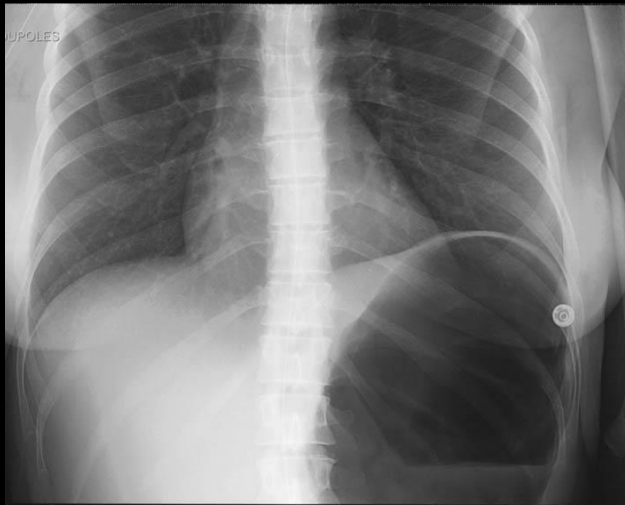


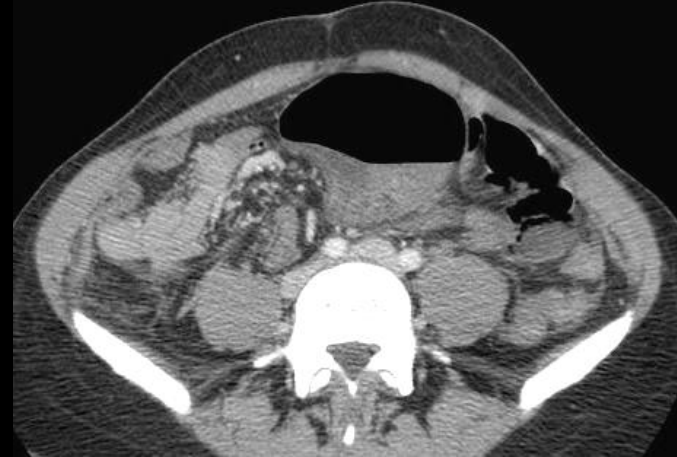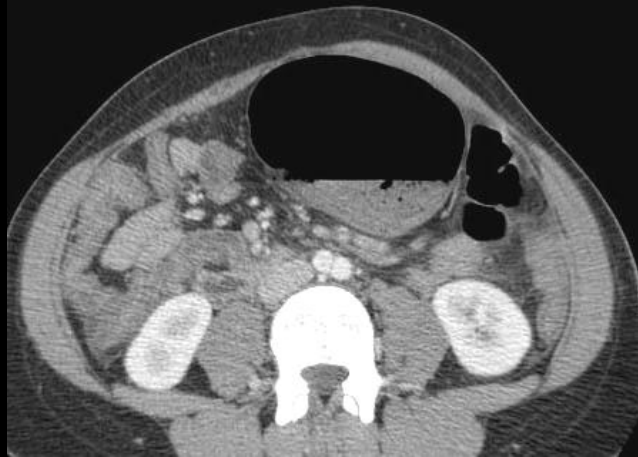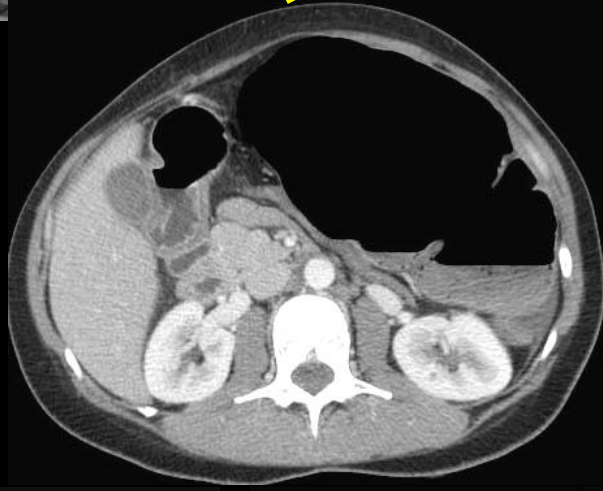
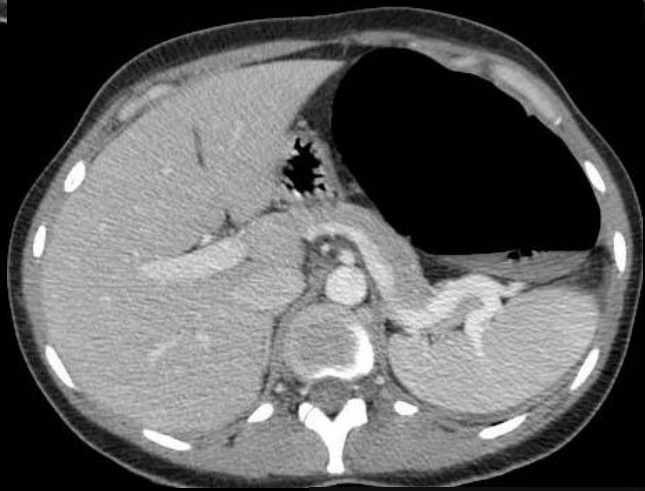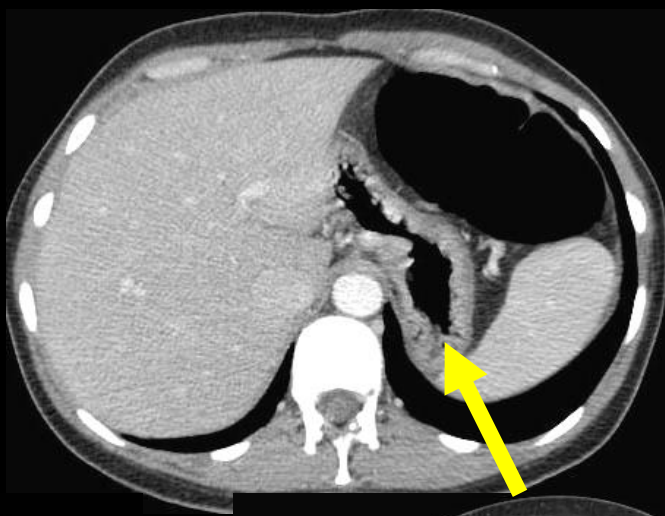
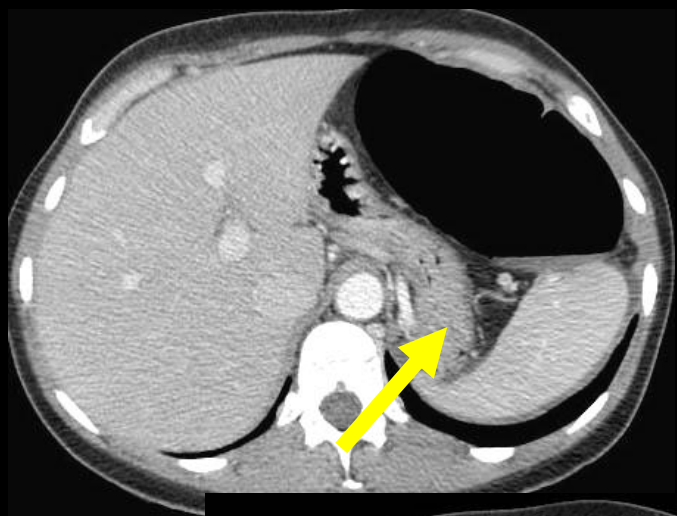


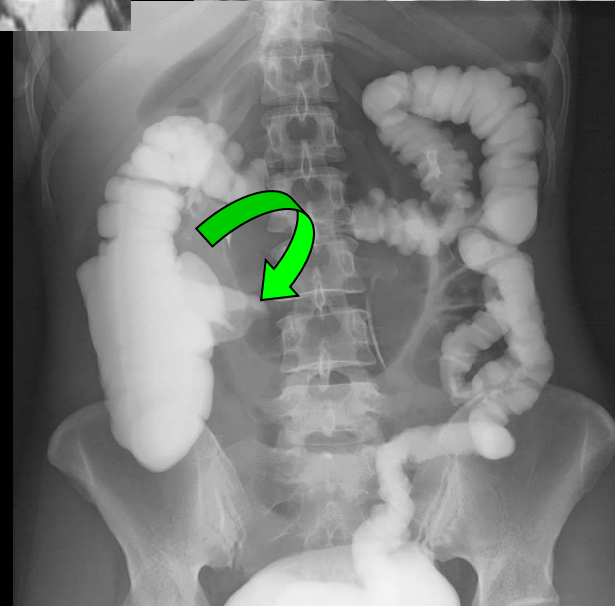
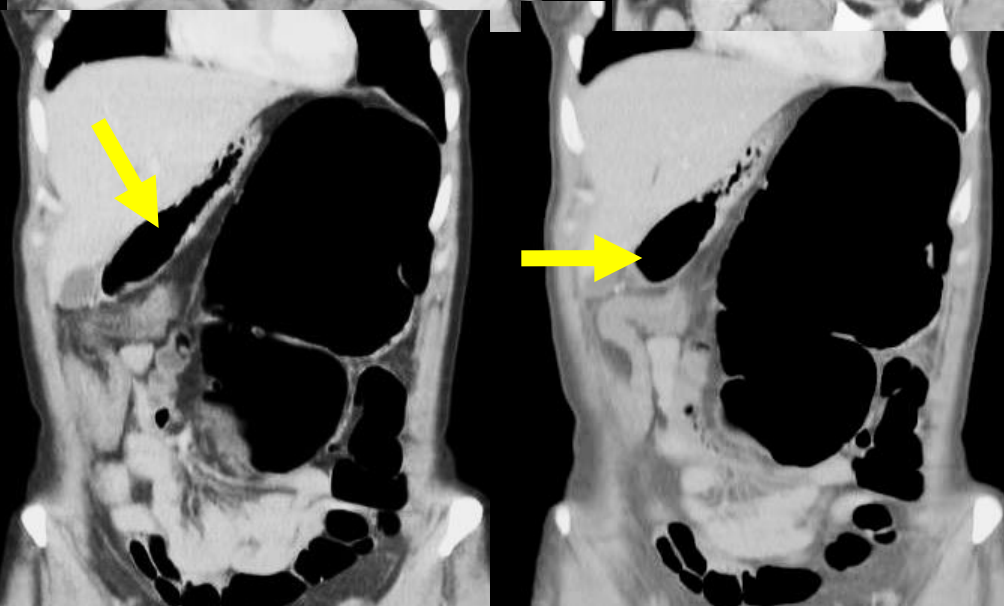
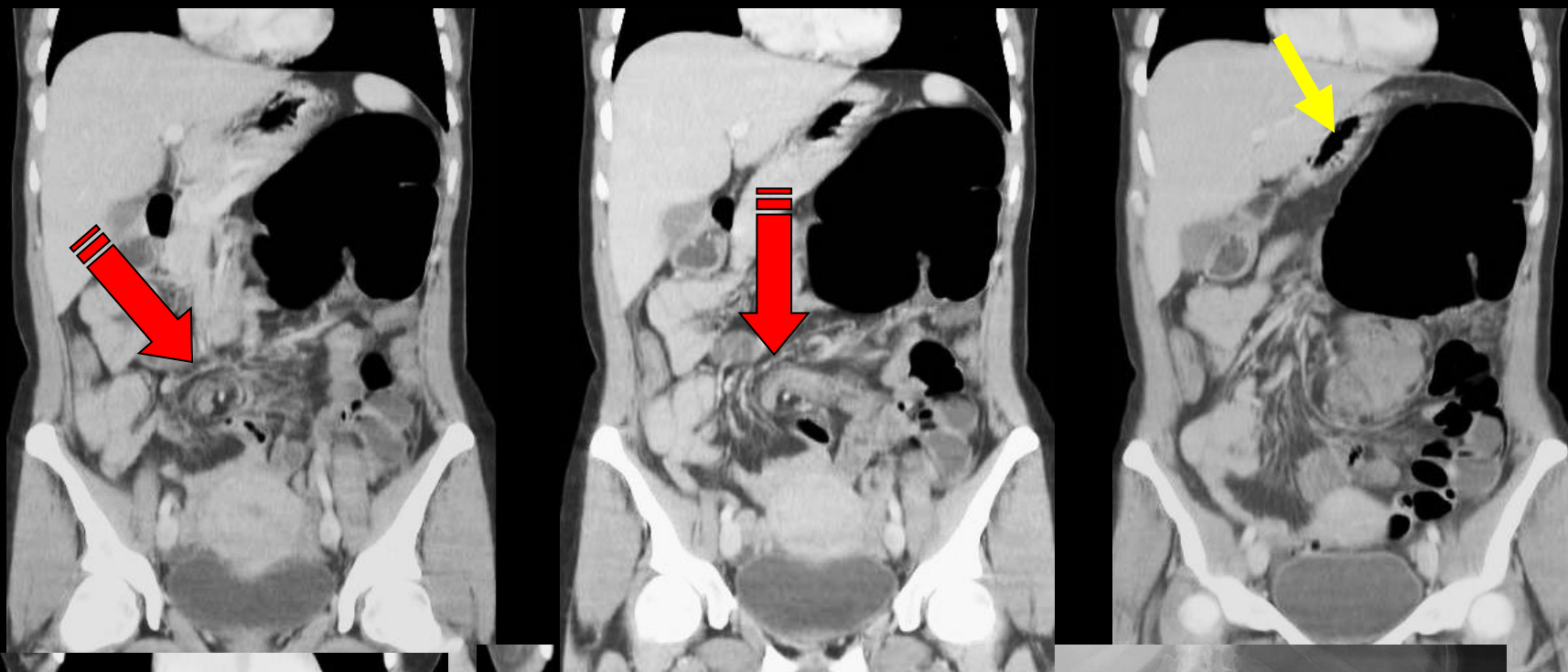**volvulus méésentérico-axial (loop type) dur
méésentère commun complet**



asp. post CT



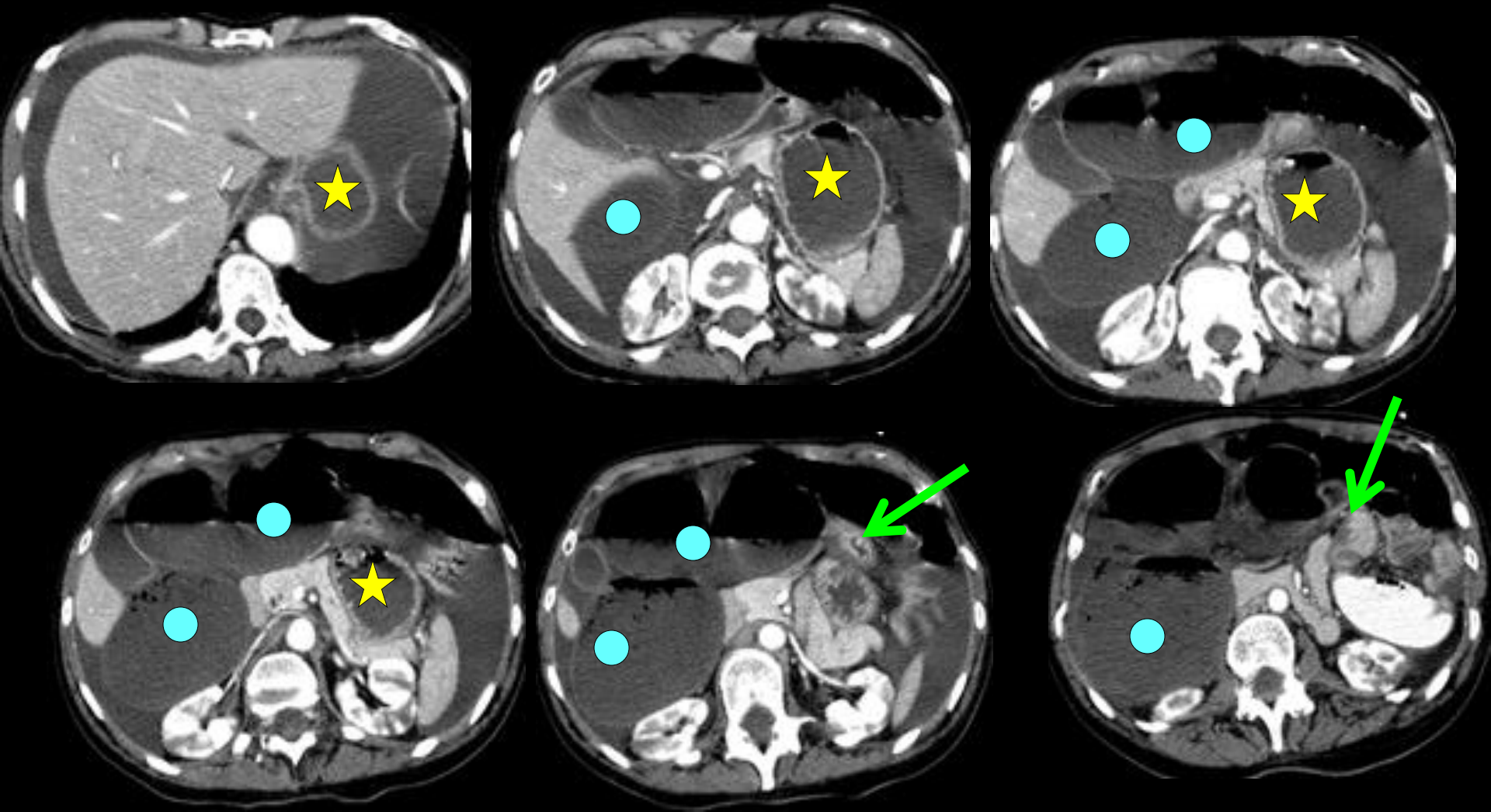




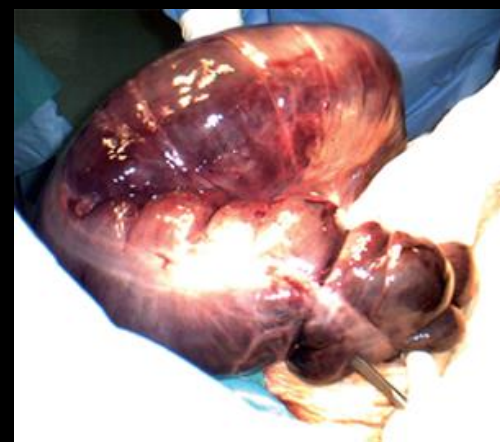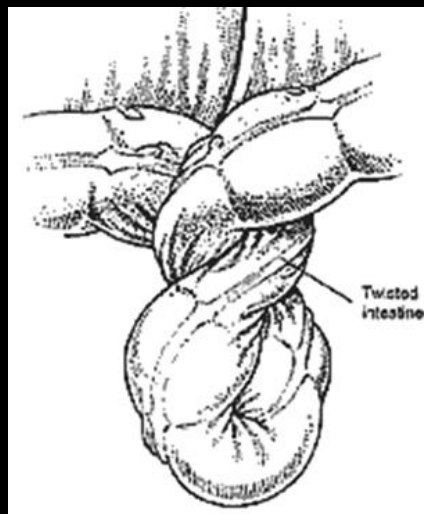
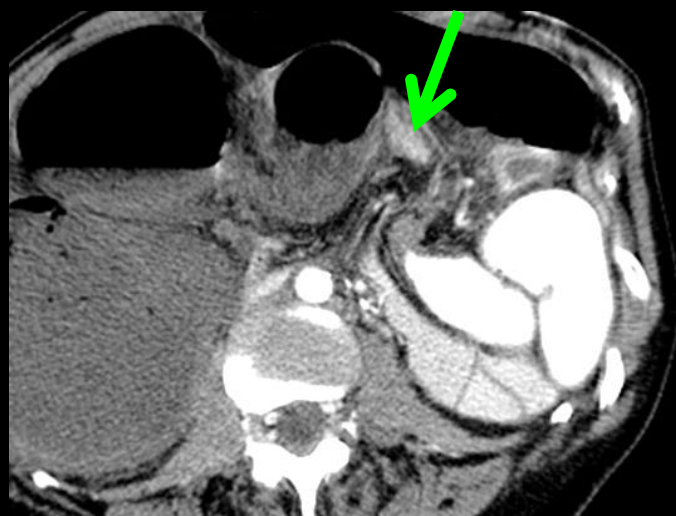
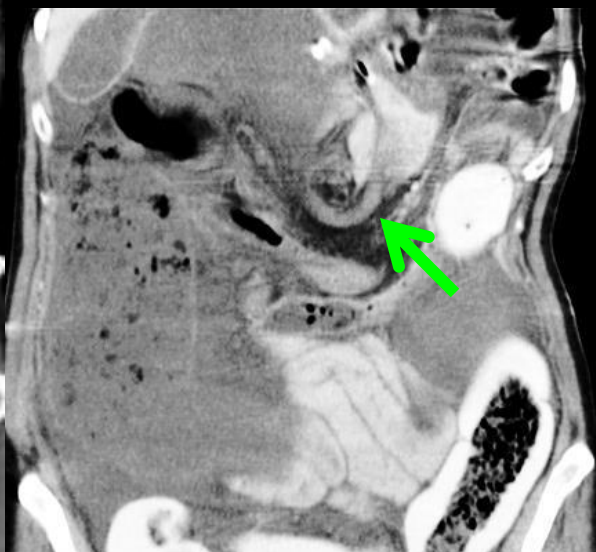
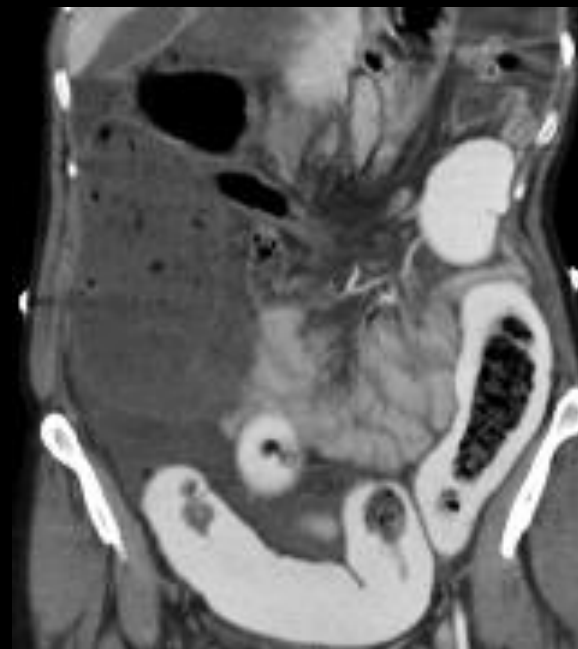
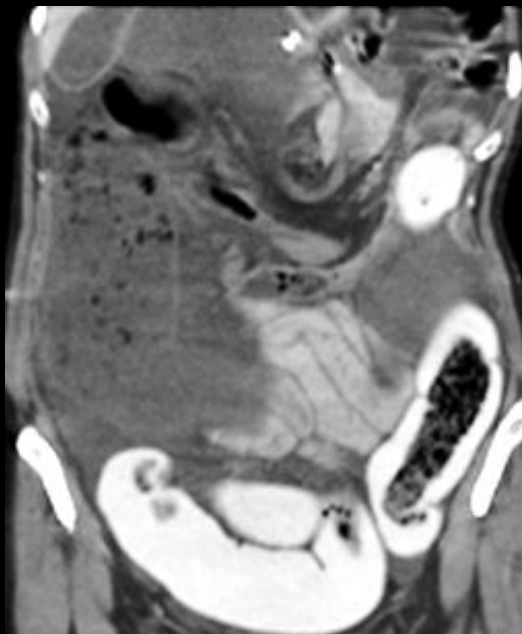
volvulus mésentérico-axial ("loop type") du cæcum !!!

femme 59 ans , constipée chronique , parkinsonienne ; syndrome abdominal hyperalgique à début brutal avec choc .

obs. M. Zins St Joseph Paris



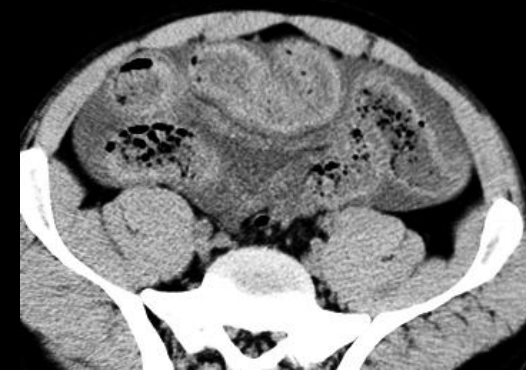
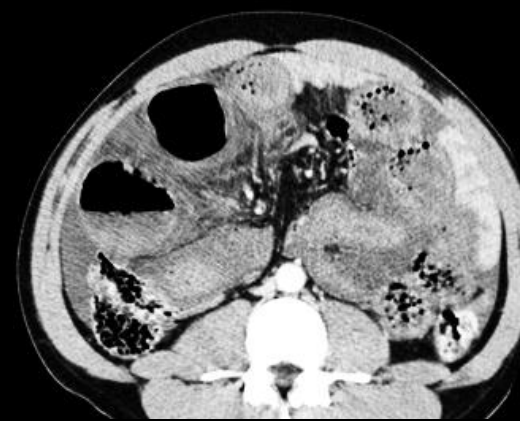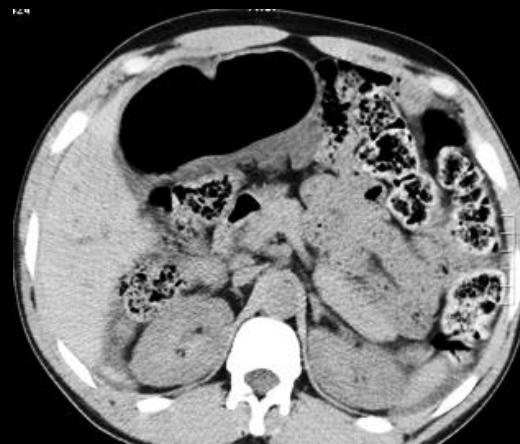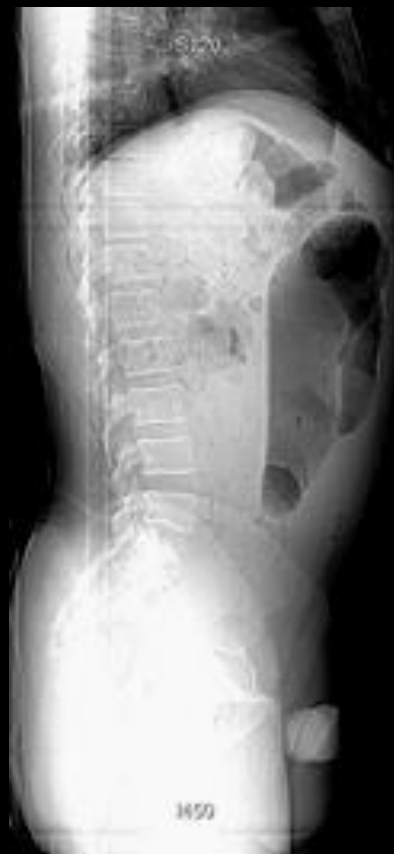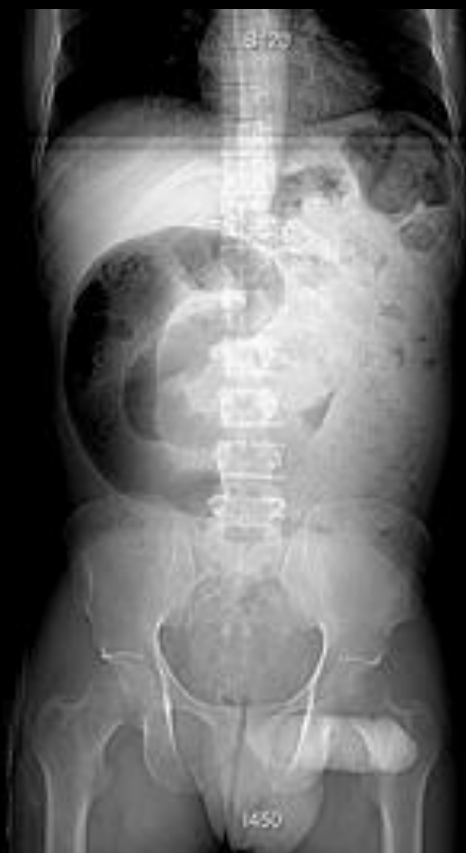whirl sign dans la moitié gauche du colon transverse



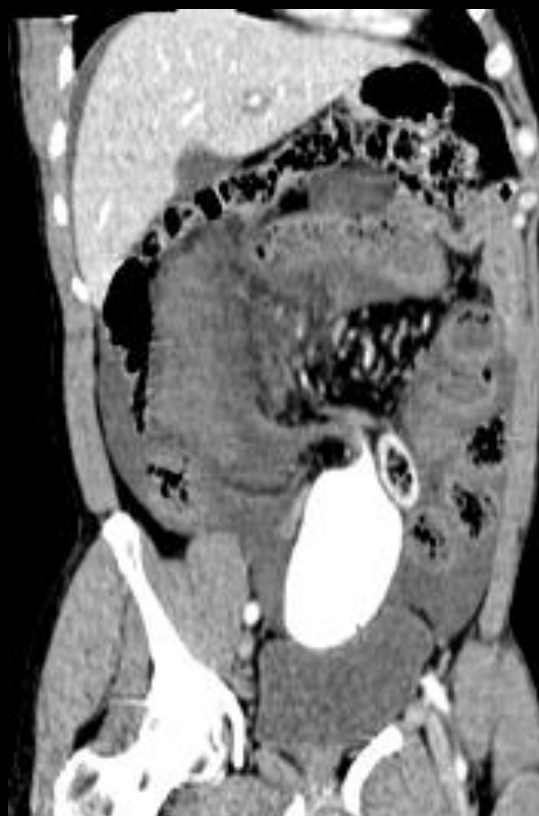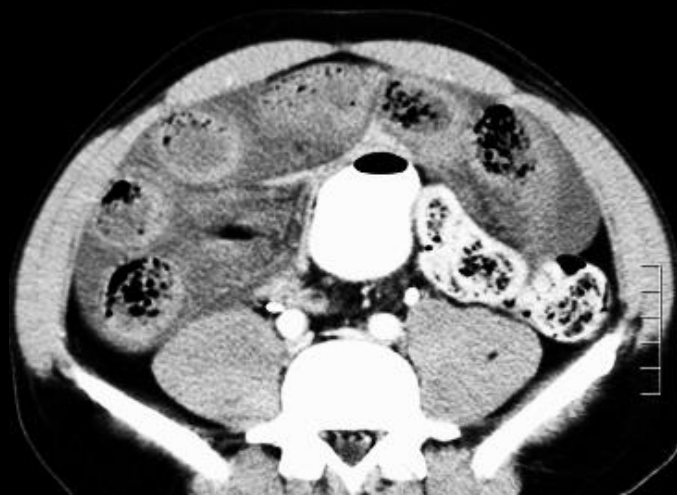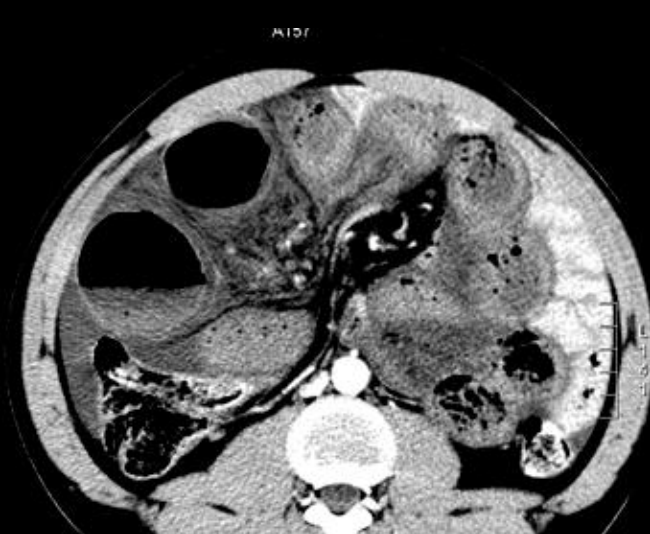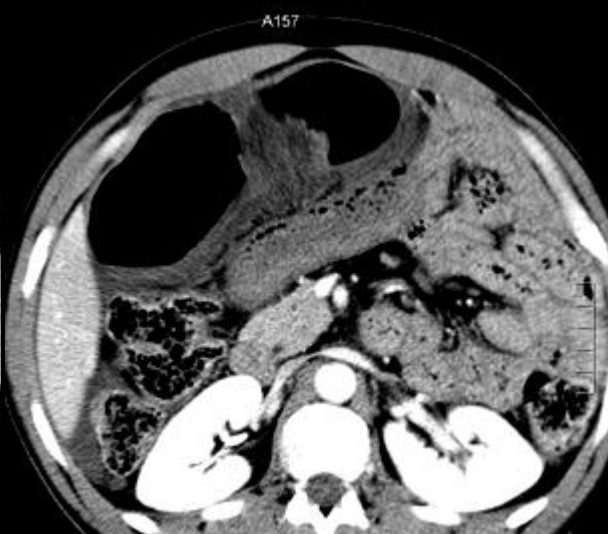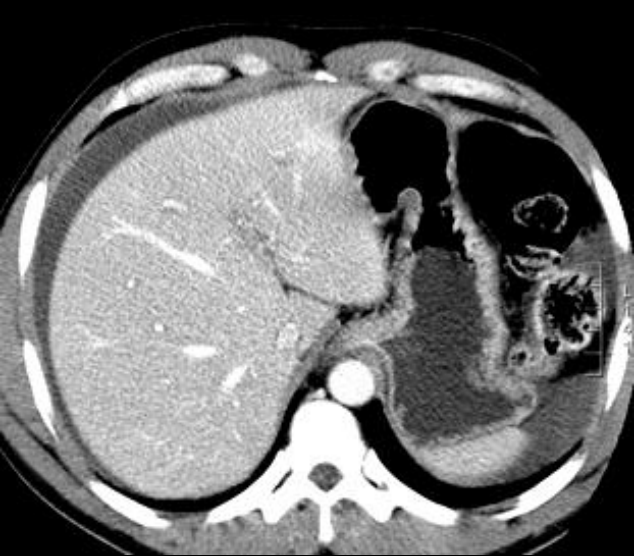volvulus mésentérico-axial du colon transverse

*Obs. Marc Zins
Hôpital St Joseph
Paris*

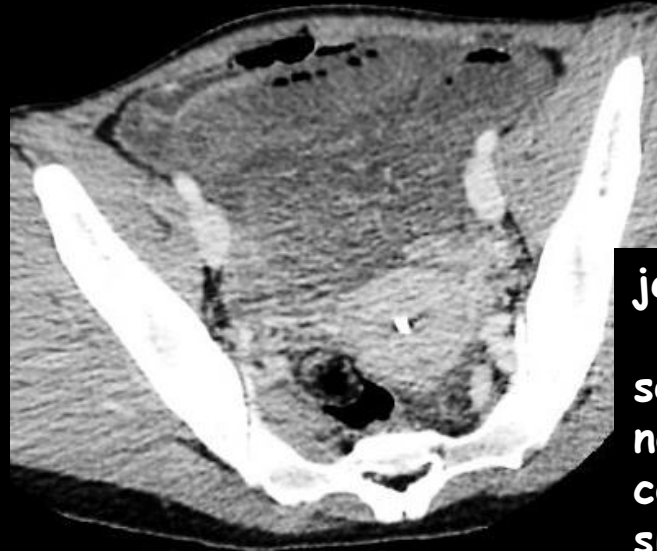
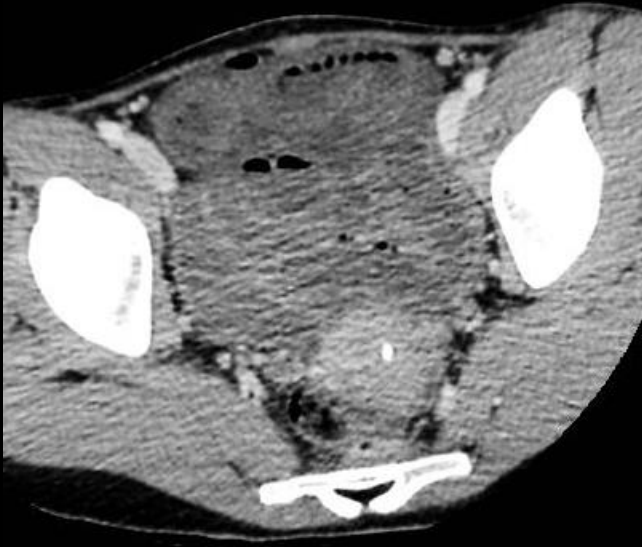
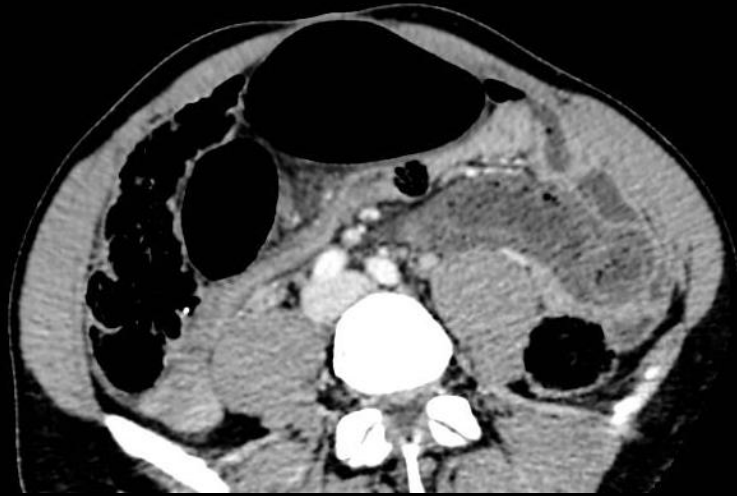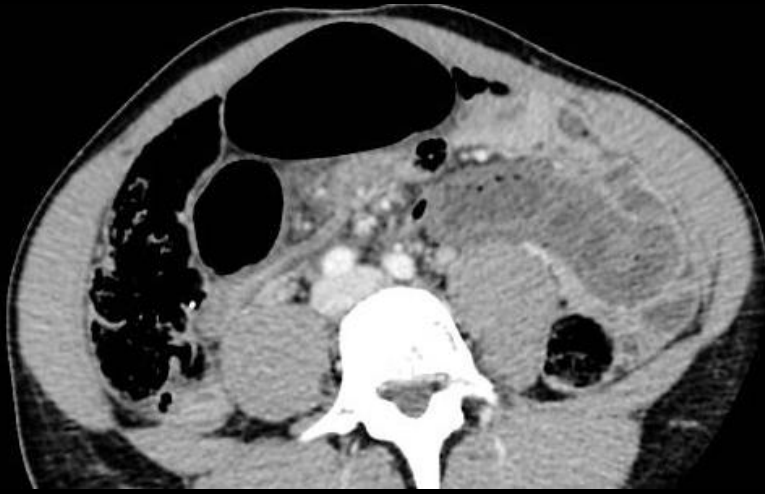3-1-1-3 double volvulus



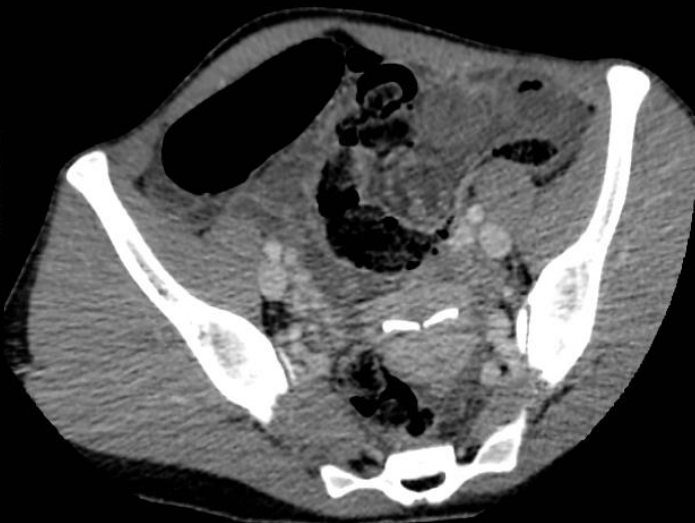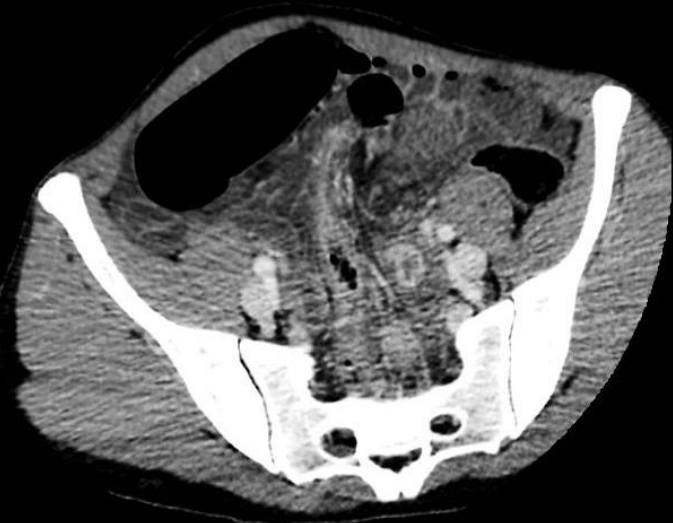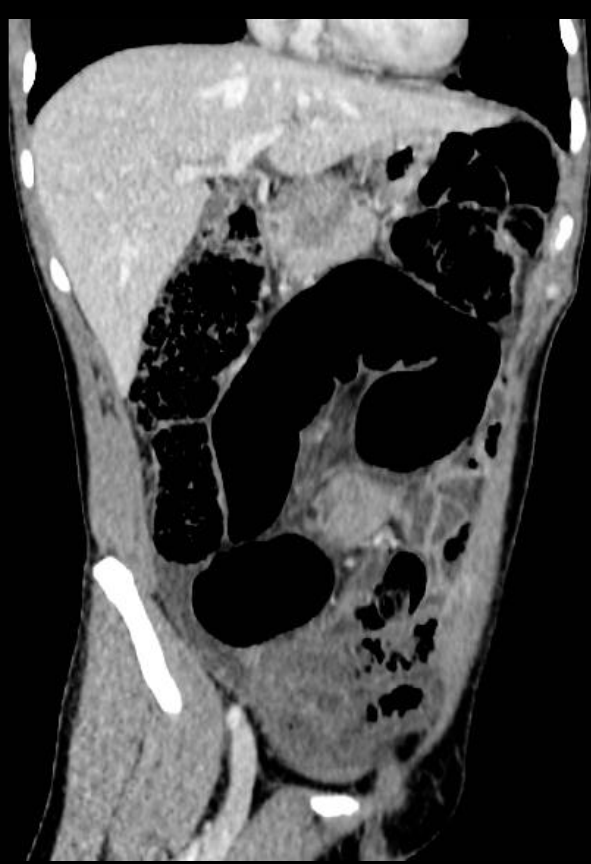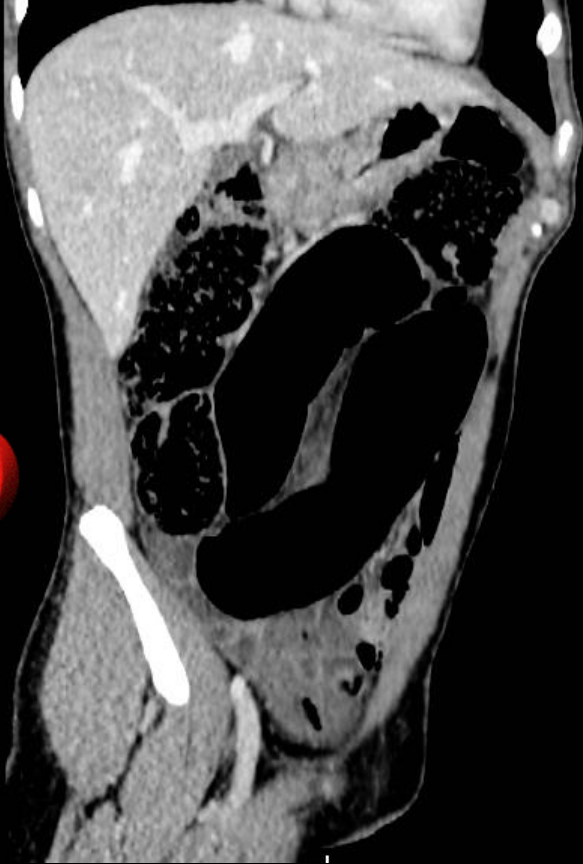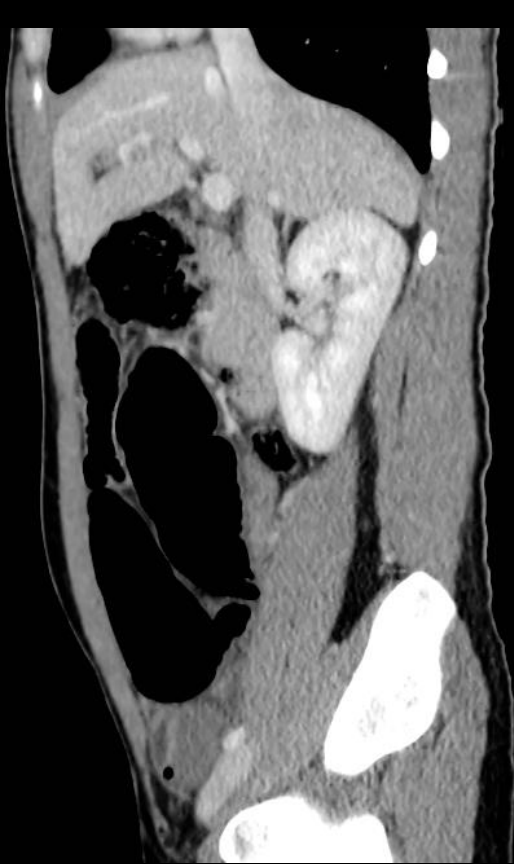*Obs. Marc Zins
Hôpital St Joseph Paris*

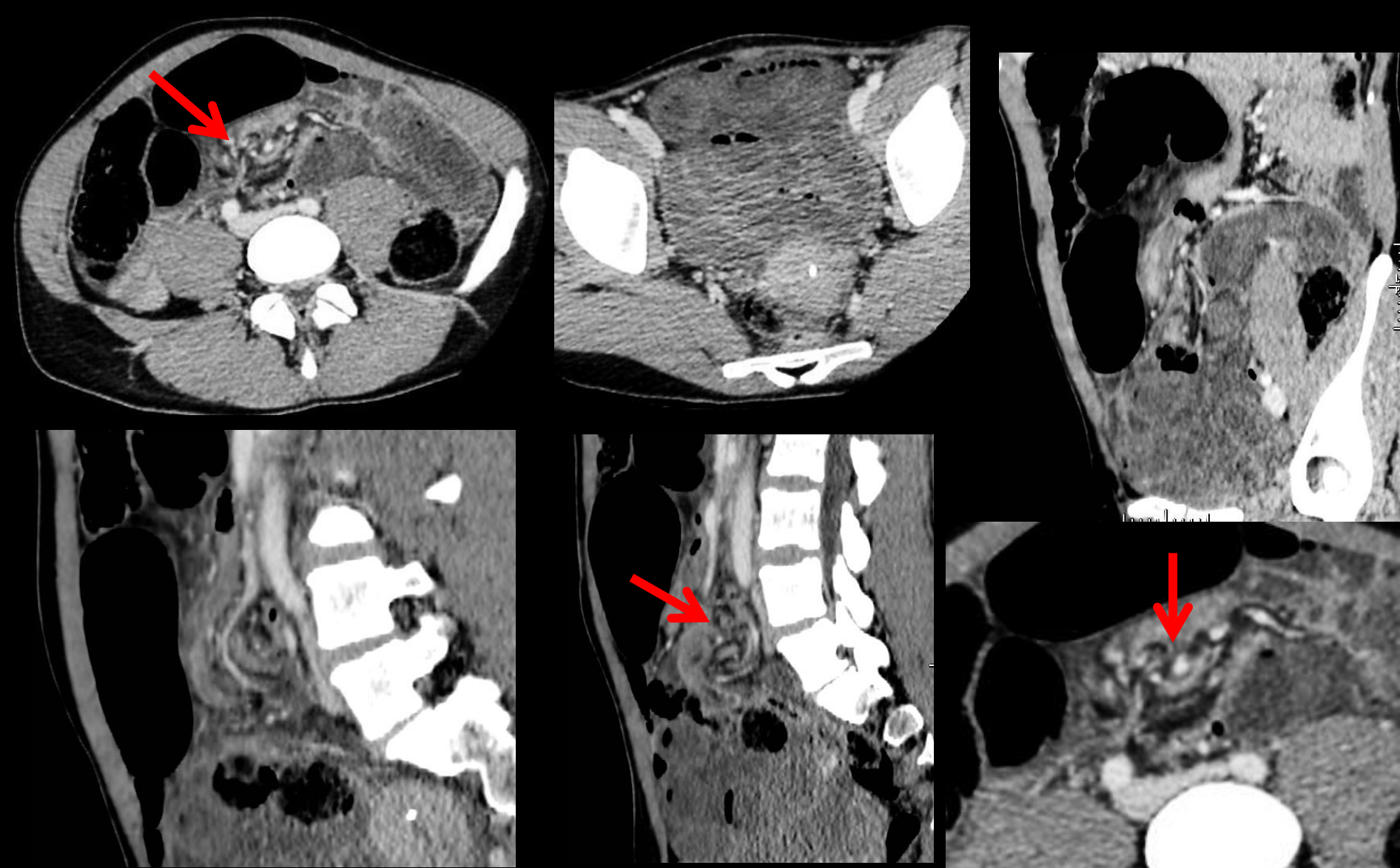

double nœud iléo-sigmoïdien
(iléo-sigmoïd knot double
volvulus : du grêle et du
sigmoïde)

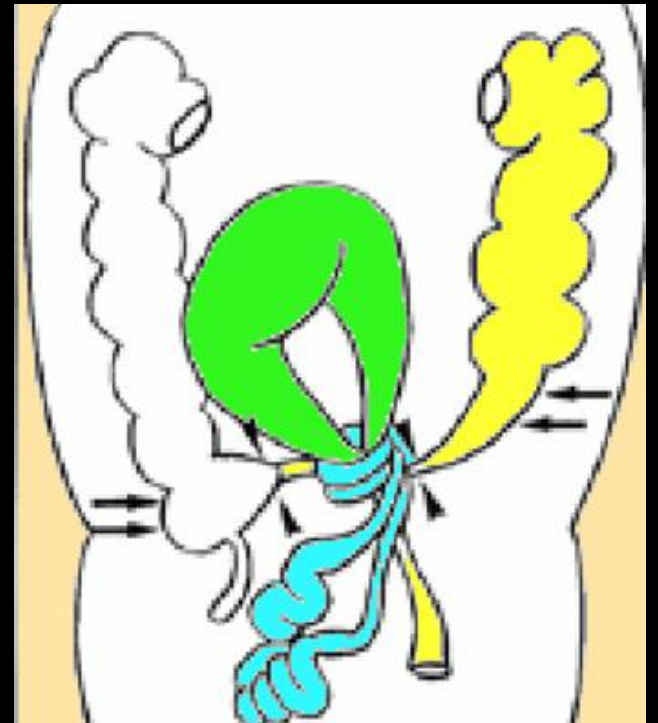
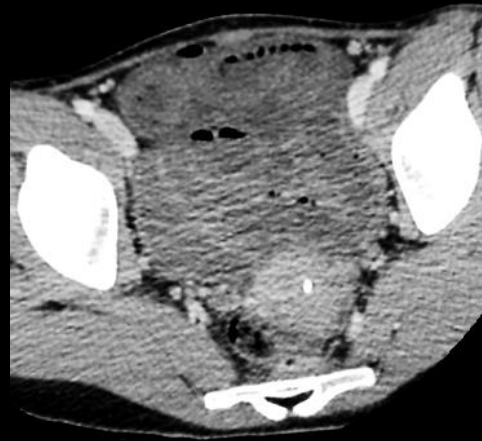
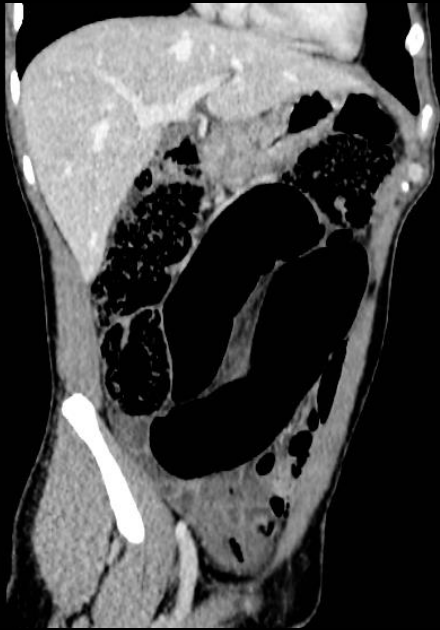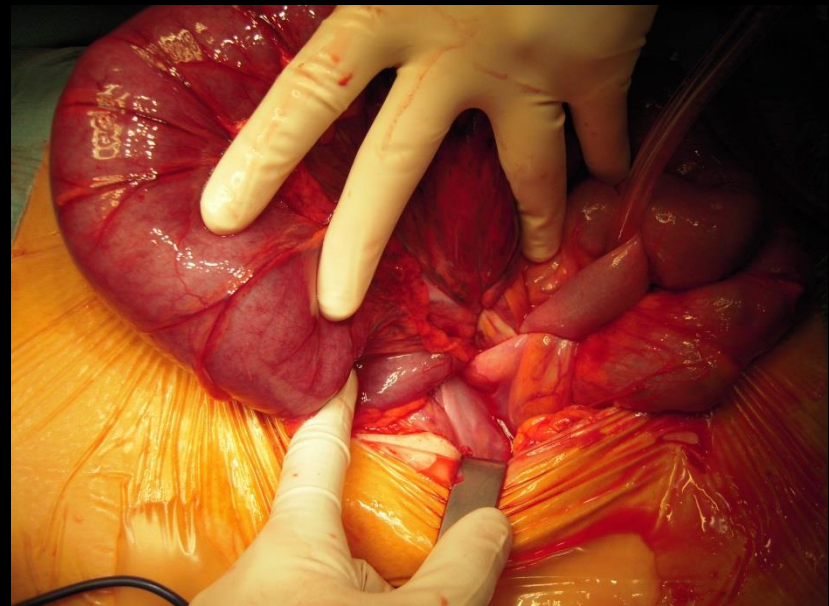
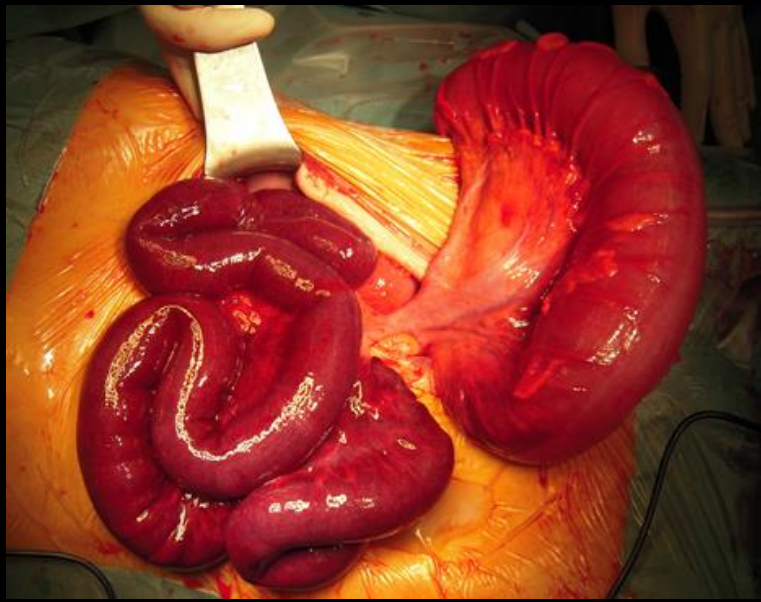


jeune femme 32 ans
sd douloureux suraigu
nocturne avec
contracture
silence sépulchral





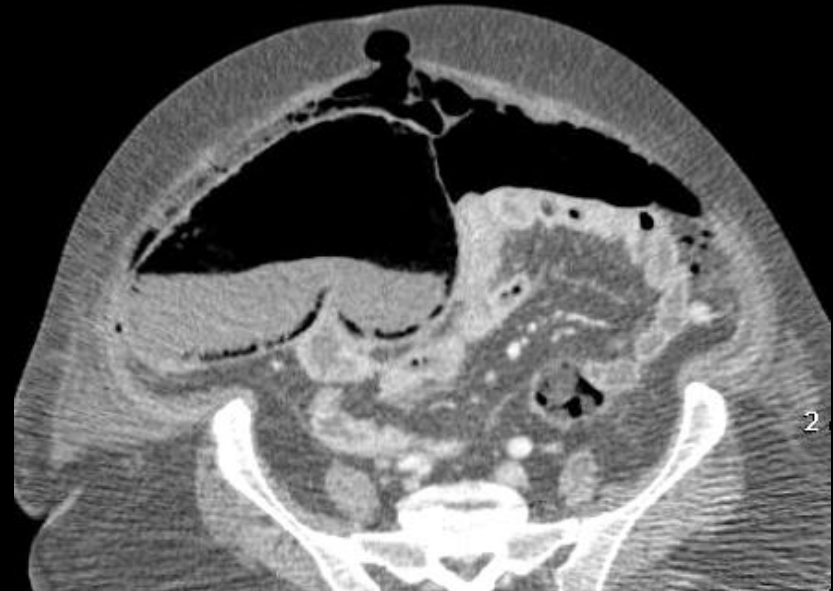
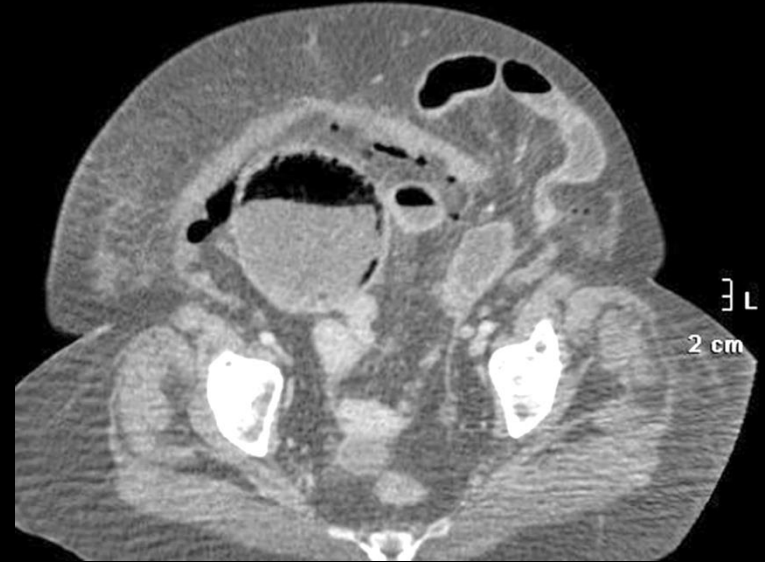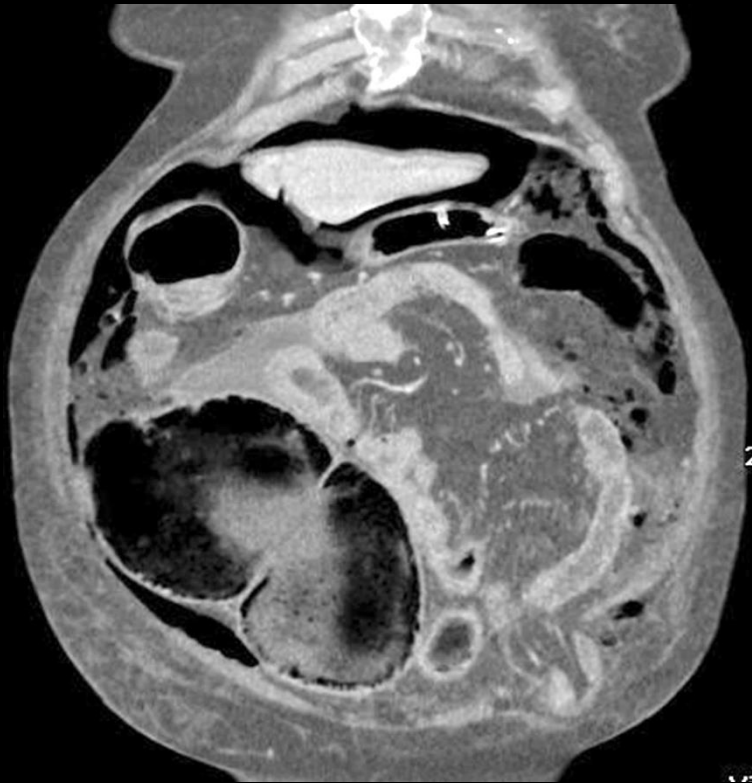
aspect de **dolichosigmoïde vertical** avec **volvulus mésentérico-axial** et d'ischémie globale des anses grêles avec "**tourbillon vasculaire**" autour de l'artère mésentérique supérieure"(whirl sign vasculaire) caractéristique d'un **volvulus du grêle** compliquant une rotation incomplète de l'anse intestinale primitive de type 180°

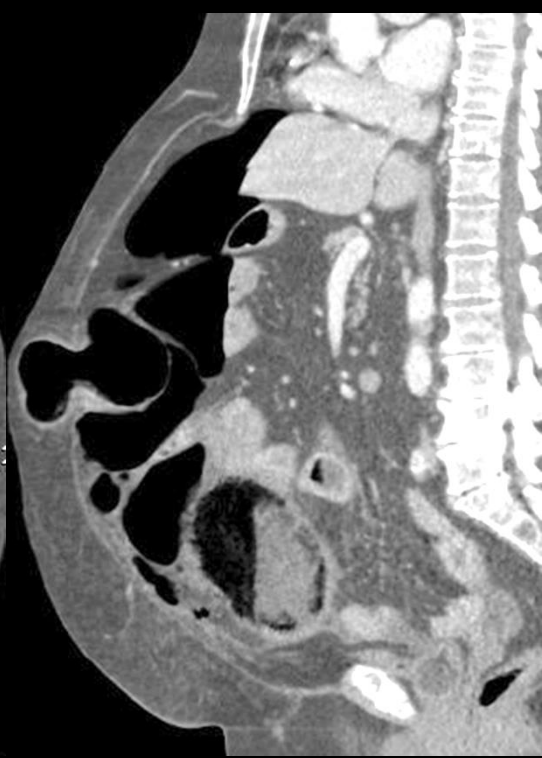
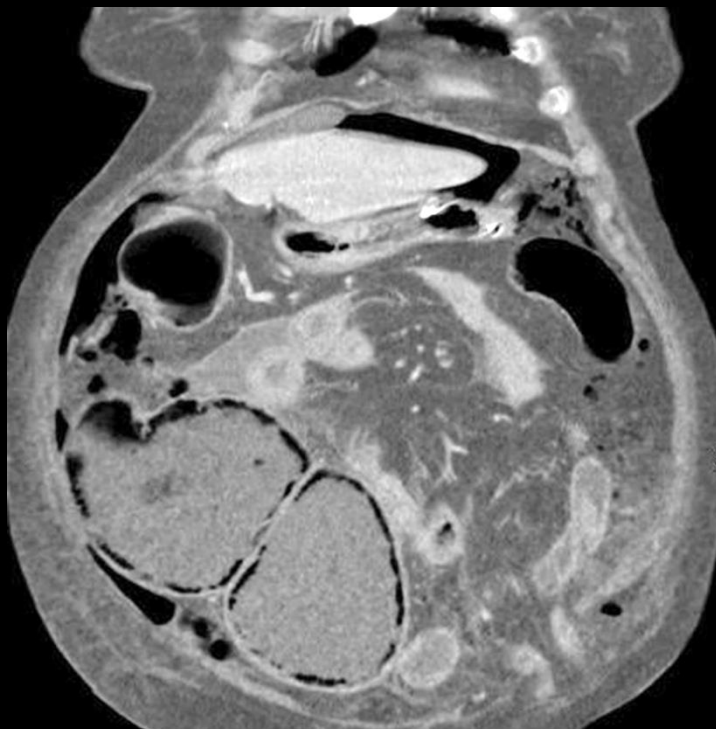
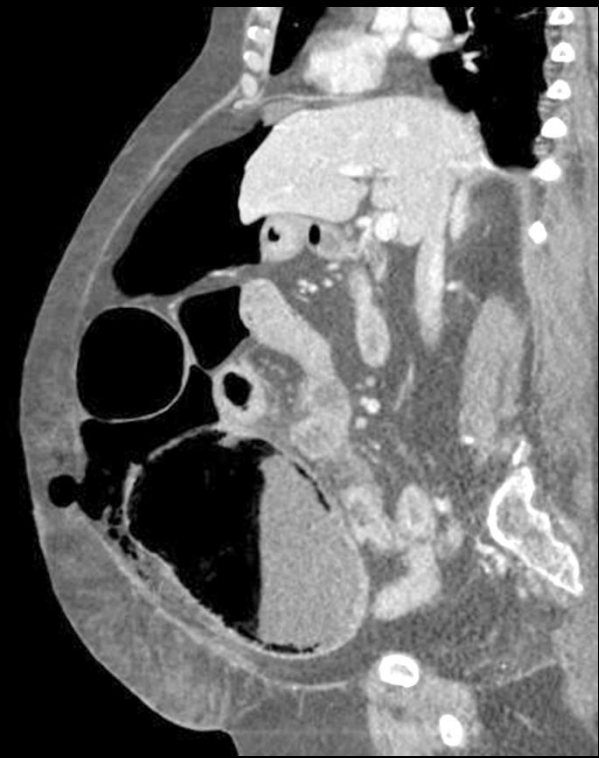

**double nœud iléo-sigmoïdien (iléo-sigmoïd knot
double volvulus : du grêle et du sigmoïde)**

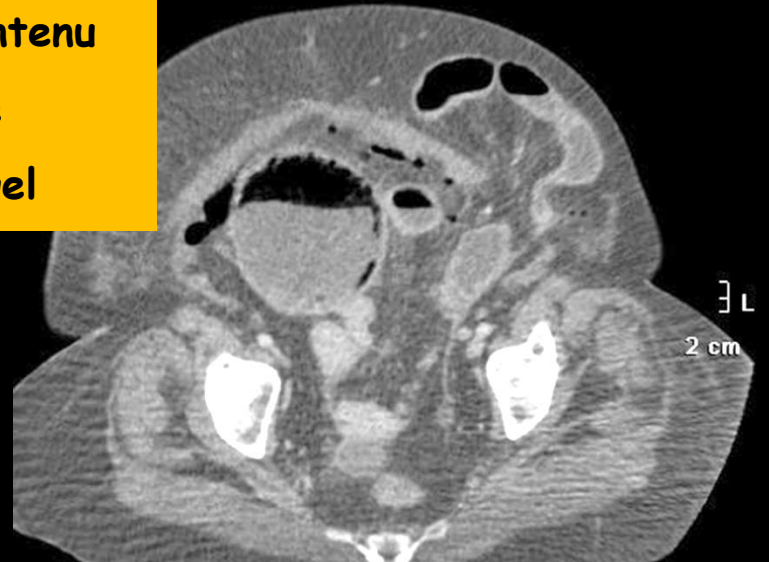
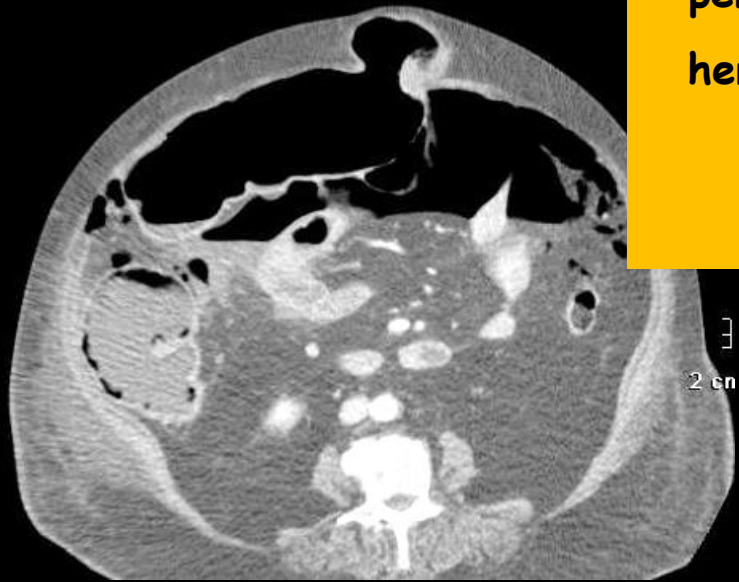
3-1-1 occlusions colo-rectales d'origine extrinsèque

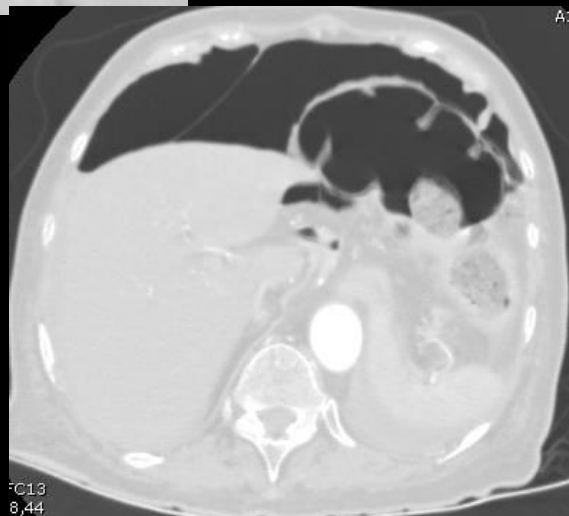
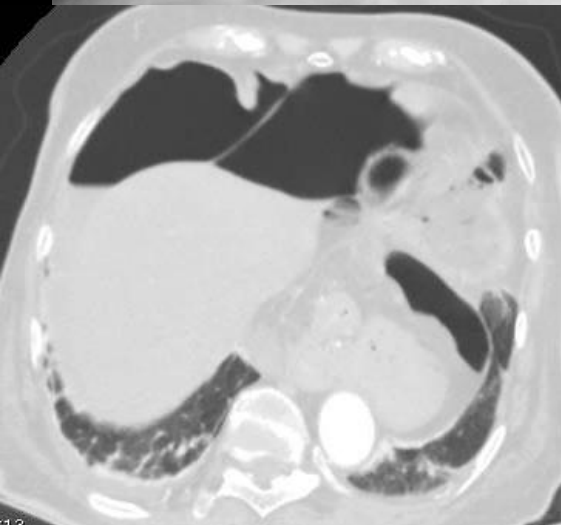
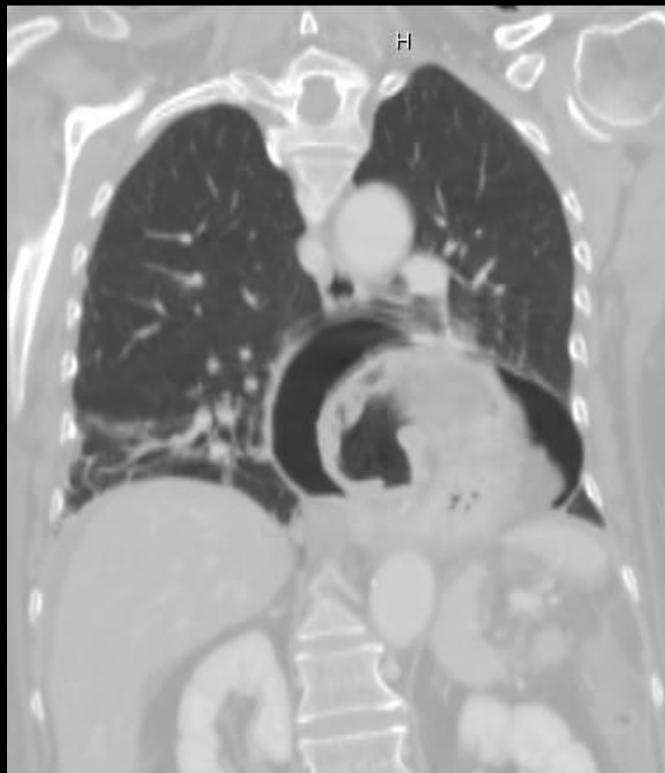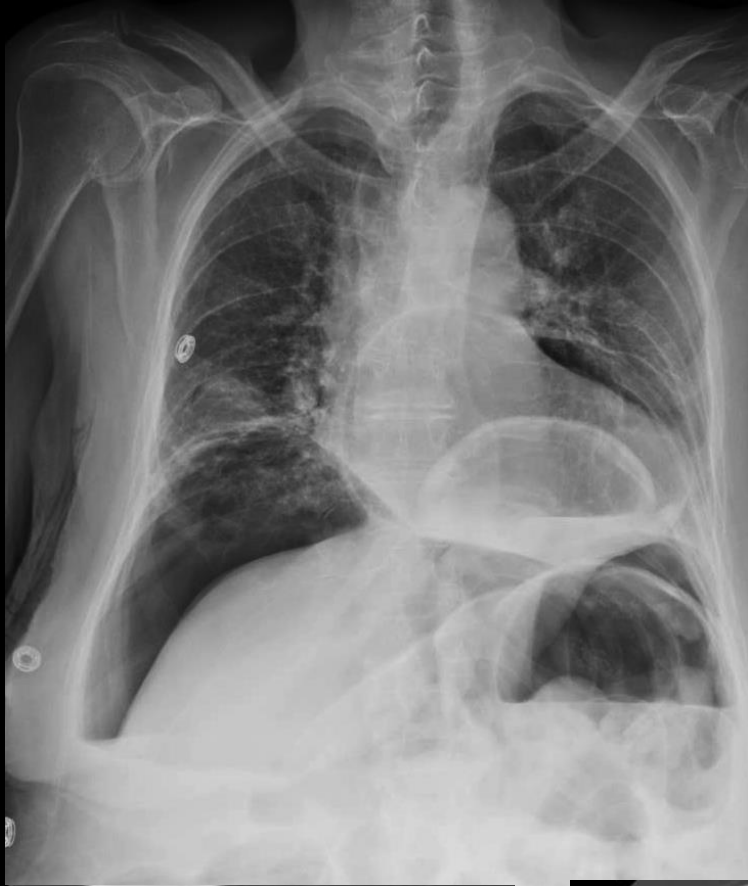3-1-1-2 hernies pariétales



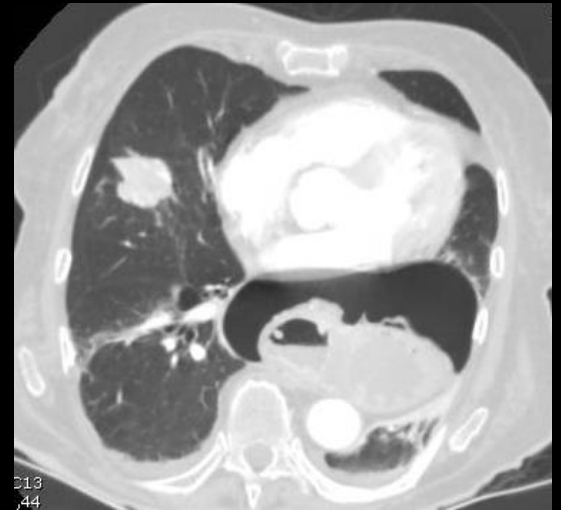

**perforation diastatique sur
hernie ombilicale à contenu
colique transverse
+ hernie de Spiegel**

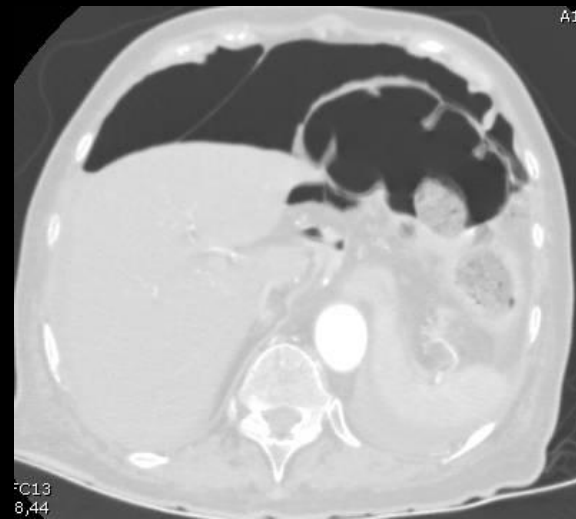
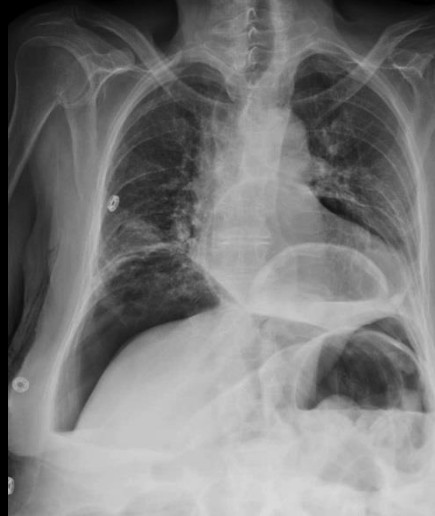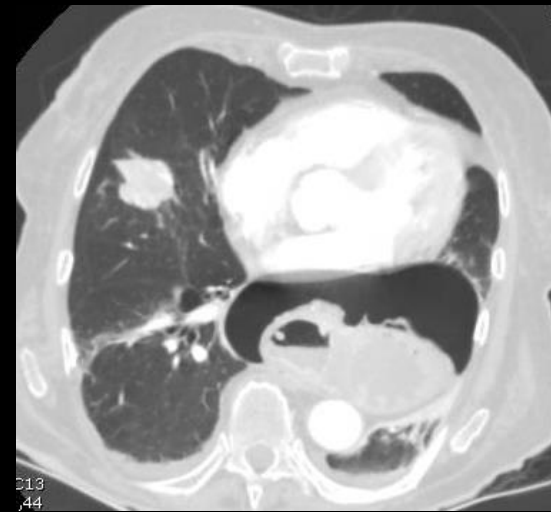
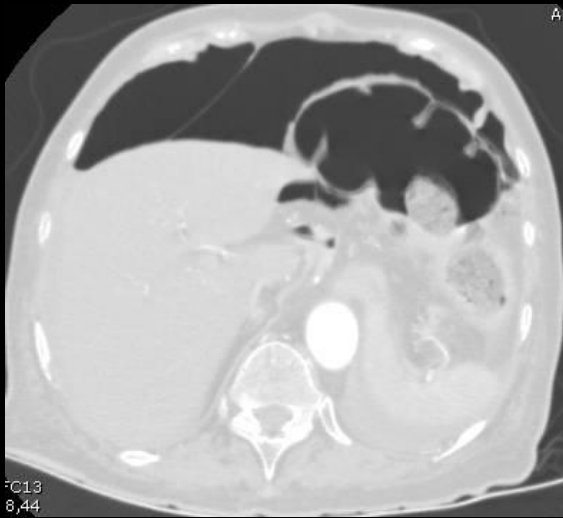

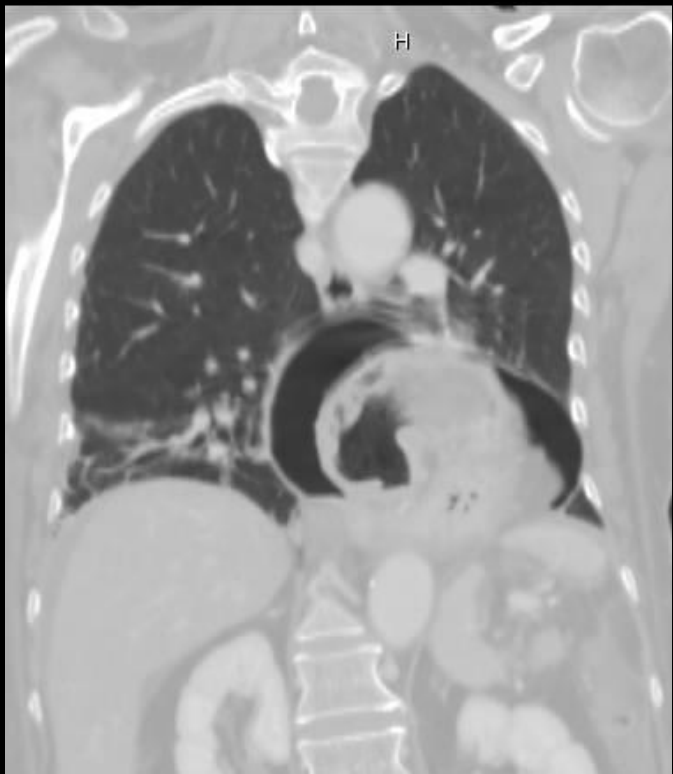


FC13
8,44

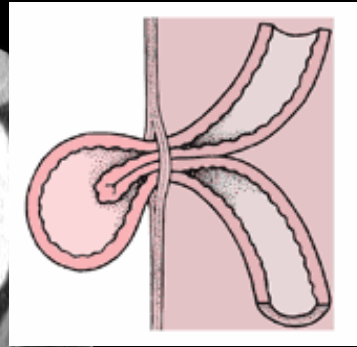
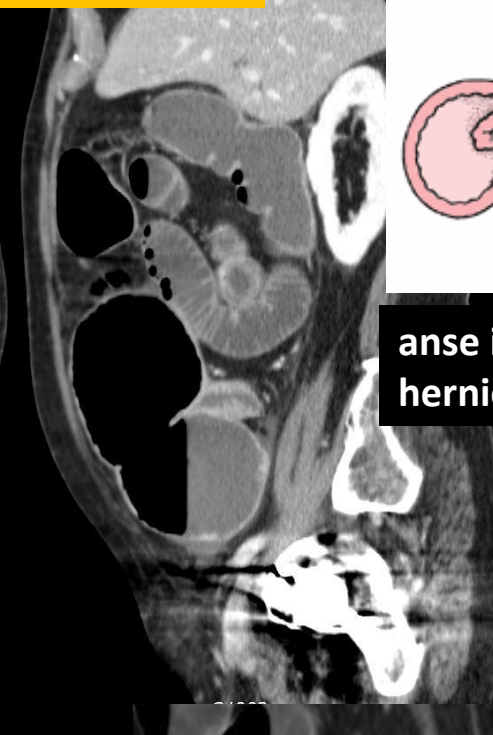
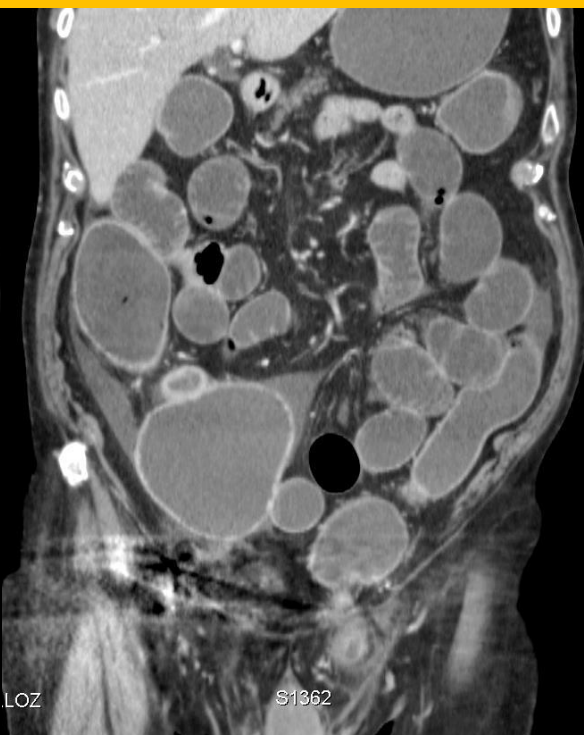
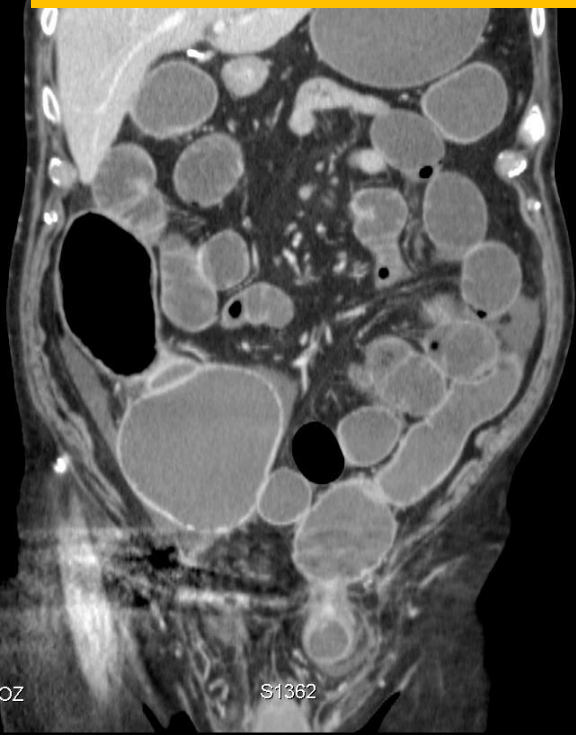

F13
,44

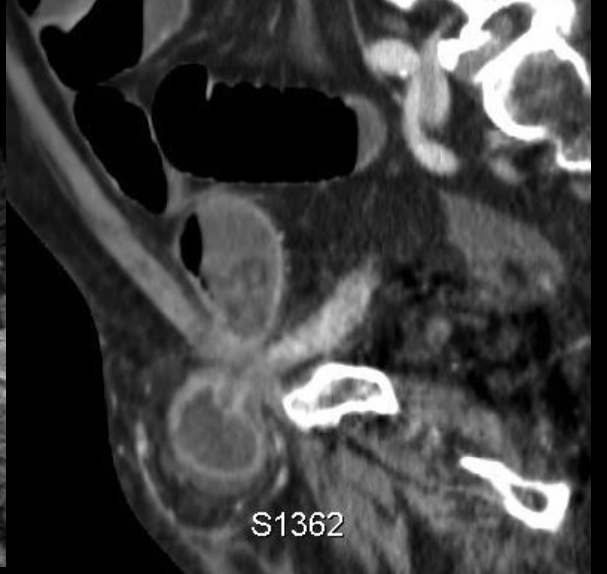
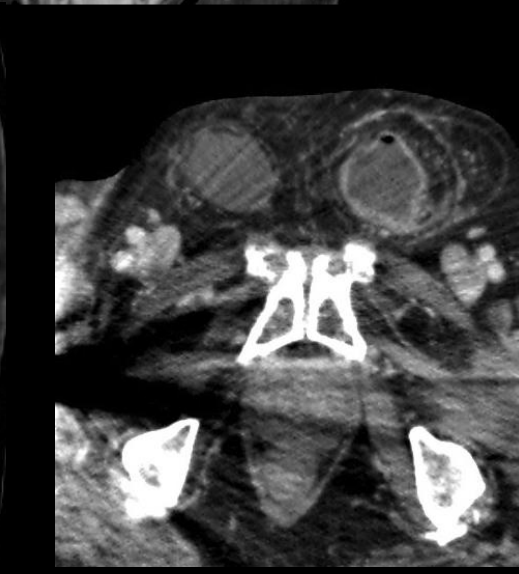
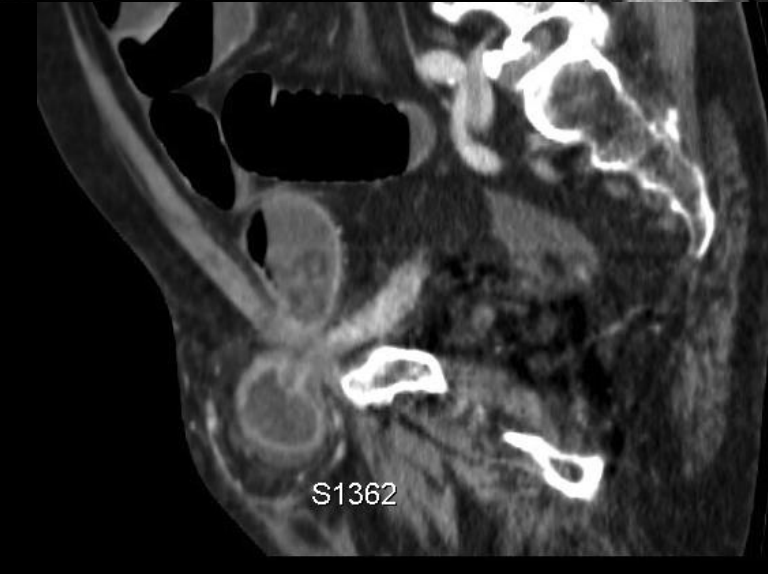


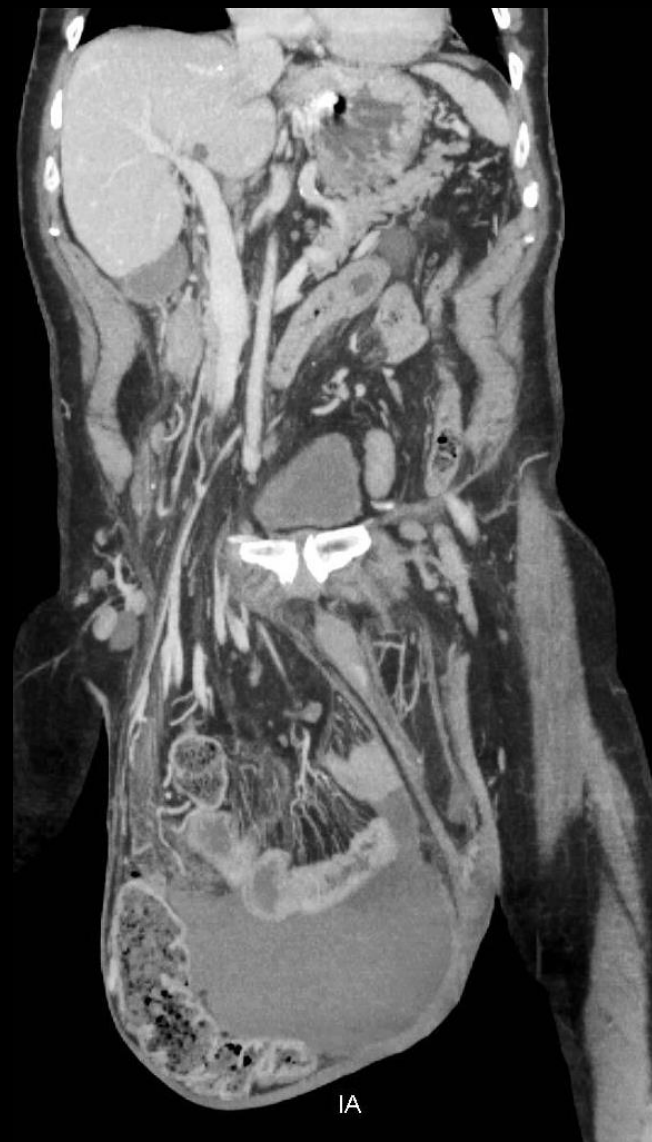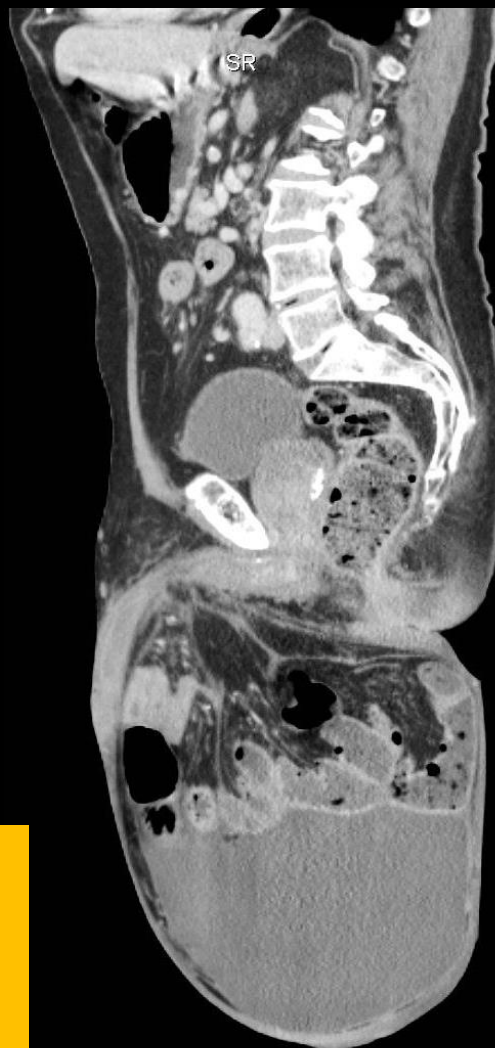
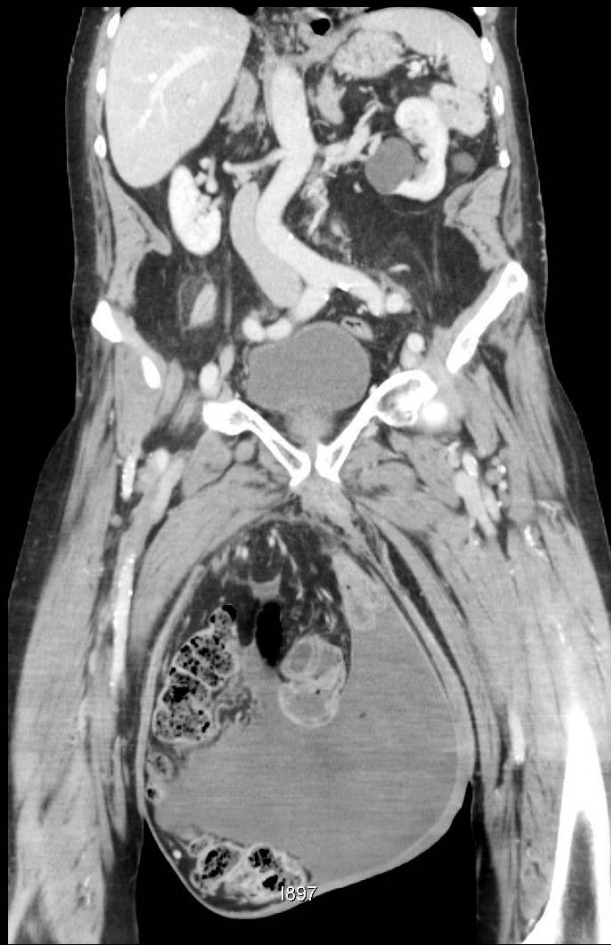**hernie hiatale par glissement et pneumopéritoine abondant
(perforation diastatique du caecum)
le colon transverse n'accompagne pas l'estomac dans le sac
herniaire**

hernie inguinale oblique externe avec incarceration du sigmoïde

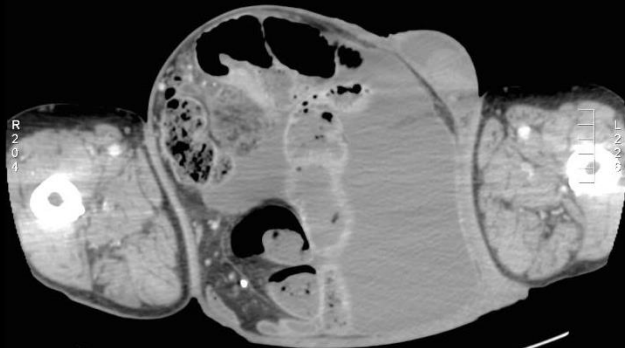
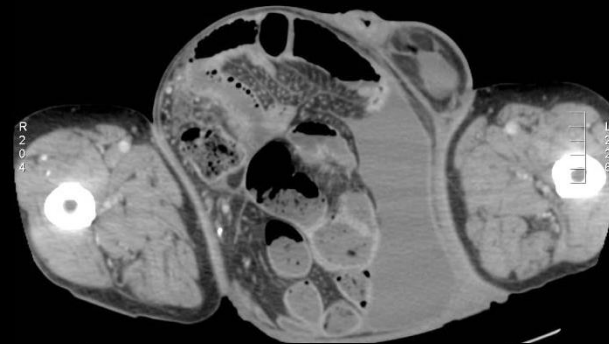
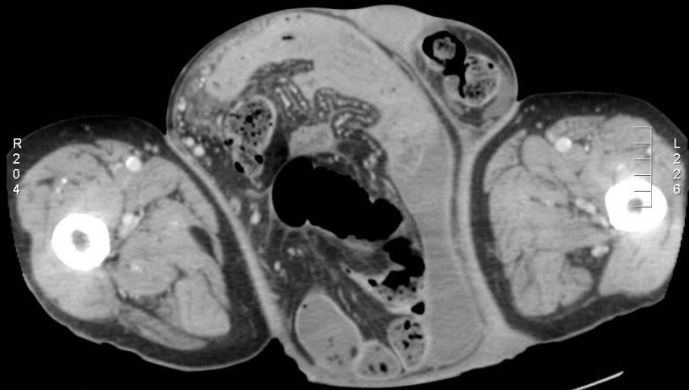
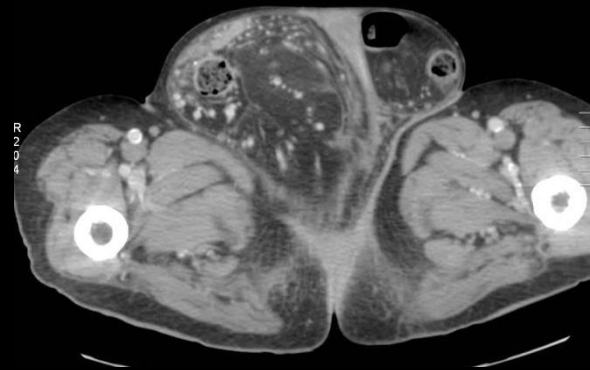
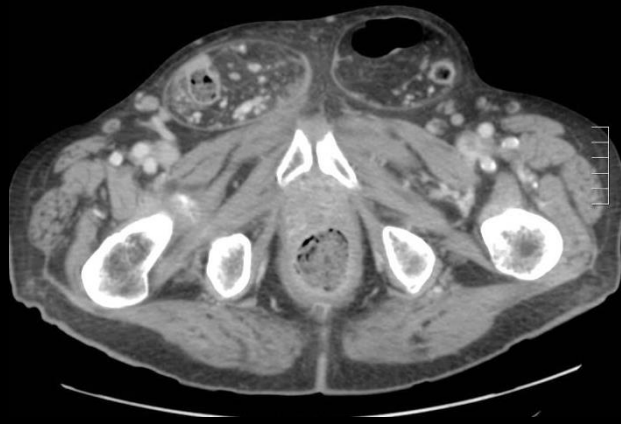

**anse incarcerée
hernie étranglée**



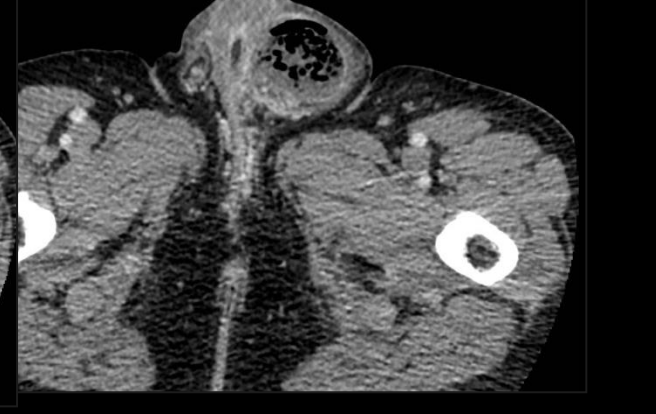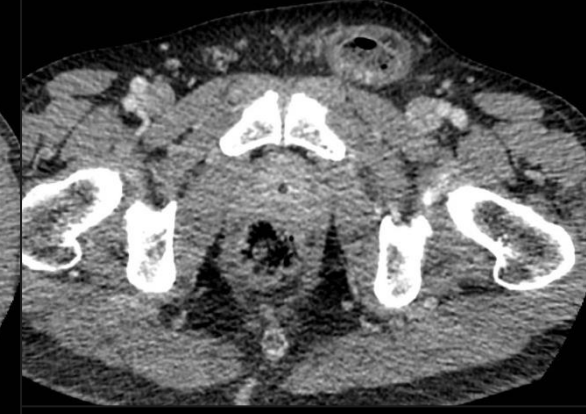
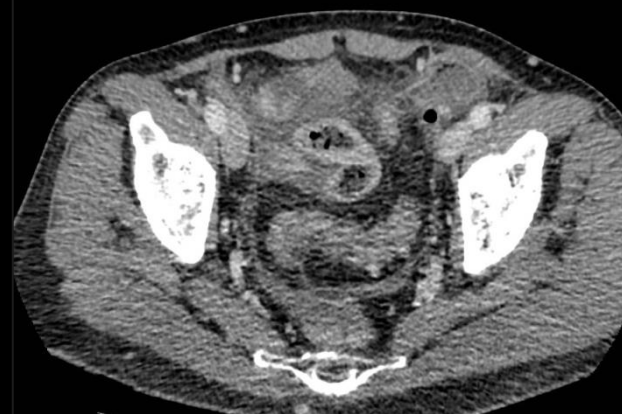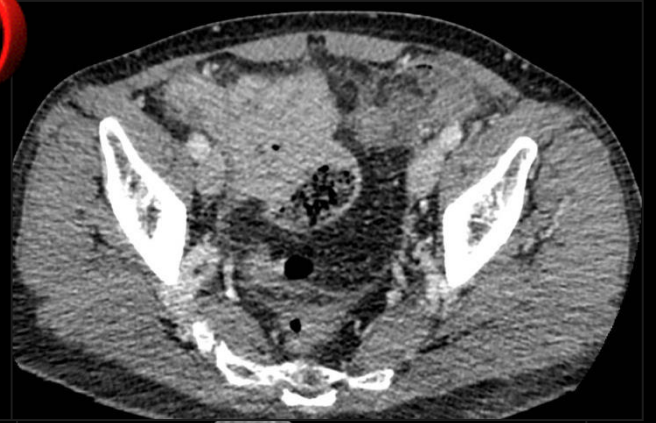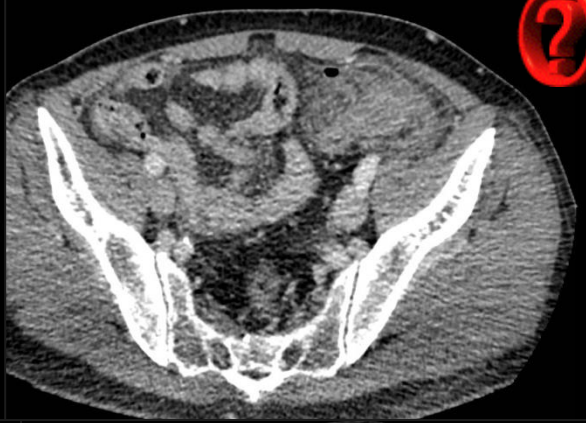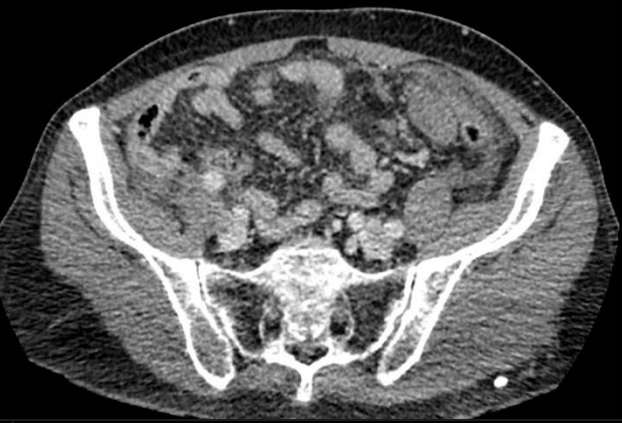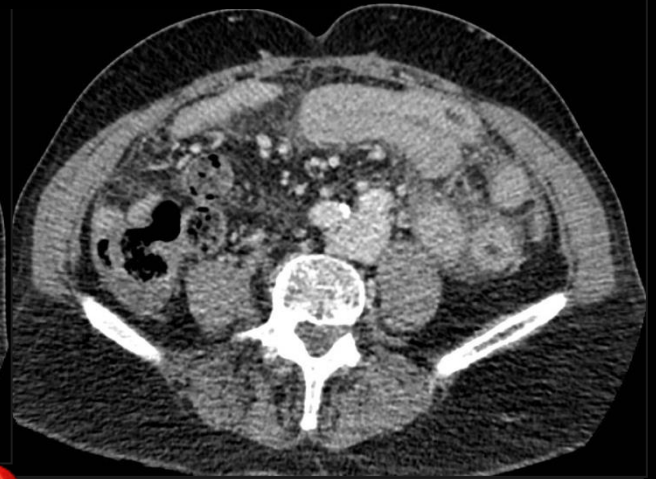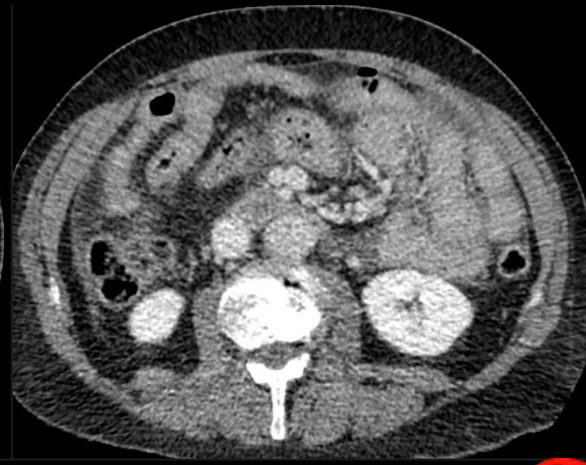
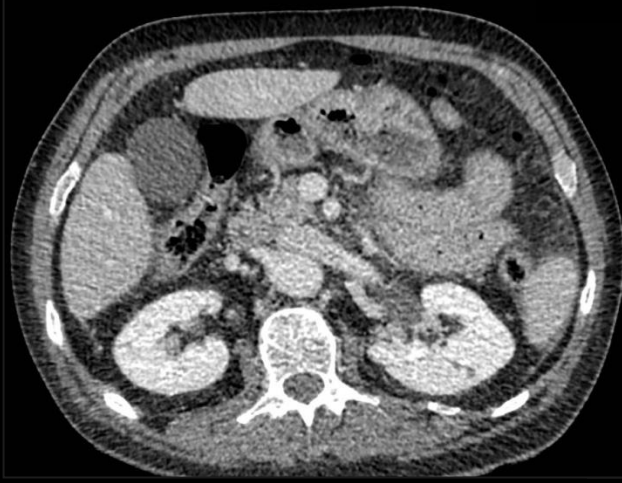


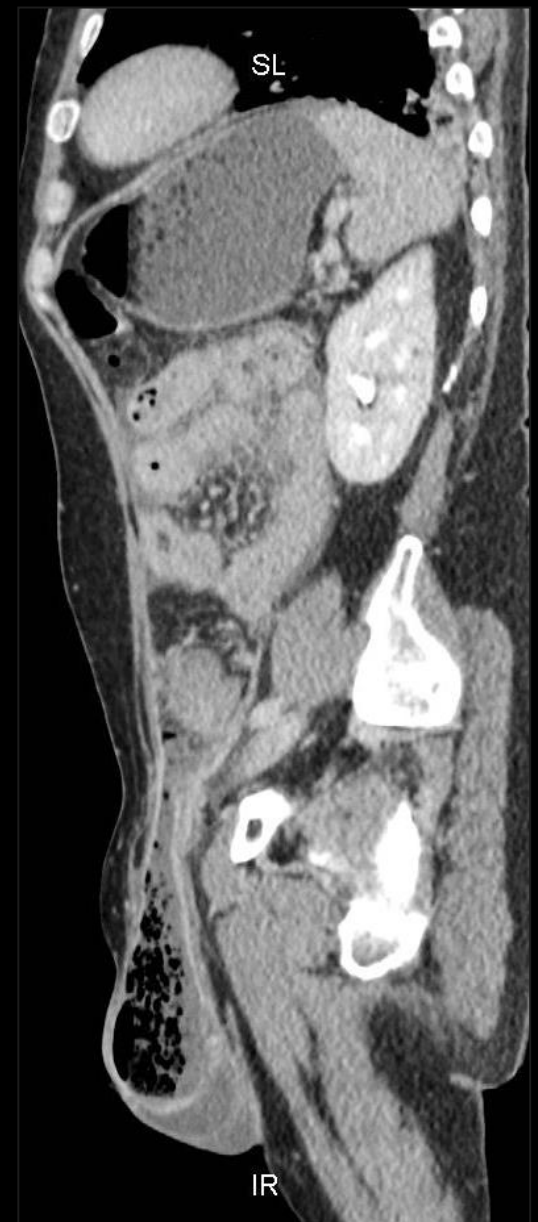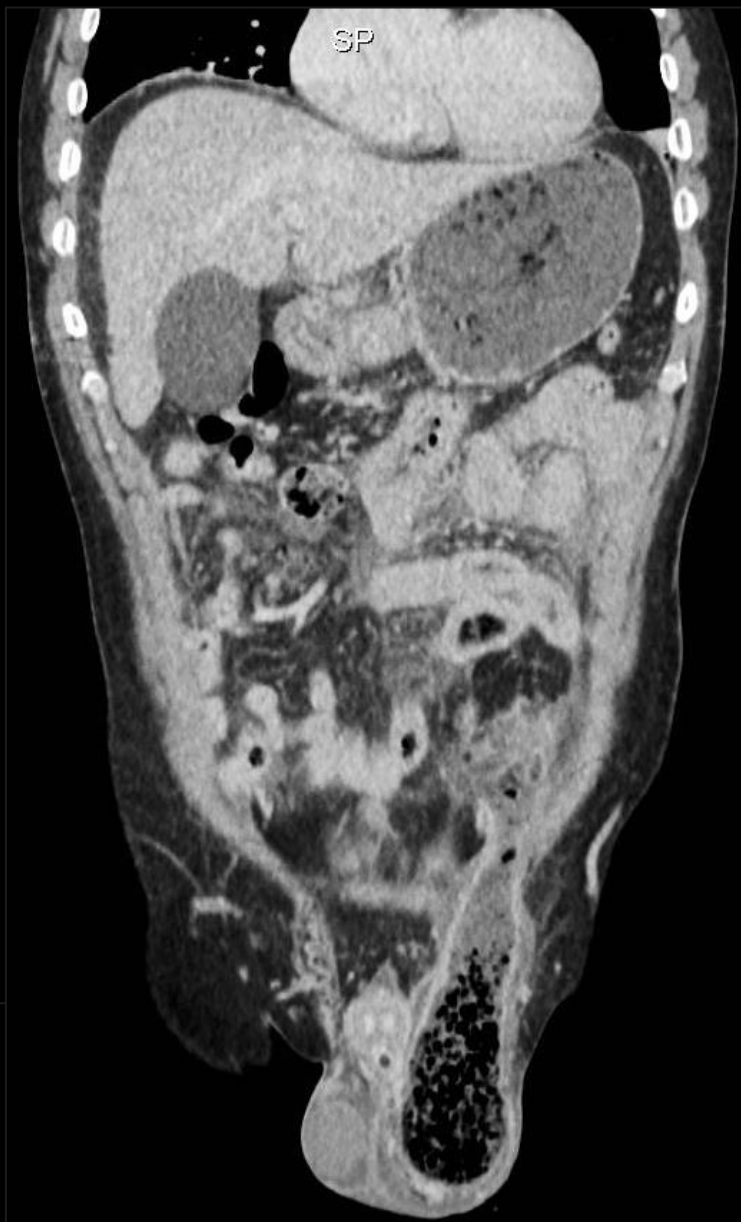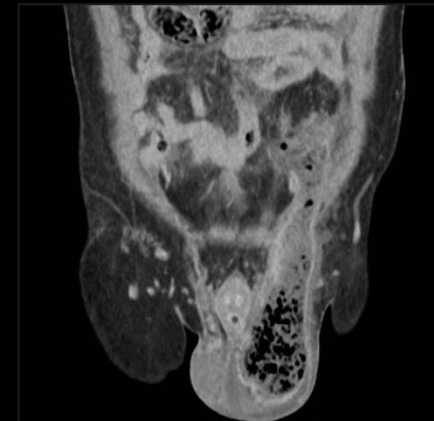
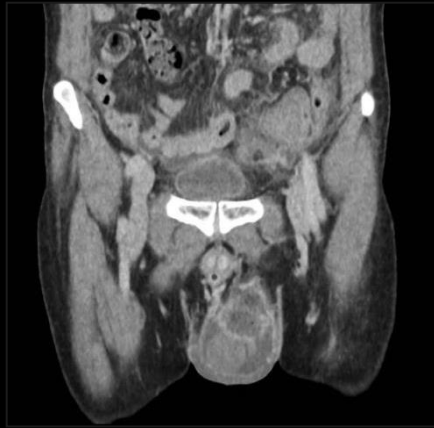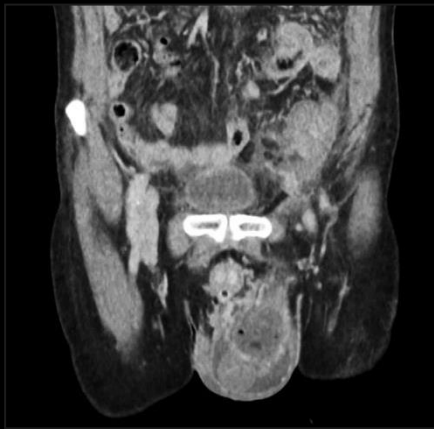volumineuse hernie inguino-scrotale oblique externe à contenu épiploïque , grêle et colique + hydrocèle



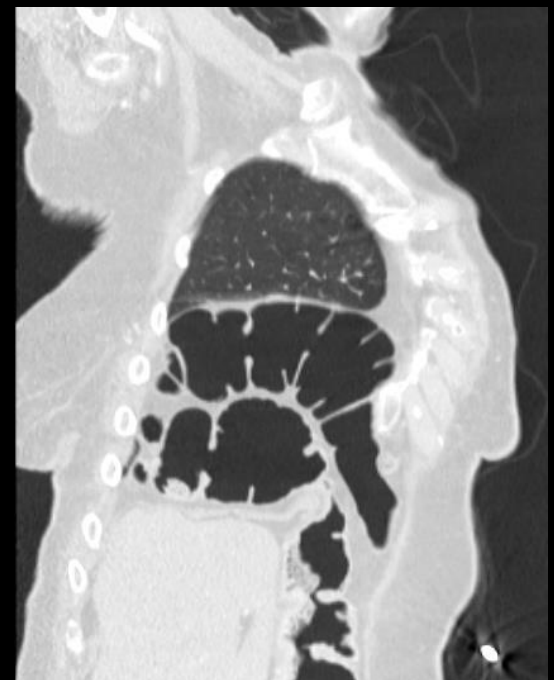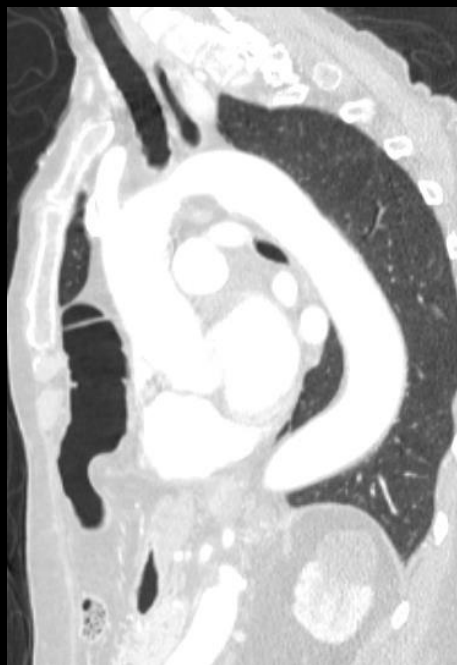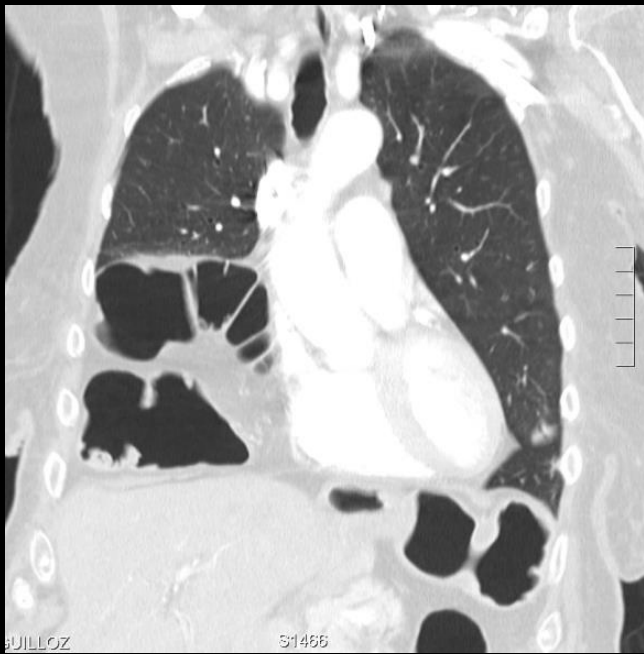
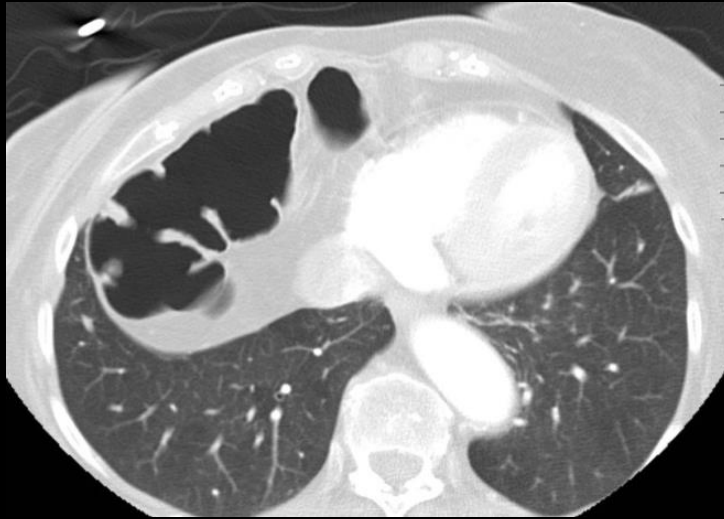
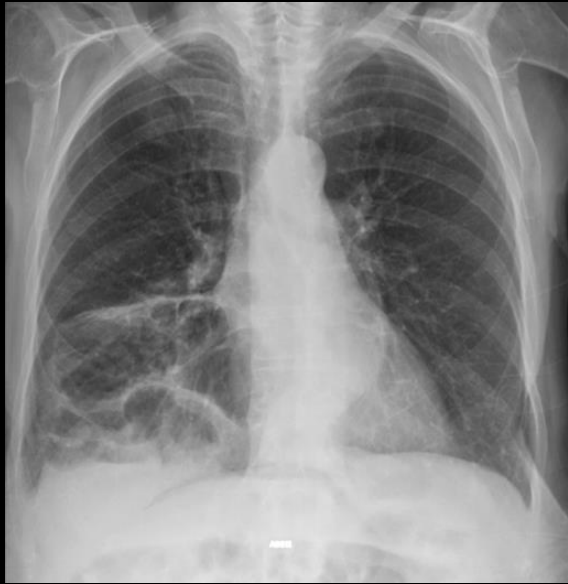volumineuse hernie inguino-scrotale oblique externe à contenu épiploïque , grêle et colique +hydrocèle

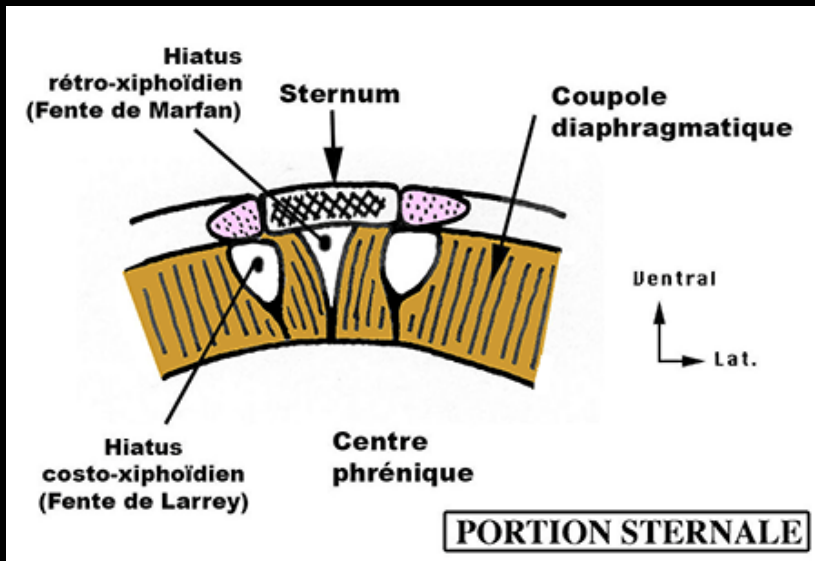
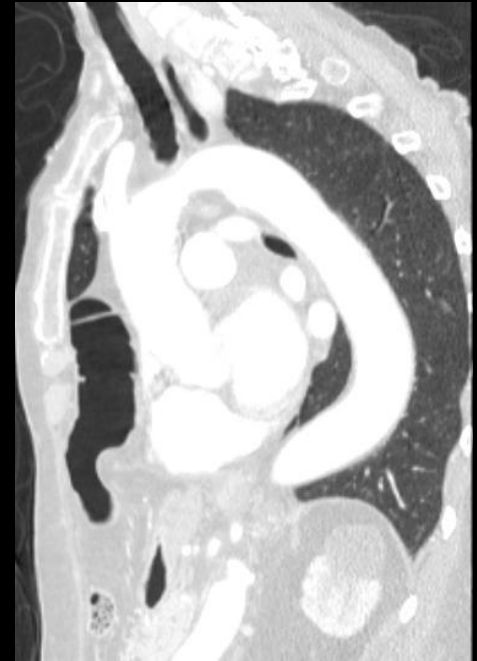
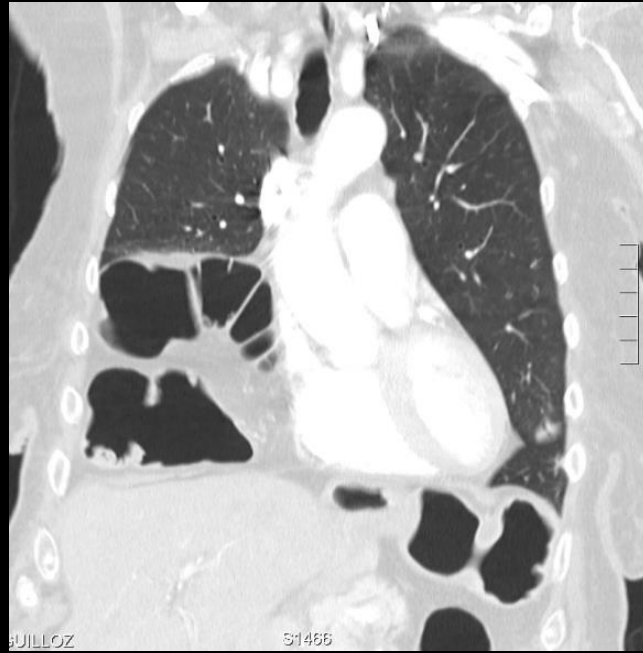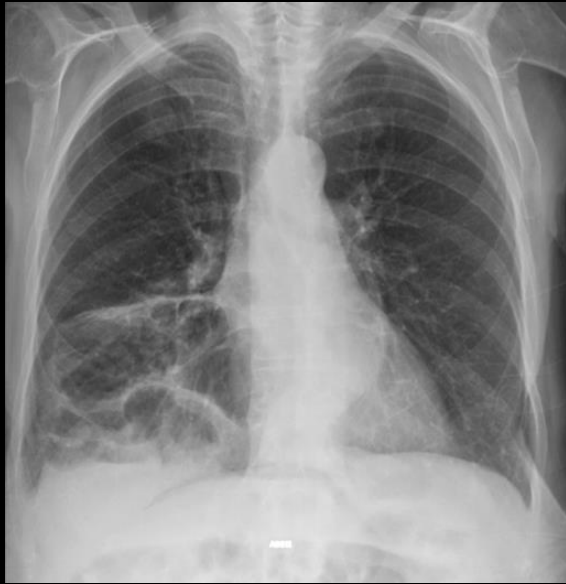traumatisme inguinal (écrasement)





**rupture du sigmoïde intra-herniaire après contusion
inguinale (hernie inguinale oblique externe)**



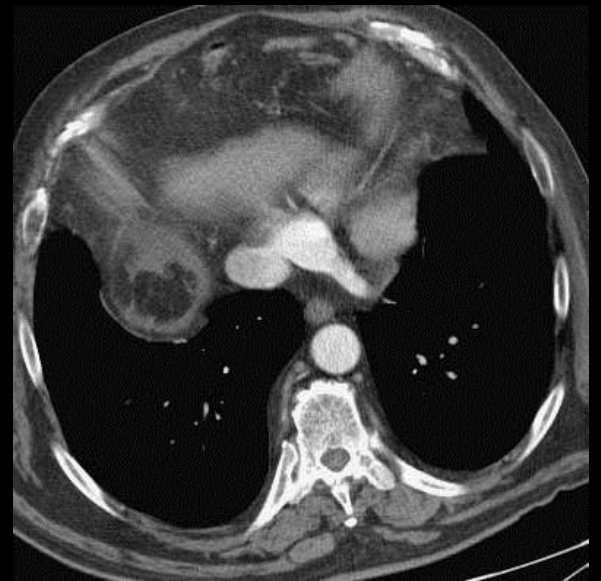
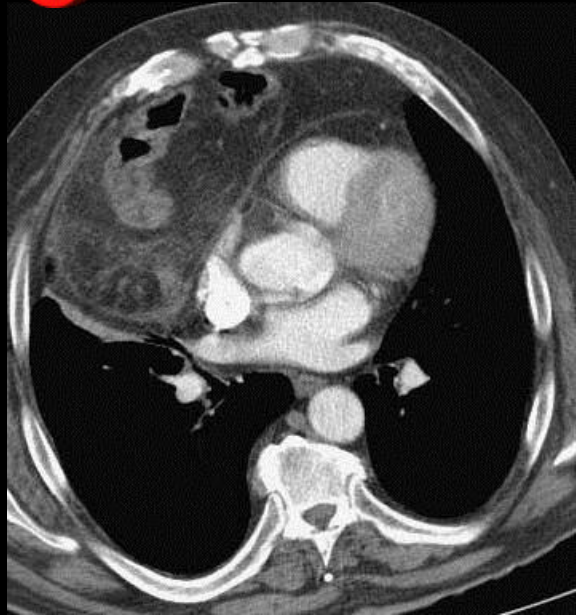
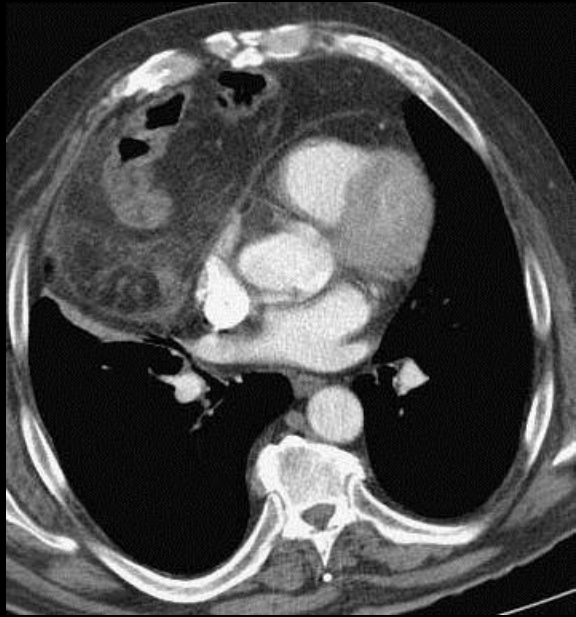
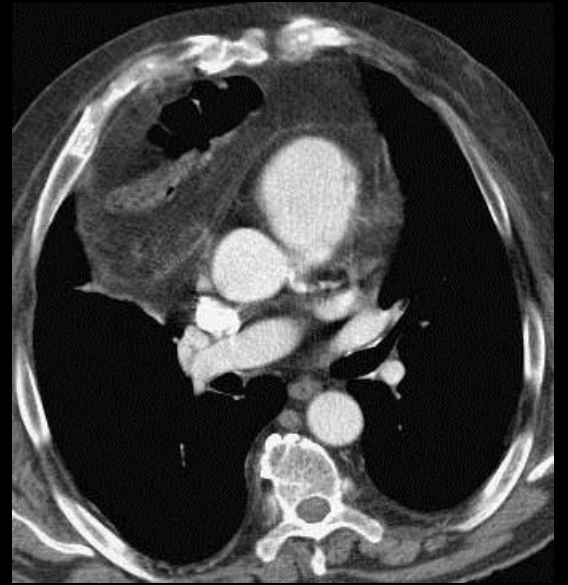
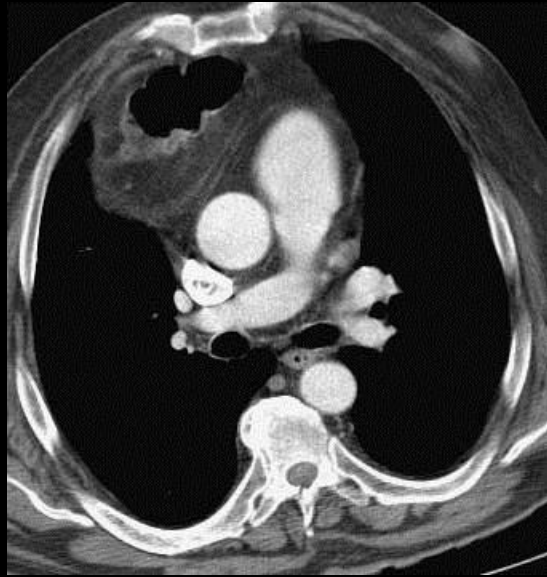
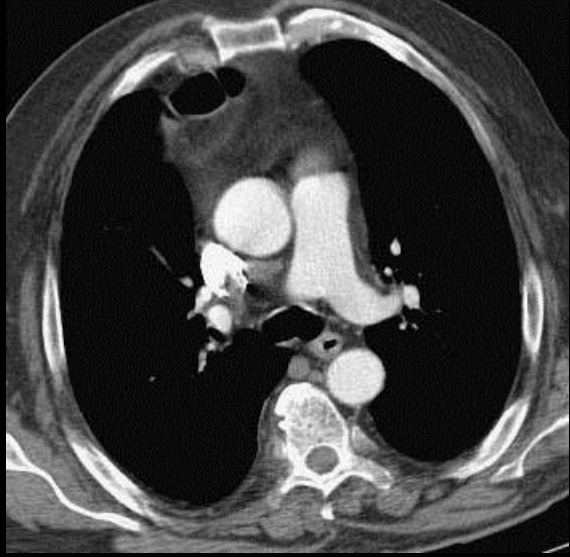


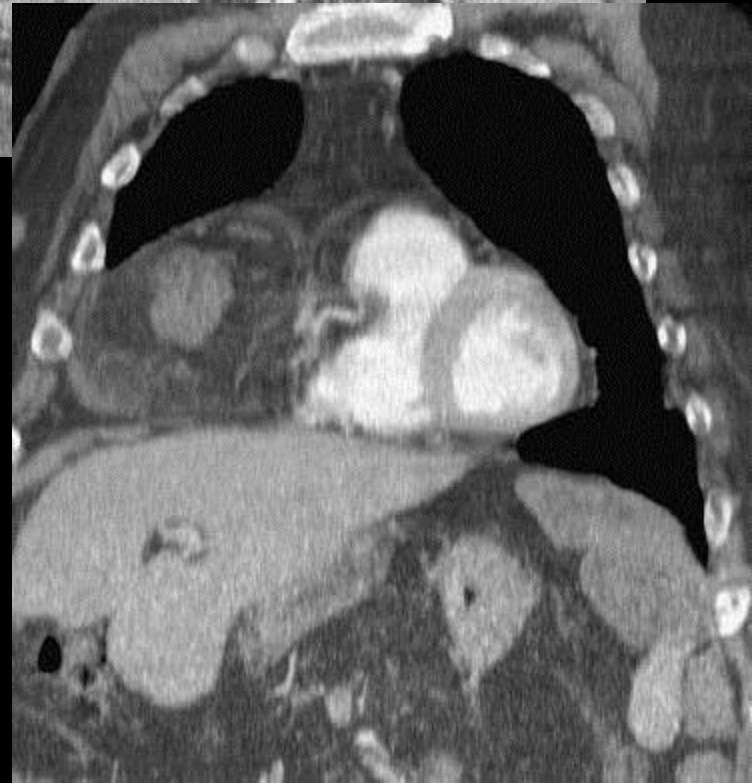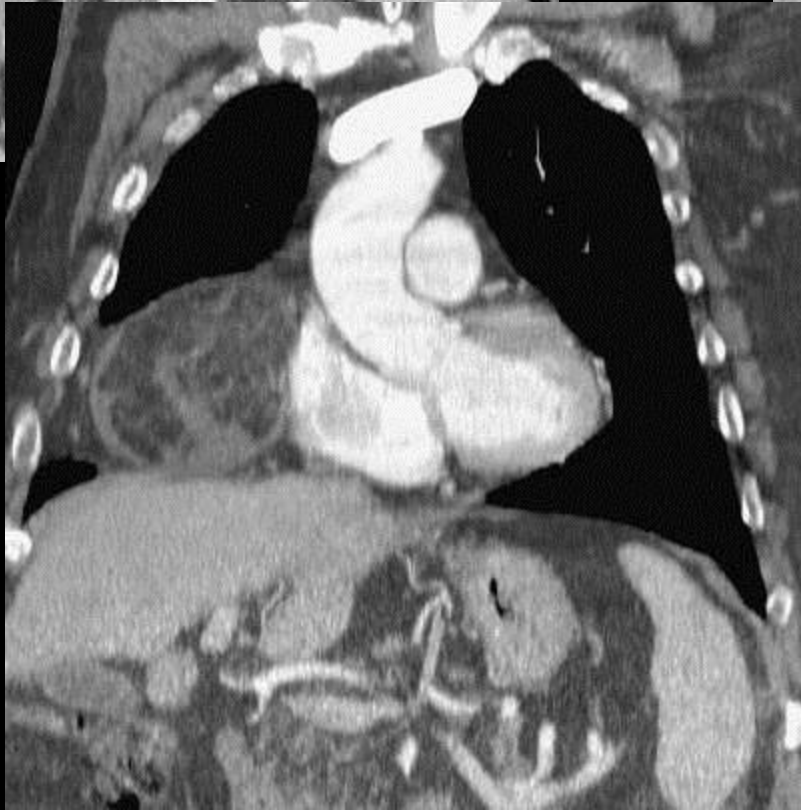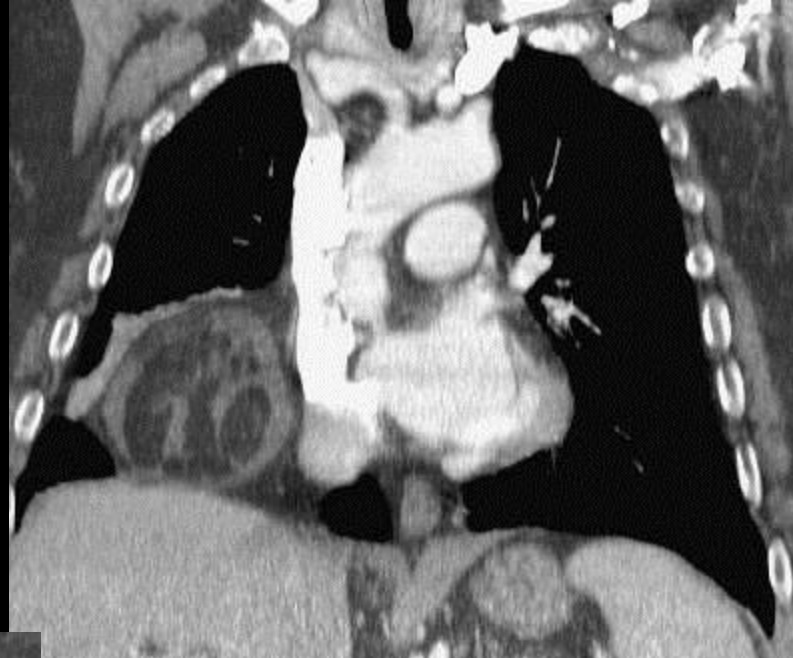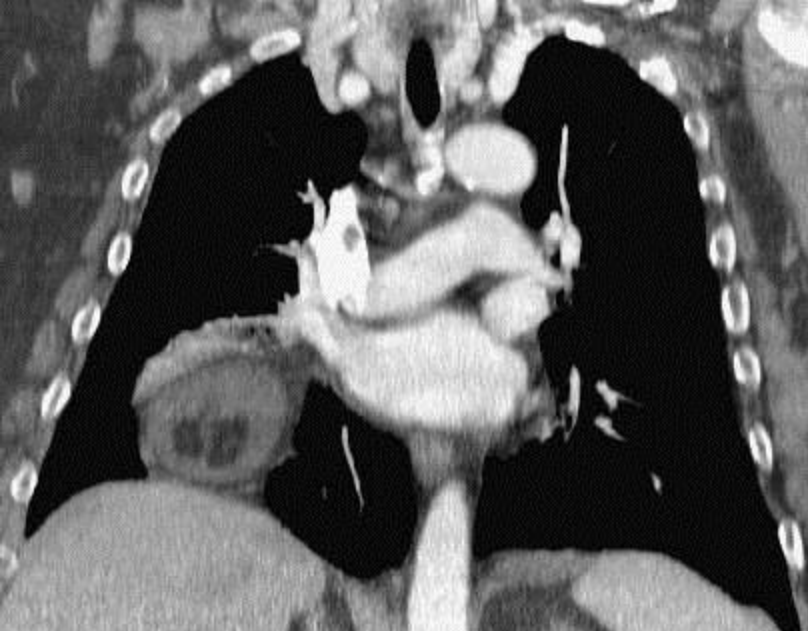**volumineuse hernie
médiastinale antérieure
(rétro-costo-xyphoïdienne)**

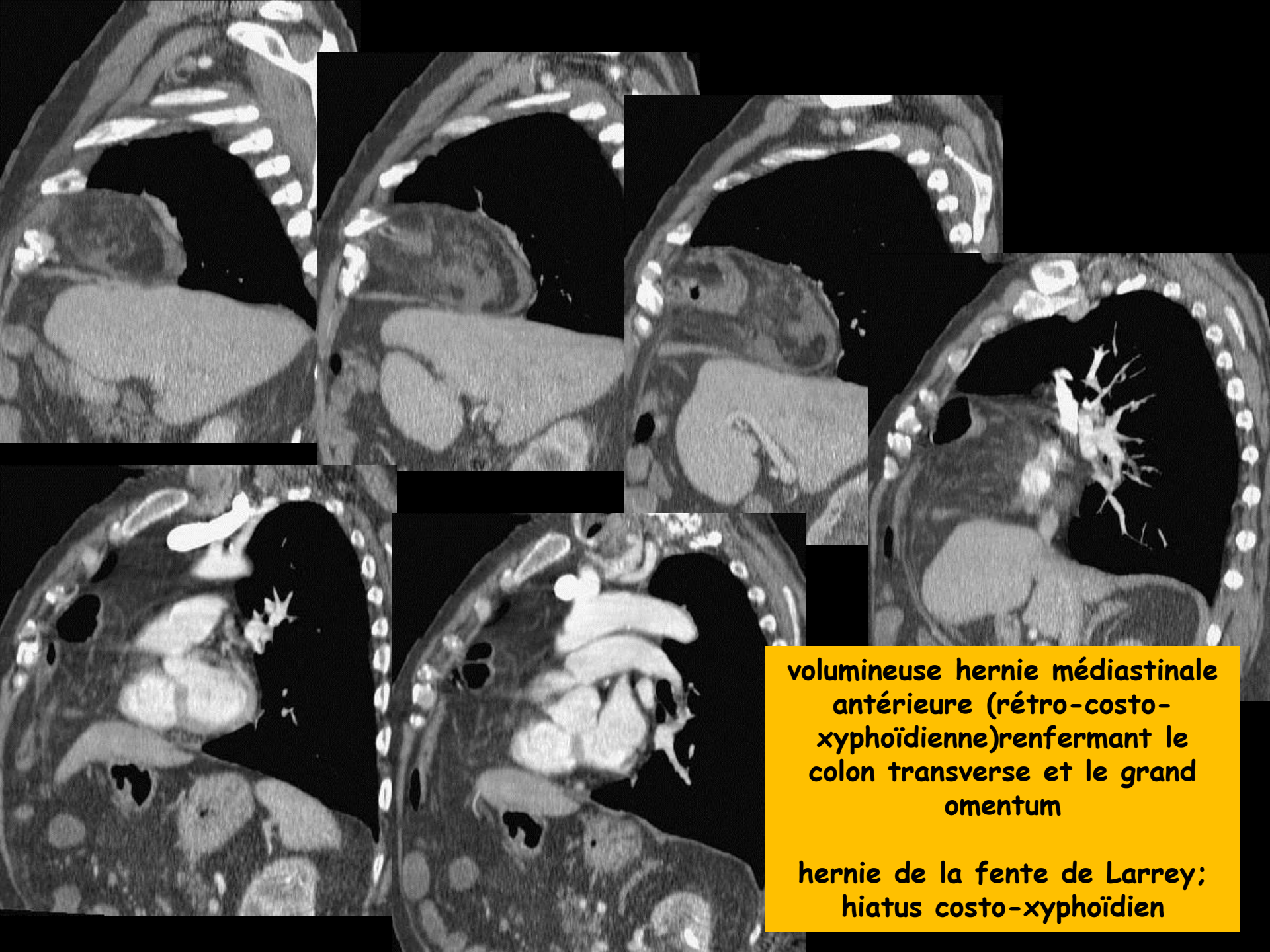
**hernie de Morgagni fente de
Marfan (médiane)**

hiatus rétro-xyphoïdien

**hernie de la fente de Larrey;
hiatus costo-xyphoïdien**

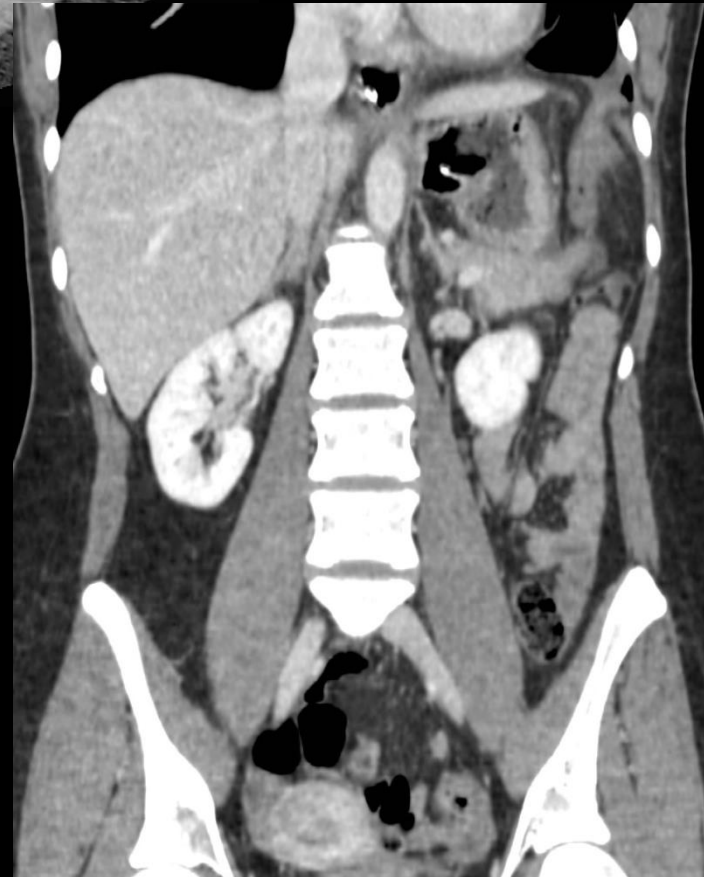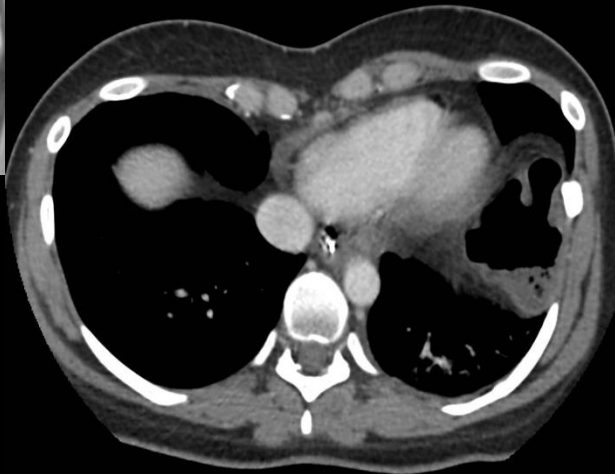

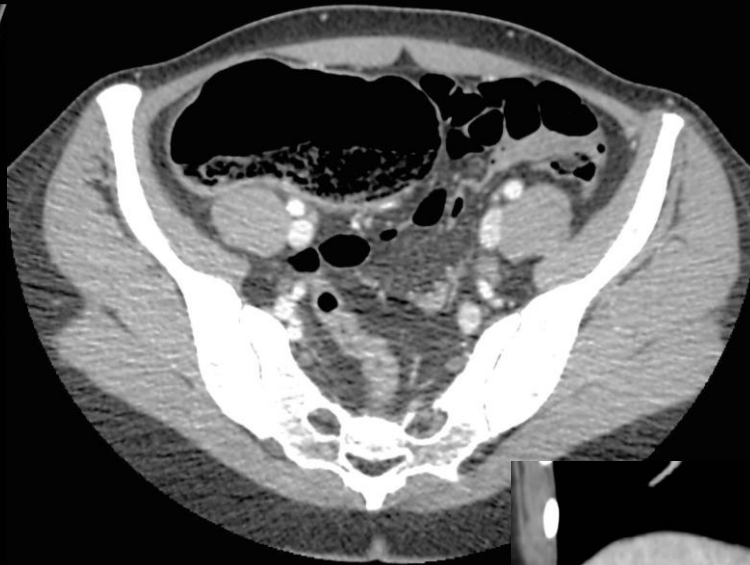
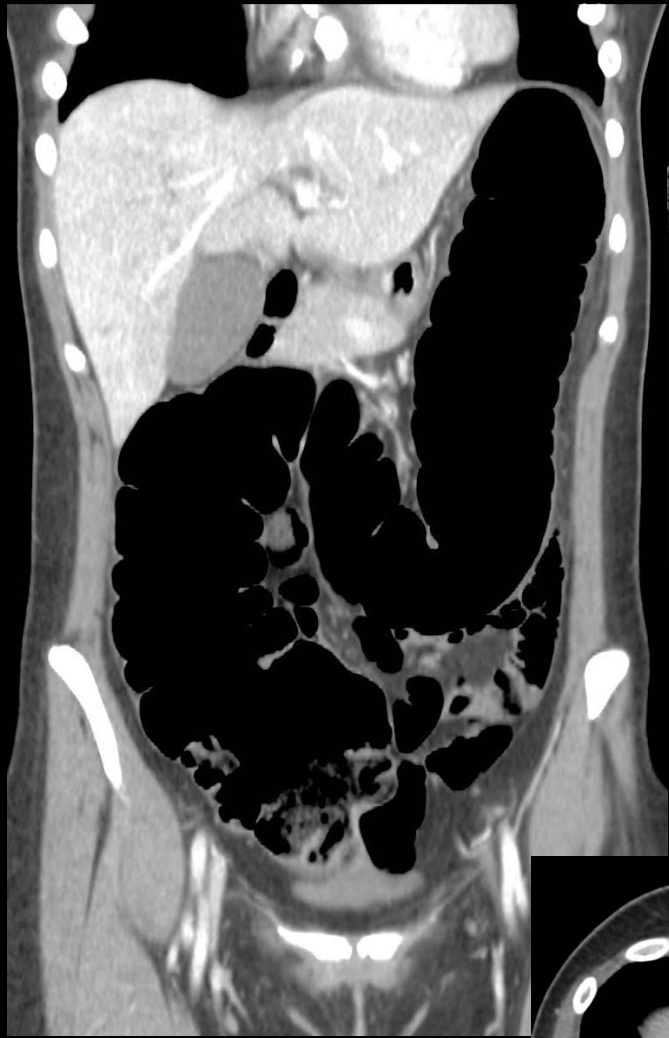


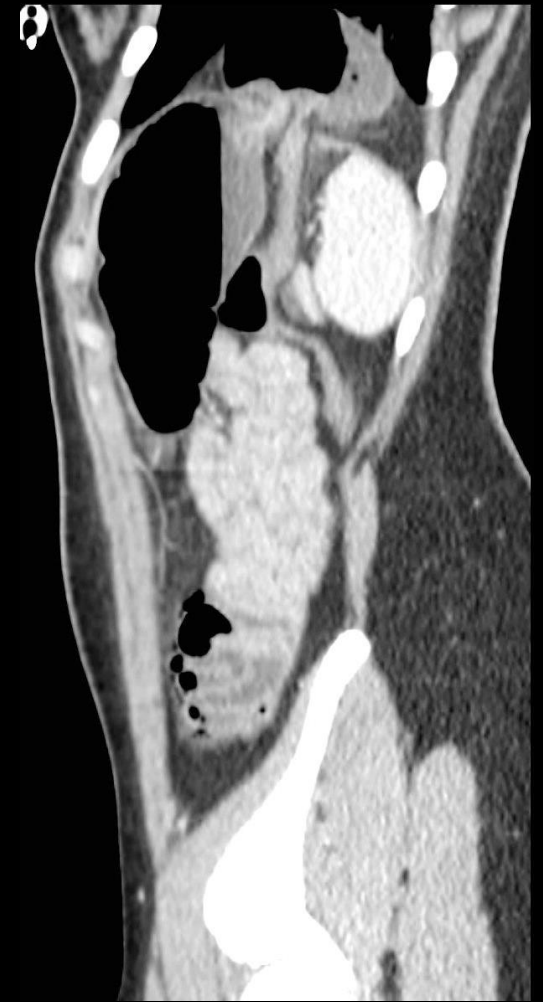
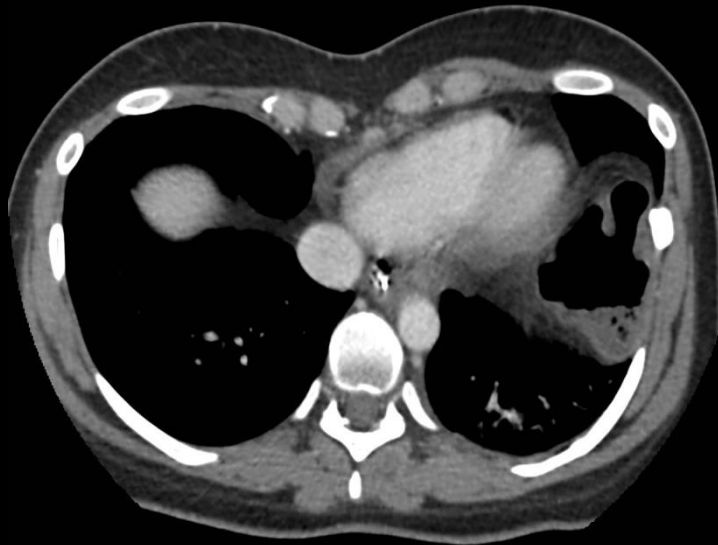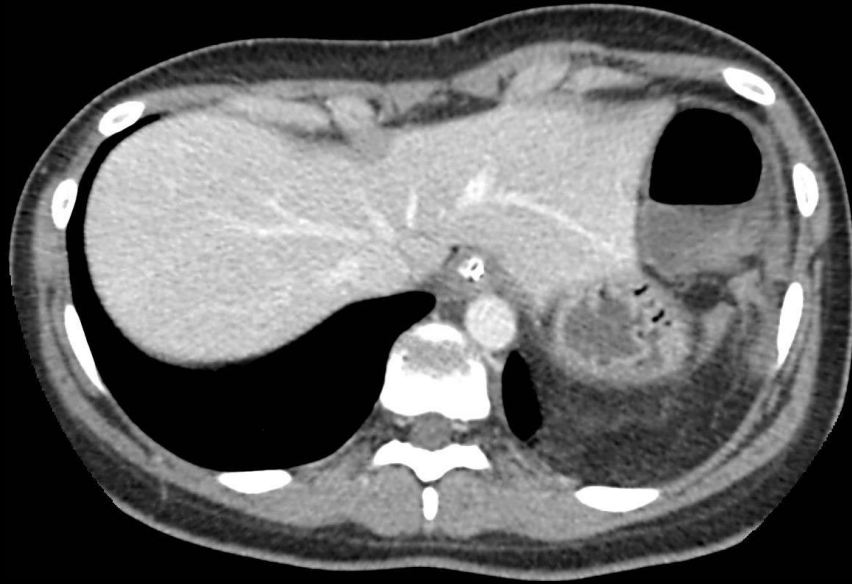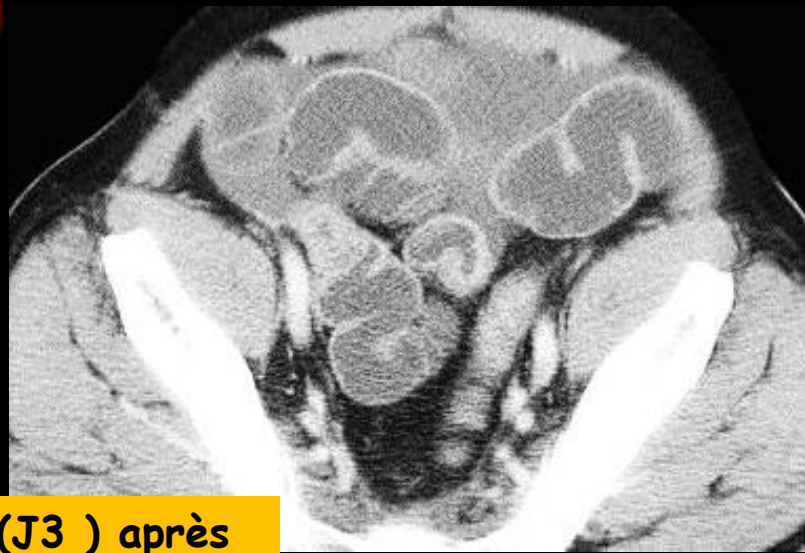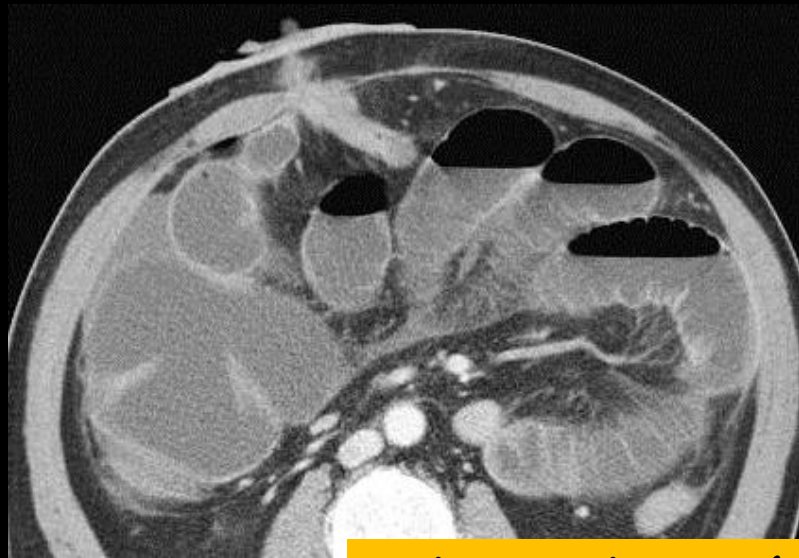
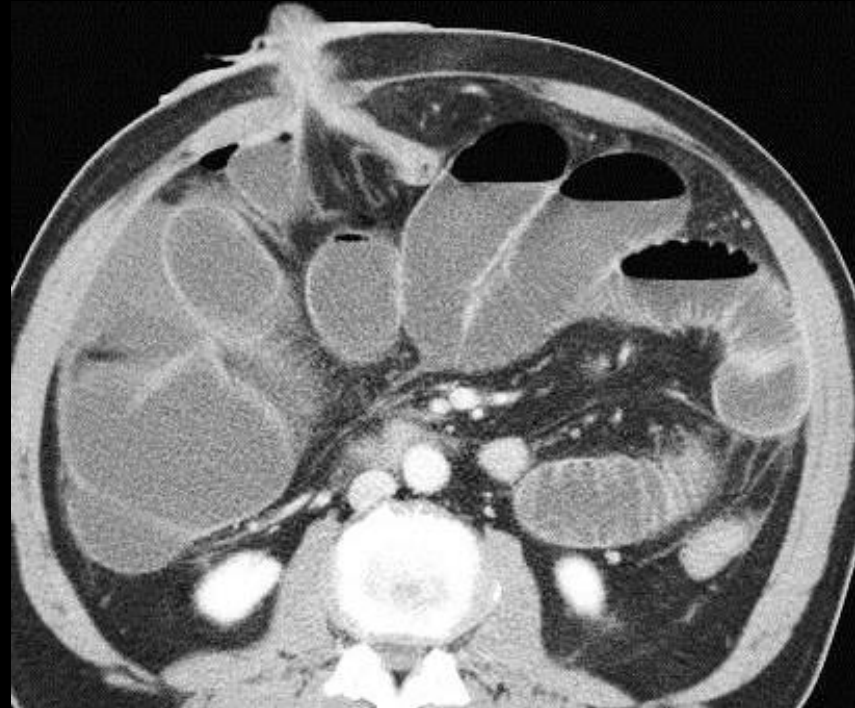
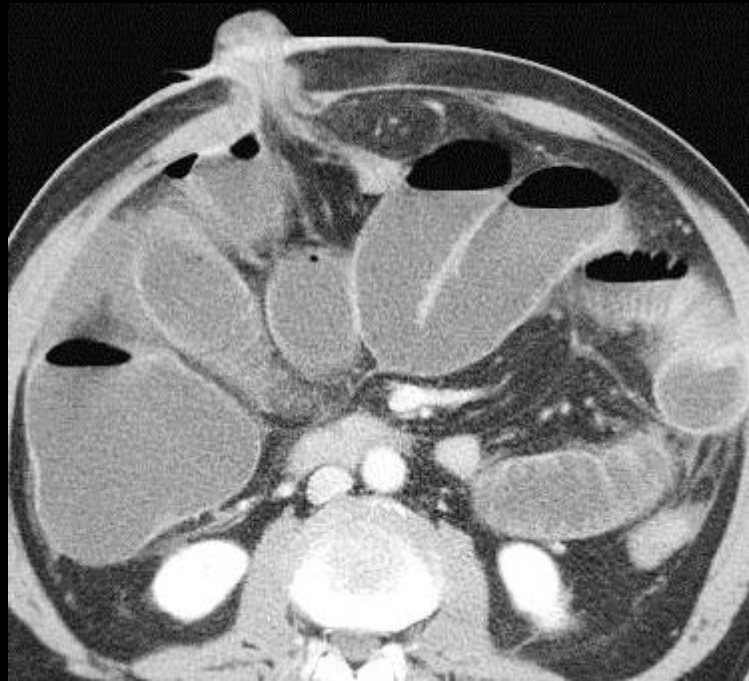
**volumineuse hernie médiastinale
antérieure (rétro-costo-
xyphoïdienne) renfermant le
colon transverse et le grand
omentum**

**hernie de la fente de Larrey;
hiatus costo-xyphoïdien**



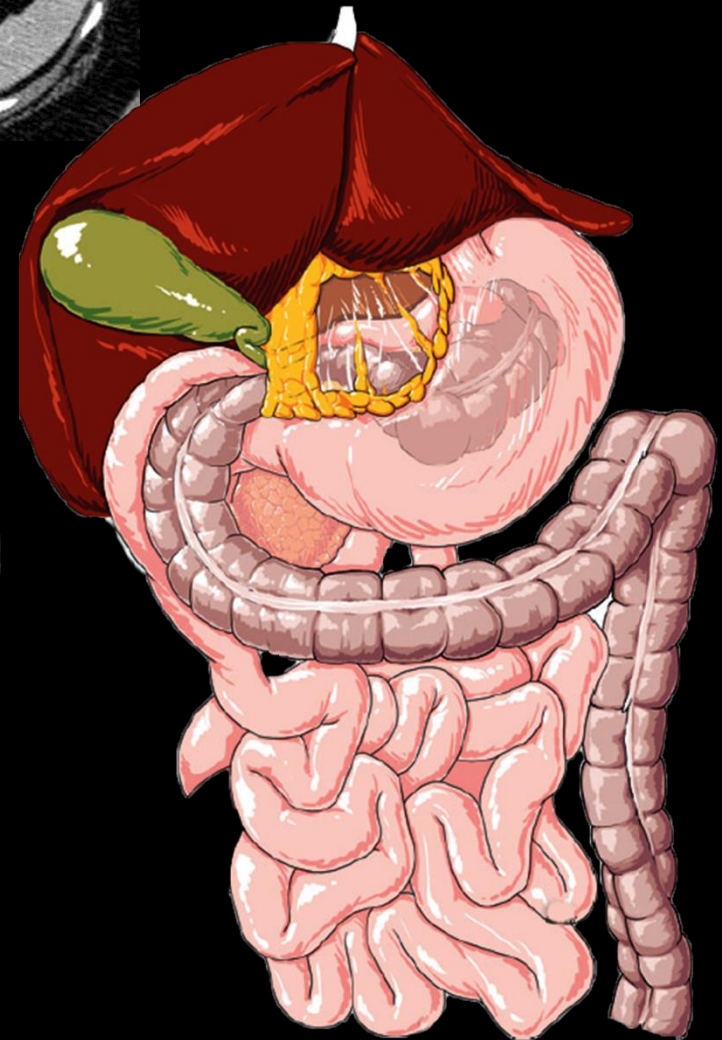
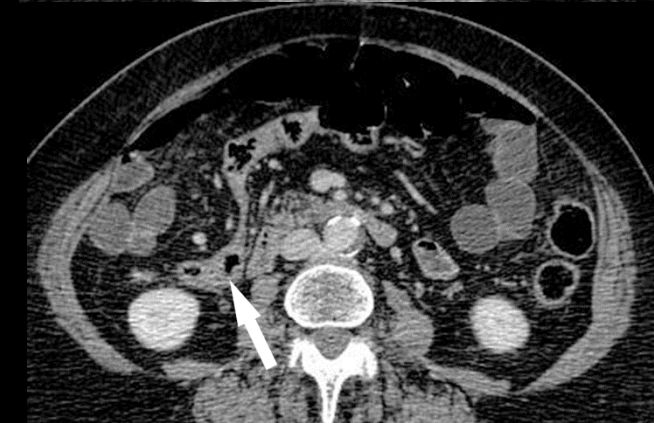
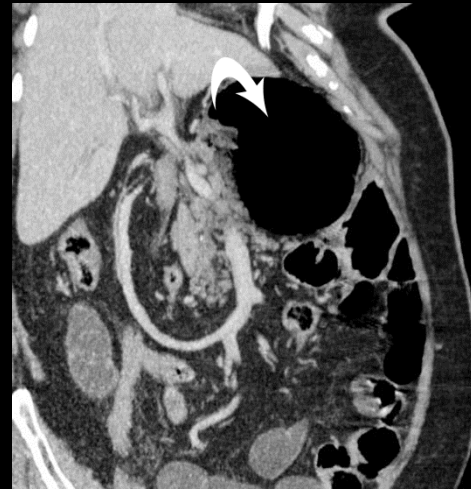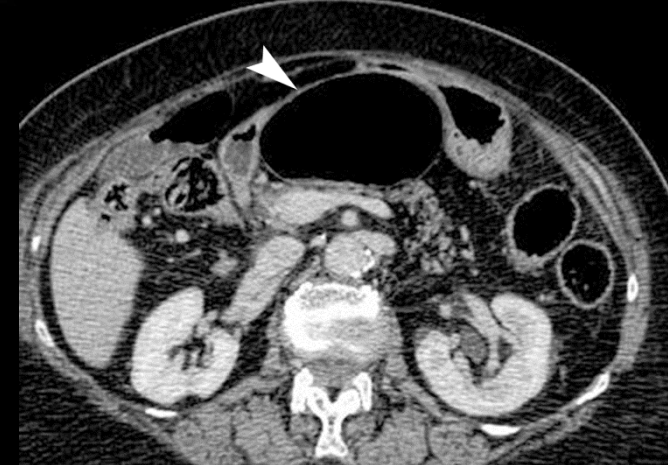

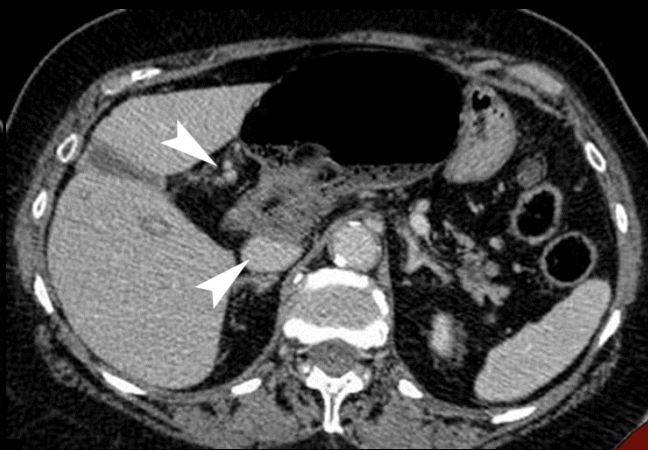
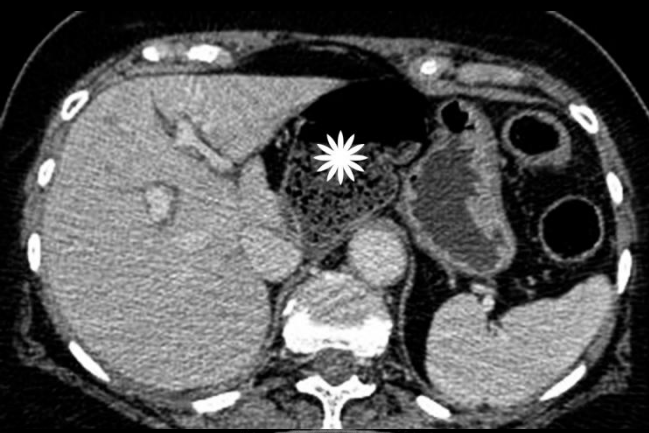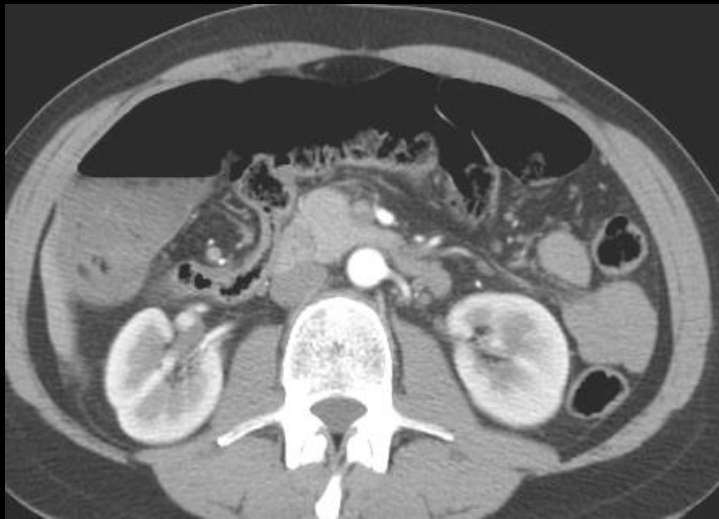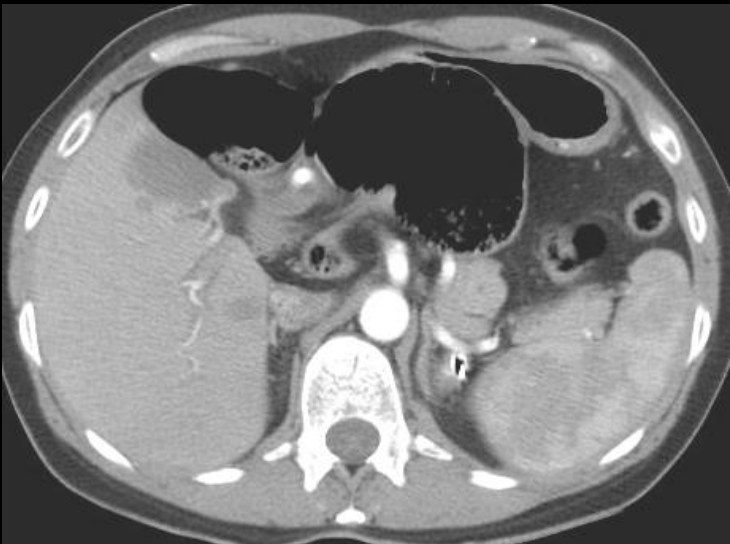
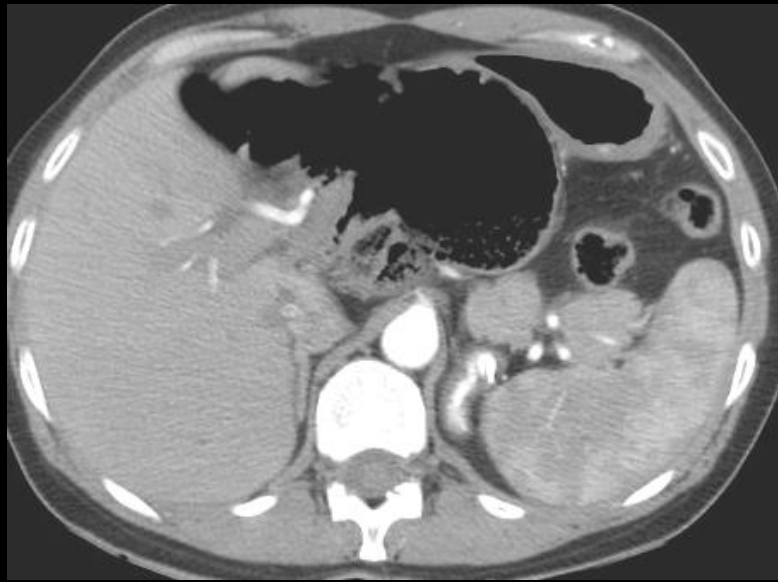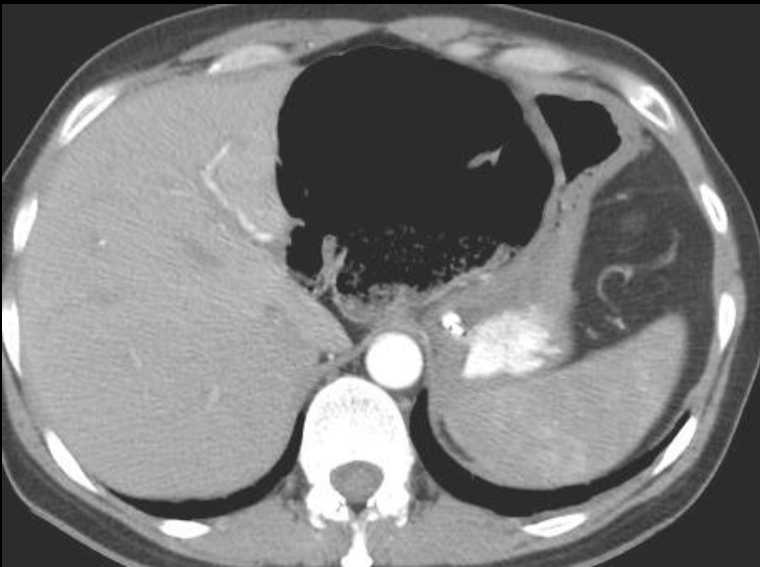occlusion colique par incarceration de l'angle gauche dans une rupture ancienne de l'hémicoupole gauche (chute de cheval avec piétinement)



occlusion colique précoce (J3) après colostomie transverse (Adk rectal)

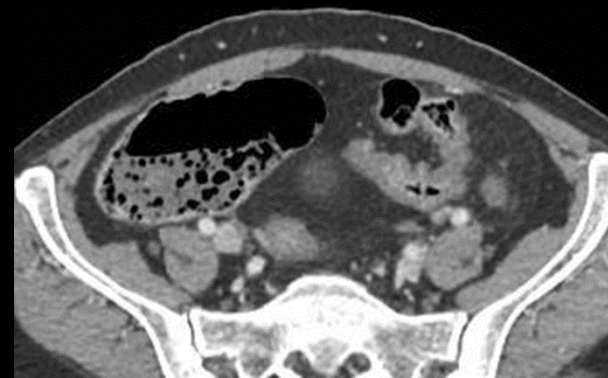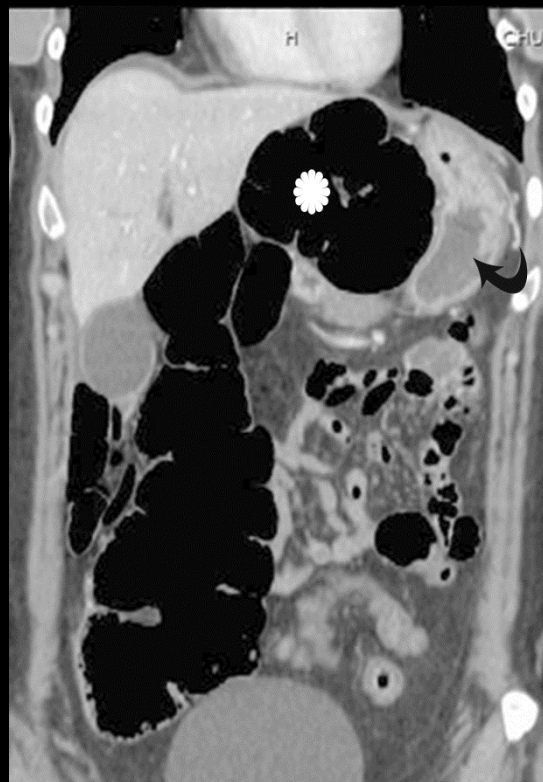
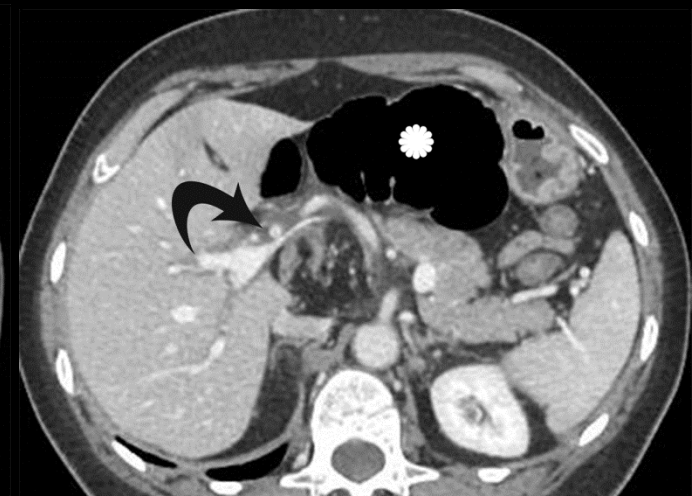
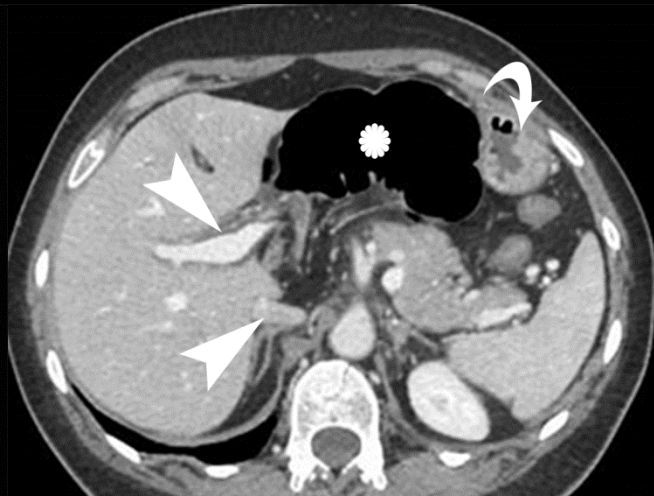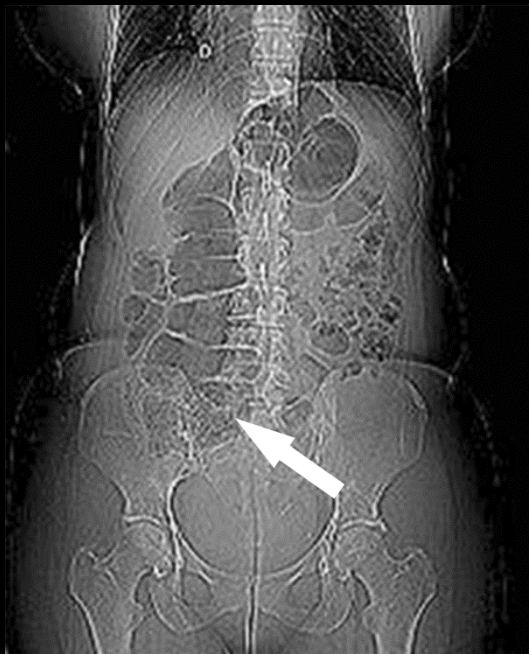3-1-1-4 hernies internes





Obs. JL Bertrand CH Perpignan

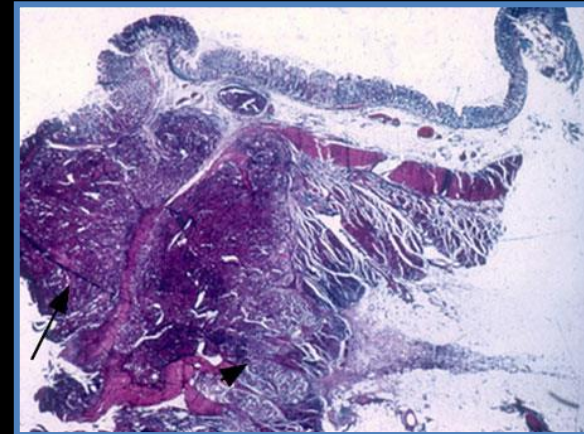
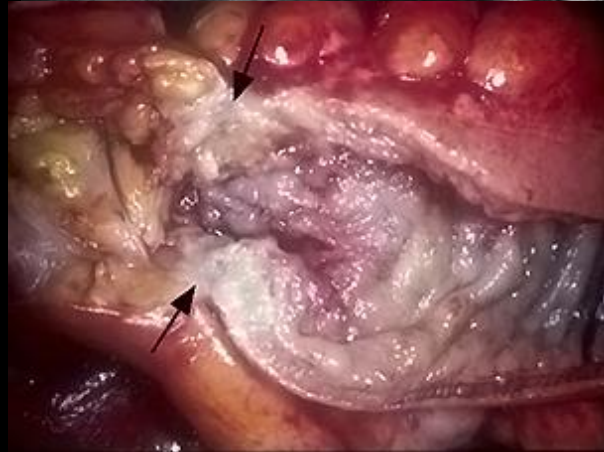
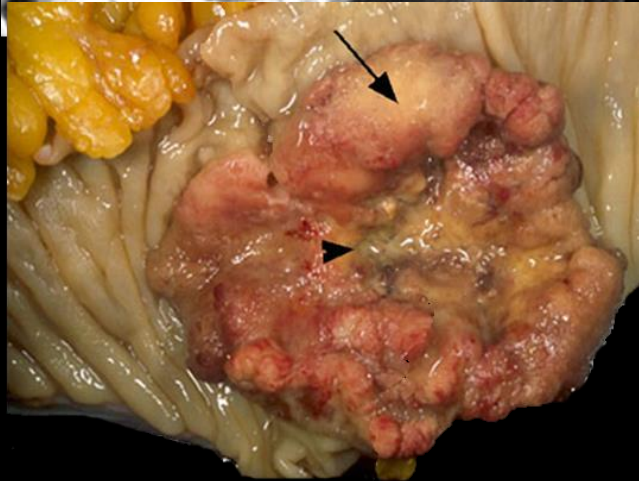
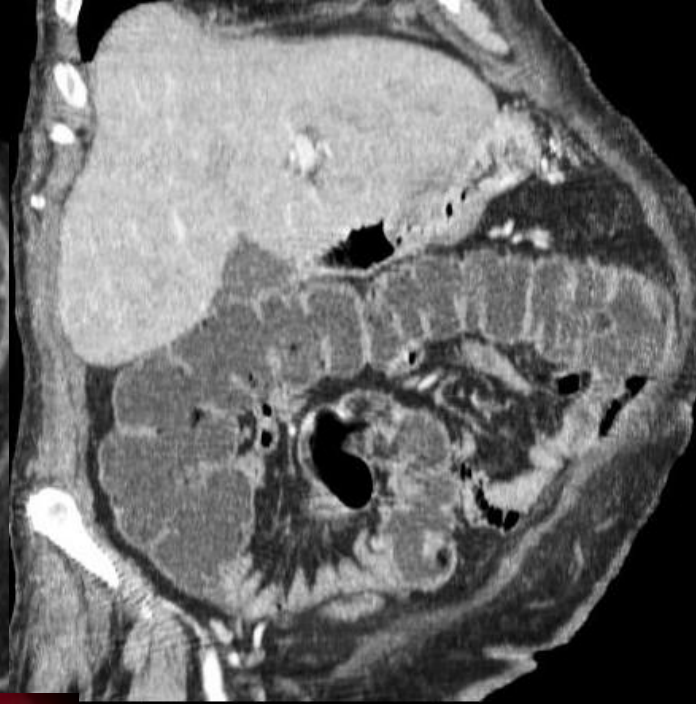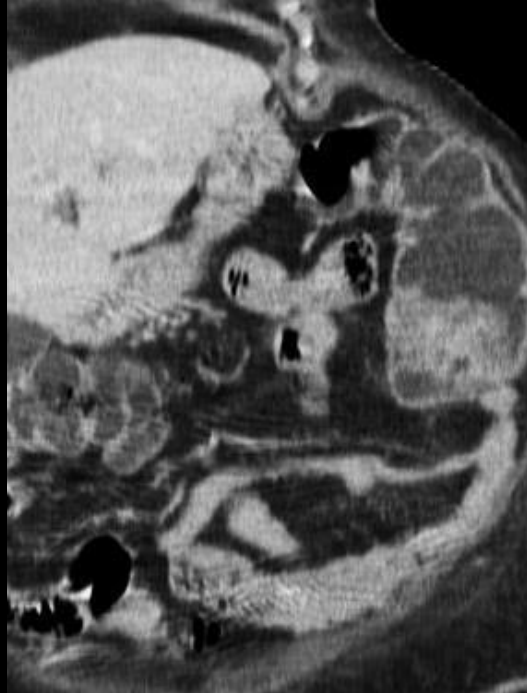
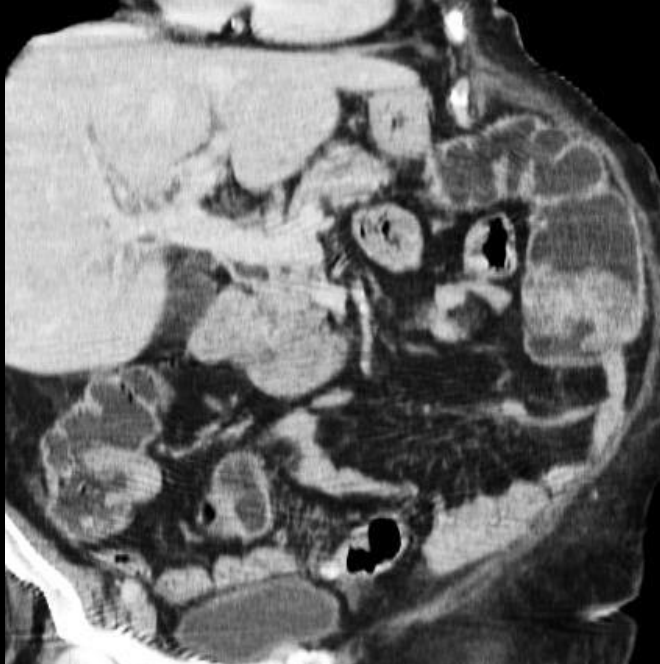
**hernie du carrefour iléo-caecal
par le hiatus omental; Blandin
type II)**

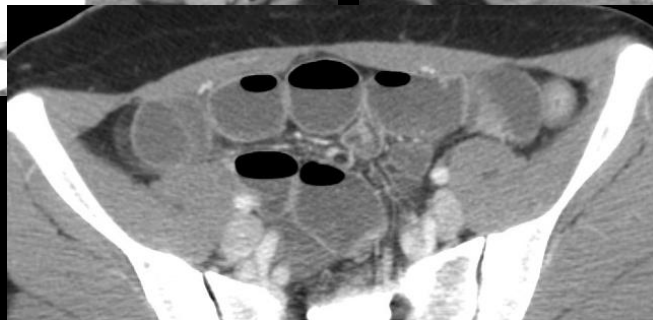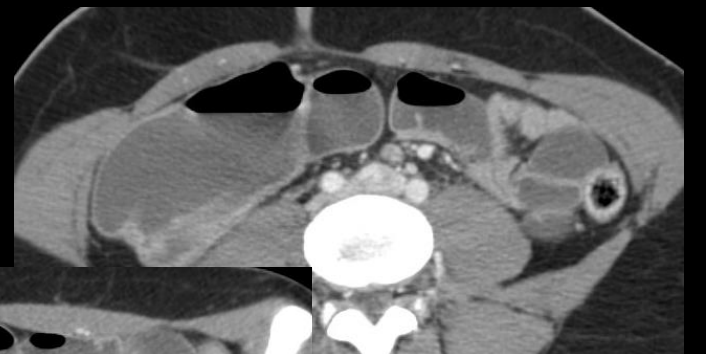
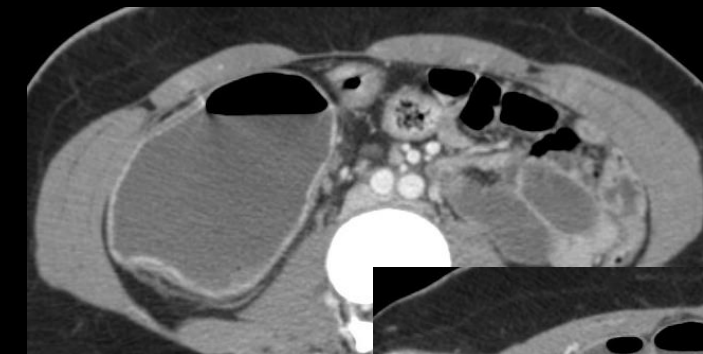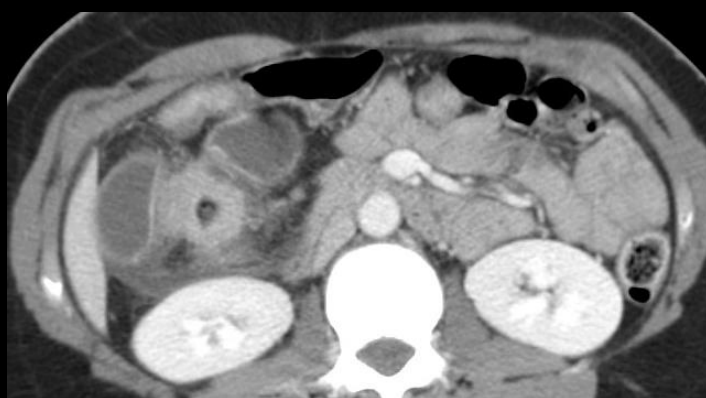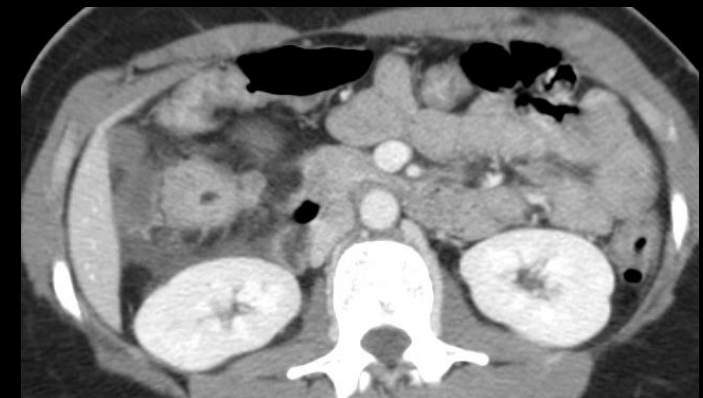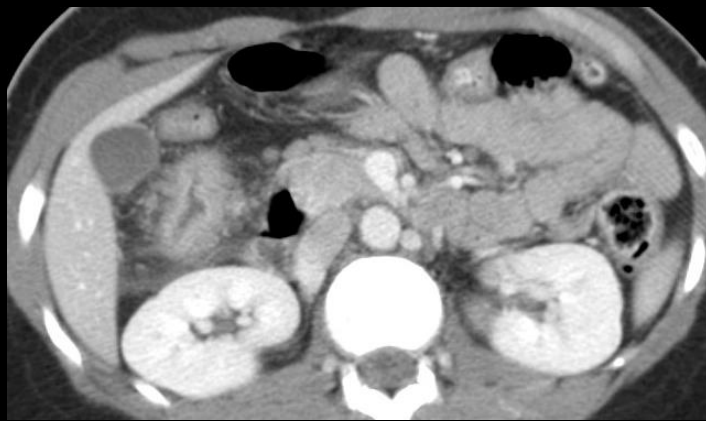


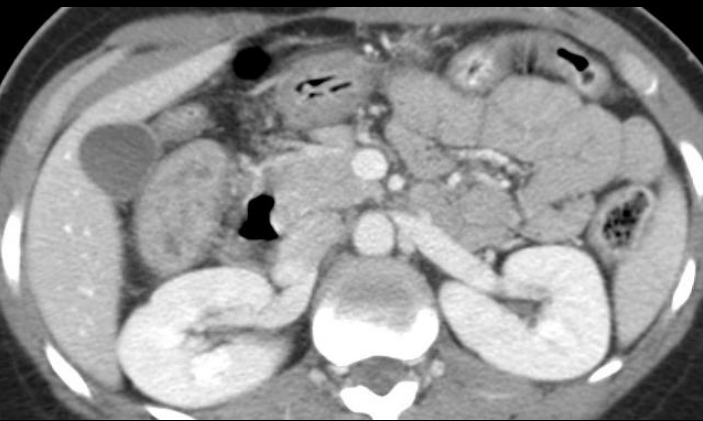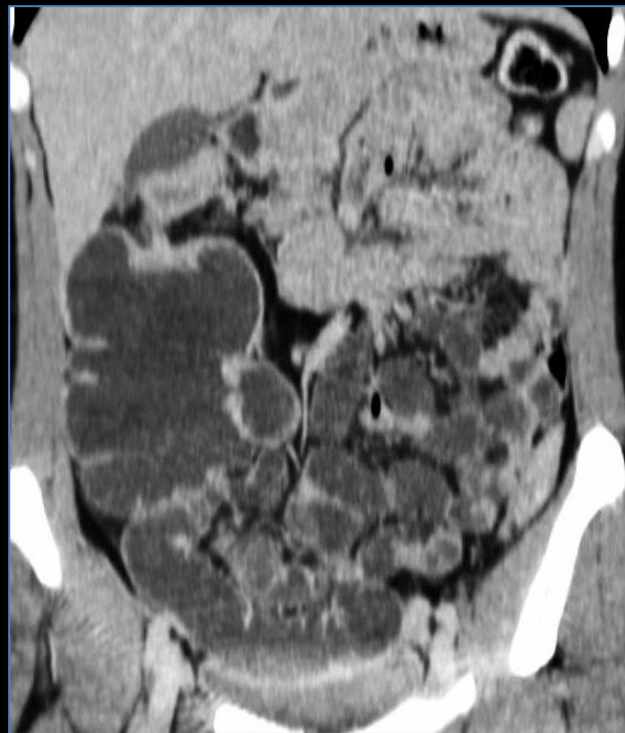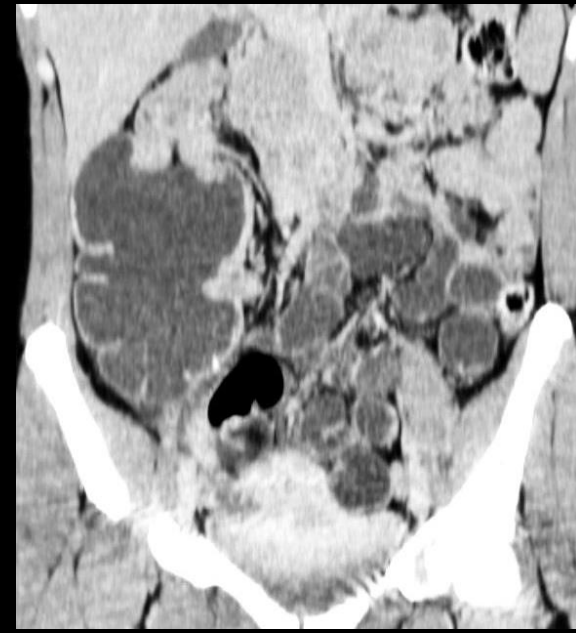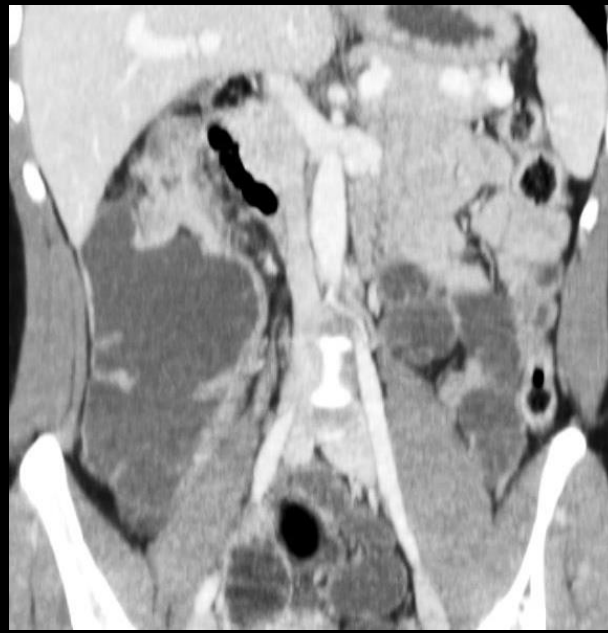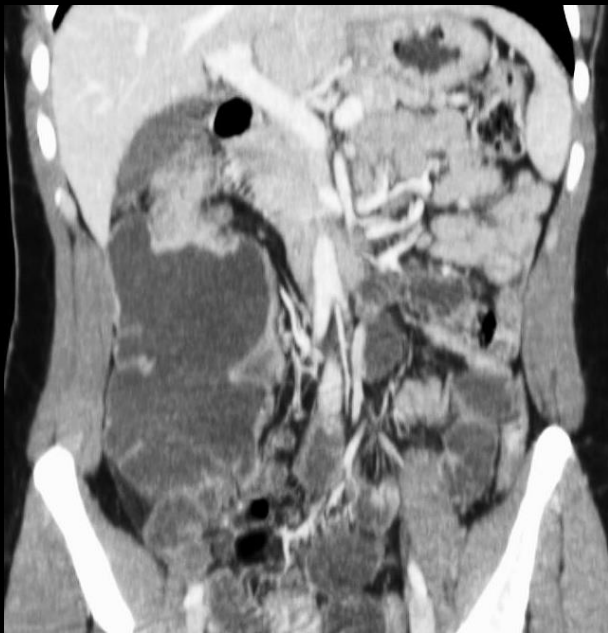**hernie du côlon
transverse par.le
hiatus de Winslow
hernie de Blandin
type III**

3-1-2 occlusions colo-rectales d'origine pariétale

3-1-3-1 lésions pariétales sténosantes colo-rectales tumorales

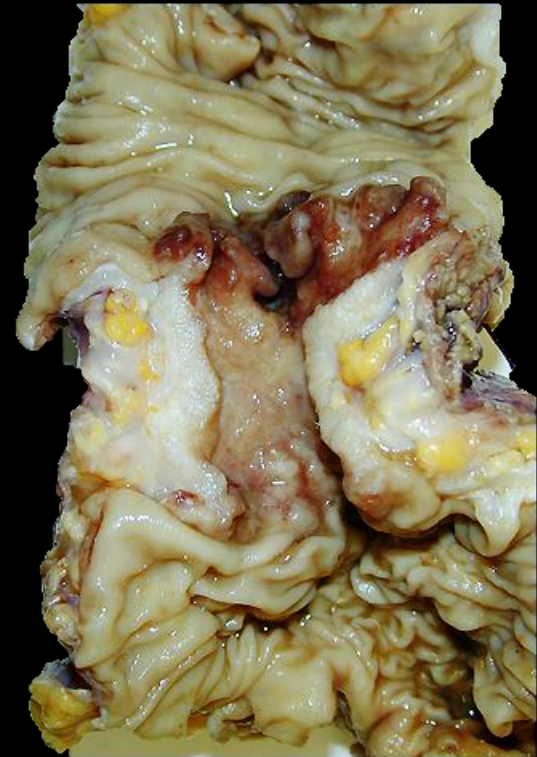

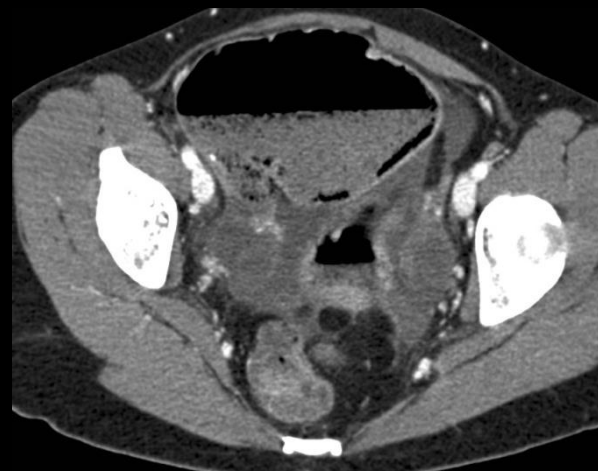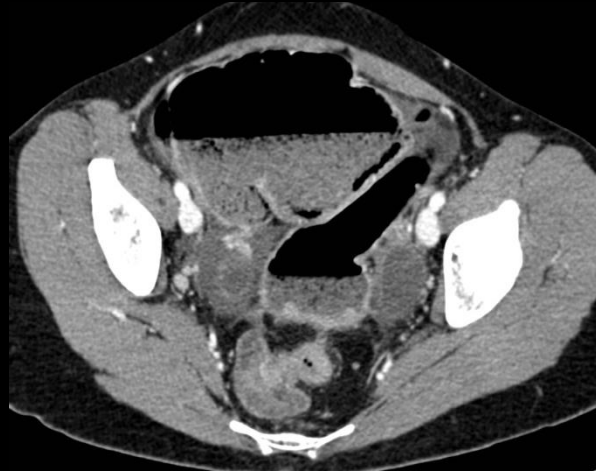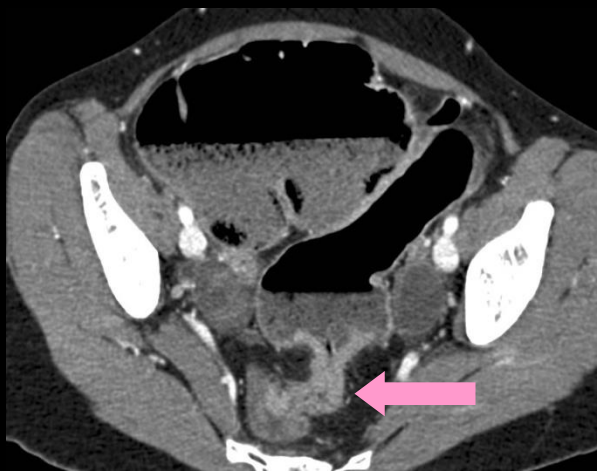
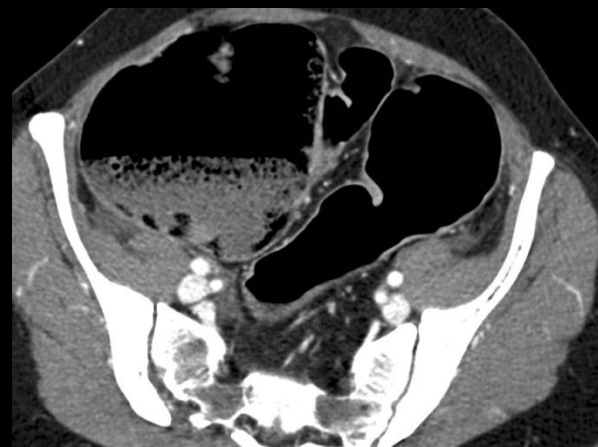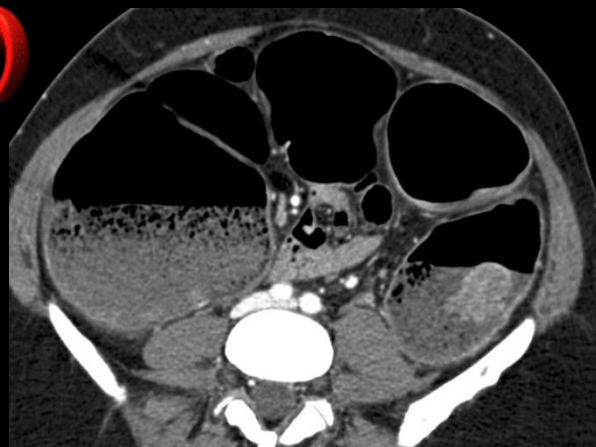
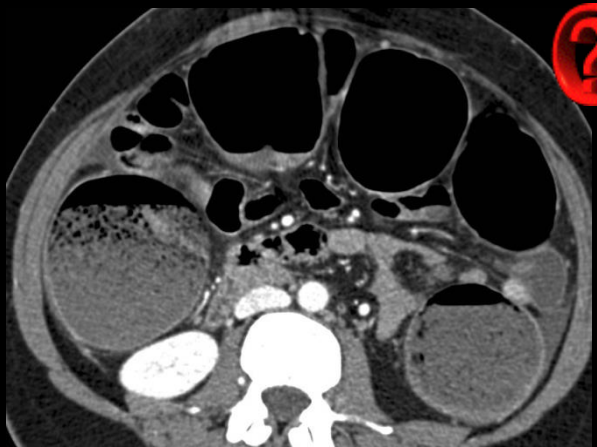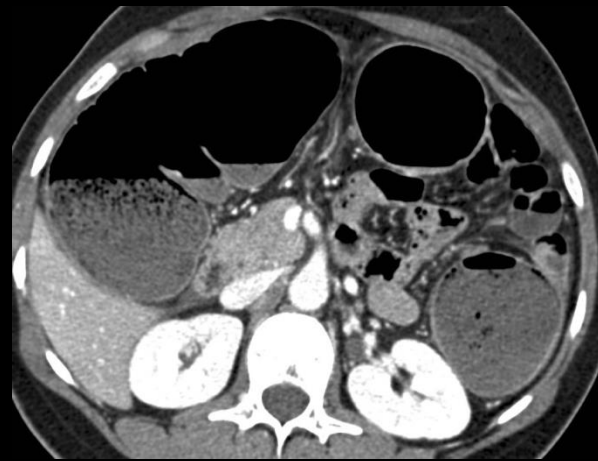


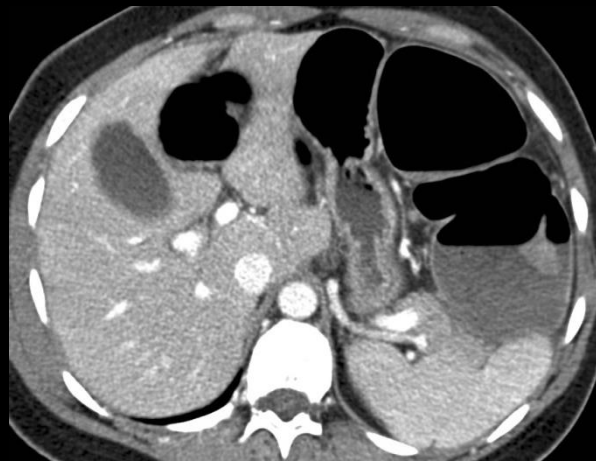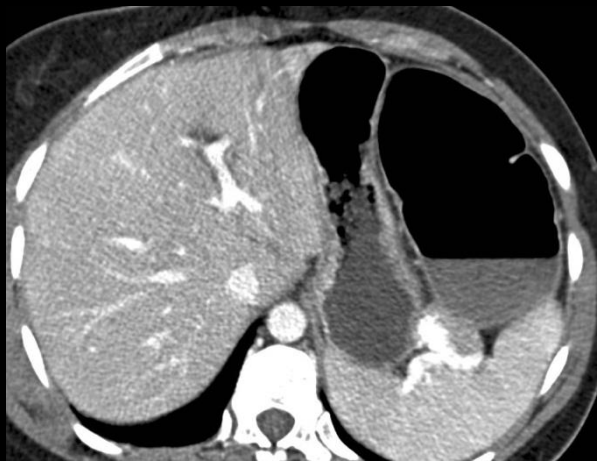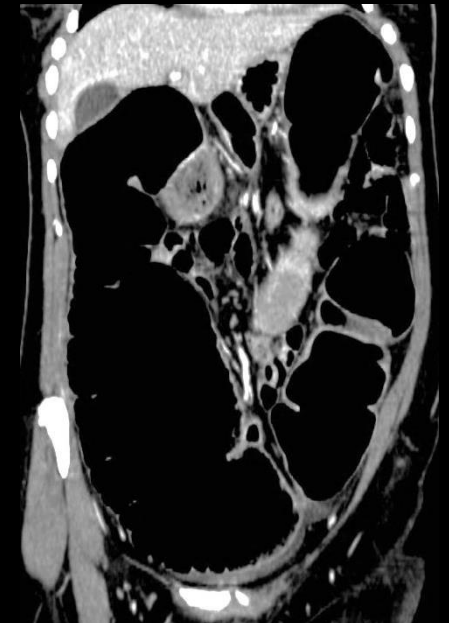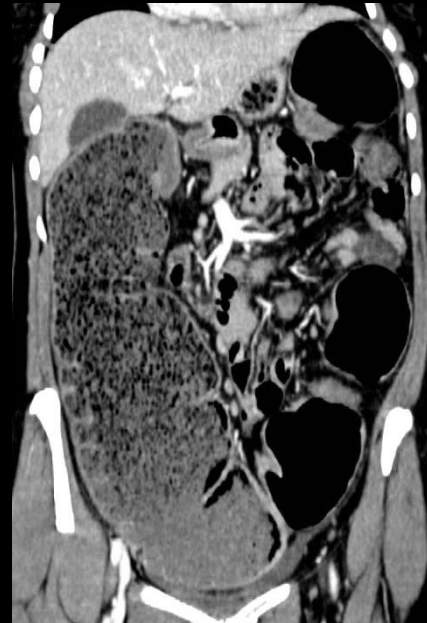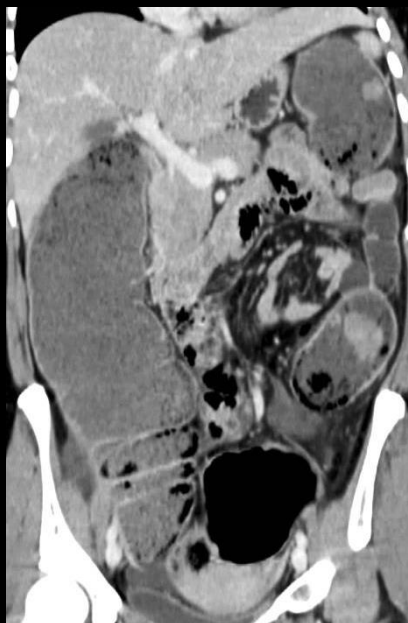


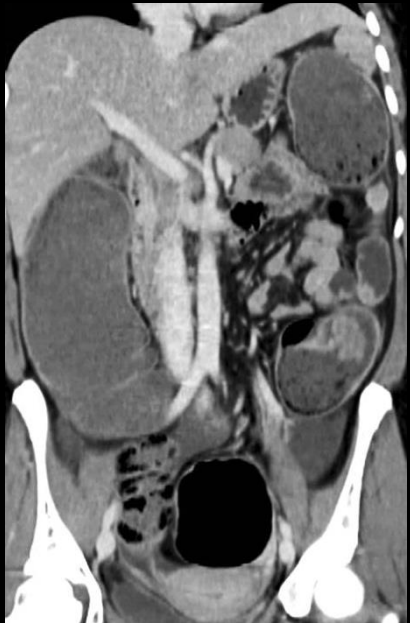**adénocarcinome sténosant
de l'angle colique
droit(adénocarcinome
moyennement différencié,
pT4) chez un homme de
24 ans**

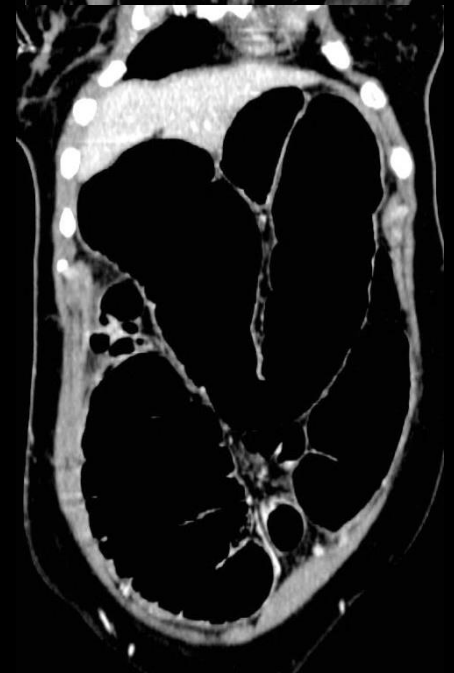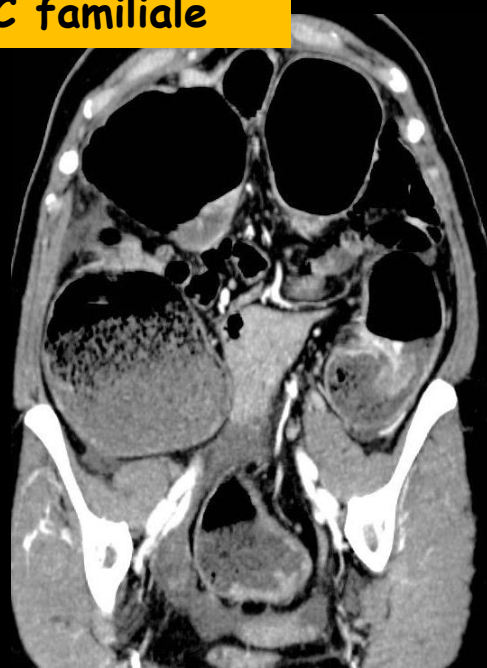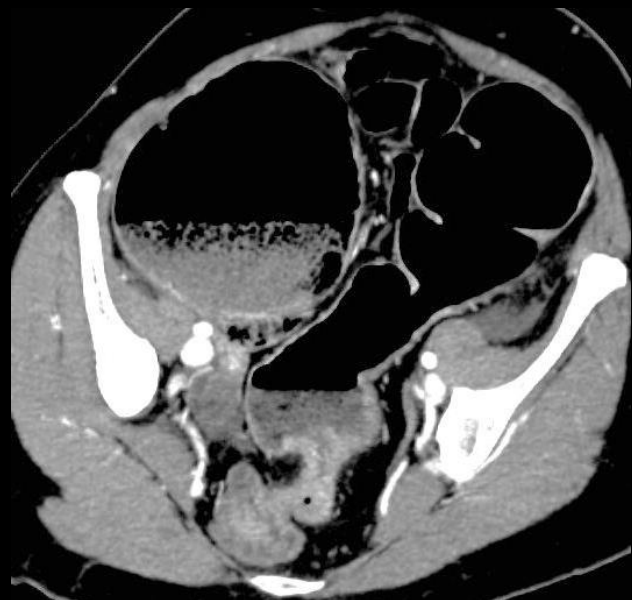
**rechercher caractère
familial (sd de Lynch)**

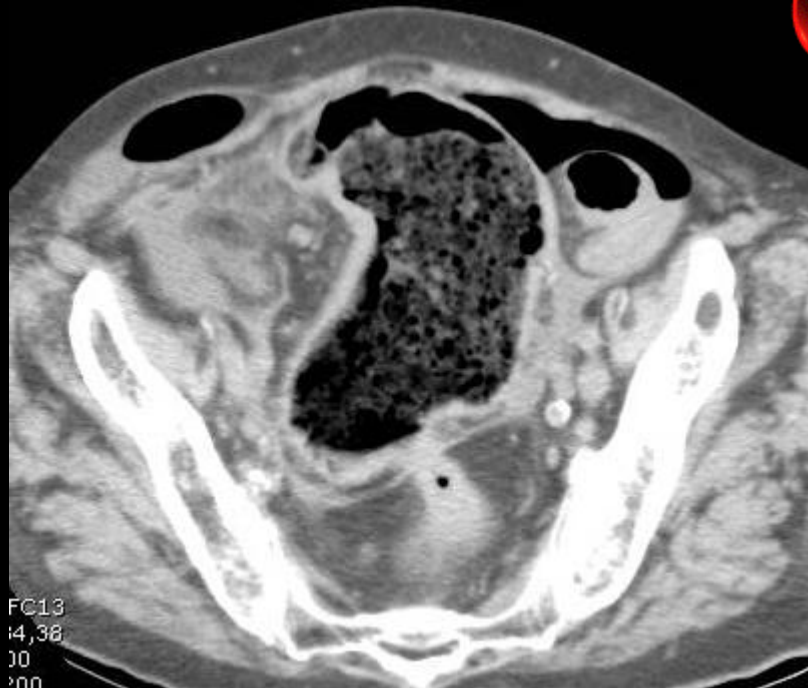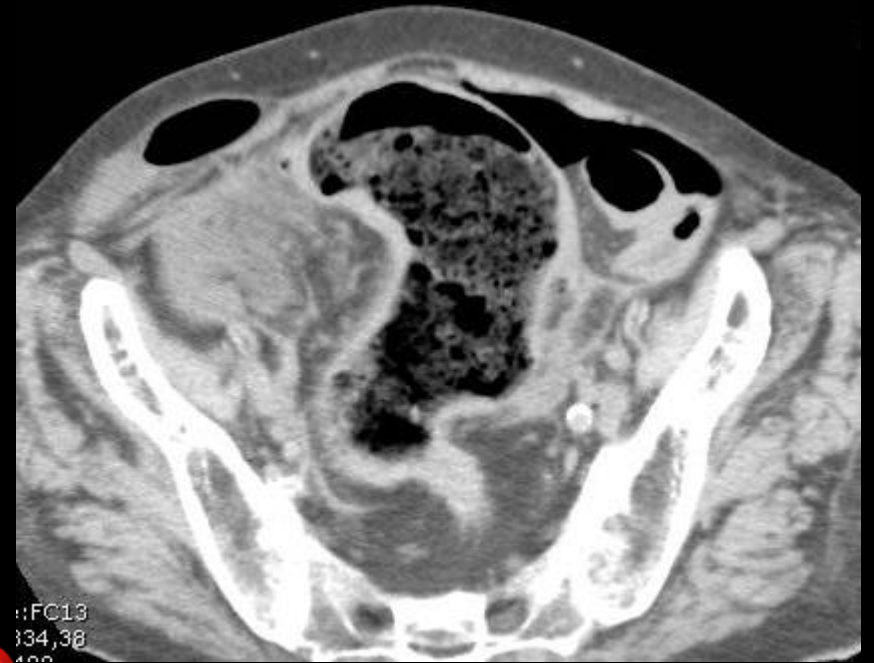
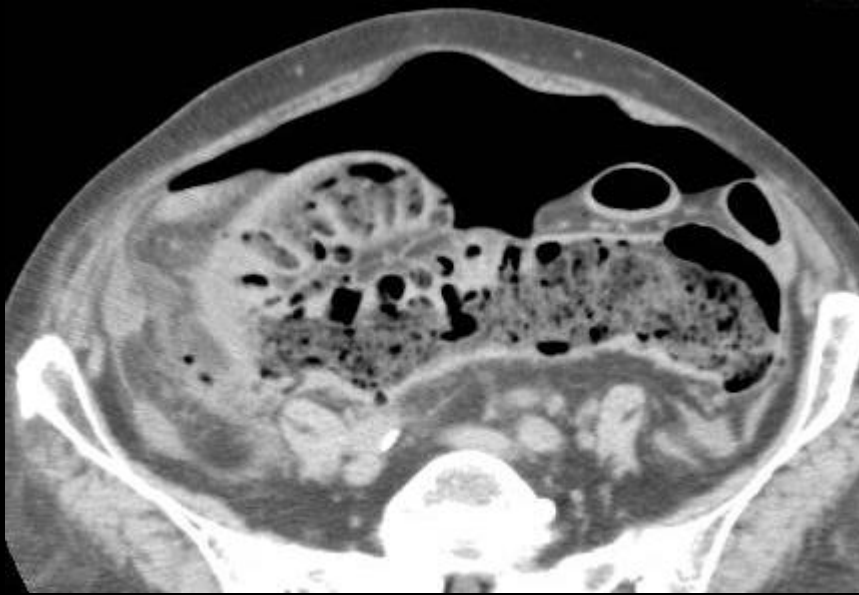




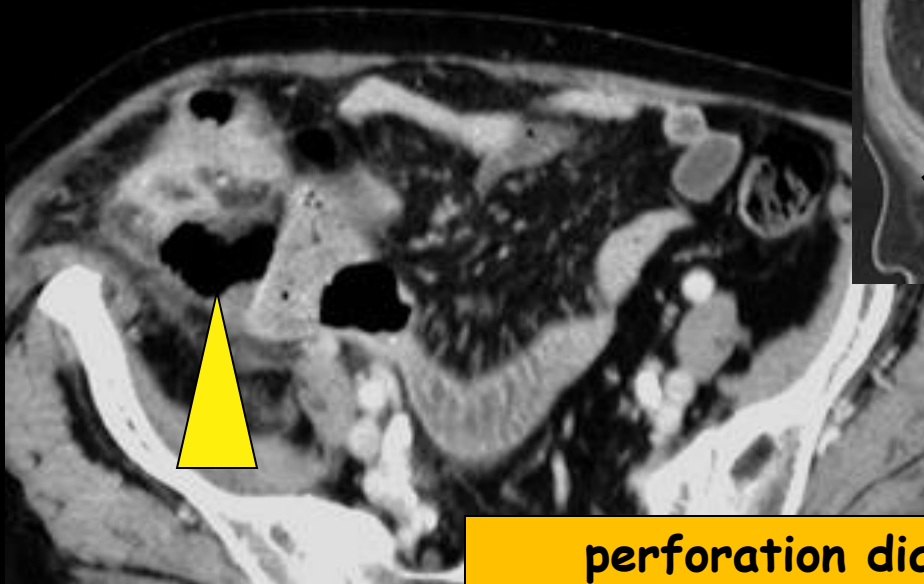
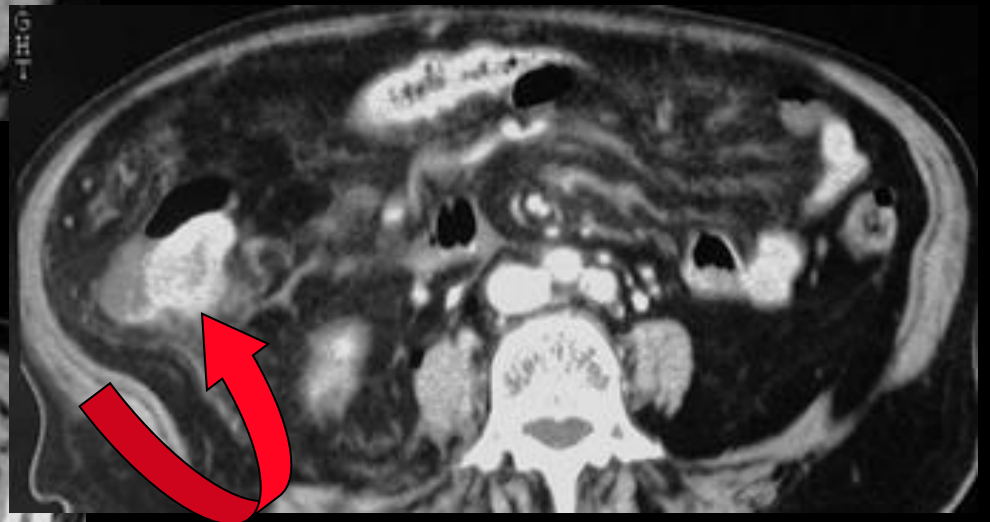
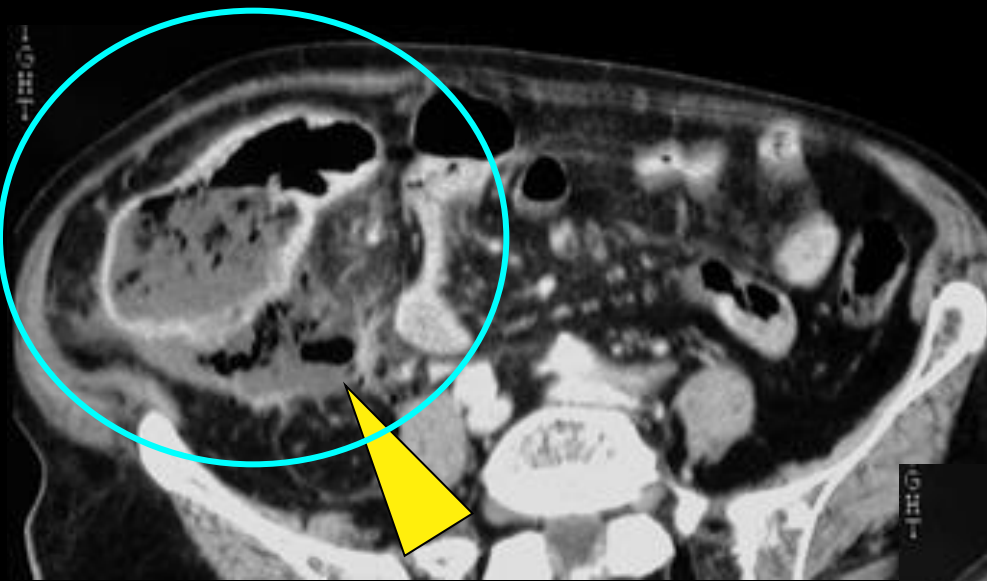


homme 34 ans, adénocarcinome sténosant de la charnière recto-sigmoïdienne; PARC familiale

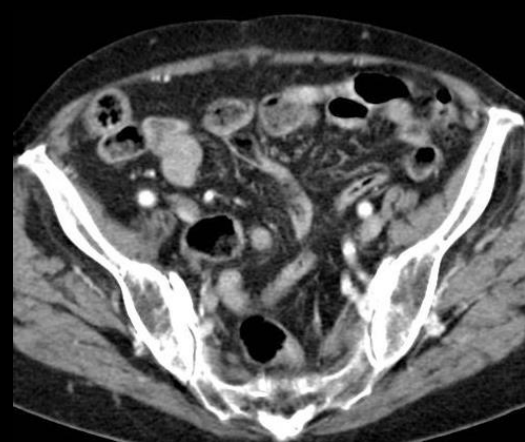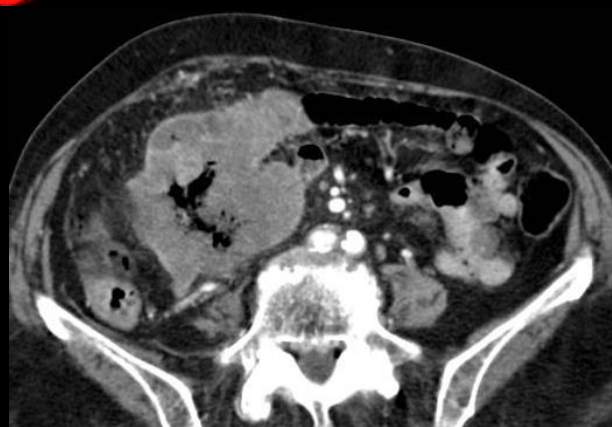
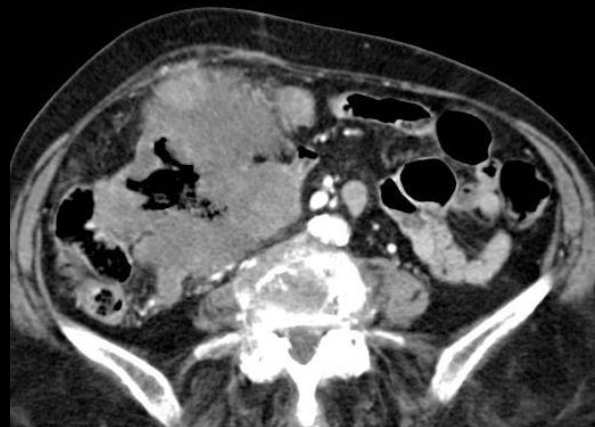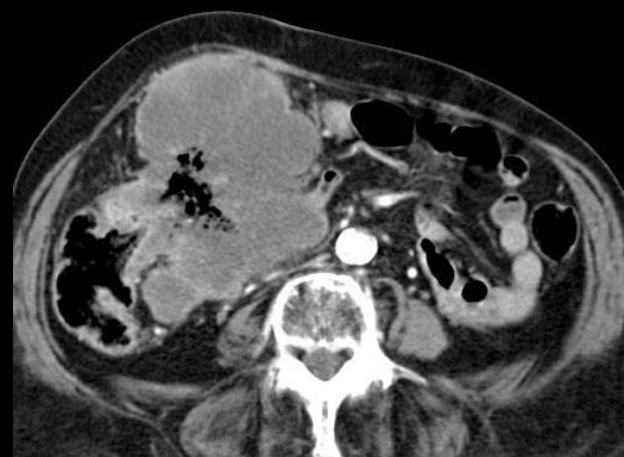
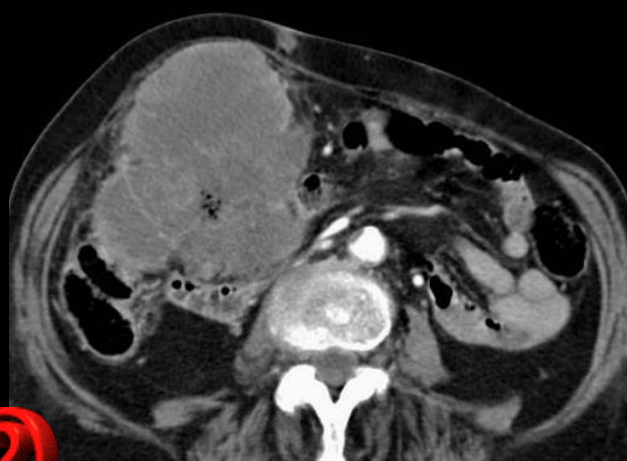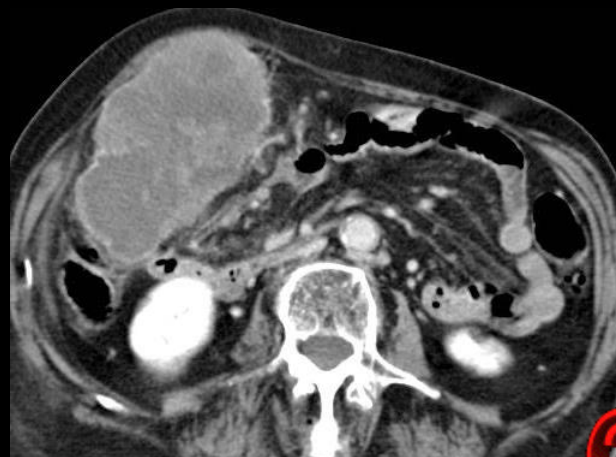
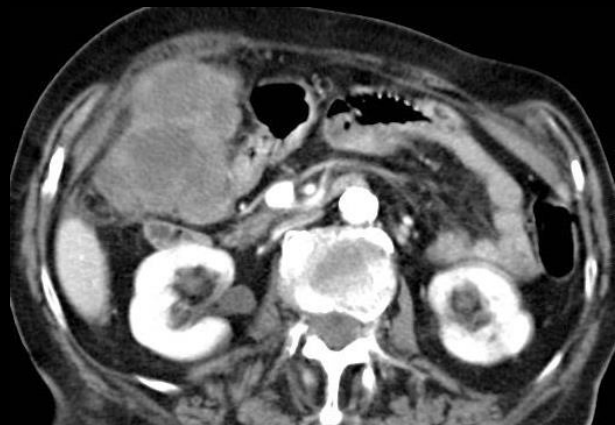
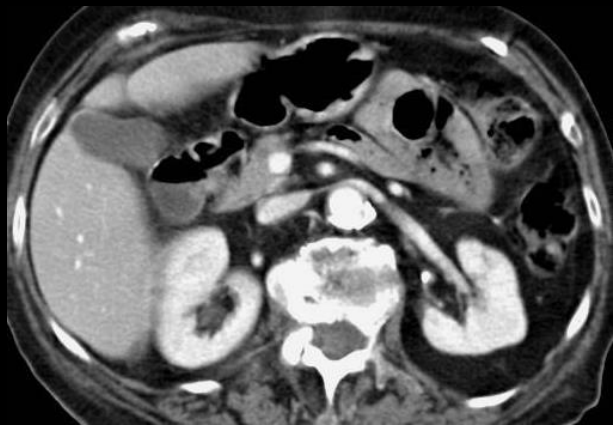
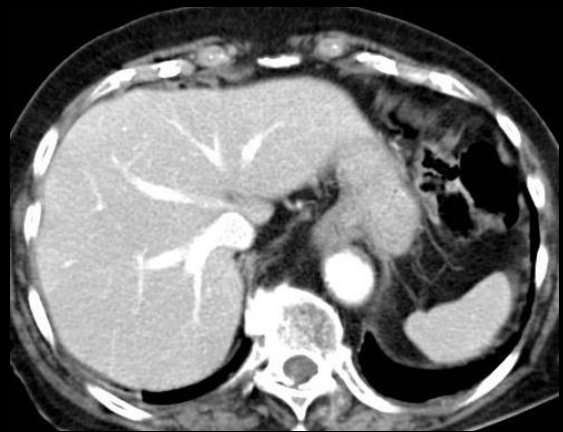


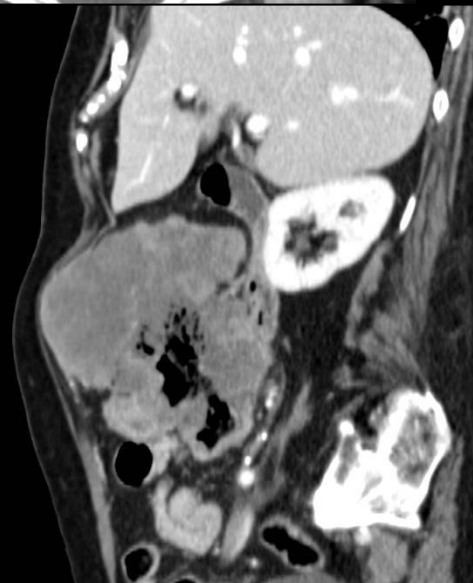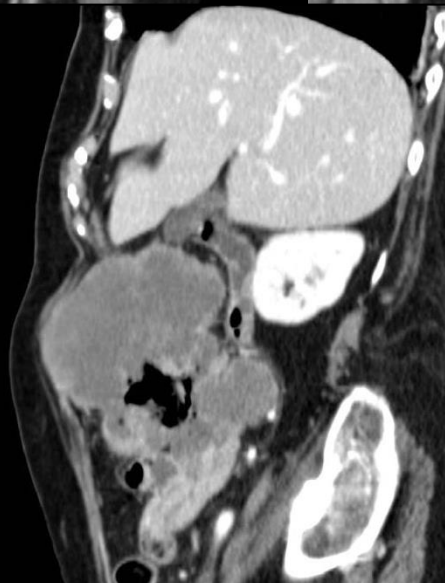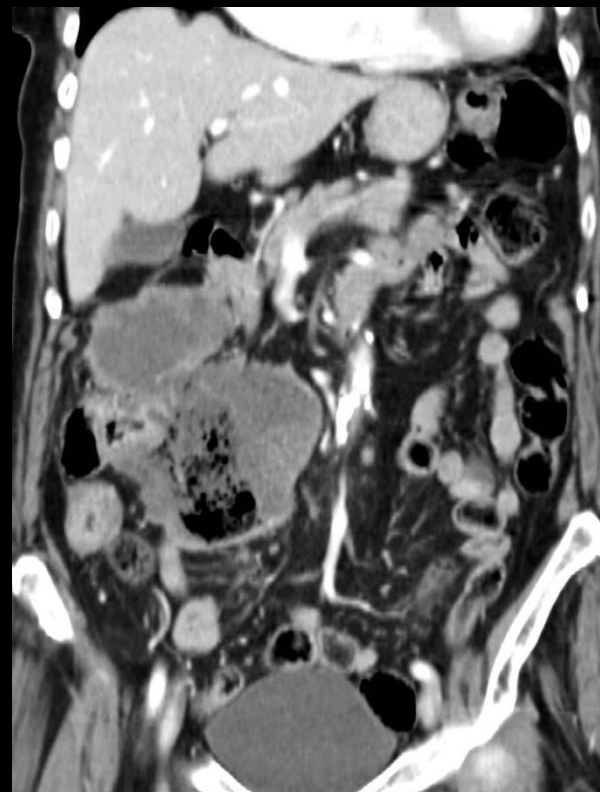
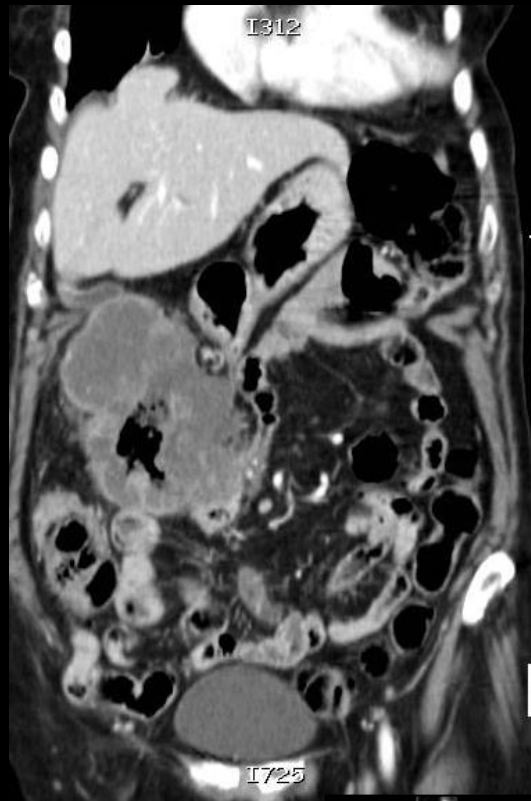
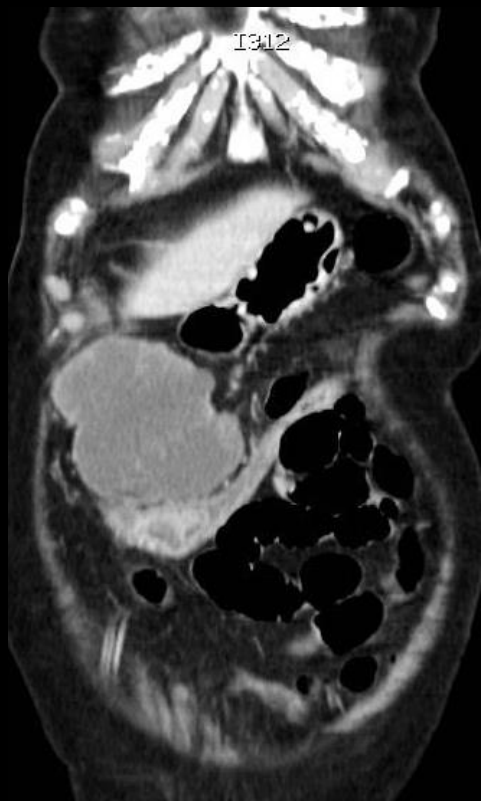


**perforation diastatique sur
adénocarcinome sténosant de
la charnière recto-
sigmoïdienne**

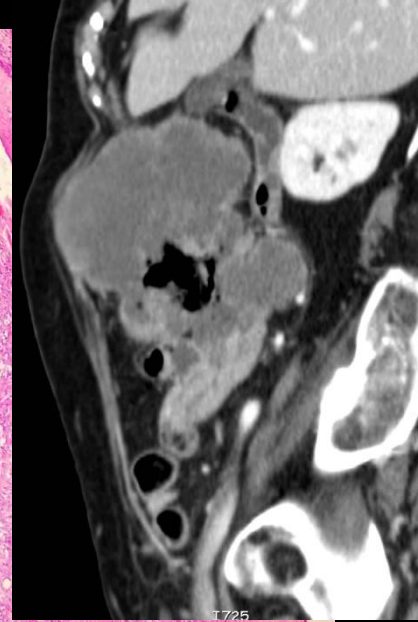
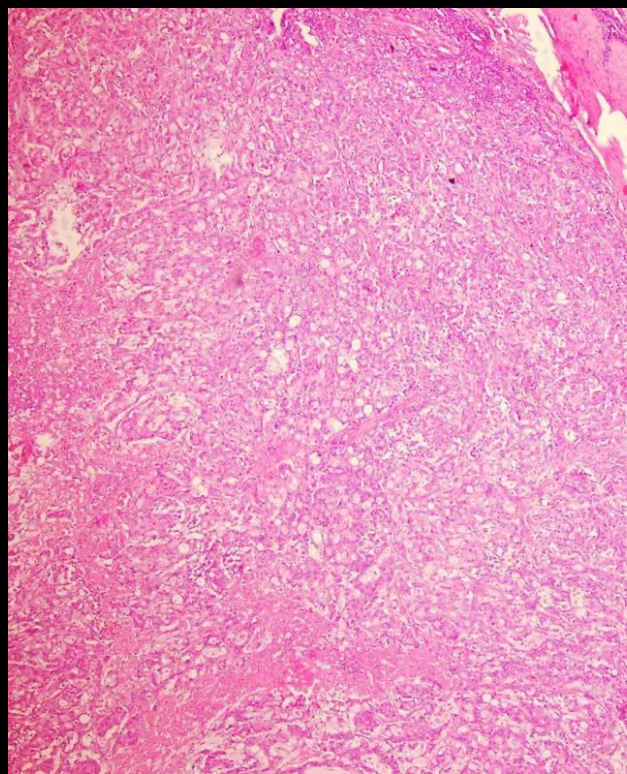
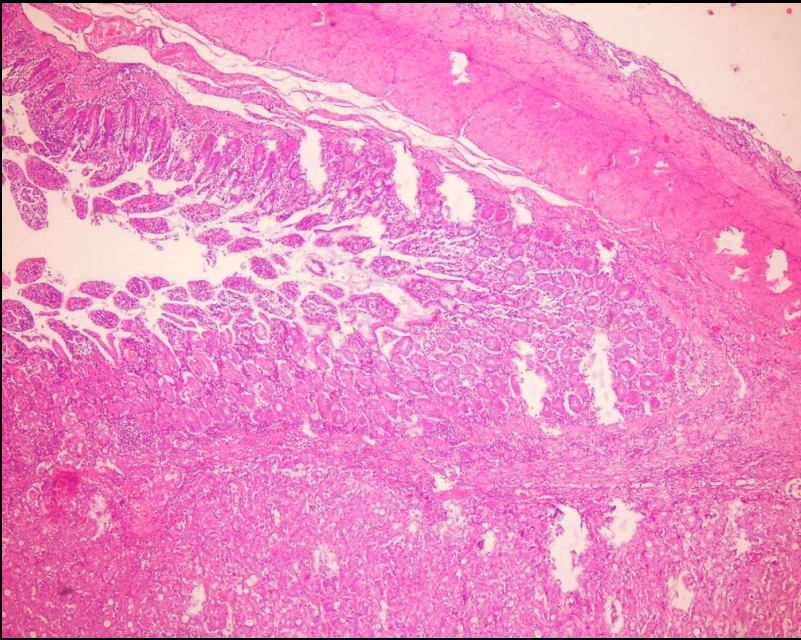


perforation diastatique "couverte" sur ADK
sténosant du colon ascendant





**volumineux adénocarcinome de l'angle
colique droit , peu obstructif malgré
son volume, chez une femme de 92
ans, surdosée en AVK**



ADENOCARCINOME MOYENNEMENT DIFFERENCIE

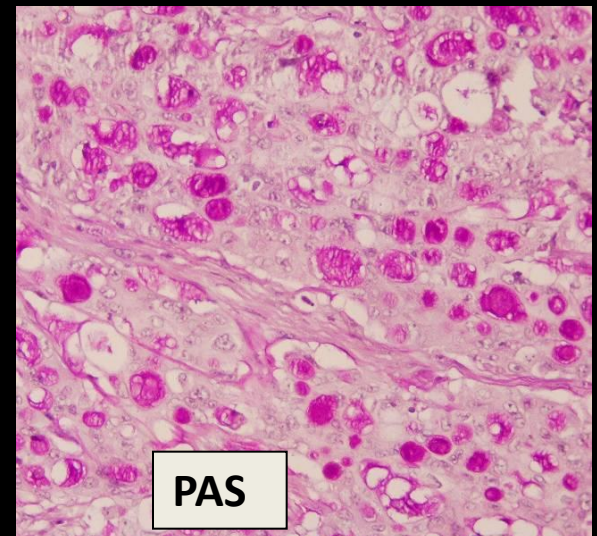
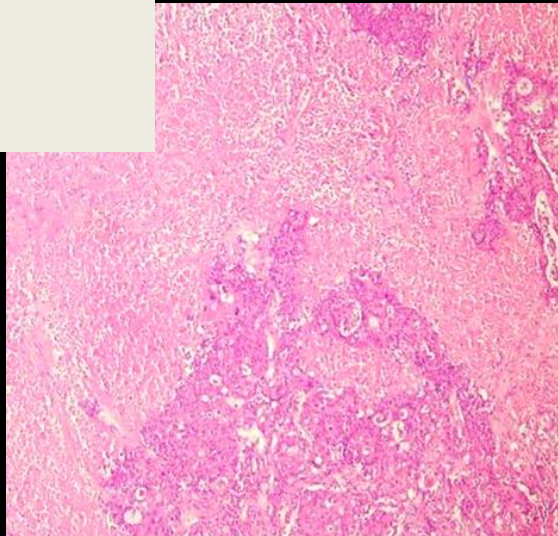
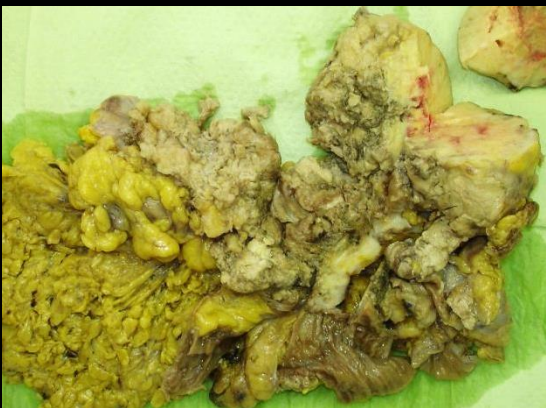Massivement nécrosé

Développement exo-luminal+++

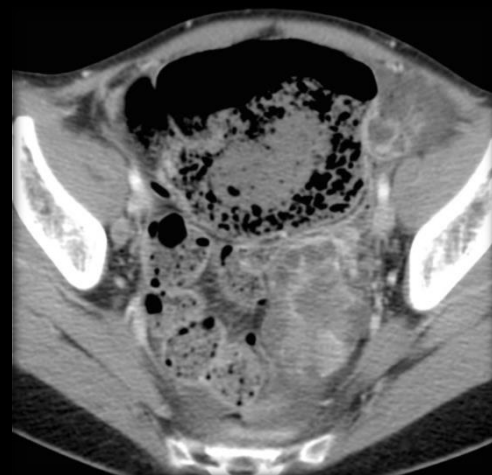
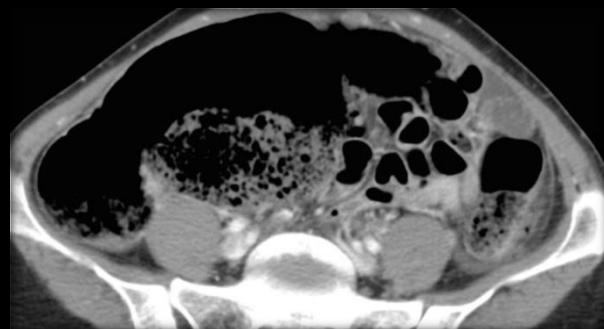
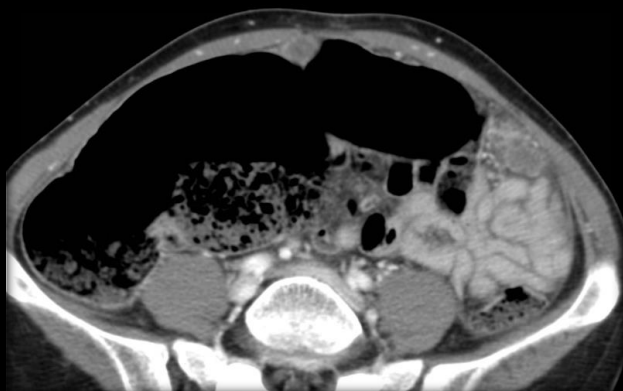
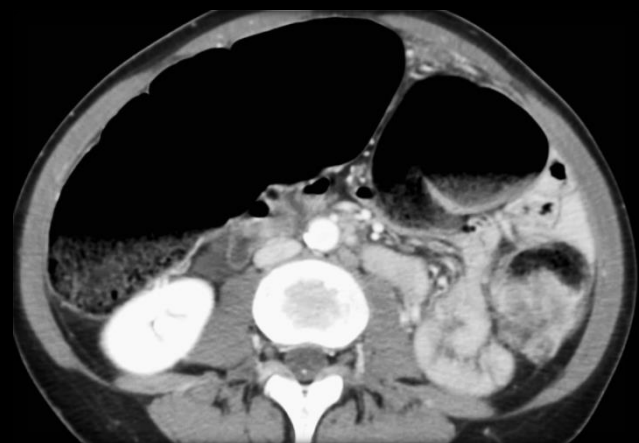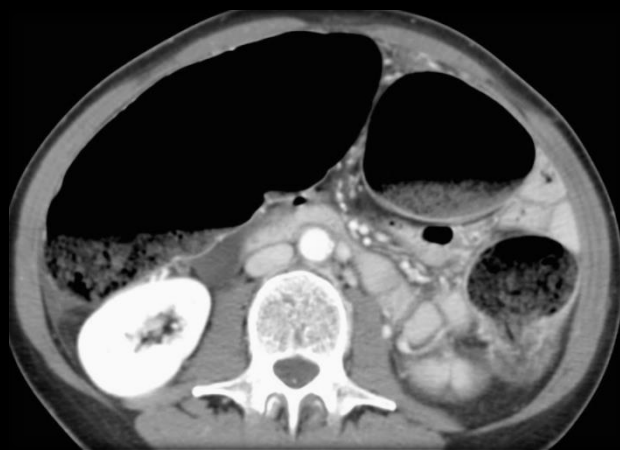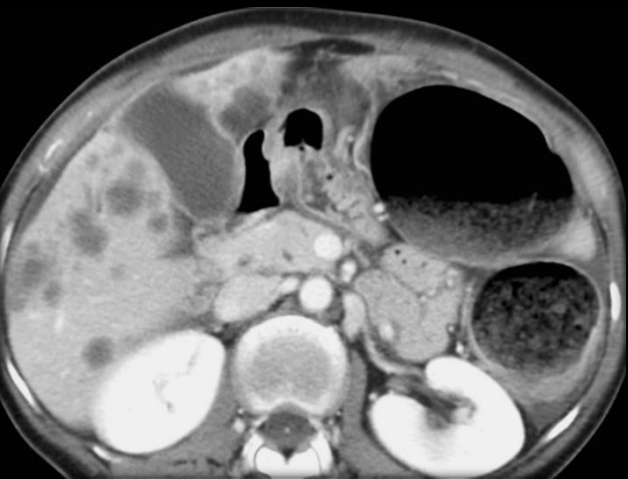
Parois colique et grêles envahies

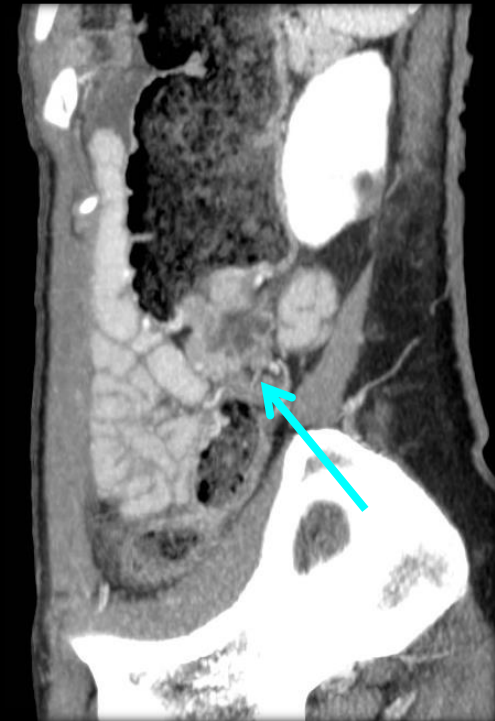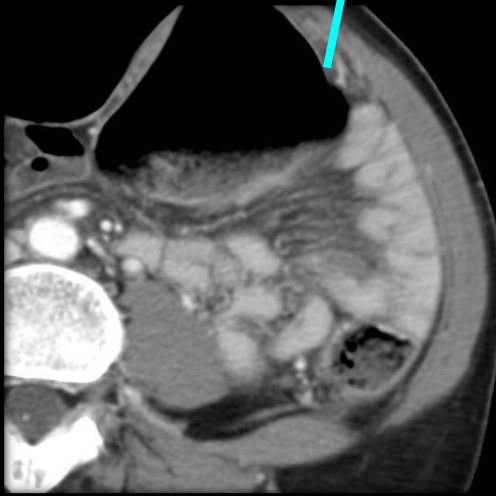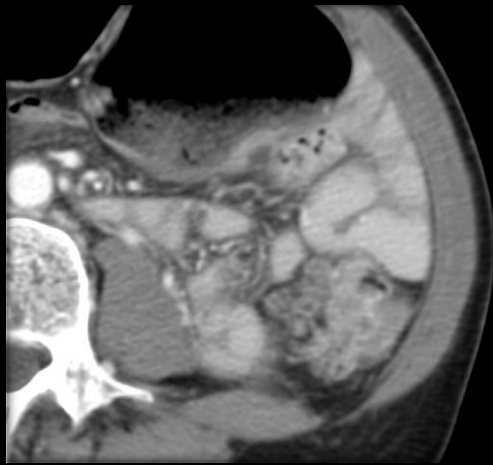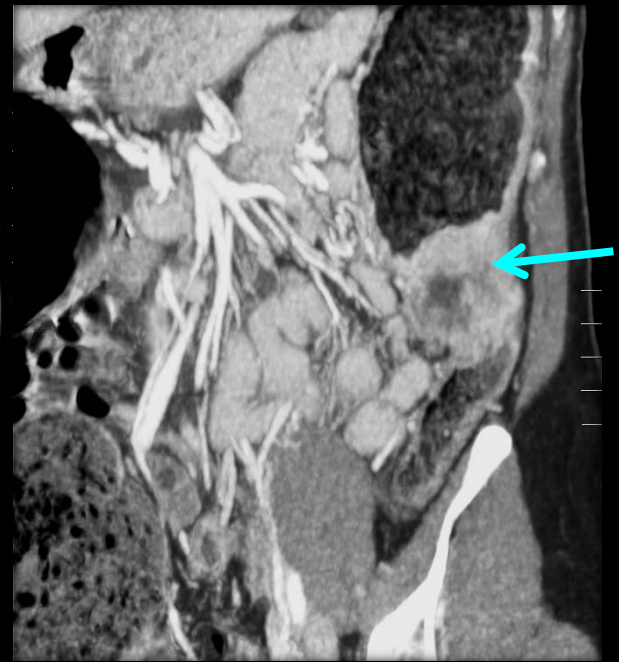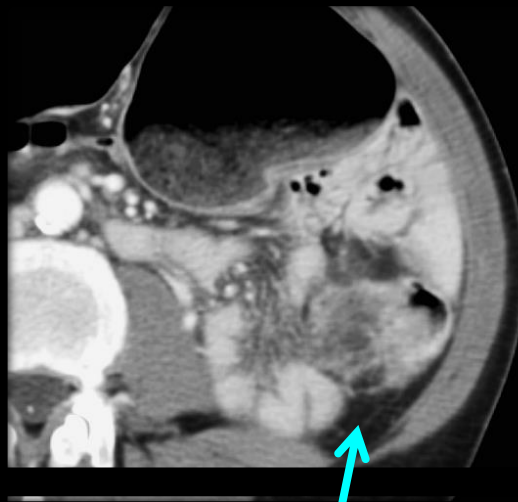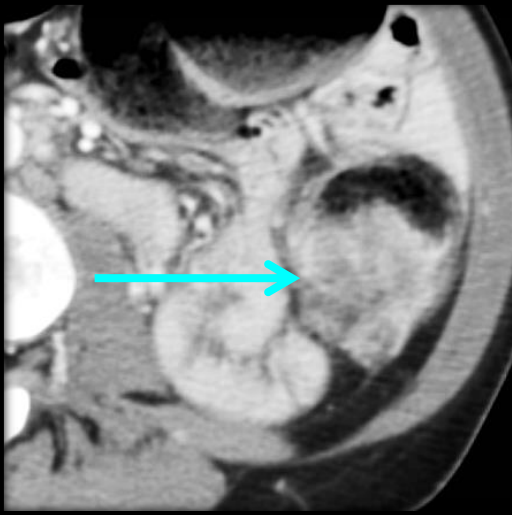
Emboles vasculaires / Pas de métastases
ganglionnaires.

pT4N0

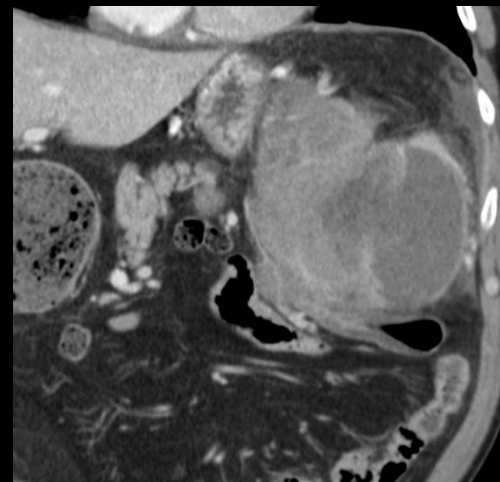
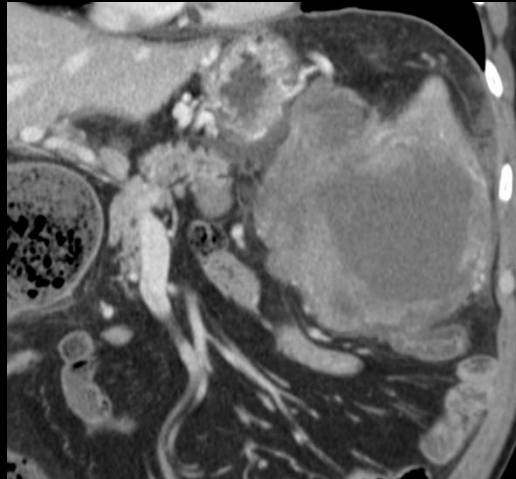
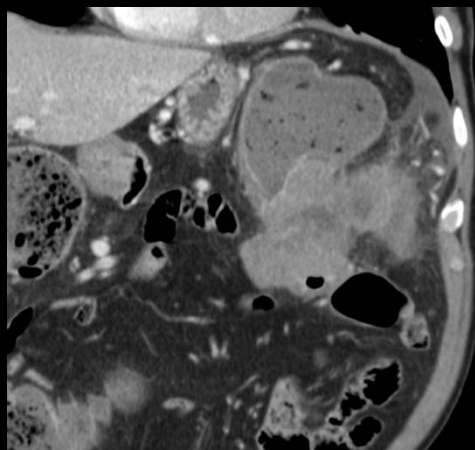
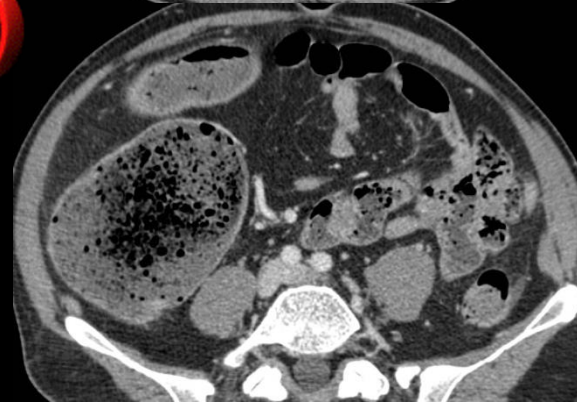
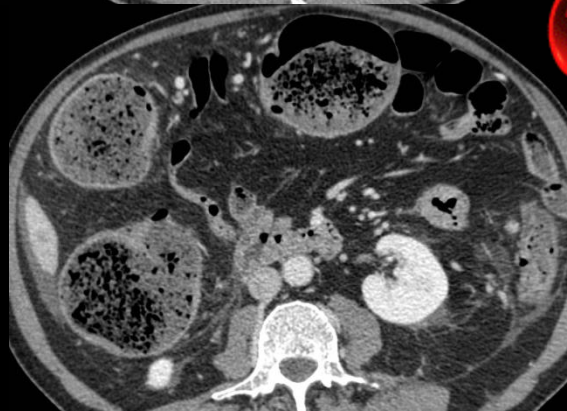
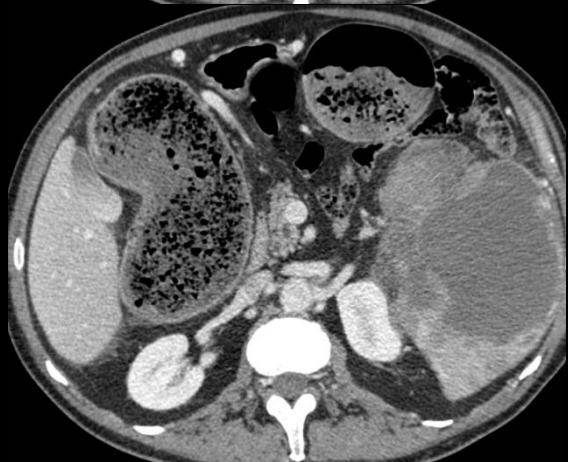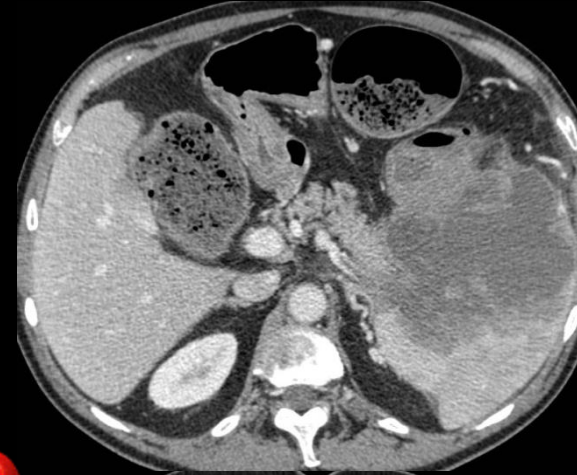
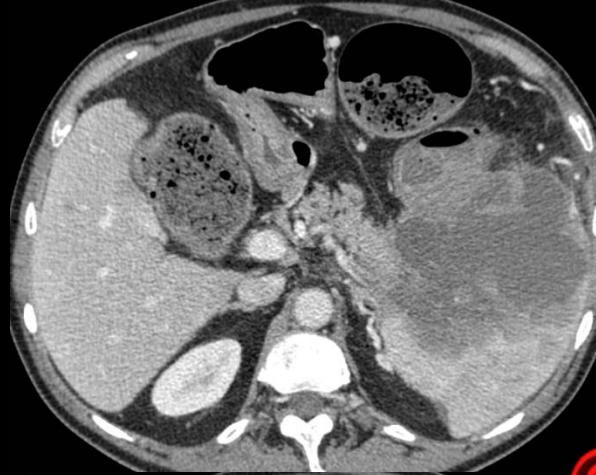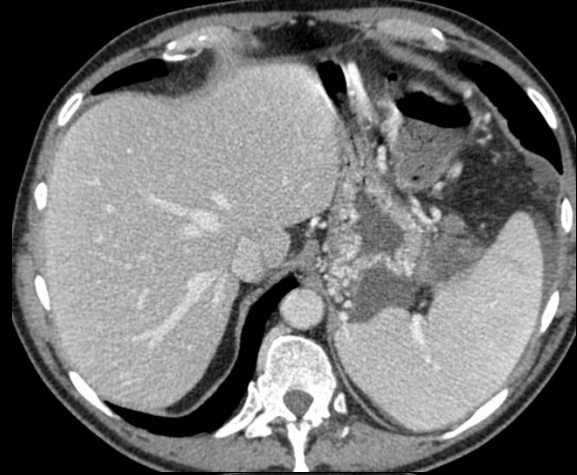


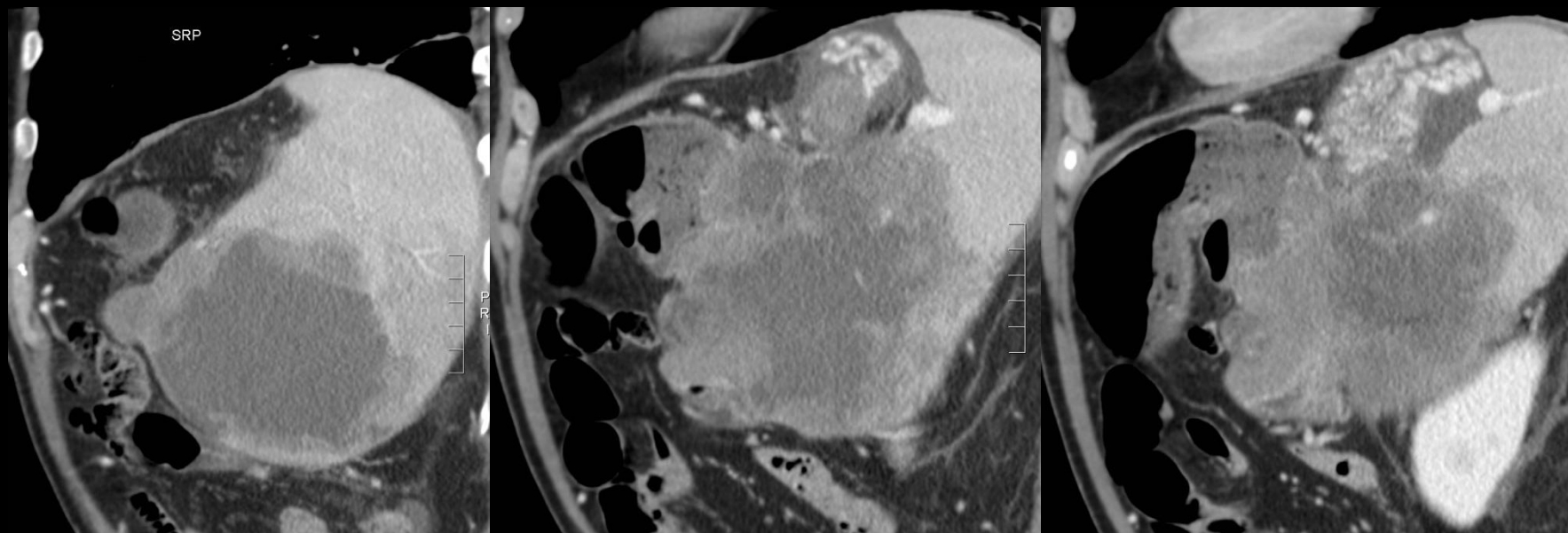
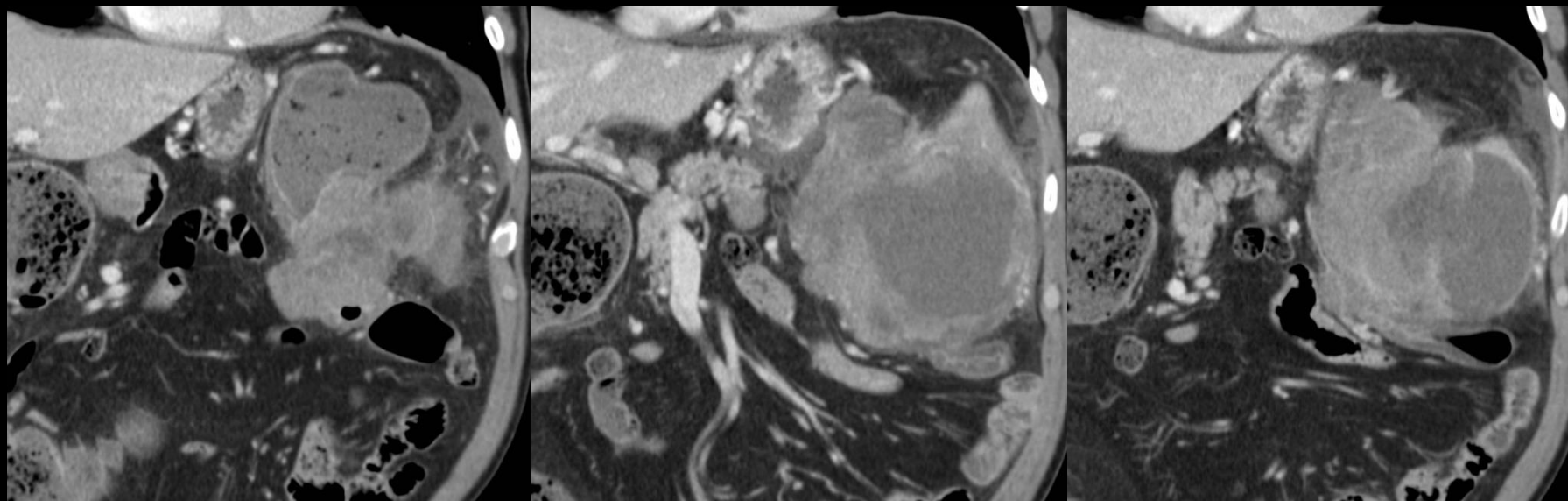
PAS



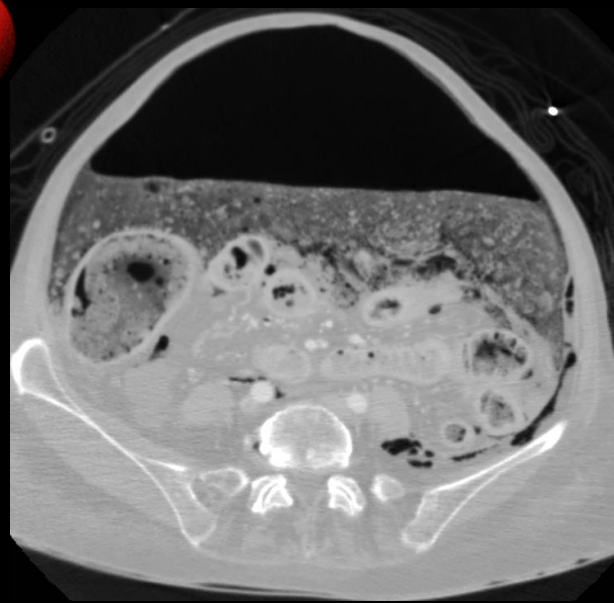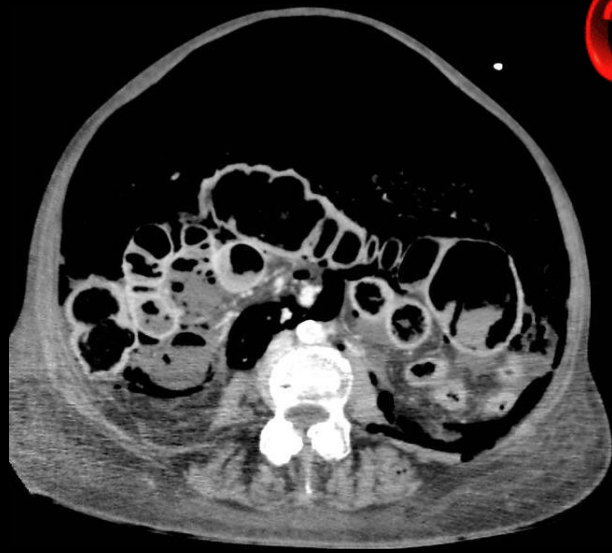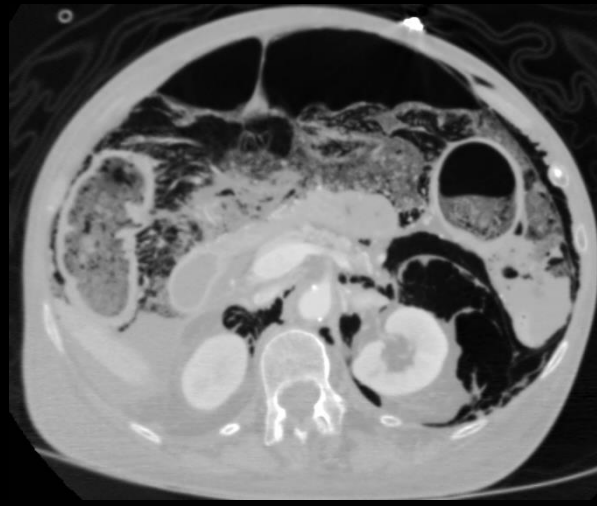


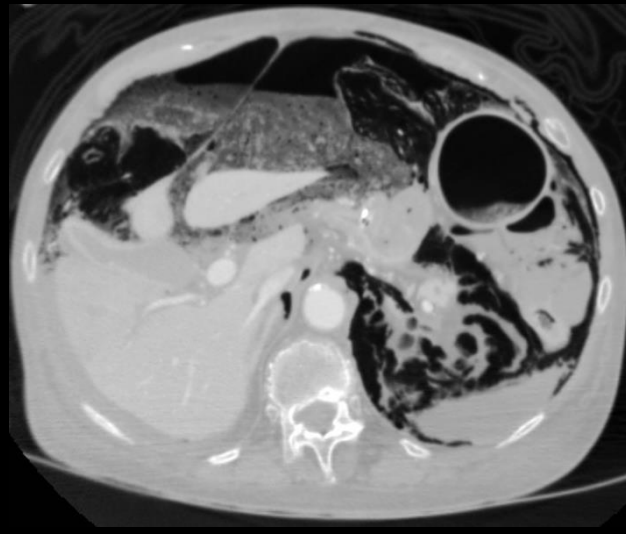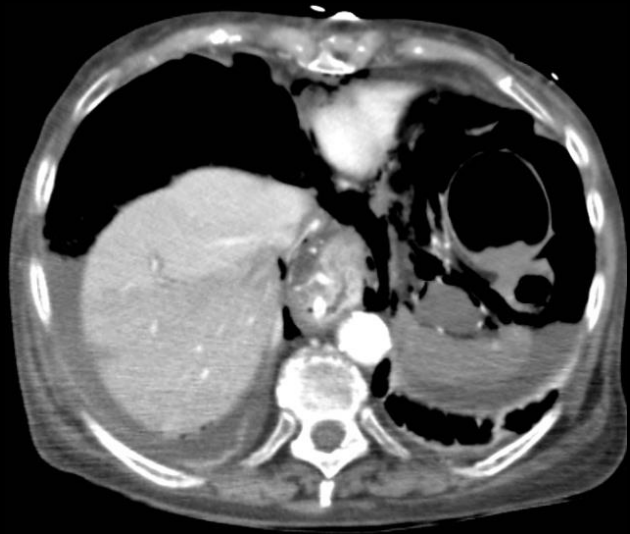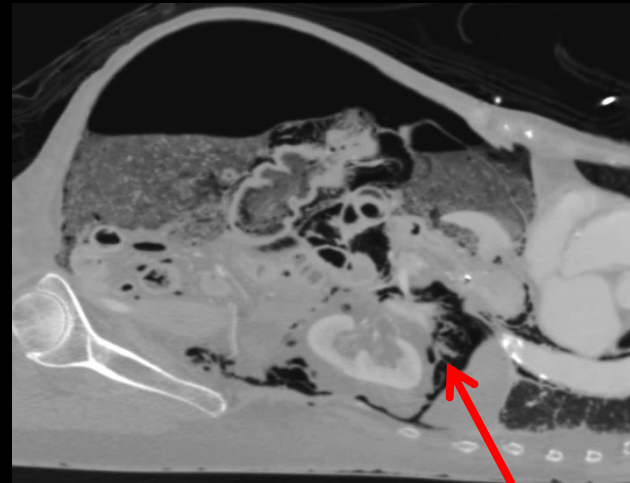
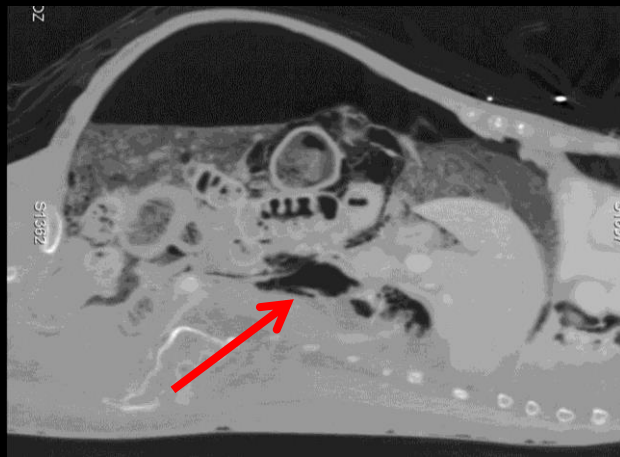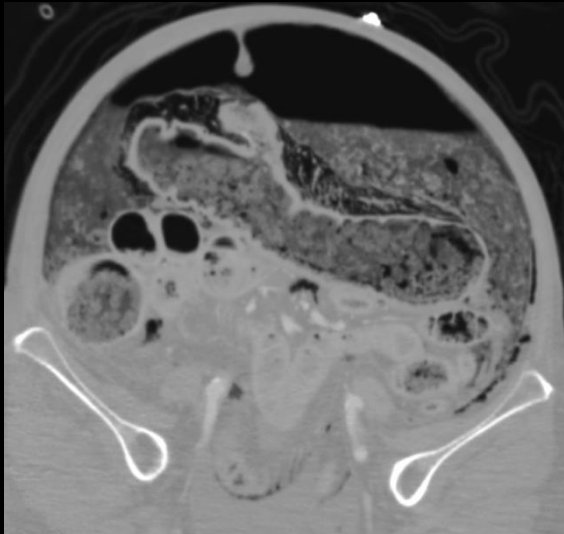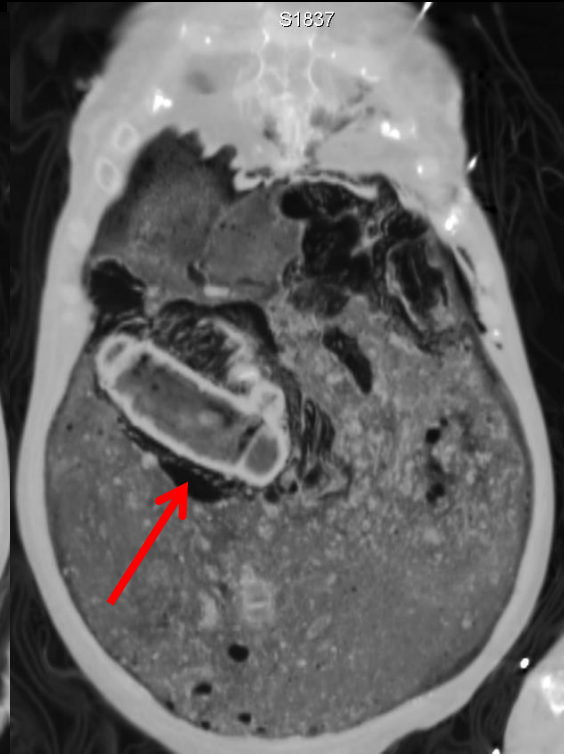
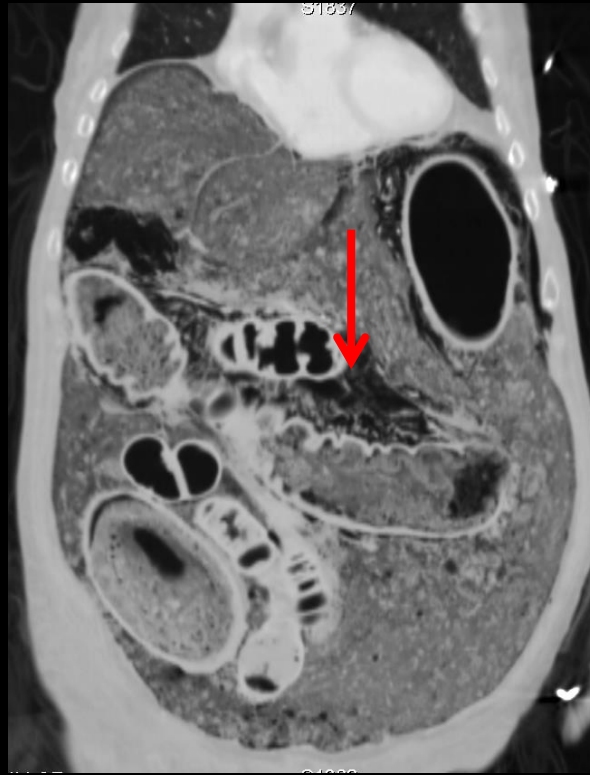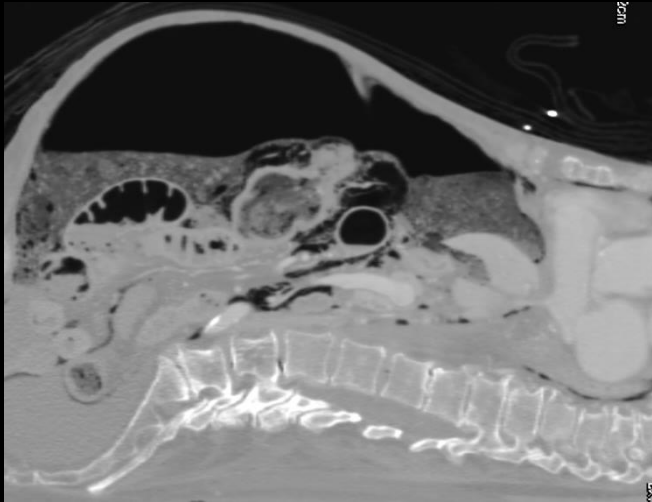
**Sténose circonférentielle serrée du colon gauche par adénocarcinome lieberkuhnien
parois coliques épaisses ; stase stercorale**

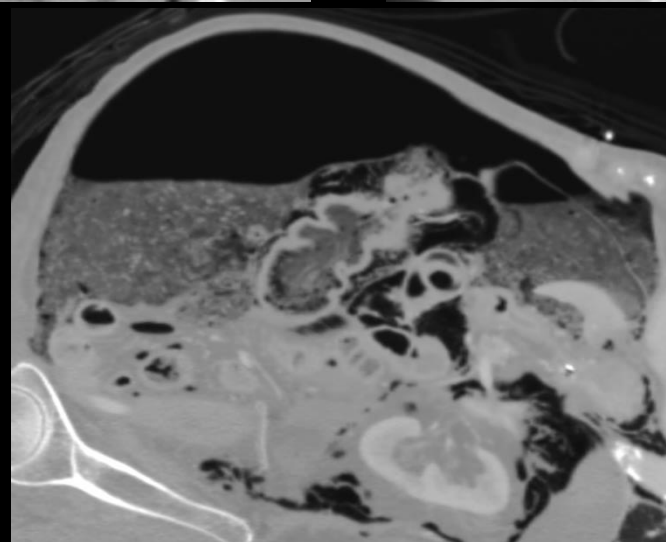
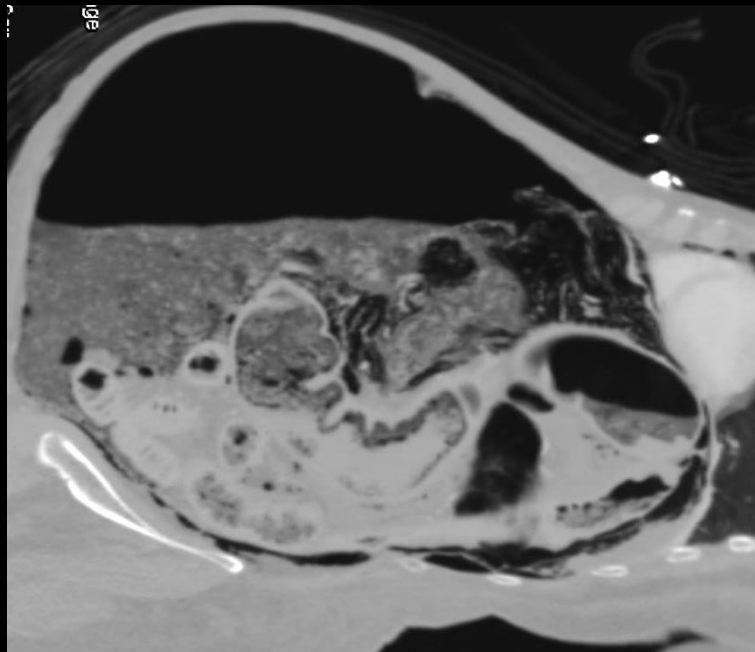
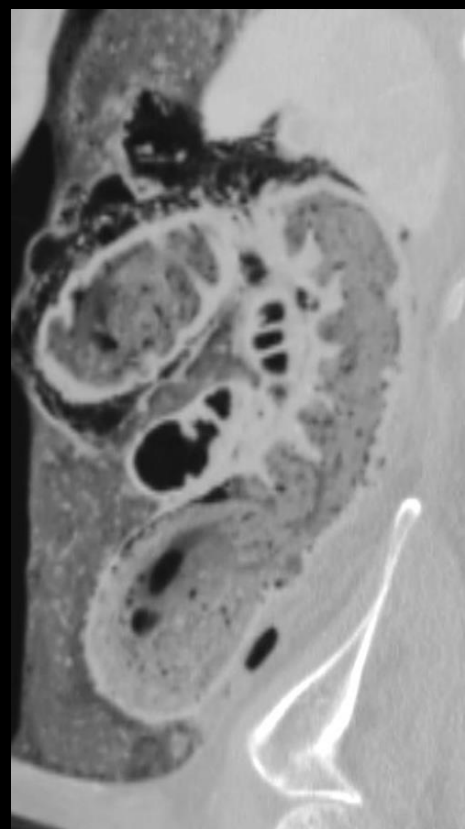
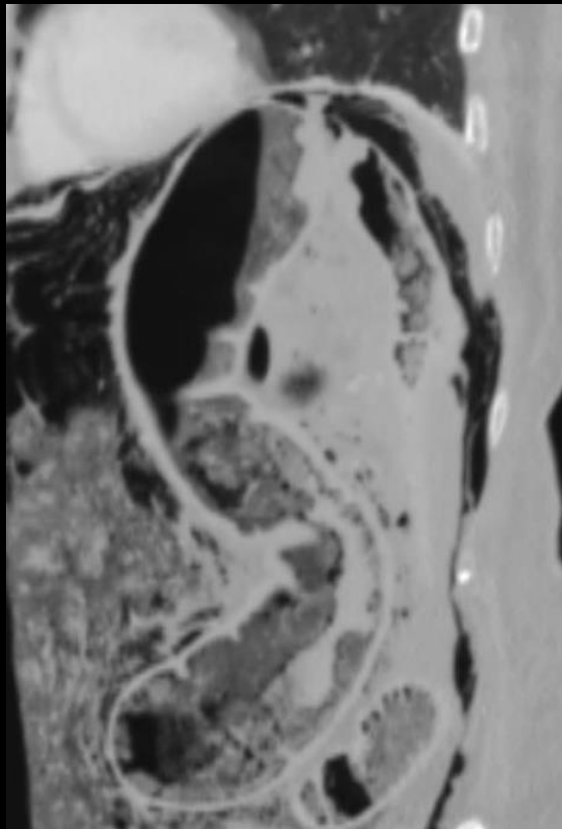
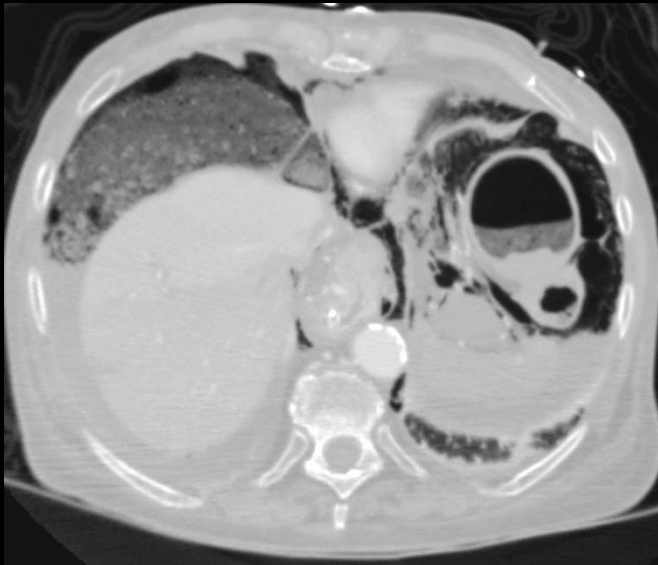


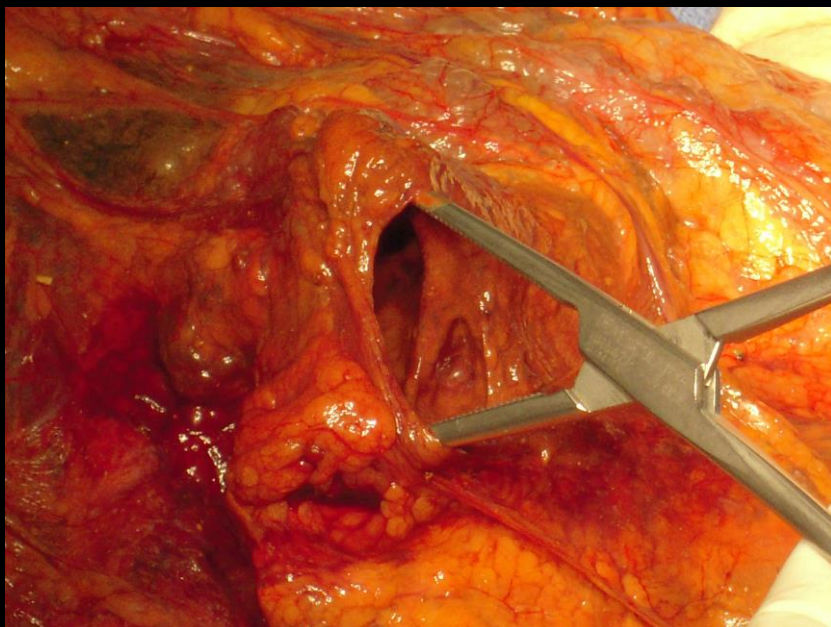
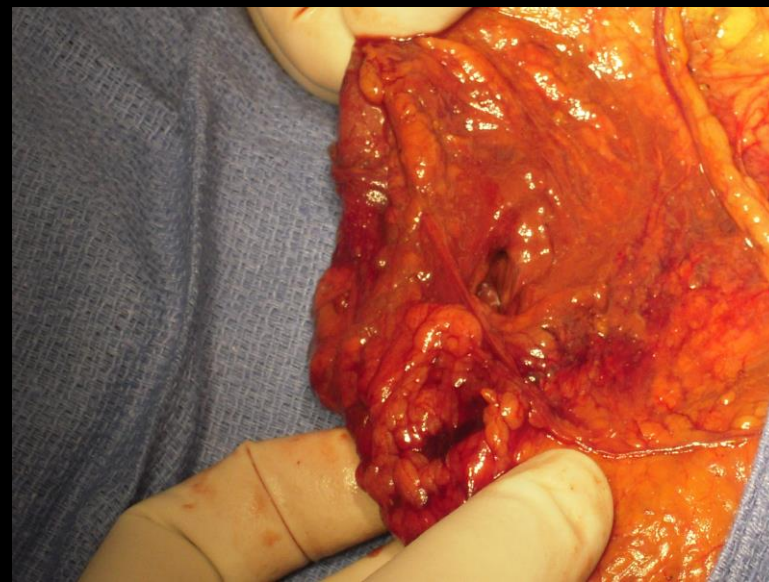
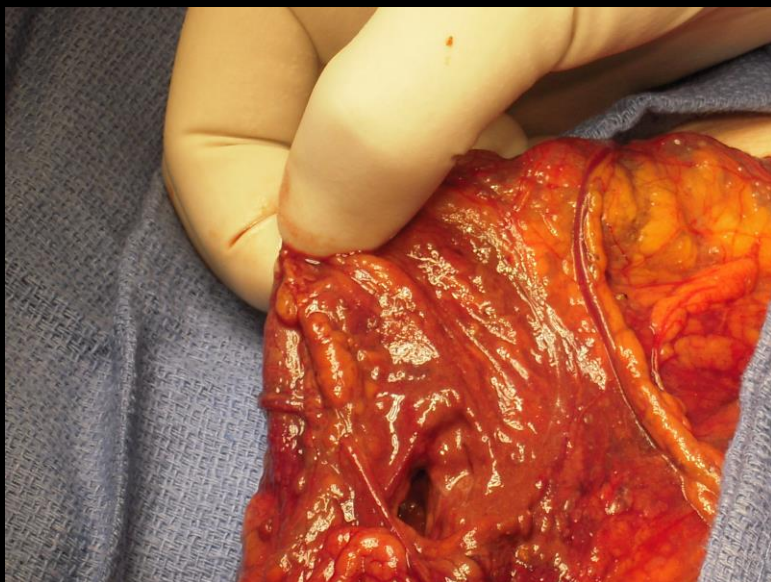


extension en un mois d'un LMNH B diffus grandes cellules splénique à l'angle colique gauche



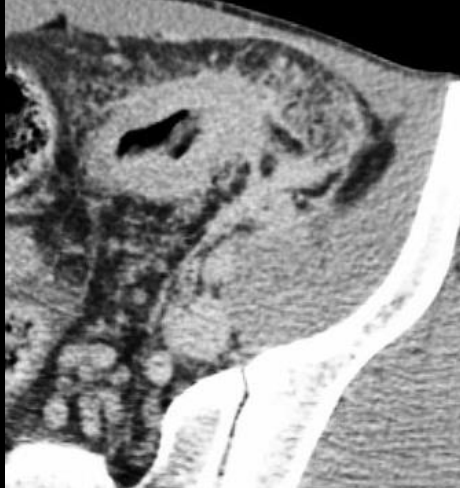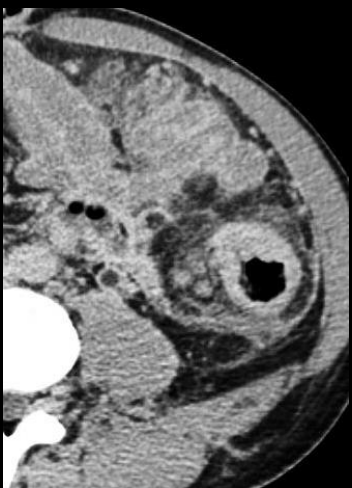
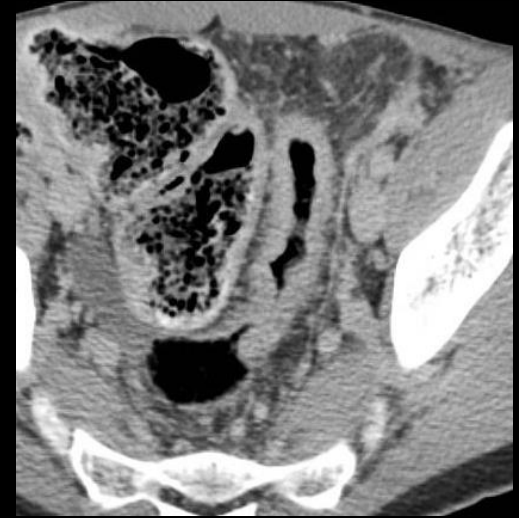
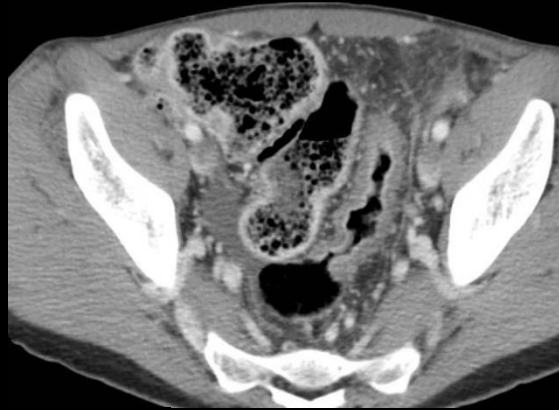

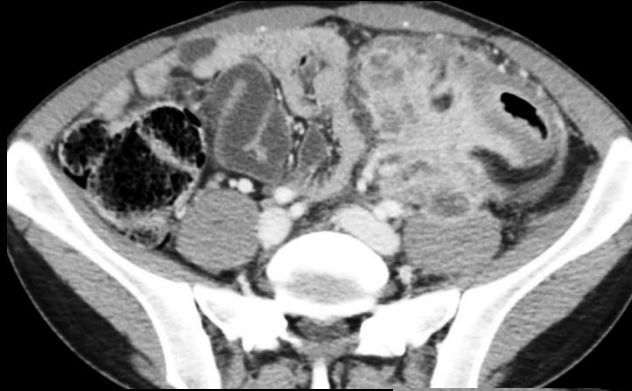
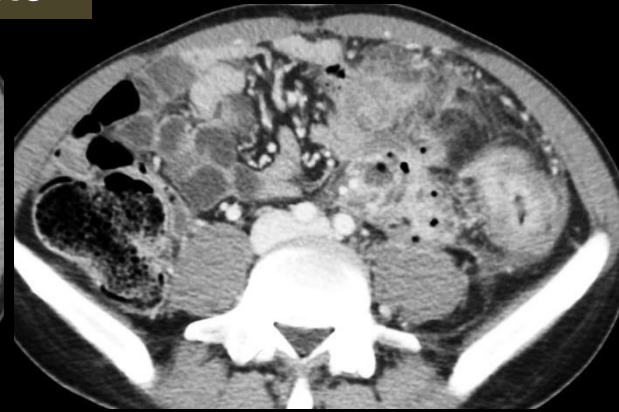
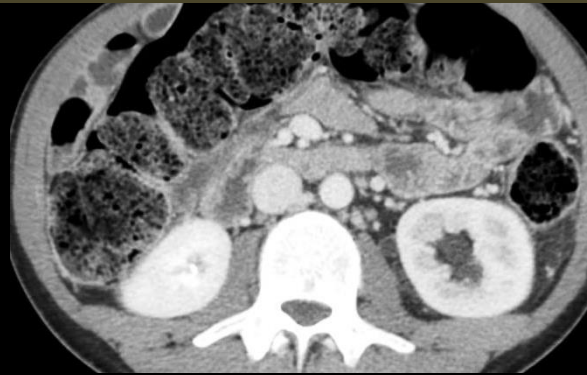
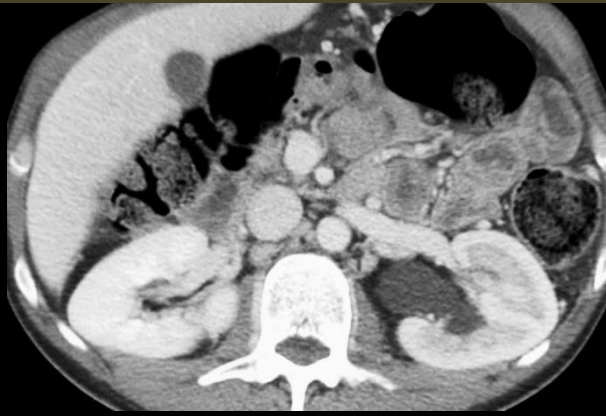

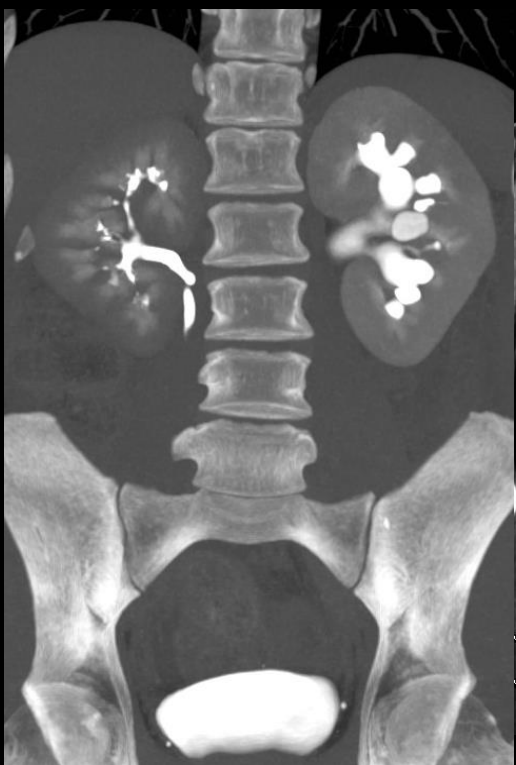perforation du colon transverse sans cause évidente à l'intervention

3-1-3-1 lésions pariétales sténosantes colo-rectales non tumorales



Crohn colique à forme
sténosante +
urétéro_hydronephrose gauche
homme 28 ans



31.9 mm
47.0 mm

31.9 mm
47.0 mm

32.6 mm
75.1 mm

32.6 mm
75.1 mm

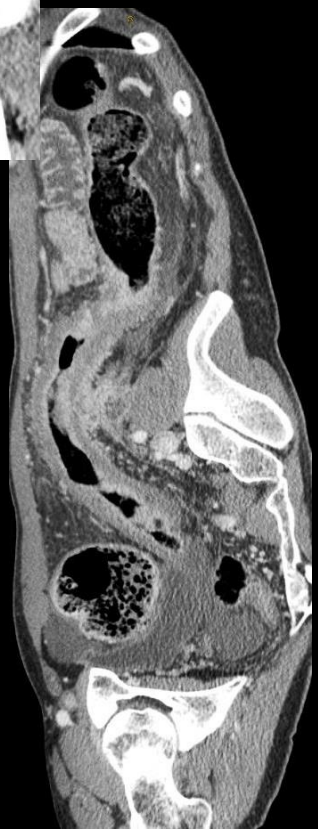31.9 mm
47.0 mm

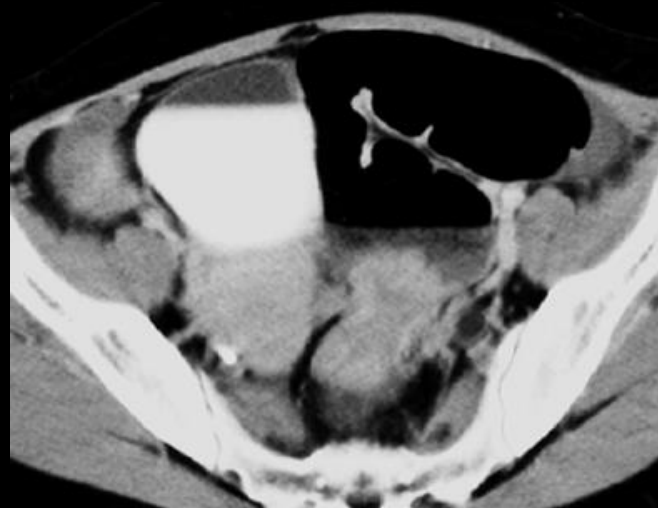
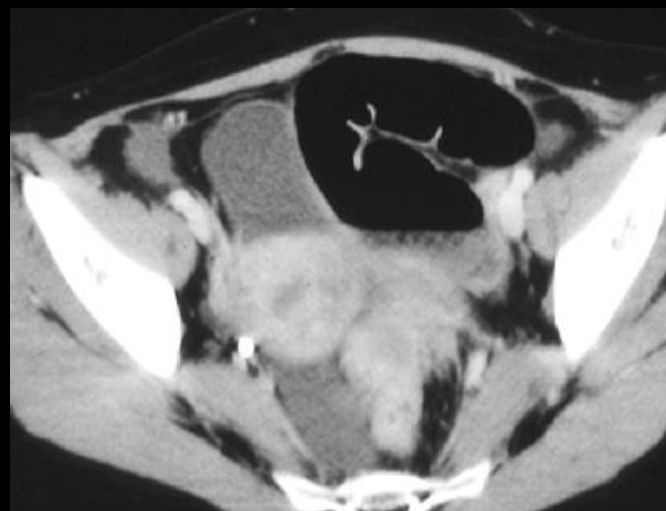
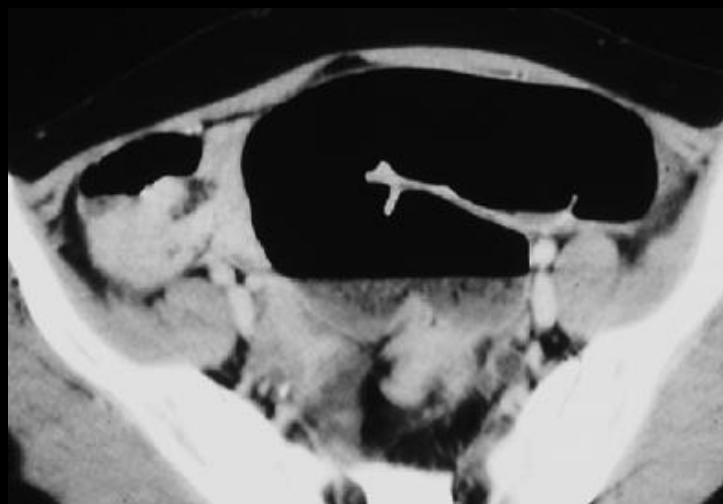
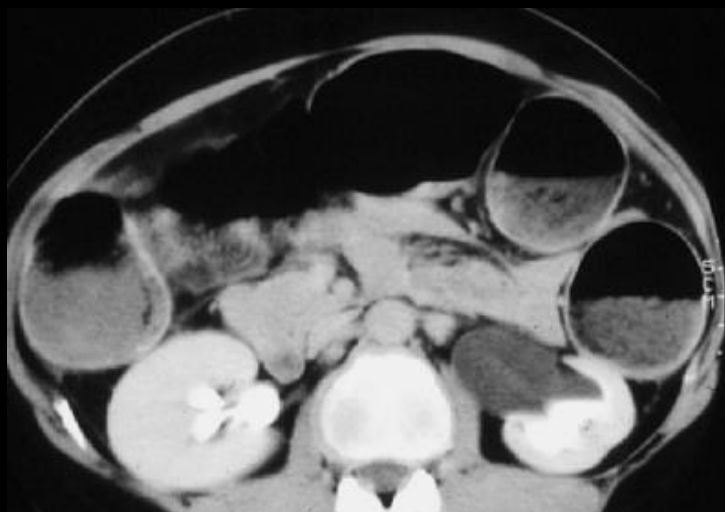31.9 mm
47.0 mm

32.6 mm
75.1 mm

32.6 mm
75.1 mm

**Crohn colique à forme
sténosante +
urétéro_hydronéphrose gauche
homme 28 ans**

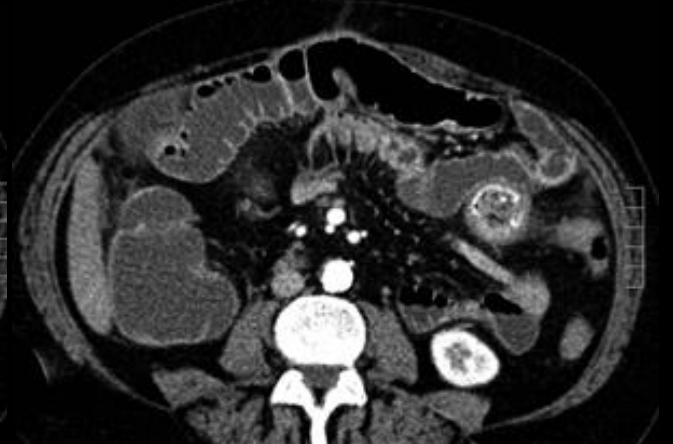
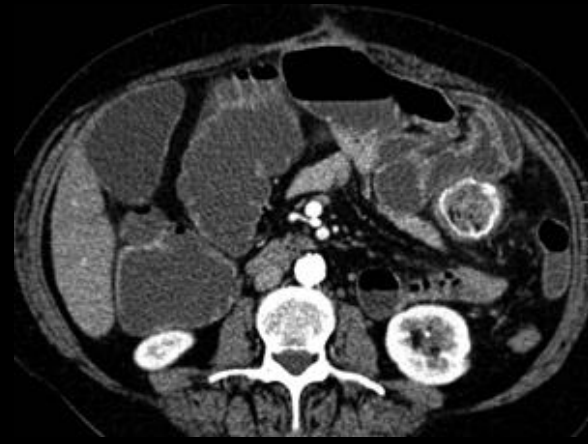
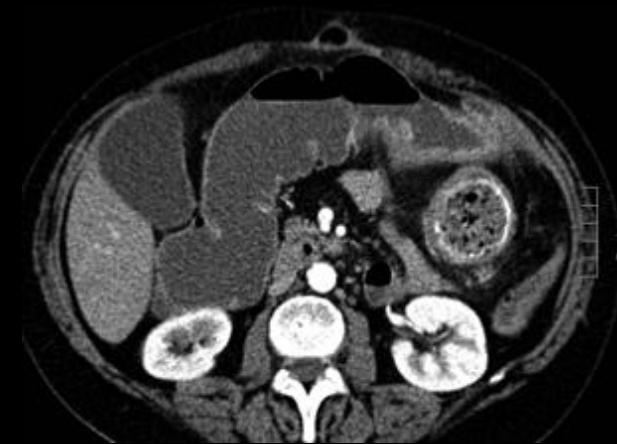
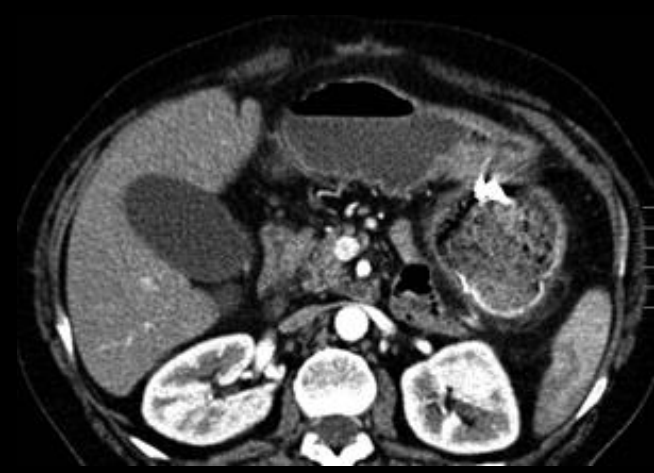
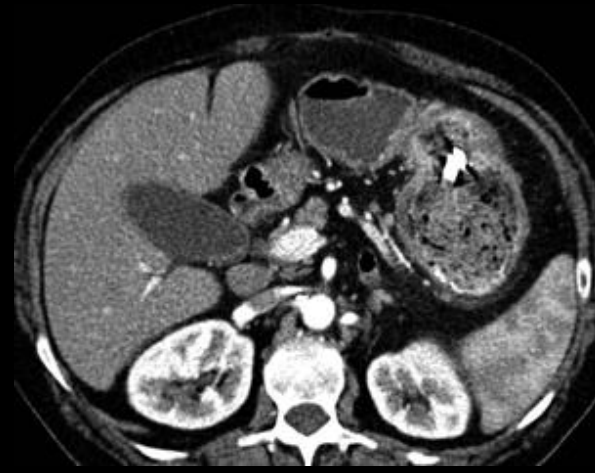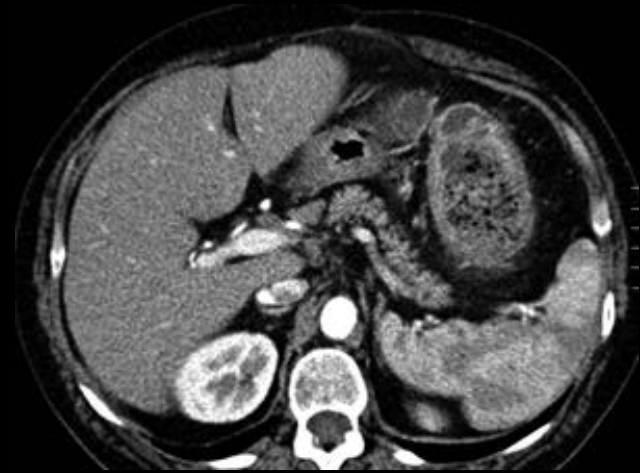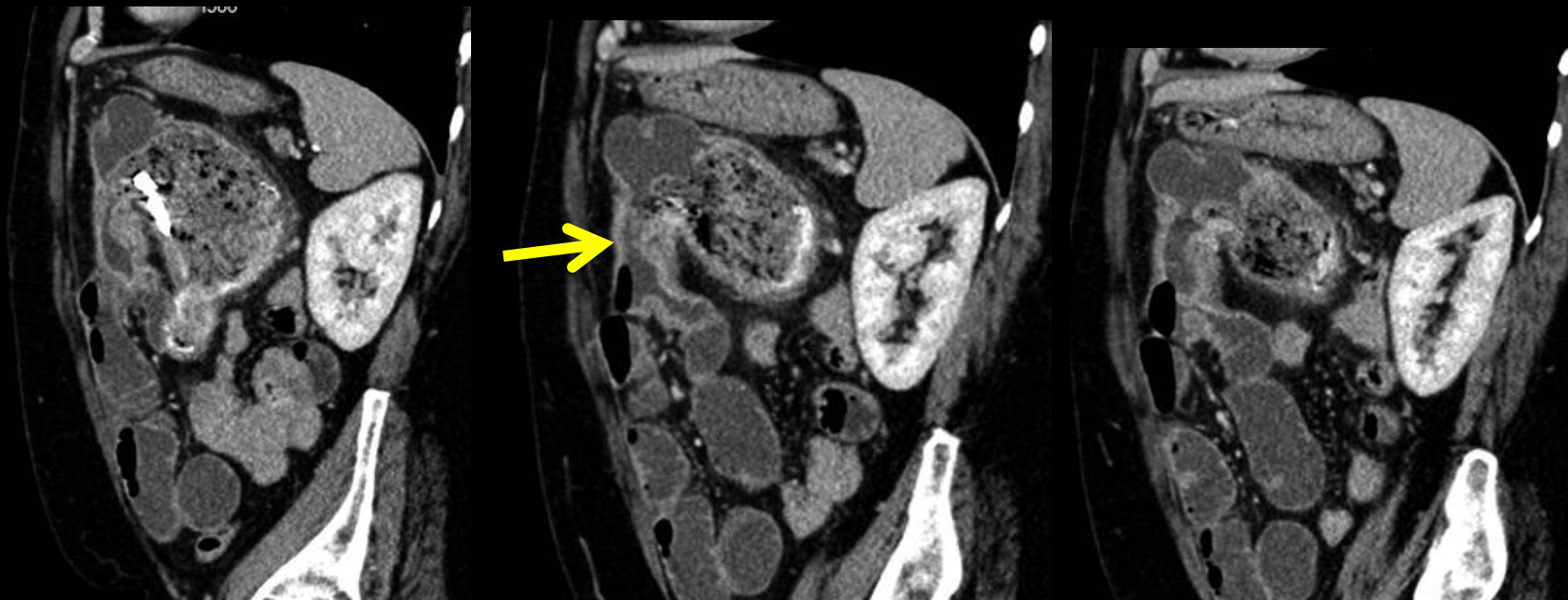endométrios pelvienne profonde -extension à la face antérieure e la charnière recto-sigmpïdienne -urétéro-hydronéphrose

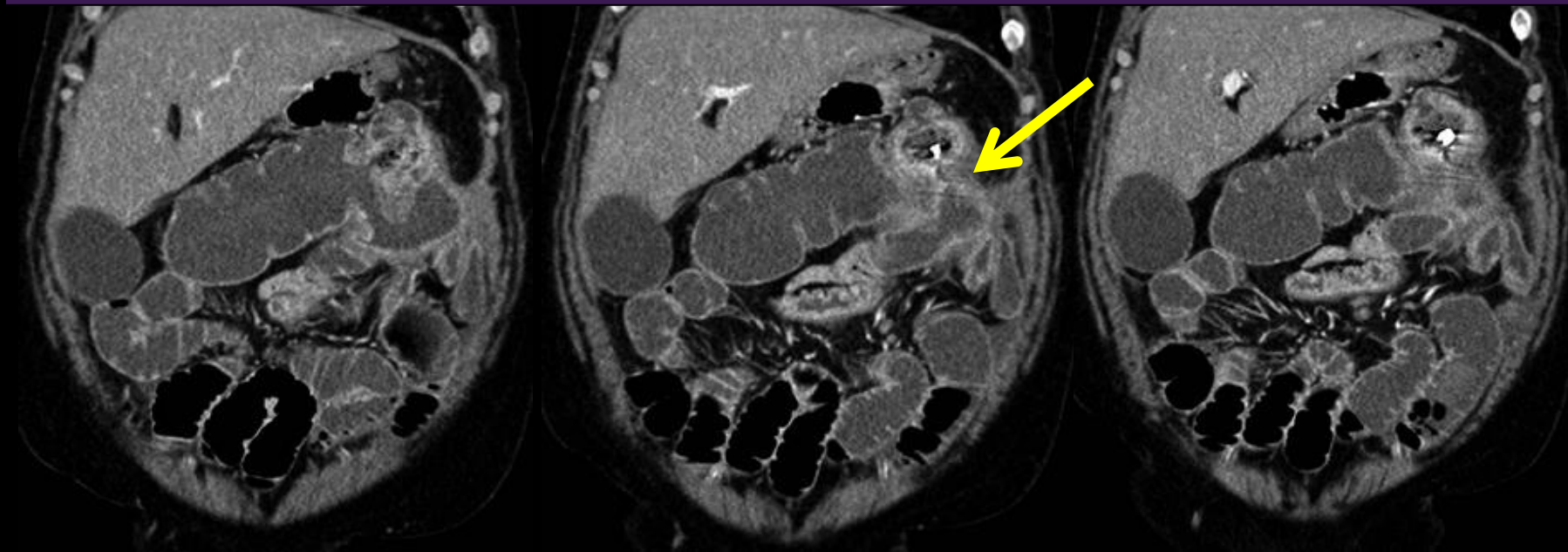
3-1-3 occlusions colo-rectales d'origine endoluminale

3-1-3-1 corps étrangers endoluminaux

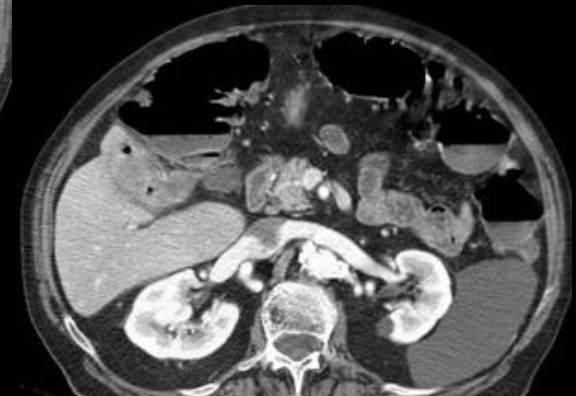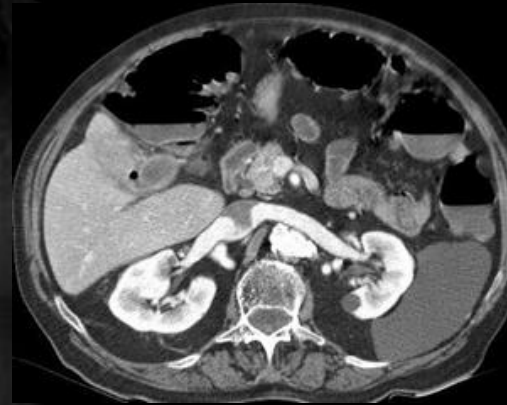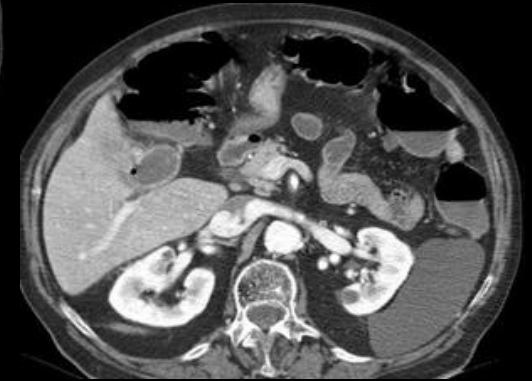


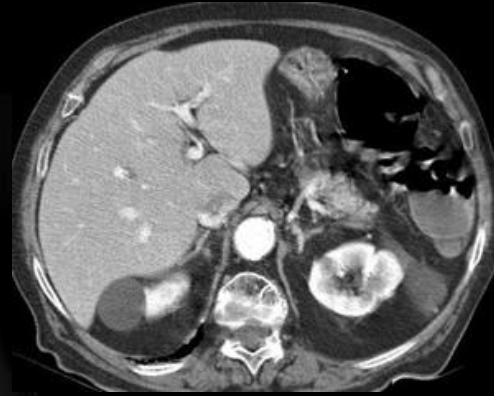
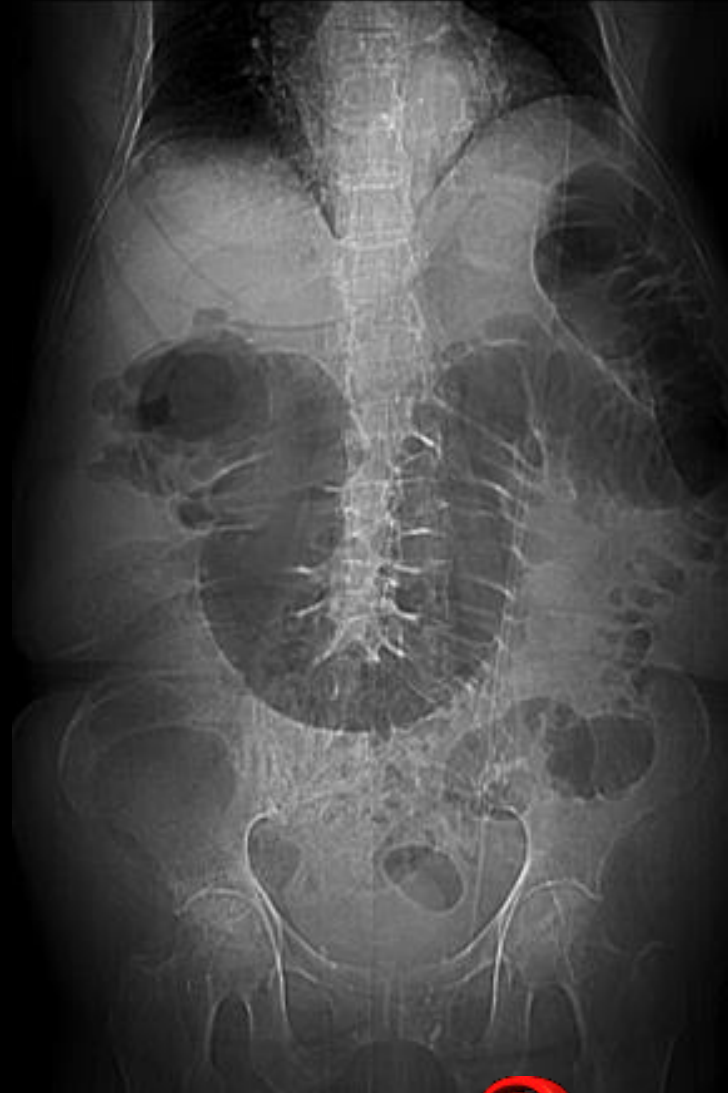
champ opératoire (corpus alienum ou gossypibome) migrant avec fistulisation grêlo-colique et occlusion colique endoluminale de l'angle gauche



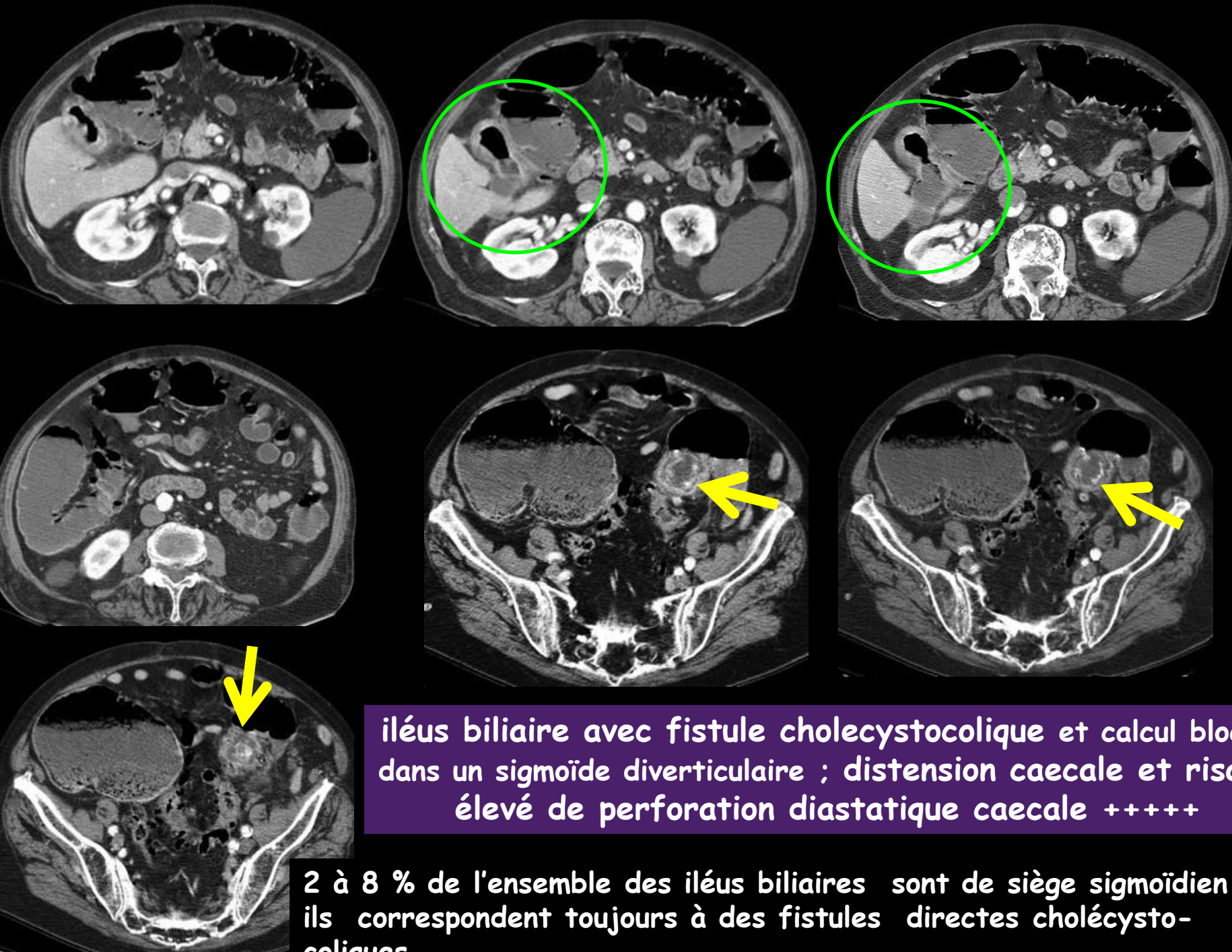
patiente de 83 ans , syndrome occlusif de survenue brutale sans signes infectieux; anémie



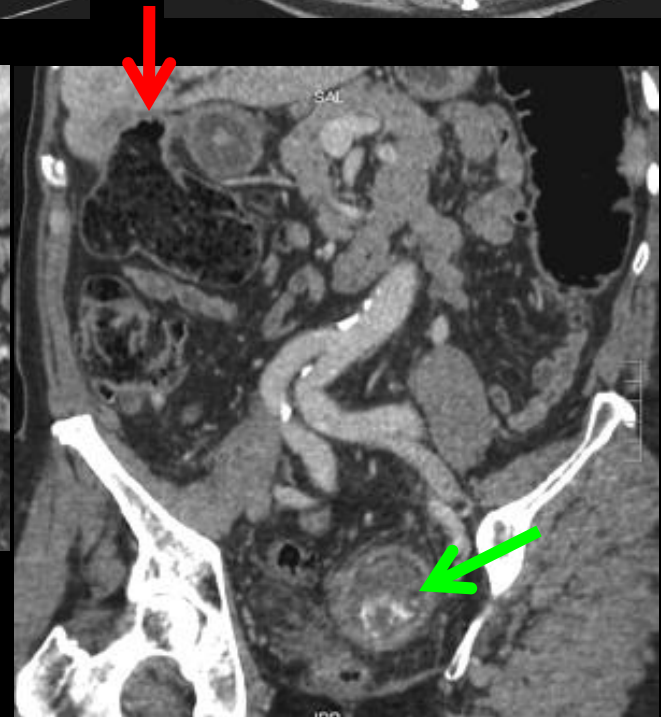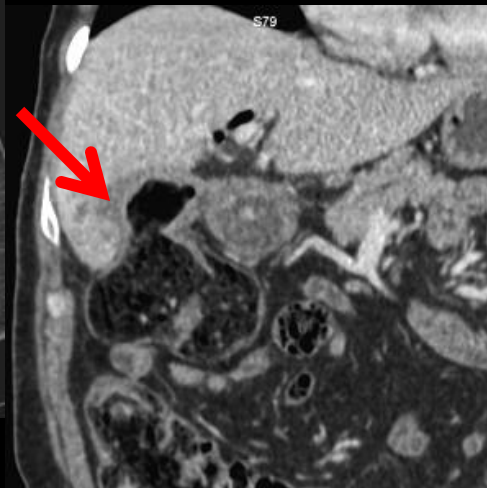
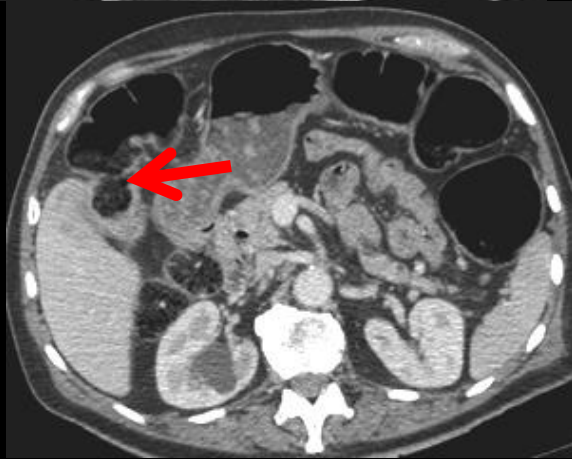
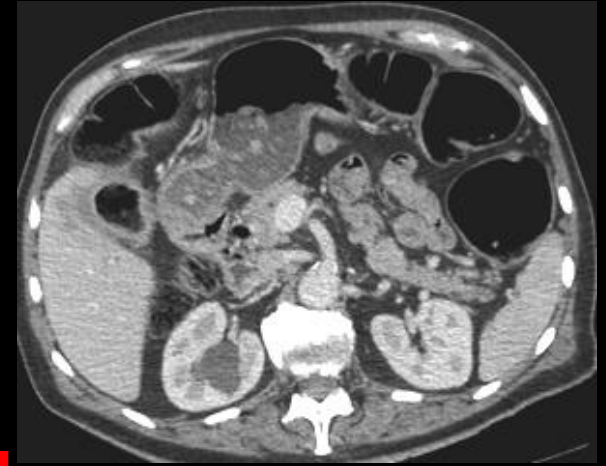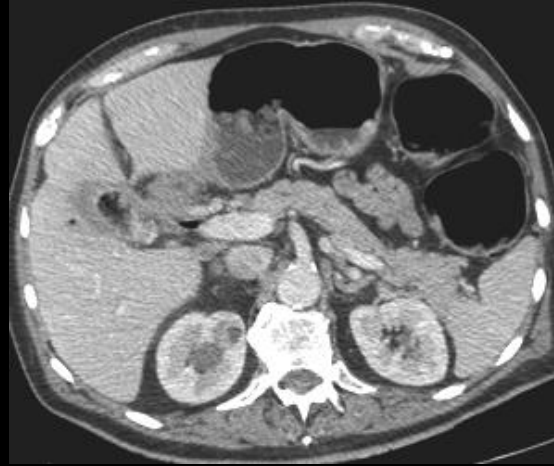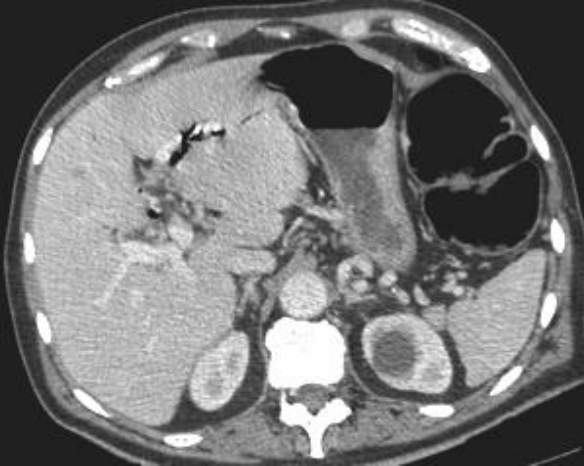diagnostic



y-a-t-il quelque chose d'inhabituel dans cet iléus biliaire , en dehors de l'absence d'aérobilie intra-hépatique ?

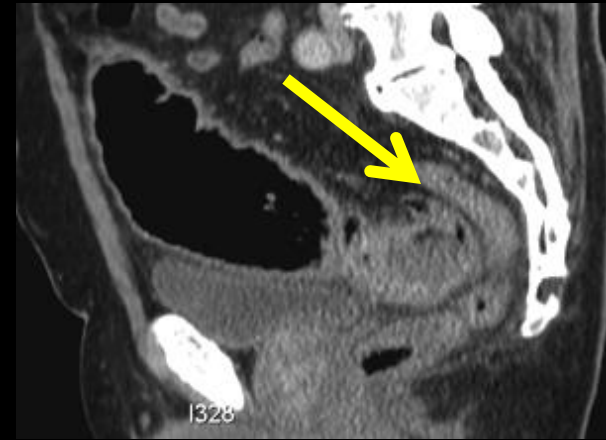
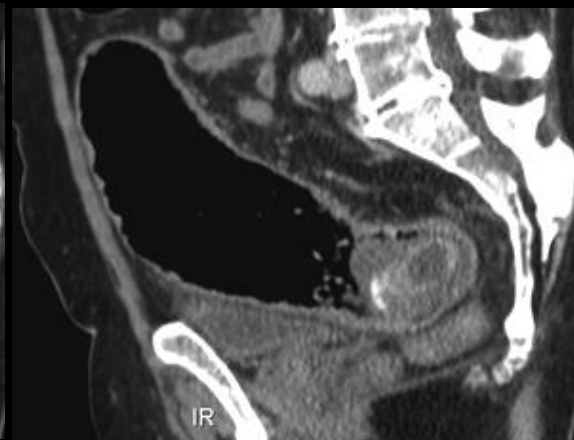
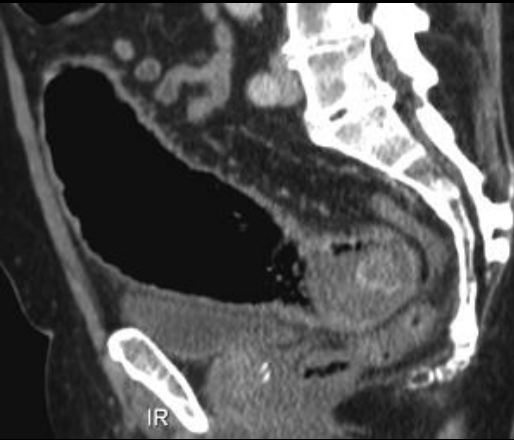
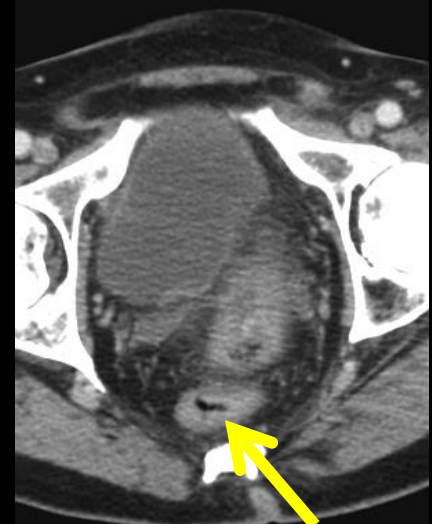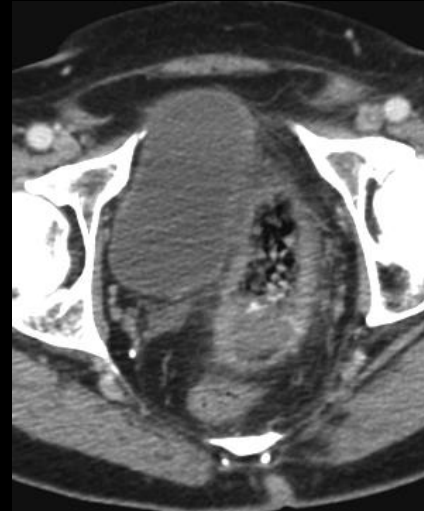

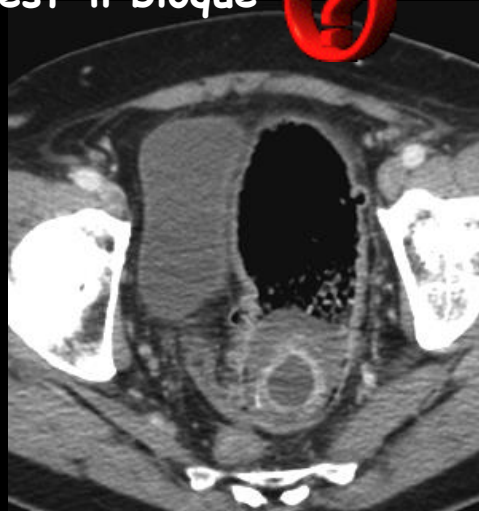
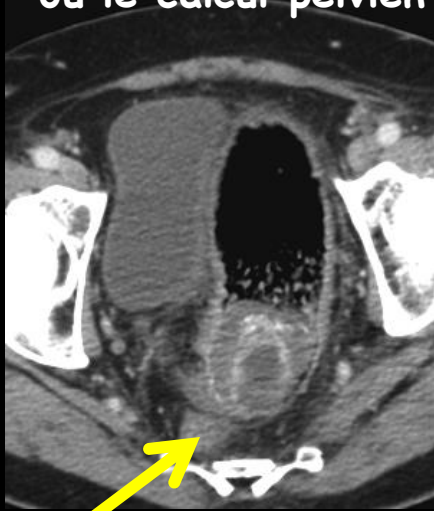patient de 77 ans , syndrome occlusif fébrile avec douleurs pelviennes

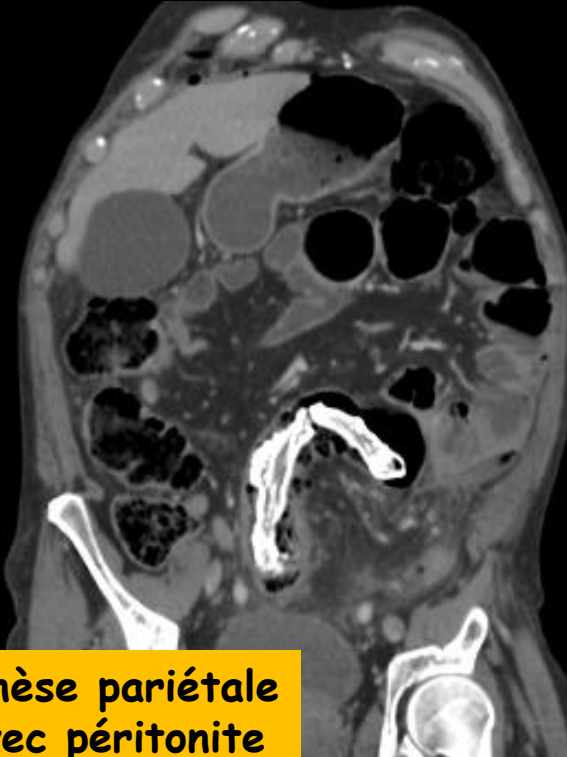
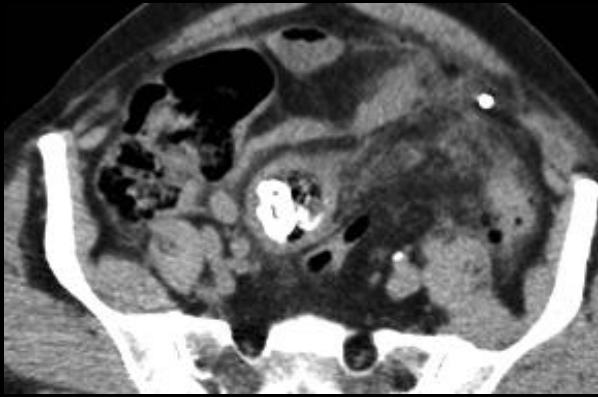
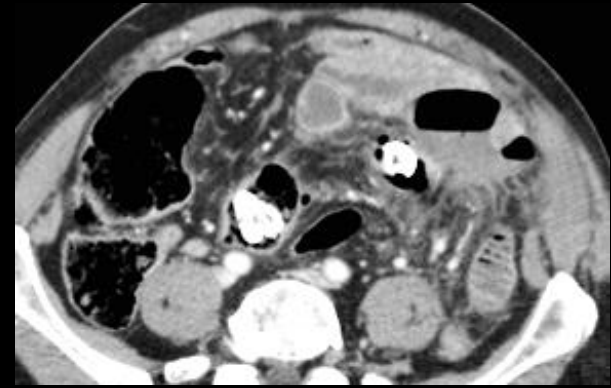
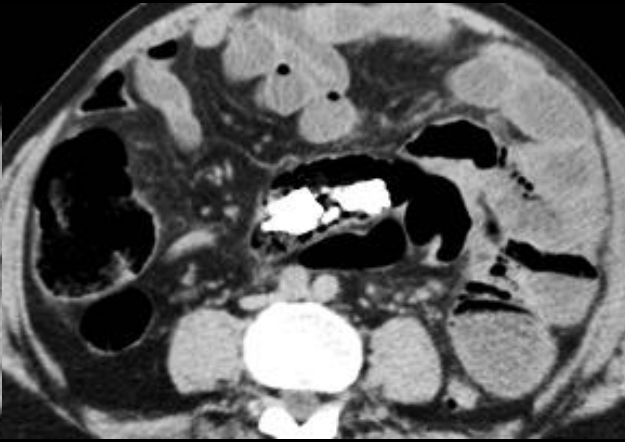
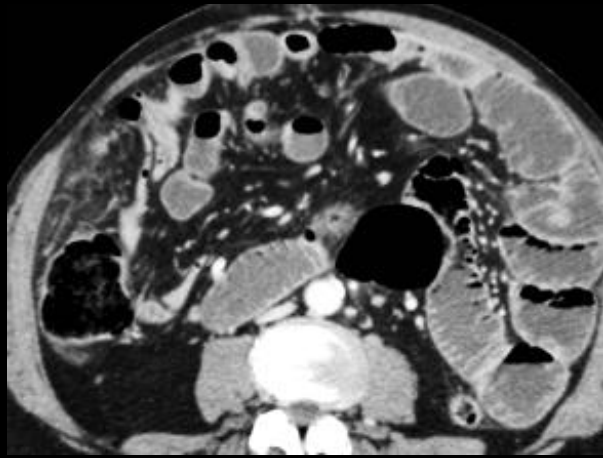


obs. Dr Damien Goudot

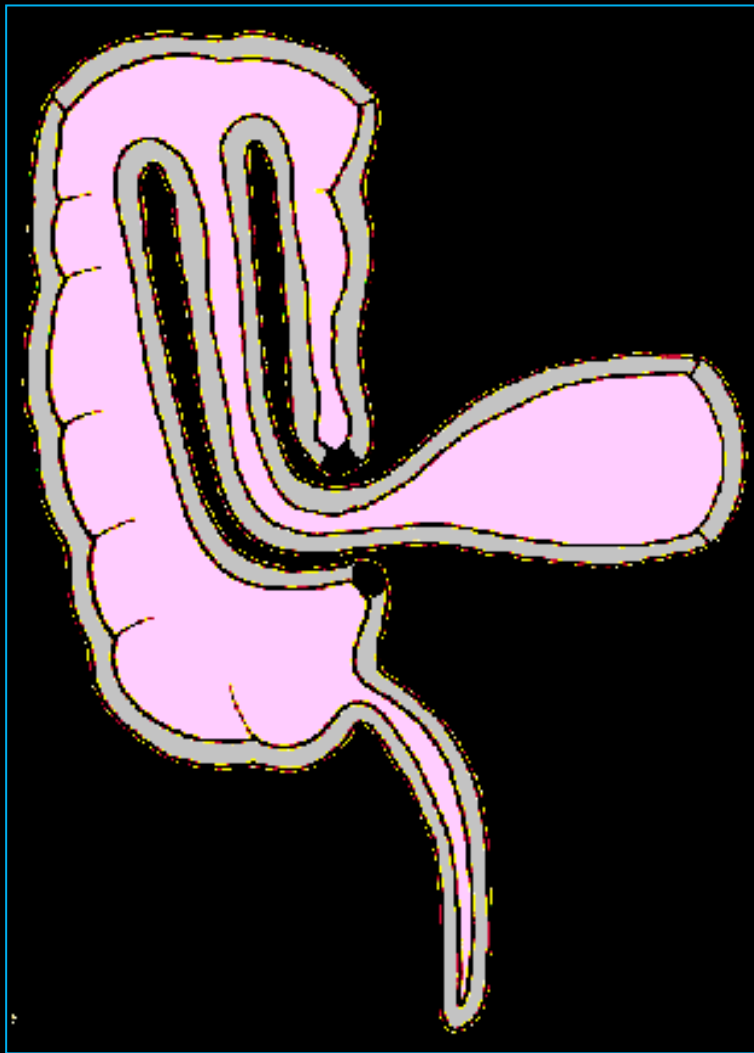
où le calcul pelvien est-il bloqué ?



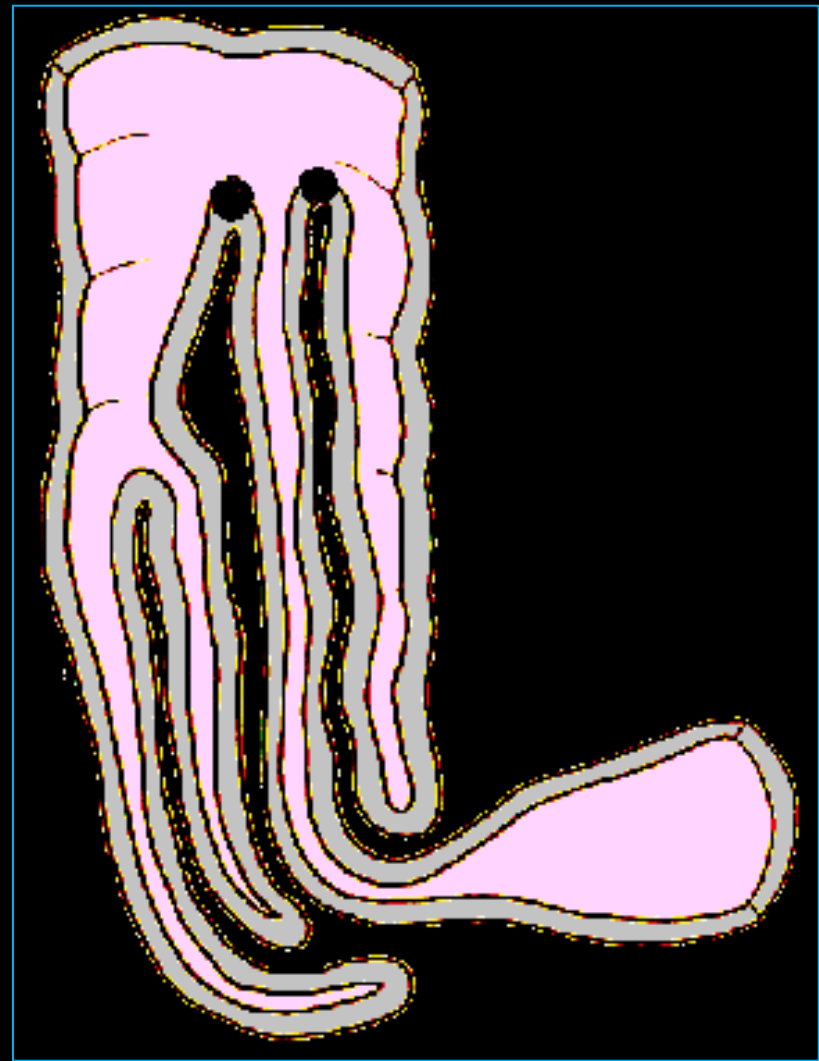
iléus biliaire avec fistule cholecystocolique et calcul bloqué dans le sigmoïde ; résection sigmoïdienne nécessaire en raison de l'état de la paroi .



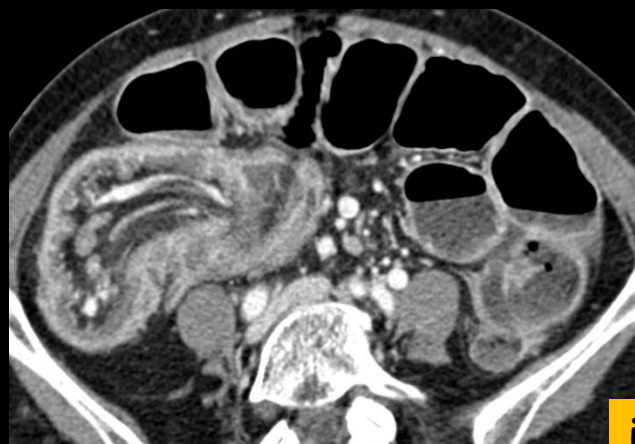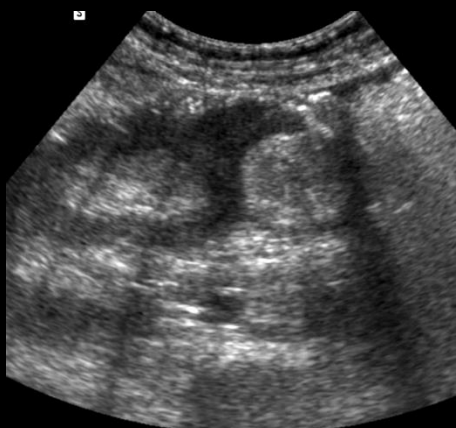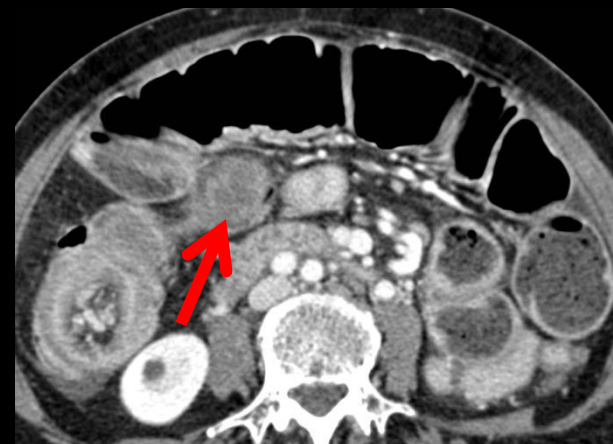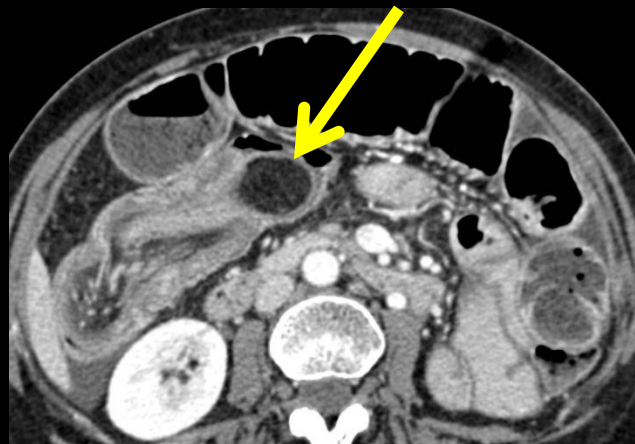
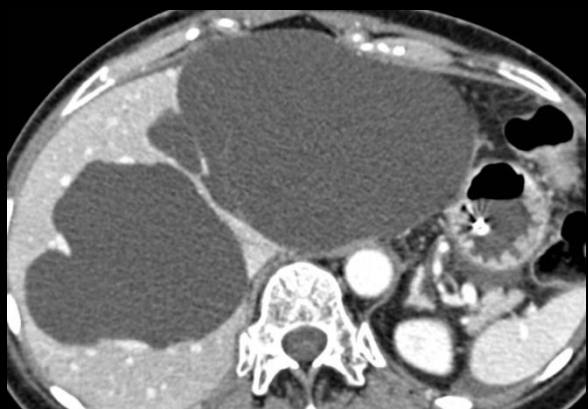migration sigmoïdienne d'une prothèse pariétale pour cure de hernie inguinale , avec péritonite ;résection sigmoïdienne



Invagination iléo-colique /
transvalvulaire: valvule de
Bauhin en place

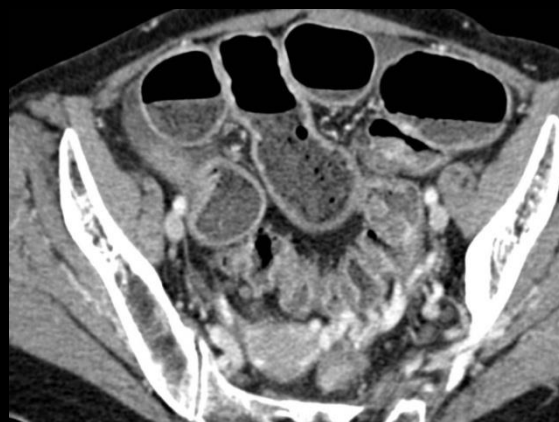
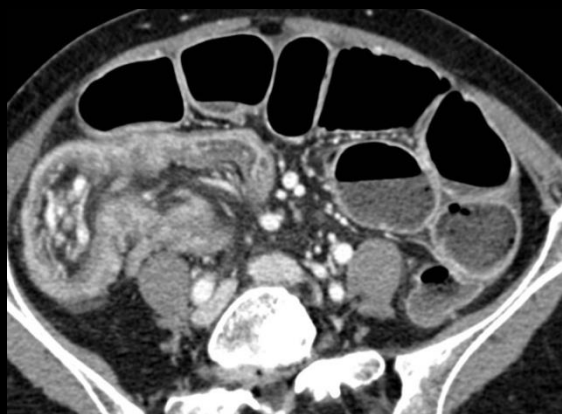
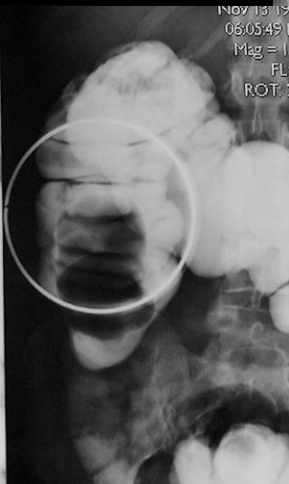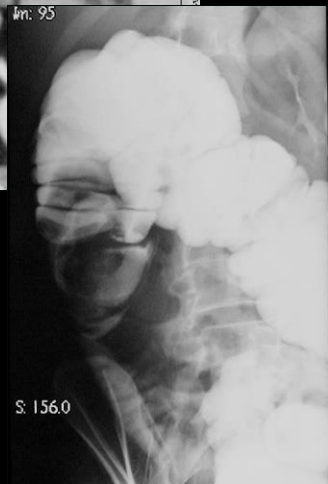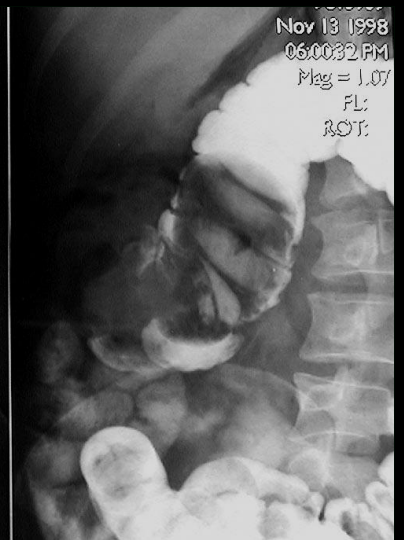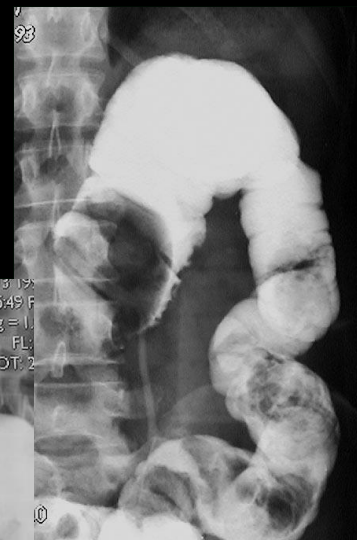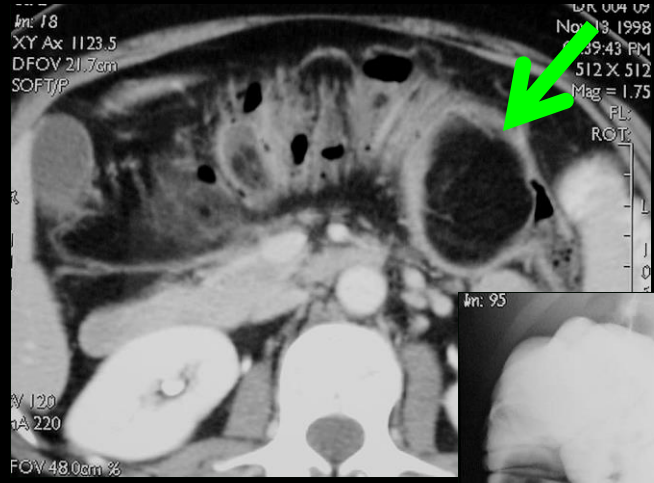
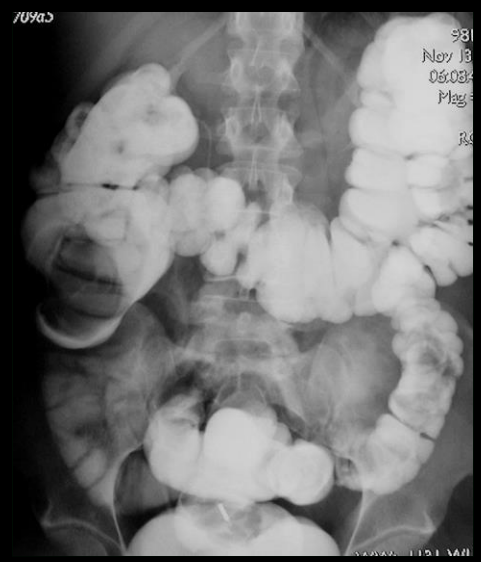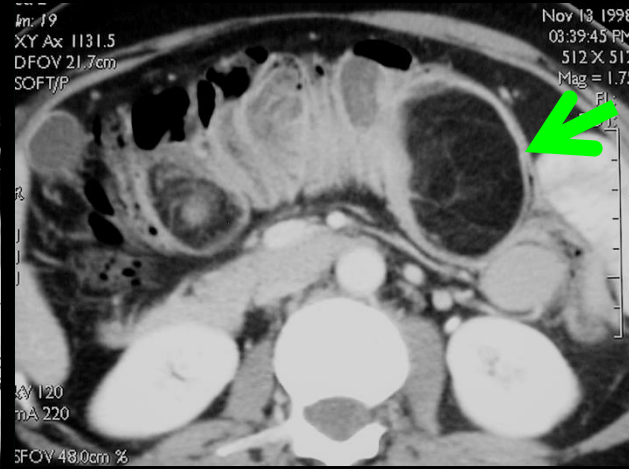
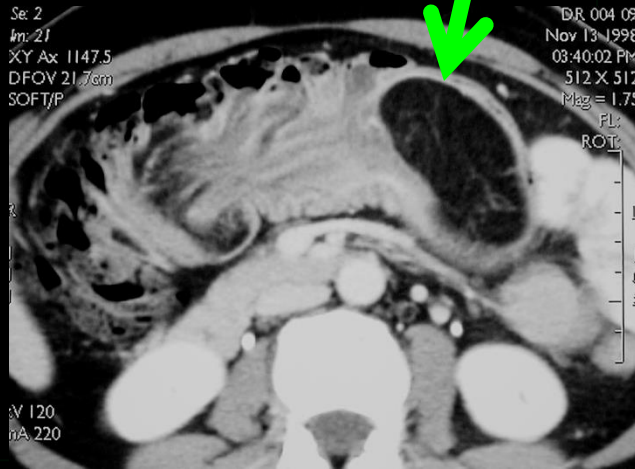
Invagination iléo-caeco-colique
: appendice invaginé, valvule
au sommet du boudin
d'invagination



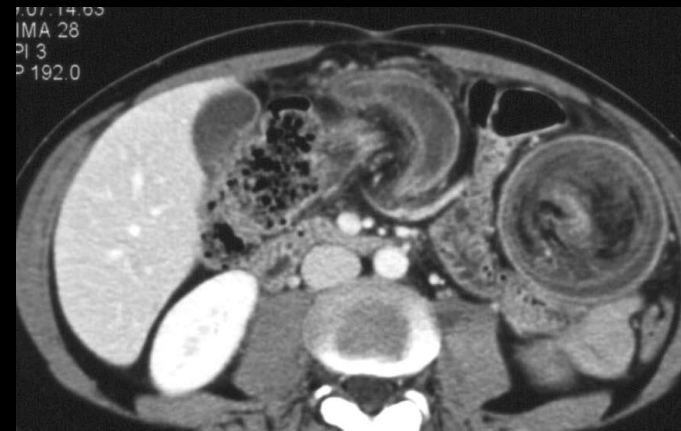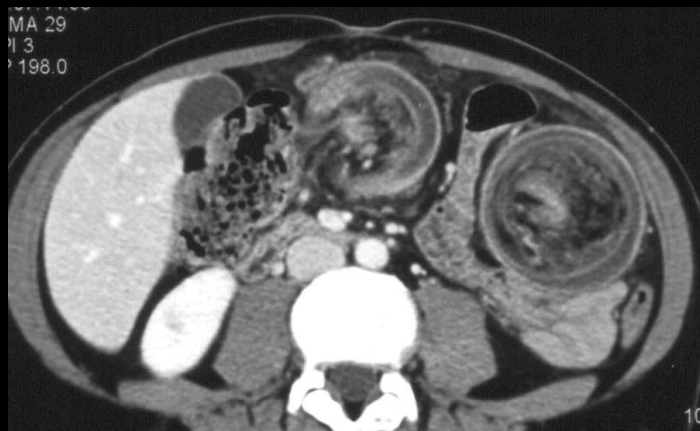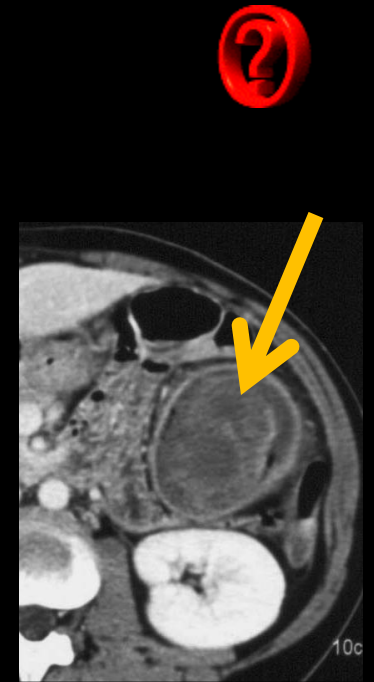
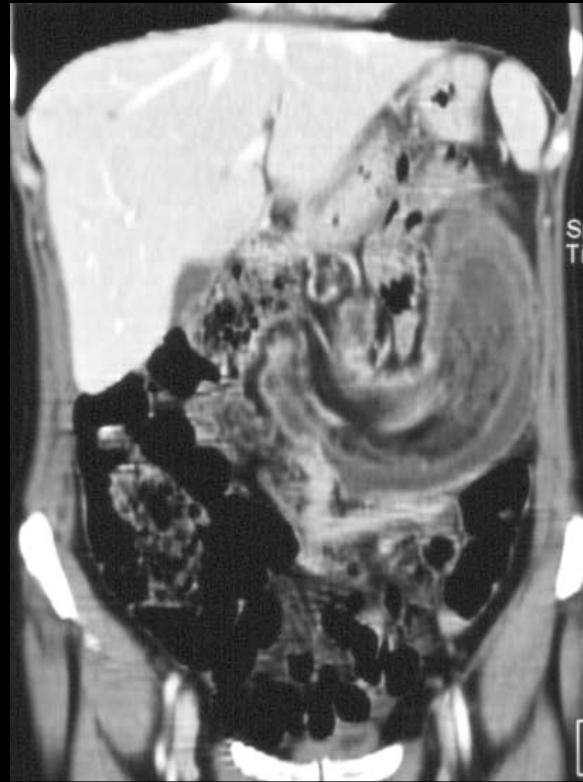
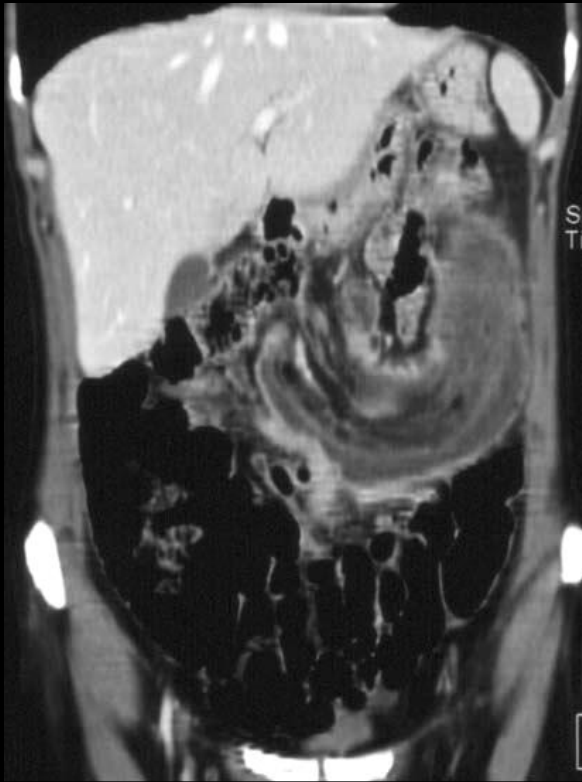
femme, 57 ans
syndrome sub-occlusif
évoluant depuis 15 j
masse palpée en FID

invagination colo-colique
chronique sur lipome caecal

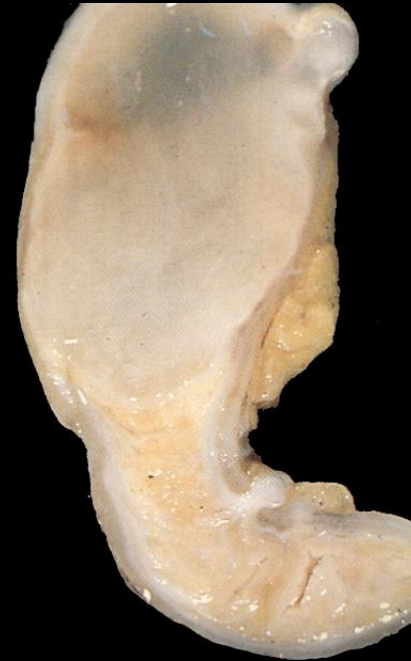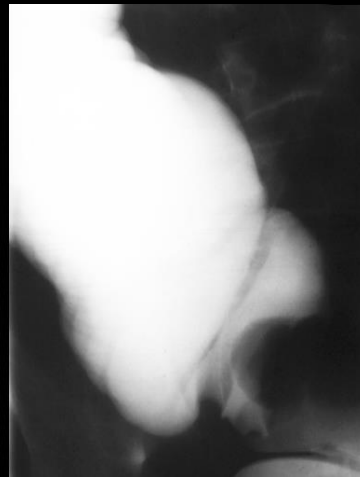
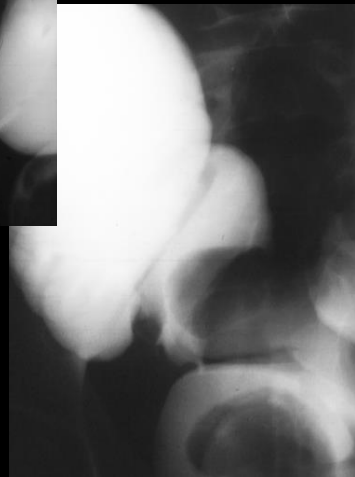
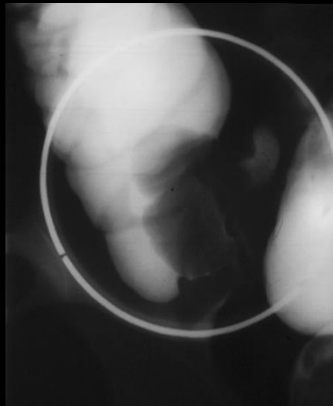
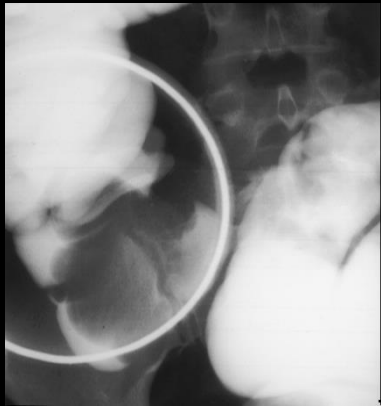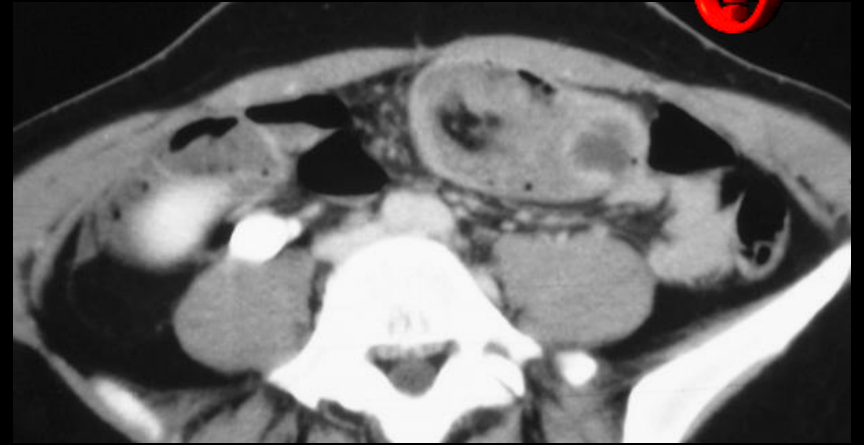
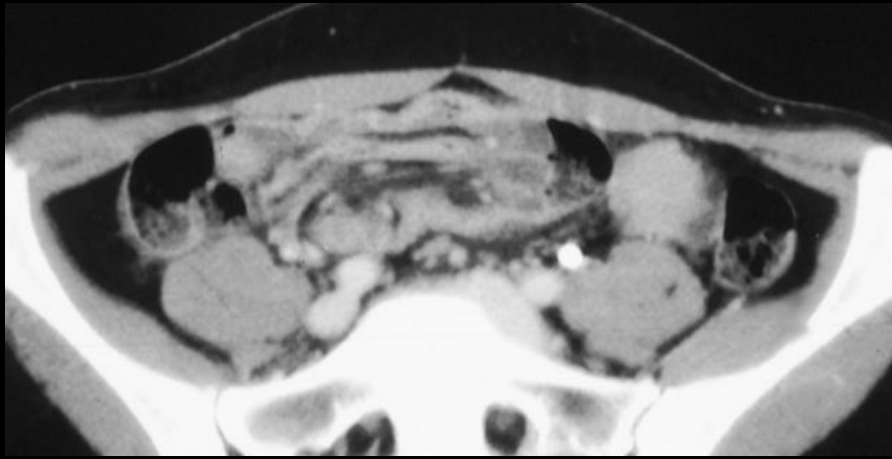




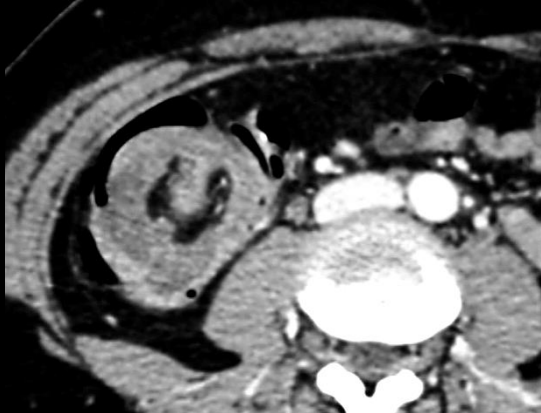
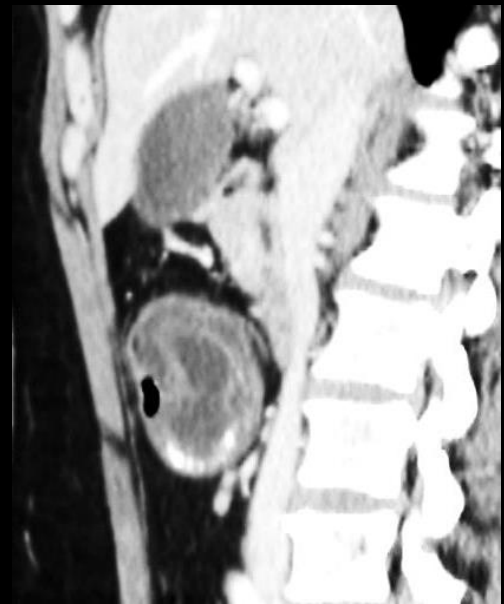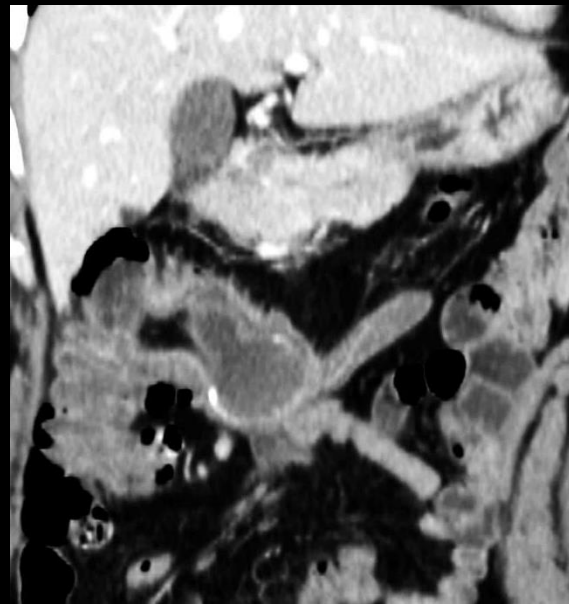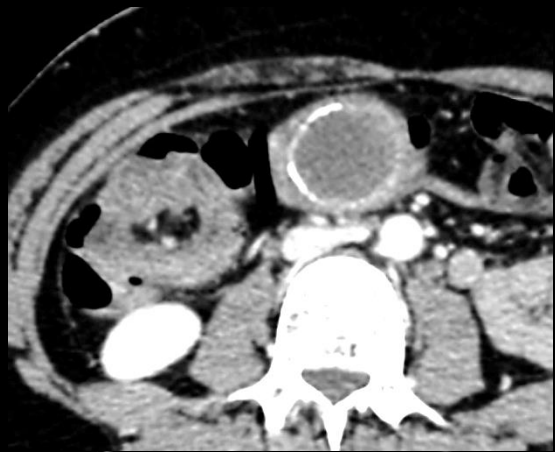
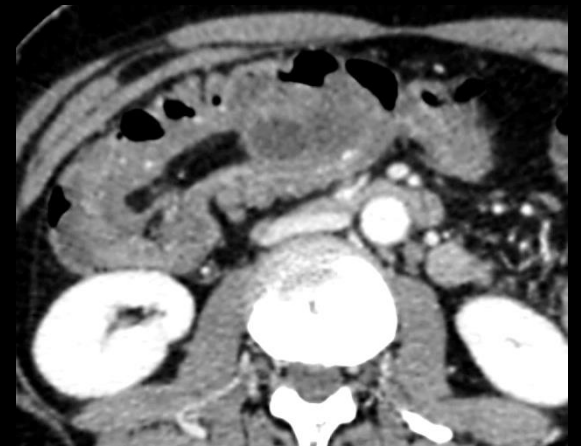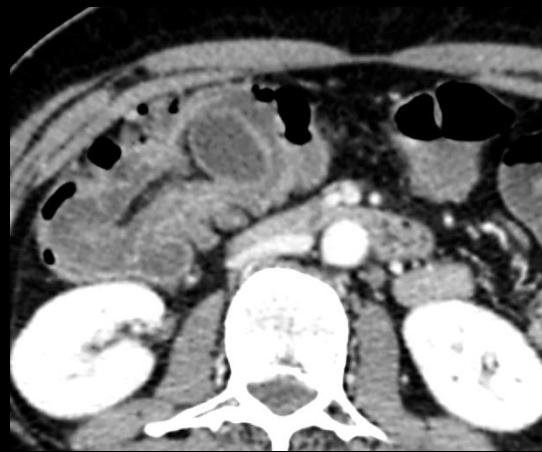
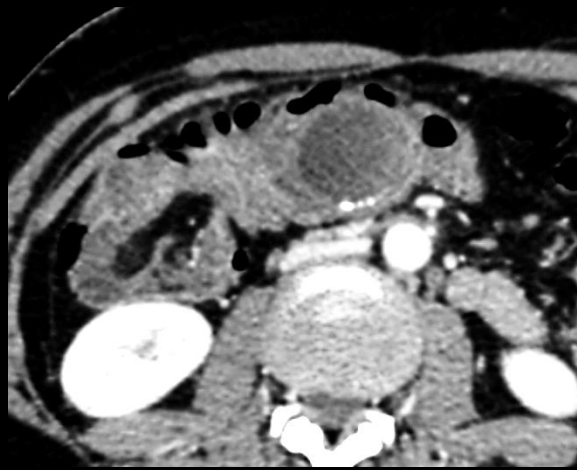**invagination chronique
sur lipome du colon ascendant**



invagination colo-colique sur adénocarcinome sténosant du caecum

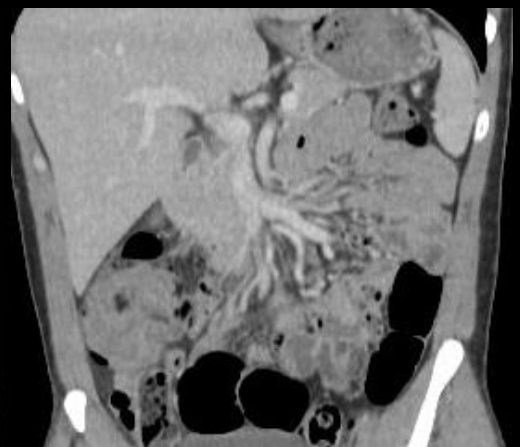
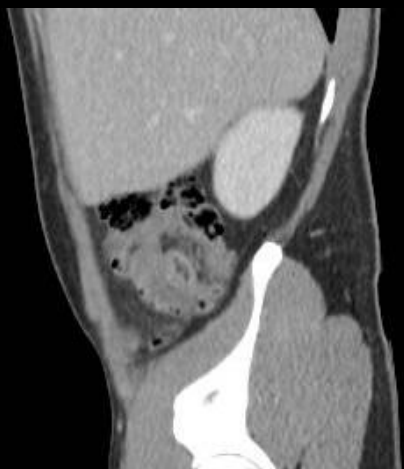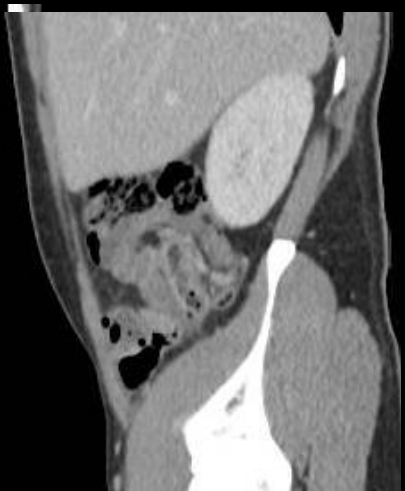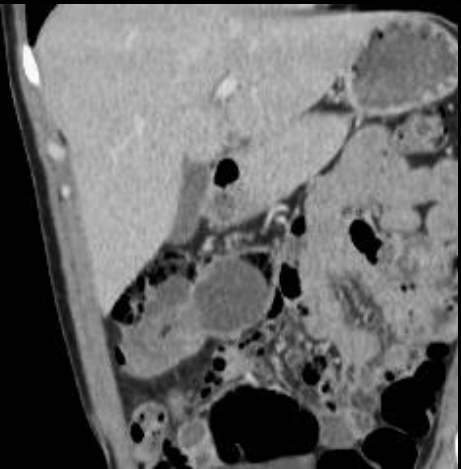
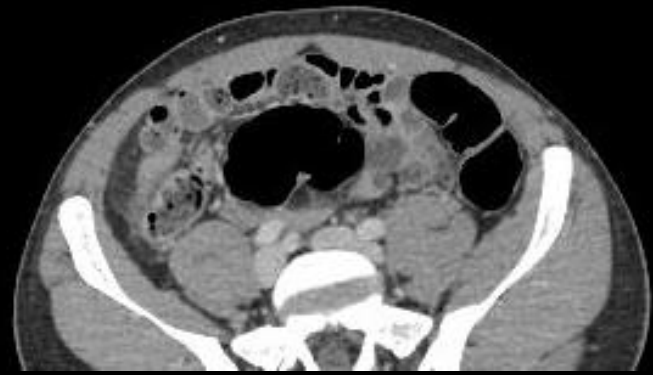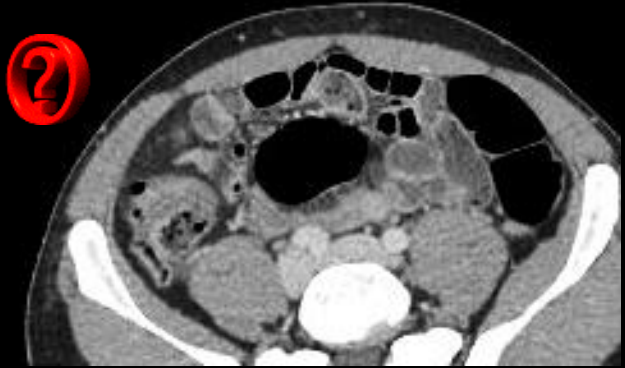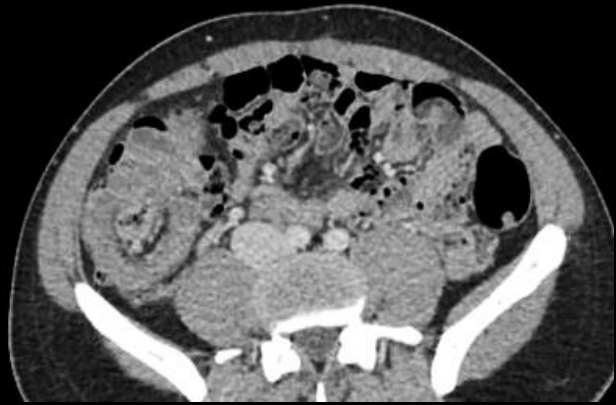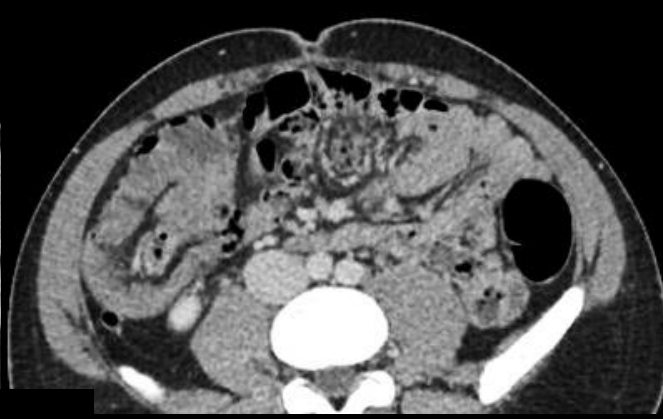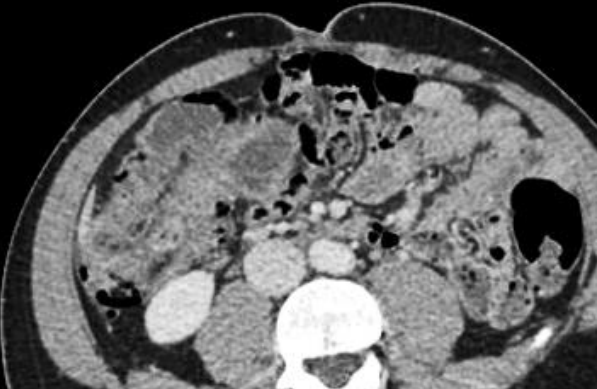


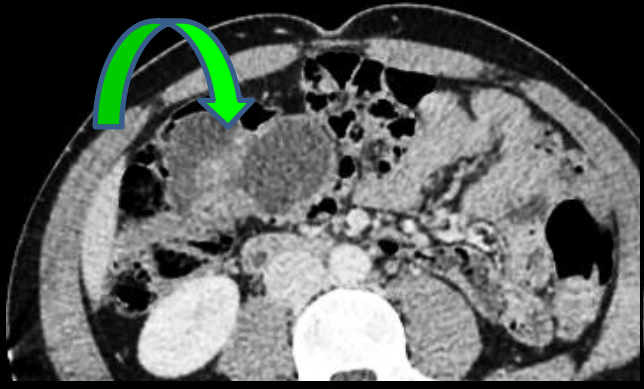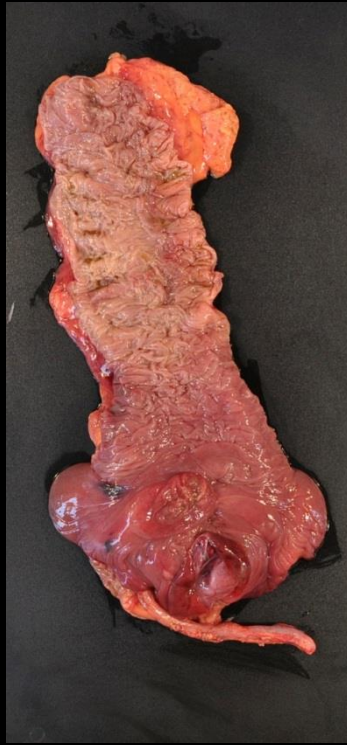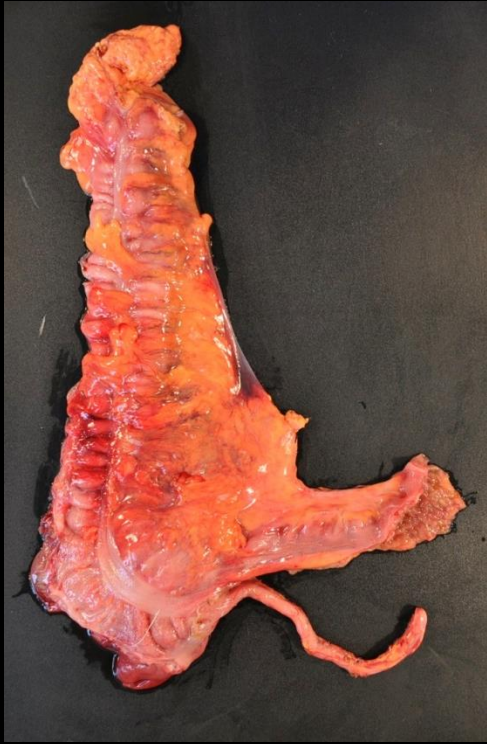**invagination iléo-colique
chronique sur mucocèle
appendiculaire**



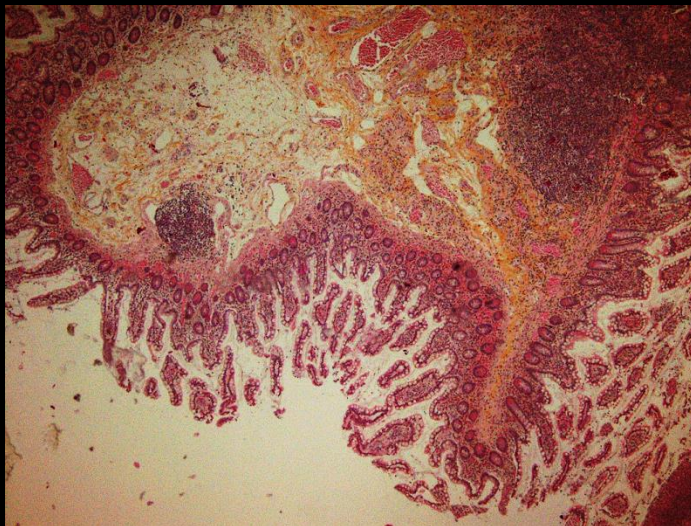
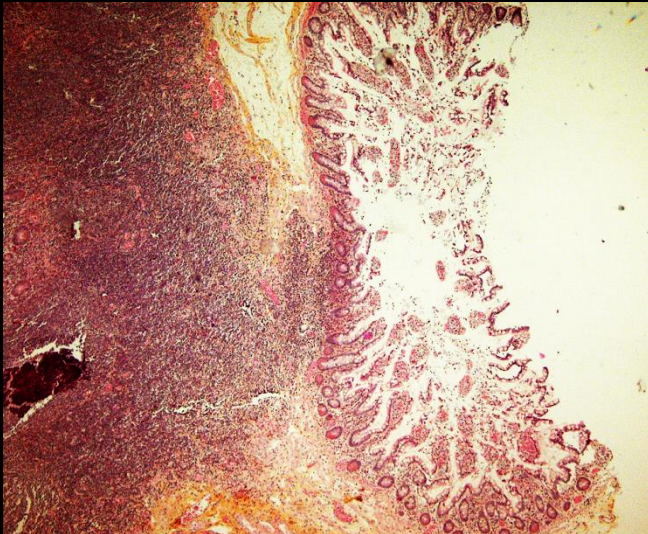
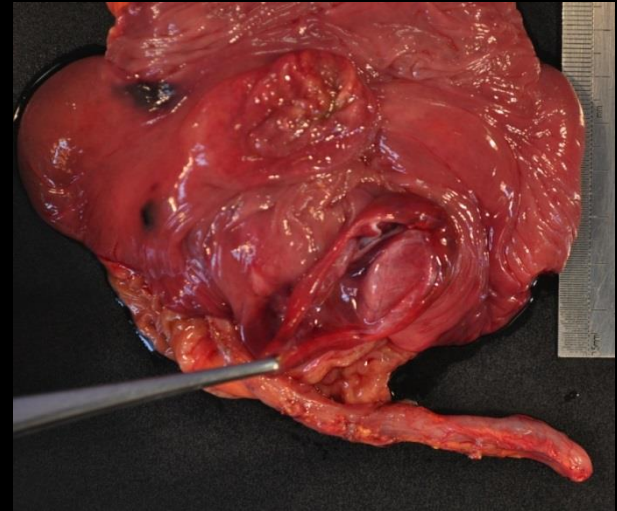
invagination iléo-colique
chronique sur mucocèle
appendiculaire



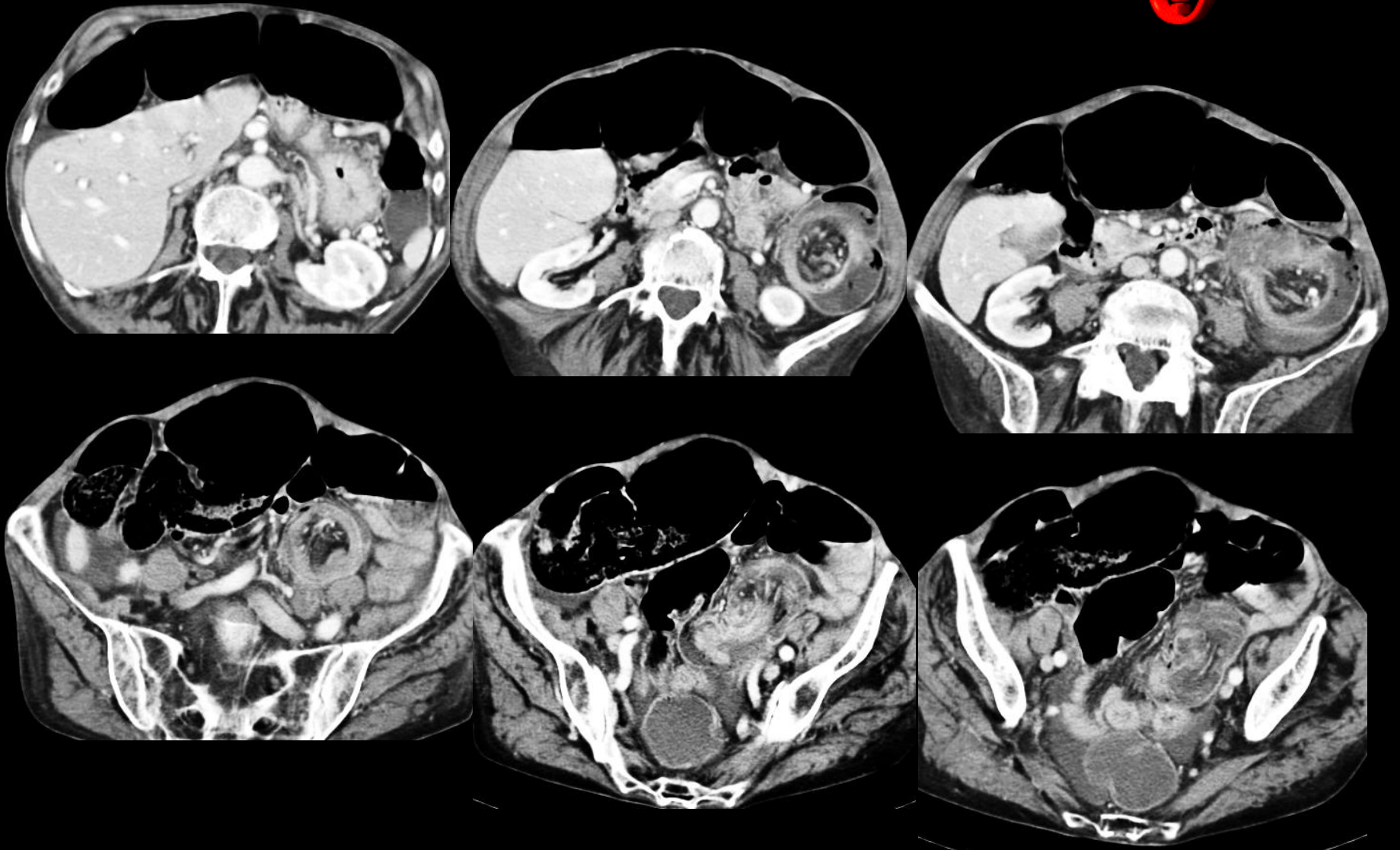




Lésion kystisée correspondant à une lésion bordée d'une muqueuse de type colique remaniée siège de dystrophies architecturales associées à un infiltrat inflammatoire marquée.

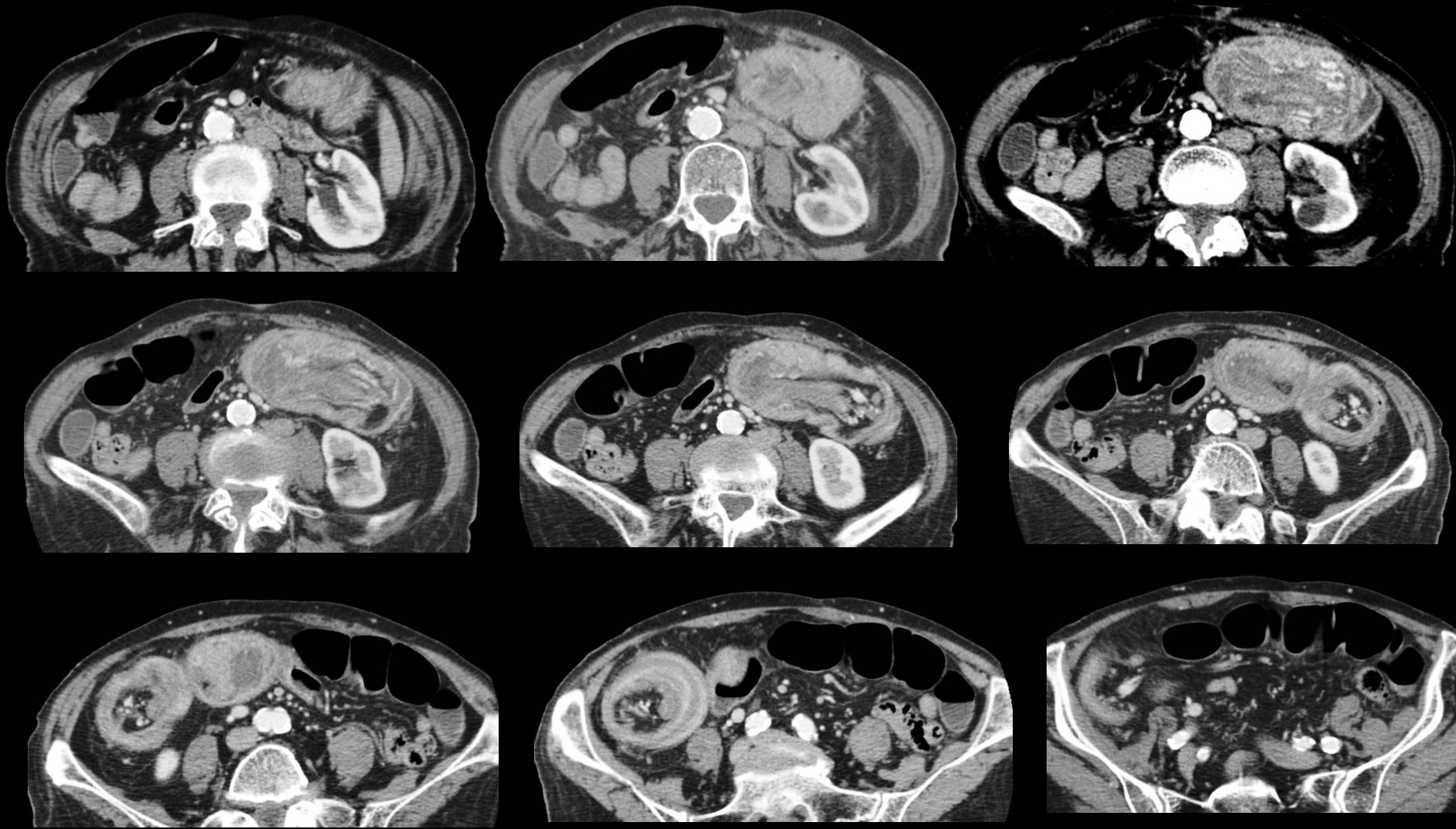


invagination
iléo-colique
chronique sur
duplication
kystique colique

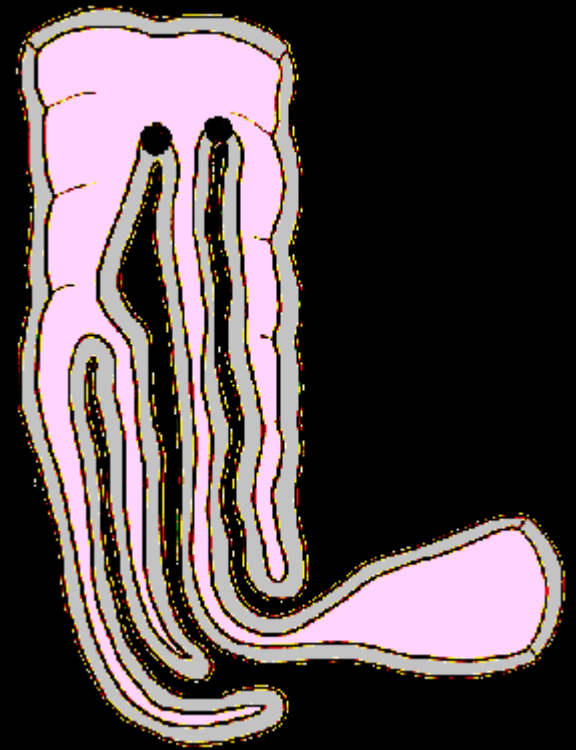
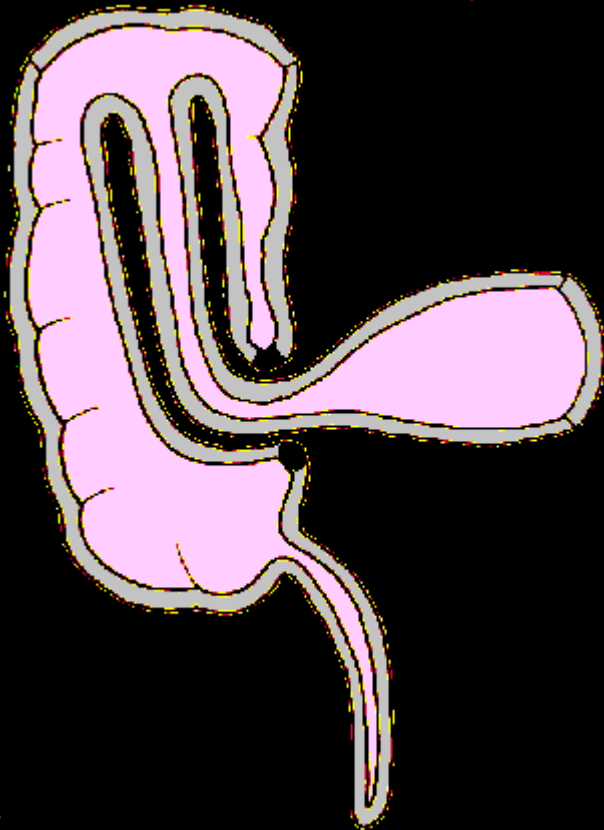
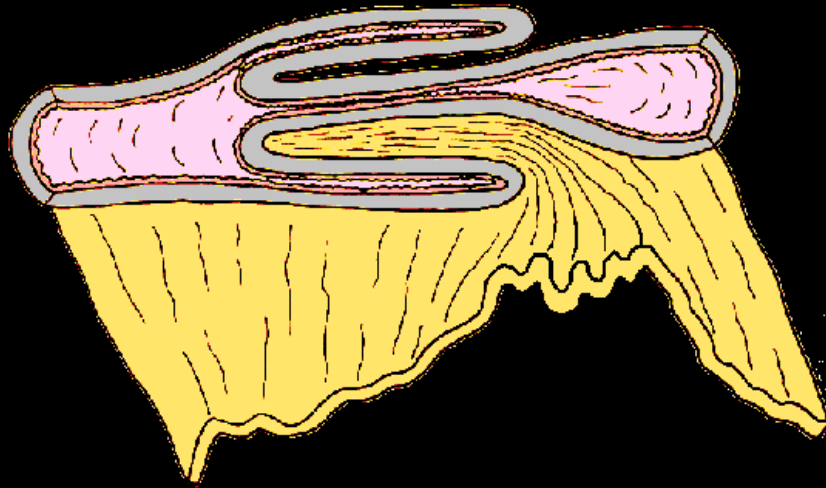


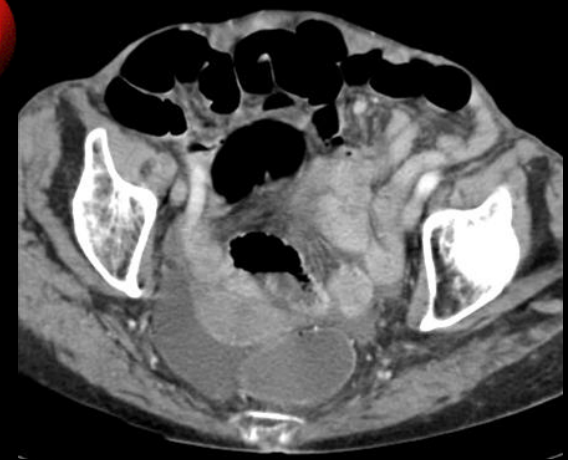
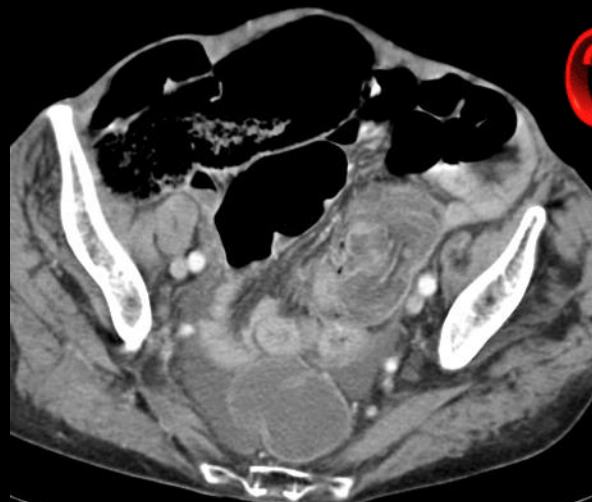
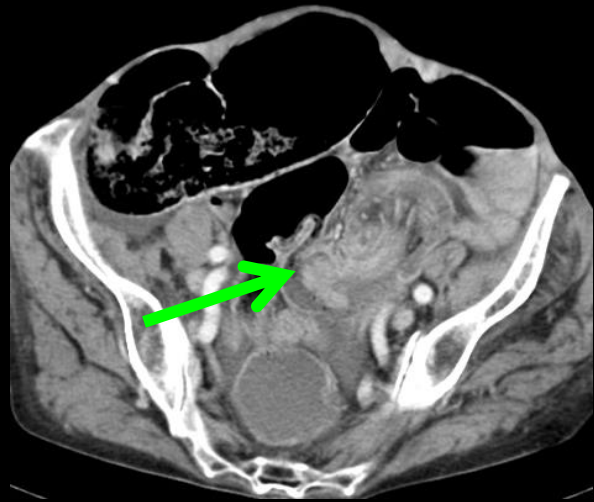
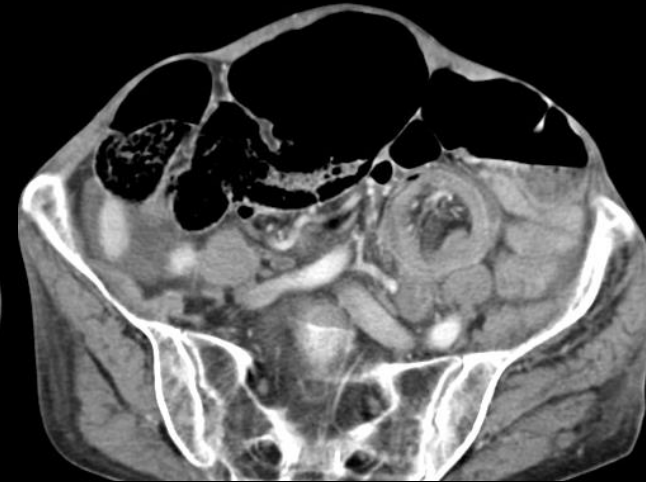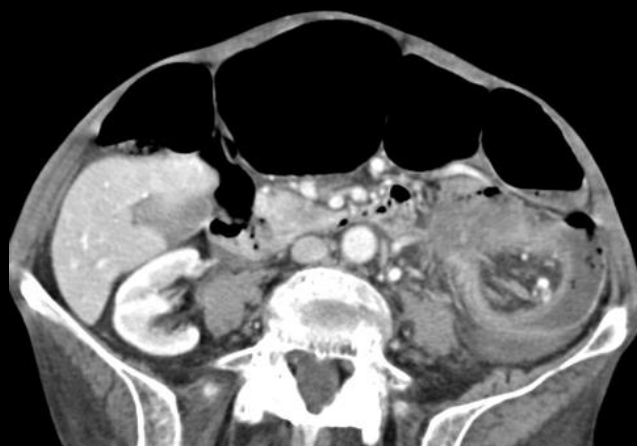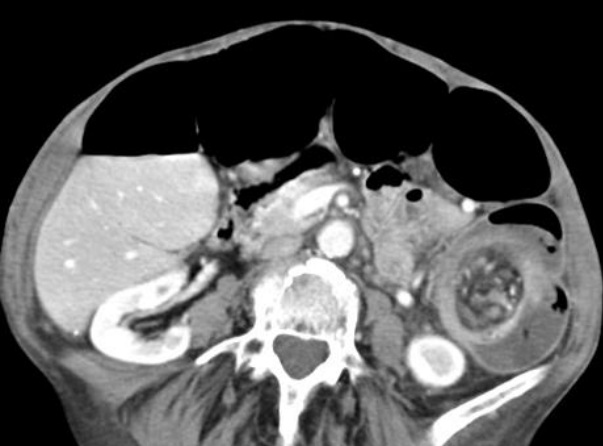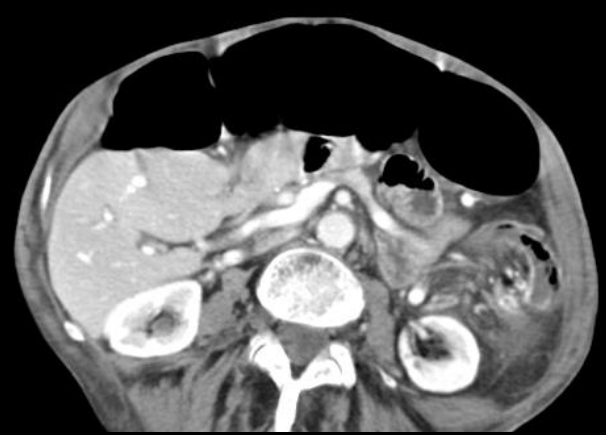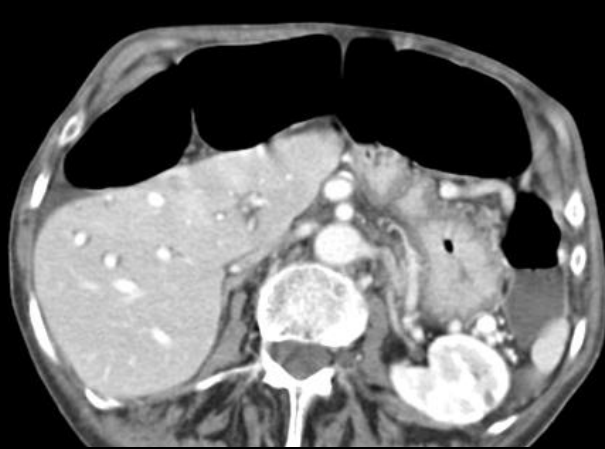
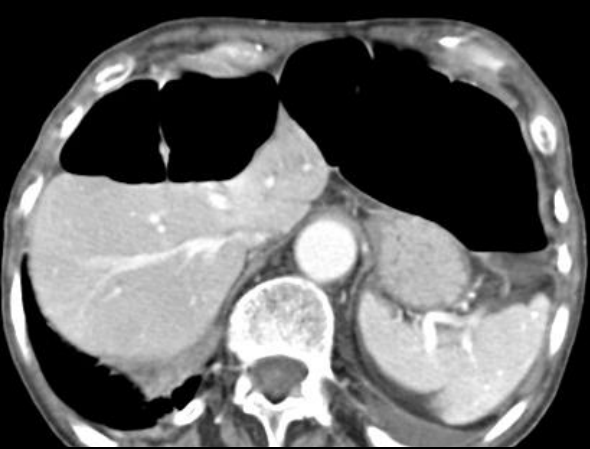invagination iléo-colique chronique sur adénocarcinome caecal

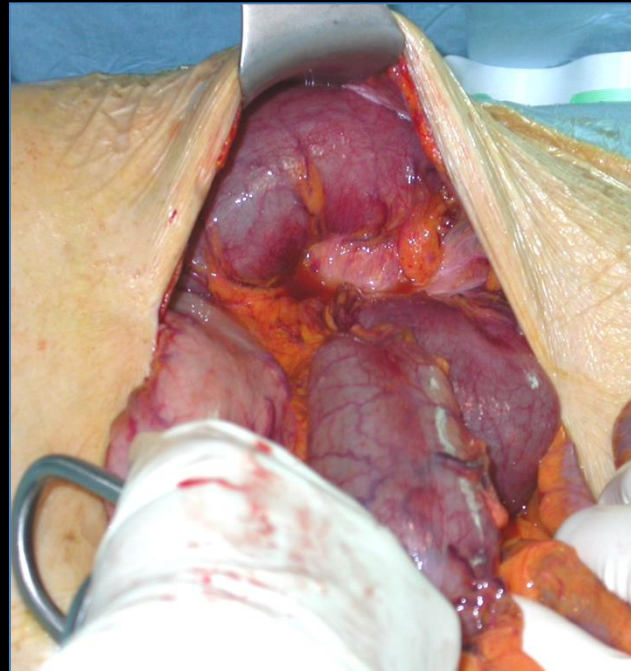
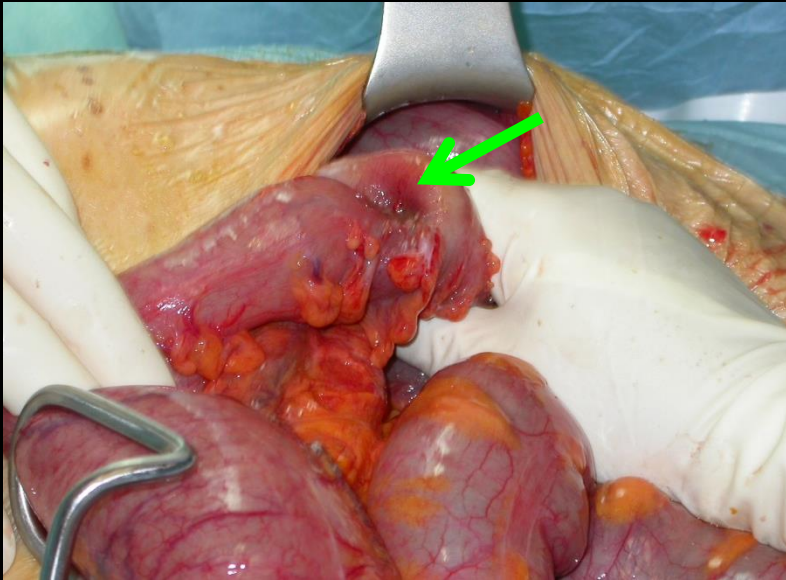
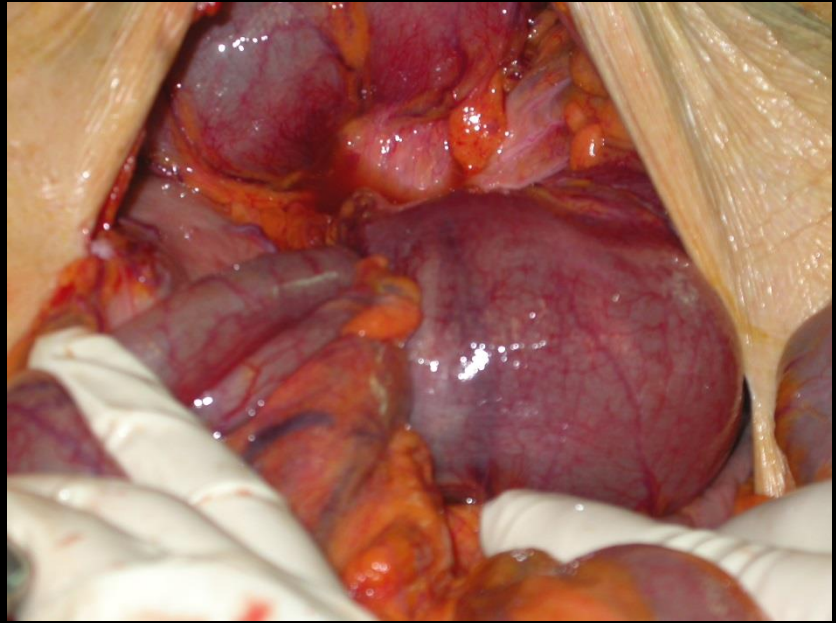
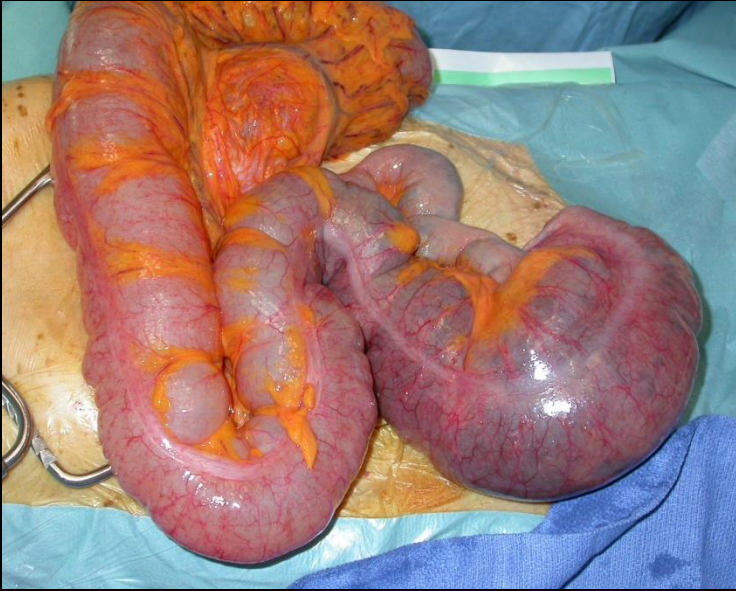3-1-3-2 invaginations coliques

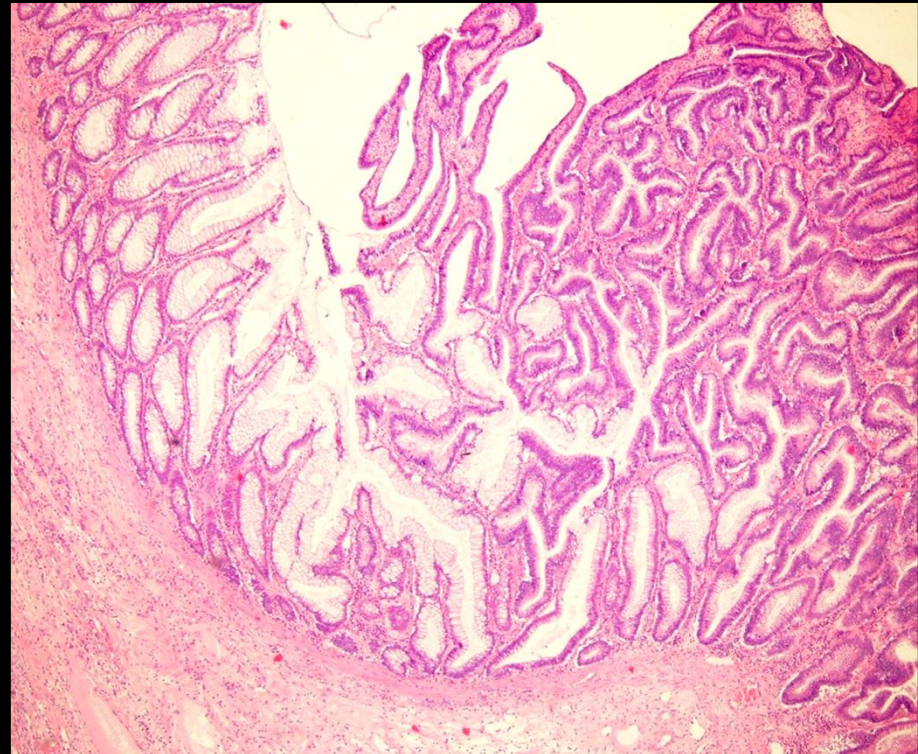
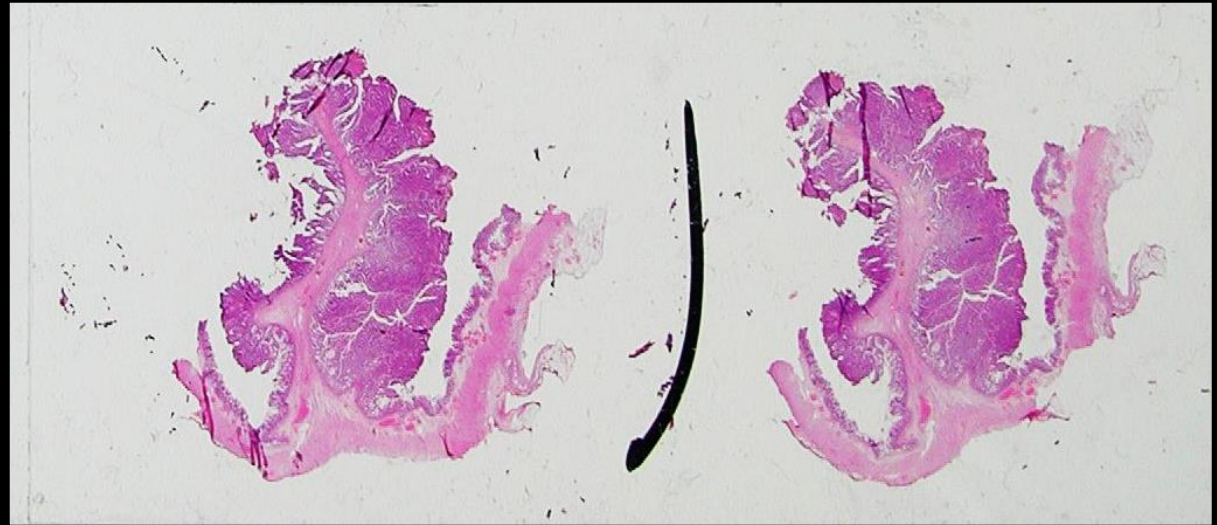
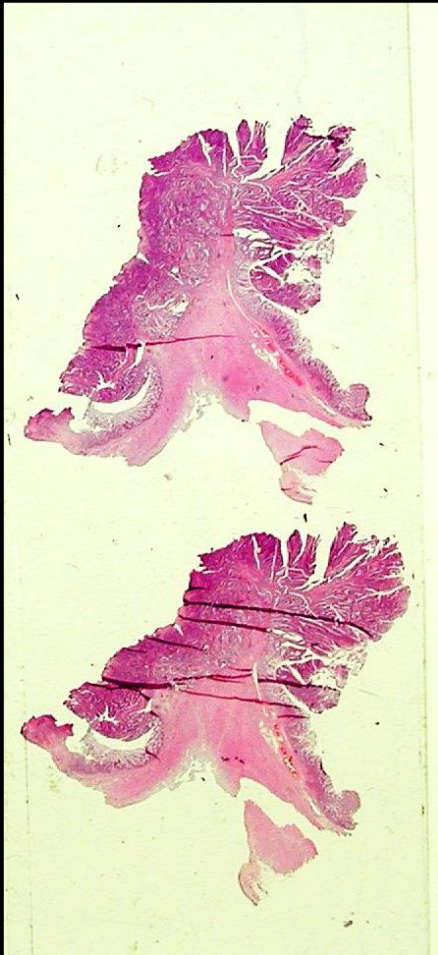

intussusception colo-colique sur adénocarcinome de la valvule de Bauhin

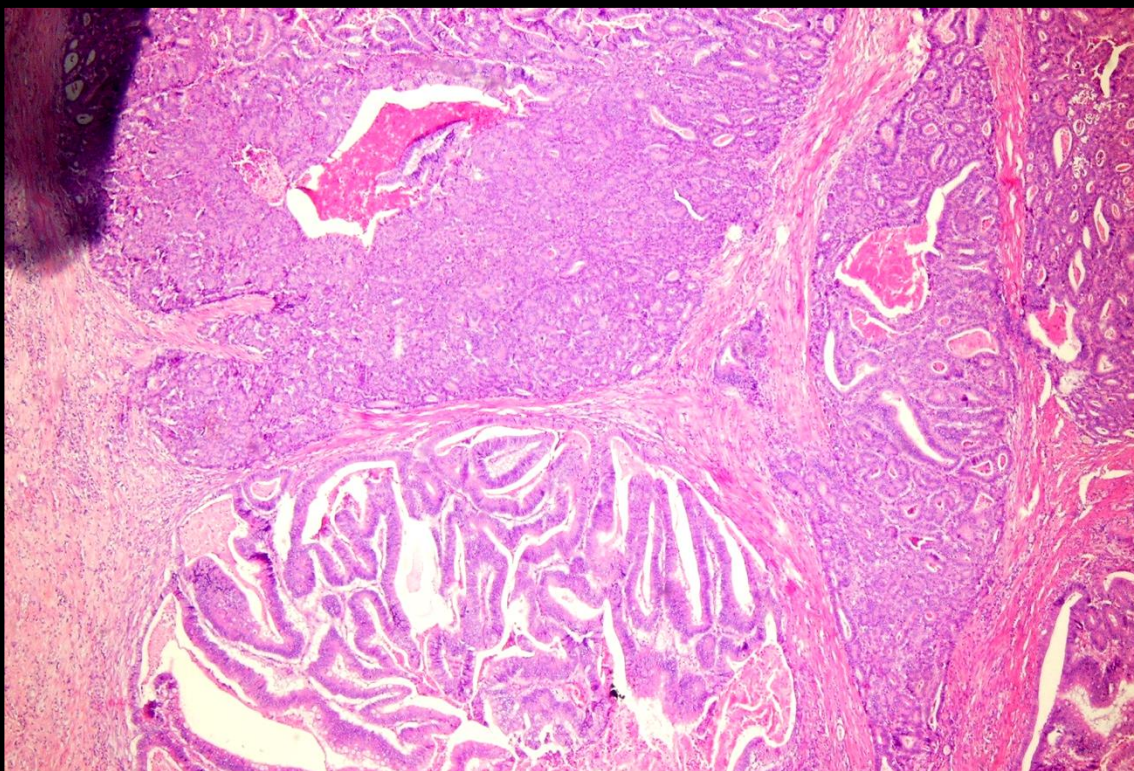
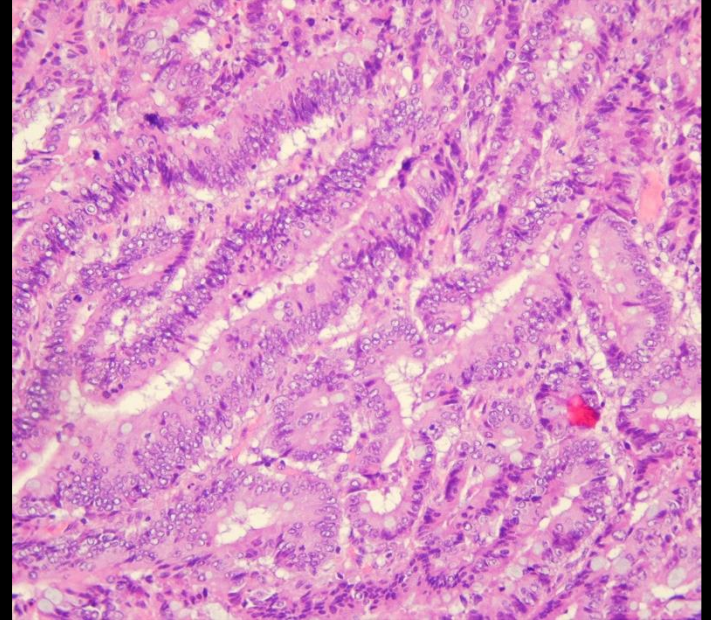
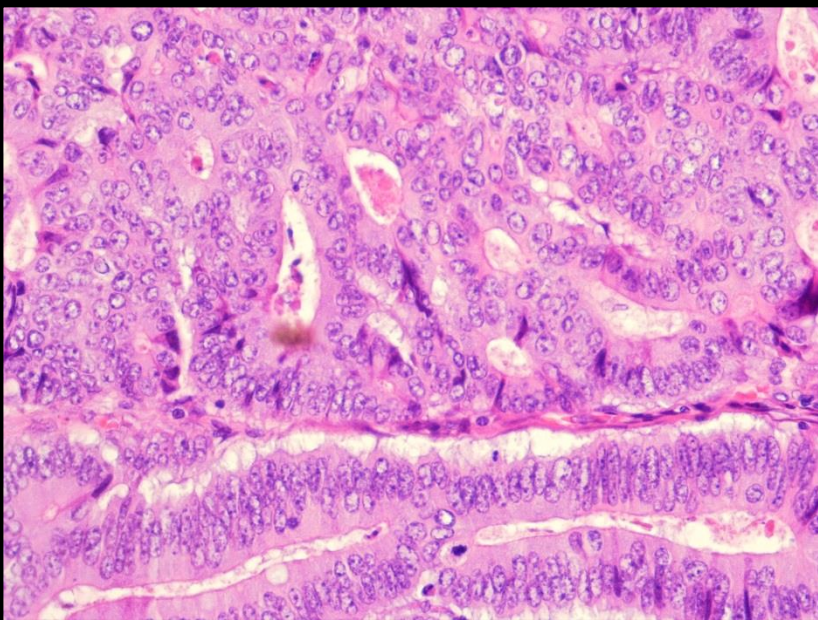


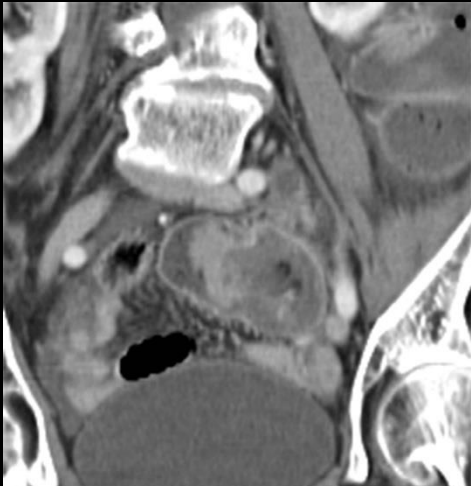
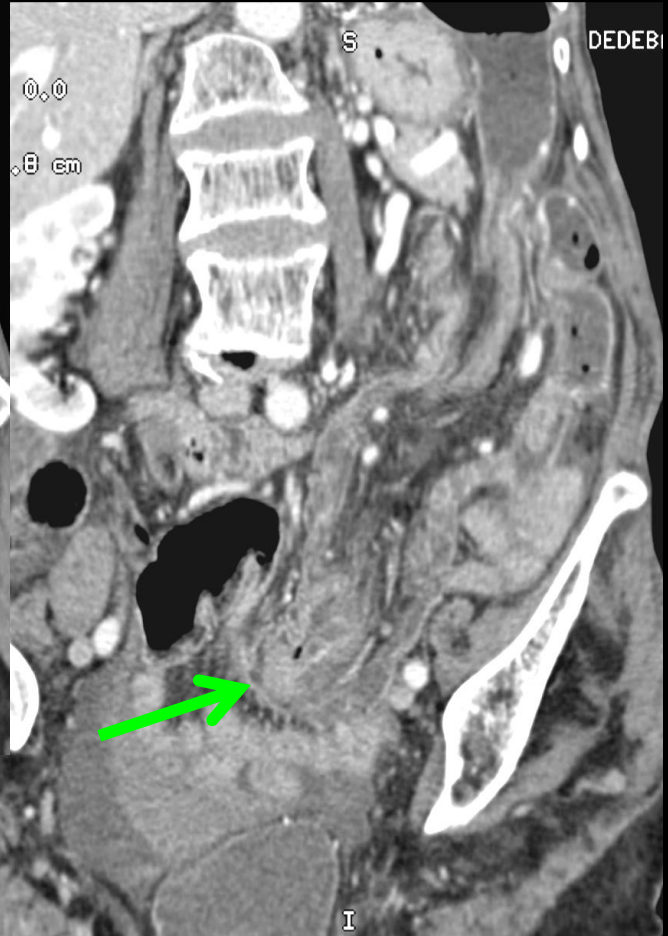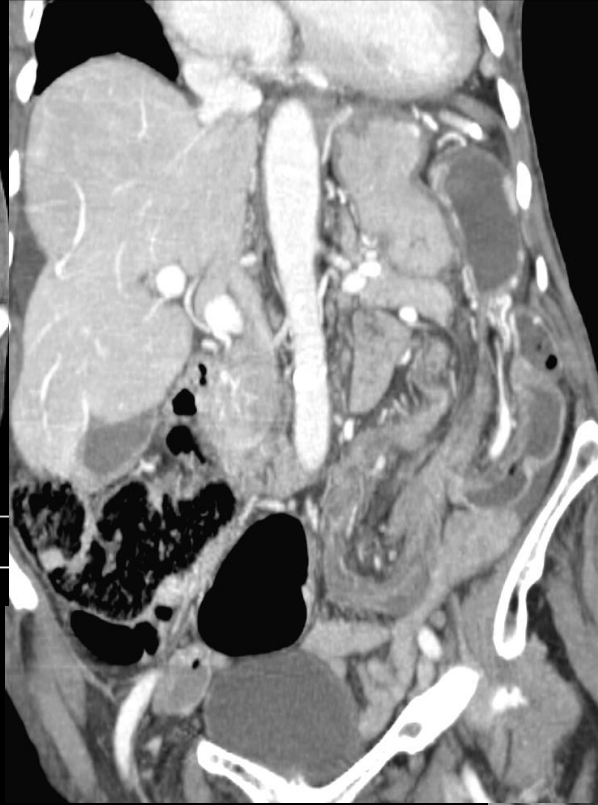

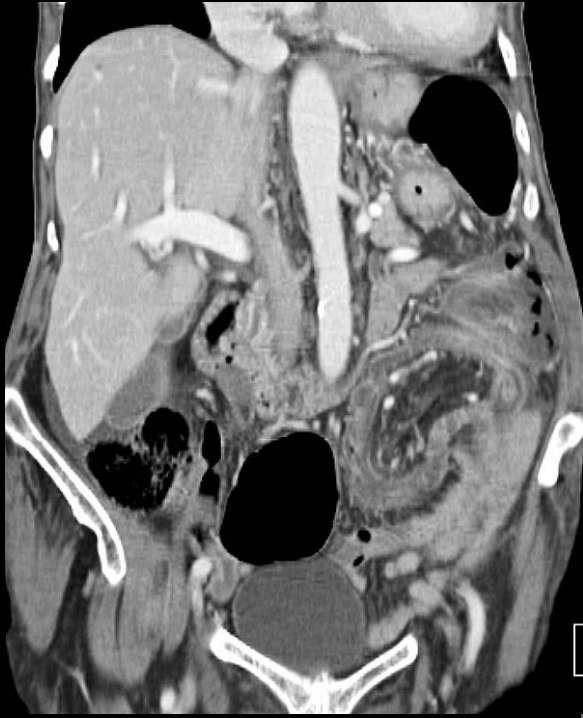




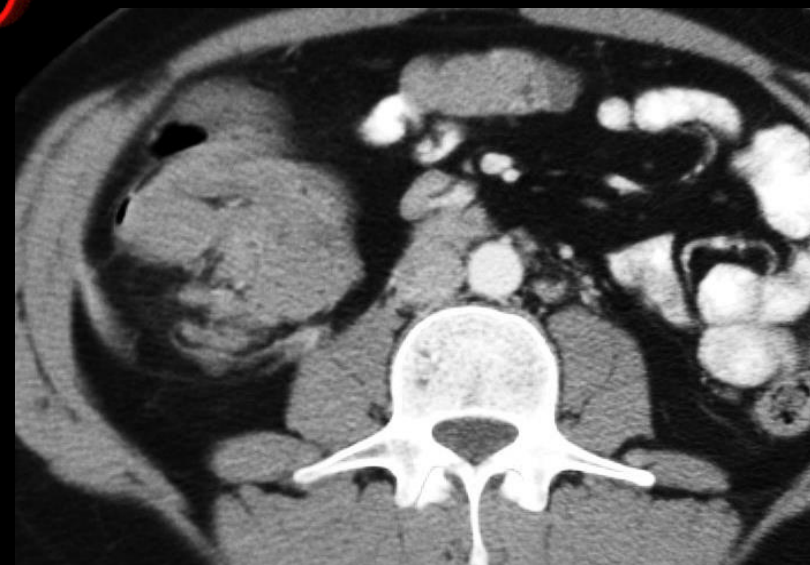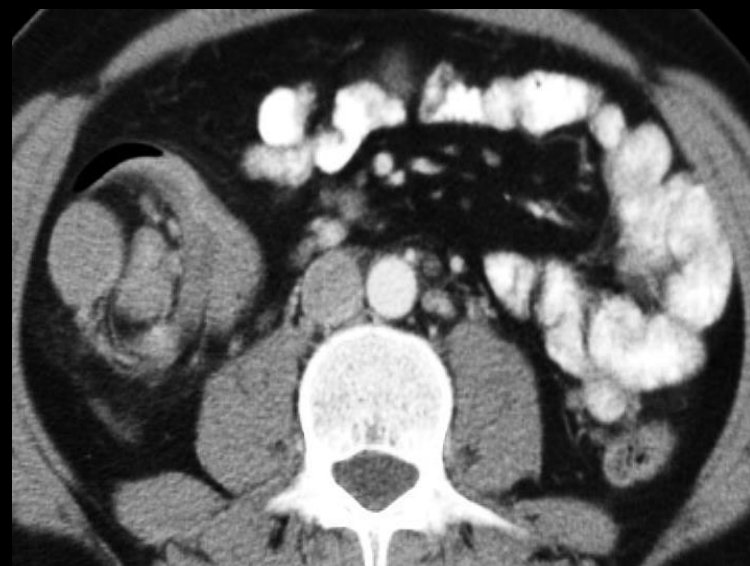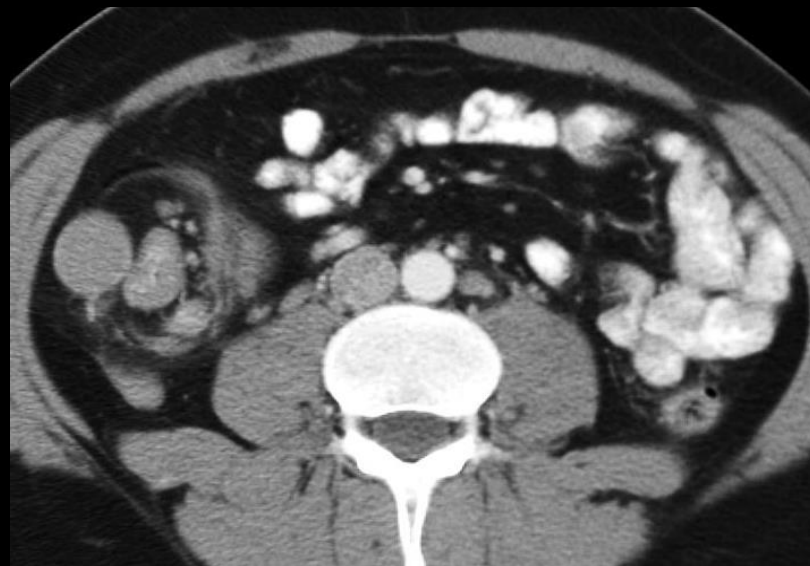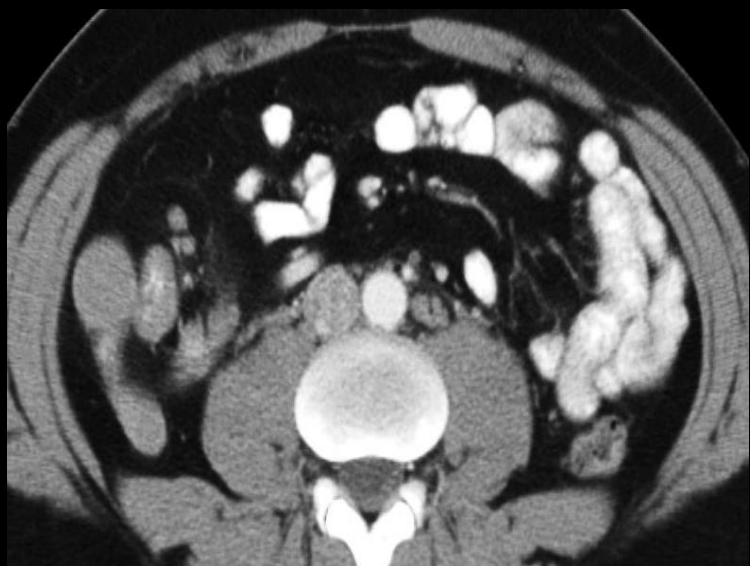sur la pièce une volumineuse lésion
circonférentielle sténosante
(adénocarcinome lieberkuhnien bien
différencié
et un polype adénomateux tubulo-
vilieux avec dysplasie sévère et
cancer in-situ

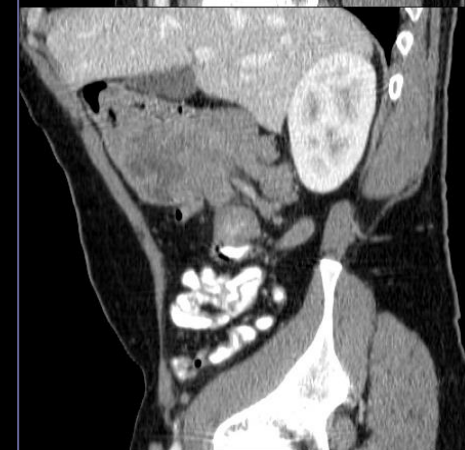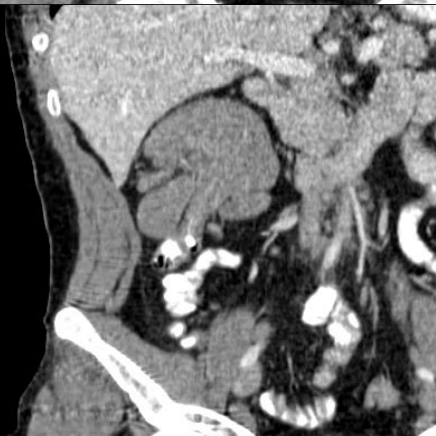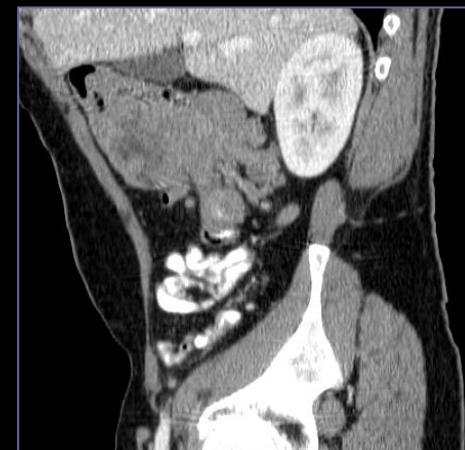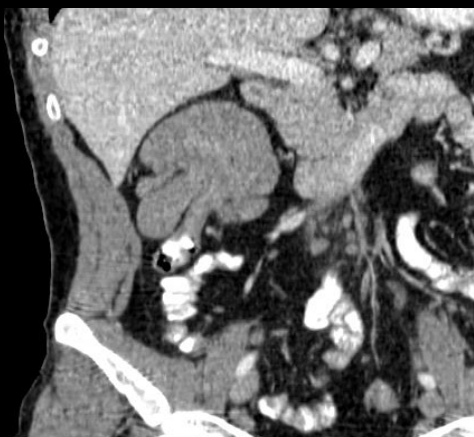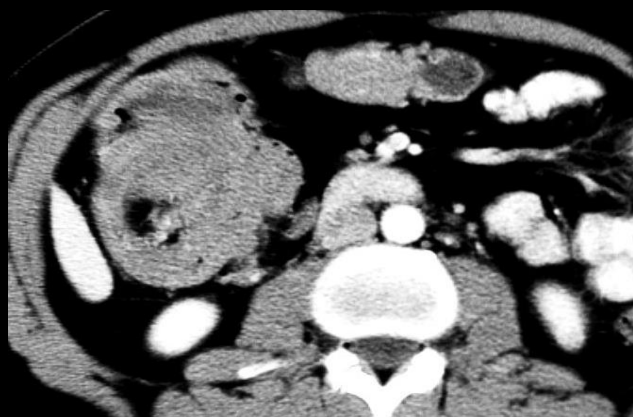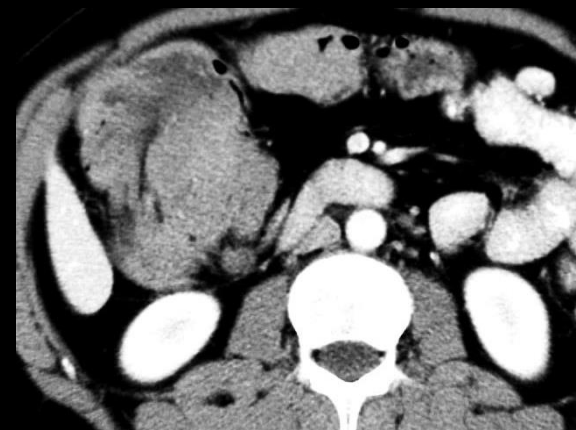
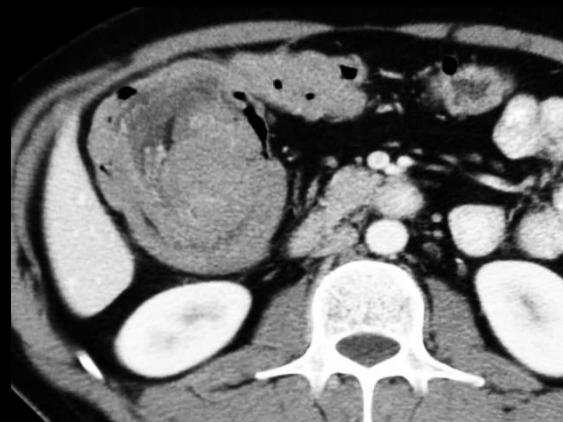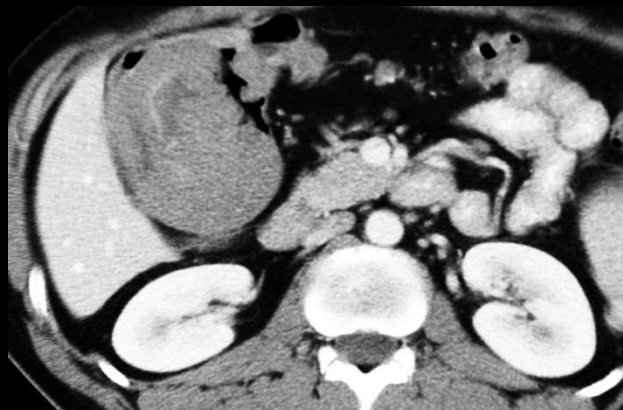




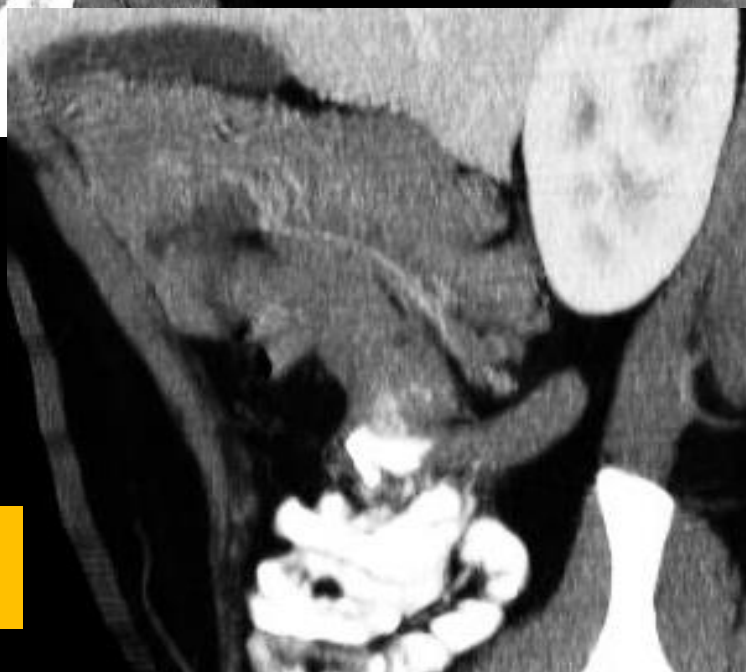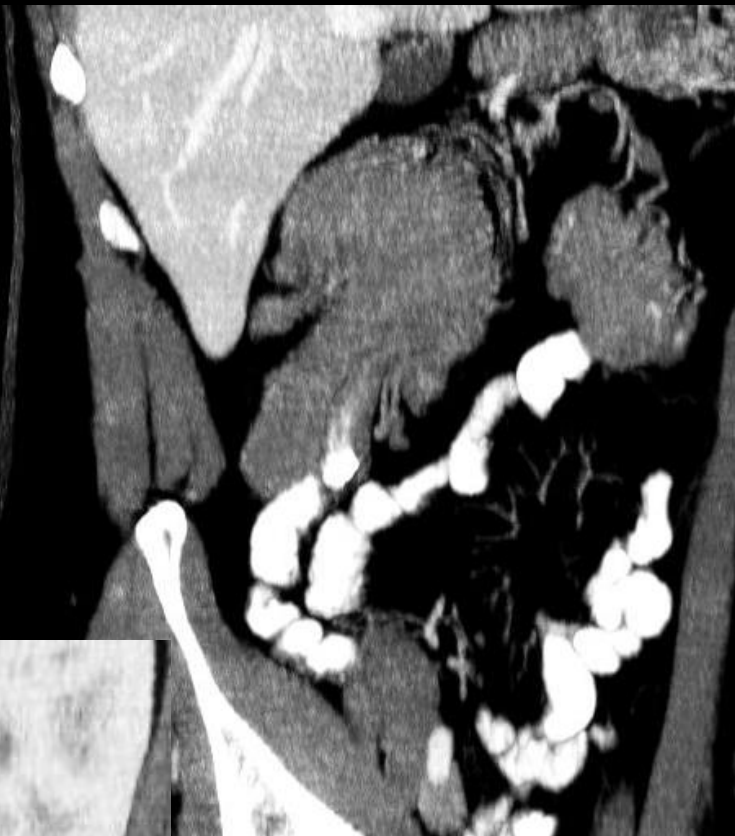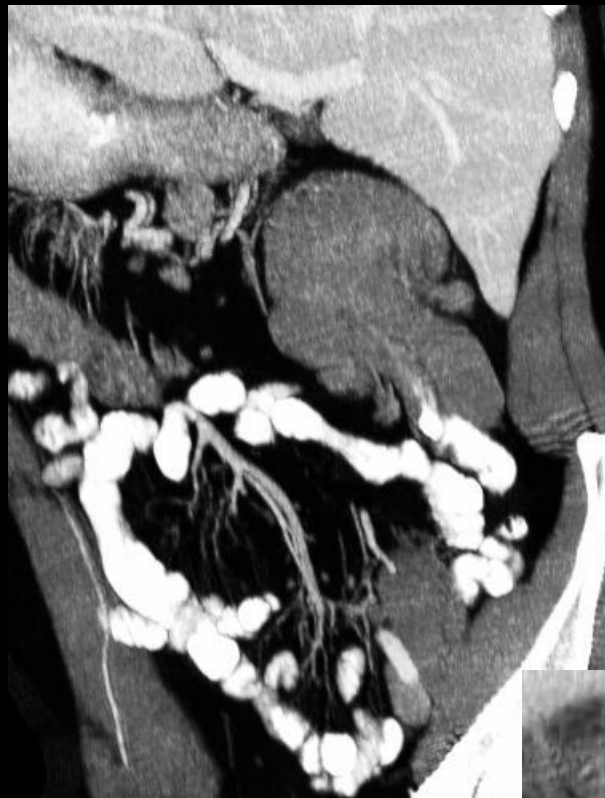invagination colo-colique sur adénocarcinome sténosant



homme 41 ans; rectorragies,
masse du flanc droit

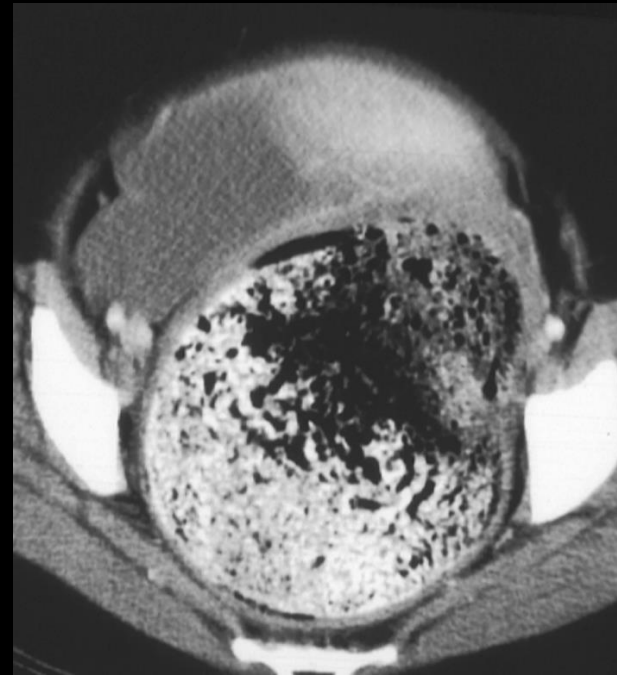
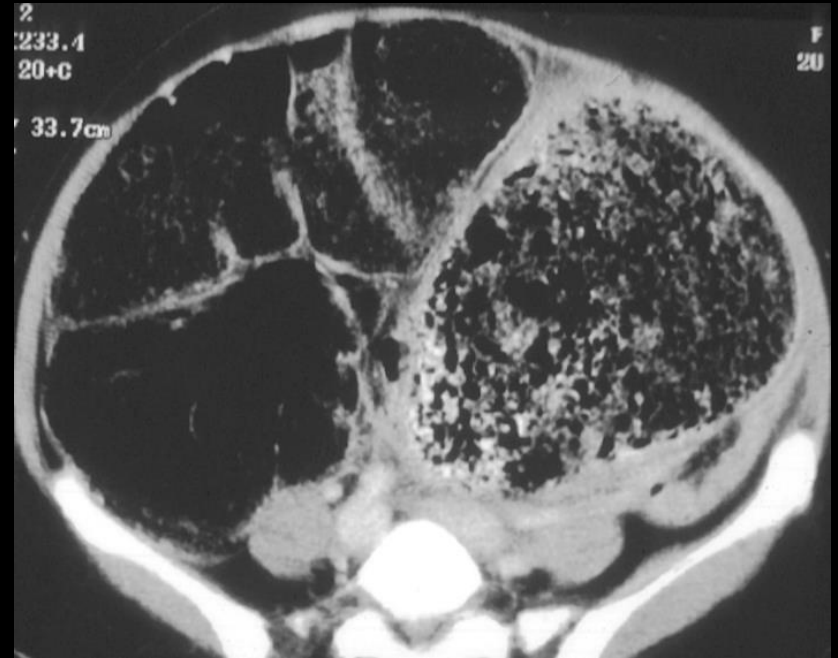
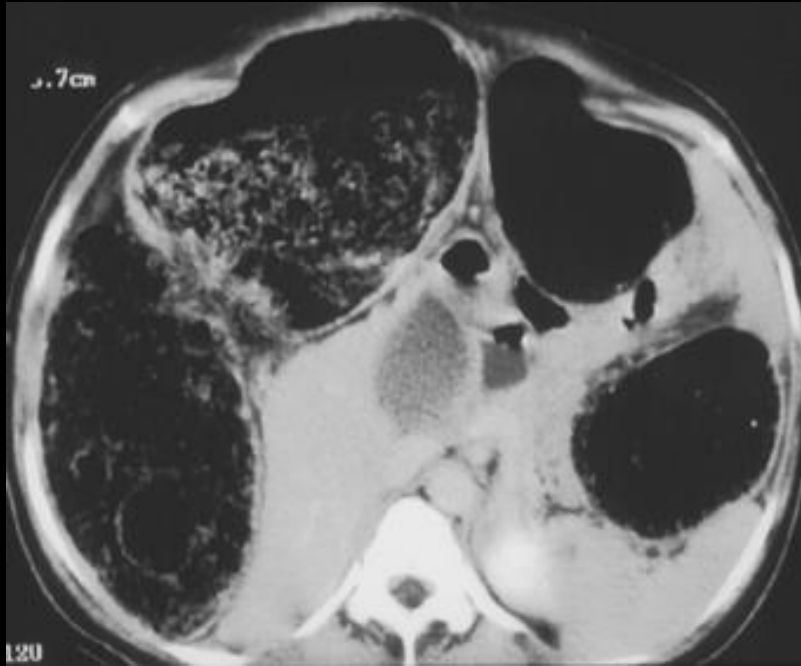


**invagination iléo-colique sur
LMNH du manteau du
carrefour iléo-caecal**

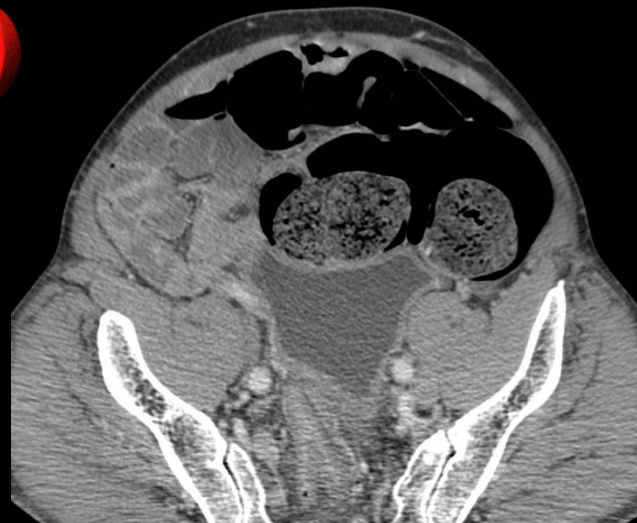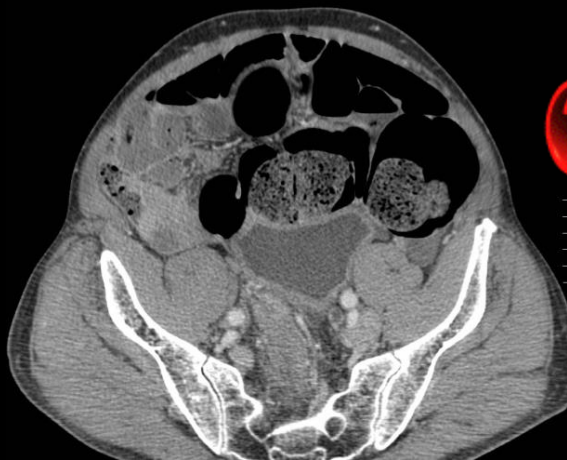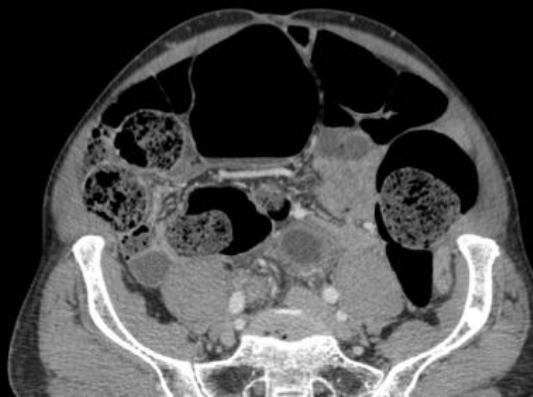


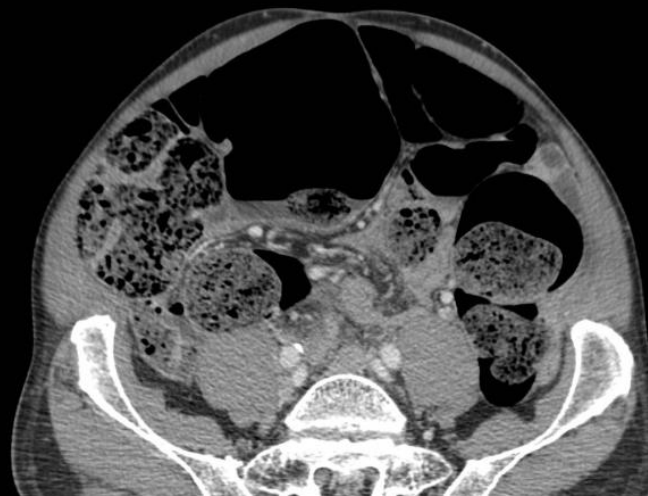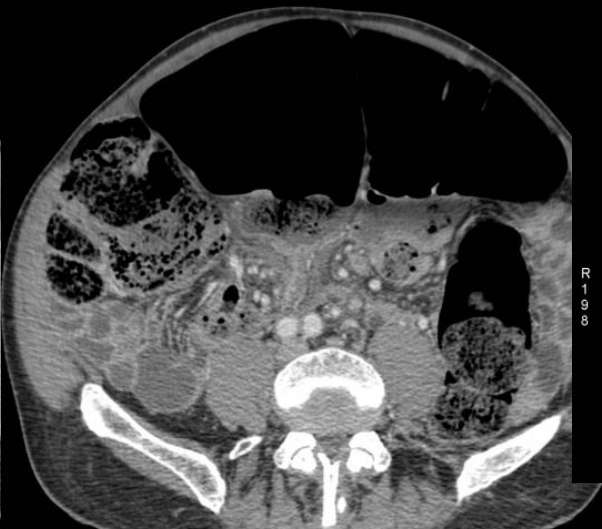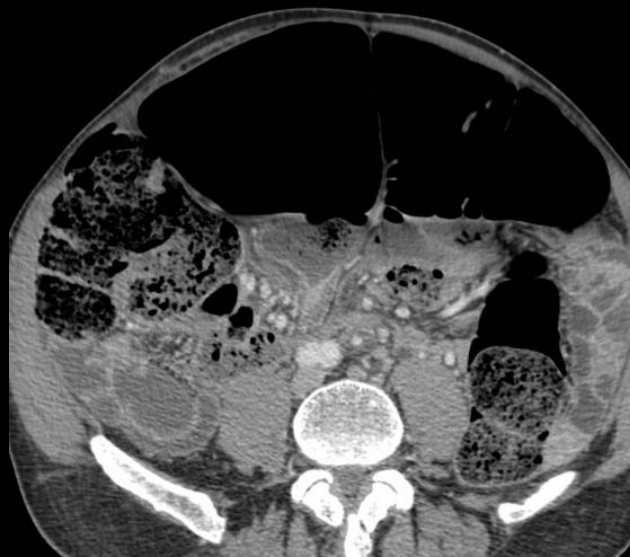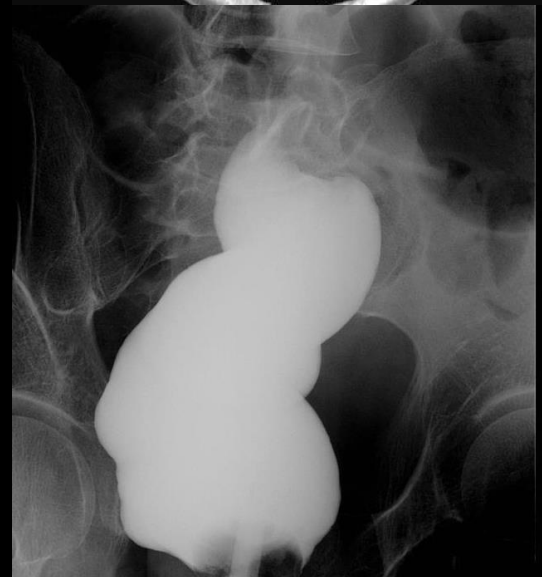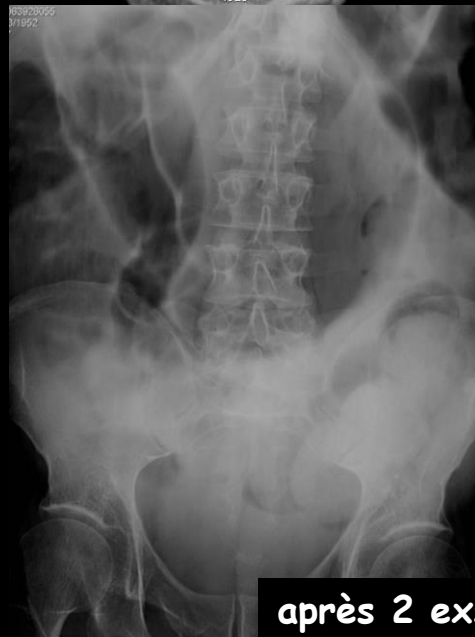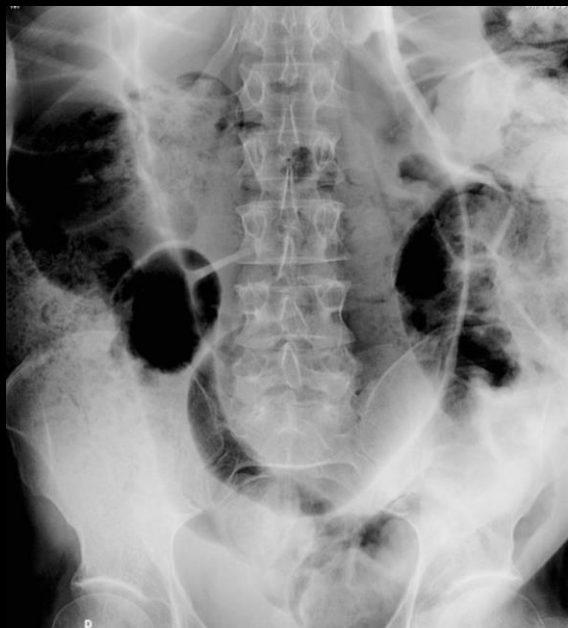
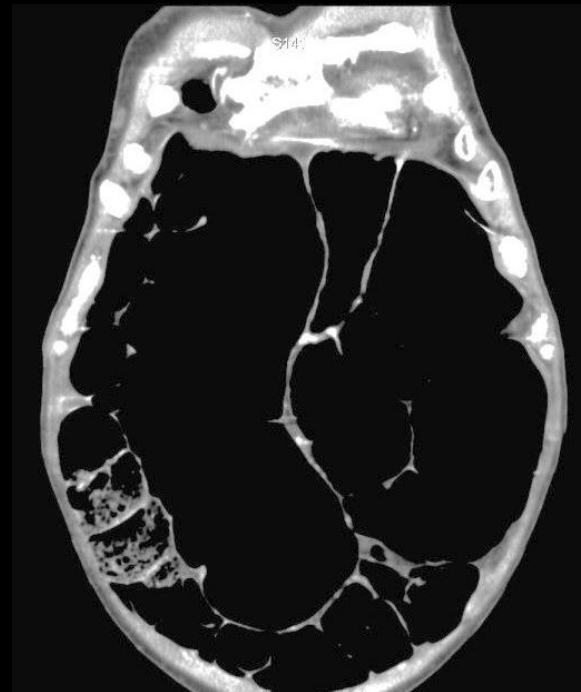
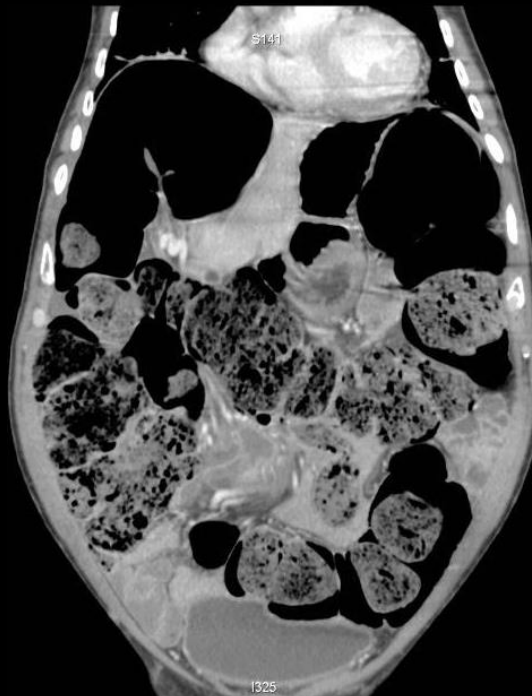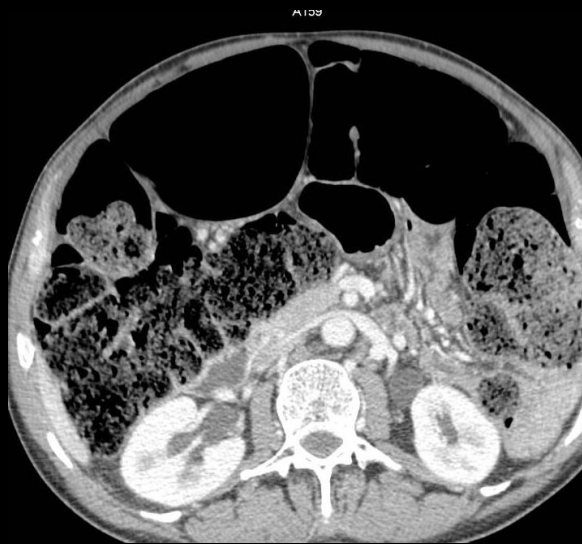invagination iléo-colique
sur LMNH du manteau

3-1-1 occlusions colo-rectales fonctionnelles

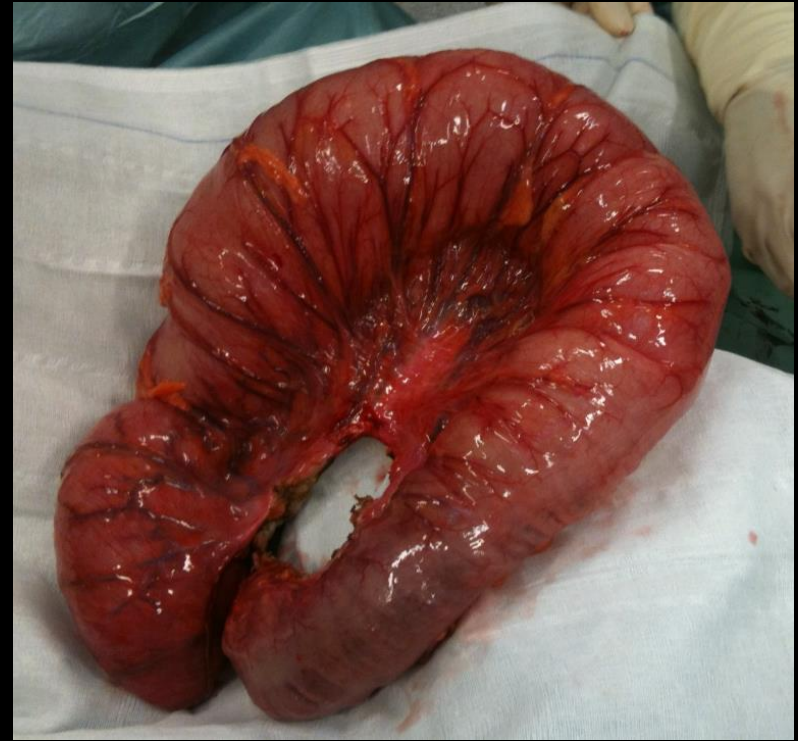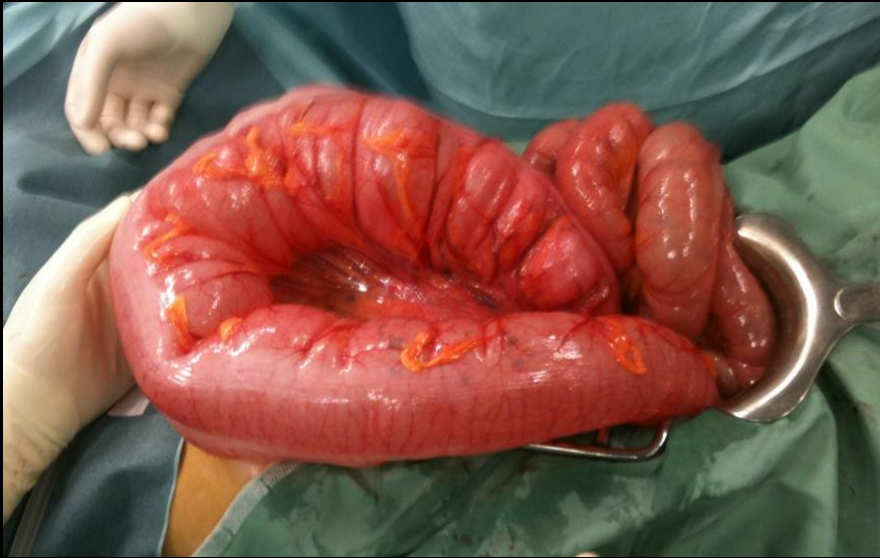


dolichocôlon neuroleptiques

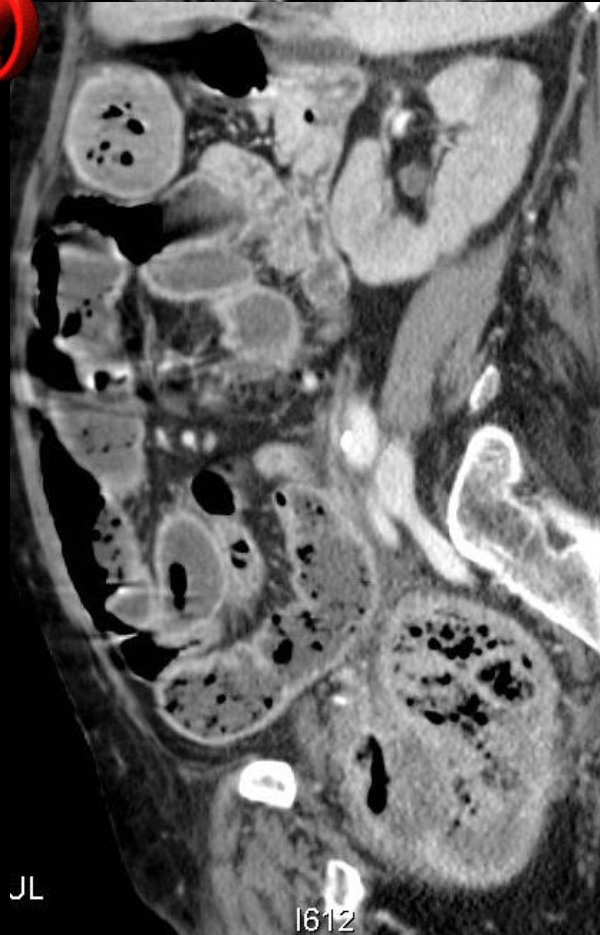
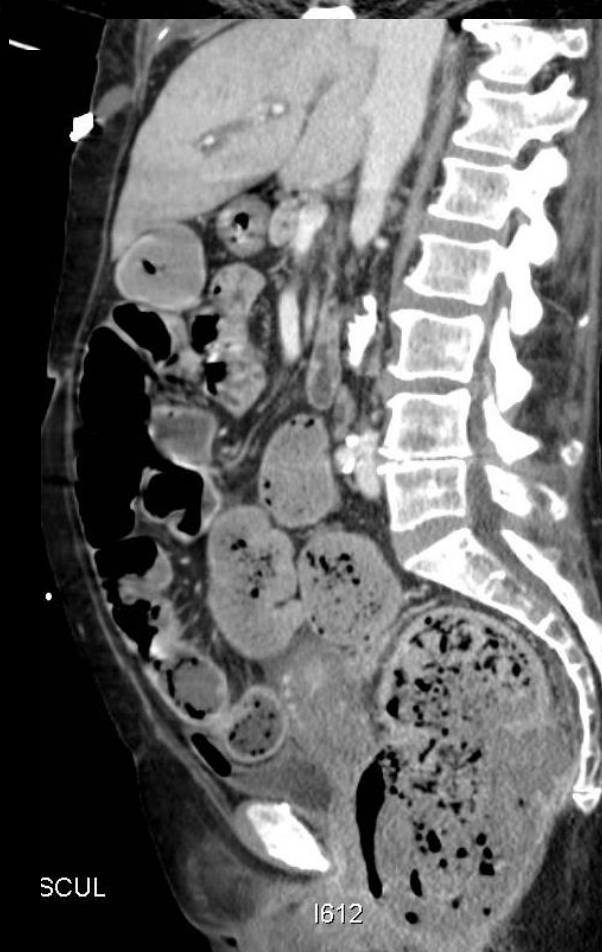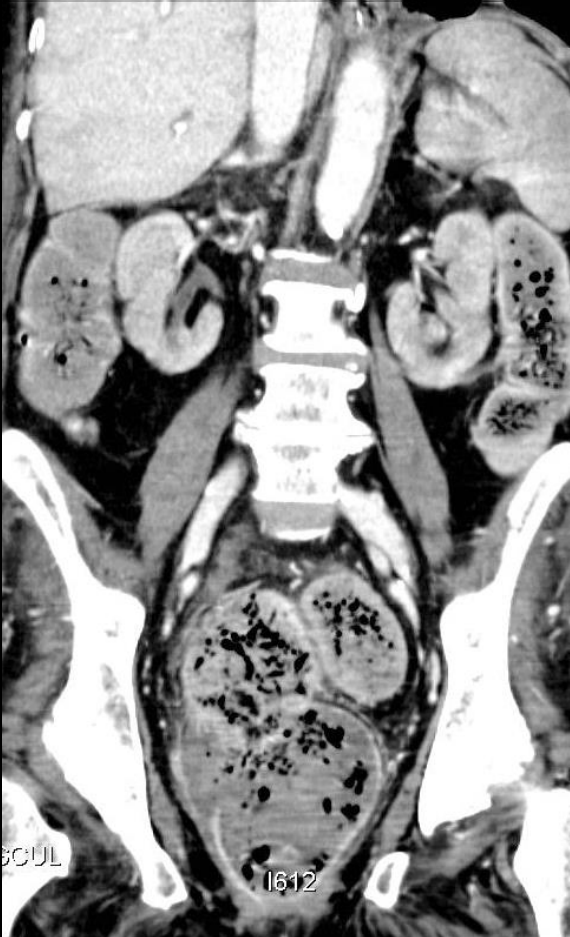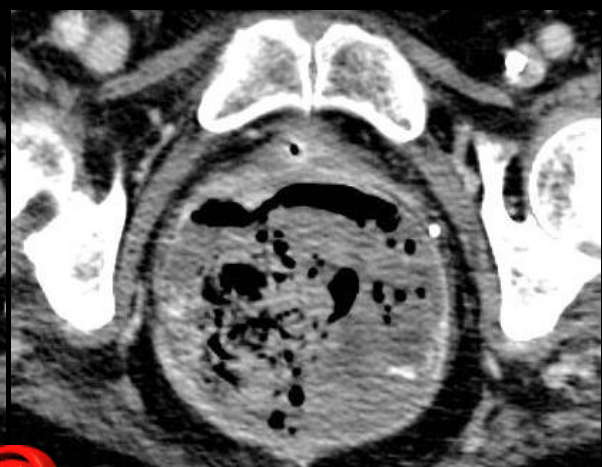
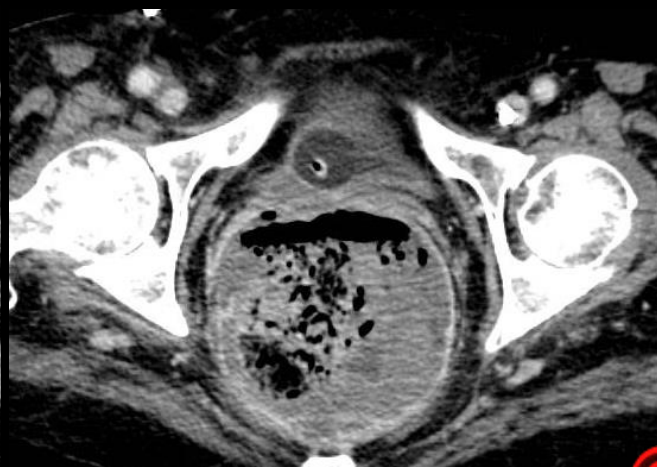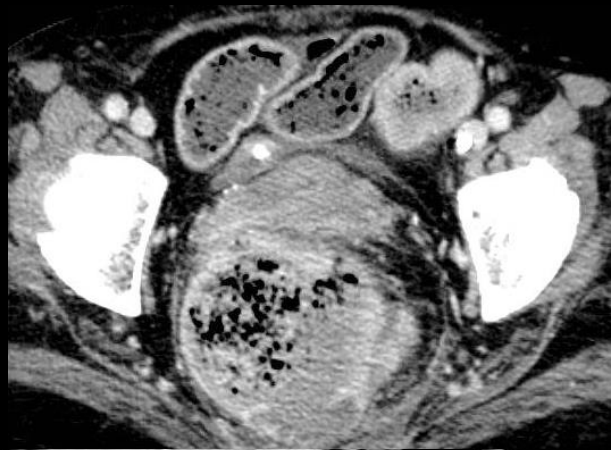


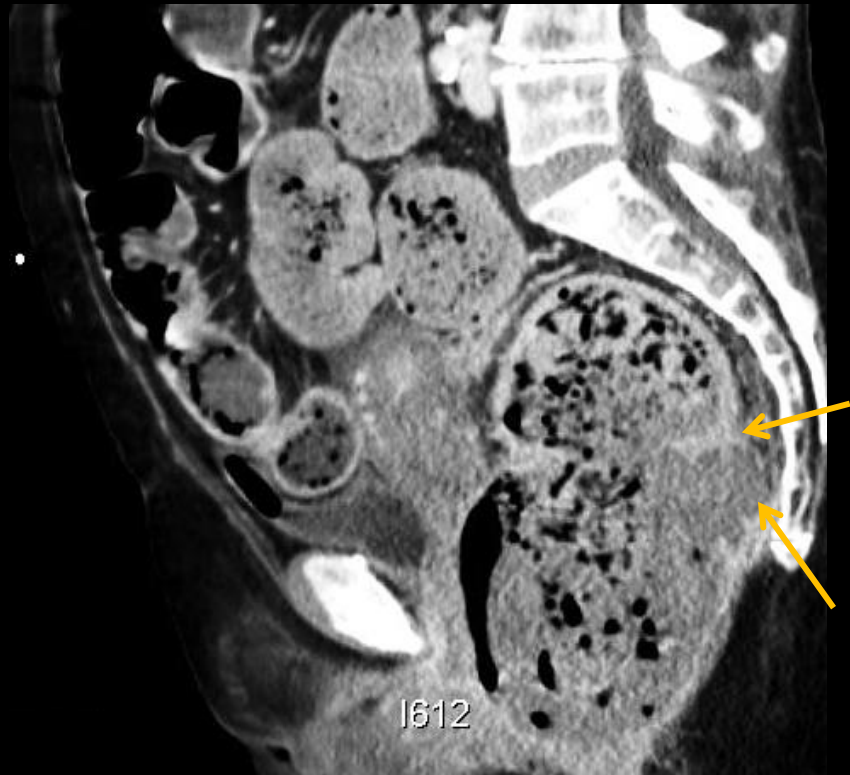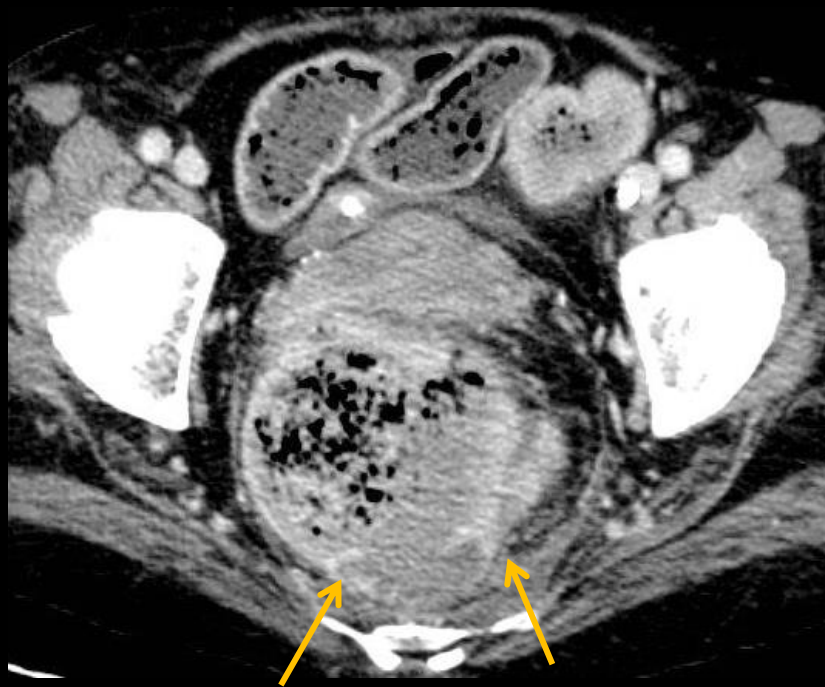


après 2 exsufflations ; patient psychotique



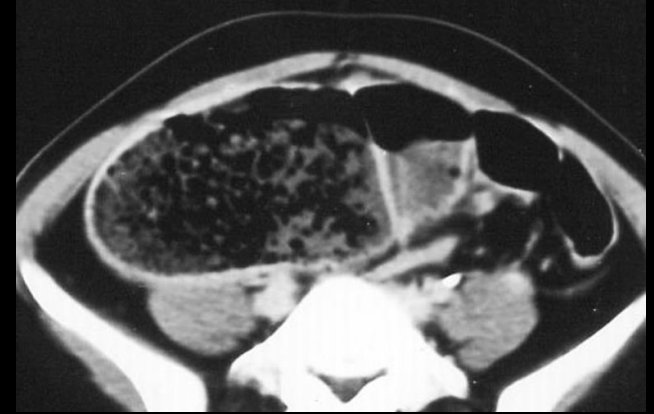
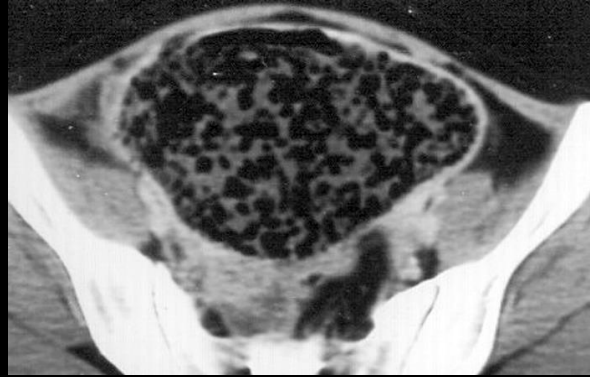
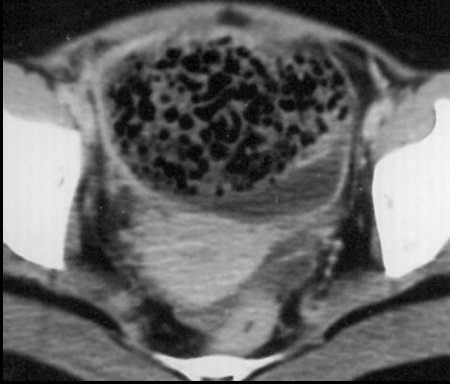
volvulus méésentérico-axial sur syndrome d'Ogilvie chez un psychotique institutionnalisé



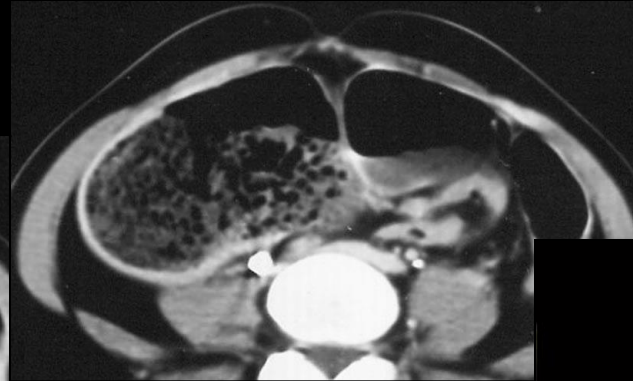
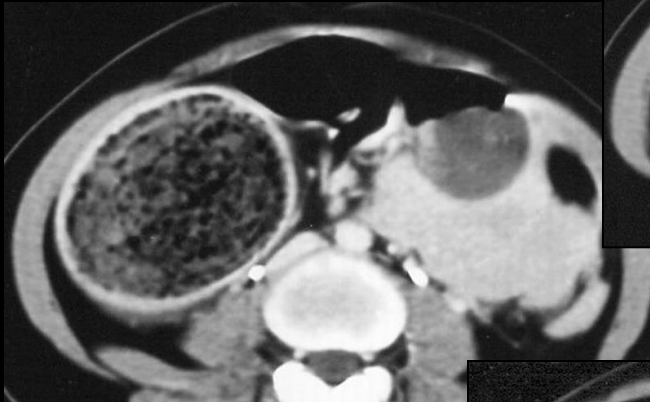

perforation rectale
postérieure sur impaction
fécale (fécalome)

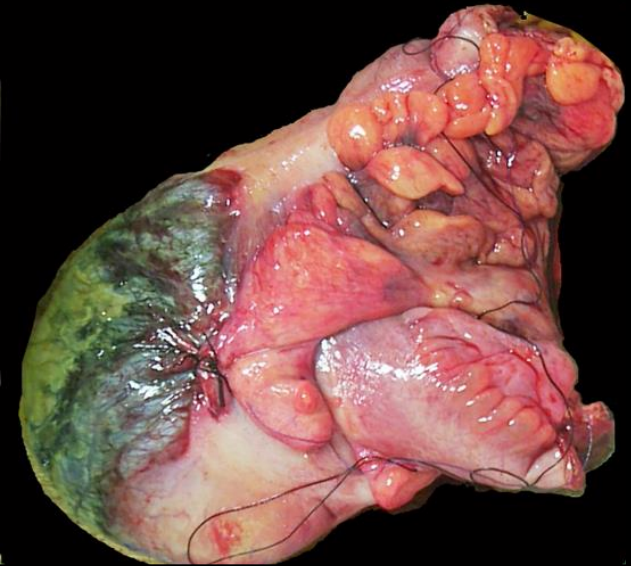
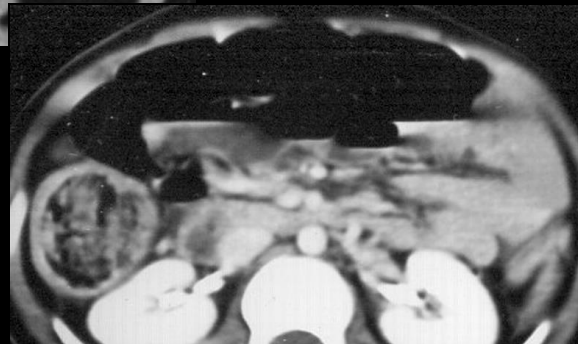jeune vietnamienne 19 ans ; sd douloureux de la FID

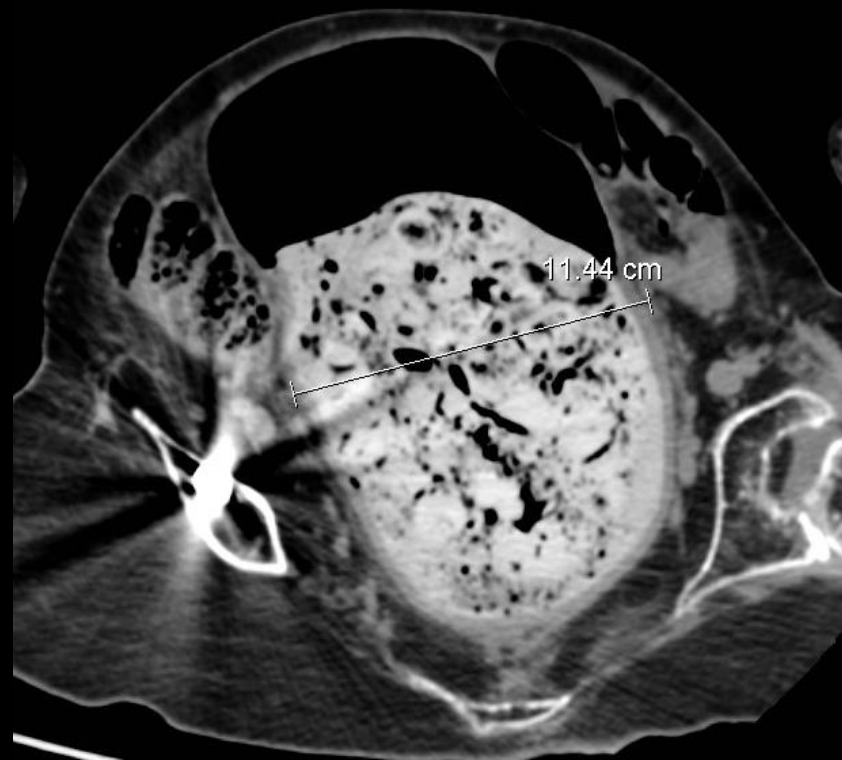
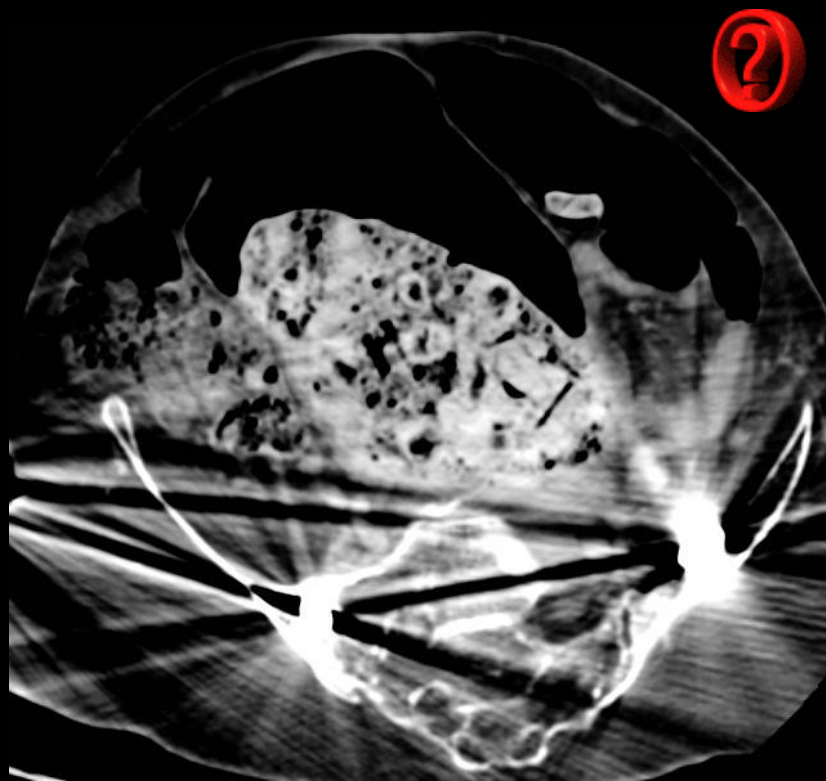
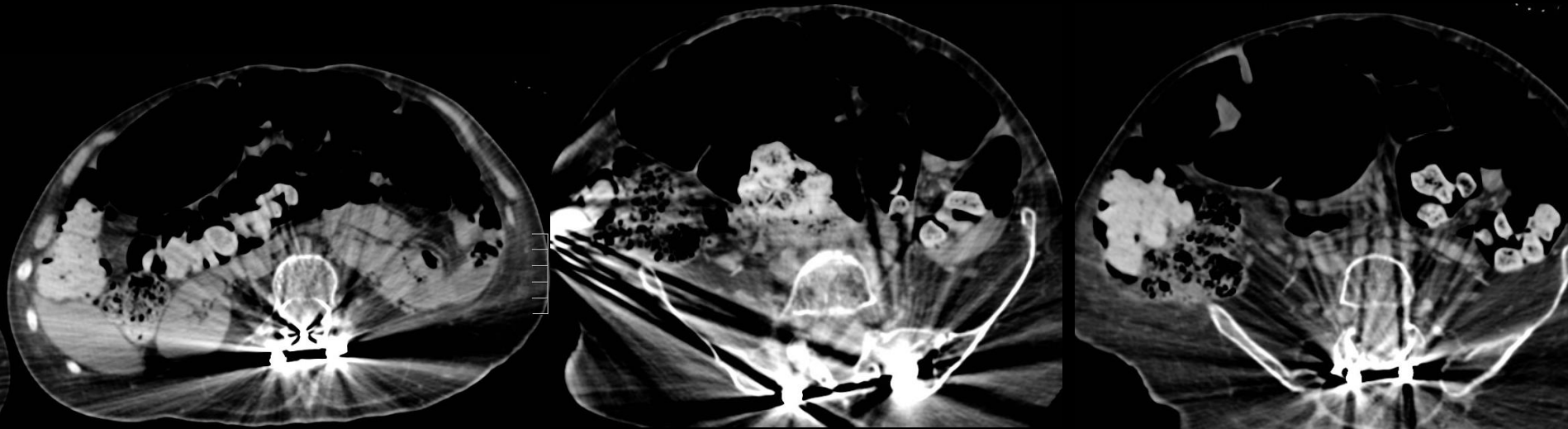


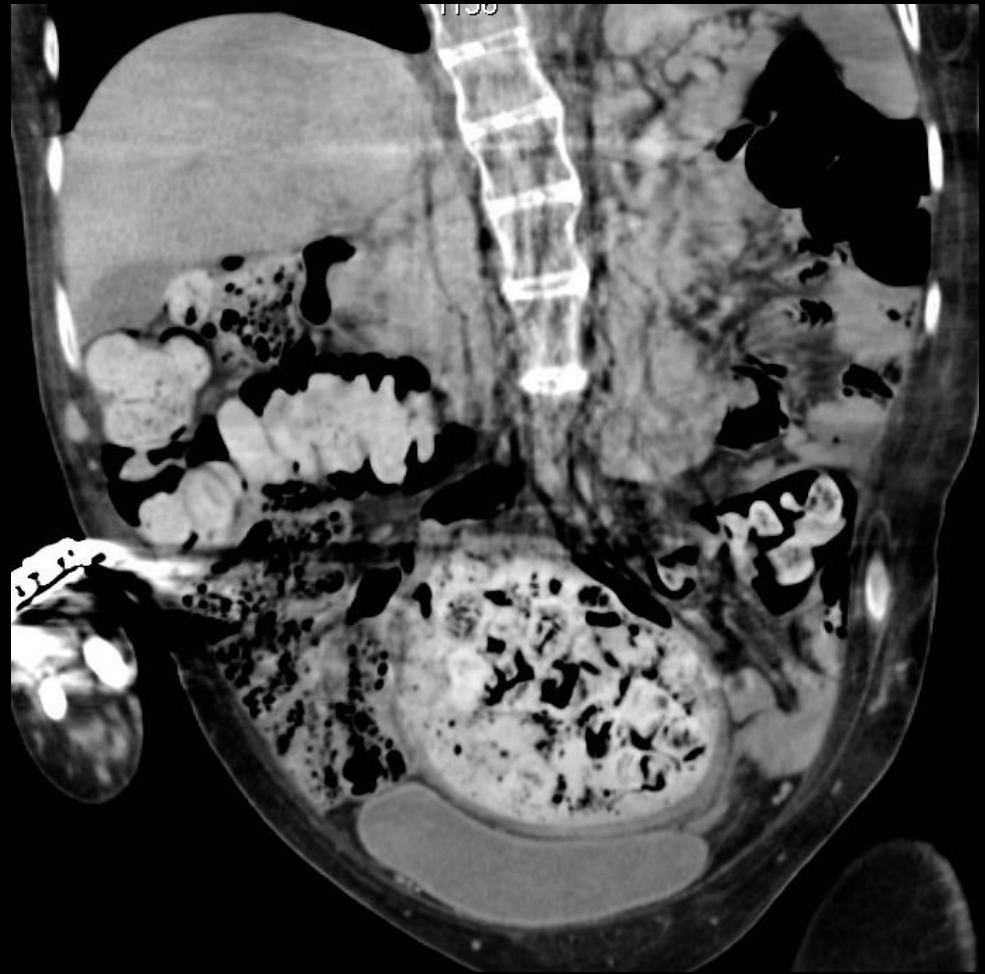
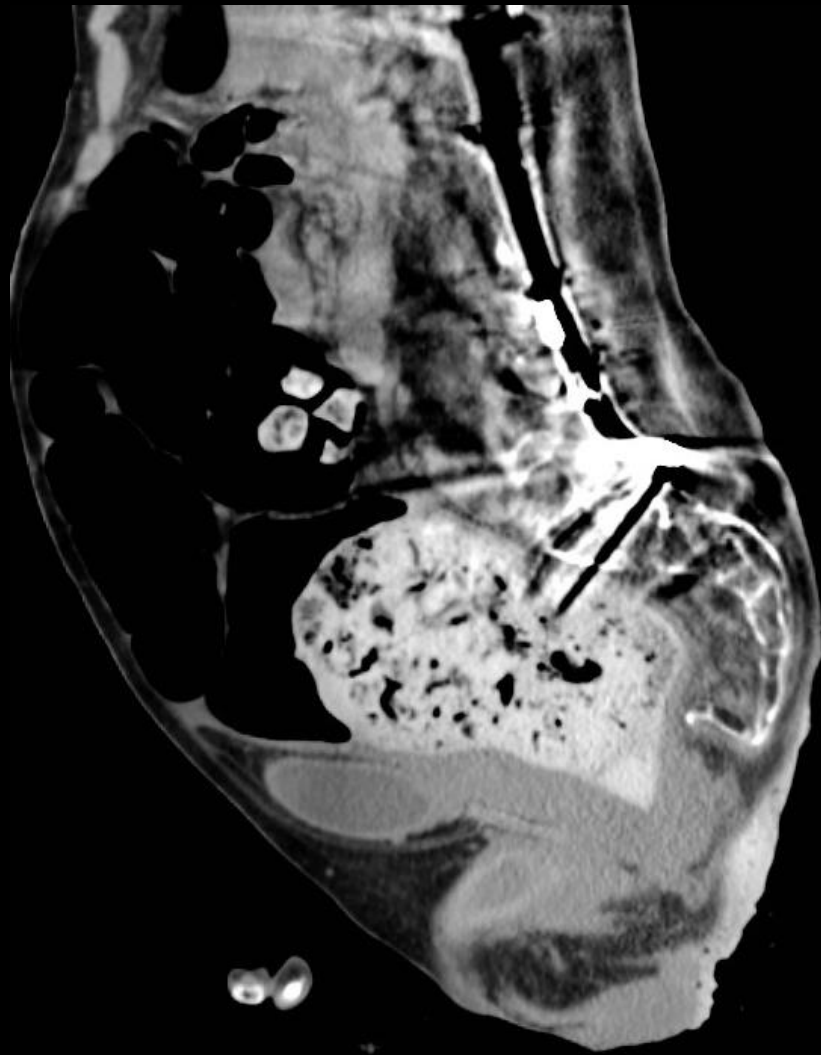
Obs. IN Phi Saigon

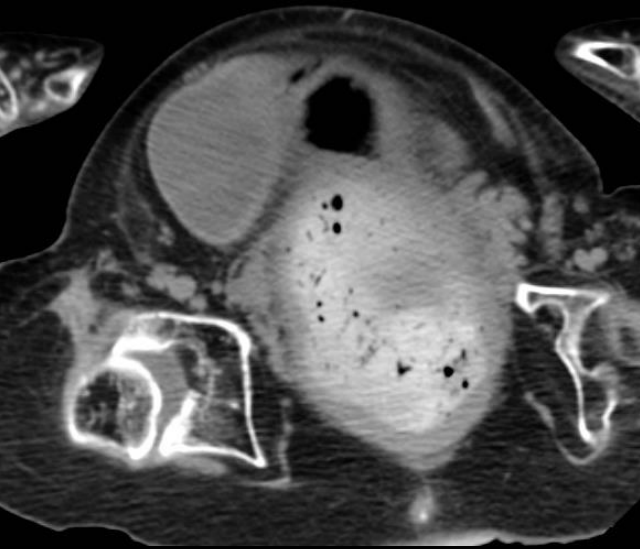


**nécrose colique
transmurale sur
impaction fécale**



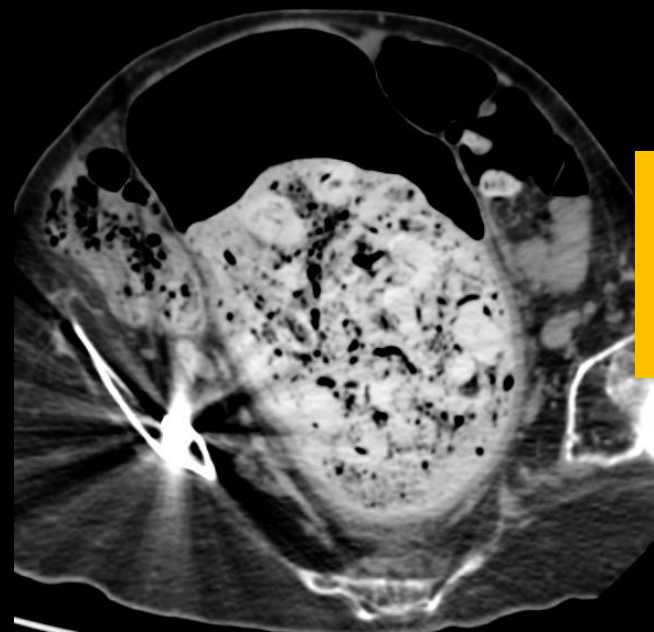
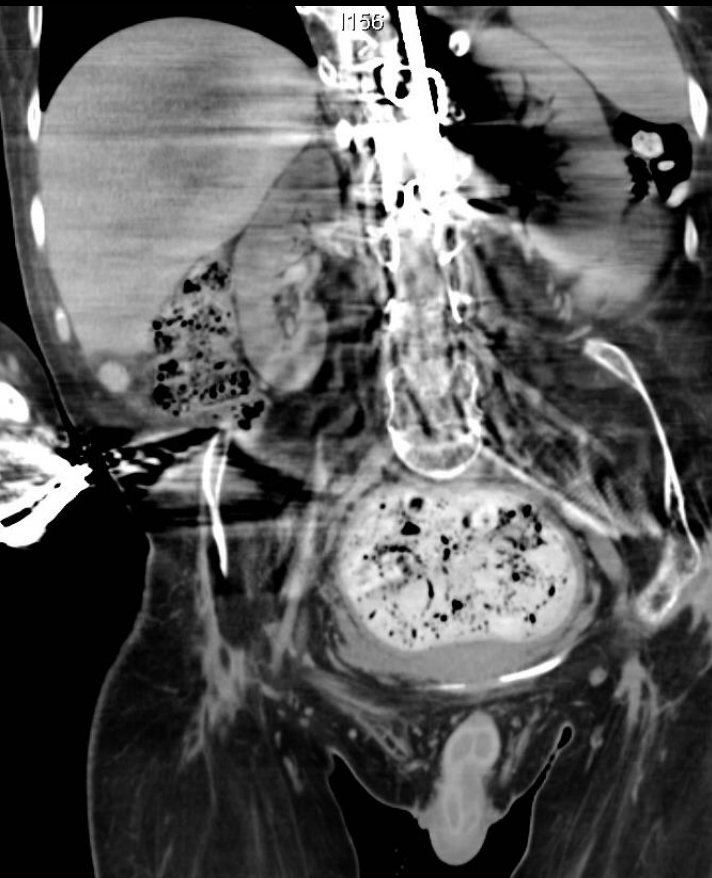
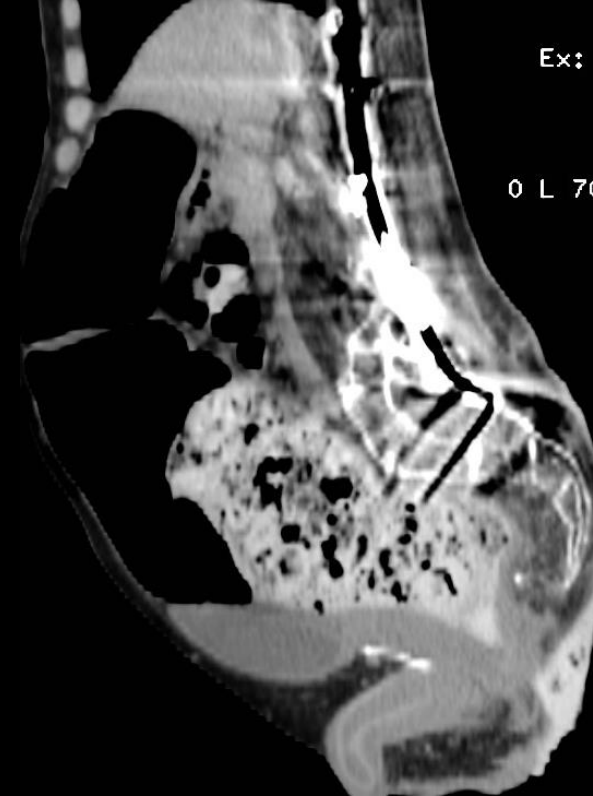
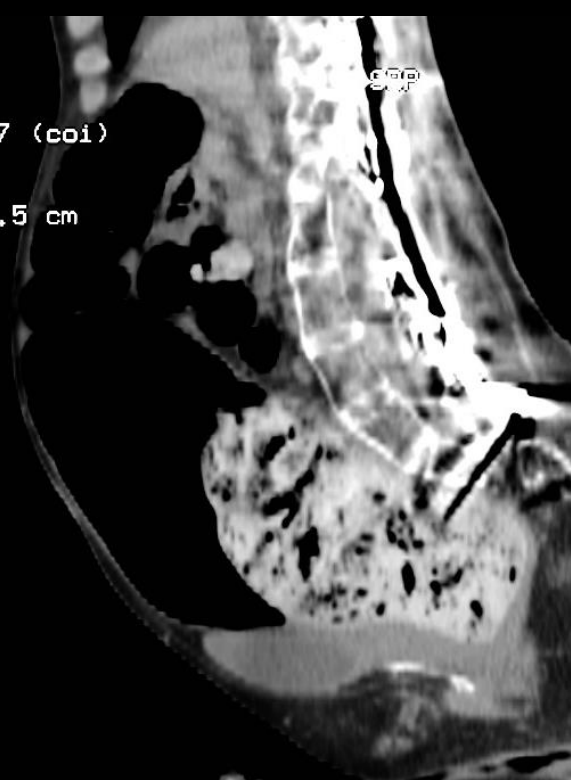





7 (coi)

.5 cm



myopathie de Duchenne
fécalome sur syndrome
d'Ogilvie