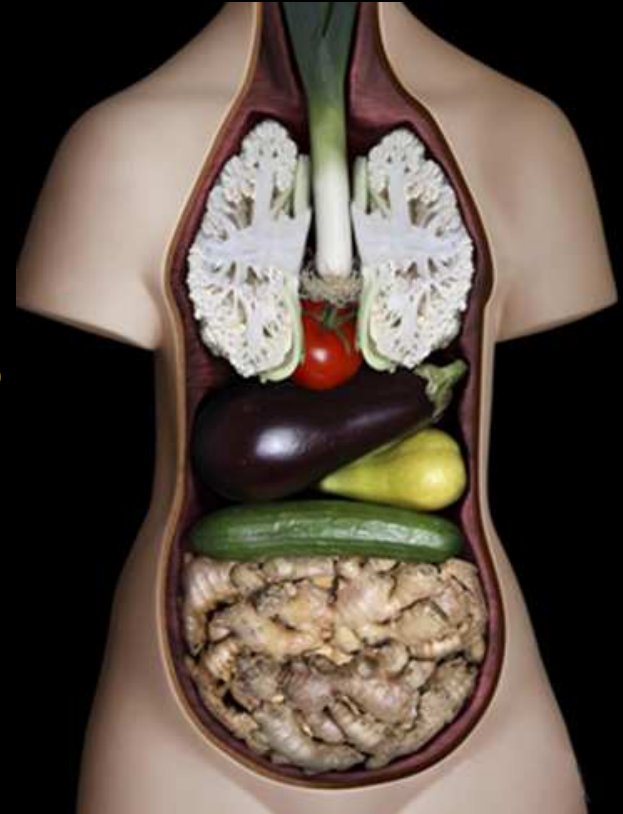
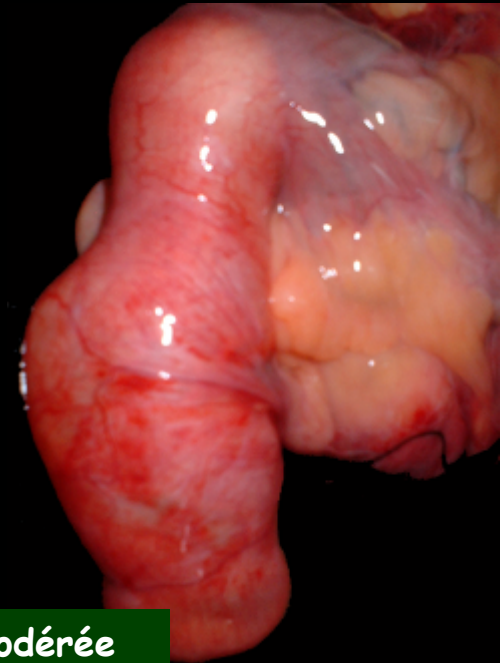
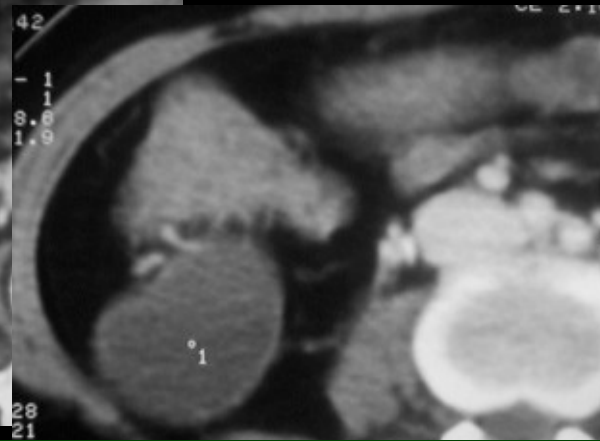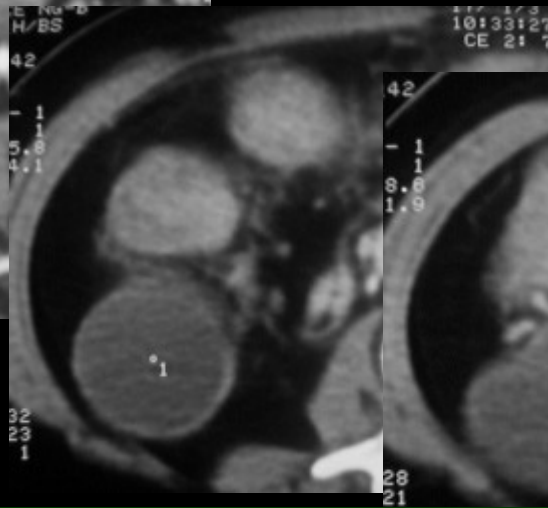
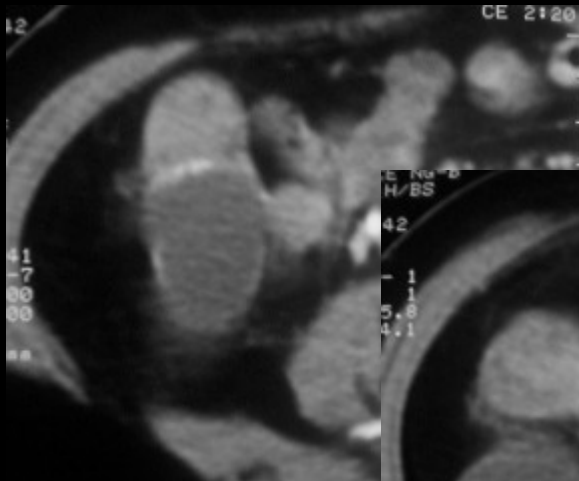
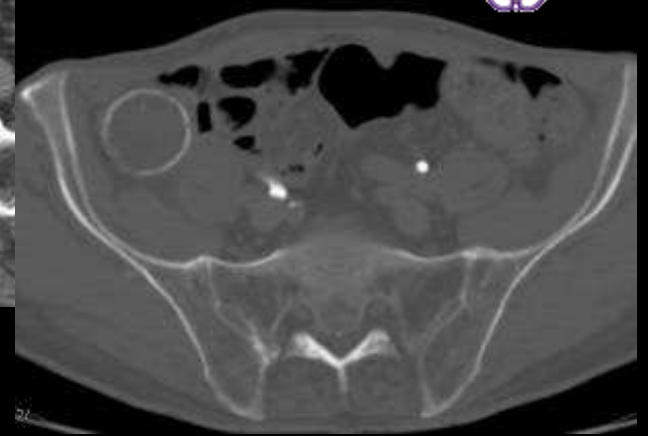
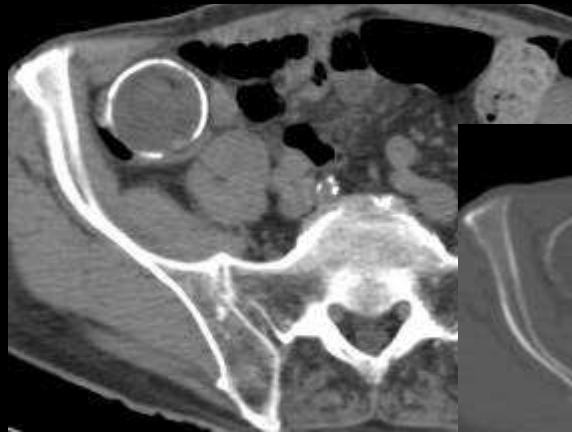
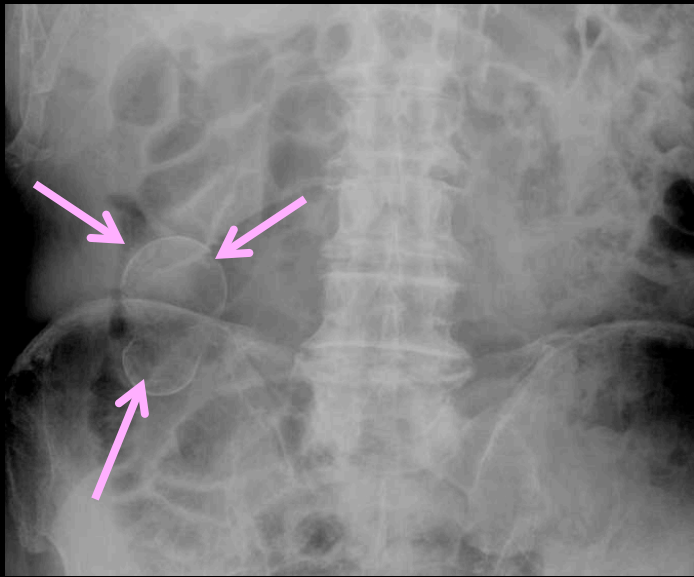


difficultés , pièges et images-clé dans la pathologie du péritoine

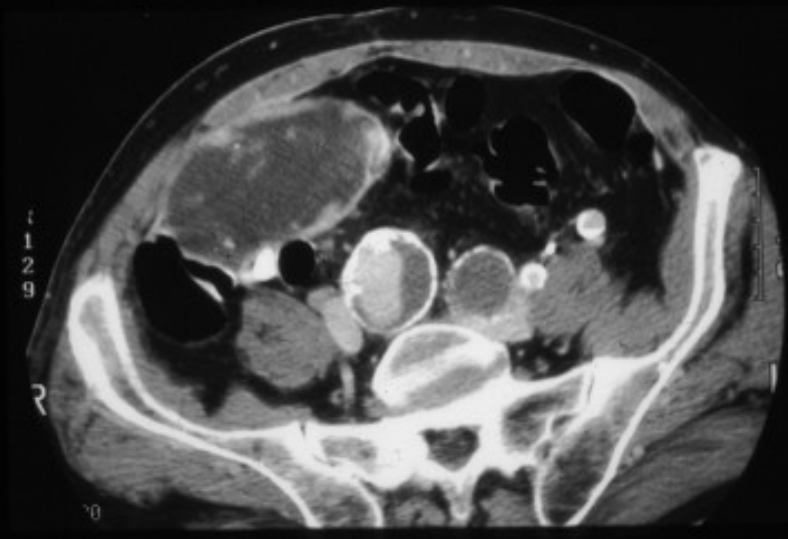
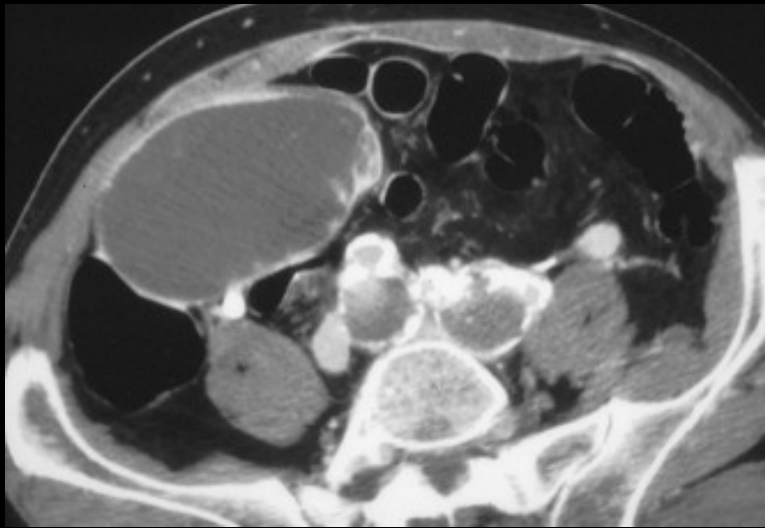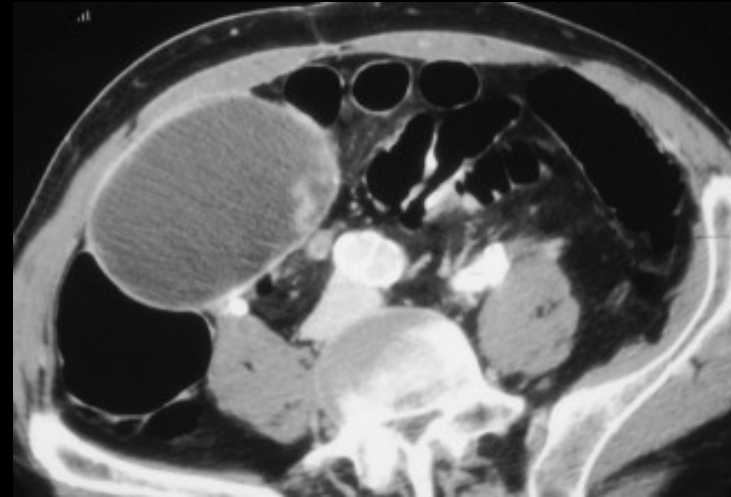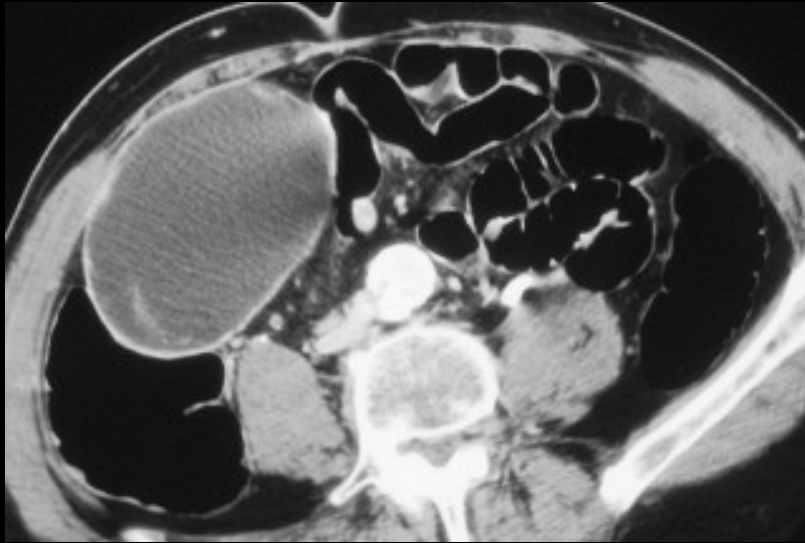
Le péritoine "acteur" de la pathologie (2)

- masses kystiques du péritoine
- tumeurs et pseudo tumeurs du péritoine



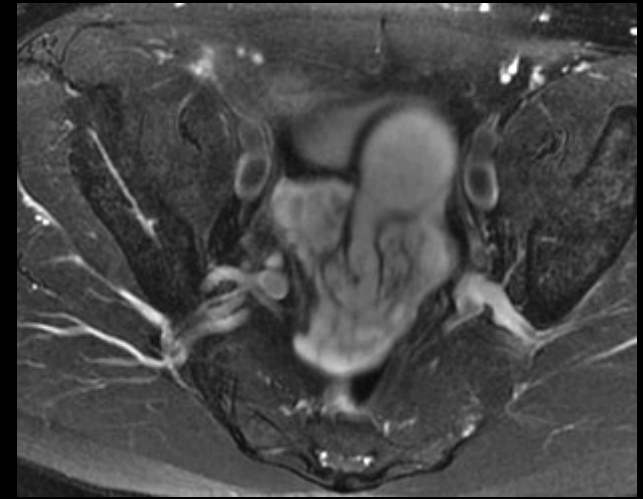
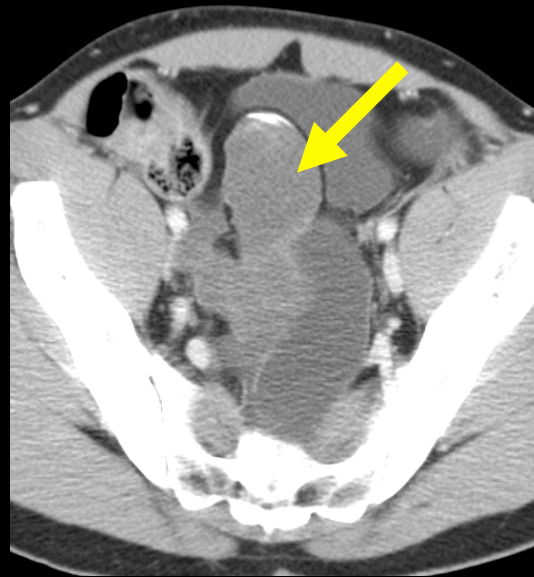
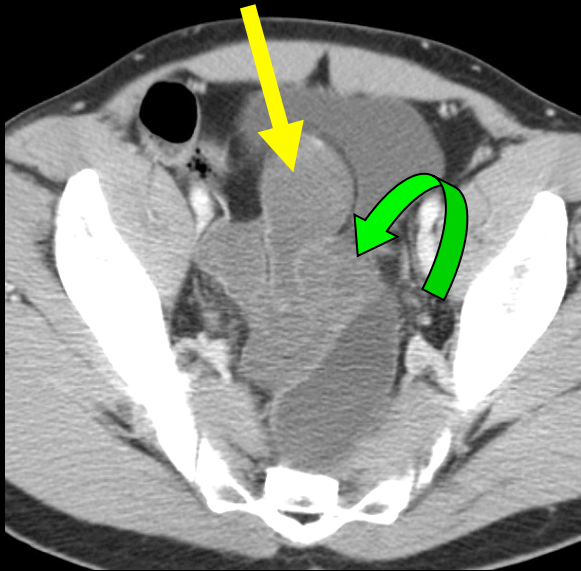
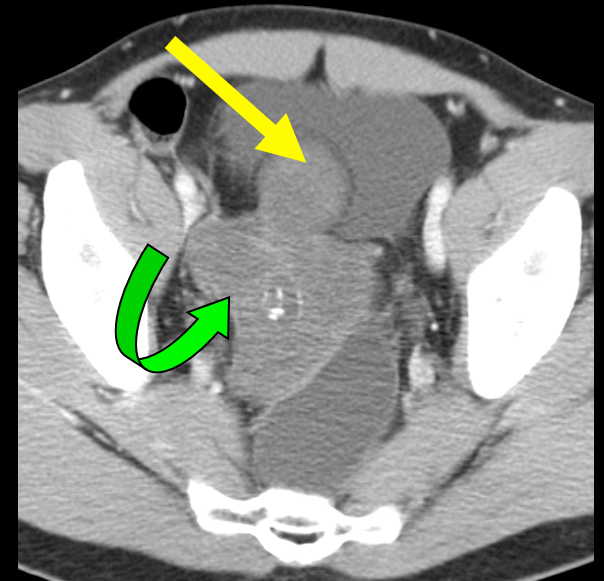
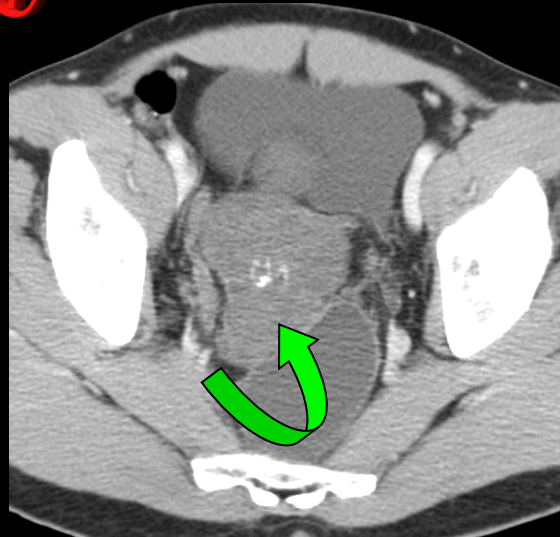
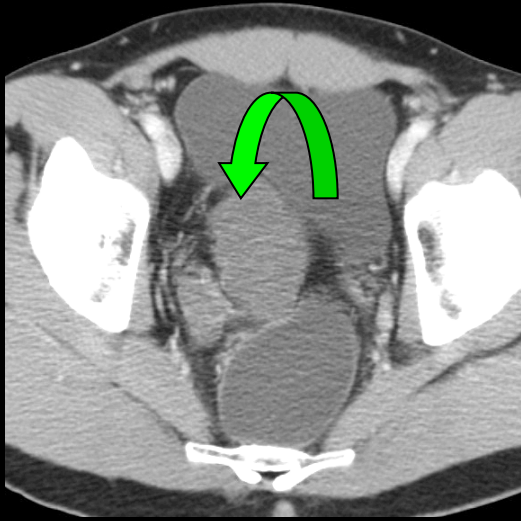
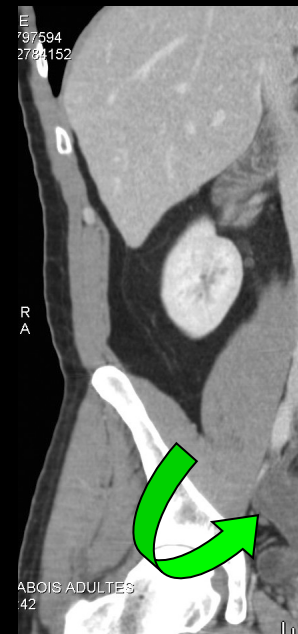
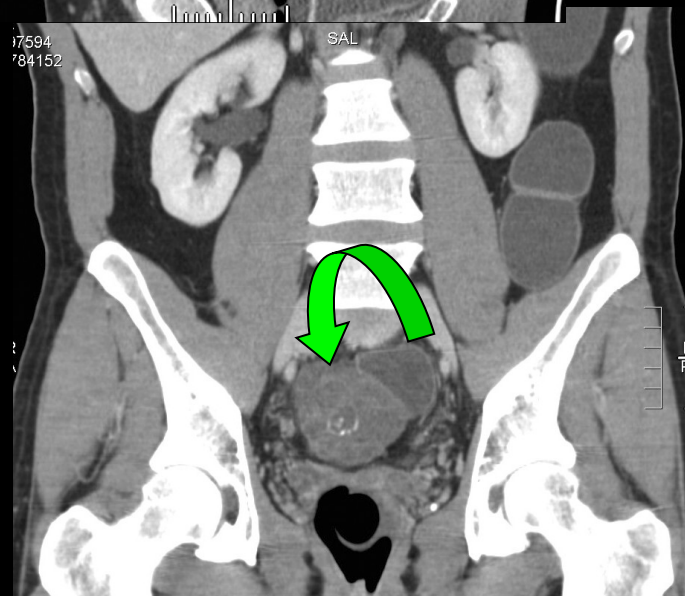
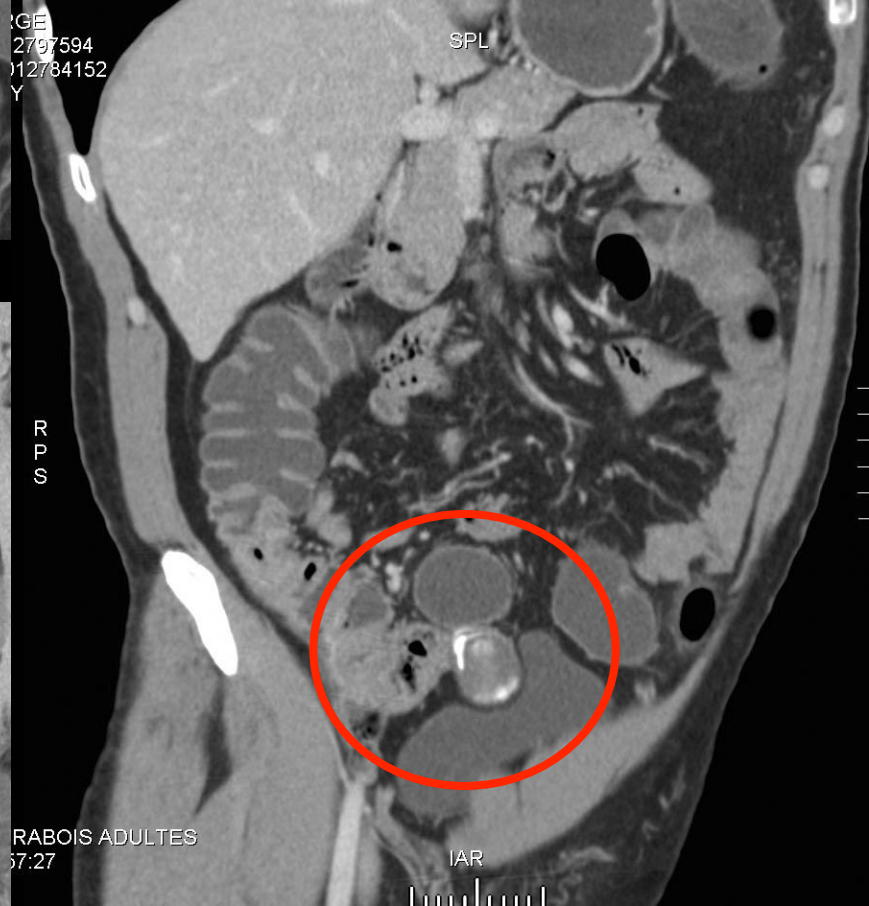
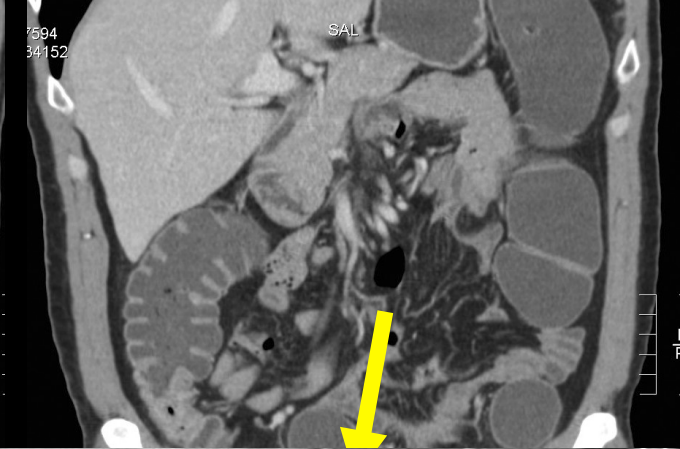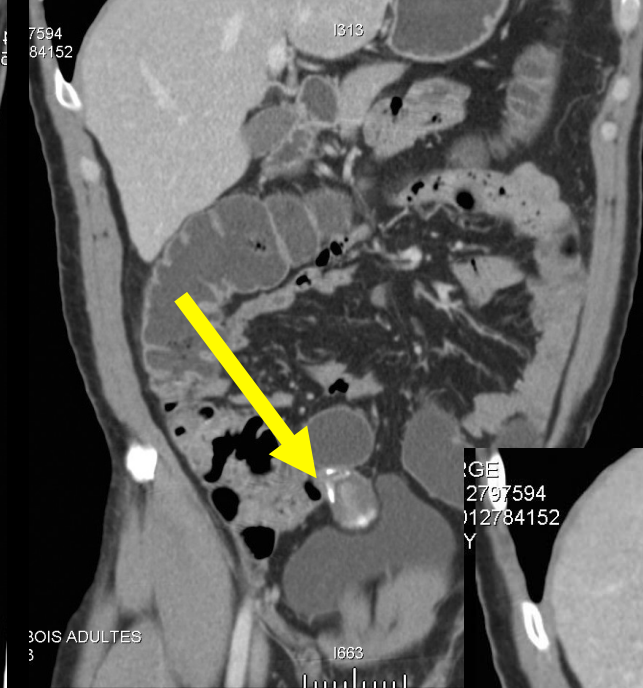
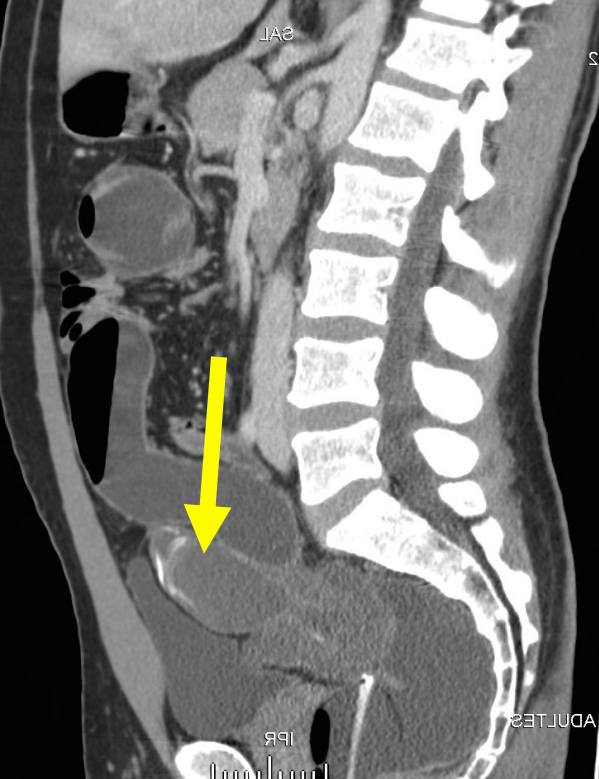
mucocele appendiculaire et hyperplasie épithéliale diffuse avec dysplasie modérée

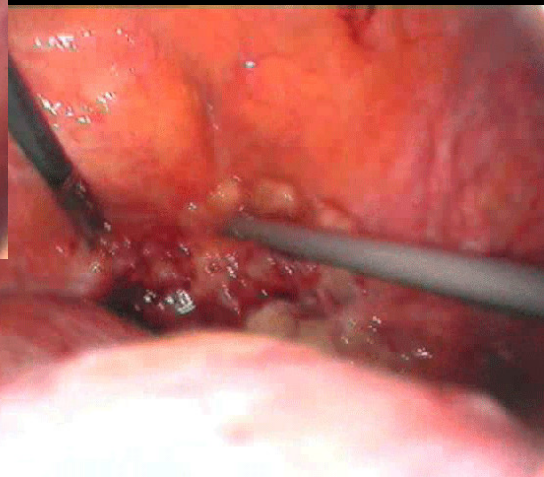
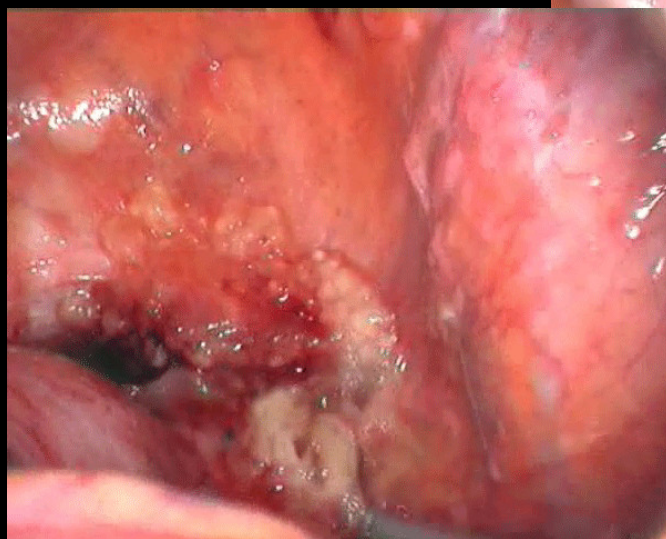
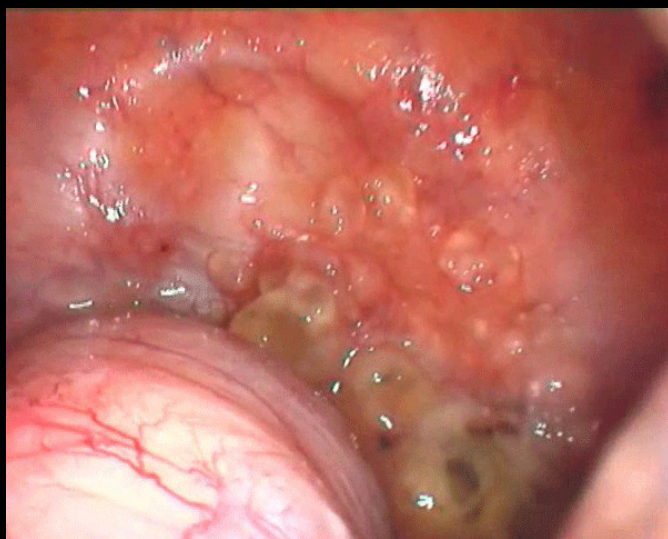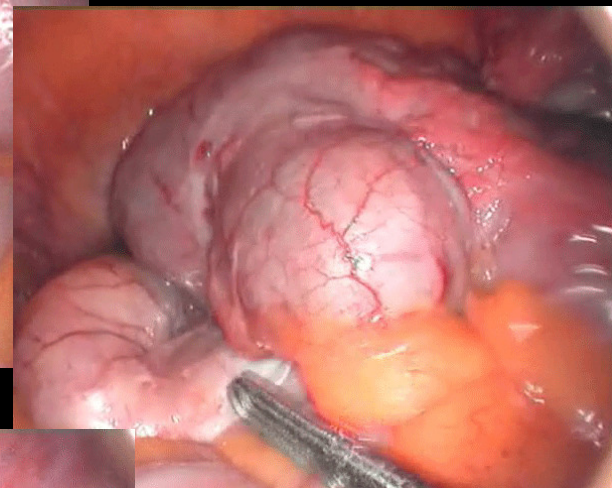
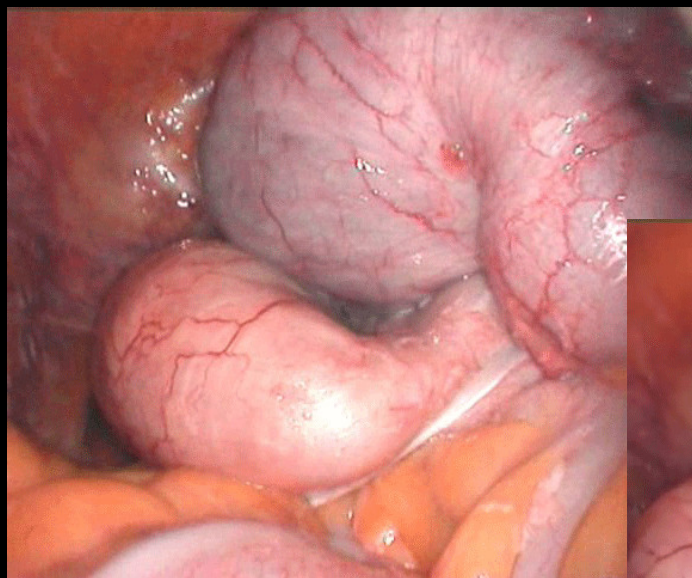
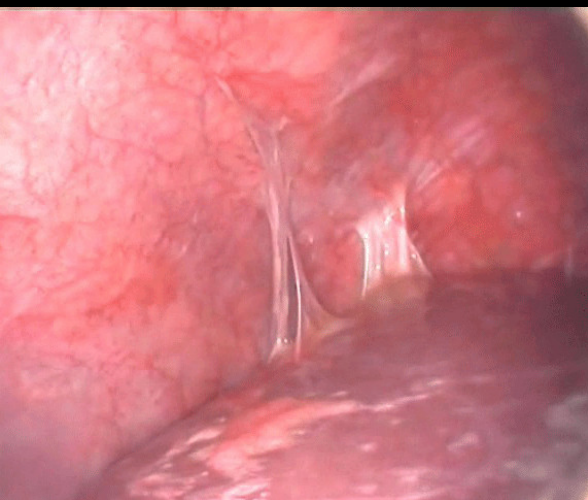


mucocèle appendiculaire et adénocarcinome mucineux

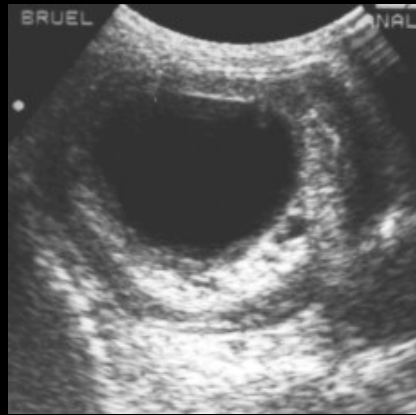
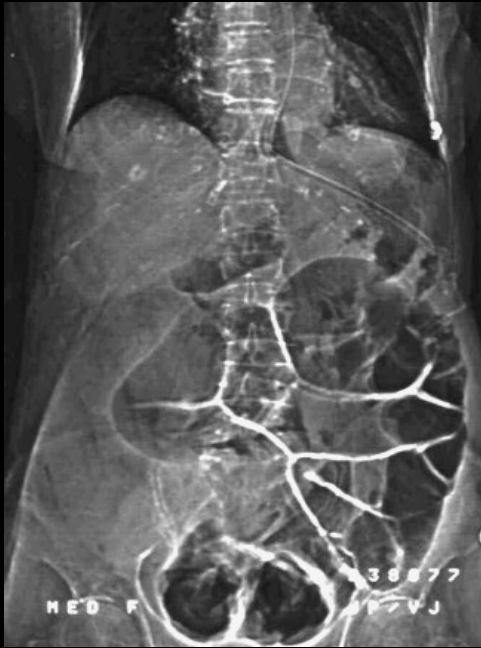homme 45 ans, douleurs abdominales atypiques, fatigue, pas de fièvre ..colo scanner ; diagnostic





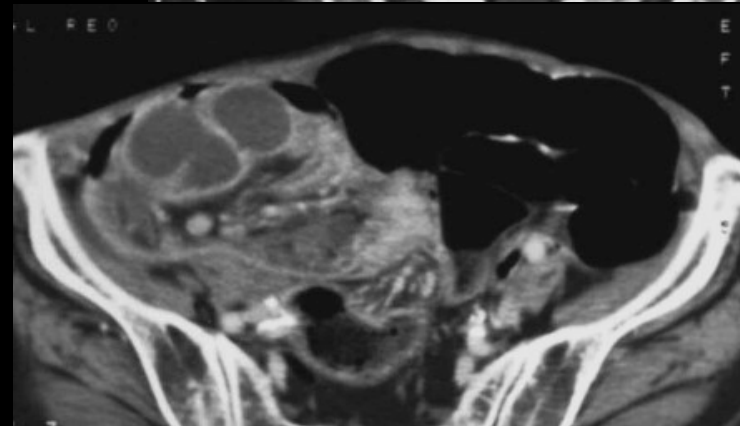
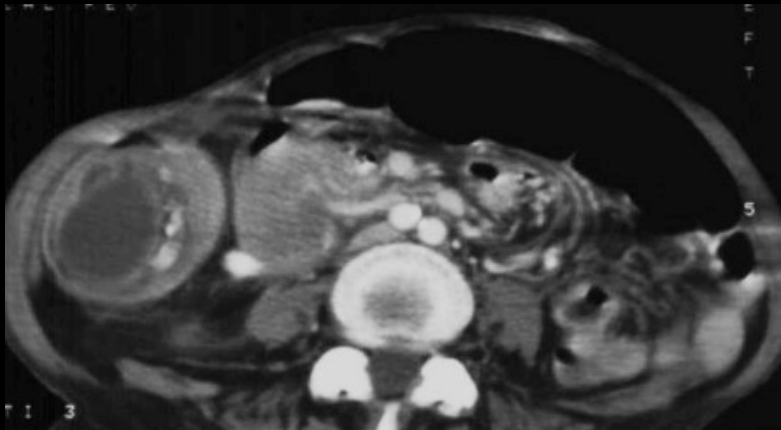
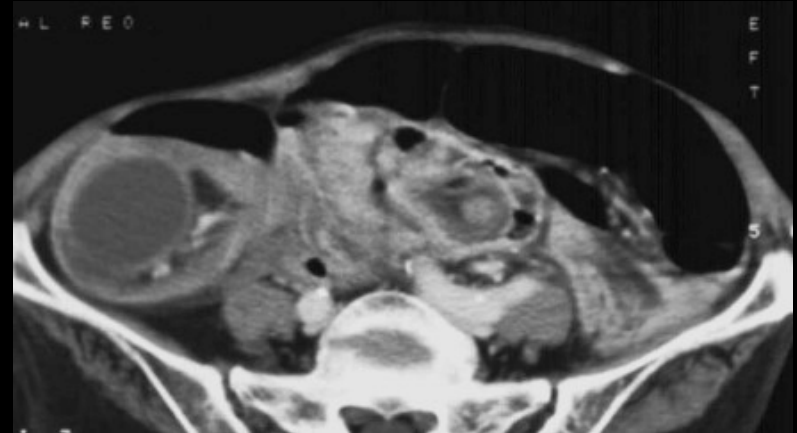


**mucocele appendiculaire maligne avec pseudomyxome péritonéal
(maladie gélatineuse du péritoine) pelvienne**

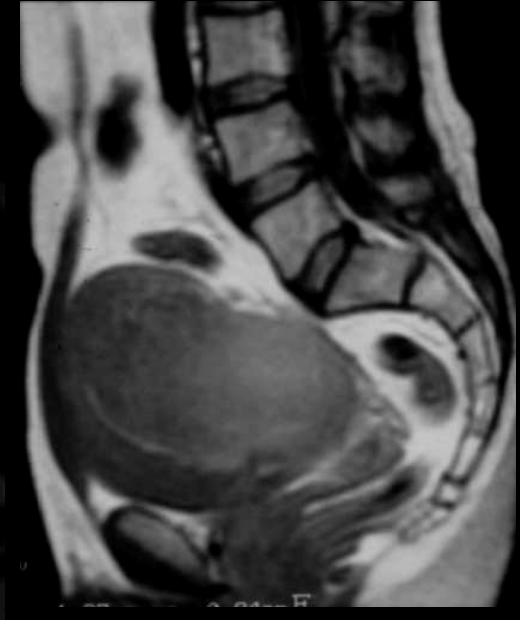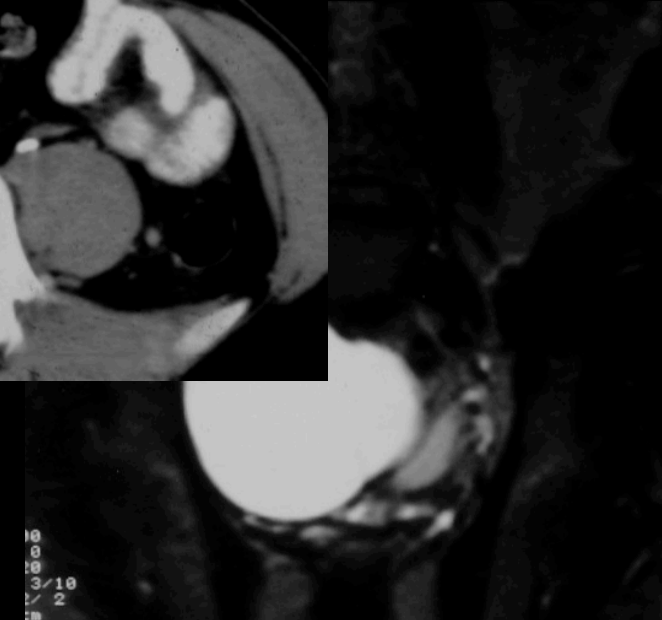
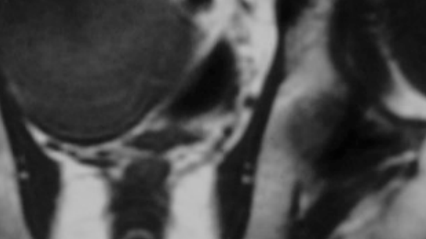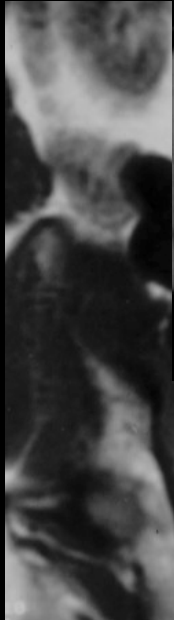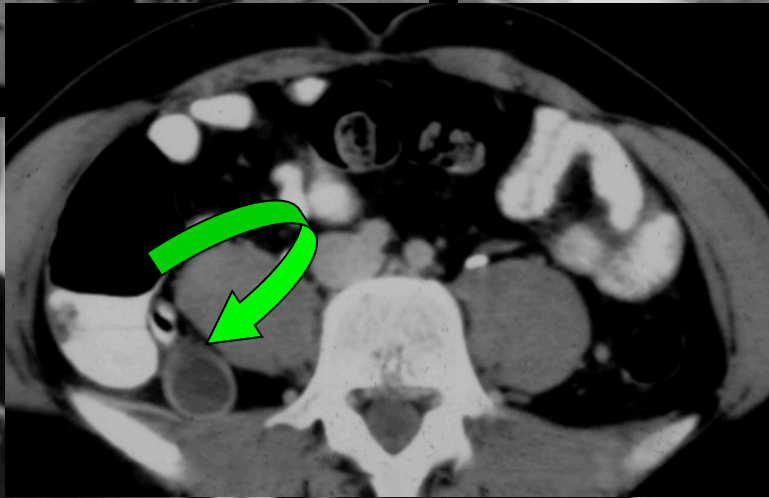
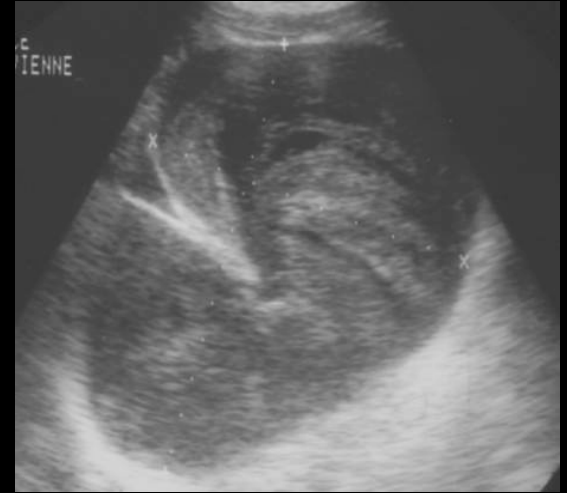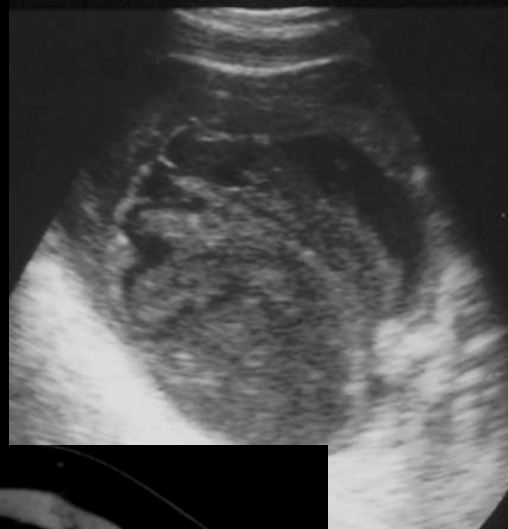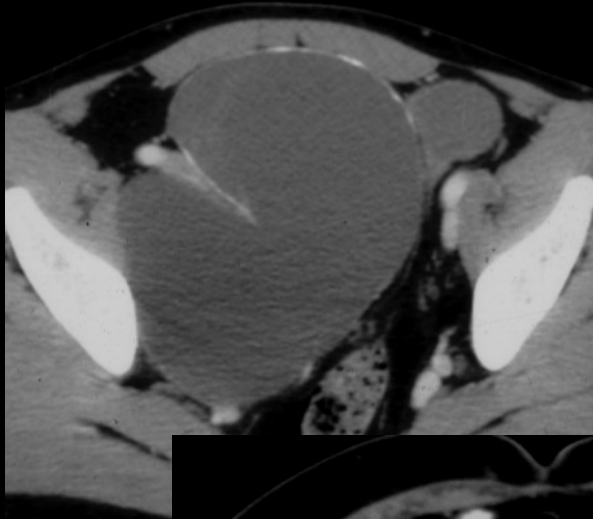


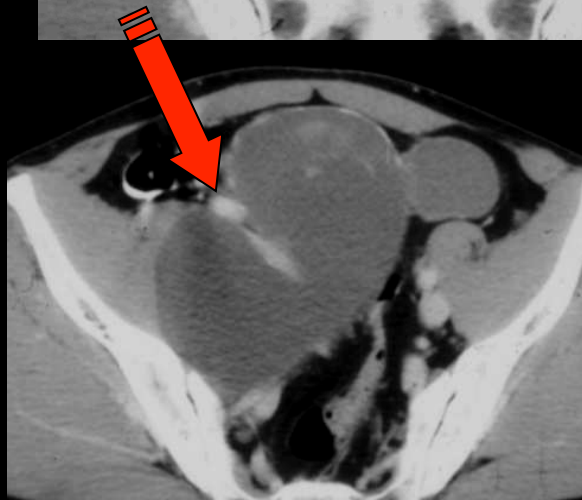
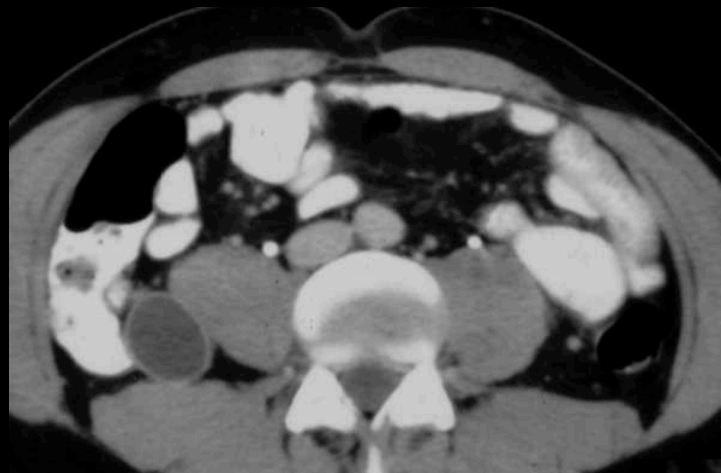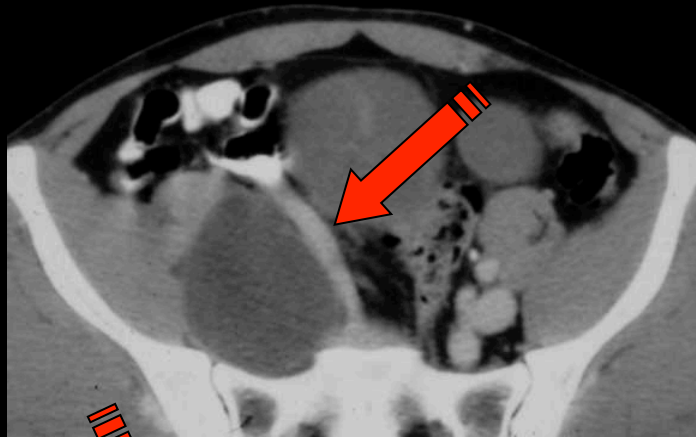
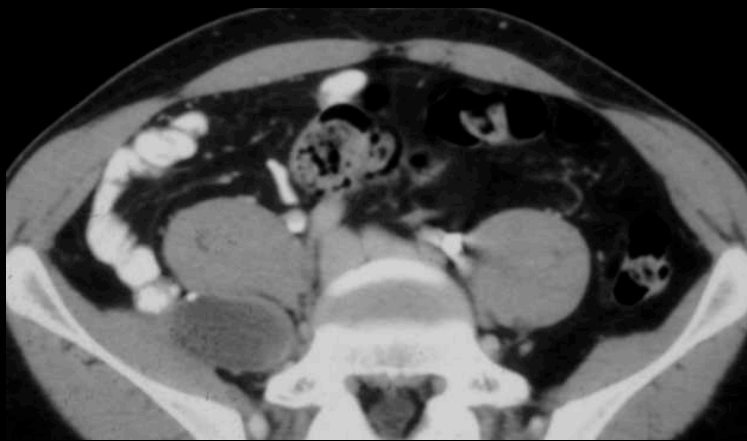*Obs. JM Bruel
CH Montpellier*

**invagination iléo-caecale sur mucocèle
appendiculaire mucocèle appendiculaire et
adénocarcinome mucineux ; femme 82 ans**

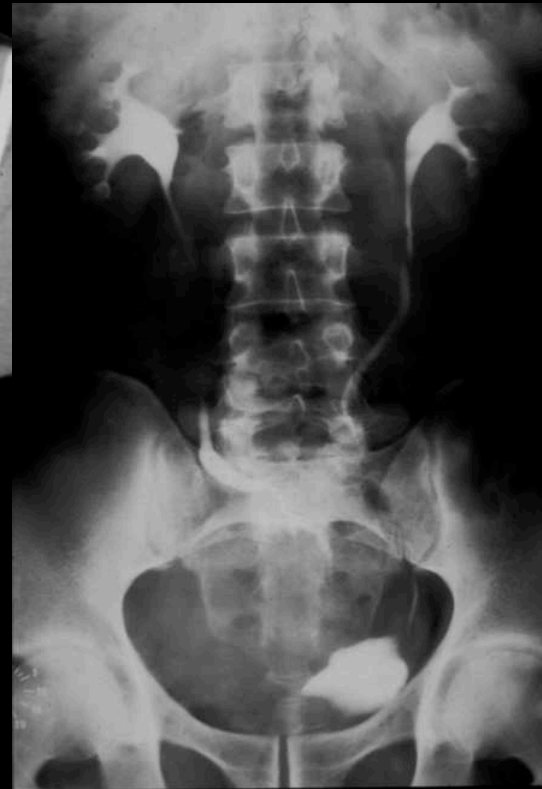
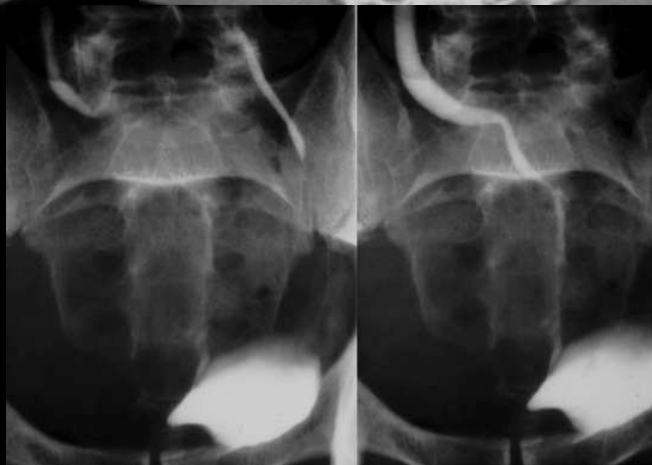
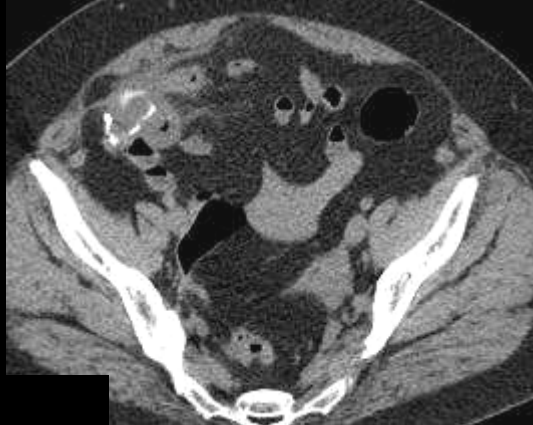
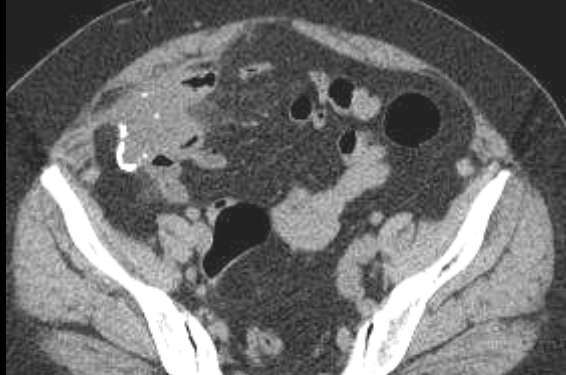
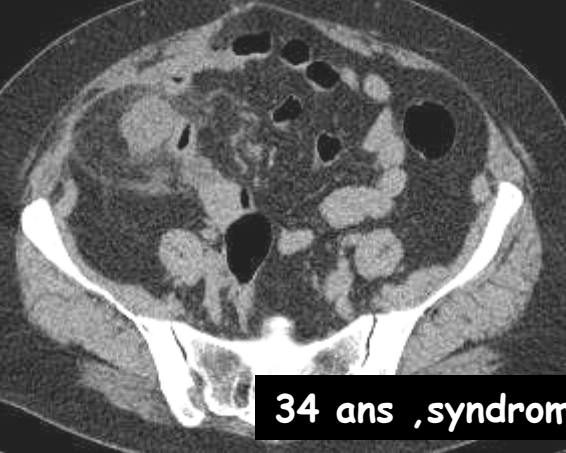
homme 34 ans, douleurs lombaires ,
pollakiurie ,pas de fièvre ...masse de la FID; diagnostic



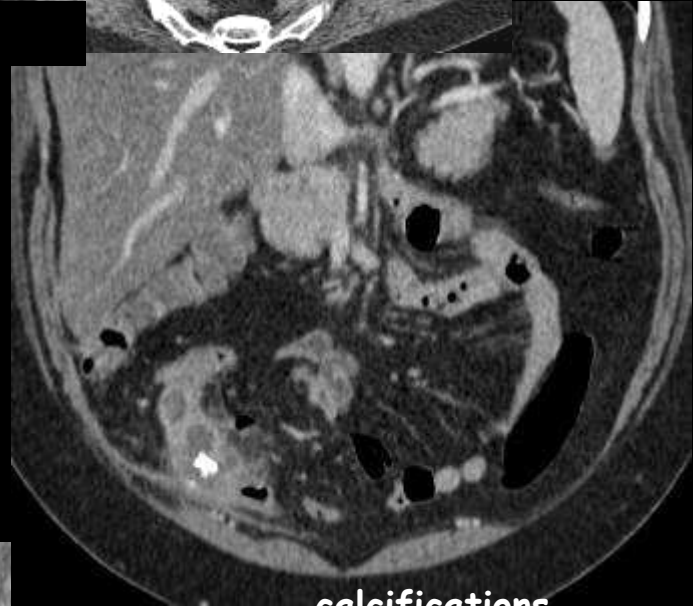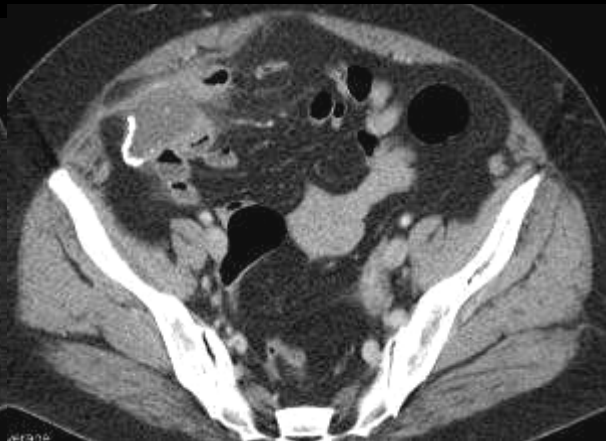

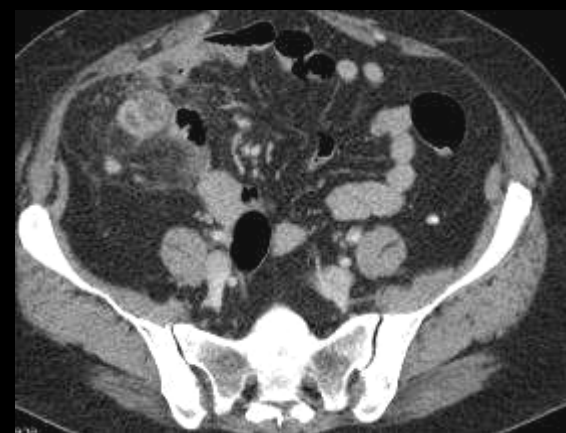
**mucocèle sur appendice
rétrocaecal , à développement
rétropéritonéal et sous
péritonéal pelvien**





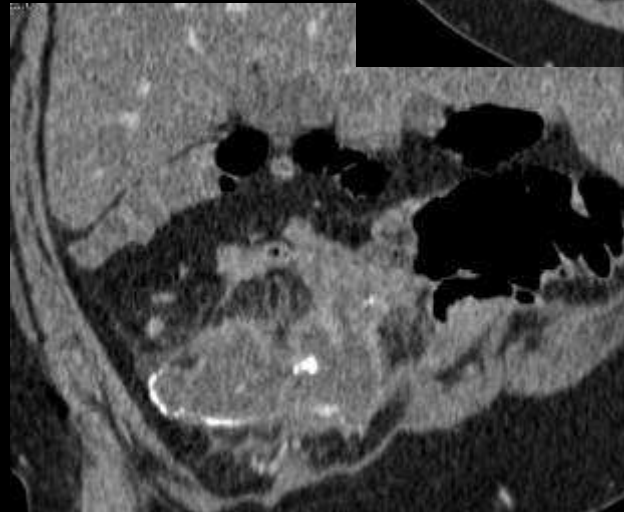
34 ans ,syndrome appendiculaire depuis 24h.!



appendicite perforée et mucocèle appendiculaire en rapport avec un néoplasme appendiculaire à potentiel malin de bas grade !

méconnaître la mucocèle ne permet pas une prise en charge chirurgicale adaptée !

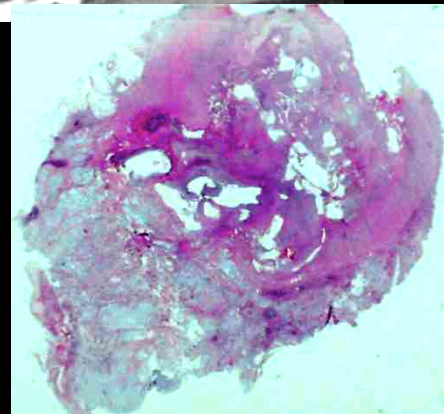
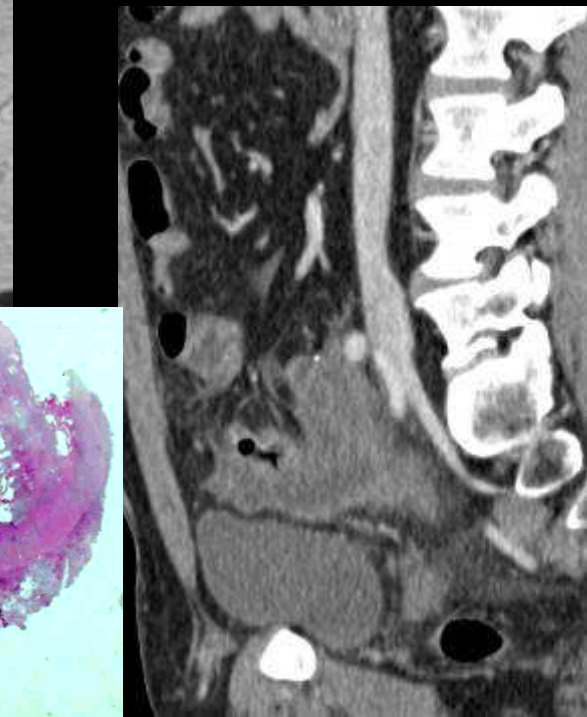
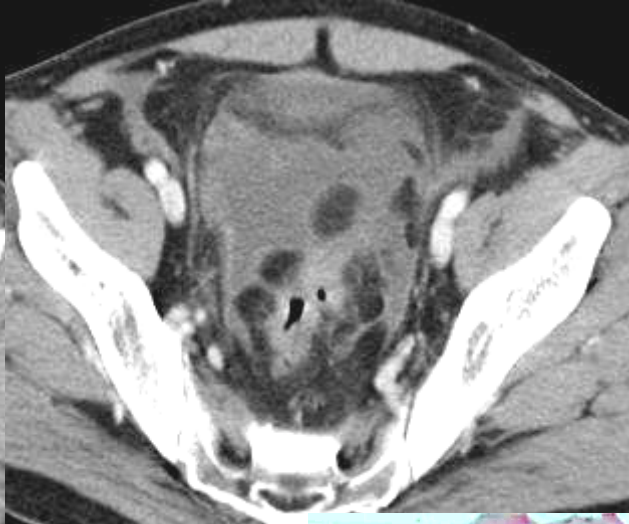
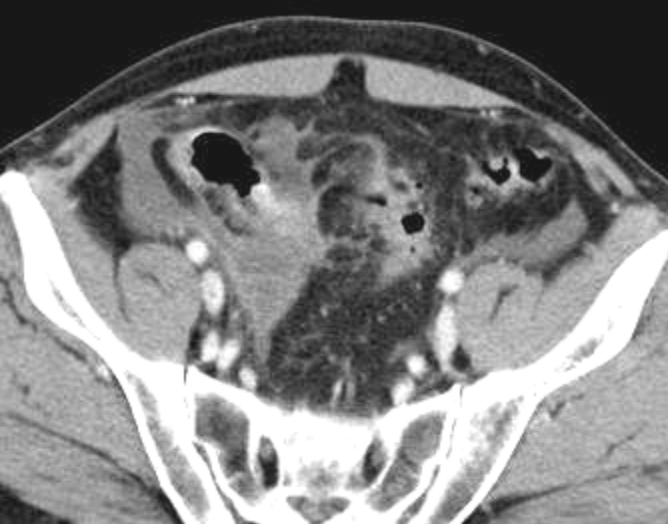
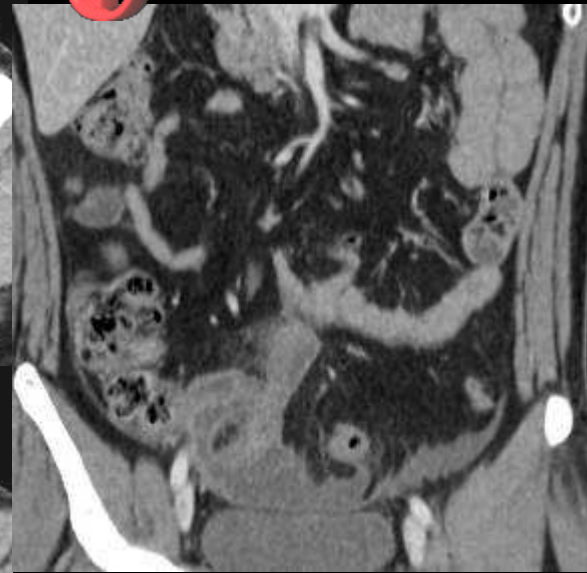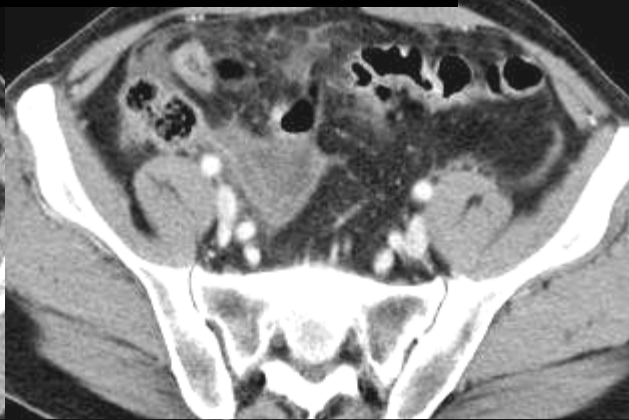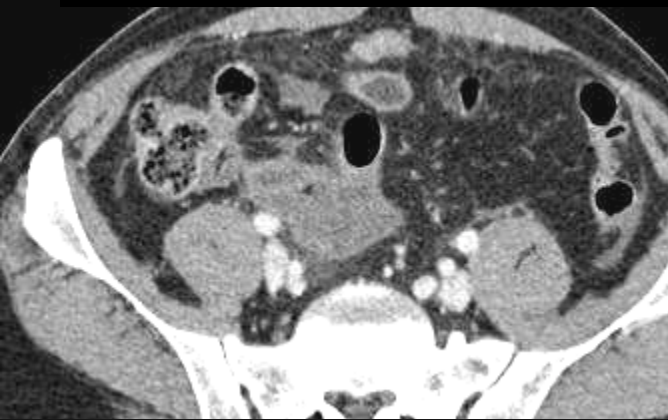
CHIP (Sugarbaker)



calcifications pariétales et intra lumenales appendiculaires

infiltration du méso appendiculaire et du péritoine en regard

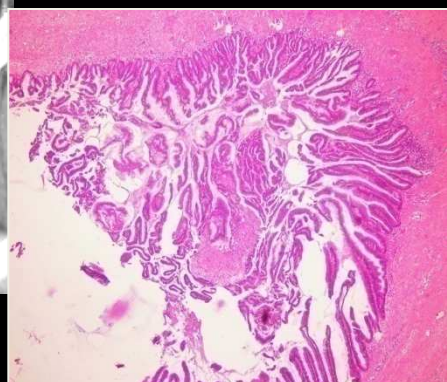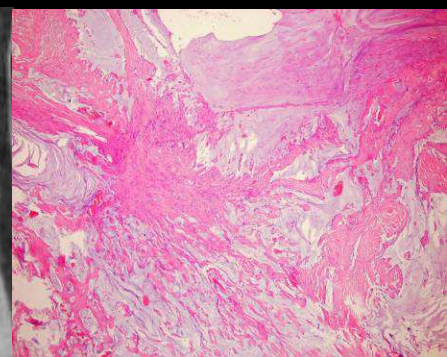
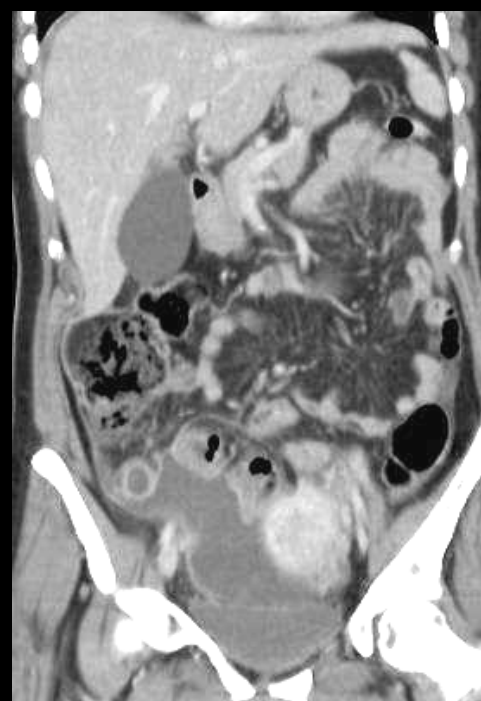
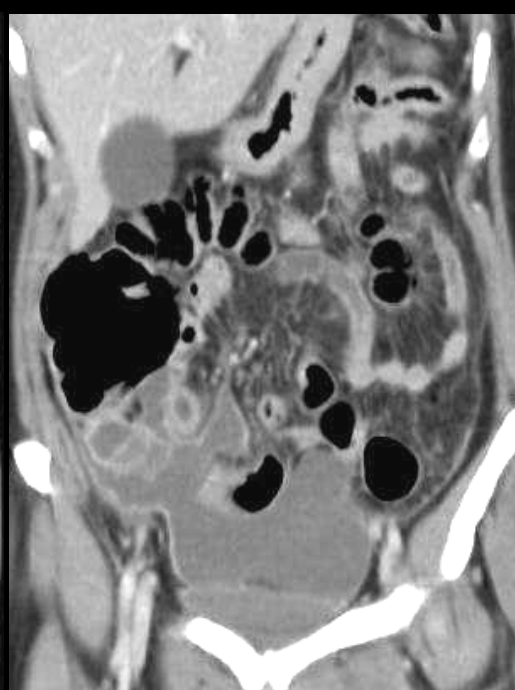
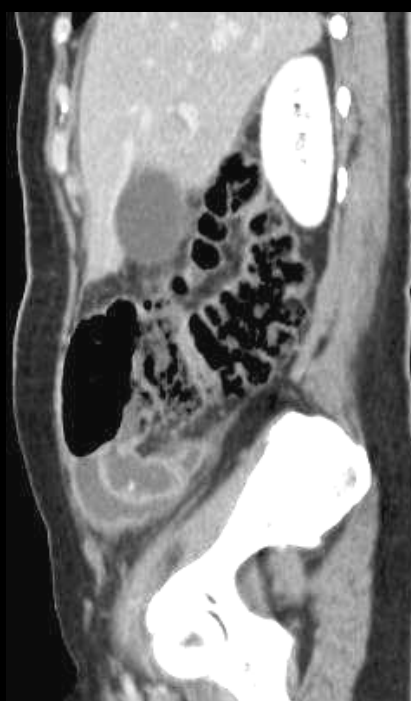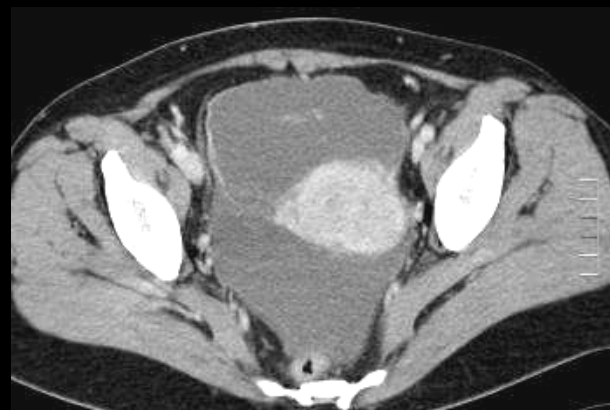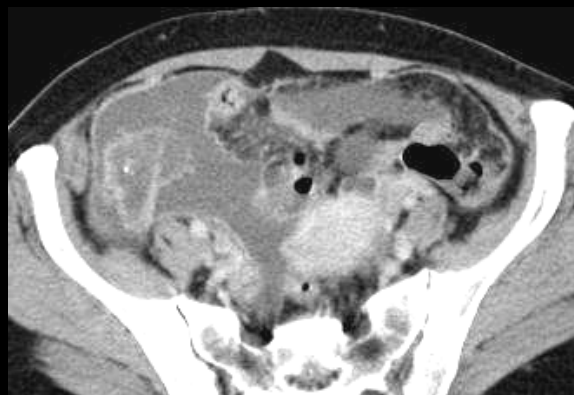
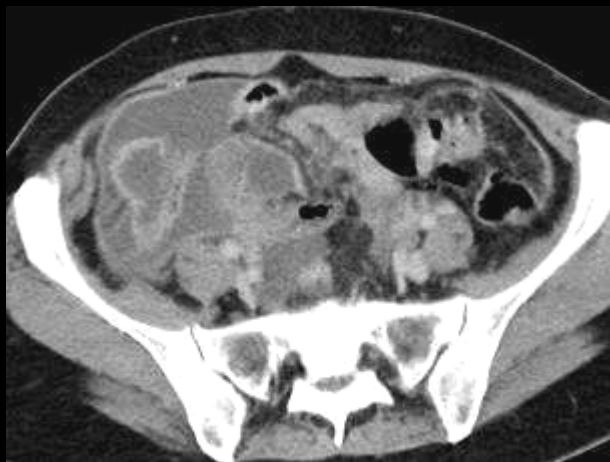
homme 41 ans ; syndrome appendiculaire depuis 2 jours



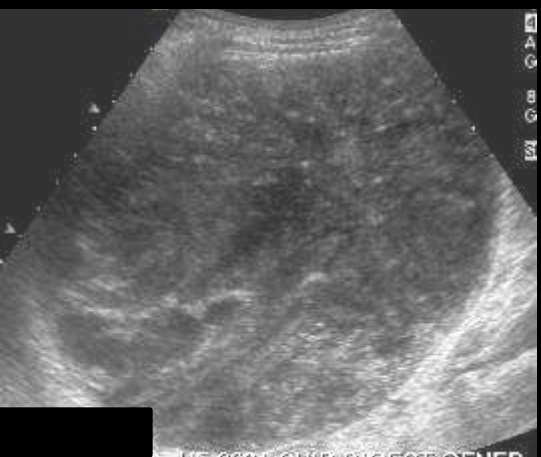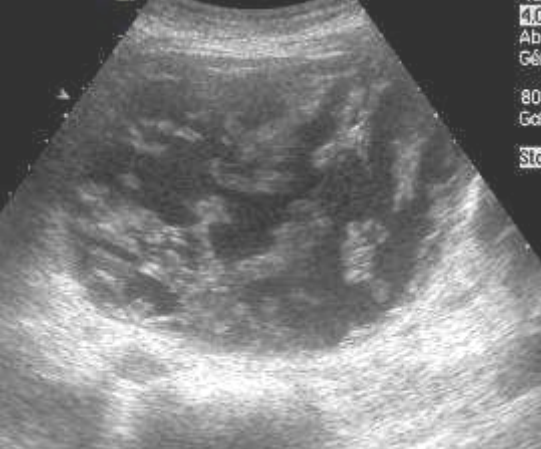appendicite perforée sur mucocèle appendiculaire en rapport avec un **néoplasme appendiculaire à potentiel malin de bas grade avec pseudomyxome péritonéal !**

diagnostic différentiel avec une complication à type de péritonite localisée pas toujours facile

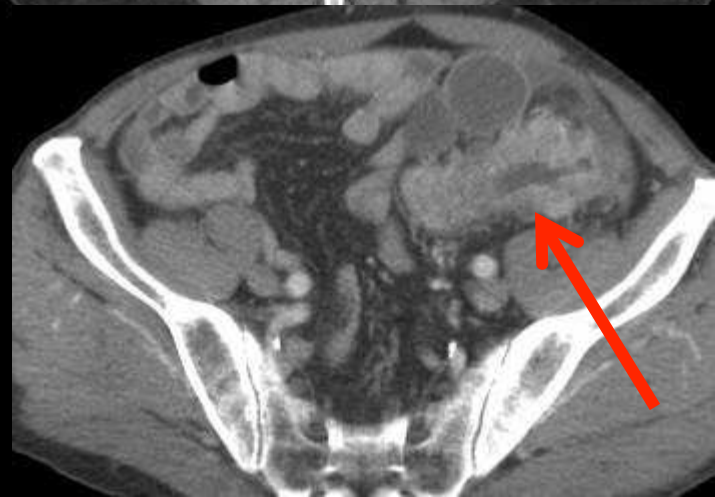
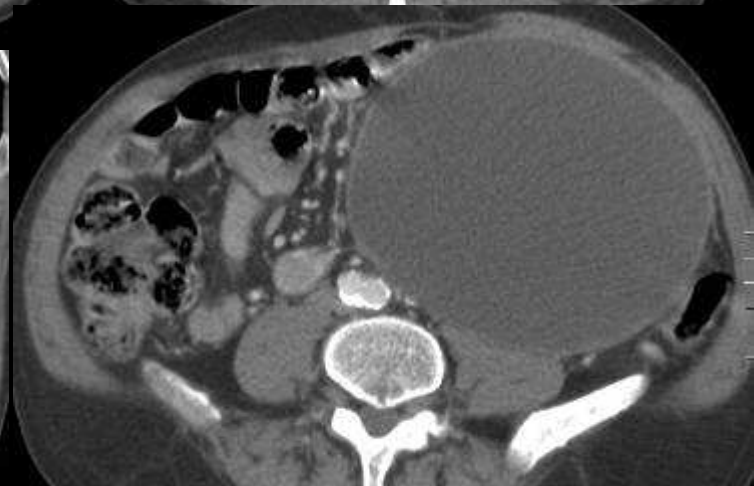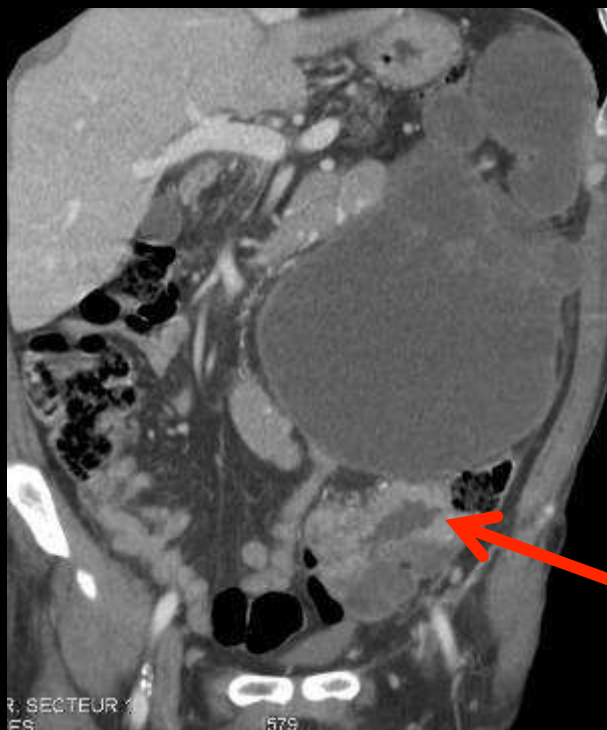
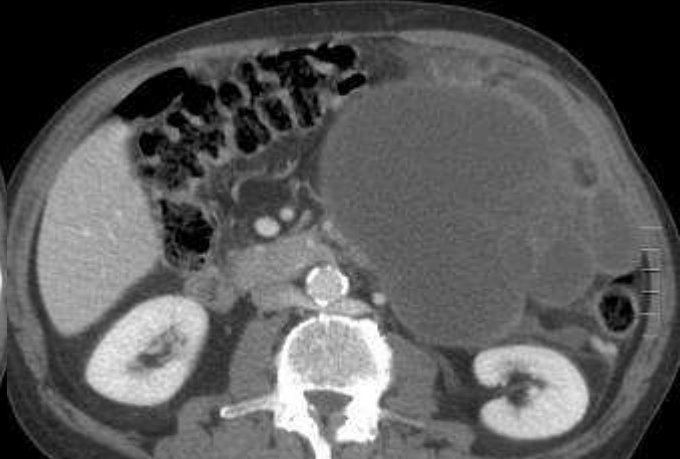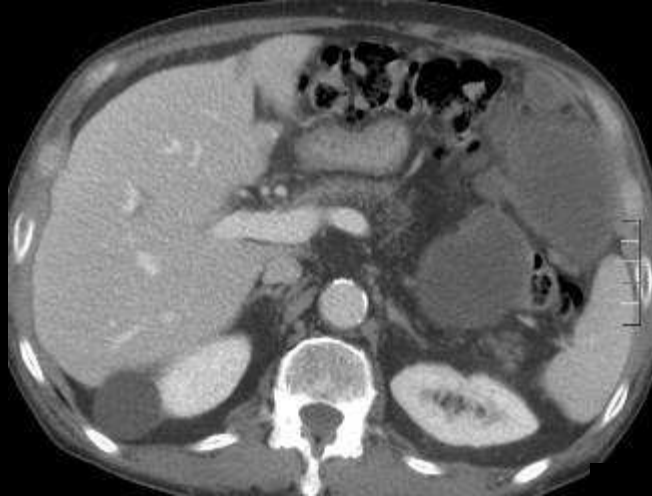femme 55 ans syndrome appendiculaire depuis 48 heures



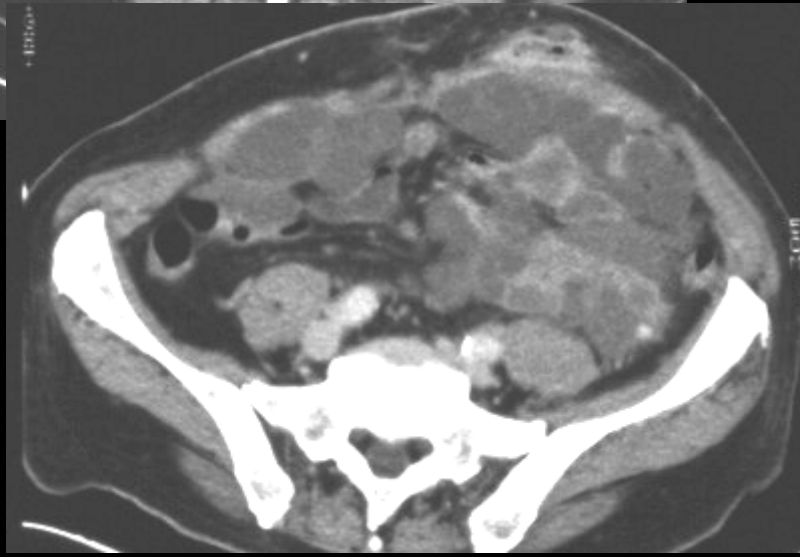
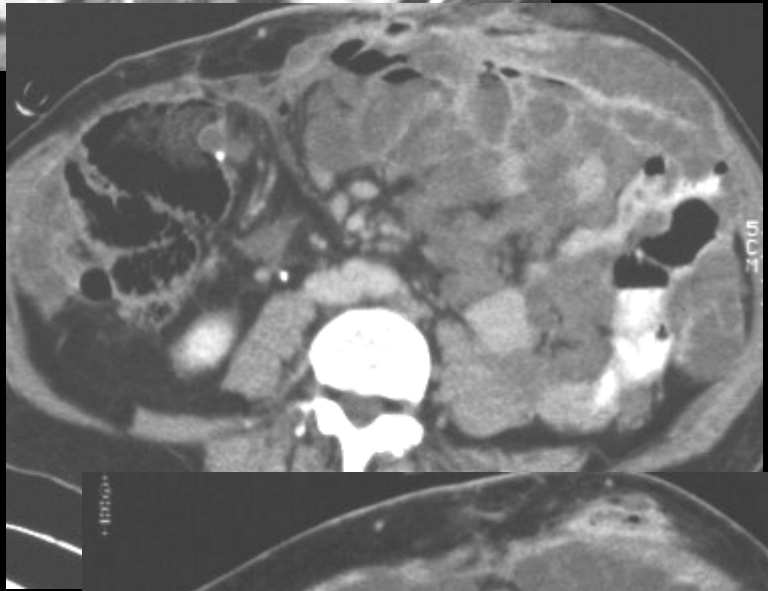
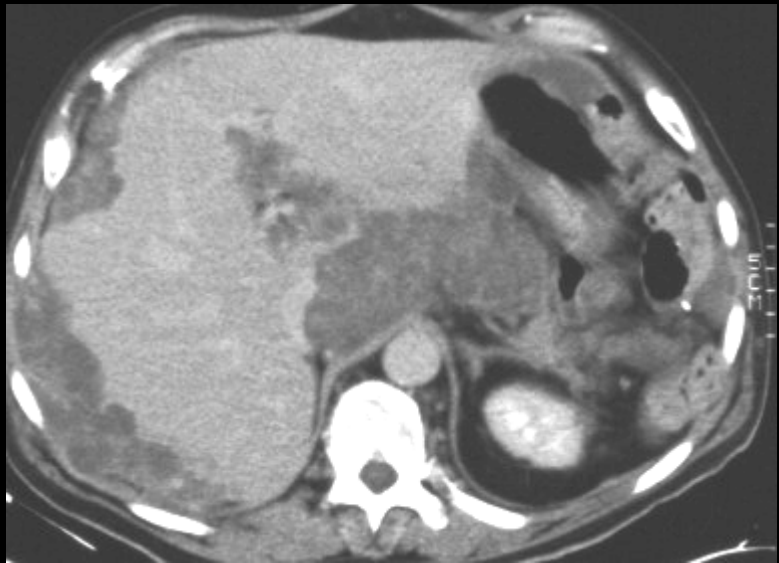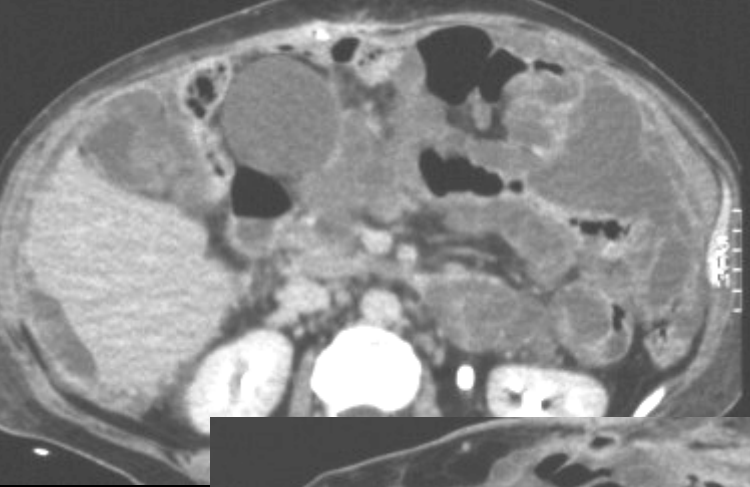
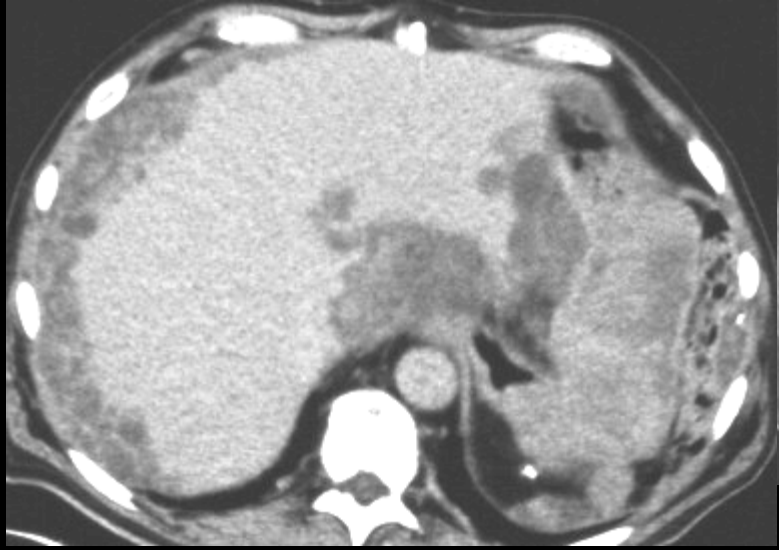mucocèle et carcinome mucineux papillaire



aspect stratifié de la mucine en échographie

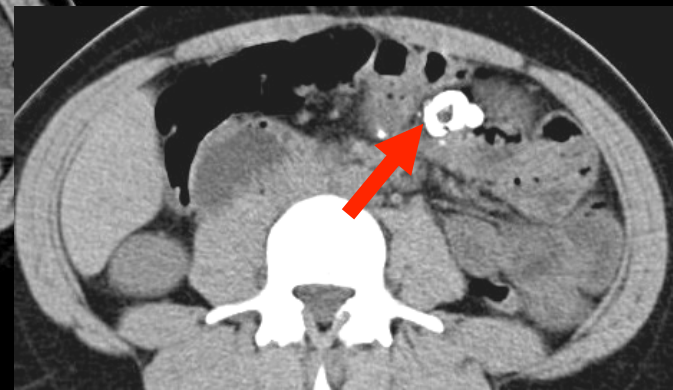
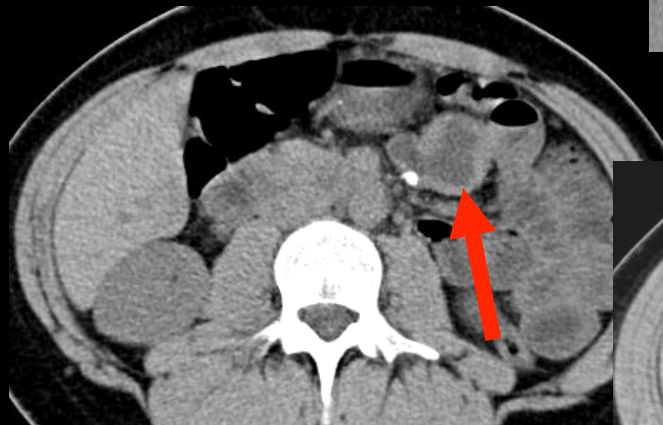
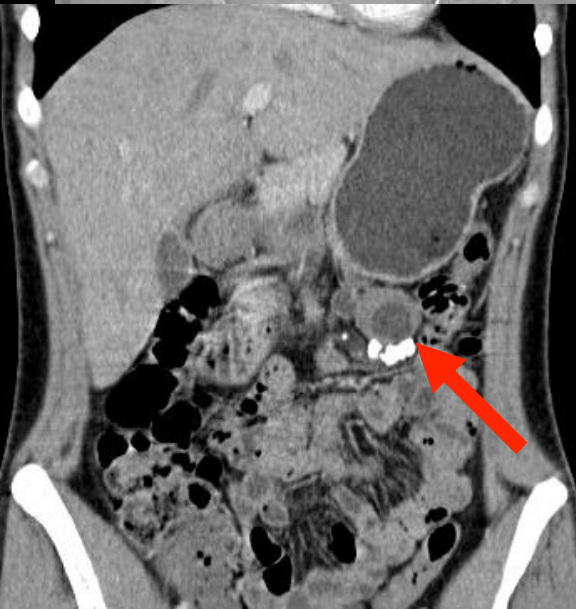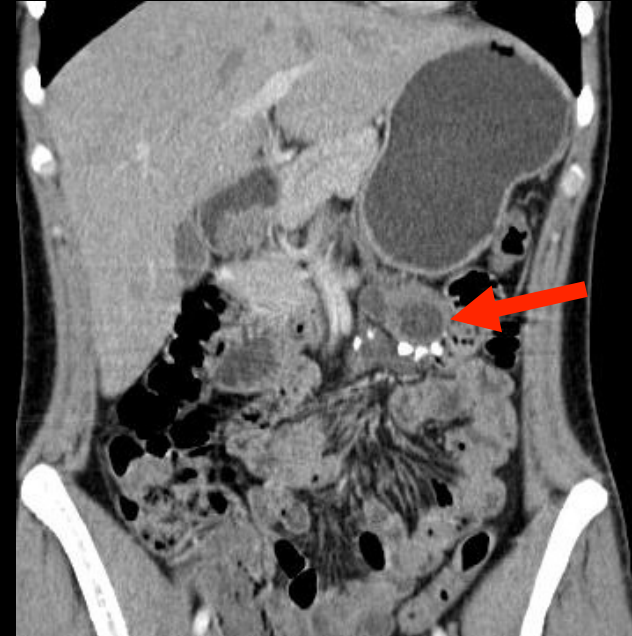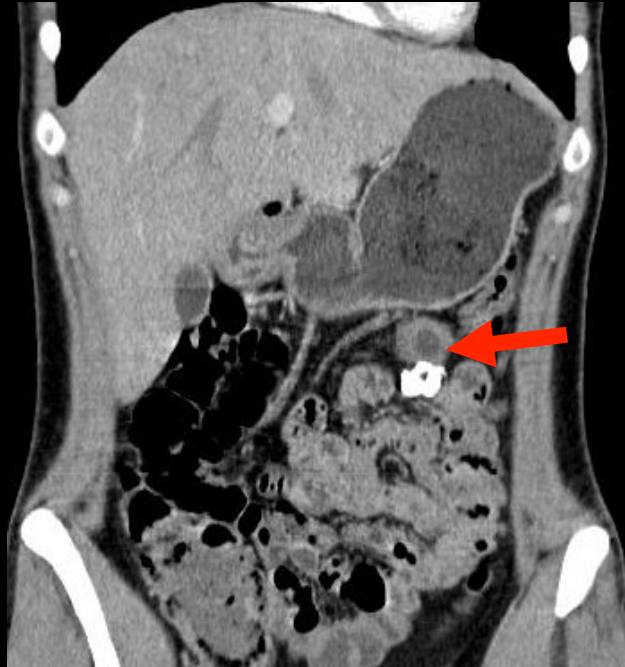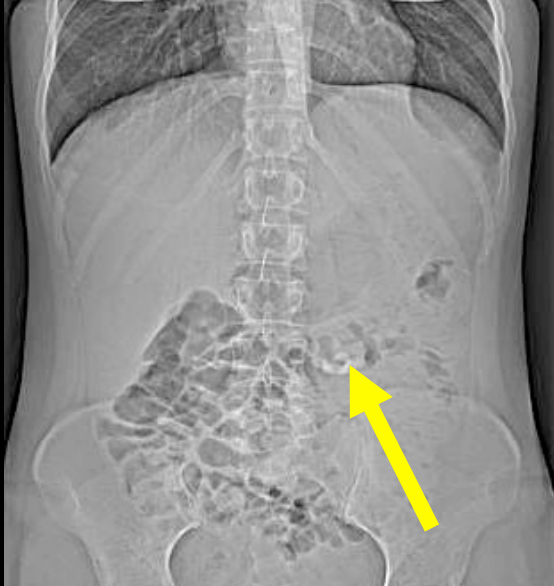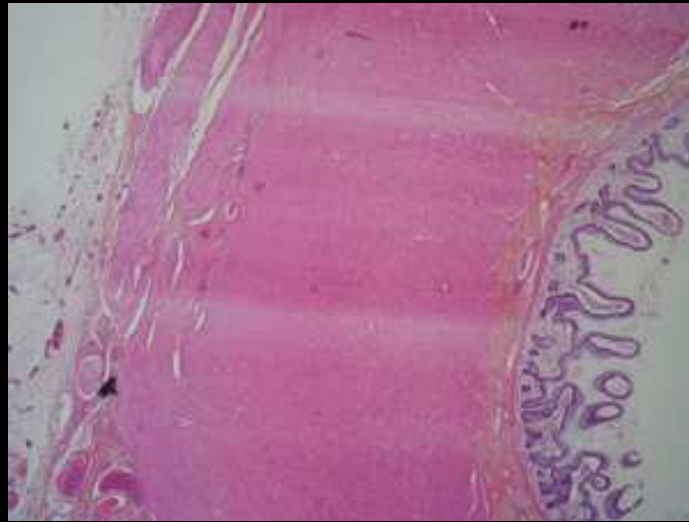
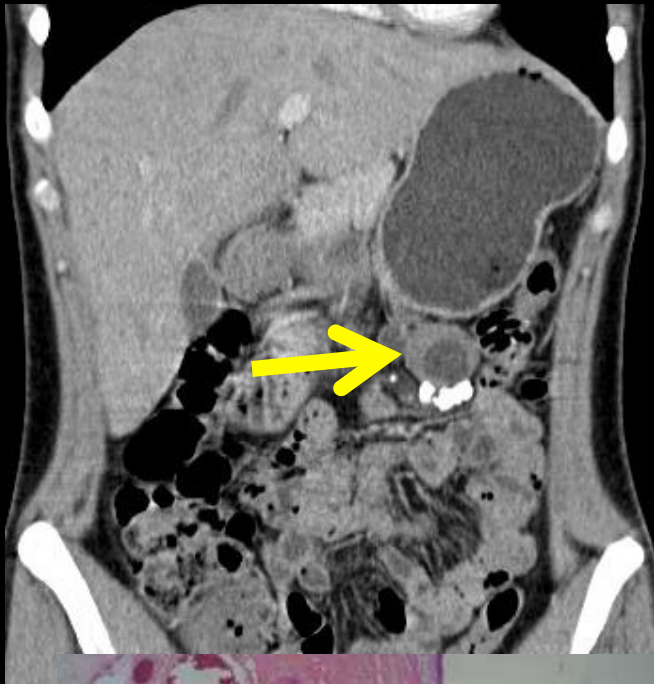carcinose péritonéale mucineuse (CMP) cloisonnée dans le flanc gauche avec implants dans l'épiploon et le méso sigmoïde en rapport avec un **adénocarcinome sigmoïdien**



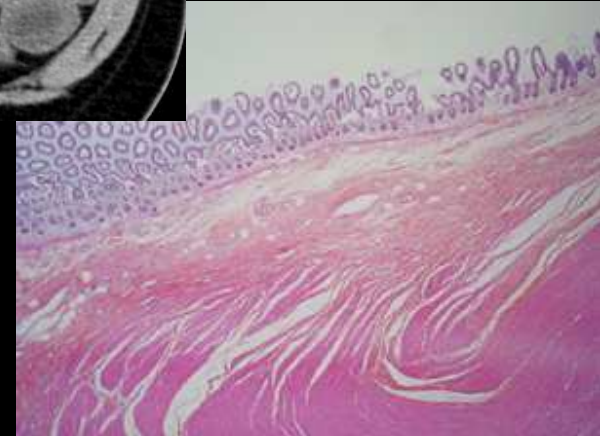
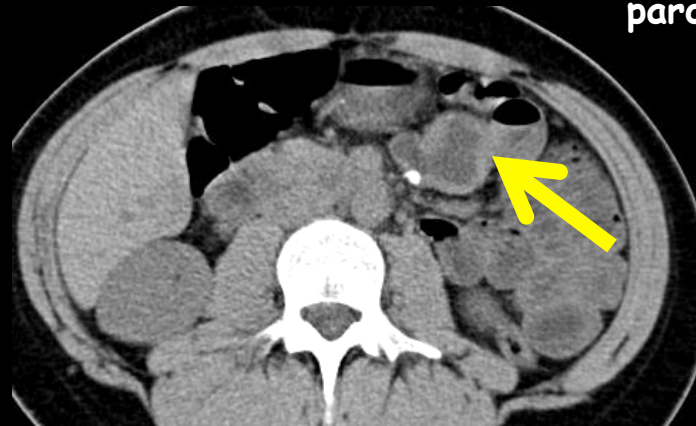
carcinose péritonéale mucineuse cloisonnée et effet de masse sur les parenchymes (scalloping) ; atteinte diffuse de l'ensemble de l'abdomen appendicectomie 2 ans auparavant (adénocarcinome)

femme 27 ans , vosgienne , douleurs de l'hypochondre gauche depuis plusieurs semaines ; coloscopie normale

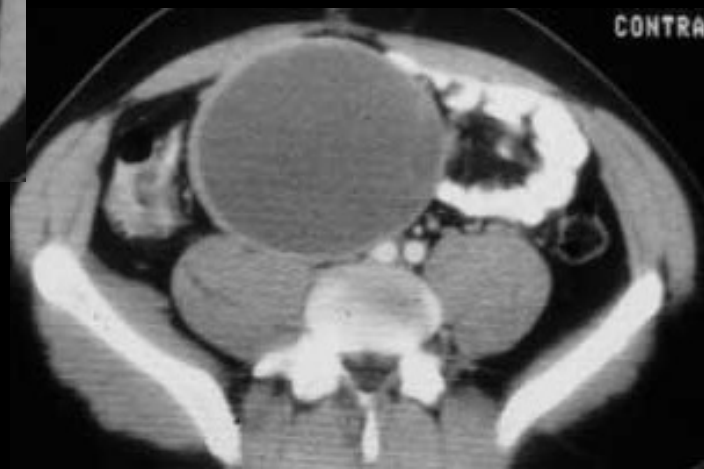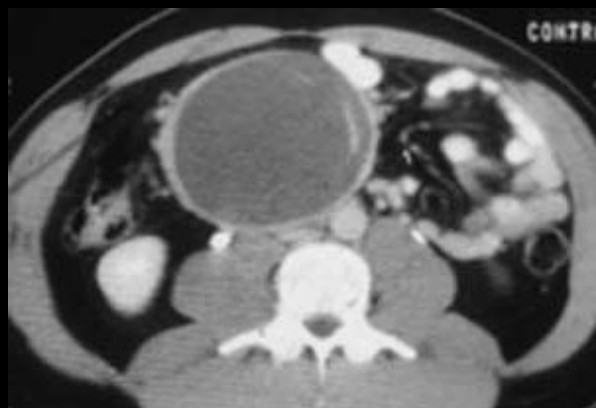

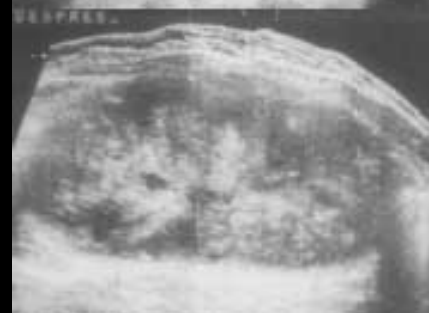
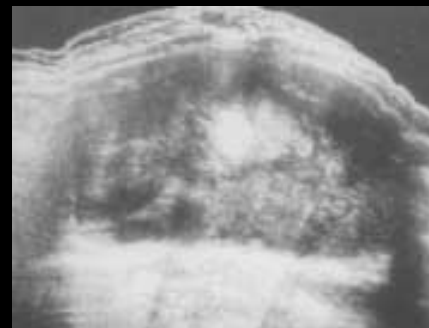
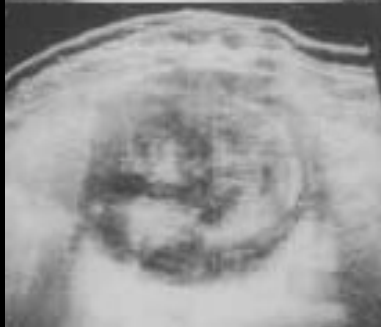
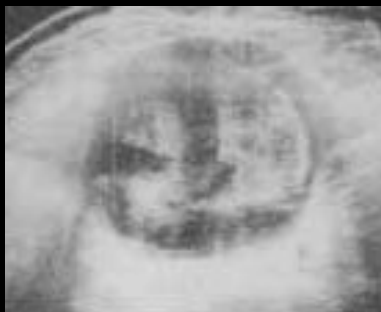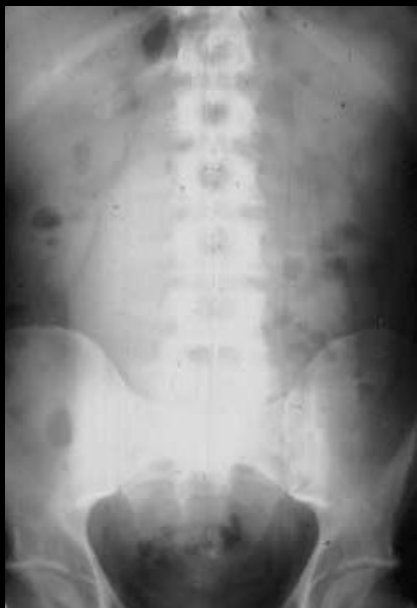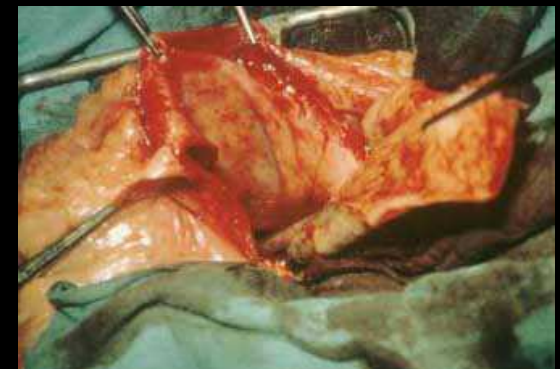
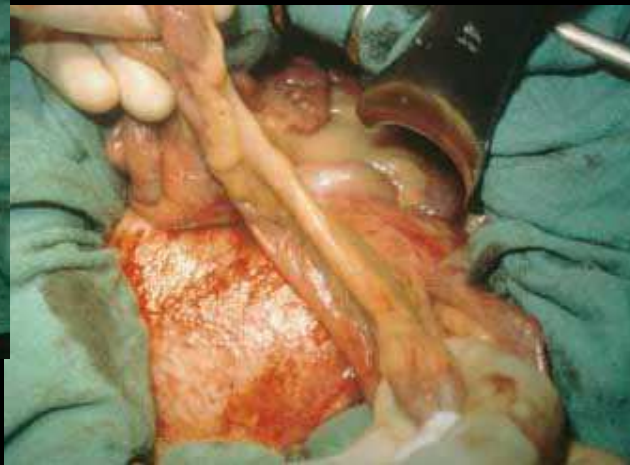
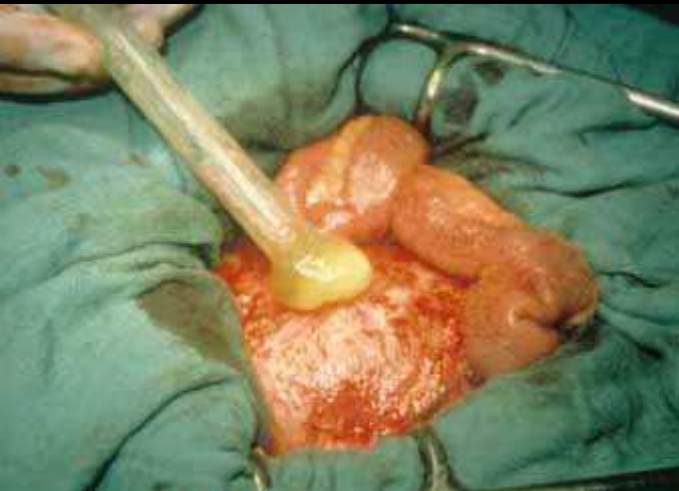
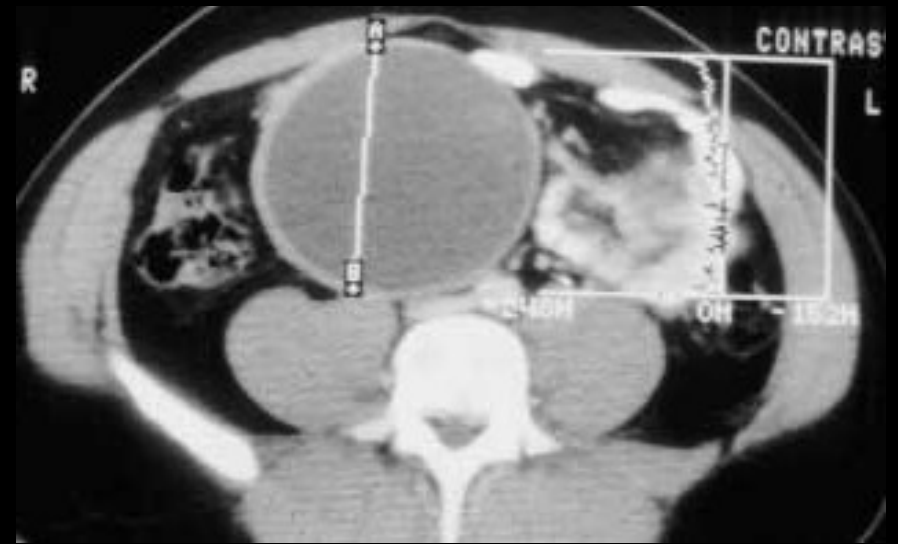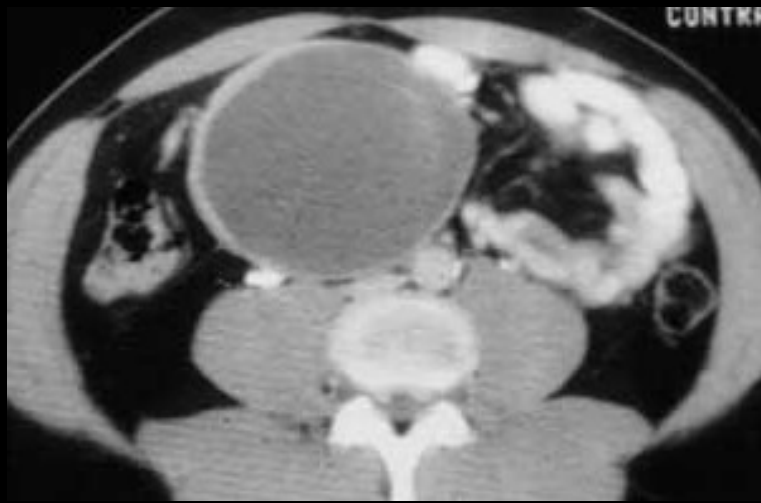parois épaisses (3 couches)



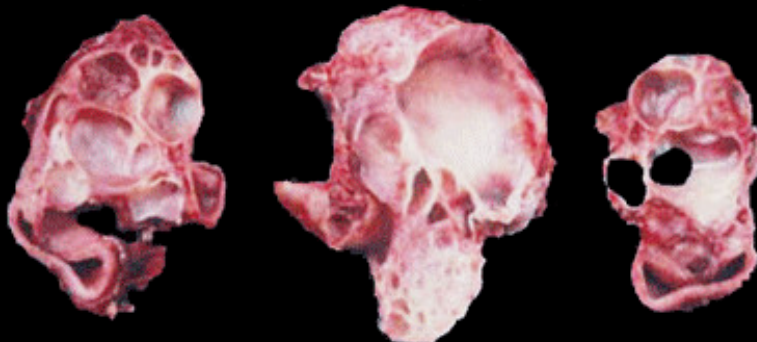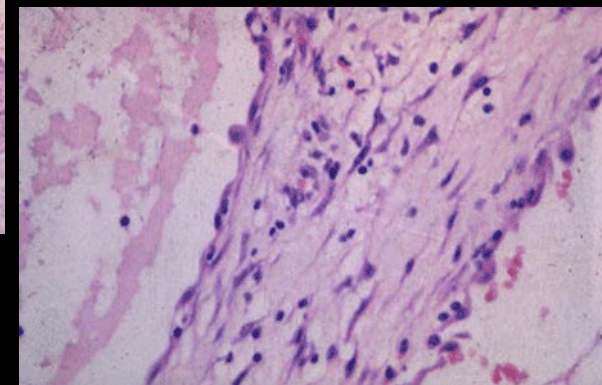
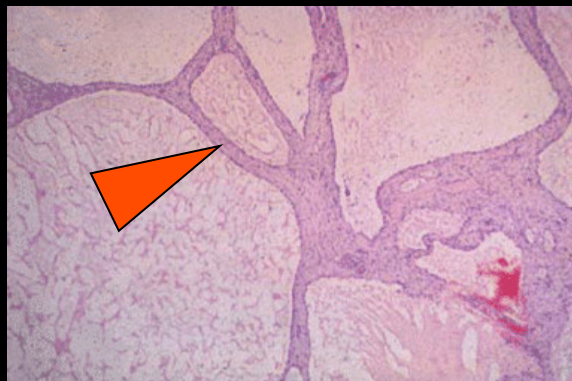
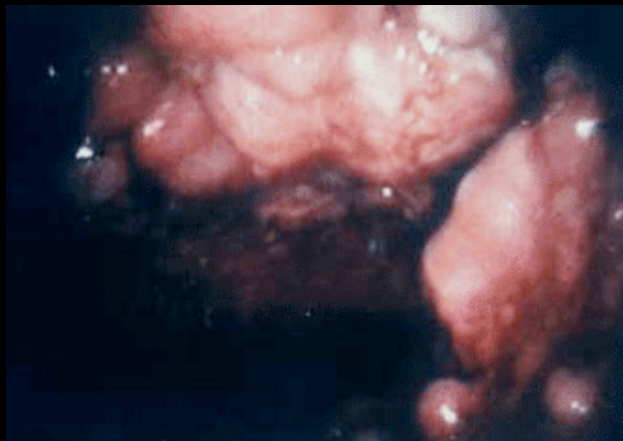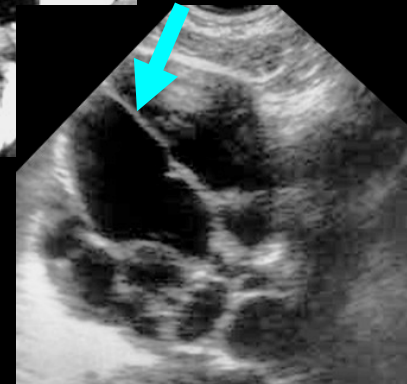
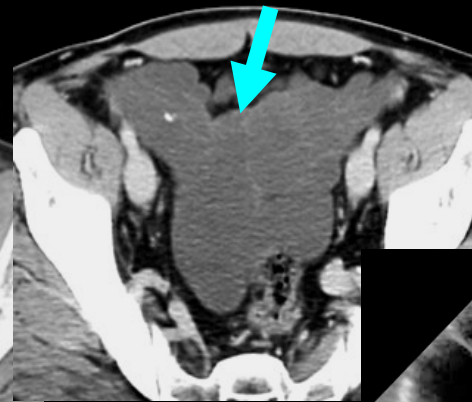
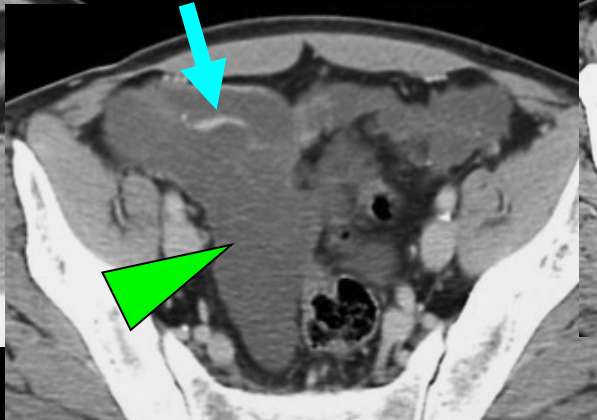
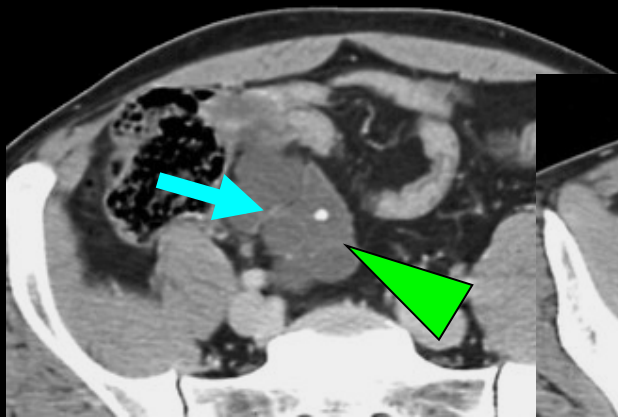
duplication intestinale (dans le mésocolon transverse)



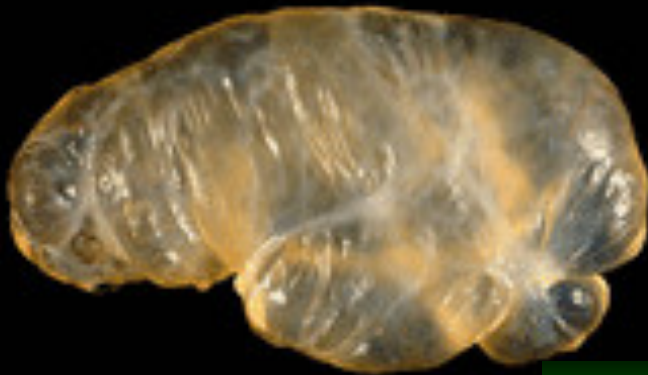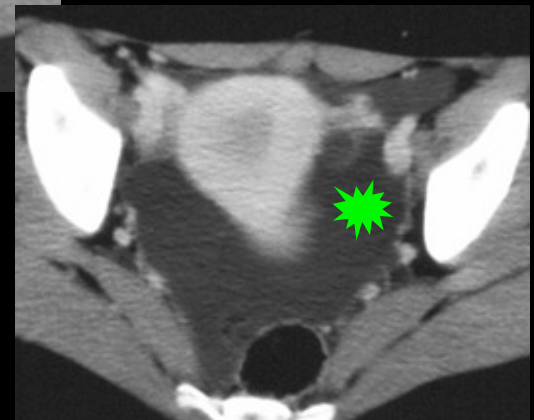
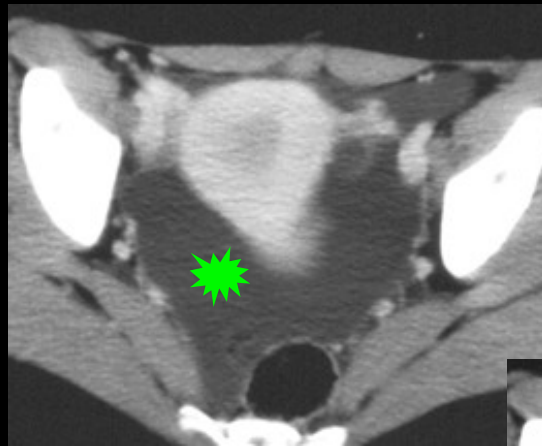
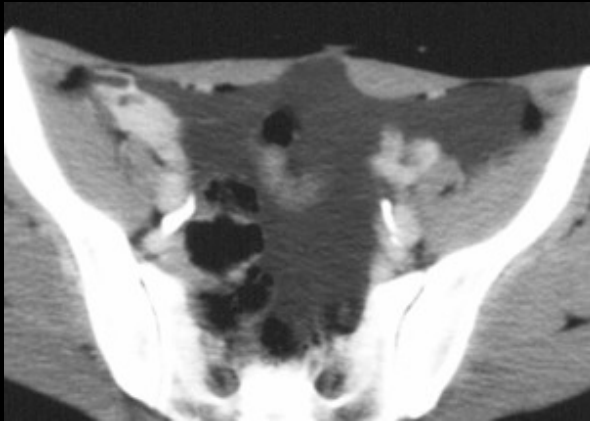
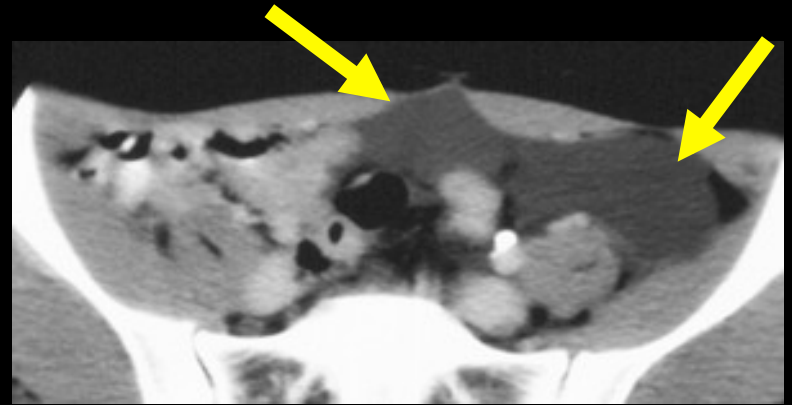
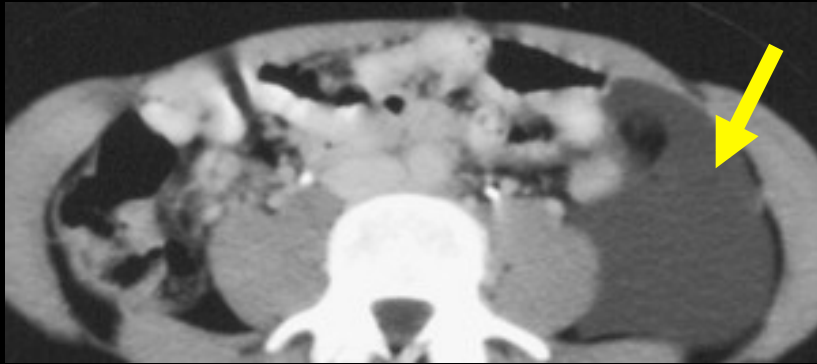
homme 26 ans , douleurs abdominales et masse palpable



duplication kystique ; évolution vers pseudo myxome et décès 3ans plus tard

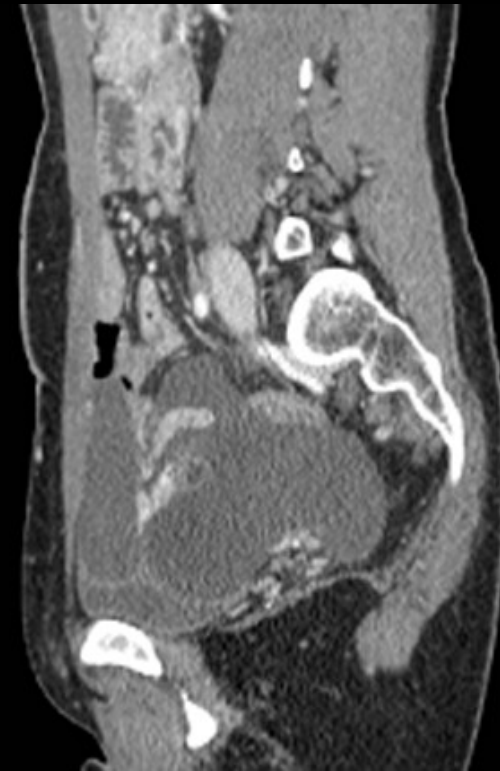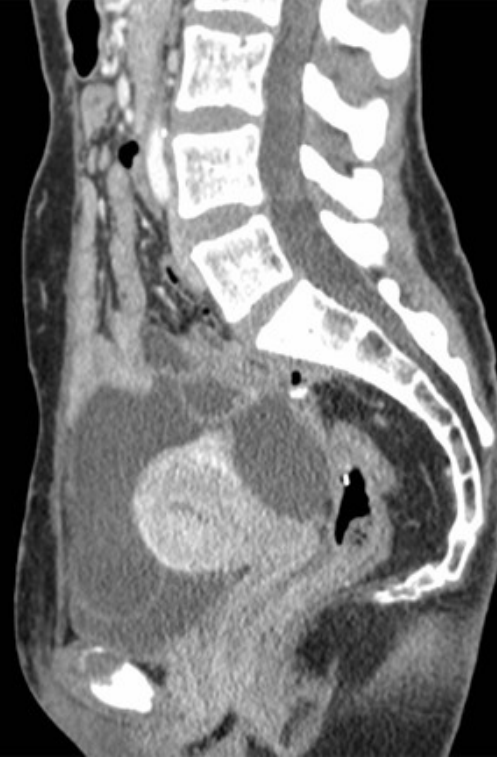
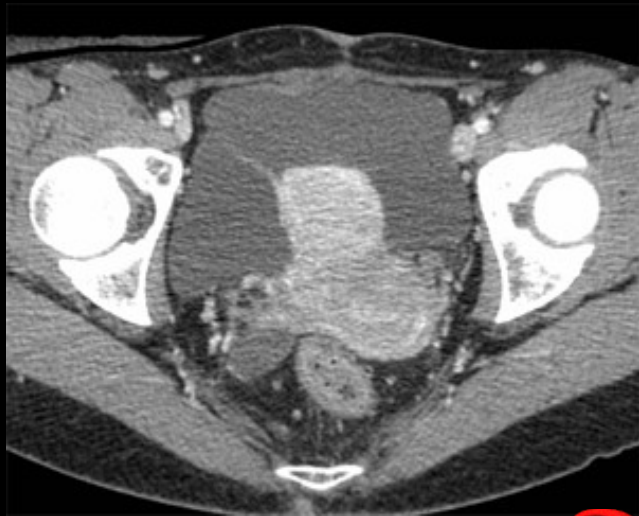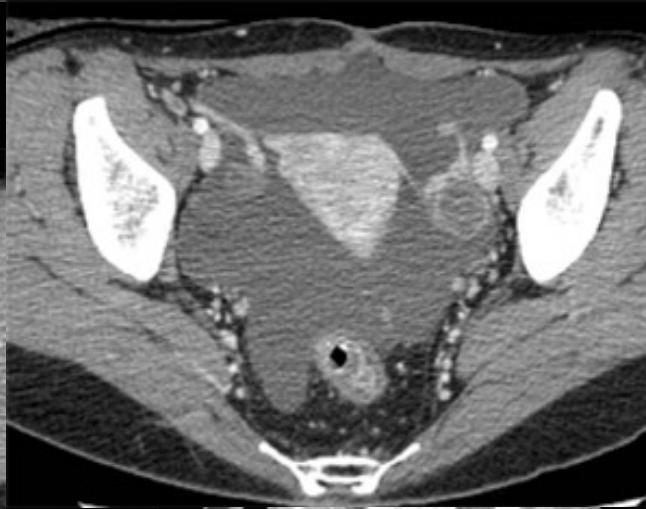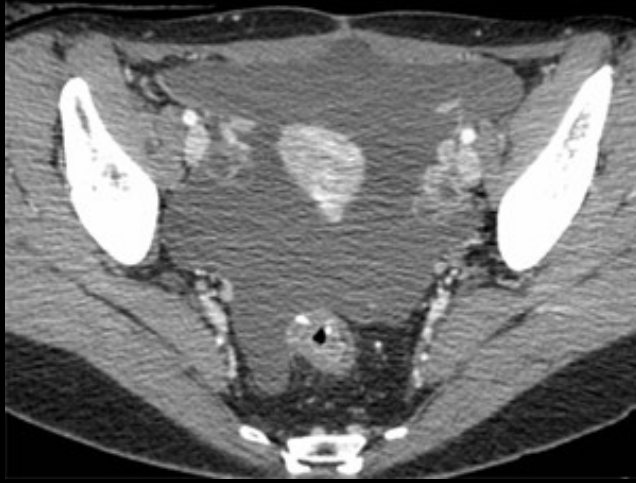


kyste péritonéal d'inclusion
mésothéliome kystique péritonéal

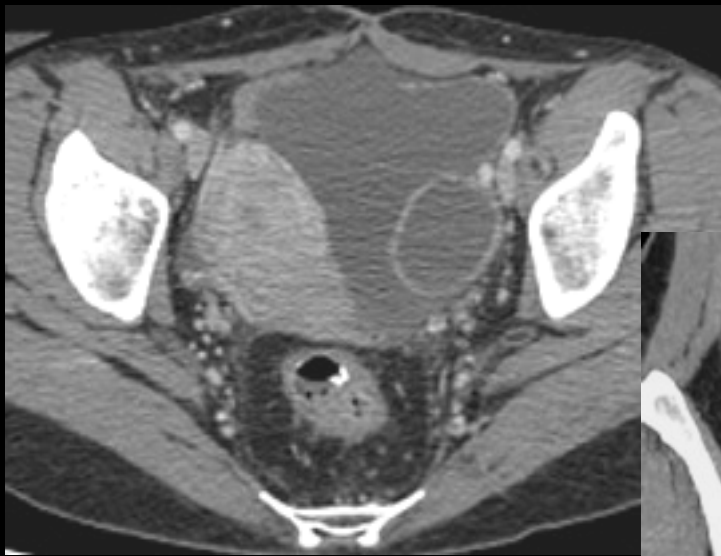

kyste péritonéal d'inclusion (mésothéliome kystique bénin)

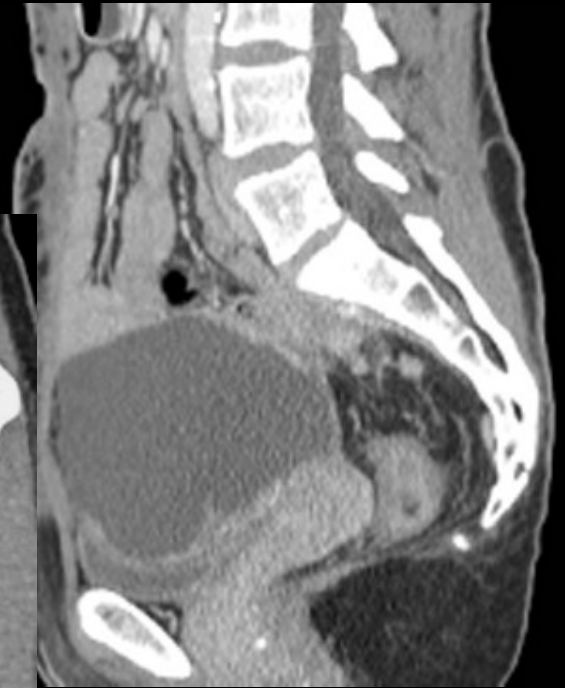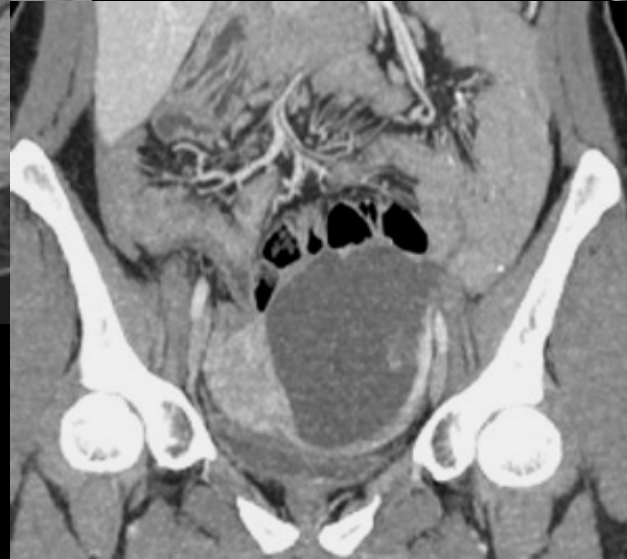femme 36 ans, ATCD colectomie totale Crohn puis sepsis nécessitant 2 interventions (fistule , péritonite)



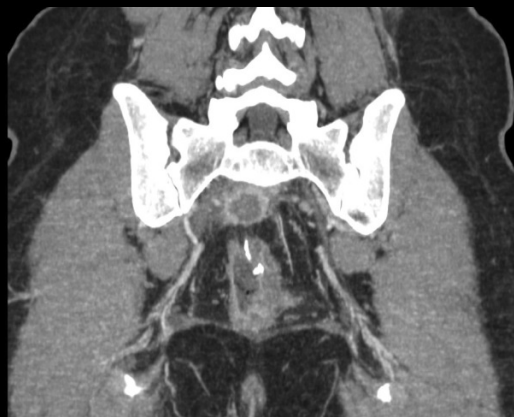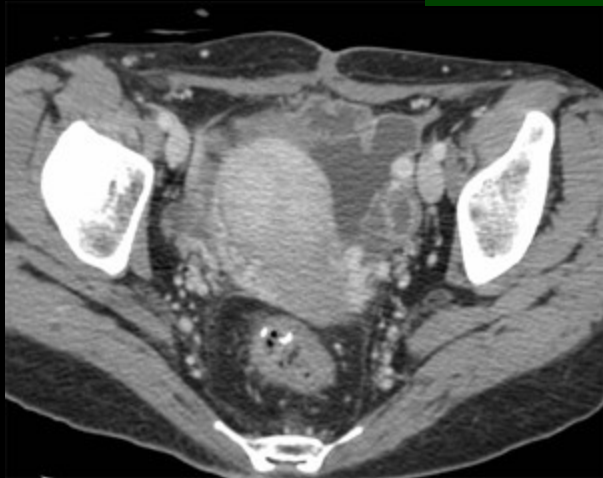
bilan 2007



bilan 2006

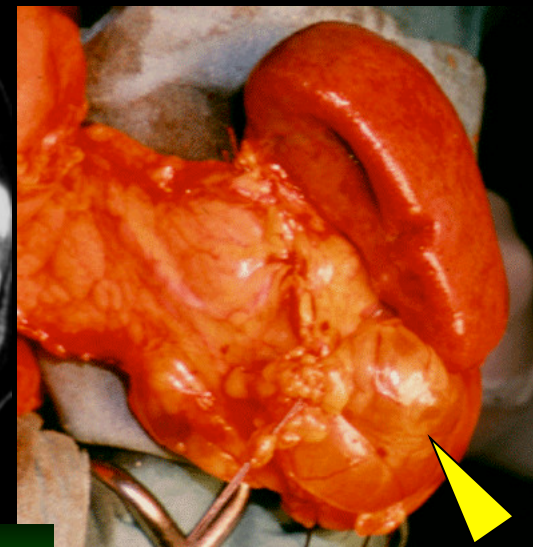
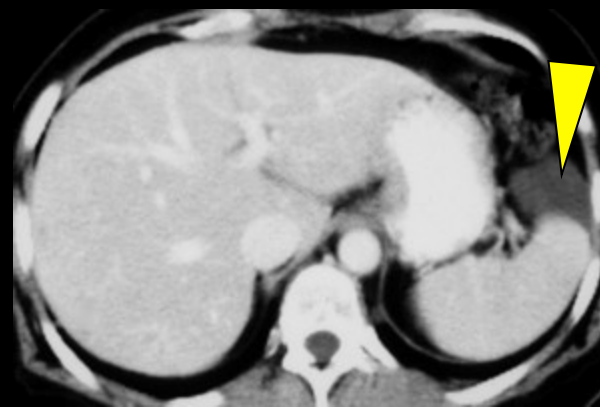
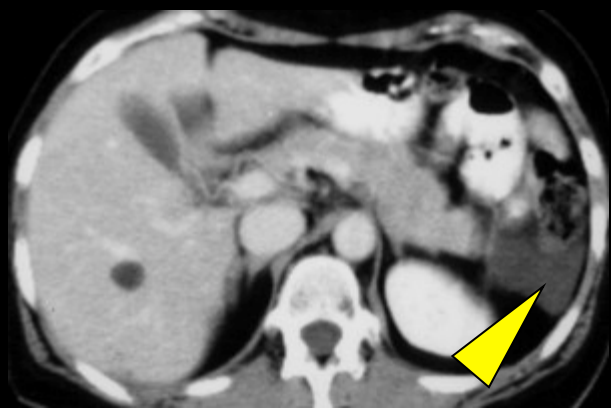
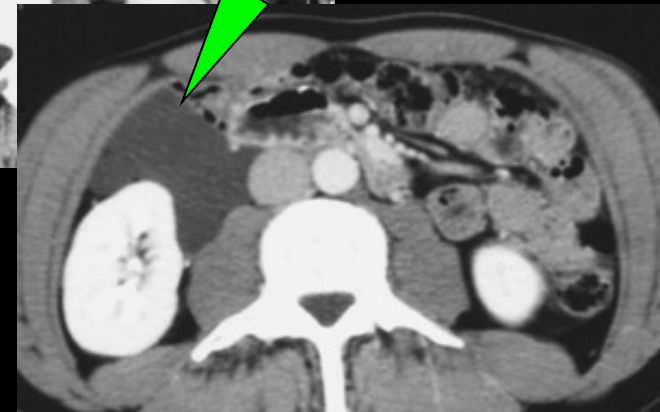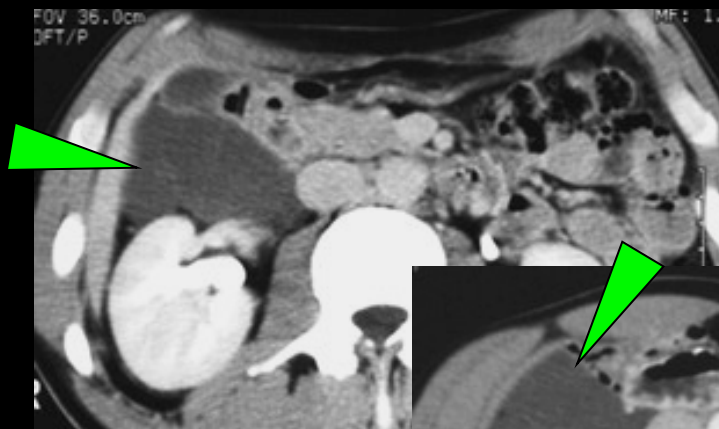
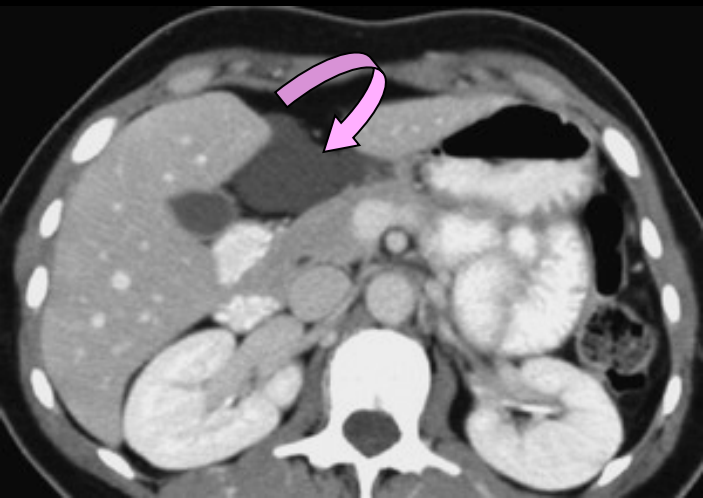


kyste d'inclusion péritonéal (peritoneal inclusion cyst)

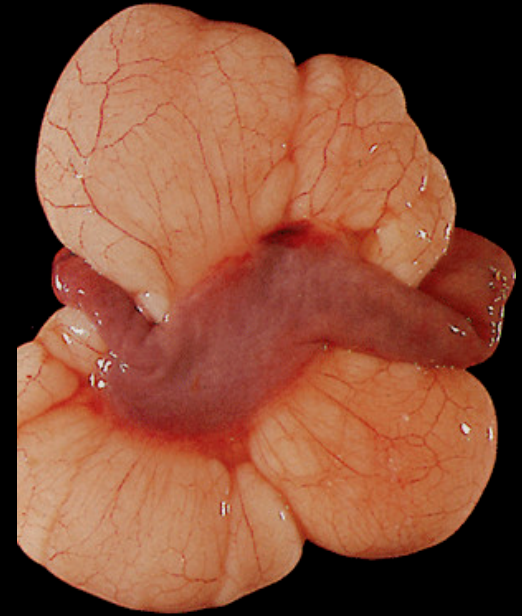
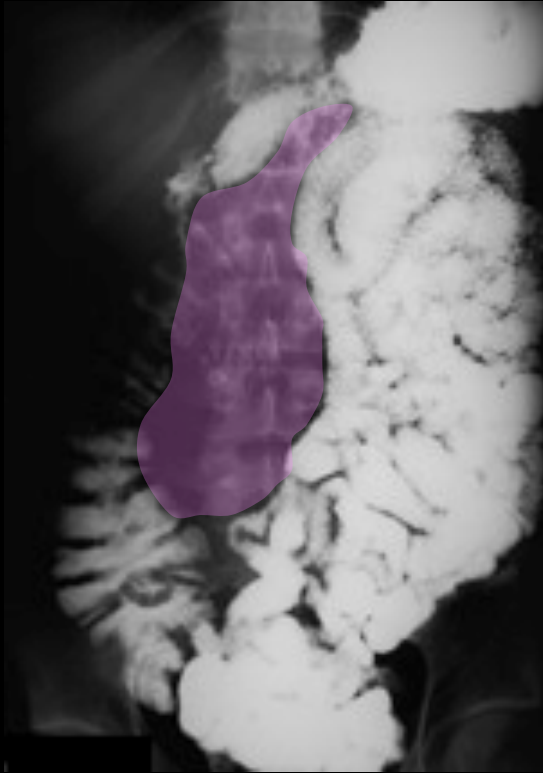
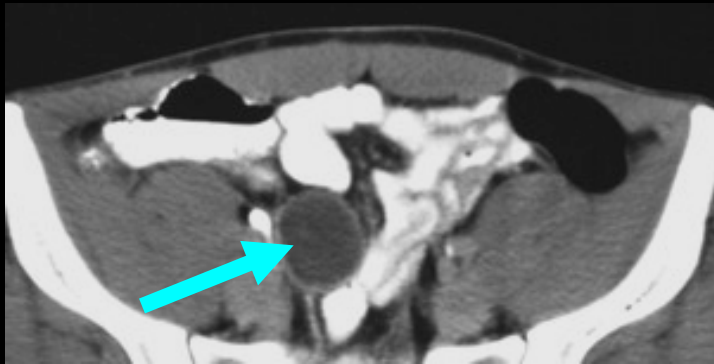
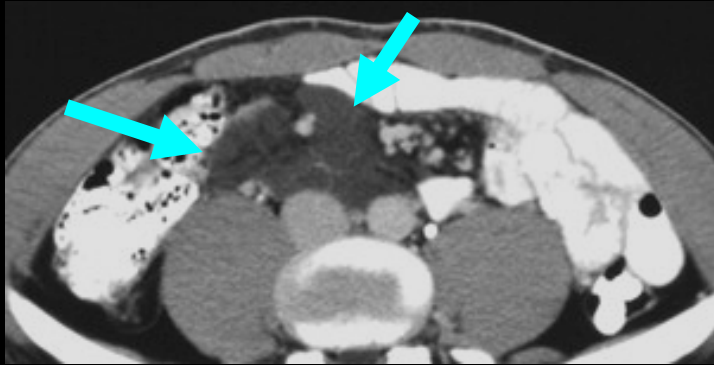
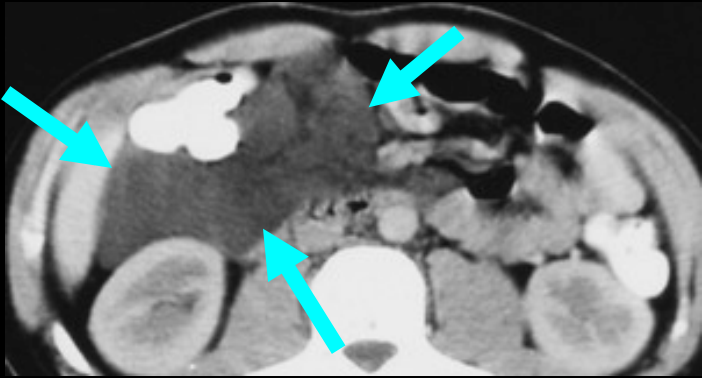


ATCD chir pelvienne

bilan 2005

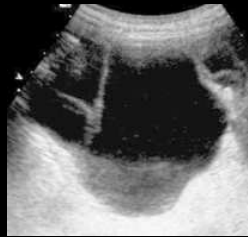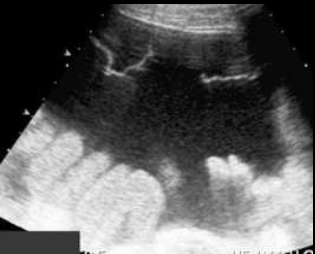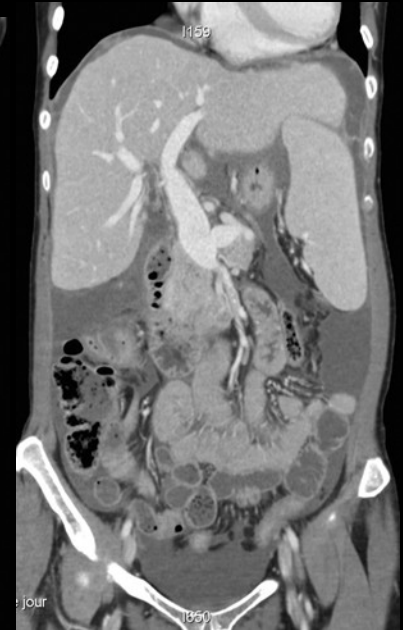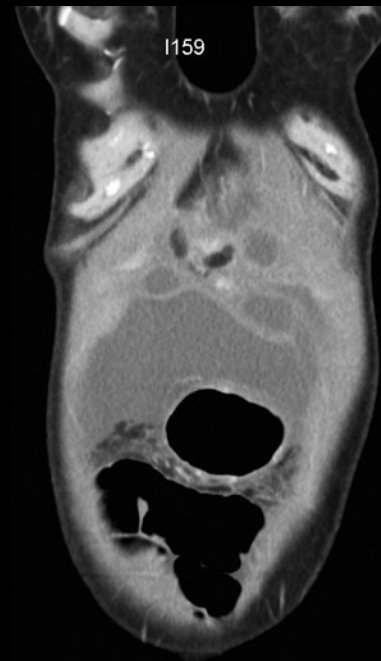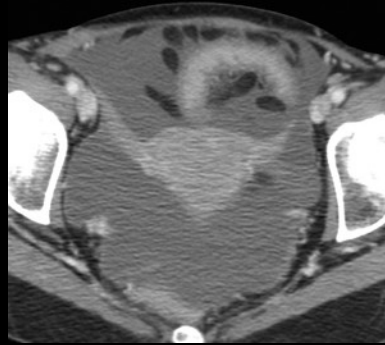
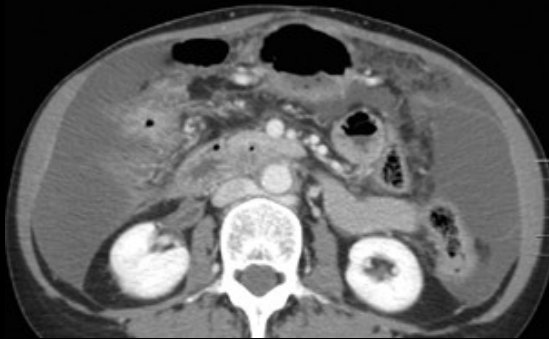
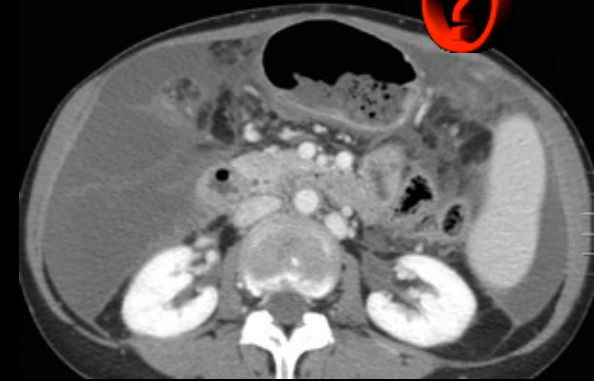


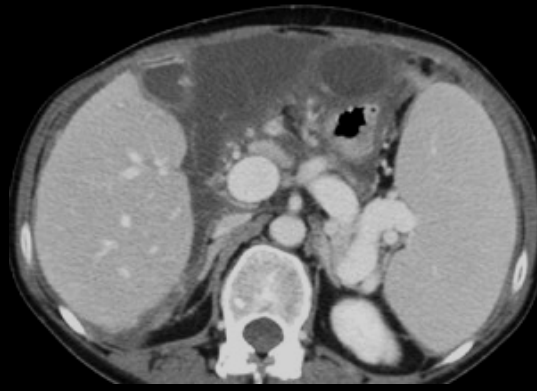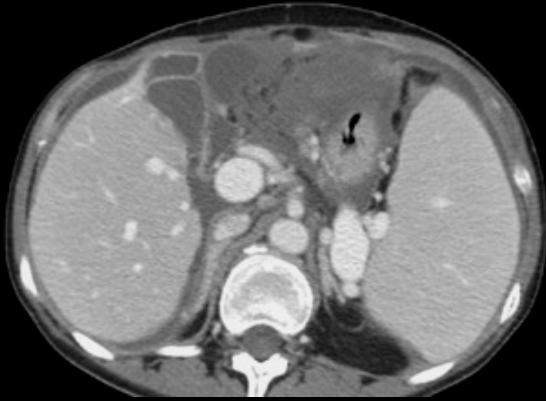lymphangiomes kystiques péritonéaux



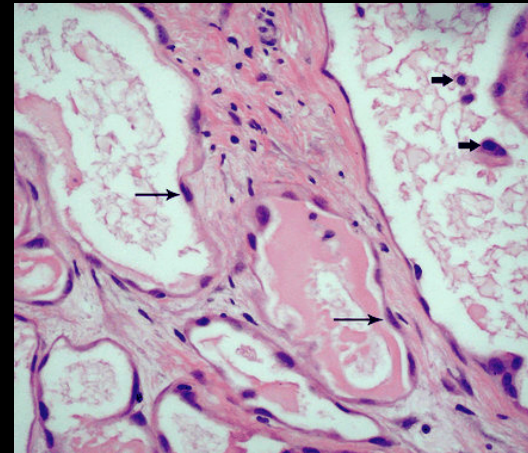
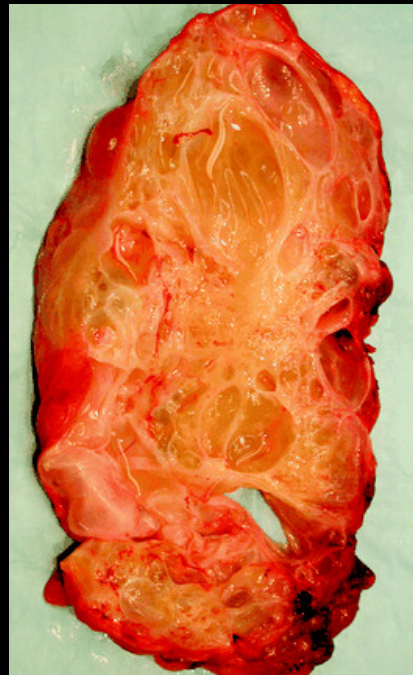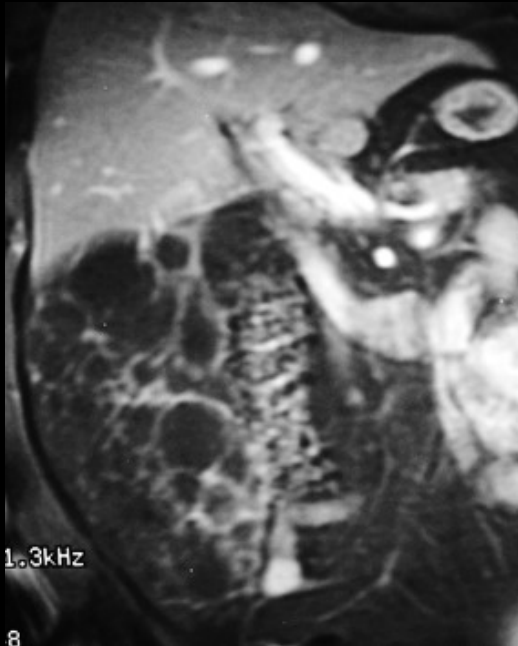
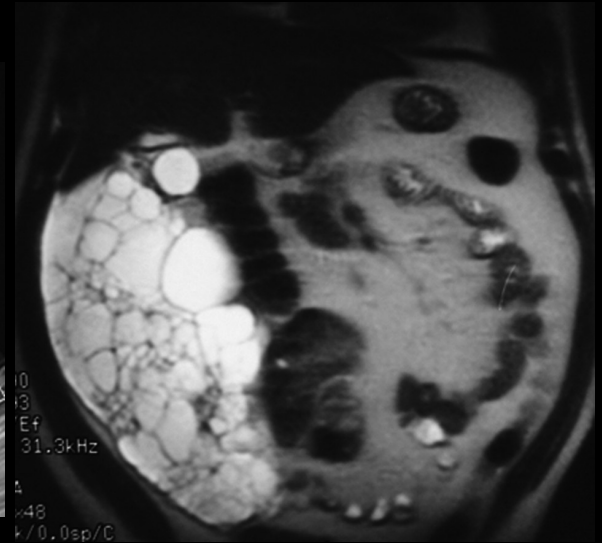
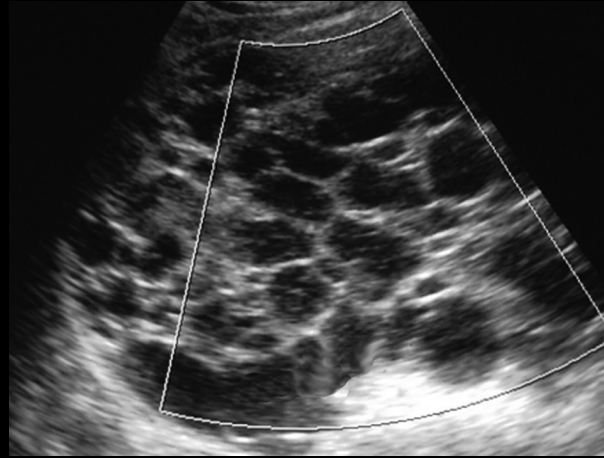
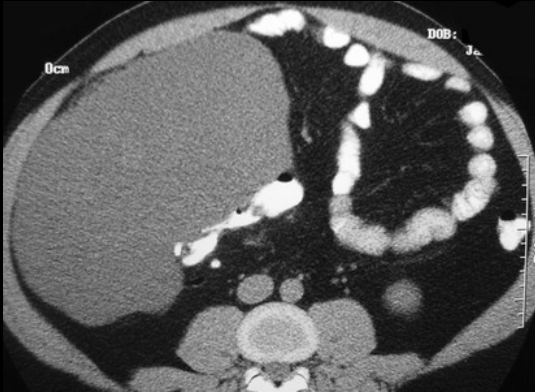récidive d'un lymphangiome
kystique (rétro-)péritonéal

femme 49 ans ; "ascite" chronique . traitement anti tuberculeux pendant un an inefficace ; aucun argument étiologique



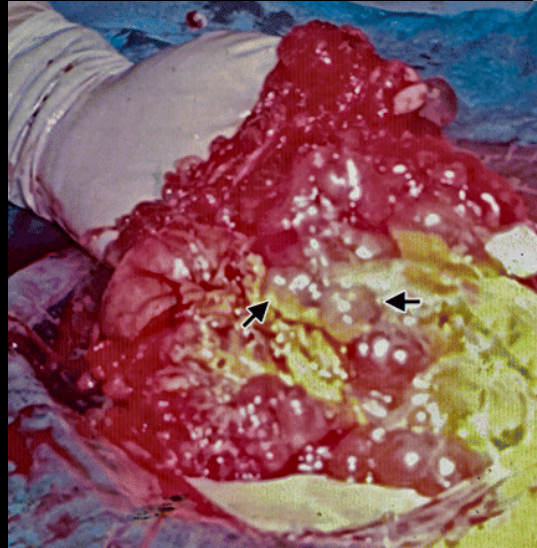
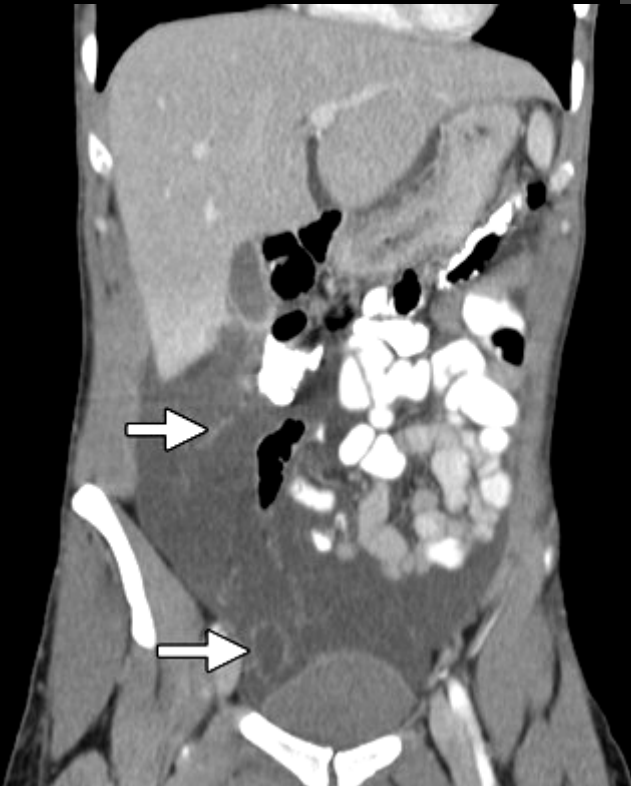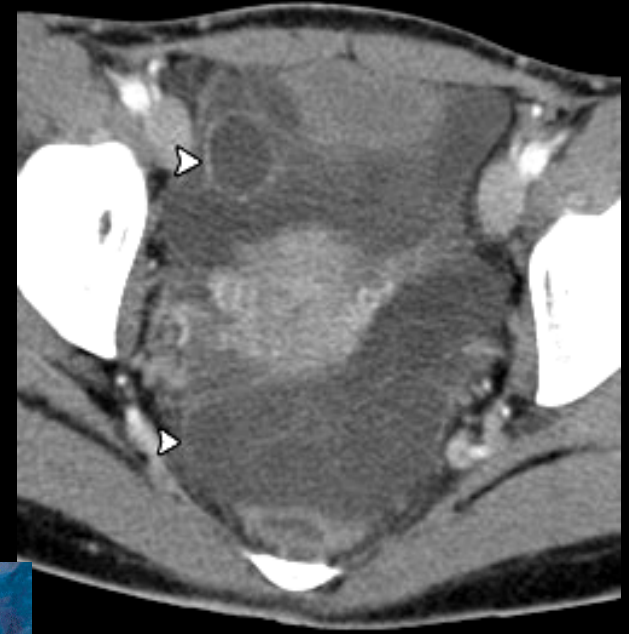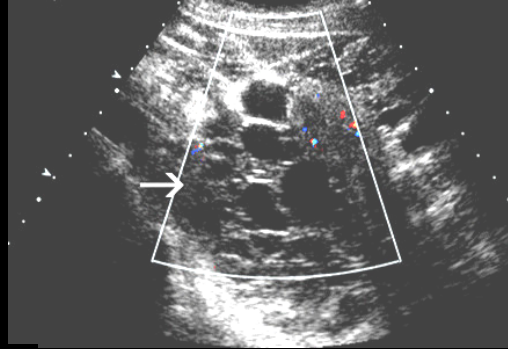
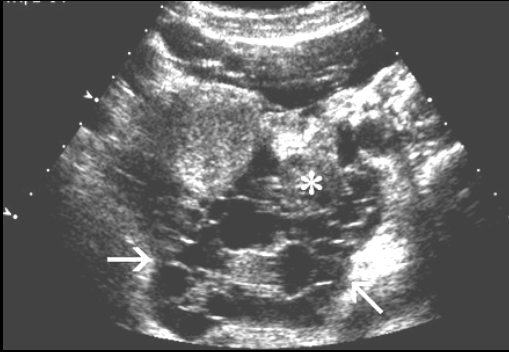
mésothéliome multikystique
(syn : kyste péritonéal d'inclusion multiloculaire, mésothéliome kystique)

homme 34 ans vagues douleurs abdominales



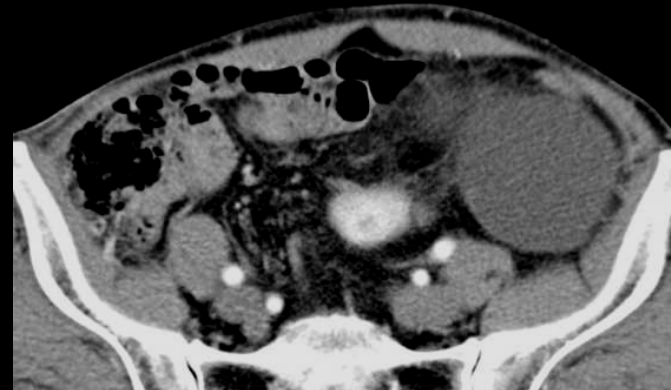
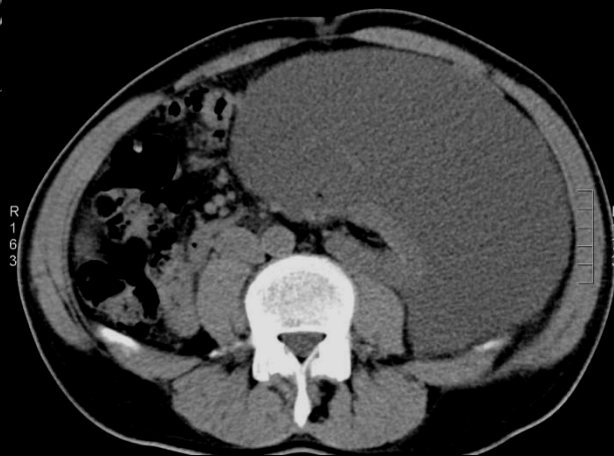
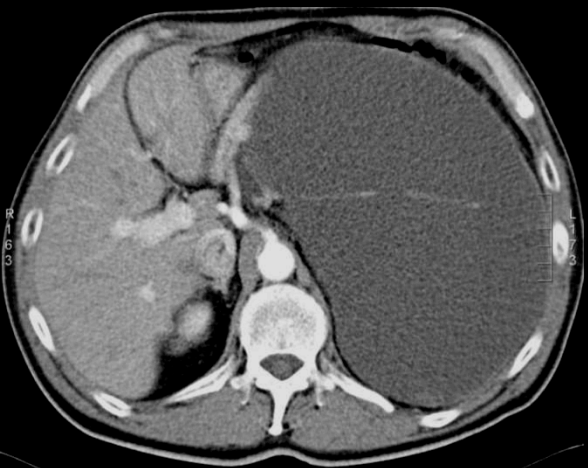
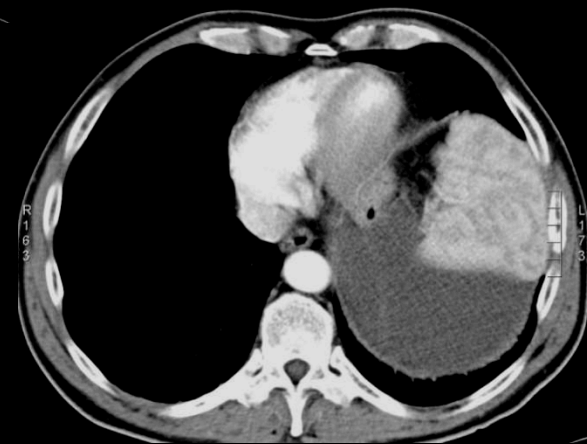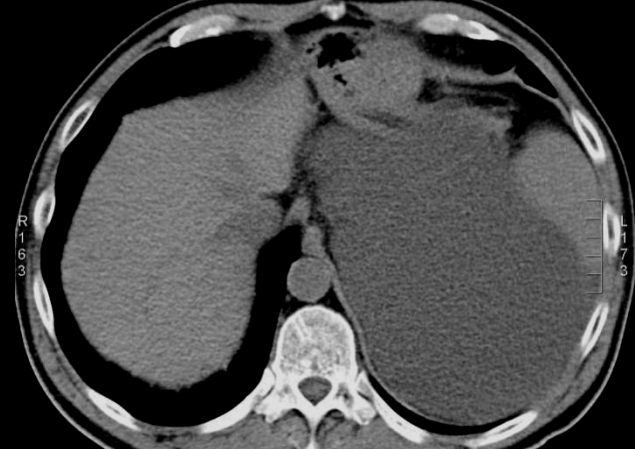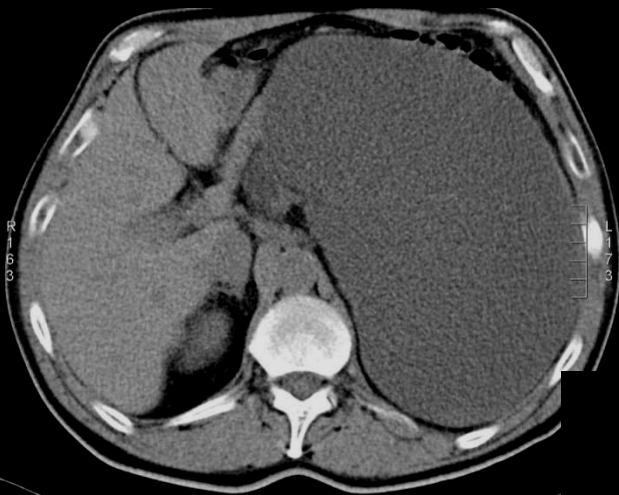le **mésothéliome multikystique** du péritoine pourrait correspondre à une prolifération mésothéliale non tumorale, plutôt qu'à une véritable néoplasie

femme 27 ans , 1 pare , antécédents d'infetions génitales

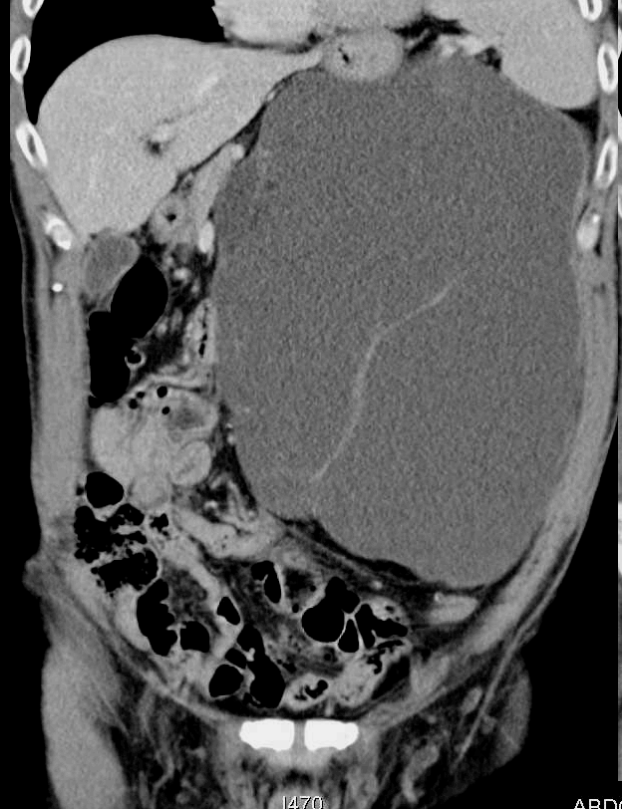

mésothéliome multikystique
(syn : kyste péritonéal d'inclusion
multiloculaire, mésothéliome kystique)

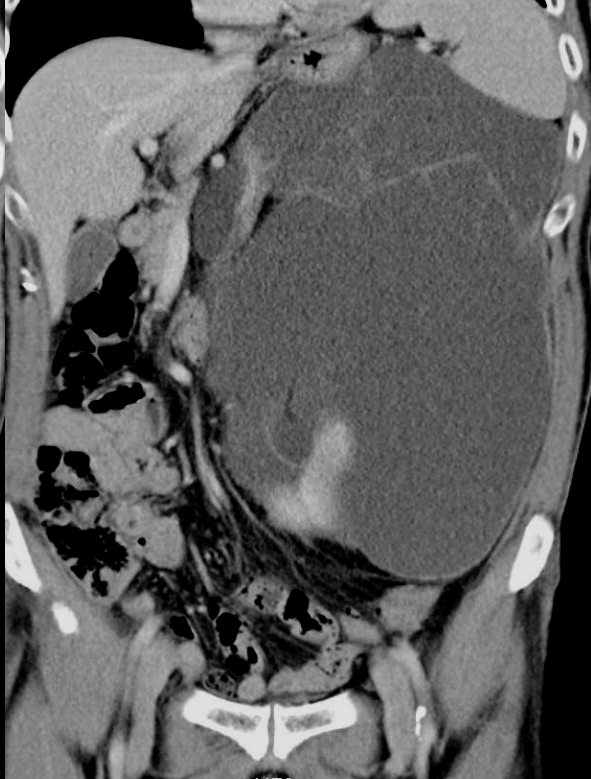homme 60 ans : pas de tabac, pas d' alcool.
ATCD : ulcère gastrique sous AINS
motif : pesanteur et douleur abdominale.
pas d'AEG en dehors anorexie.



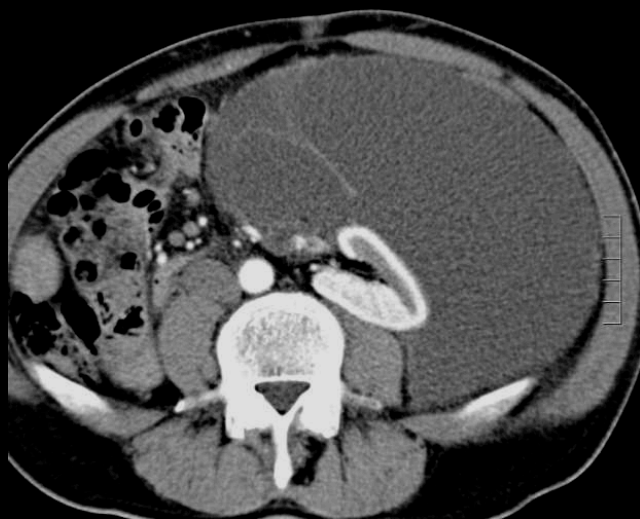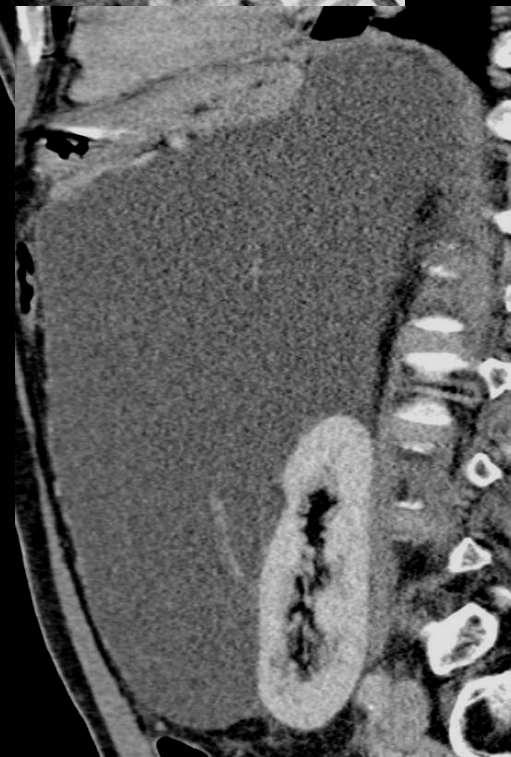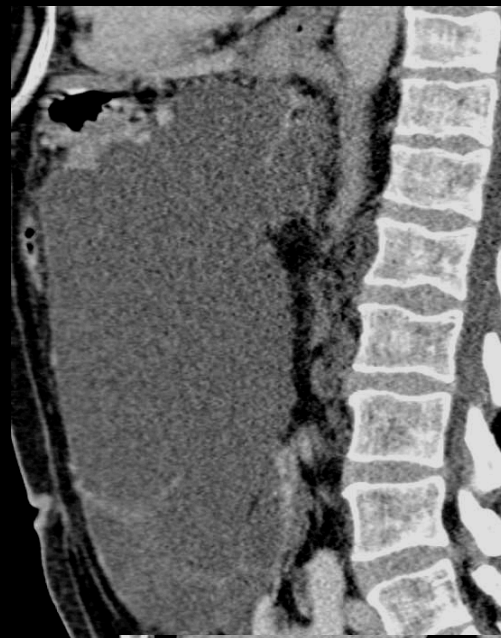13/10/2008



1470

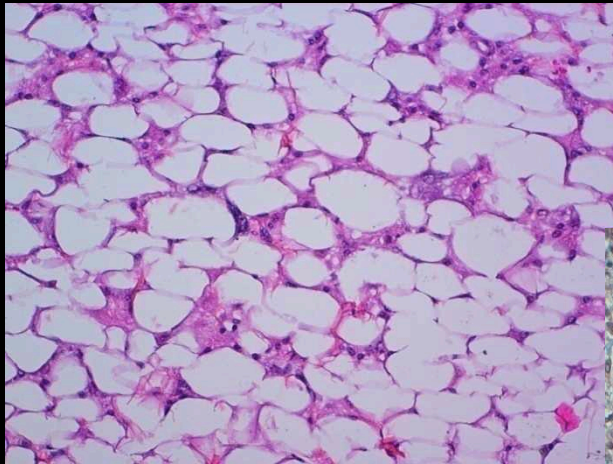


ARDC

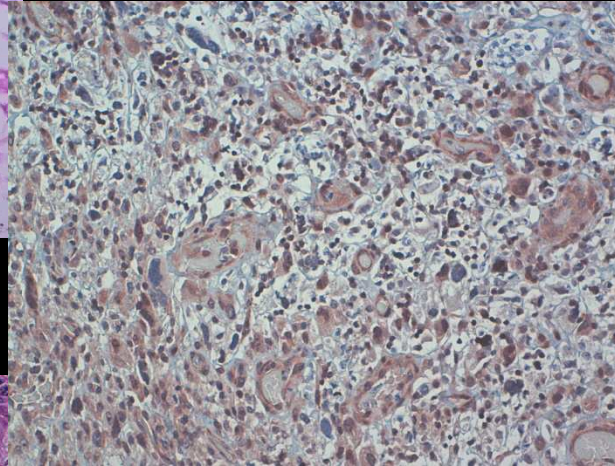


diagnostic (s)



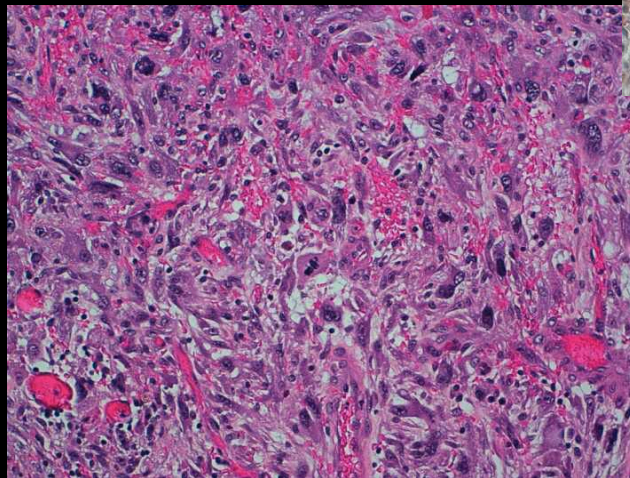


contingent liposarcomateux
bien différencié



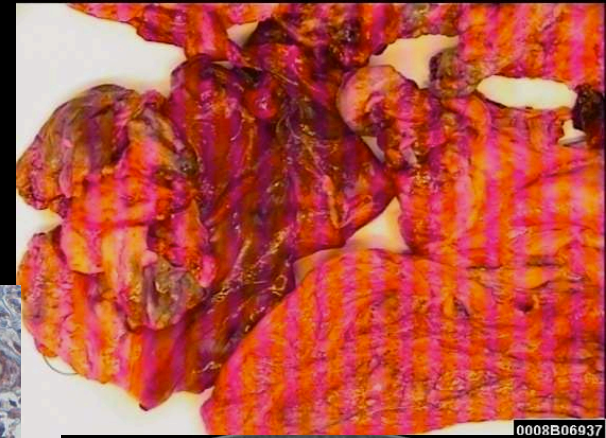expression de MDM2
(protéine modulatrice du gène
suppresseur de tumeur Tp53)

Liposarcome dédifférencié
rétropéritonéal , à expression clinique
abdominale

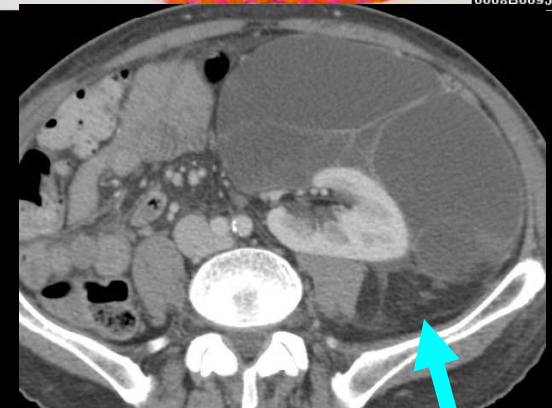


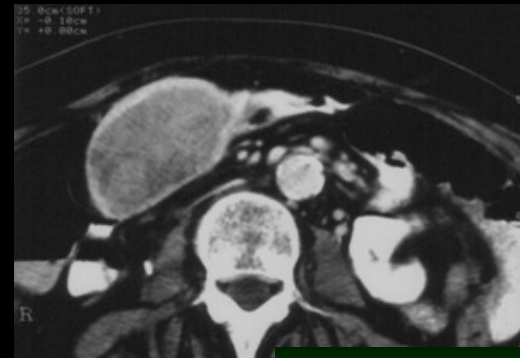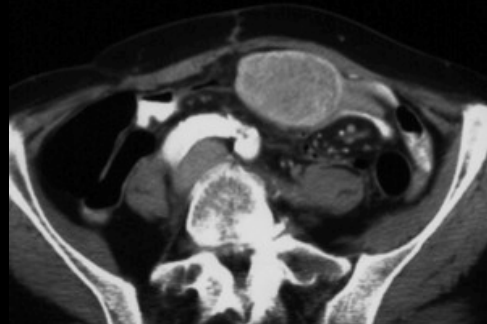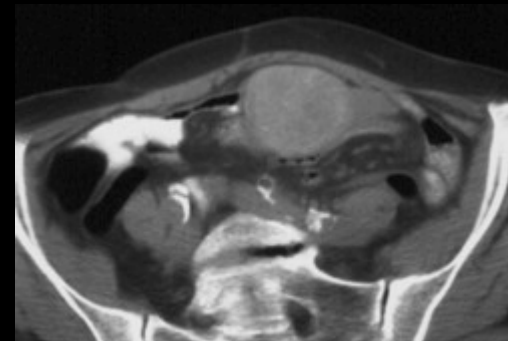
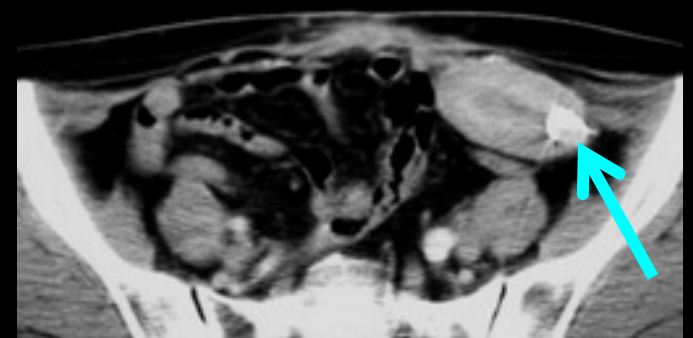
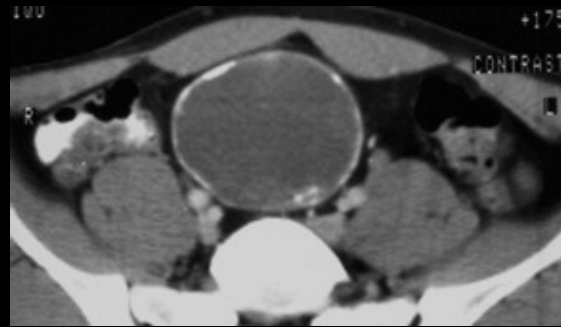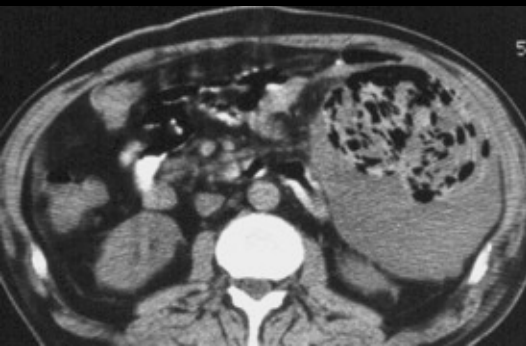
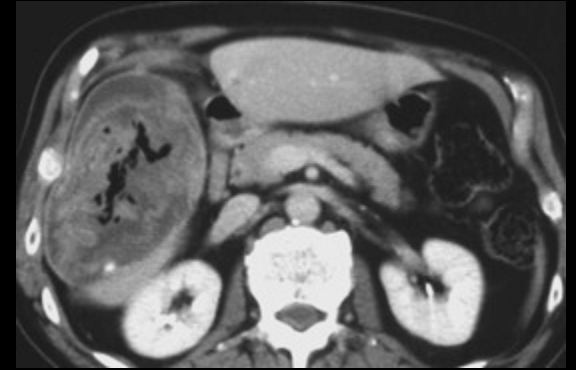
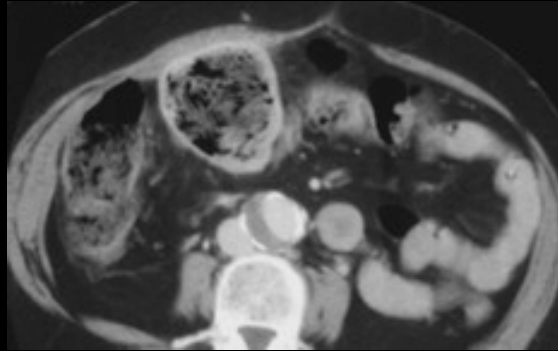
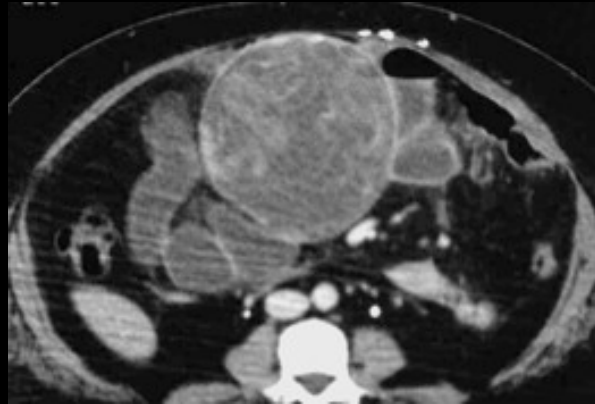
contingent sarcomateux
indifférencié pléomorphe

adulte après 40 ans
tumeurs volumineuses, , localement récidivante et multifocale
envahissent souvent le péritoine et le tube digestif
métastases rares (15%)
liposarcome bien différencié et sarcome non adipeux
amplification de MDM2 et CDK4



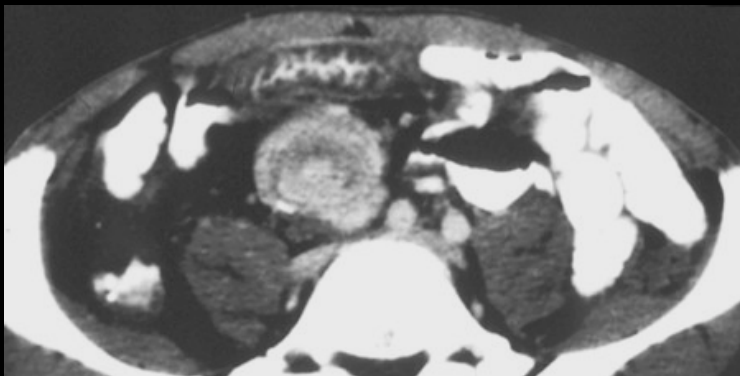
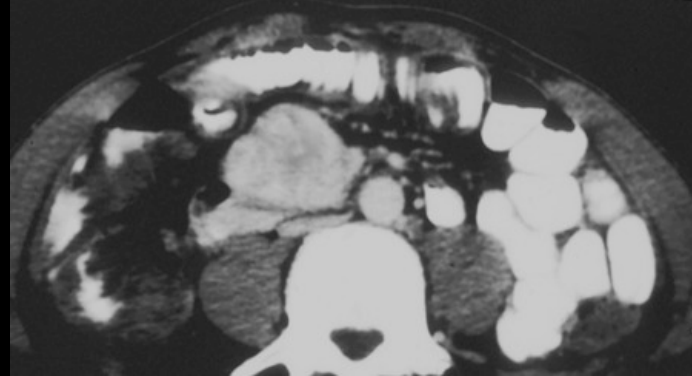
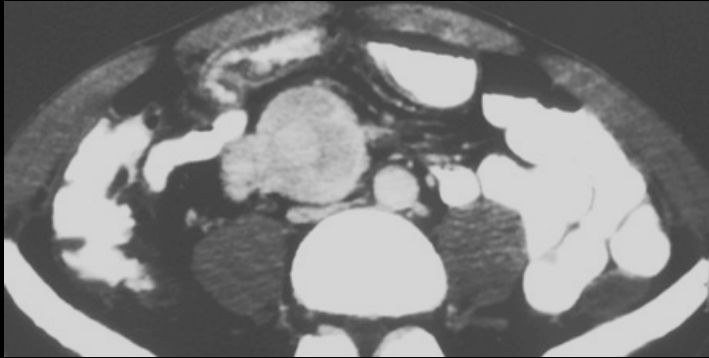
0008B06937





corpus alienum !!!

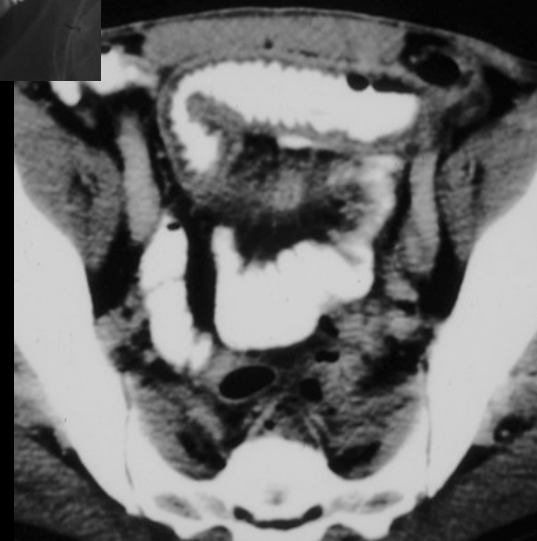
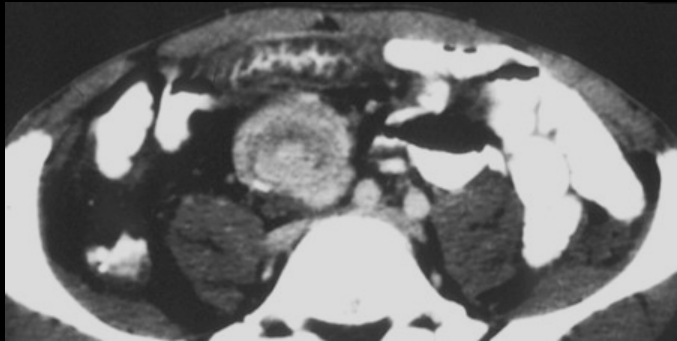
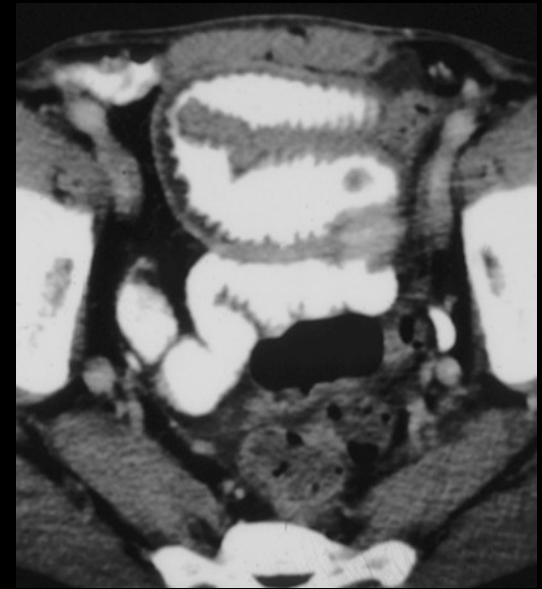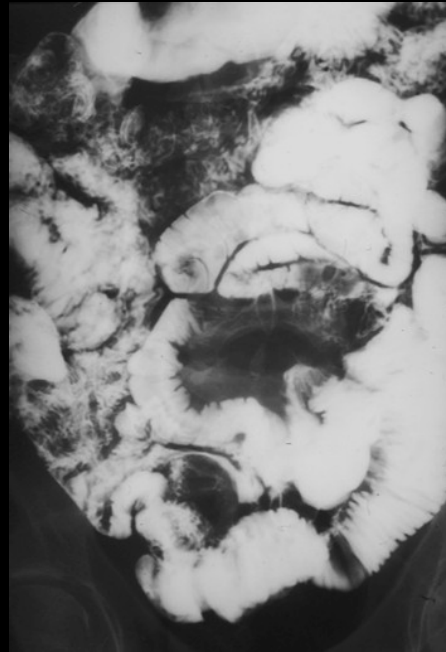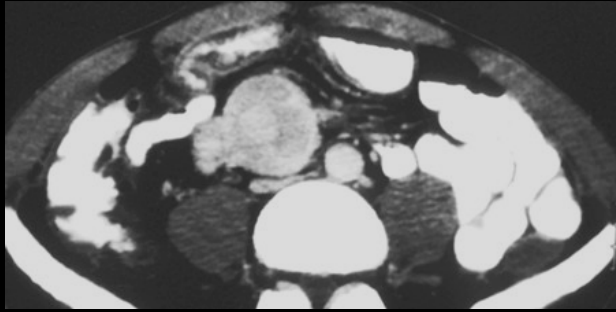
femme 43 ans , douleurs abdominales par crises depuis plusieurs mois ;
quelle est la première hypothèse diagnostique à évoquer **devant toute**
masse du mésentère chez un adulte



Quels sont les principaux caractères
sémiologiques à analyser pour
progresser dans la caractérisation
lésionnelle

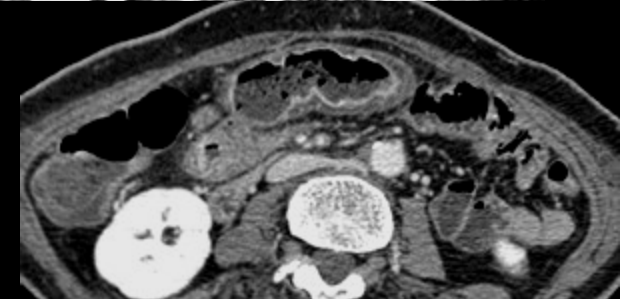
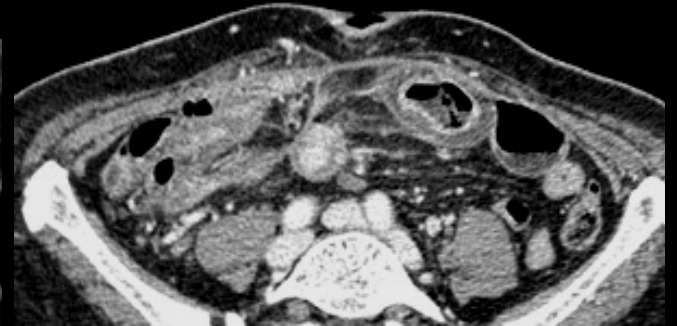
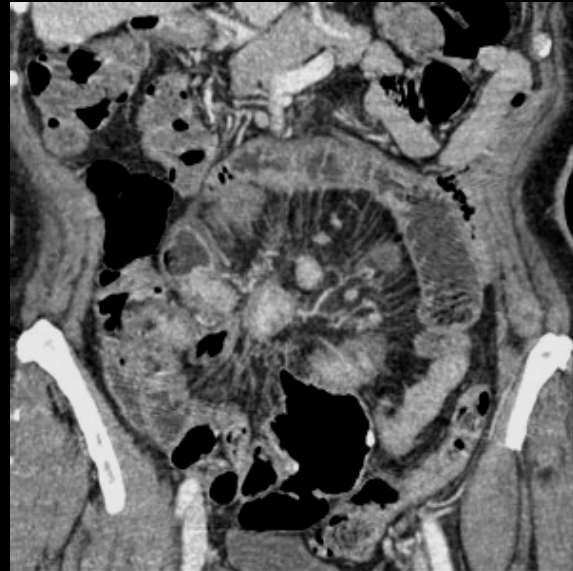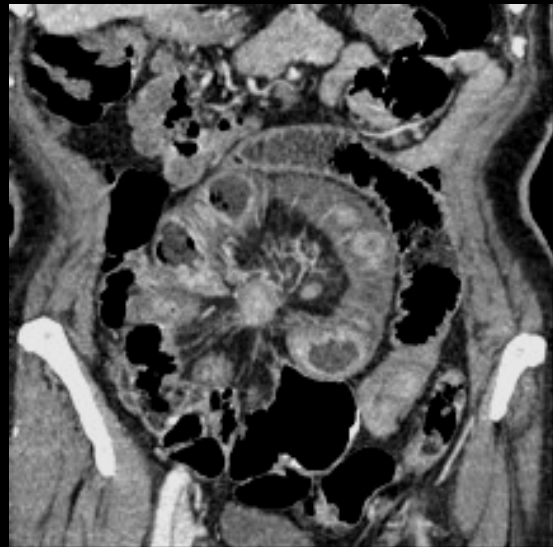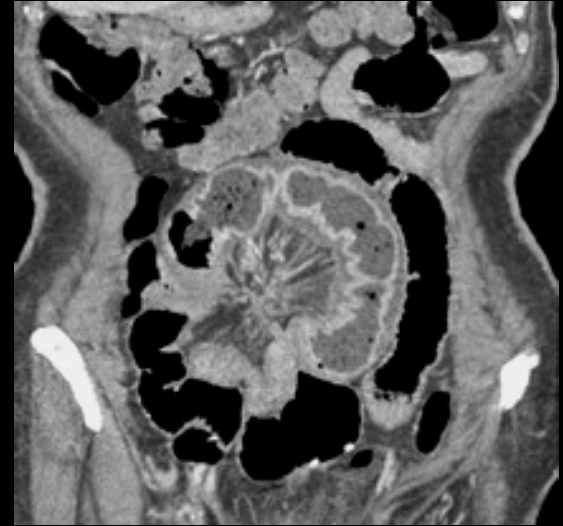
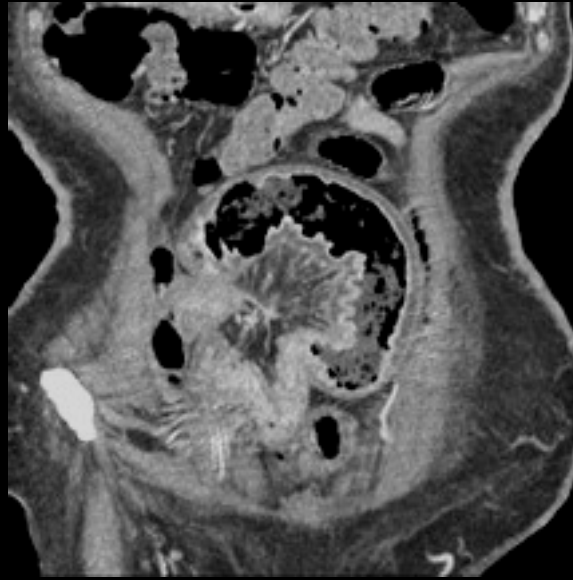
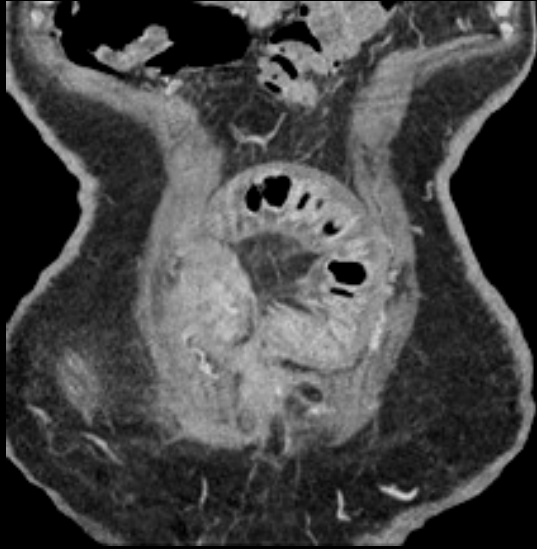


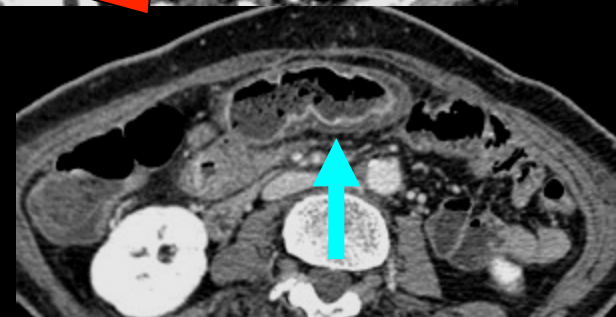
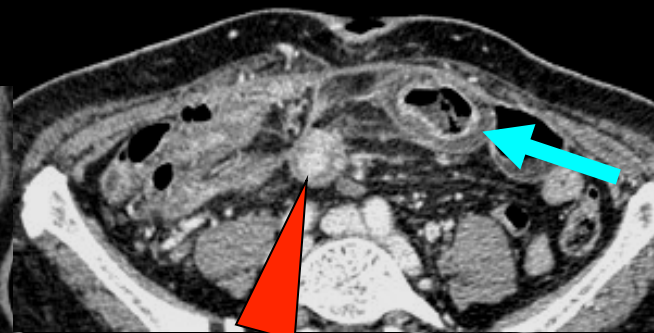
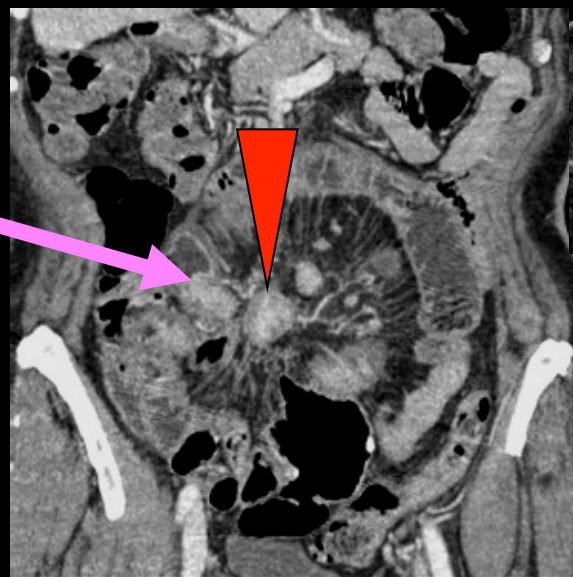
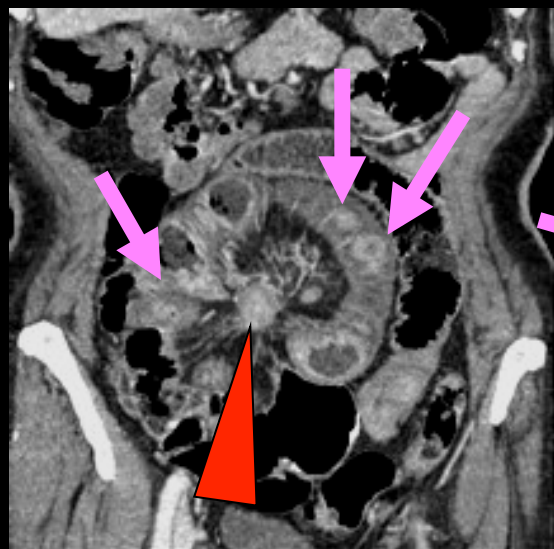
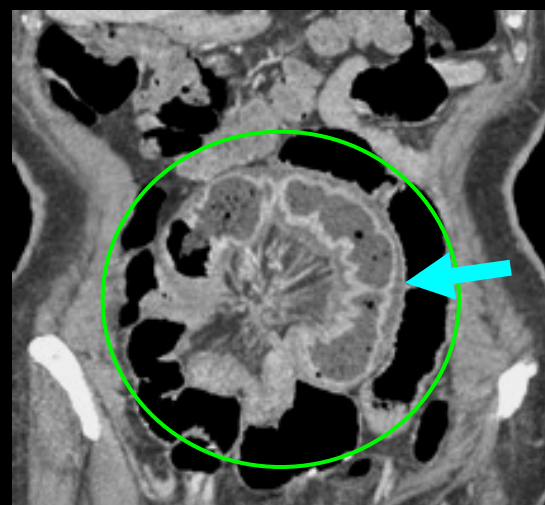
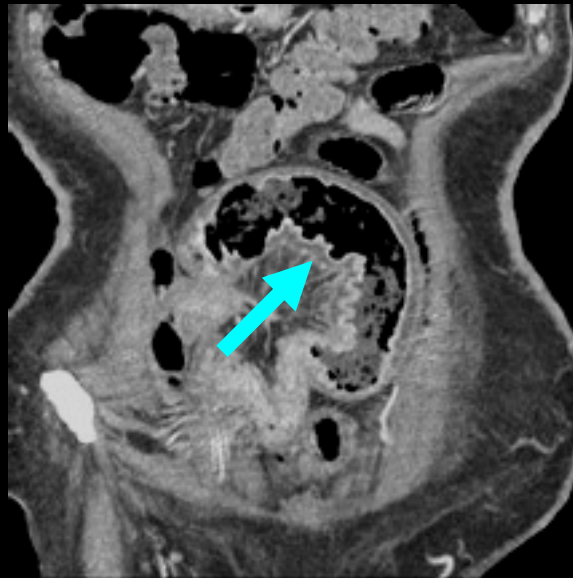
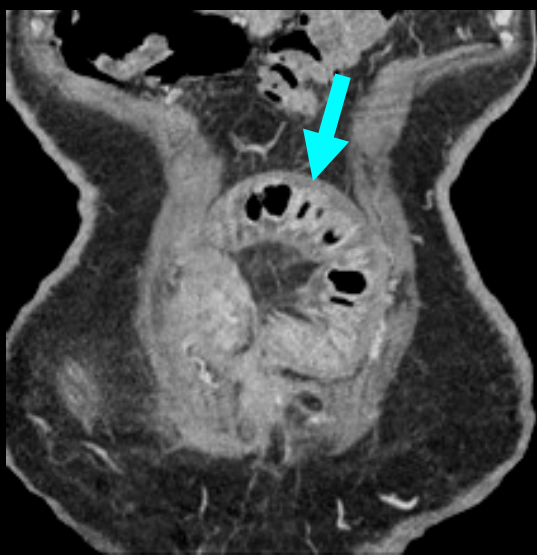
- contours
- rehaussement ; intensité ,homogénéité
- anomalies du mésentère et des parois des anses de voisinage
- anomalies de calibre des vaisseaux mésentériques



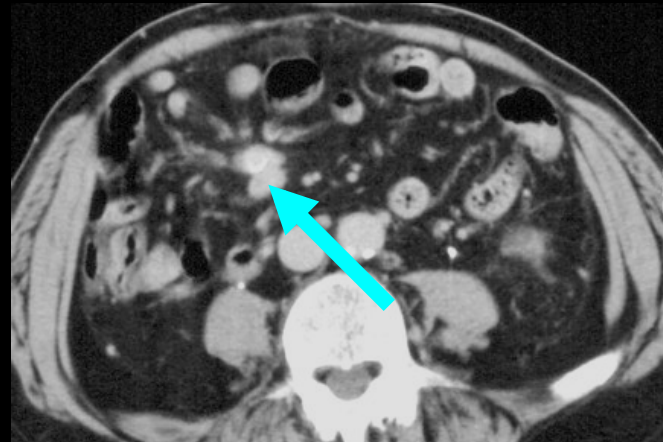
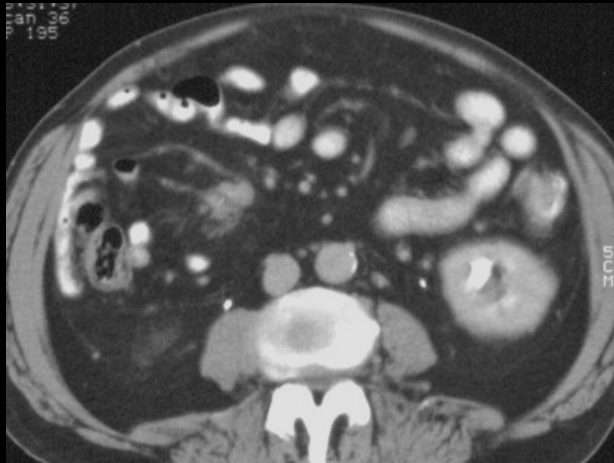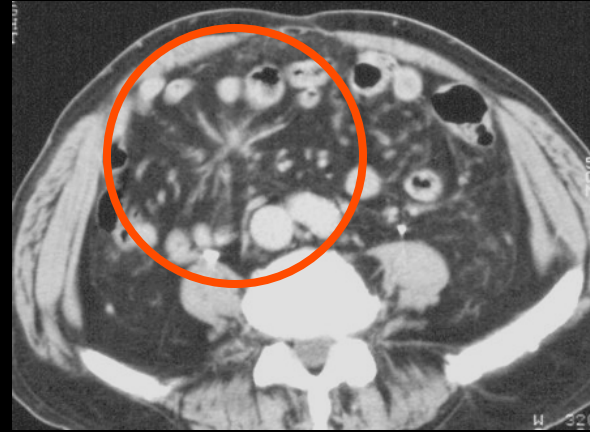
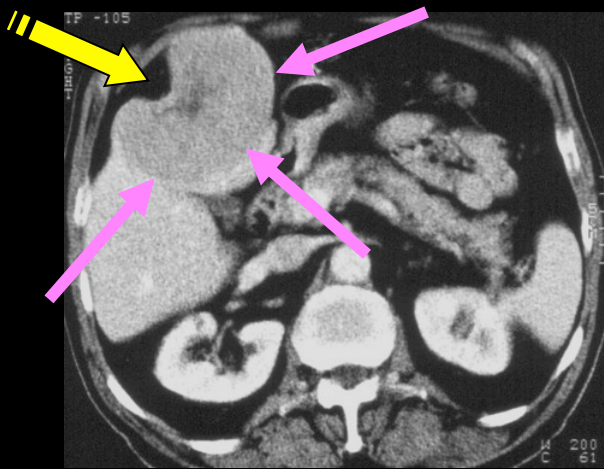
tumeur carcinoïde iléale **sans** mésentérite rétractile **ni spiculations**
signes d'ischémie chronique et/ou lymphangiectasies pariétales

femme 52 ans , douleurs abdominales et diarrhées par crises depuis plusieurs mois ;
quels sont les principaux éléments sémiologiques à décrire

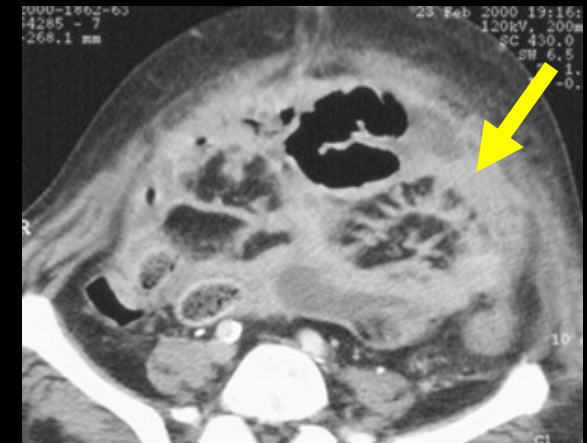
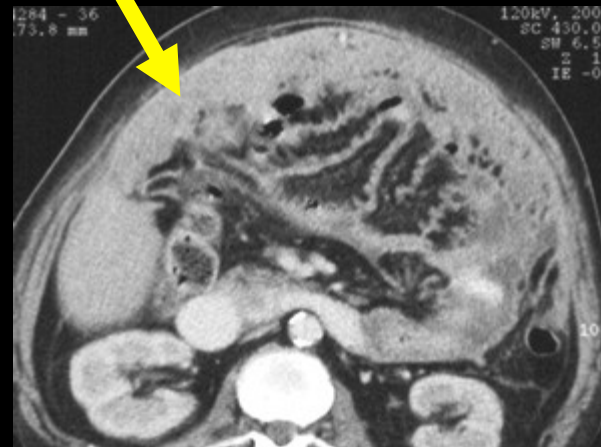
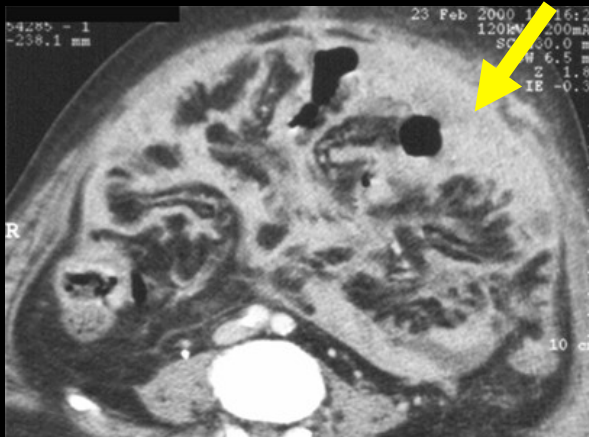
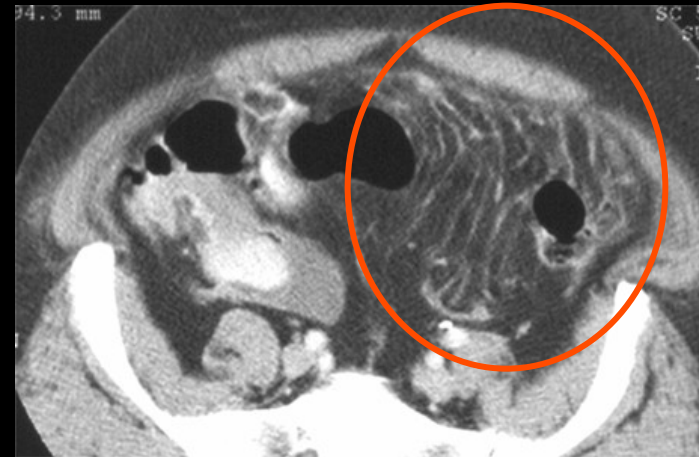
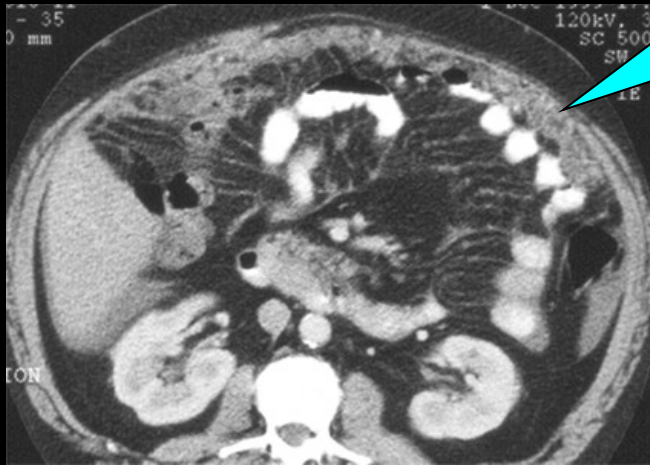




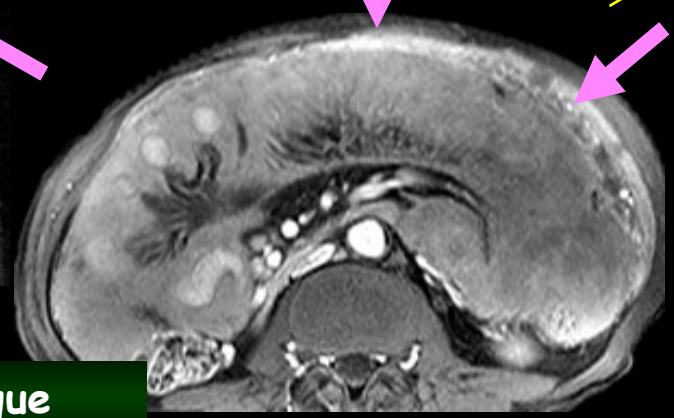
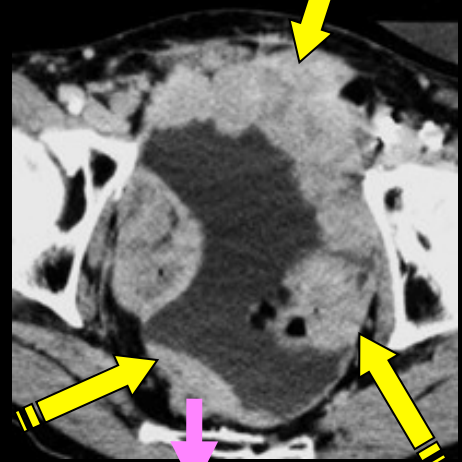
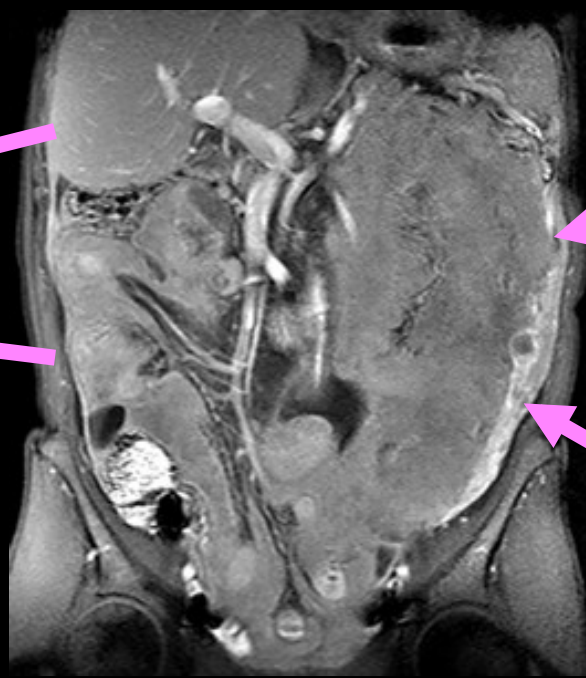
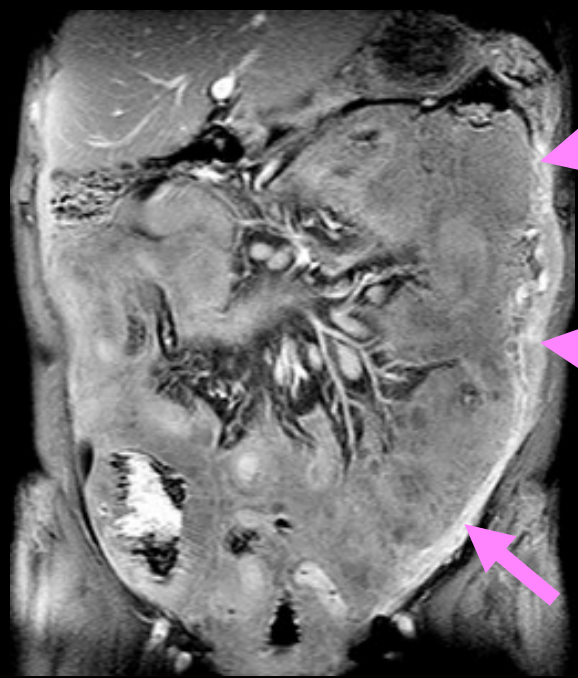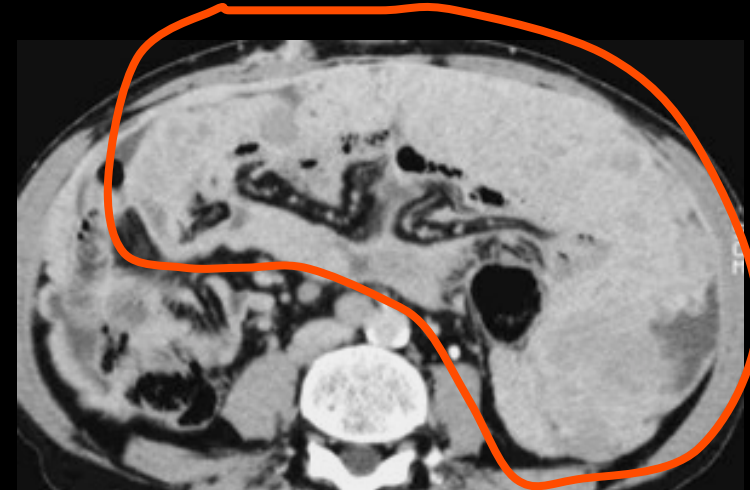
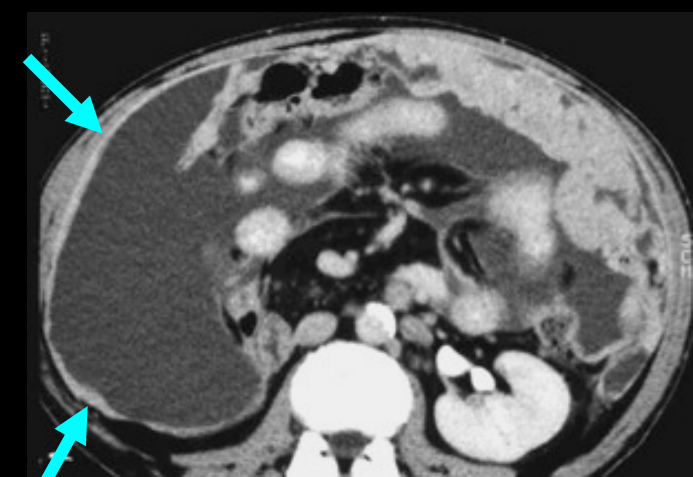tumeurs carcinoïdes iléales et mésentérite rétractile ;
ischémie chronique et/ou lymphangiectasies pariétales



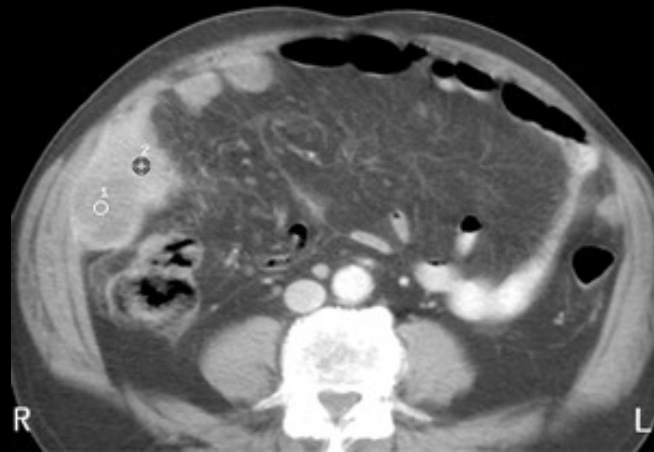
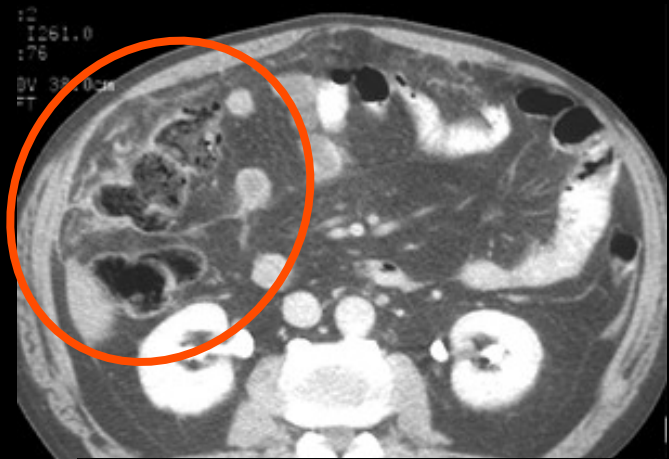
tumeur carcinoïde iléale méconnue sur 3 scanners réalisés en 6 mois ;
diagnostic sur biopsie de la métastase hépatique !!!



mésotéliome péritonéal primitif forme desmoplastique
évolution sur 14 mois ; fibrose collagène +++++

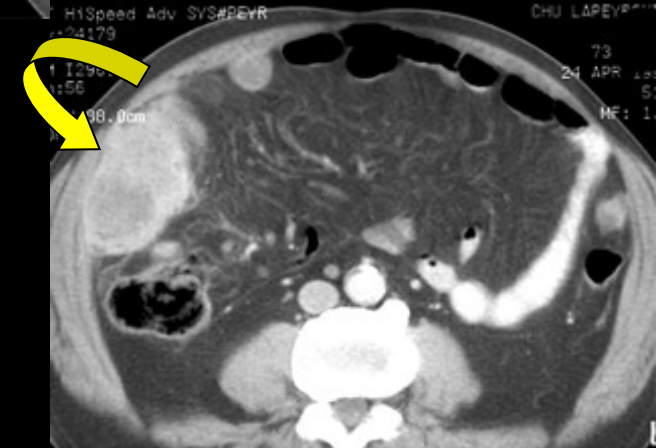

mésothéliome primitif du péritoine ;forme desmoplastique



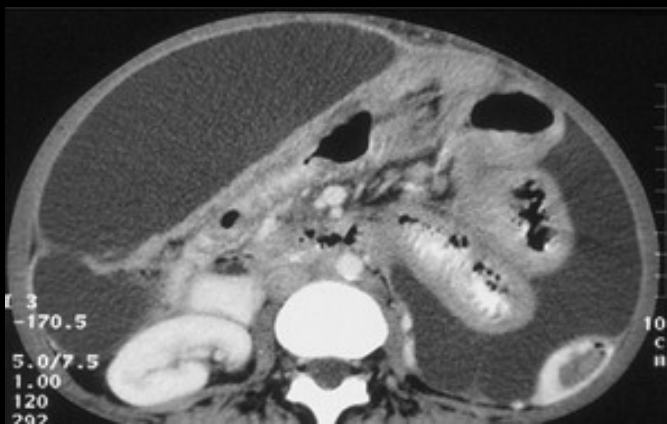mésothéliome primitif du péritoine forme sarcomateuse "sèche" .

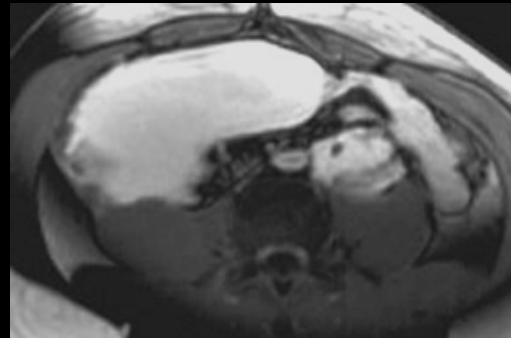
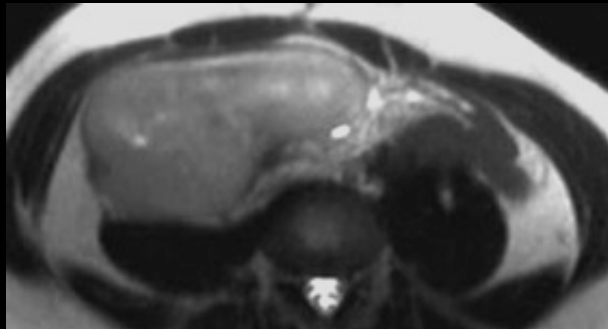
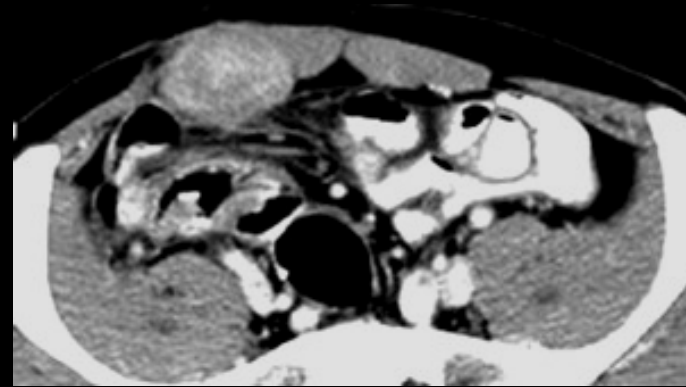
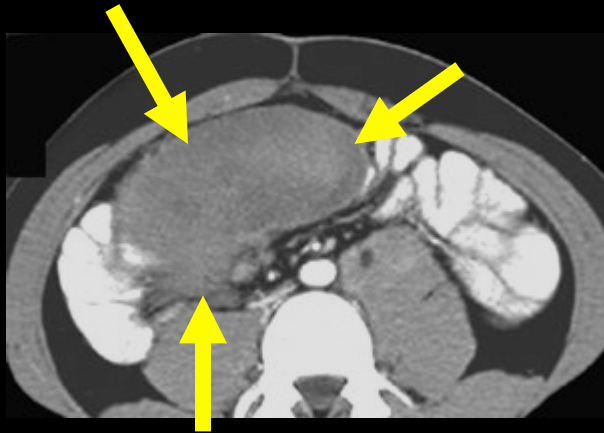obs. P Taurel Montpellier



mésothéliome primitif du péritoine forme pseudo-carcinomateuse , ascitique.

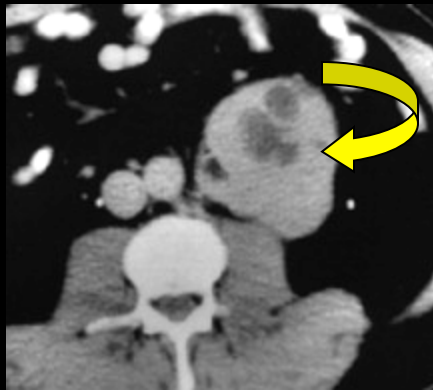
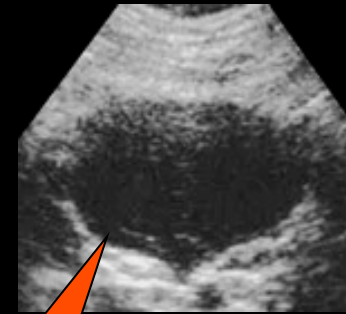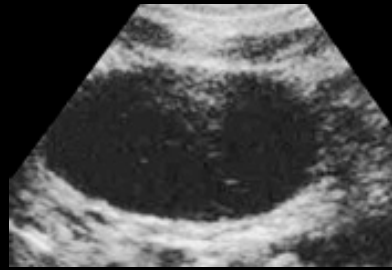
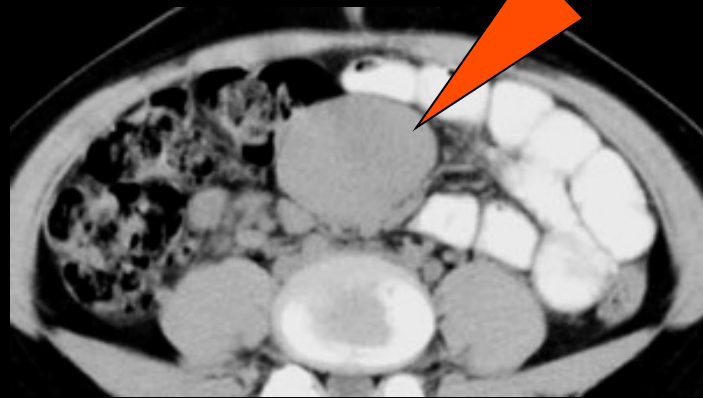
obs. P Taurel Montpellier



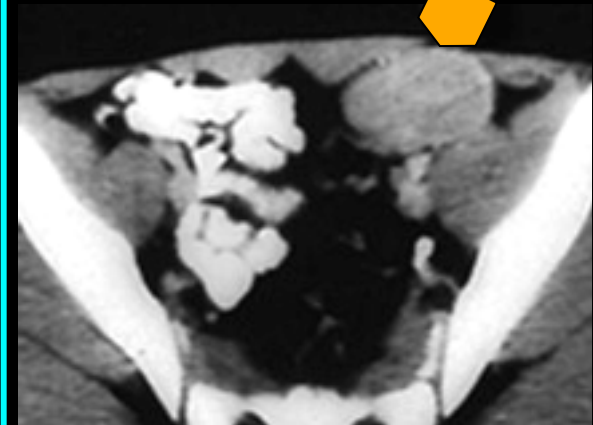
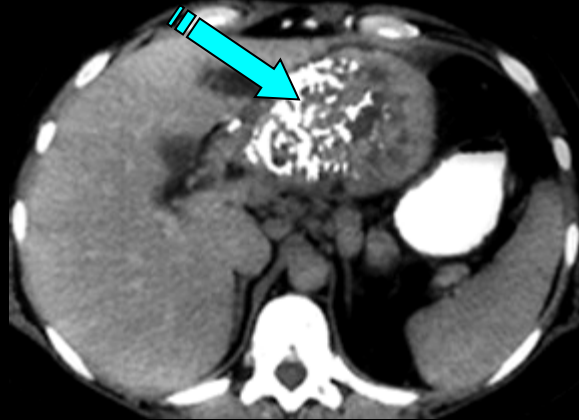


antécédents: colo-proctectomie pour polypose adénomateuse recto-colique familiale

tumeurs desmoïdes ; syndrome de Gardner : polypose adénomateuse recto-colique familiale + ostéomes + tumeurs fibreuses abdominales (pariétales antérieures ; gaine des grands droits) ...

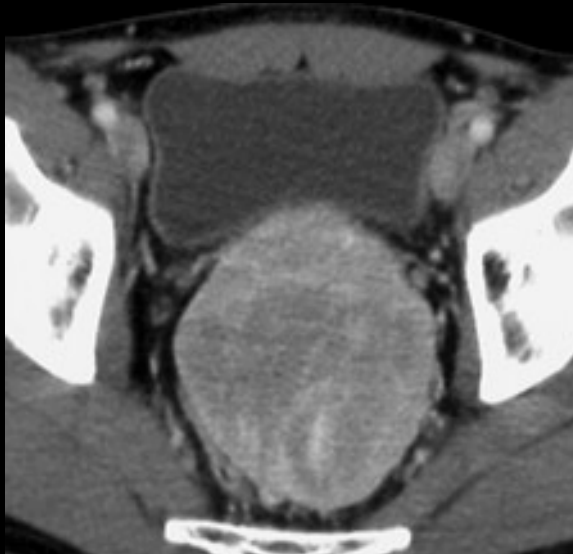
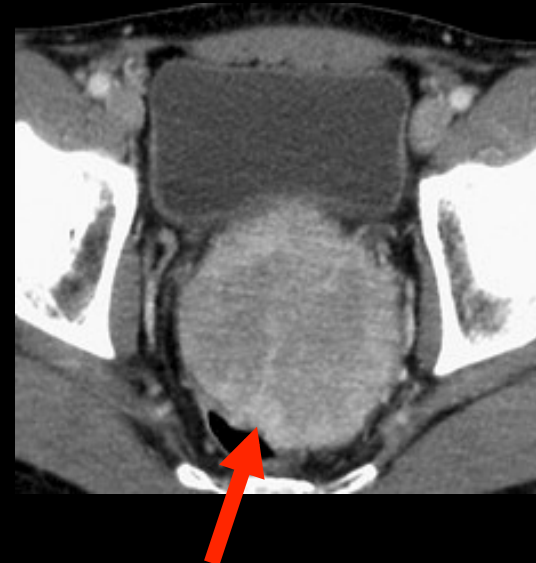
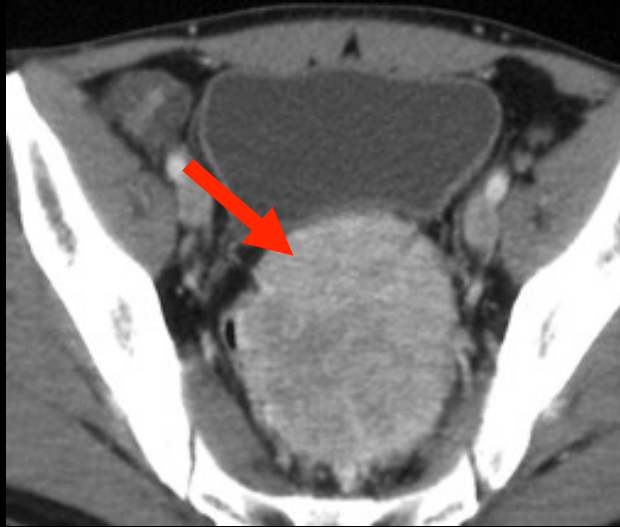rehaussement +++



maladies de Castelman ; formes angio-folliculaires ; sd lympho-prolifératif bénin
≠ forme à cellules plasmocytaires disséminée à potentiel malin : myélome condensant ,
sd POEMS (polyneuropathie, organomégalie, endocrinopathie, protéine
monoclonale, anomalies cutanées...)

22 ans , syndrome douloureux hypogastrique résistant aux antalgiques



tumeurs hypervascularisées du péritoine

T stromales (GIST)

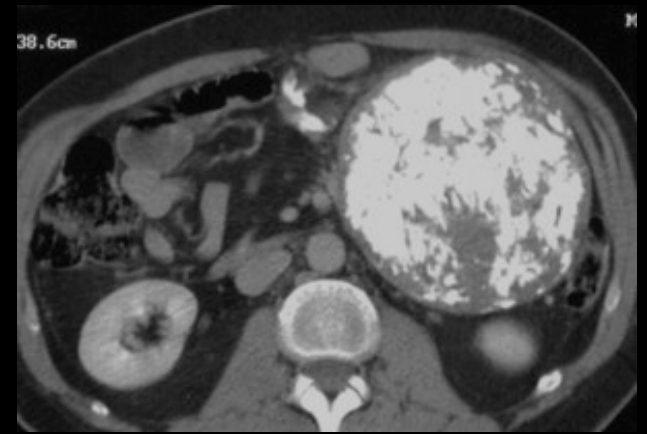
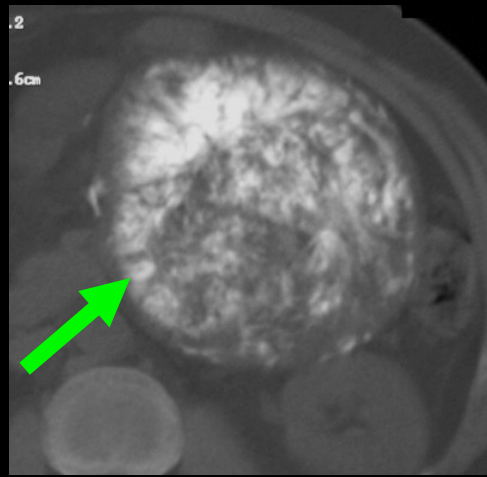
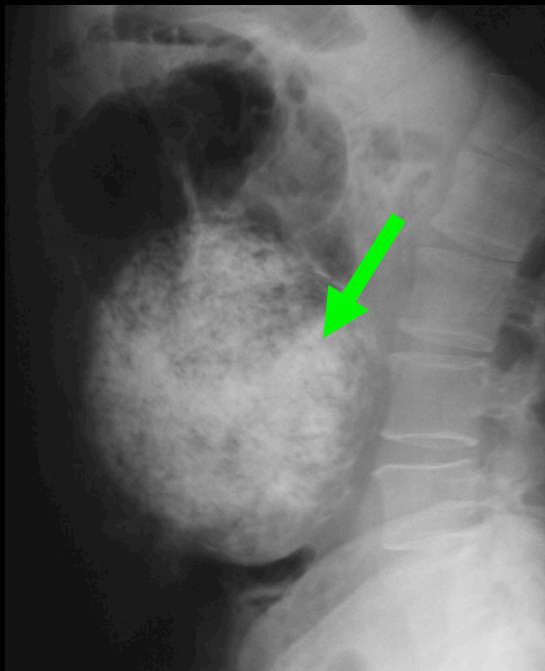
T conjonctives vasculaires

T carcinoïdes

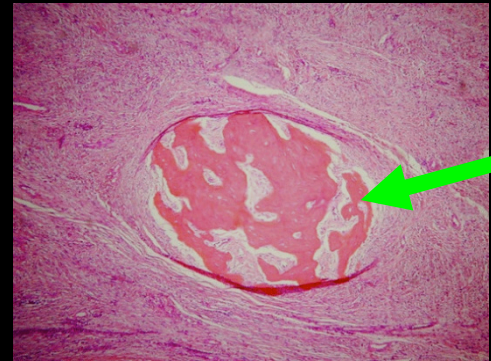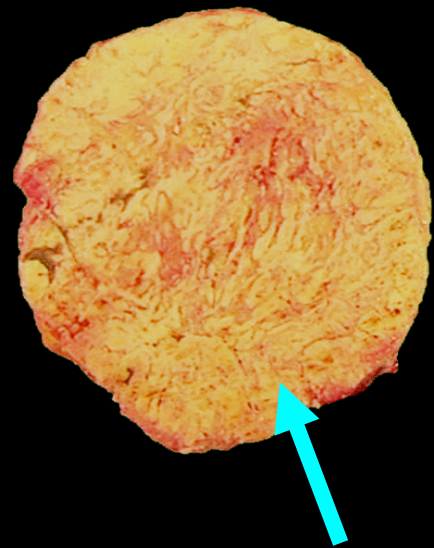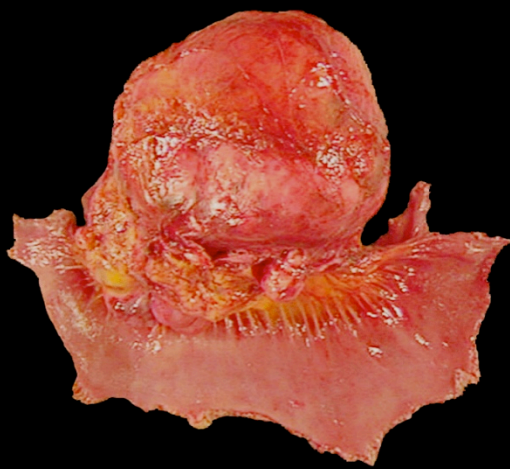
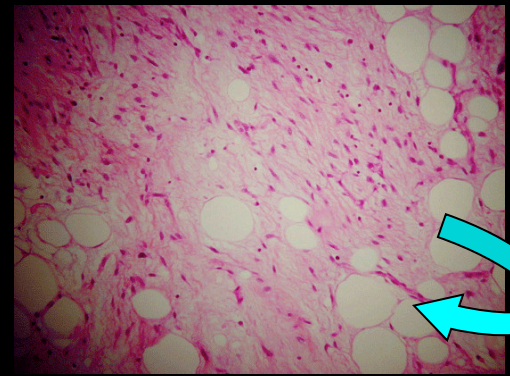
Castelman angio folliculaire

métastase hypervascularisée (Grawitz +++)

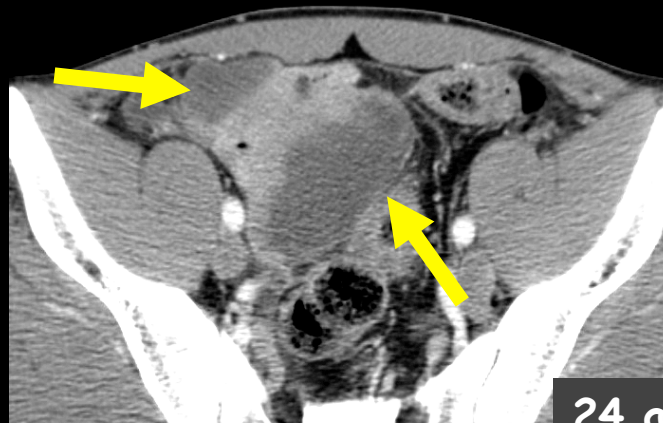
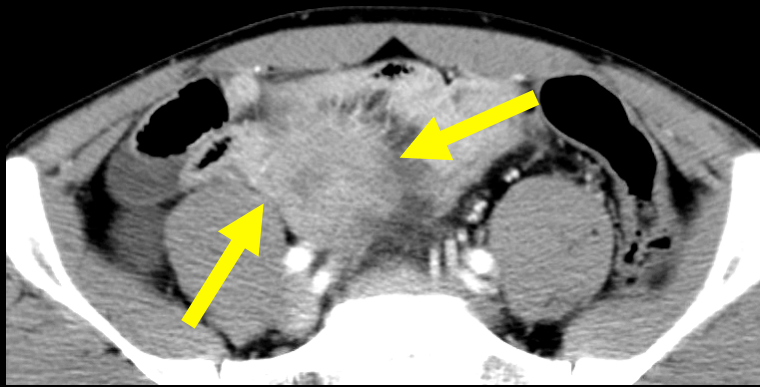
hémangiopéricytome du cul de sac de Douglas ; hypervascularisation +++



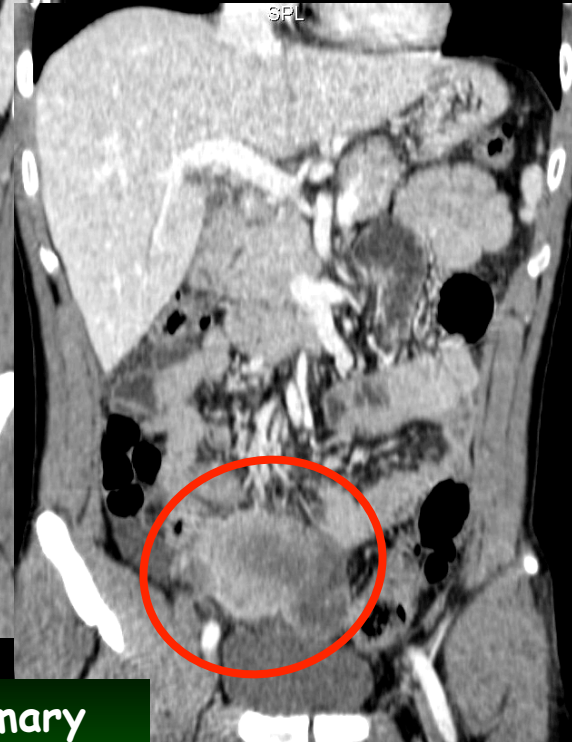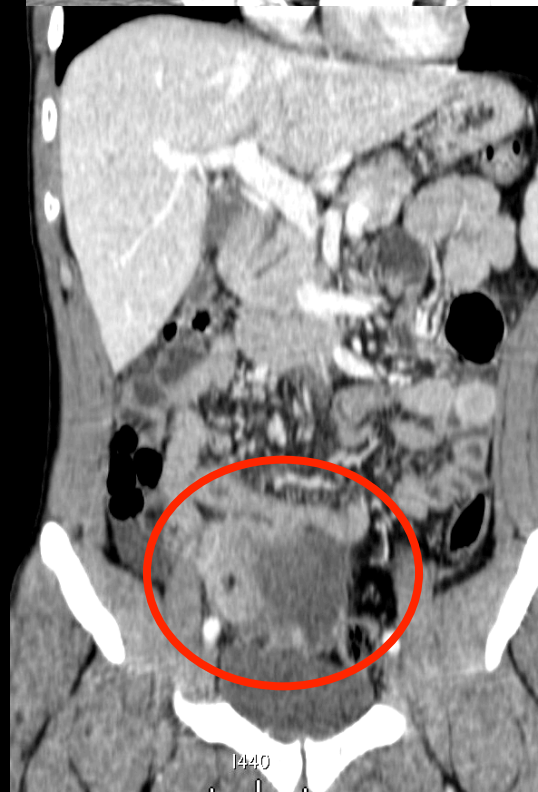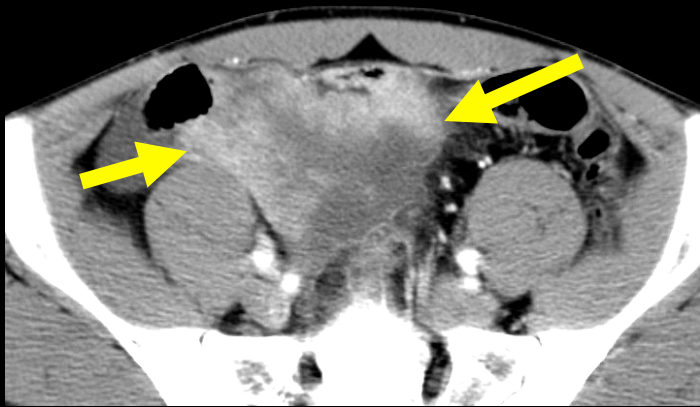
45 ans , pas d'atcd, pas d'atteinte de l'état général .



liposarcome péritonéal avec métaplasie osseuse

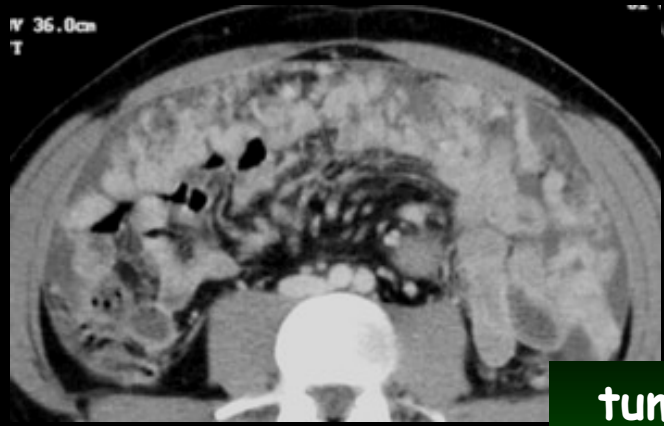
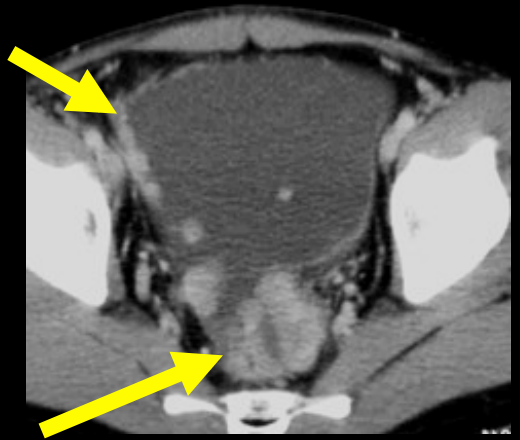
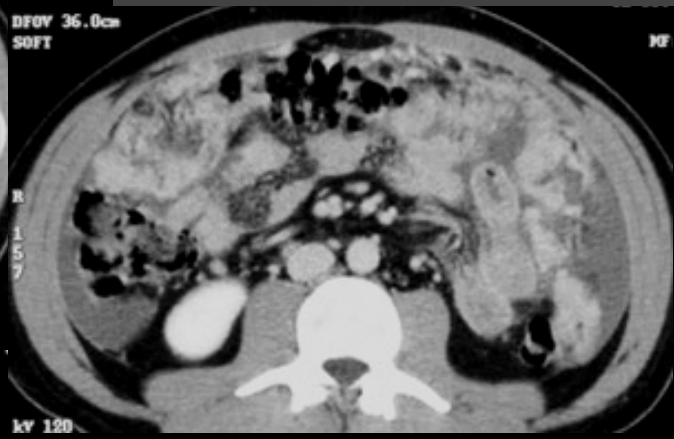
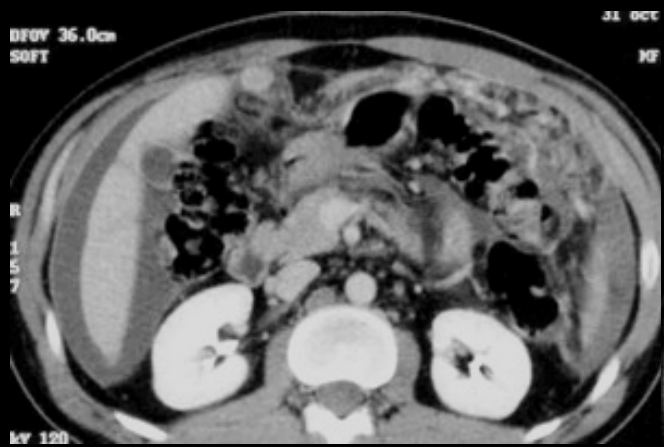


24 ans , pas
d'atcd , tableau
d'appendicite

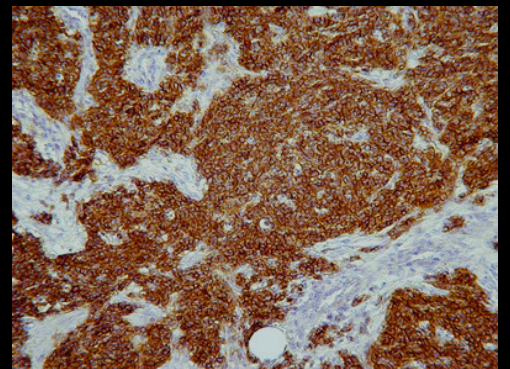
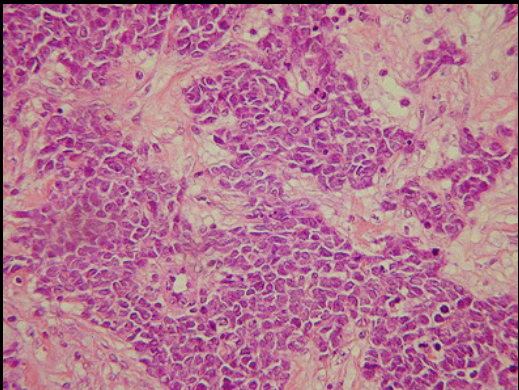
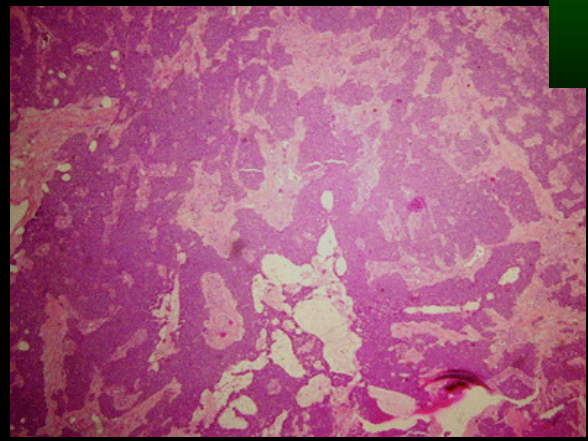


tumeur desmoplastique à petites cellules rondes = PNET (primary
neuro-ectodermique tumor ~ sarcome d'Ewing des tissus mous)

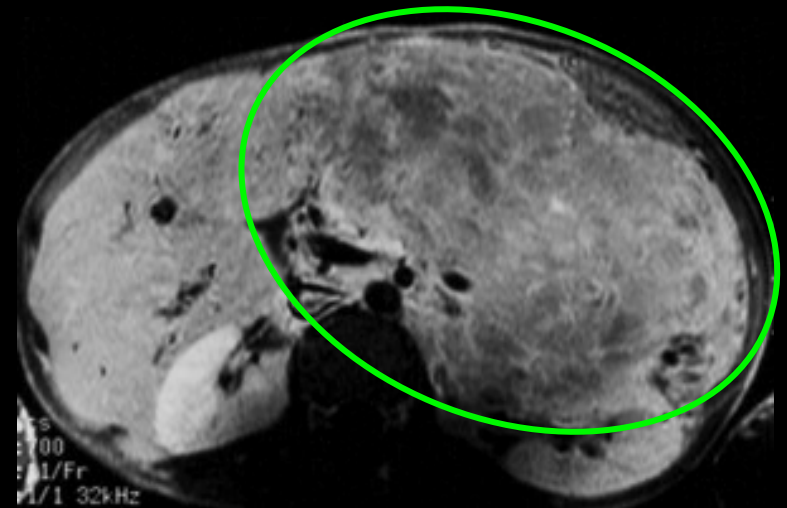
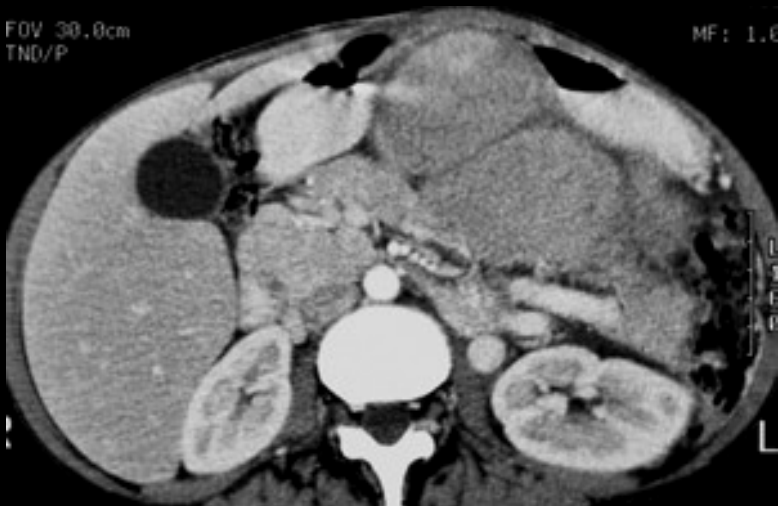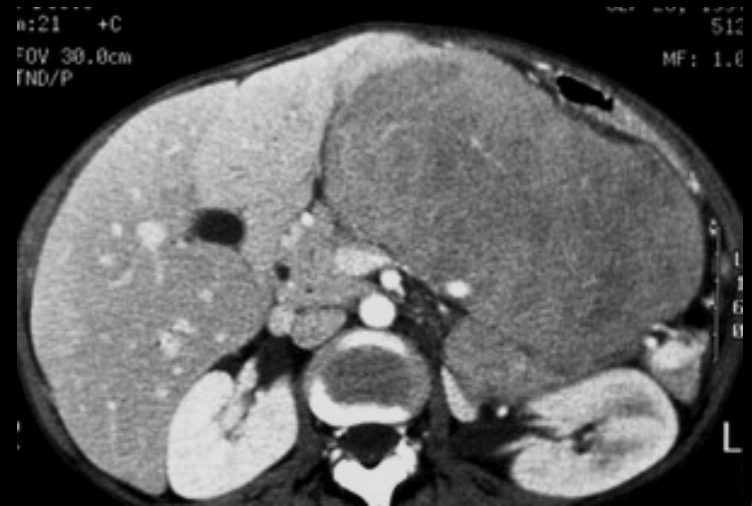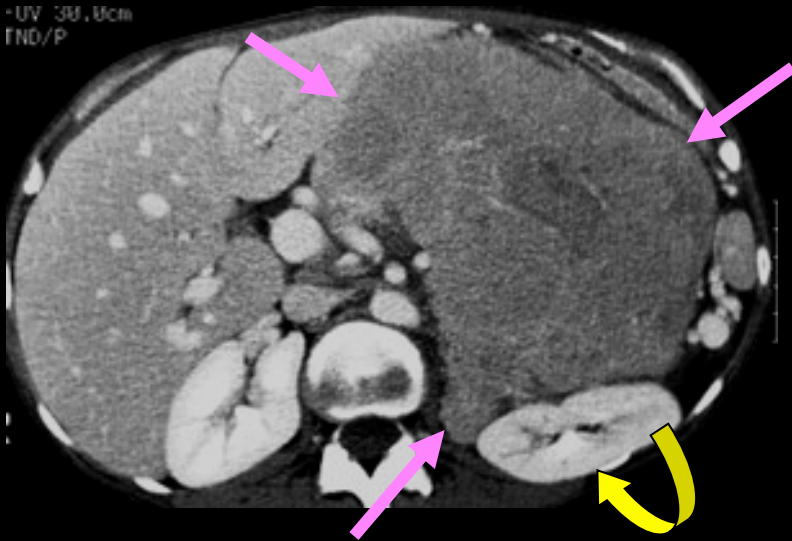homme 44 ans ,atteinte majeure et d'évolution rapide de l'état général



tumeur desmoplastique à petites cellules rondes = PNET (primary neuro-ectodermique tumor ~ sarcome d'Ewing des tissus mous)

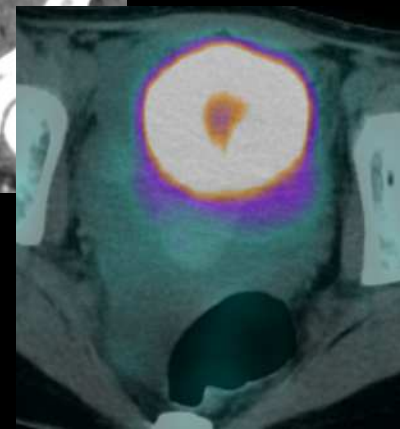
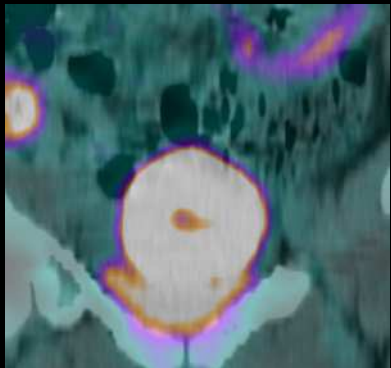
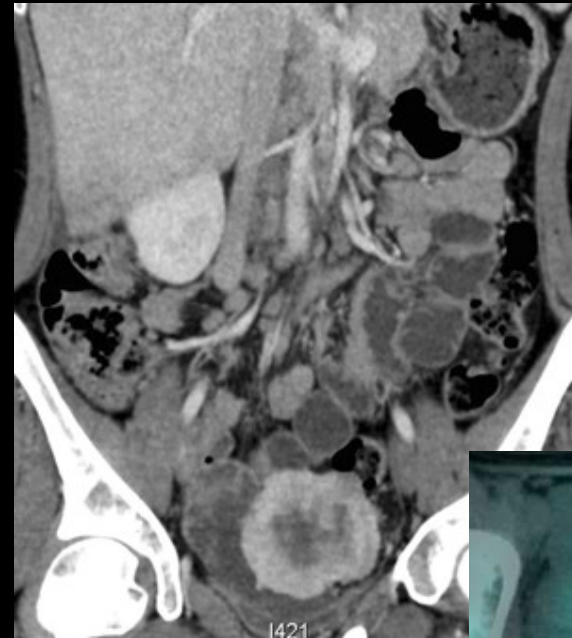
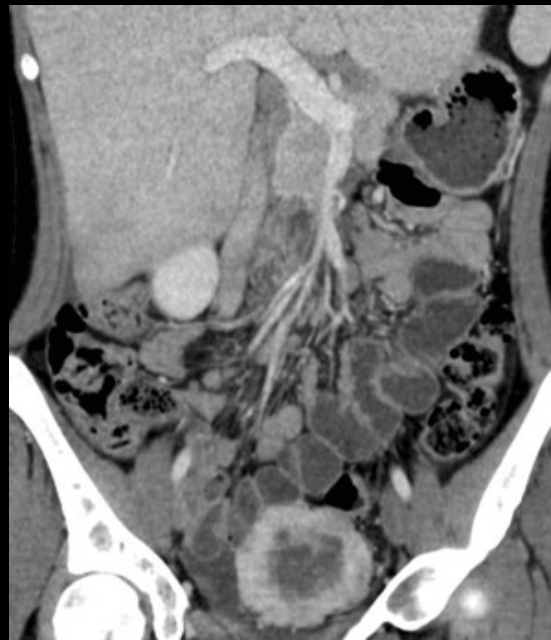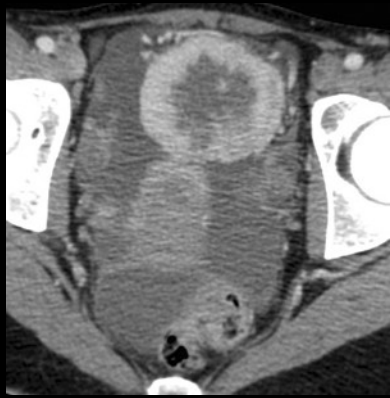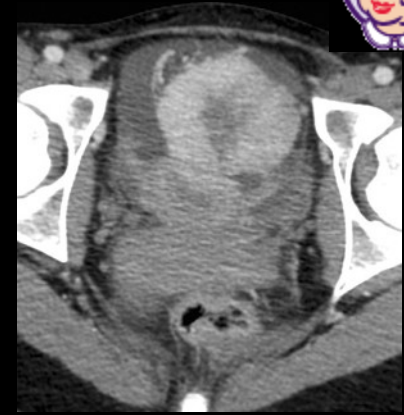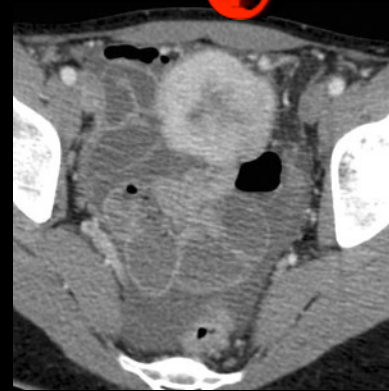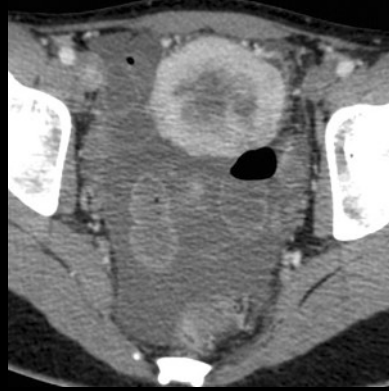


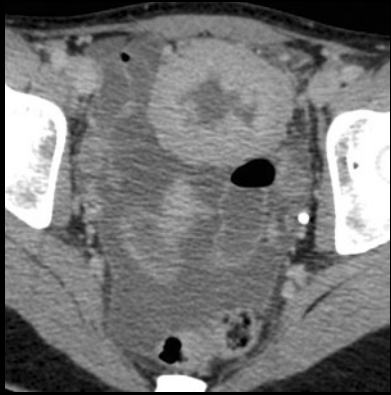jeune femme 28 ans dégradation rapide de l'état général et masse abdominale palpable dure , douloureuse



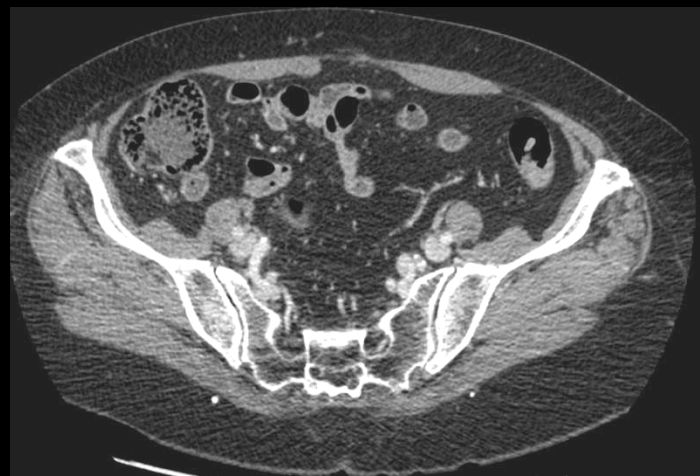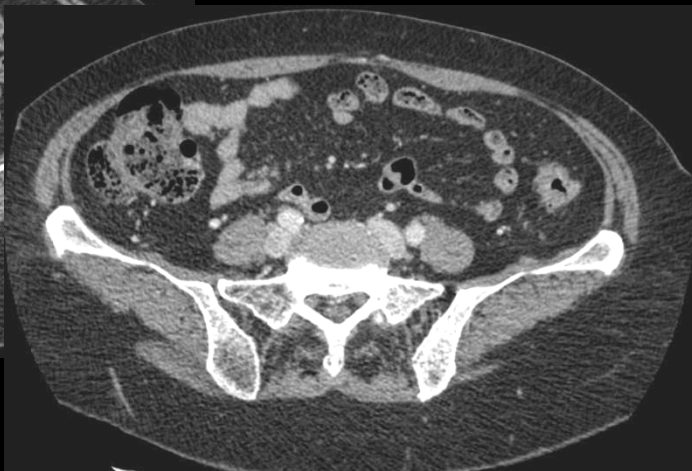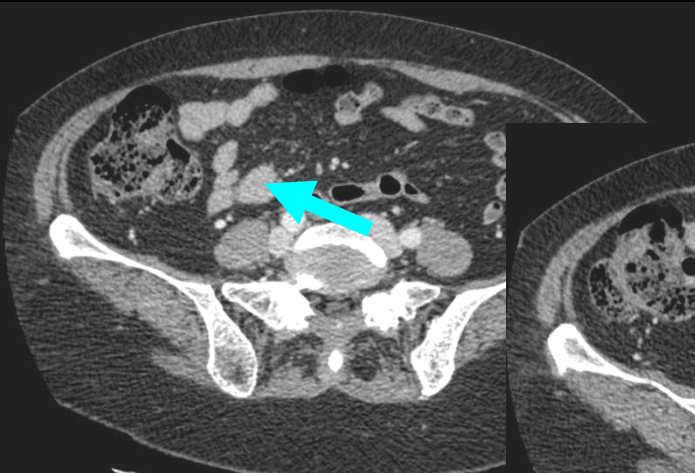
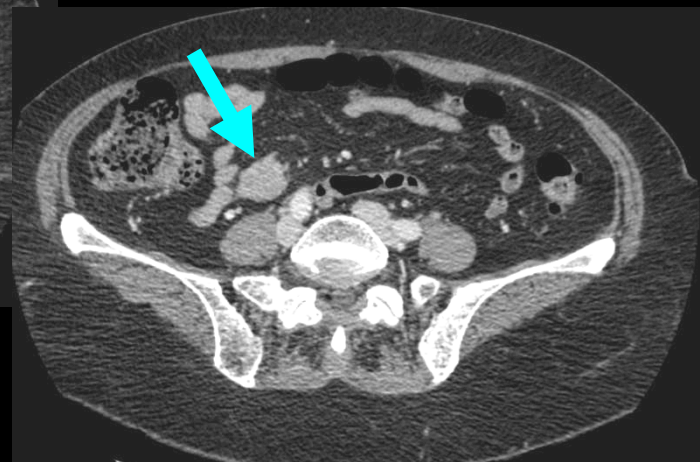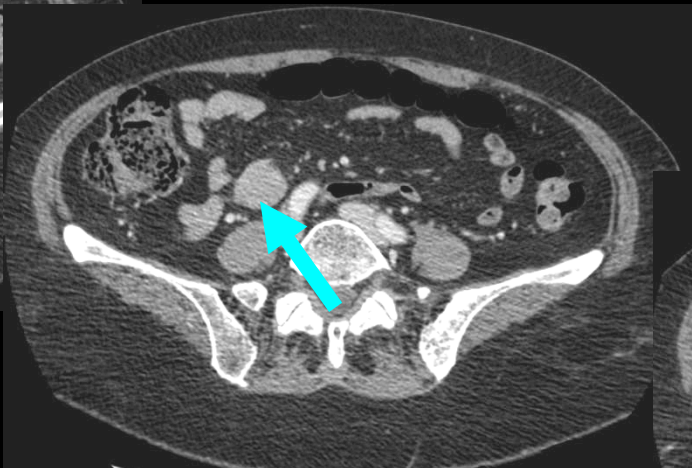
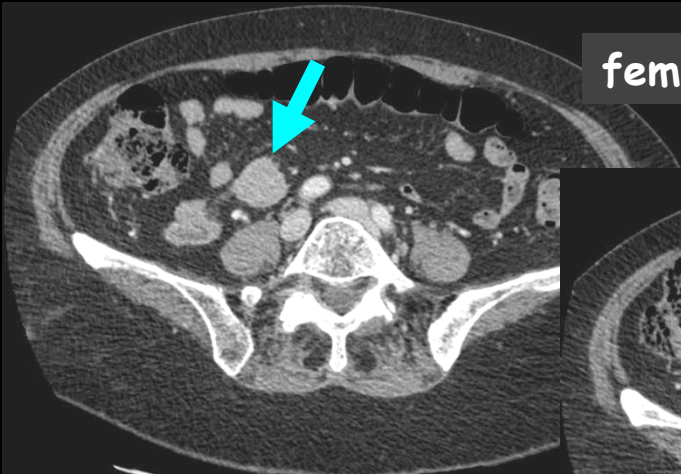histiocytome fibreux malin du péritoine

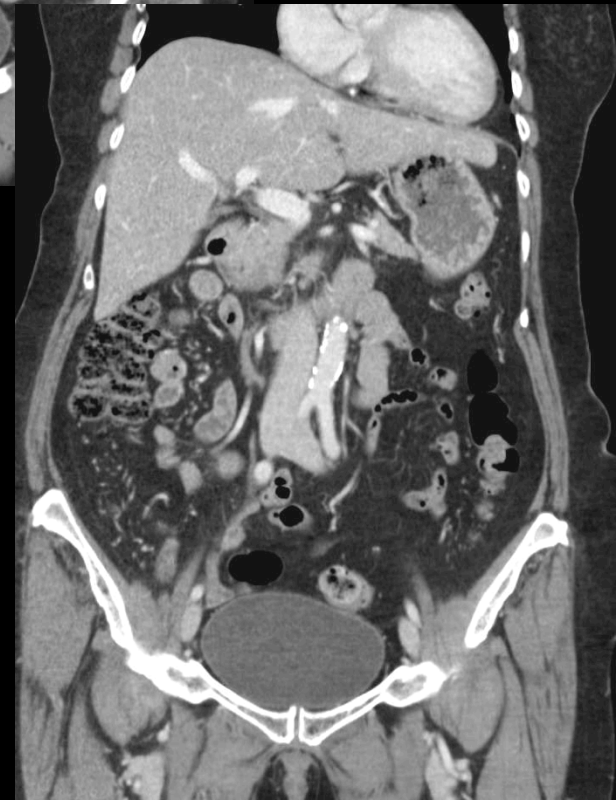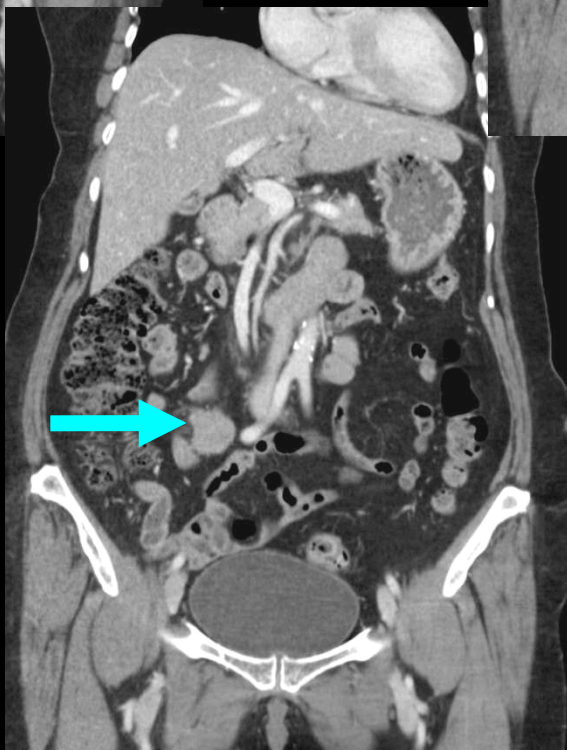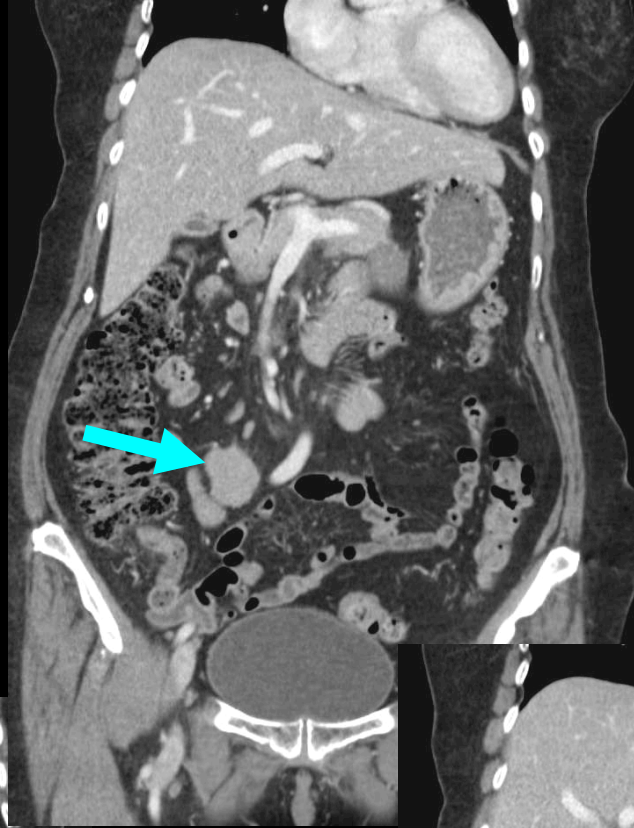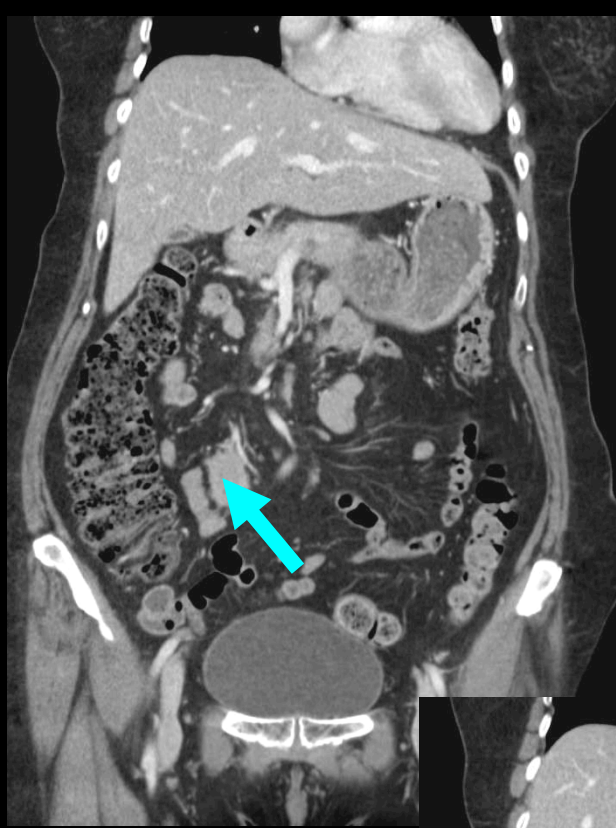jeune fille 20 ans ,douleurs hypogastriques , asthénie



pseudo tumeur inflammatoire ou
tumeur myofibroblastique
sujet jeune ,rehaussement +++

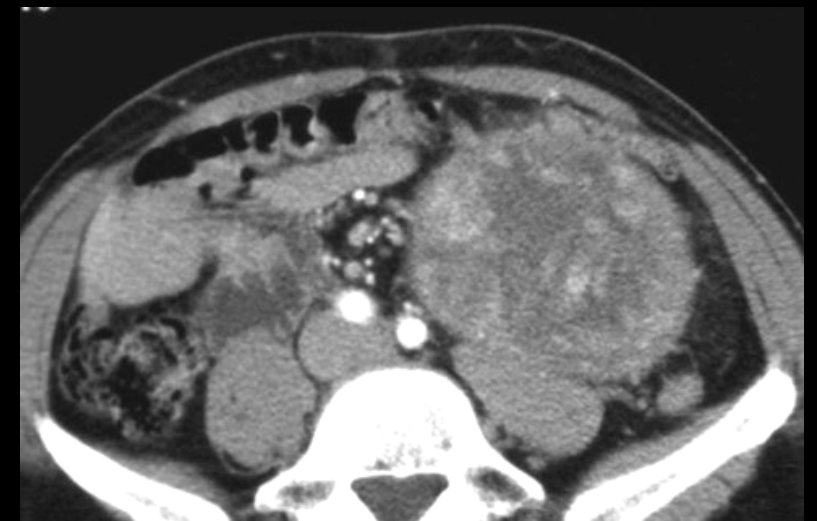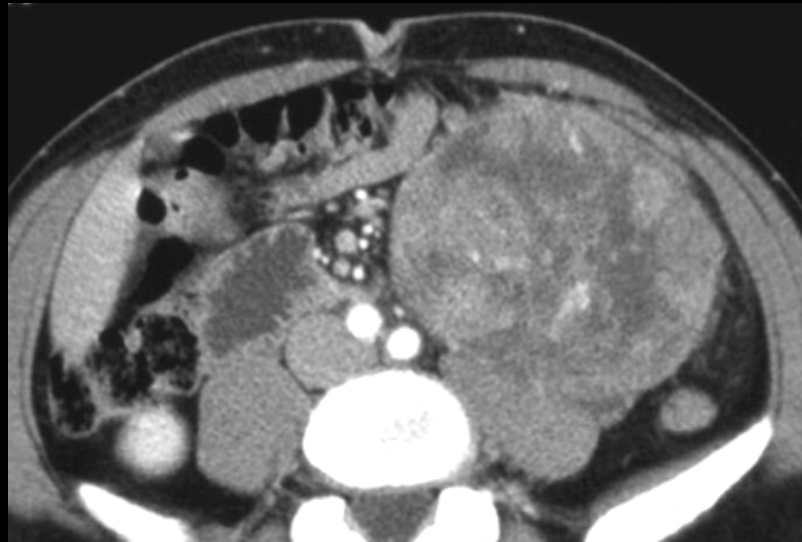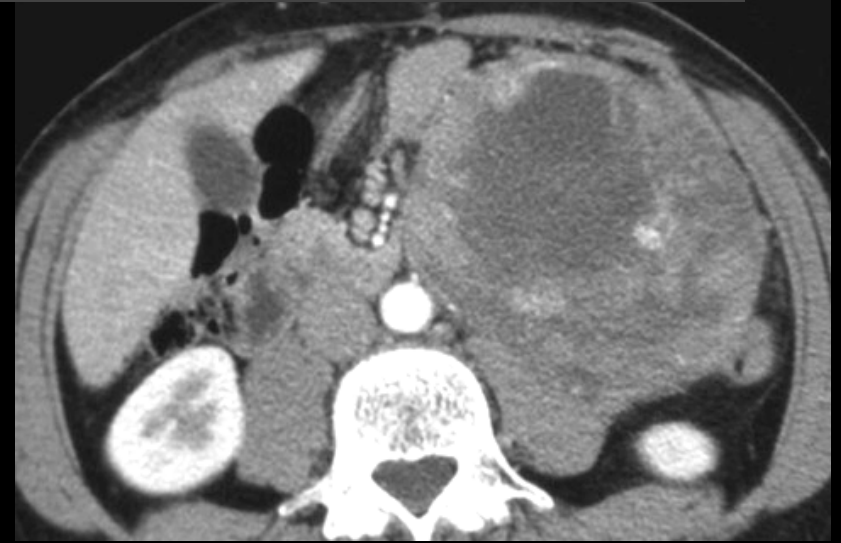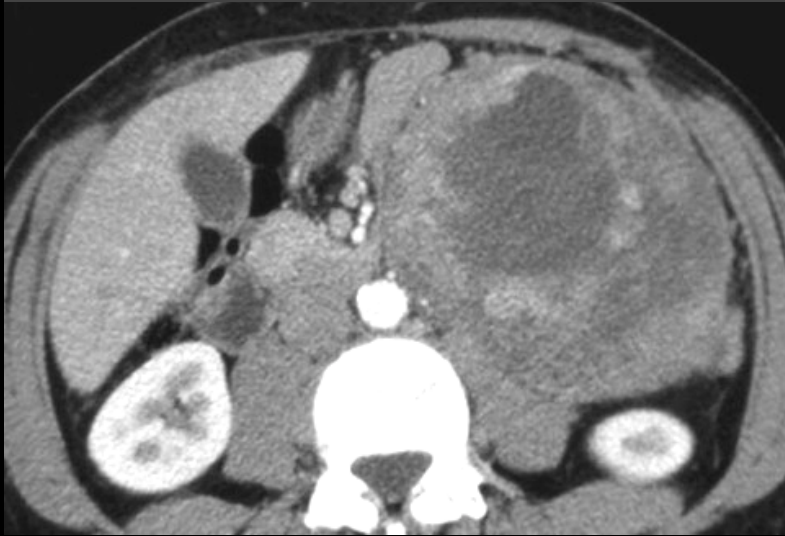femme 47 ans, pseudo polyarthrite rhizomélique atypique





LMNH B diffus à grandes cellules, (CD 20 +)

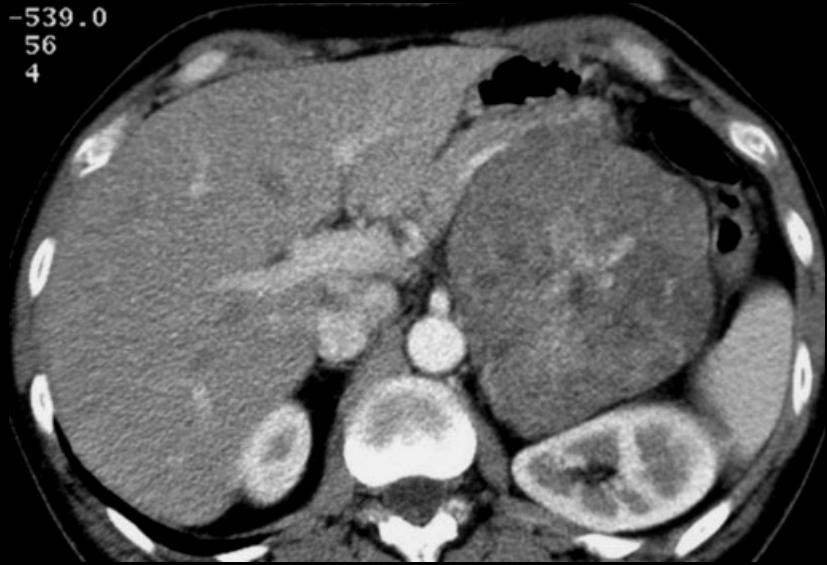
homme 62 ans sans antécédents petite baisse de l'état général ; masse palpable de l'HCG diagnostic du clinicien : splénomégalie ;



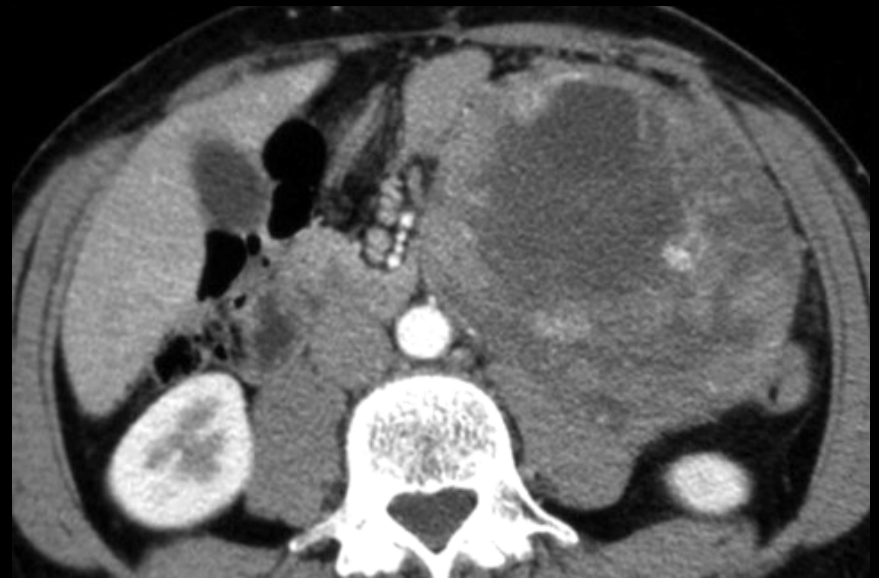
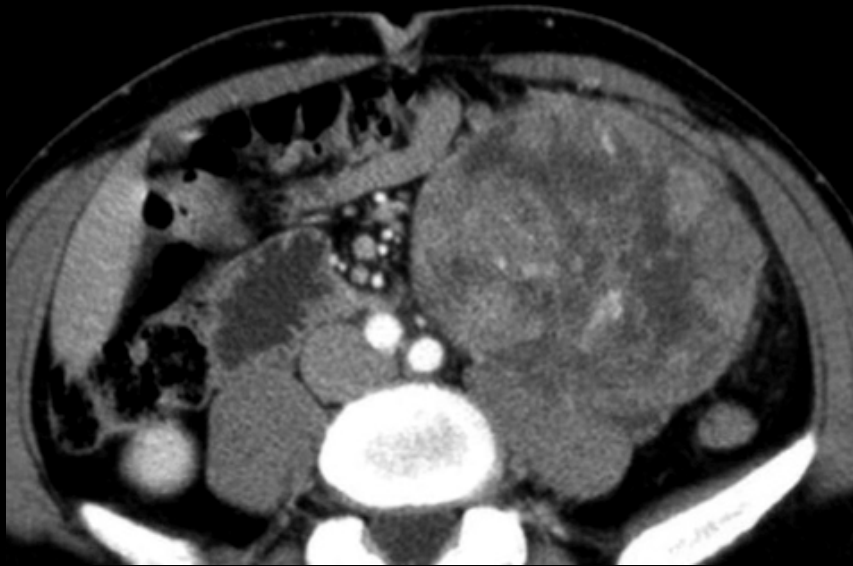
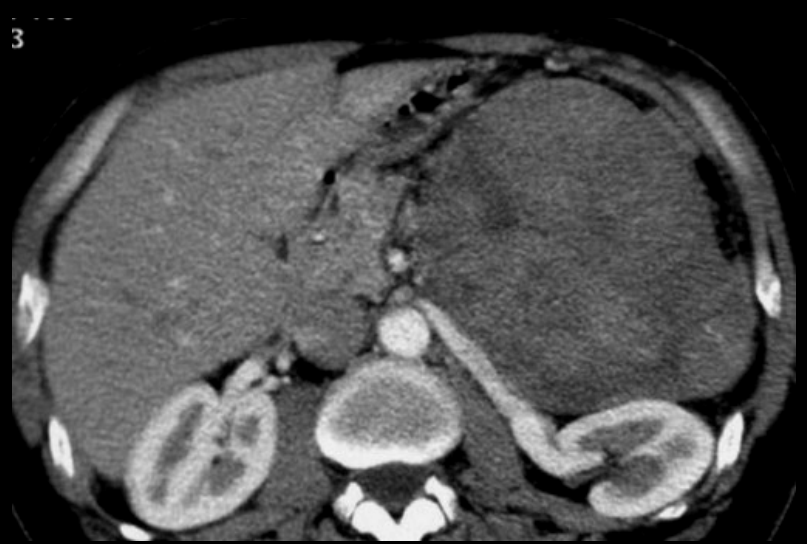diagnostic



-539.0
56
4



3



léiomyosarcome à point de départ **rétrpéritonéal** !!!